

# Bones, joints and muscles of the foot

# Joints of the foot

## Tarsal joints

Talocrural joint

## Intertarsal joints

### Proximal joints

- Subtalar joint
- Talocalcaneonavicularis joint
- Calcaneocuboideal joint

### Distal joints

- Cuneonavicular joint
- Cuneocuboideal joint
- Naviculocuboideal joint

Interphalangeal joints

Metatarsophalangeal joints

Intermetatarsal joints

Tarsometatarsal joints

# Joints of the foot

## Tarsal joints

**Talocrural joint**

Tarsometatarsal joints

Intermetatarsal joints

Metatarsophalangeal joints

Interphalangeal joints

Intertarsal joints

### Proximal joints

- Subtalar joint
- Talocalcaneonavicularis joint
- Calcaneocuboideal joint

### Distal joints

- Cuneonavicular joint
- Cuneocuboideal joint
- Naviculocuboideal joint

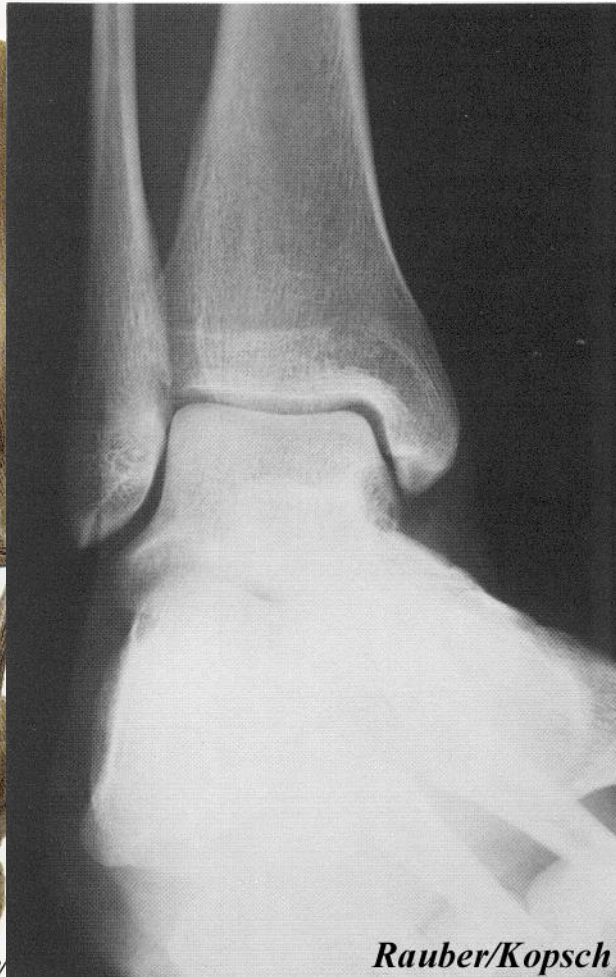
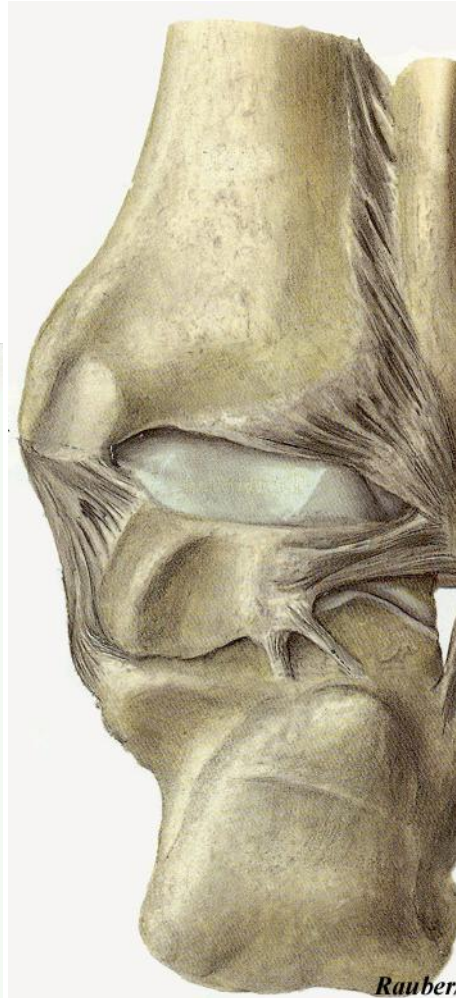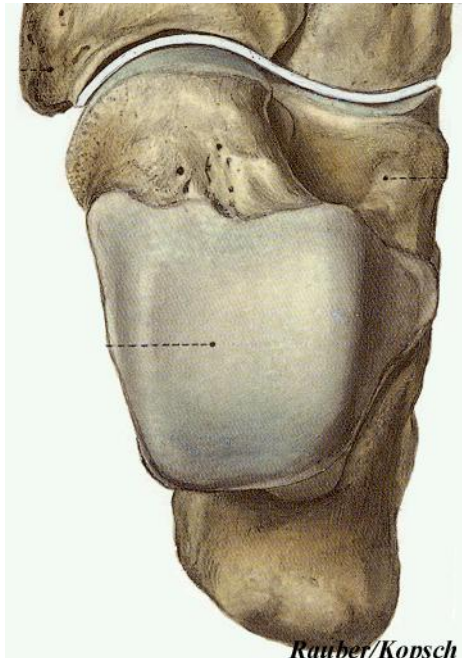
# Upper ankle joint

## *Movement and weight transmission*

### Talocrural joint

### Convexity and concavity

- Malleoli at different levels
- „fork”
- width of trochlea tali



# Upper ankle joint - capsule and ligaments

## Capsule

- Malleoli outside

## Collateral ligaments

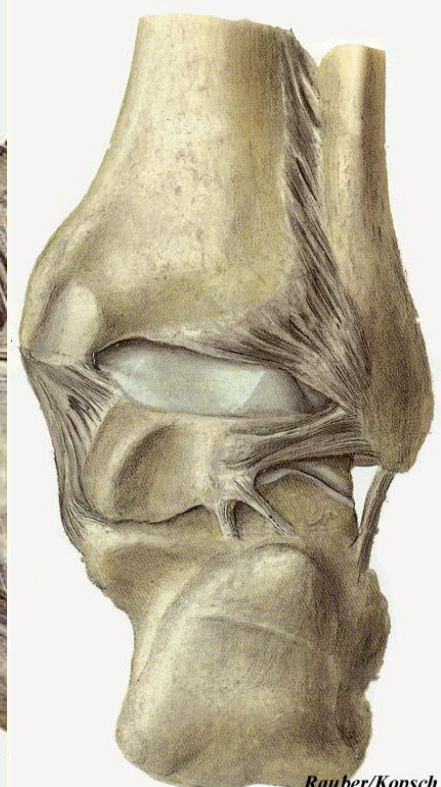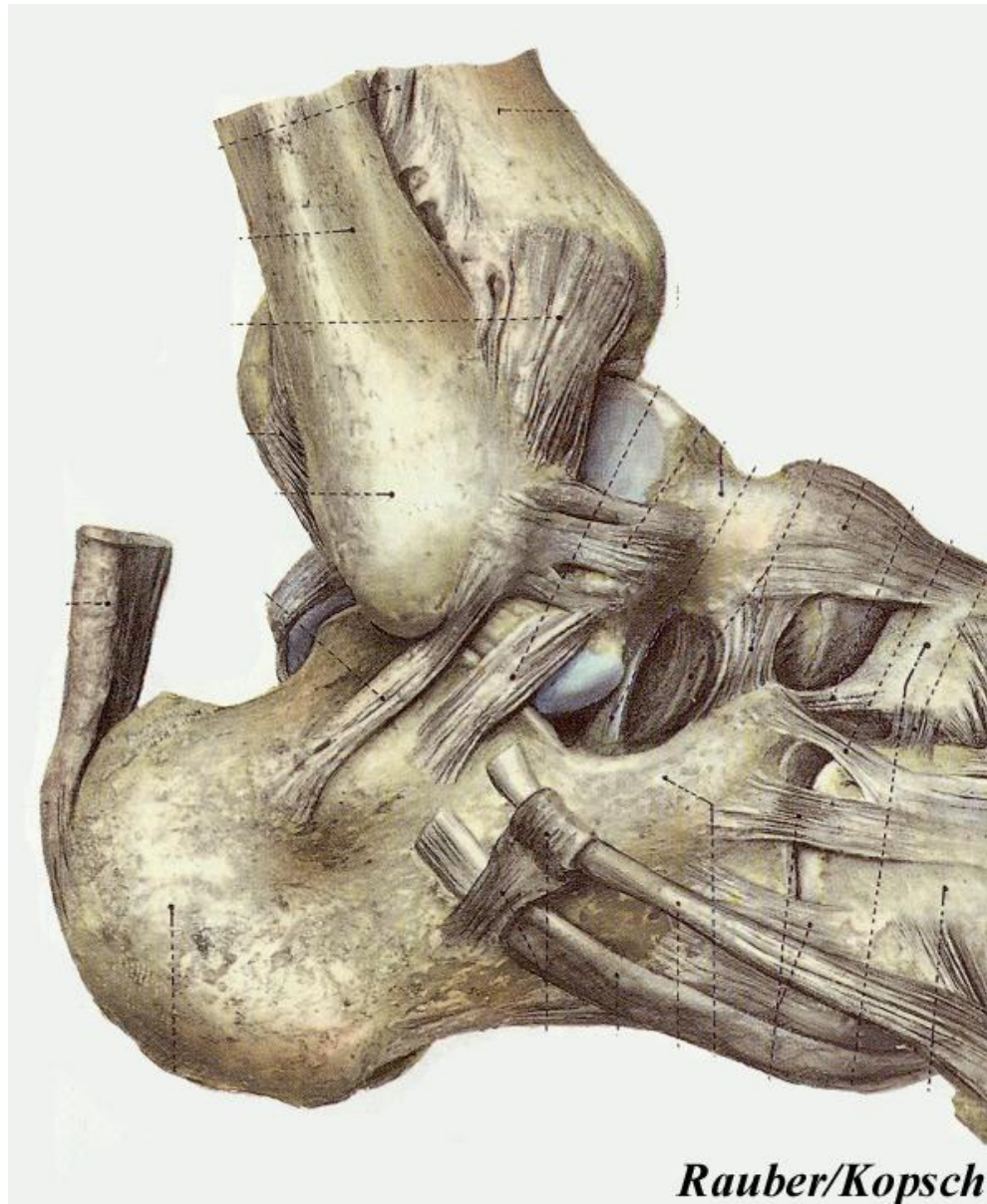*stability*

## Medially

- Deltoid lig. (4 parts)

## Laterally

- Ant. talofibular lig. (main stabilisator)
- Post. talofibular lig.
- Calcaneofibular lig.



# Upper ankle joint - Stability

## In the frontal plane

- collateral fibres and ligaments

## In Plantarflexion

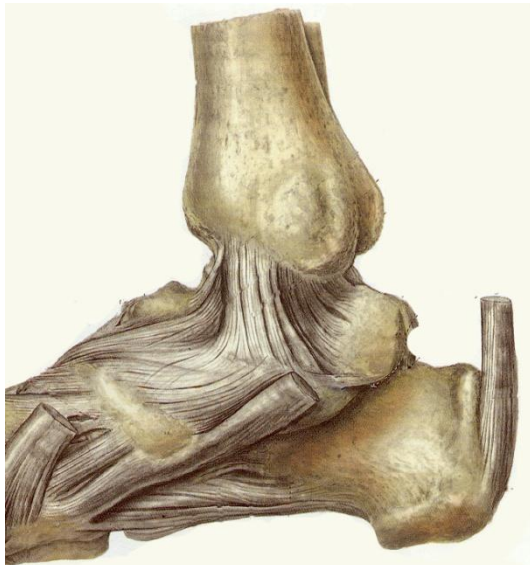
- anterior ligaments (ant. tibiotalar part, tibionavicular part; ant. talofibulare part)

## In Dorsalflexion

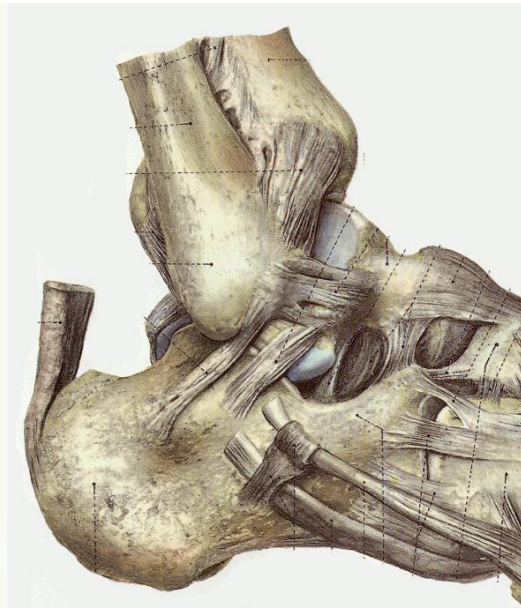
- posterior ligaments (post. tibiotalar part, post. talofibulare part)
- shape of trochlea tali

hinge joint

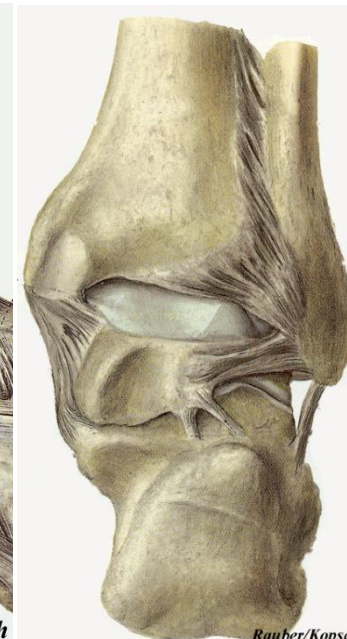
+ „rotation” (side movements)



Rauber/Kopsch



Rauber/Kopsch



Rauber/Kopsch

# Joints of the foot

## Tarsal joints

Talocrural joint

## Intertarsal joints

### Proximal joints

- Subtalar joint
- Talocalcaneonavicularis joint
- Calcaneocuboideal joint

### Distal joints

- Cuneonavicular joint
- Cuneocuboideal joint
- Naviculocuboideal joint

Tarsometatarsal joints

Intermetatarsal joints

Metatarsophalangeal joints

Interphalangeal joints

# Lower ankle joint - Talotarsal joint

## Talocalcaneonavicular joint

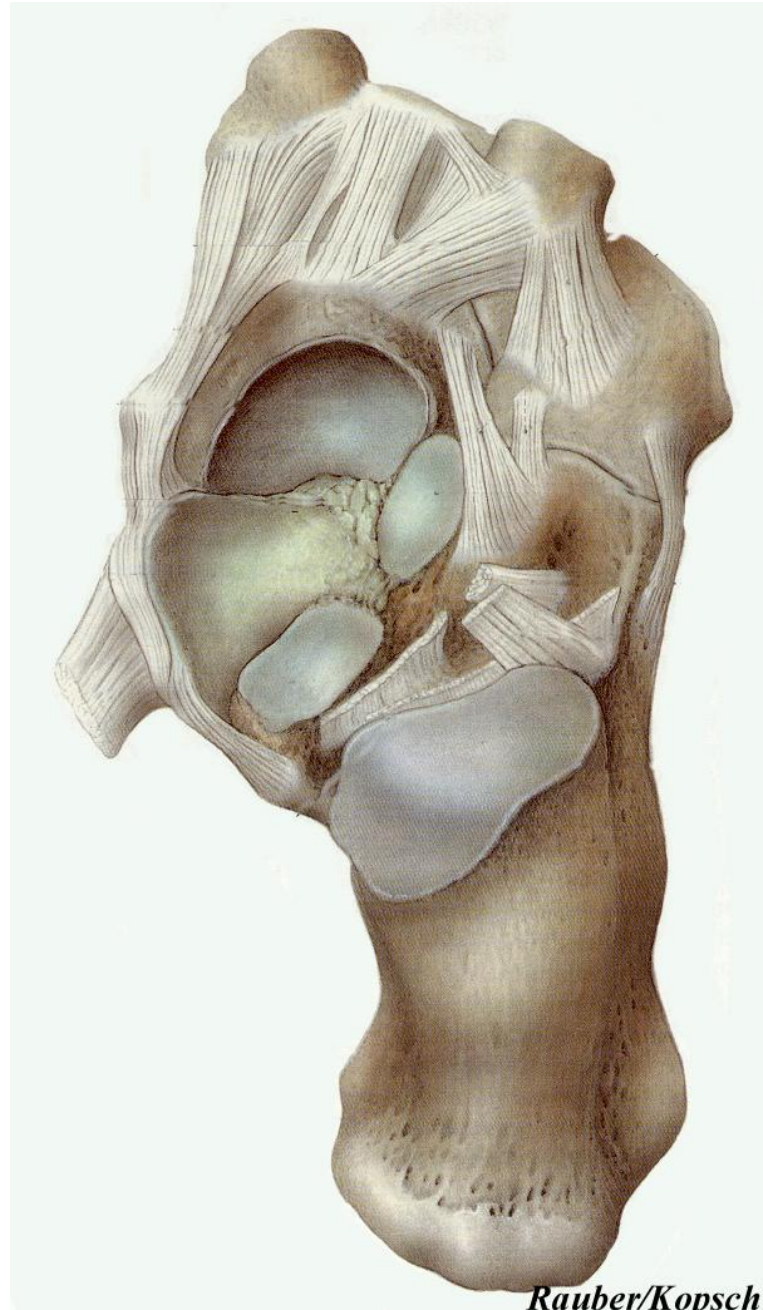
- ball and socket joint
- spring ligament

## *Tarsal sinus*

- *Interosseal talocalcaneal ligament*

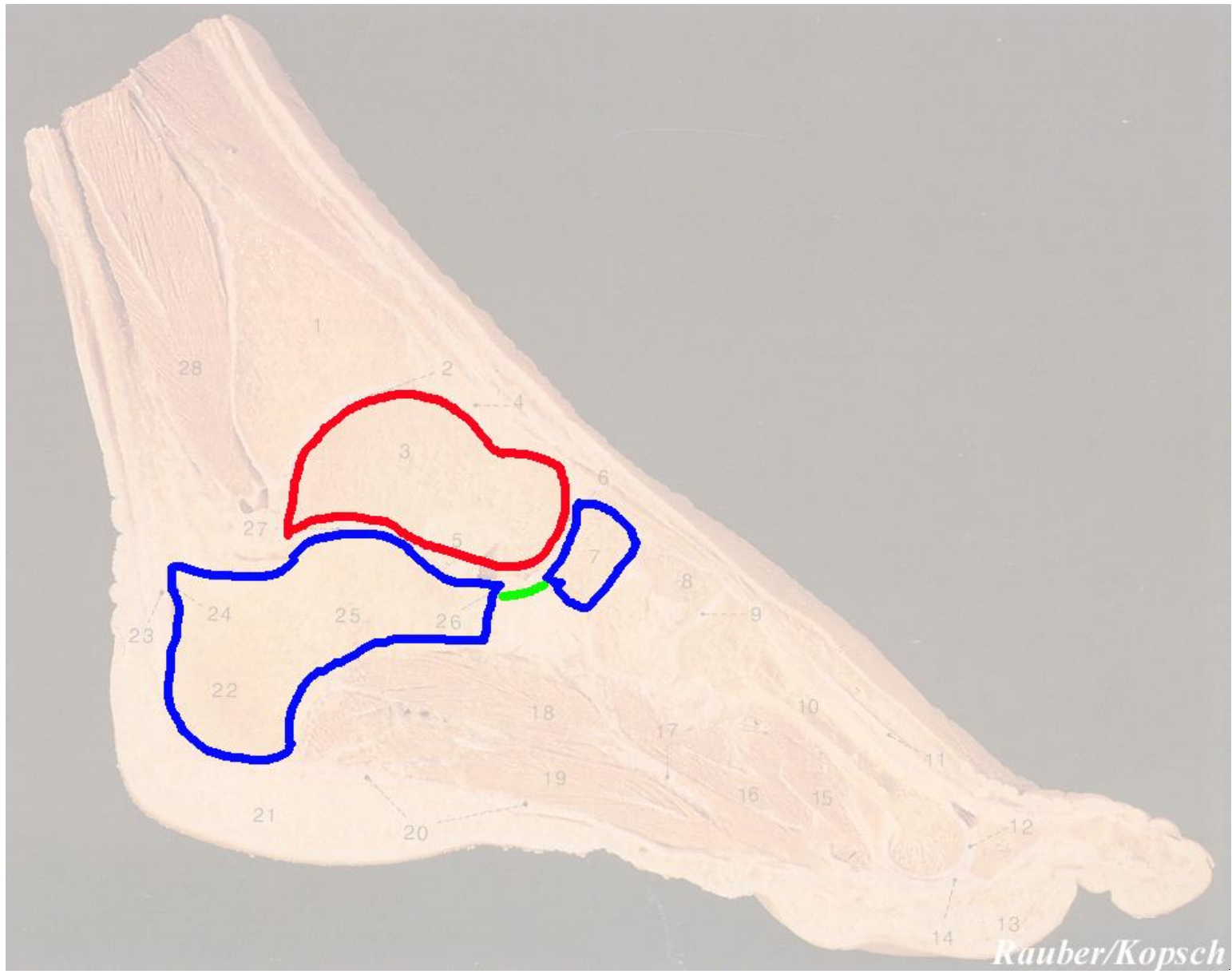
## Subtalar joint (Post. talocalcaneal joint)

- hinge joint
- separated joint cavity





# Lower ankle joint - Talotarsal joint

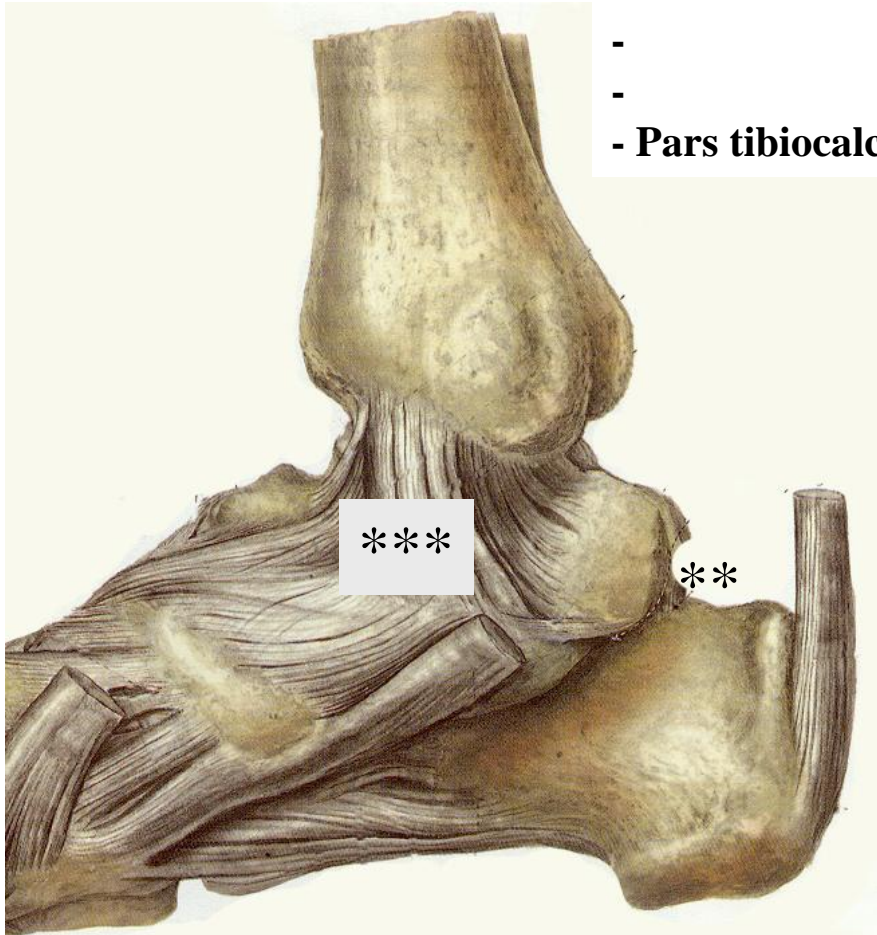


# Lower ankle joint - Ligaments, dorsal side

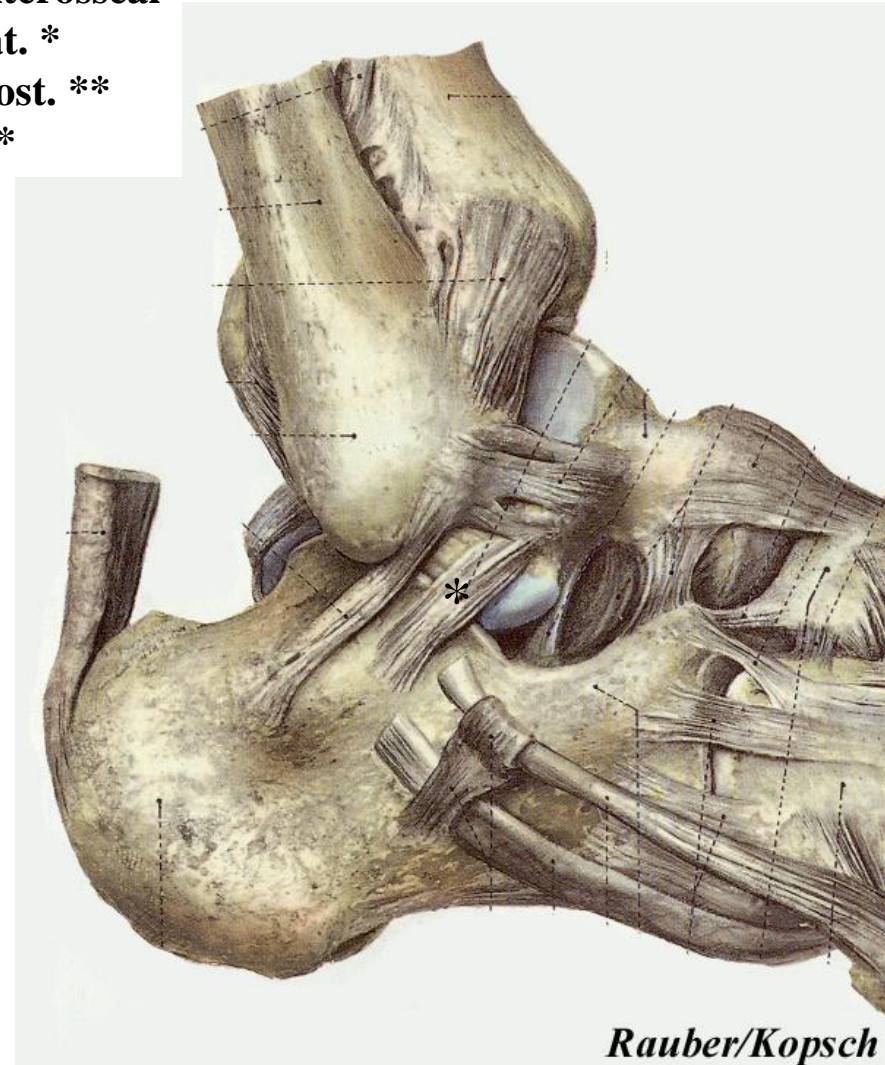
## Subtalar joint

### - Talocalcaneal ligaments

- interosseal lat. \*
- post. \*\*
- Pars tibiocalcanea \*\*\*



*Rauber/Kopsch*

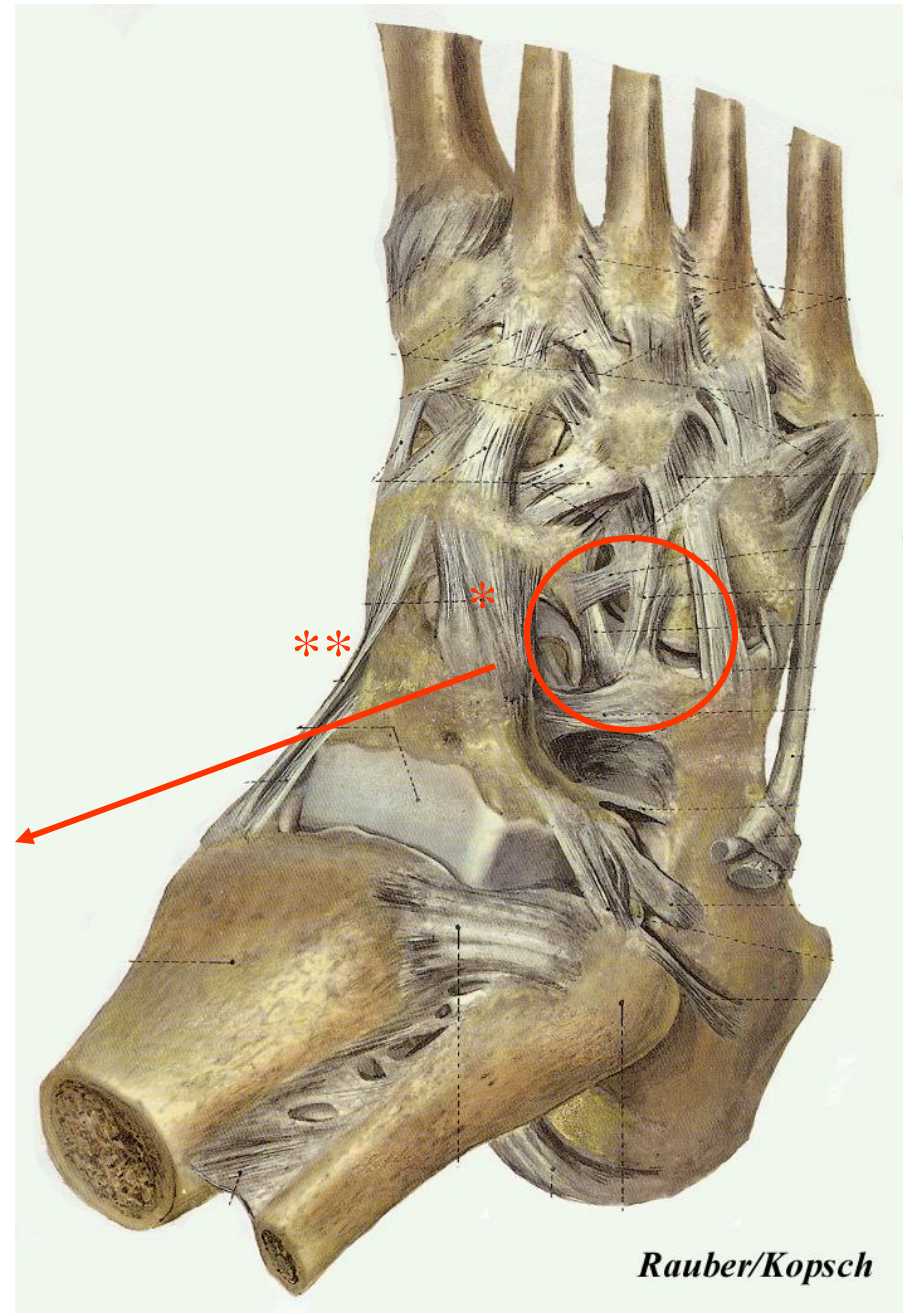
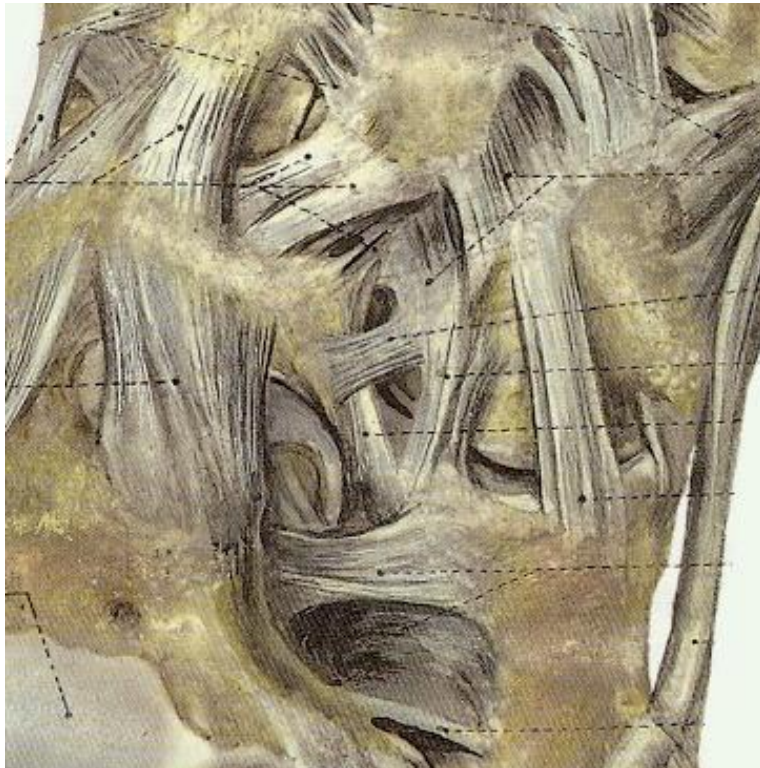

*Rauber/Kopsch*

# Lower ankle joint - Ligaments, dorsal side

## Talocalcaneonavicular joint

- Talonavicular lig. \*
  - Tibionavicular part \*\*
  - 
  - Bifurcate lig.
- Calcaneonavicular and calcaneocuboideal ligaments



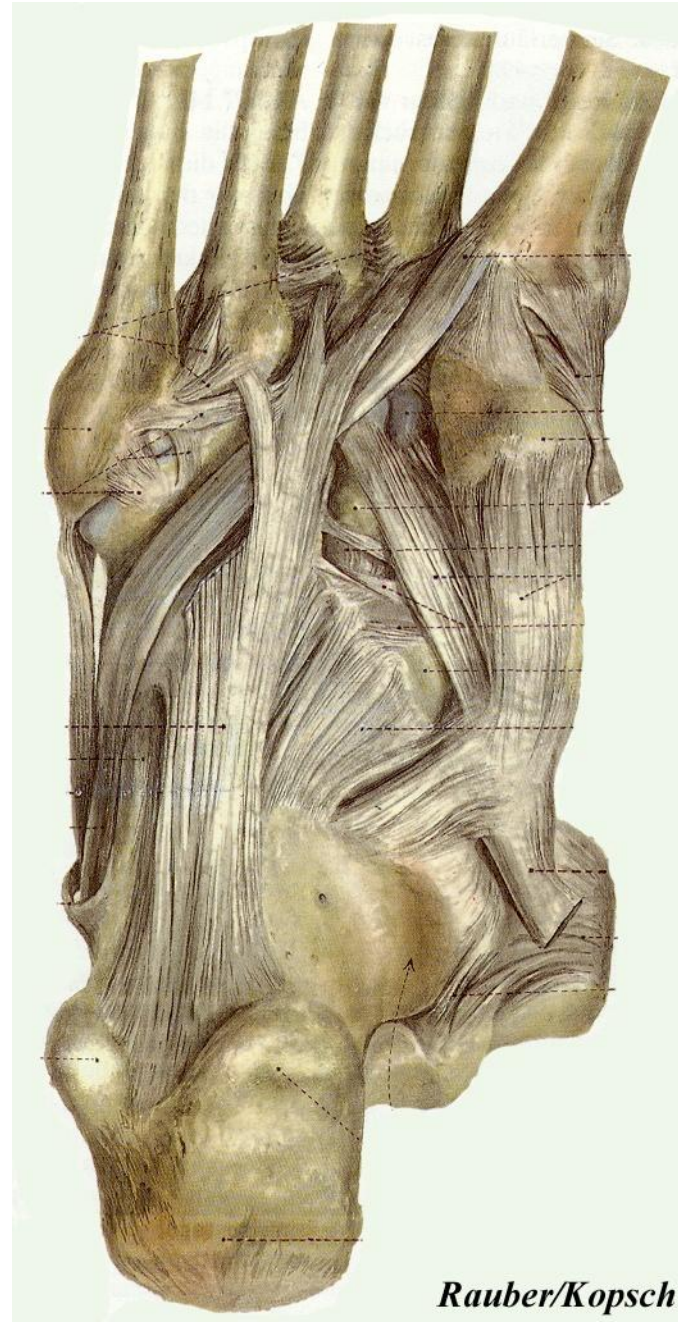# Lower ankle joint - Ligaments, plantar side

## Capsule

- not in the casual sense
  - spring ligament
- tenses arches of foot, no weight carrying
- Long plantar ligament

## Pivot joint

- Inversion and Eversion



# Joints of the foot

## Tarsal joints

Tarsometatarsal joints

Intermetatarsal joints

Metatarsophalangeal joints

Interphalangeal joints

## Intertarsal joints

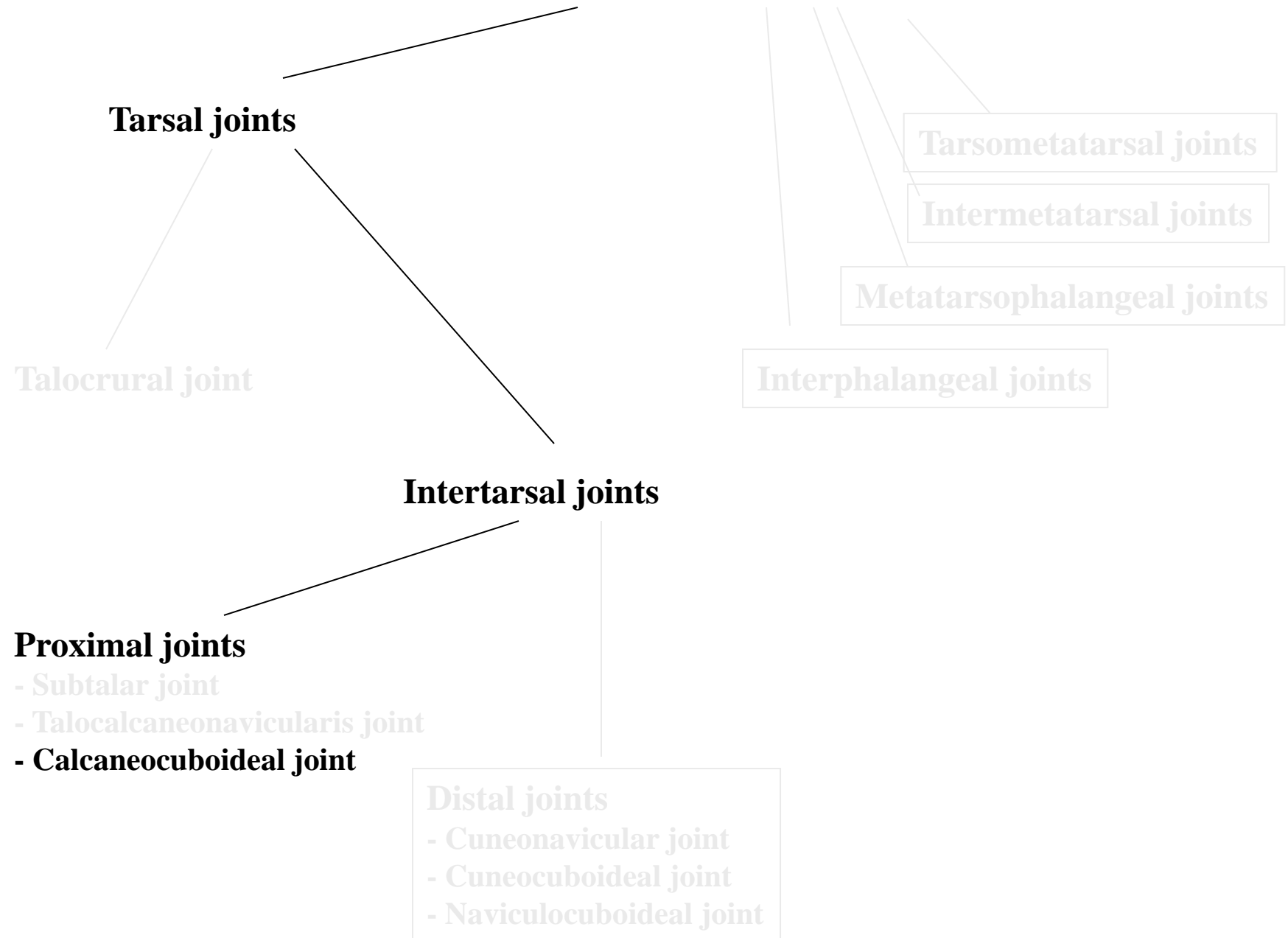
### Distal joints

- Cuneonavicular joint
- Cuneocuboideal joint
- Naviculocuboideal joint

## Proximal joints

- Subtalar joint
- Talocalcaneonavicularis joint
- Calcaneocuboideal joint

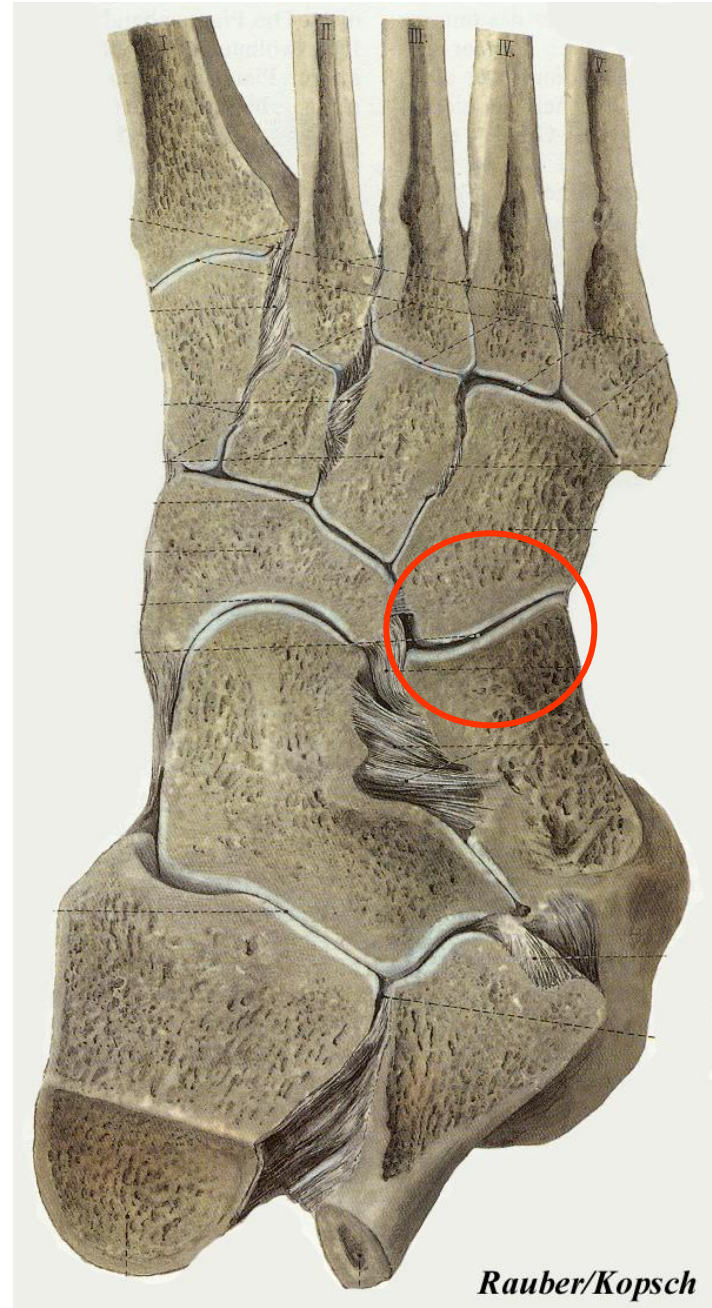Talocrural joint



# Calcaneocuboideal joint

## Shape, movements

- saddle joint
- Amphiarthrosis



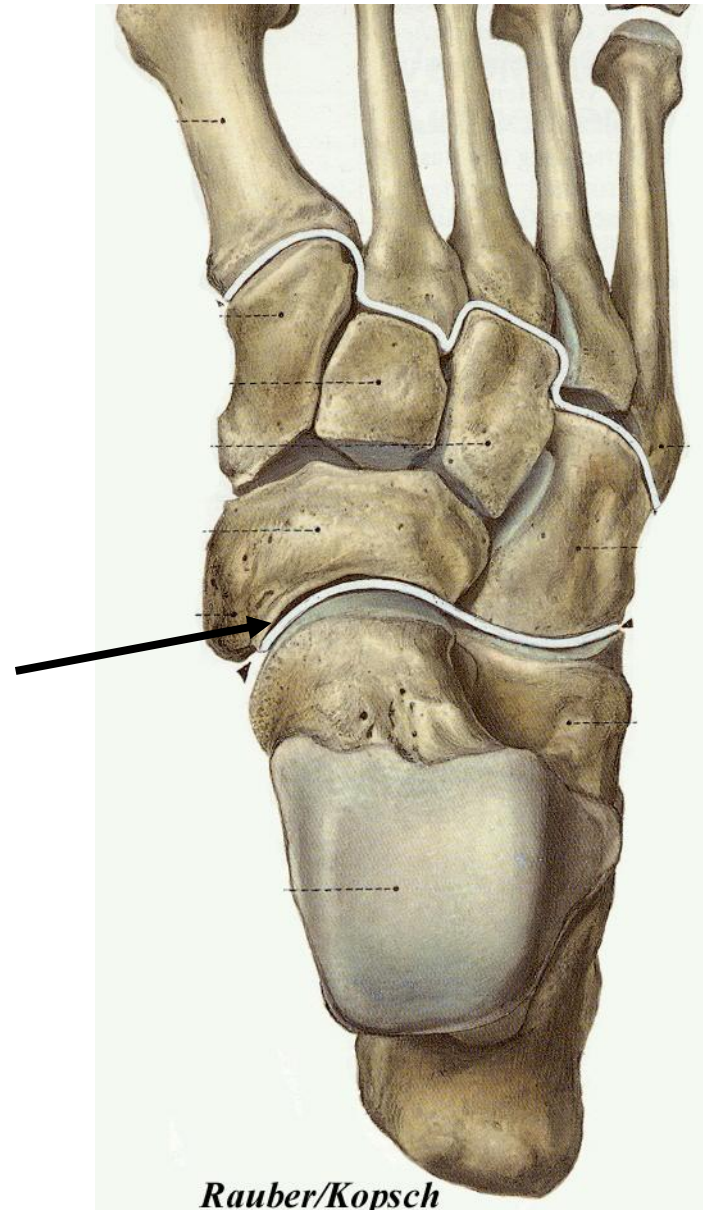# Transverse tarsal joint (joint of Chopart)

## Shape, movements

### Talonavicular and calcaneocuboideal joints

- separated joint cavities
- not an amphiarthrosis
- key for splay-foot (longitudinal arch)
- strong ligaments

### Bifurcate ligament



# Joints of the foot

## Tarsal joints

Talocrural joint

## Intertarsal joints

### Proximal joints

- Subtalar joint
- Talocalcaneonavicularis joint
- Calcaneocuboideal joint

### Distal joints

- Cuneonavicular joint
- Cuneocuboideal joint
- Naviculocuboideal joint

Tarsometatarsal joints

Intermetatarsal joints

Metatarsophalangeal joints

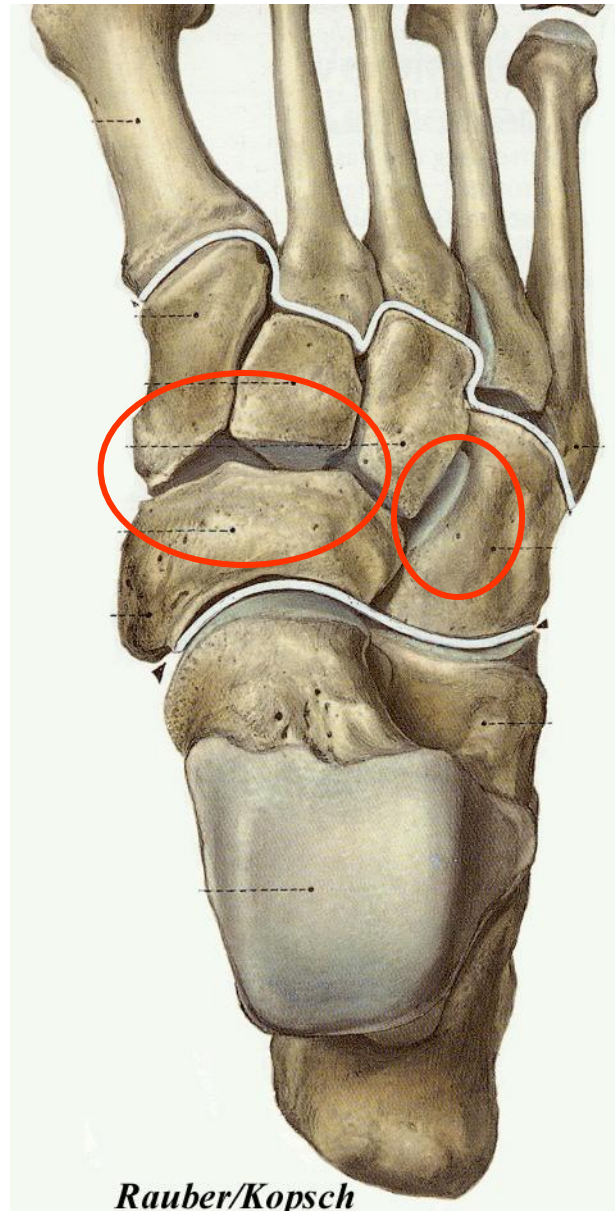
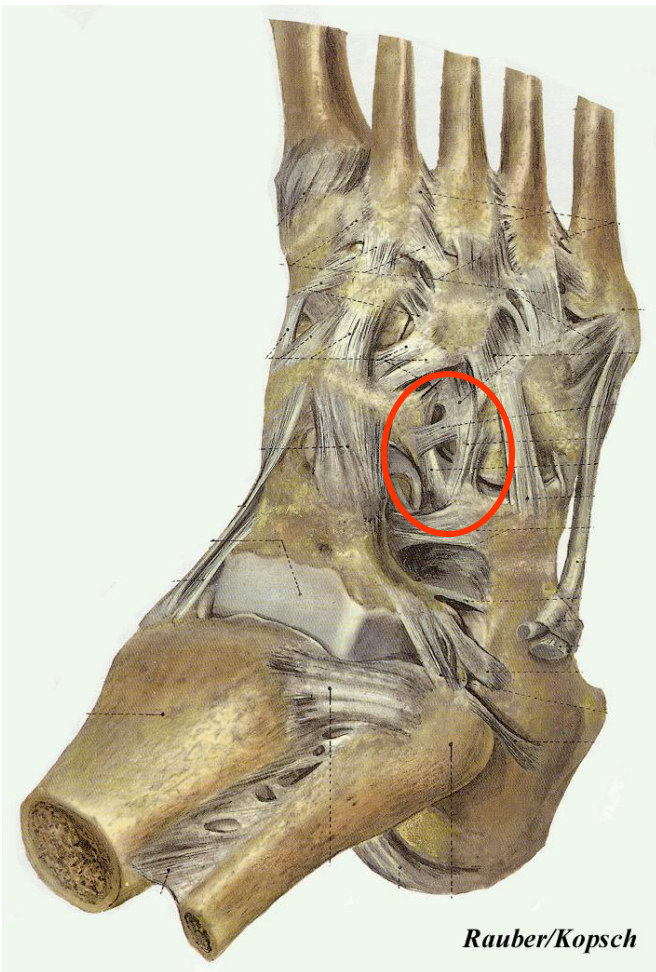Interphalangeal joints



# Cuneonavicular and cuneocuboideal joints

## Shape, movements

- Amphiarthrosis
- adaptation to ground at walk
- transverse arches (strong ligaments)



# Joints of the foot

**Tarsal joints**

**Tarsometatarsal joints**

Intermetatarsal joints

Metatarsophalangeal joints

Interphalangeal joints

**Intertarsal joints**

**Proximal joints**

- Subtalar joint
- Talocalcaneonavicularis joint
- Calcaneocuboideal joint

**Distal joints**

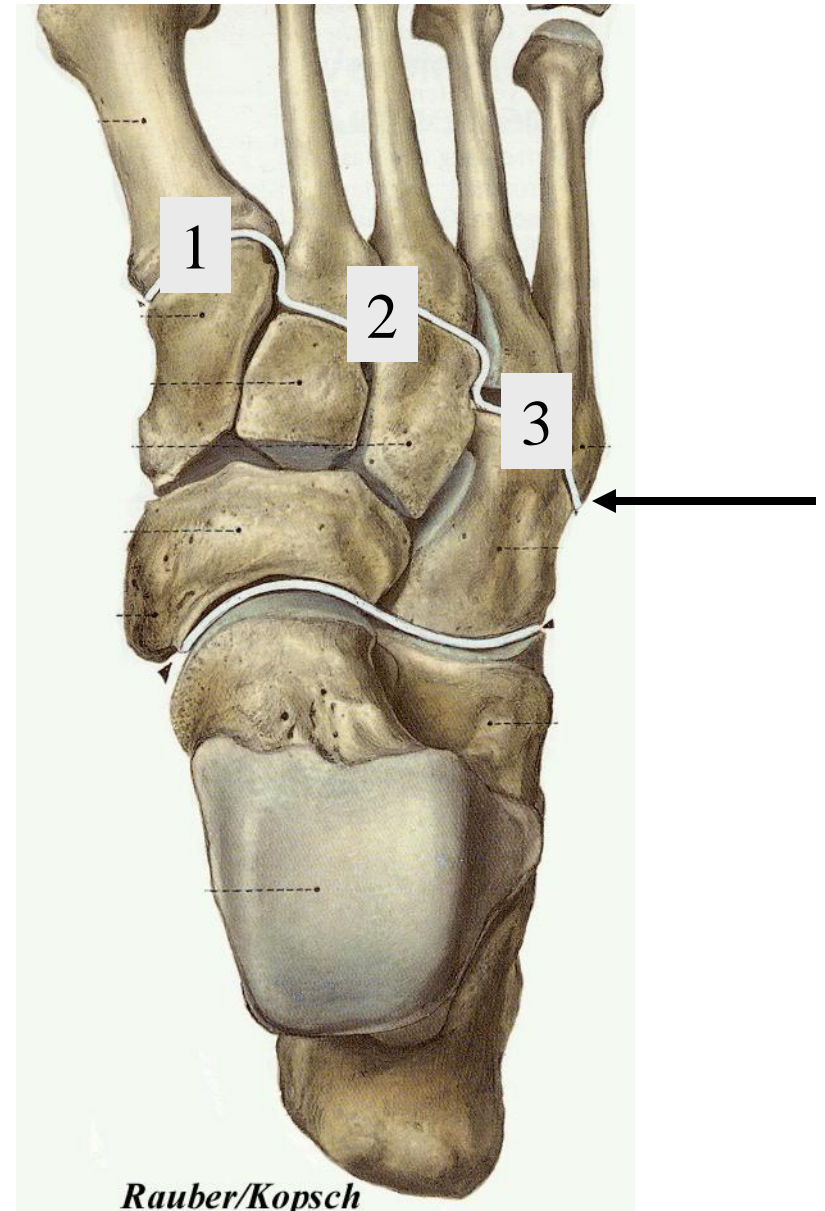
- Cuneonavicular joint
- Cuneocuboideal joint
- Naviculocuboideal joint

Talocrural joint

# Tarsometatarsal joints and line of *Lisfranc*

## Shape, movements

- separated joint cavities
- strong ligaments (Tarsometatarsal ligaments)
- small flexion und extension
- torsional movements
- at thumb small abduction



# Joints of the foot

**Tarsal joints**

**Tarsometatarsal joints**

**Intermetatarsal joints**

**Metatarsophalangeal joints**

**Interphalangeal joints**

**Intertarsal joints**

**Proximal joints**

- Subtalar joint
- Talocalcaneonavicularis joint
- Calcaneocuboideal joint

**Distal joints**

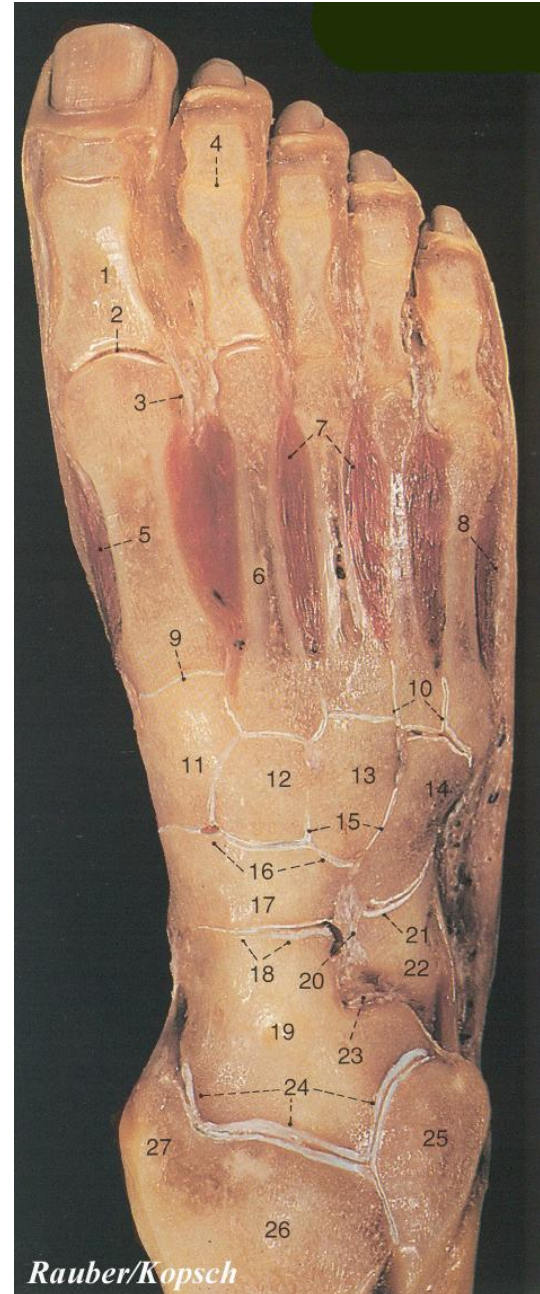
- Cuneonavicular joint
- Cuneocuboideal joint
- Naviculocuboideal joint

**Talocrural joint**

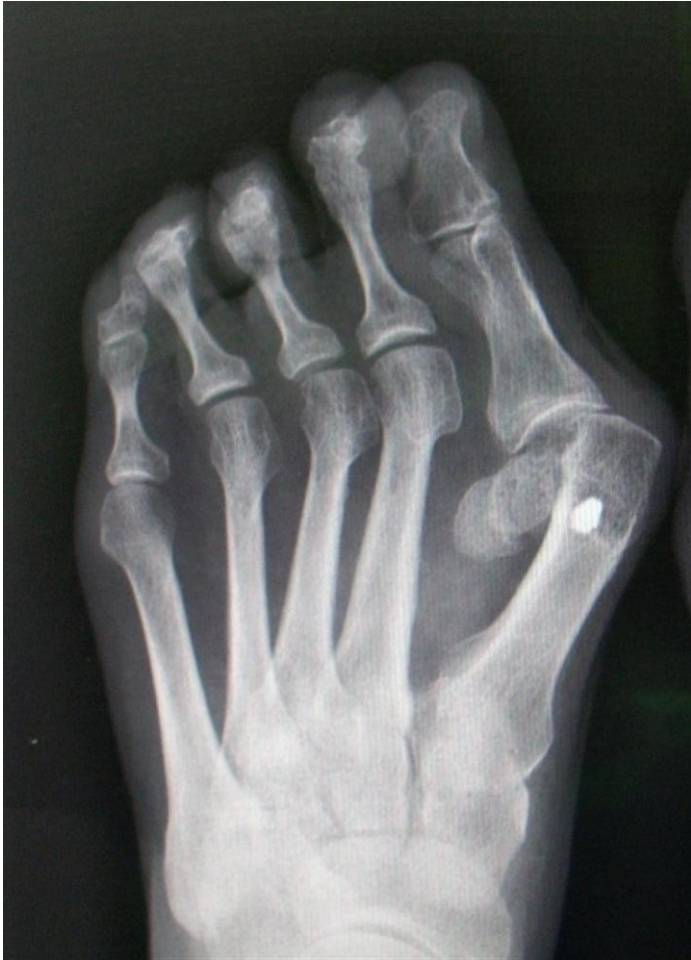# Metatarsophalangeal joints

## Shape and movements

- Hinge joints (ovoid shaped surfaces)
- plantar ligaments
- Deep transverse metatarsal ligaments
- Flexion appr.  $30^\circ$ , Extension appr.  $50^\circ$
- sesamoid bones at thumb



# Hallux valgus



Over 130 types of surgical interventions

One-day-surgery

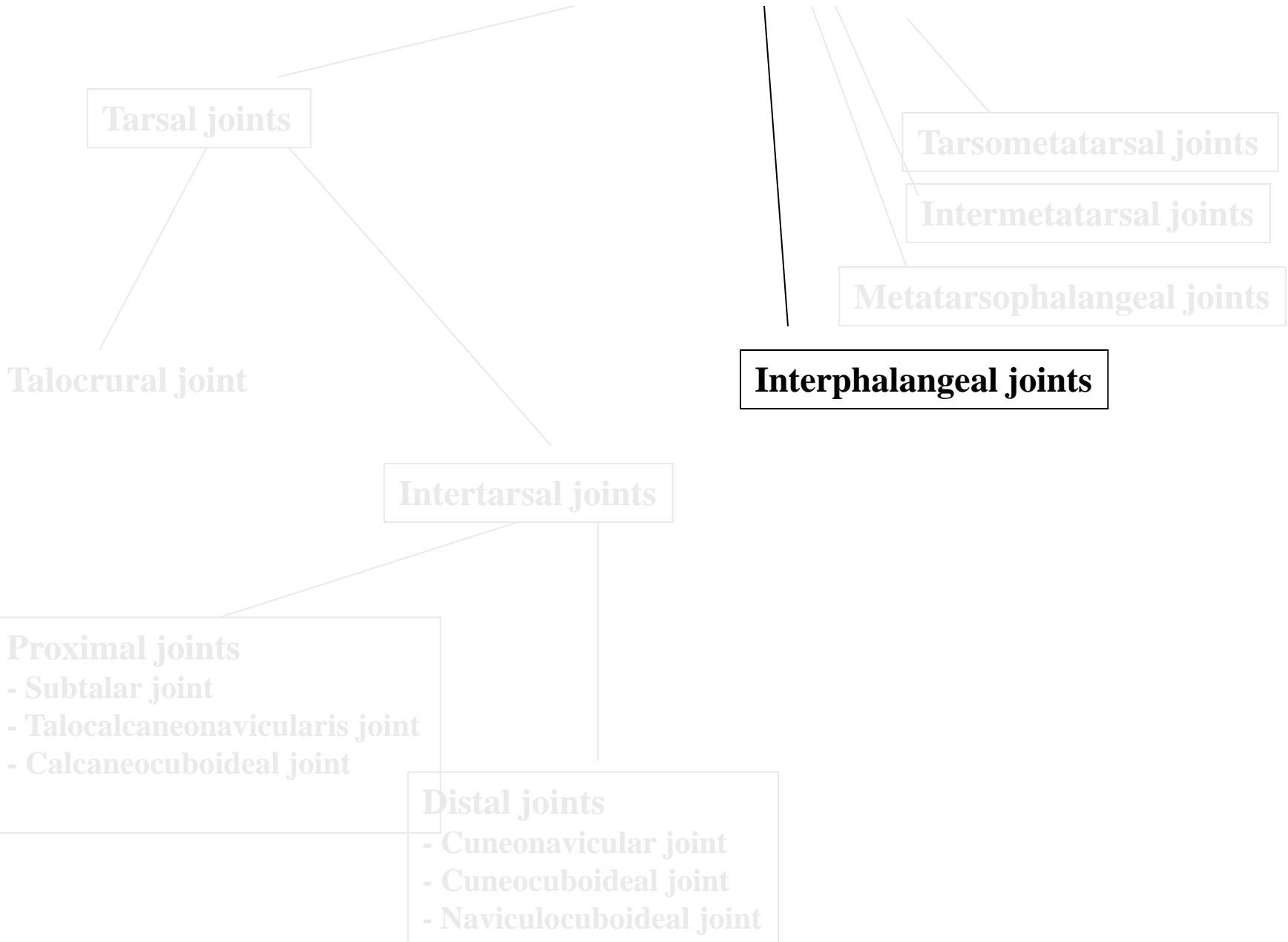
Success rate: 80-90%

Moderate cases: Chevron-surgery  
(distal transpositional osteotomy of first metatarsal bone)

Large angle: cuneiforme osteotomy

Severe cases: cheilectomia  
(removal of dorsal exostosis of first metatarsal bone)

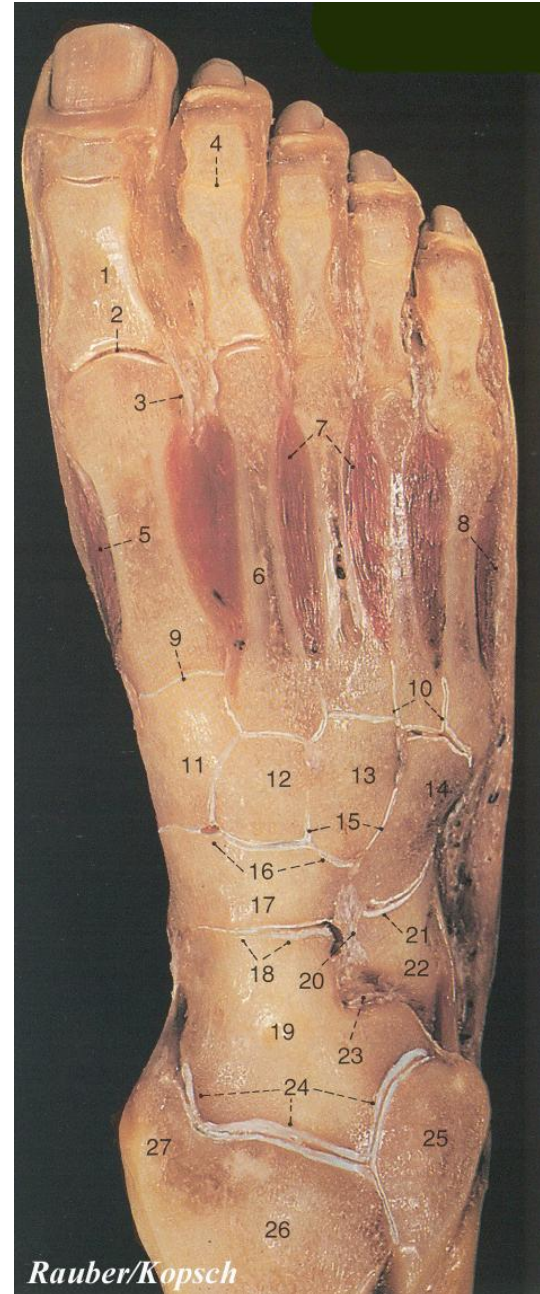
# Joints of the foot



# Interphalangeal joints

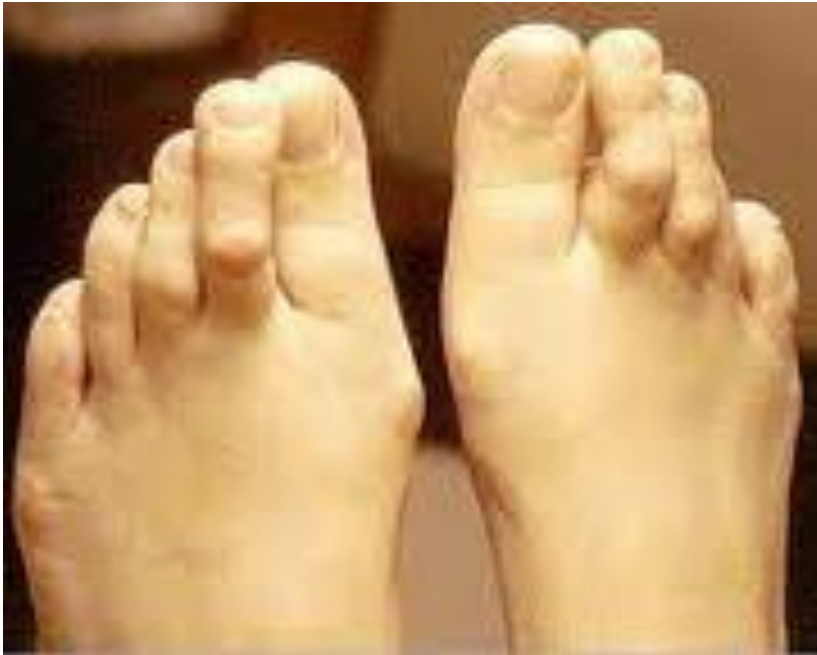## Shape and movements

- hinge joints
- plantar and collateral ligaments
- plates from fibrous cartilage
- PIP.: Flexion appr.  $35^\circ$
- DIP.: Flexion appr.  $60^\circ$ , Extension appr.  $30^\circ$





# Digitus malleus



Failure of transverse and longitudinal arches (flatfoot)

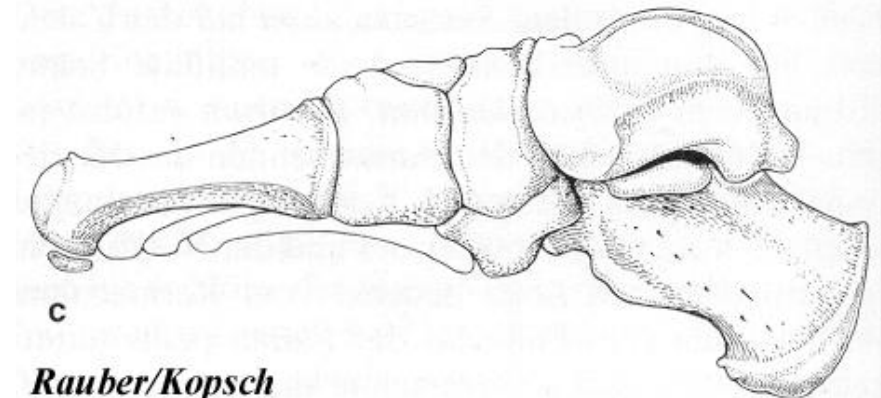
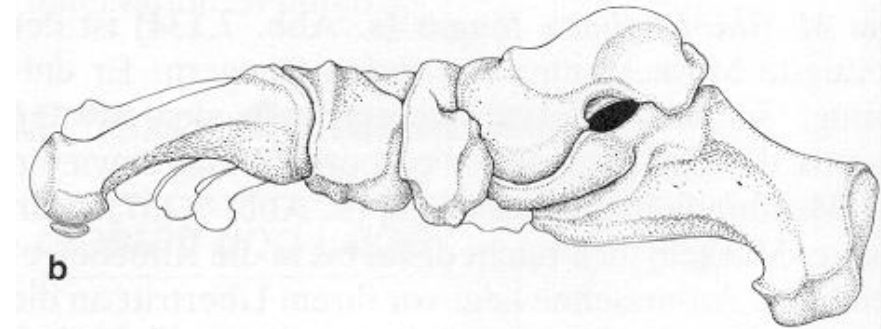
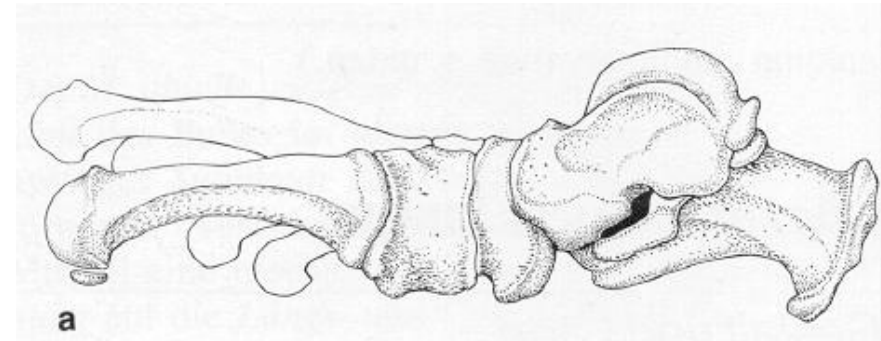
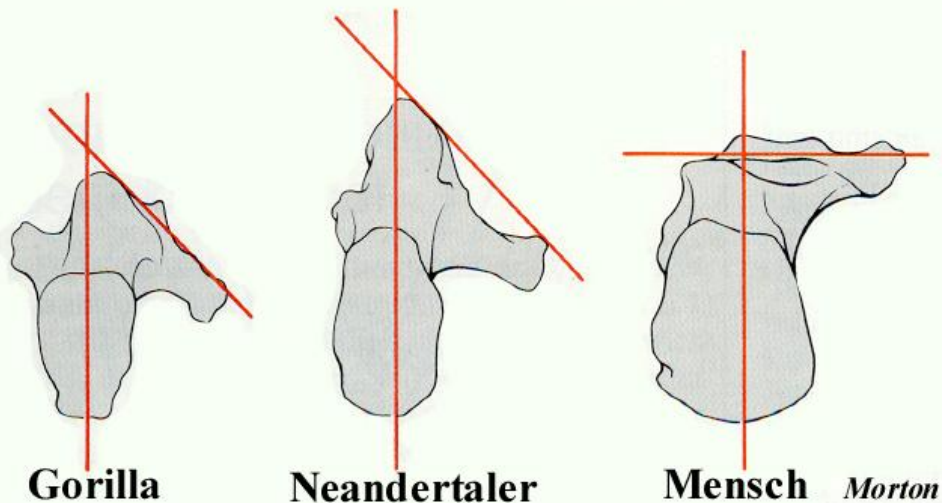
Direction of forces (how tendons pull) altered

Surgery: shortening of proximal phalanx

# Structure of foot

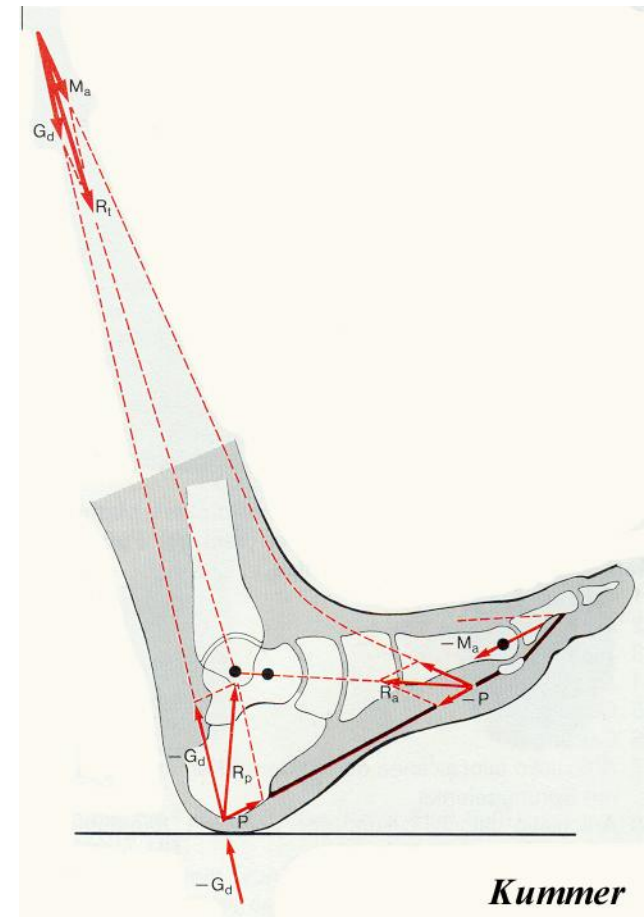
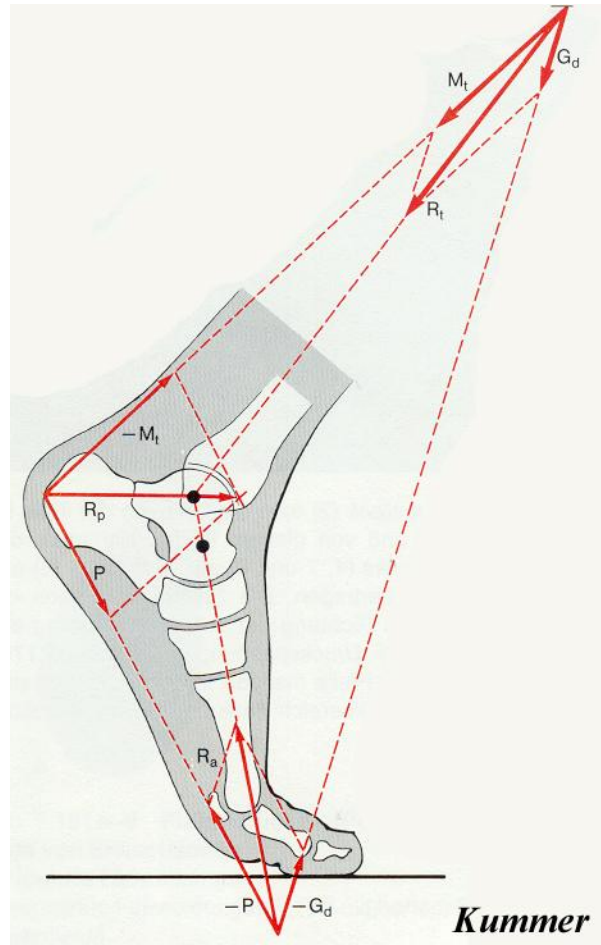
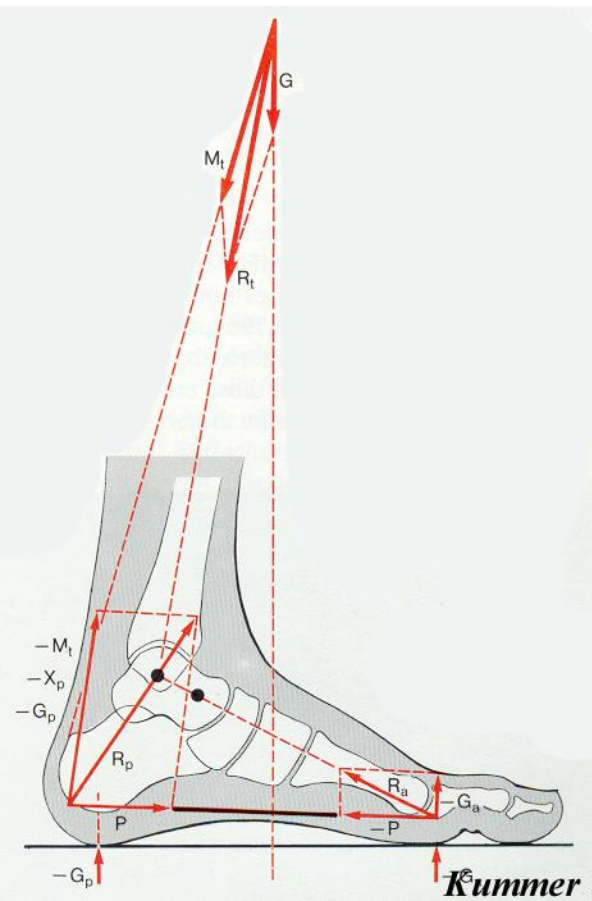
## Adaption to movements

- bipedal movement
- thumb adducted, „paralleled”
- sustains - massive talus and calcaneus
- at child flat
- position of sustentaculum tali



# Mechanics of foot

- supporters: calcaneus, heads of I. and V. metatarsal bones
- tension versus flat foot
- metatarsal bones loaded when calcaneus on ground only



# Arches of foot

*consequences of walking*

## Walking

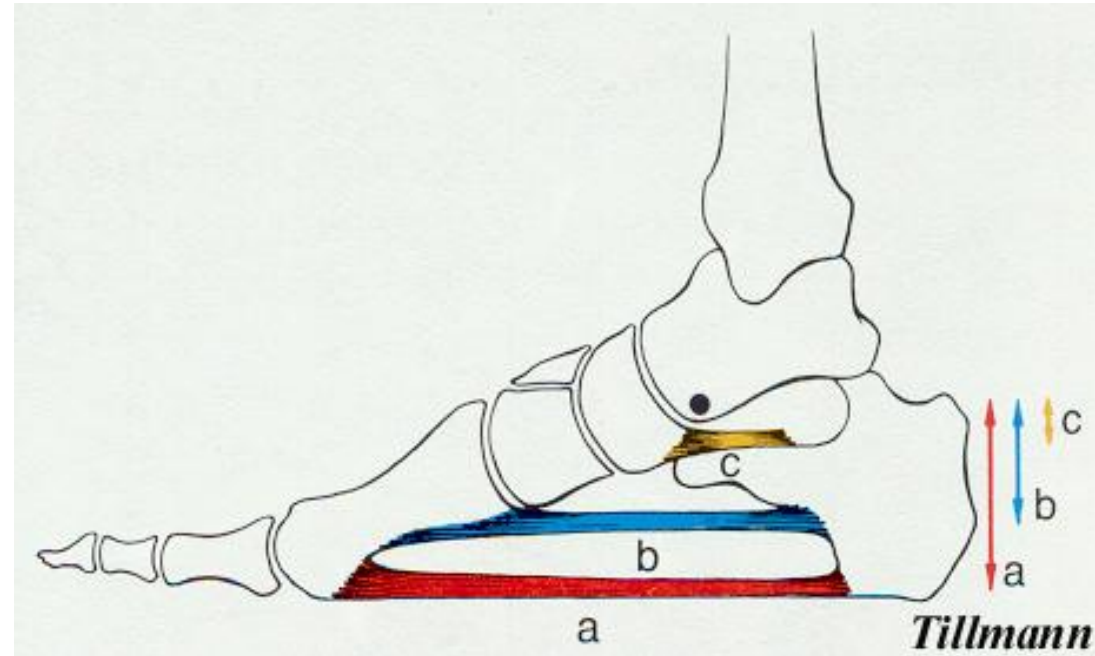
- longitudinal arches (5), transverse arch;  
top: talus
- held at standing only through ligaments
- elements on plantar side

## Longitudinal arches

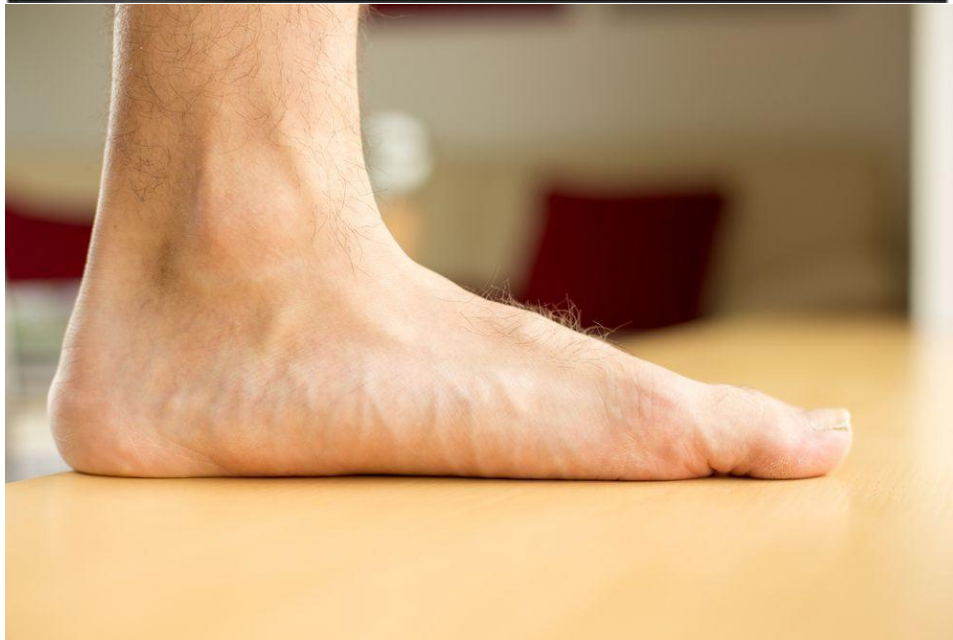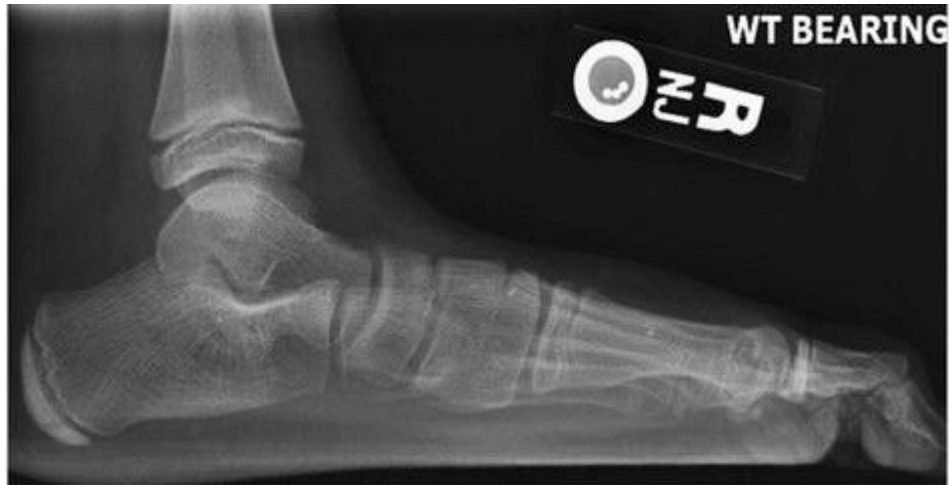- short muscles
- long plantar ligaments
- plantar aponeurosis

## Transverse arch

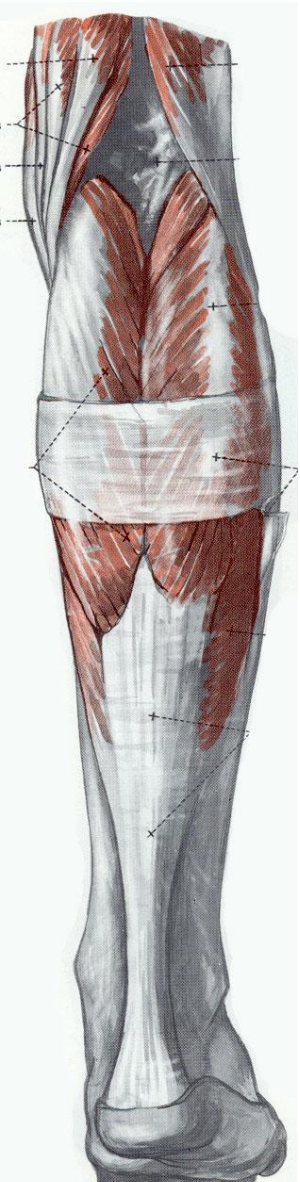
- deep transverse metatarsal ligaments
- tibialis posterior m., peroneus longus m.,  
tibialis anterior m.



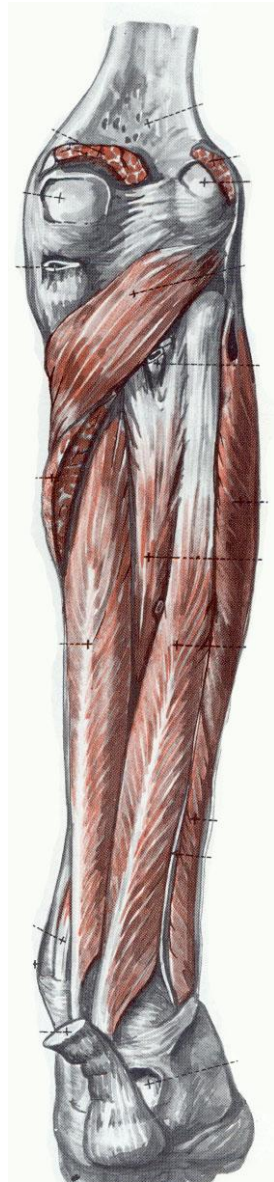
# Flatfoot – the C-sign



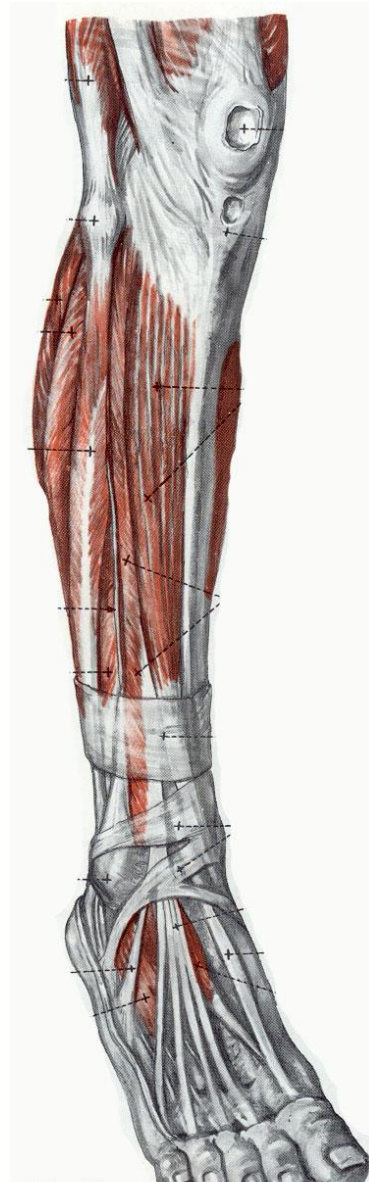# Muscles acting upon the joints of the foot



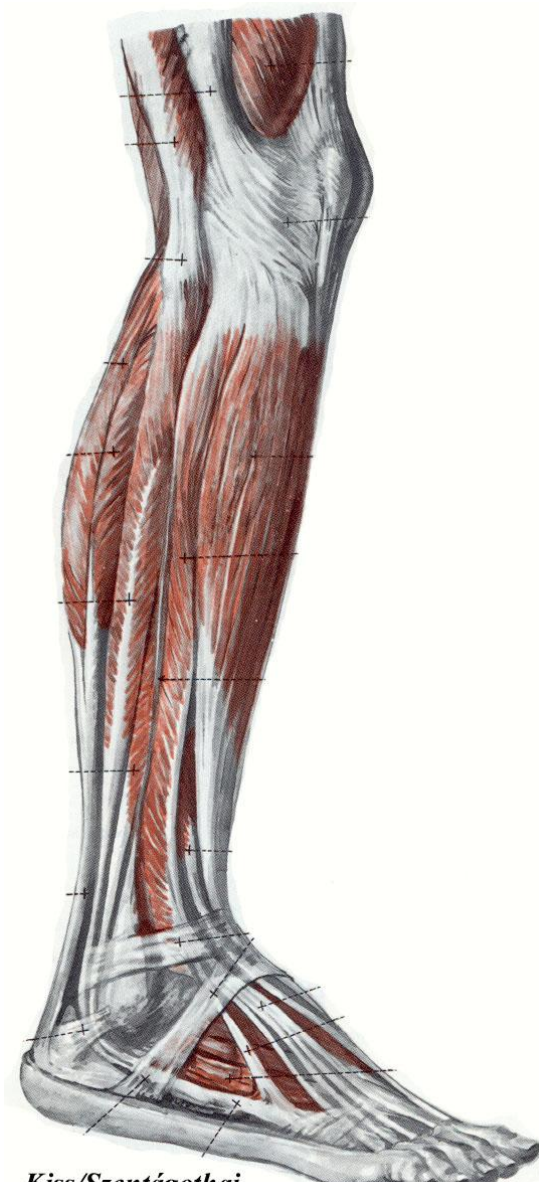
*Kiss/Szentágothai*



*Kiss/Szentágothai*

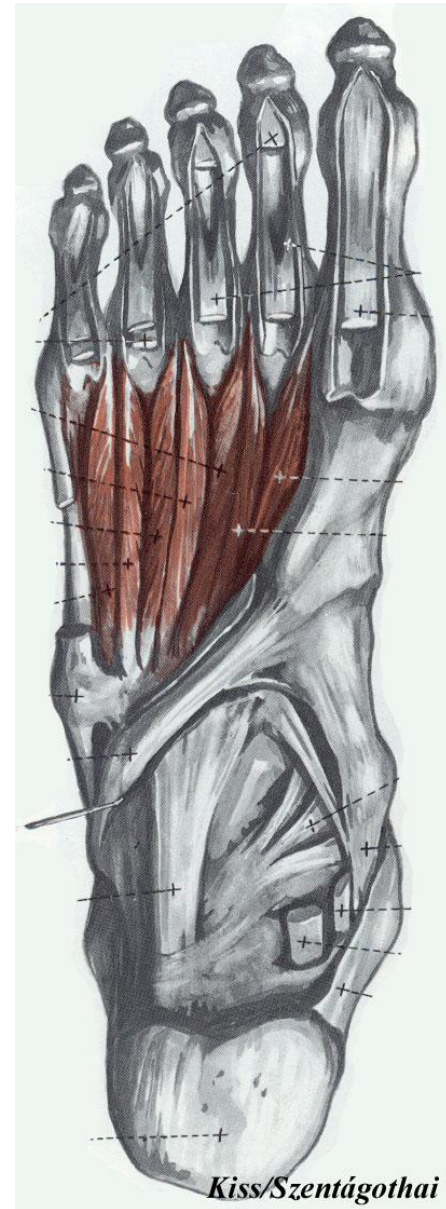
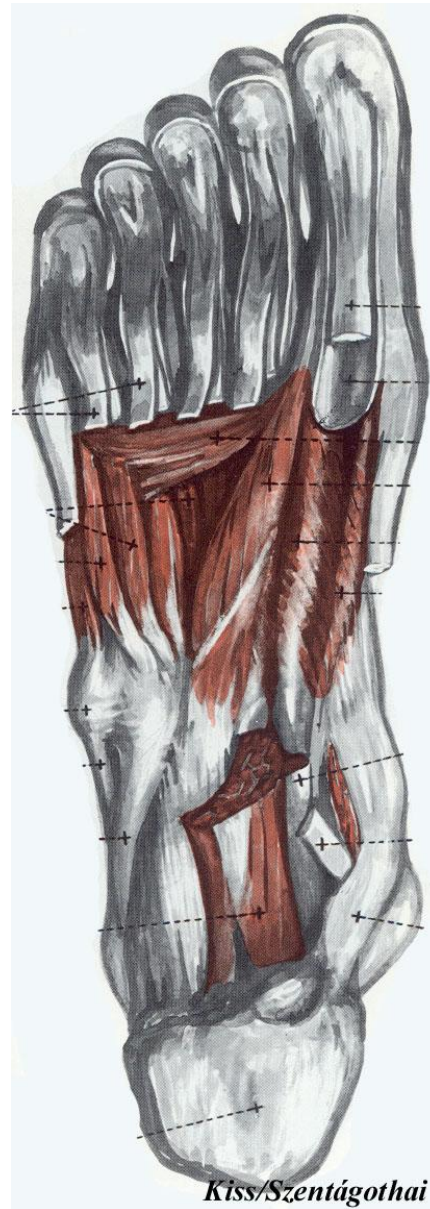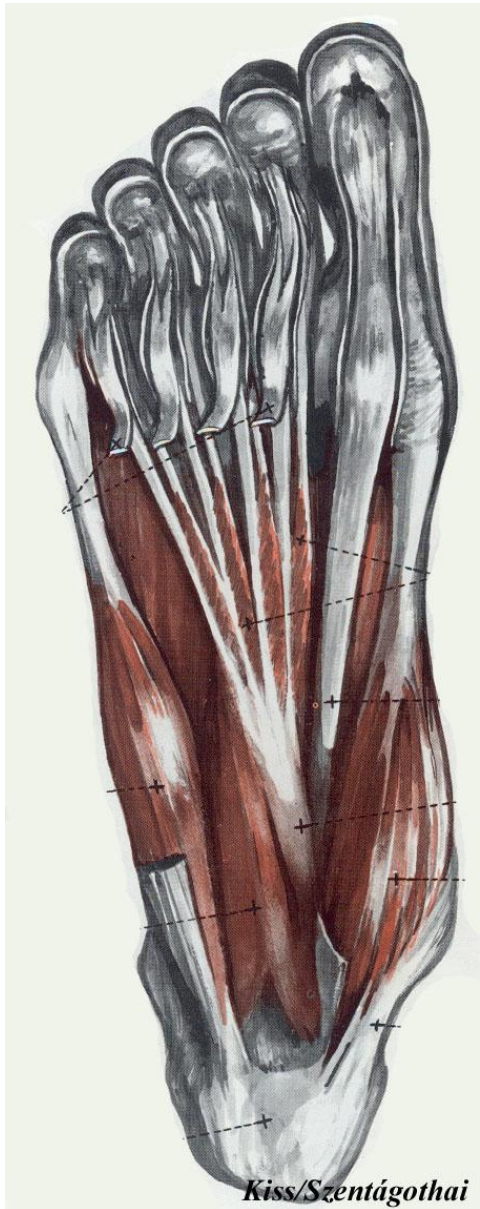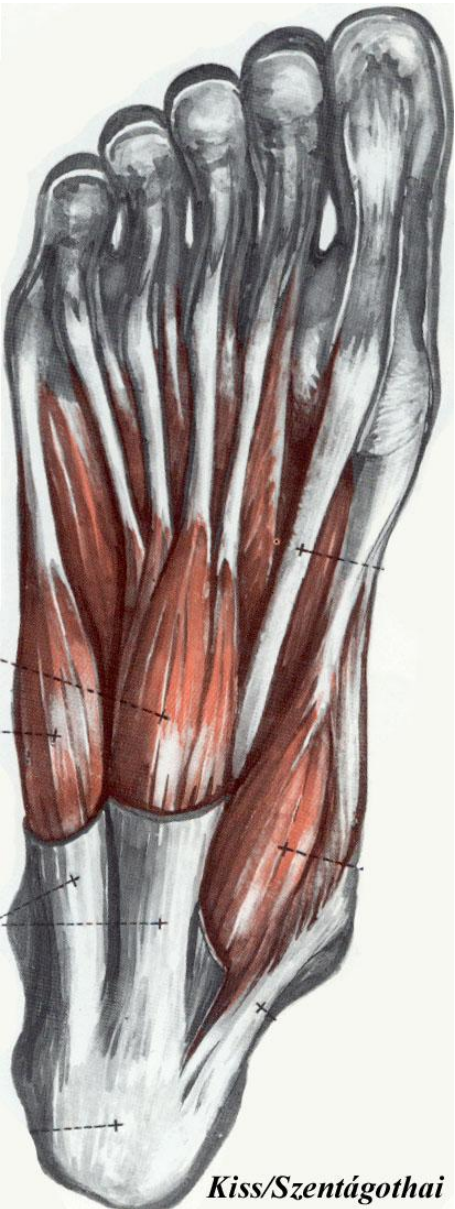


*Kiss/Szentágothai*

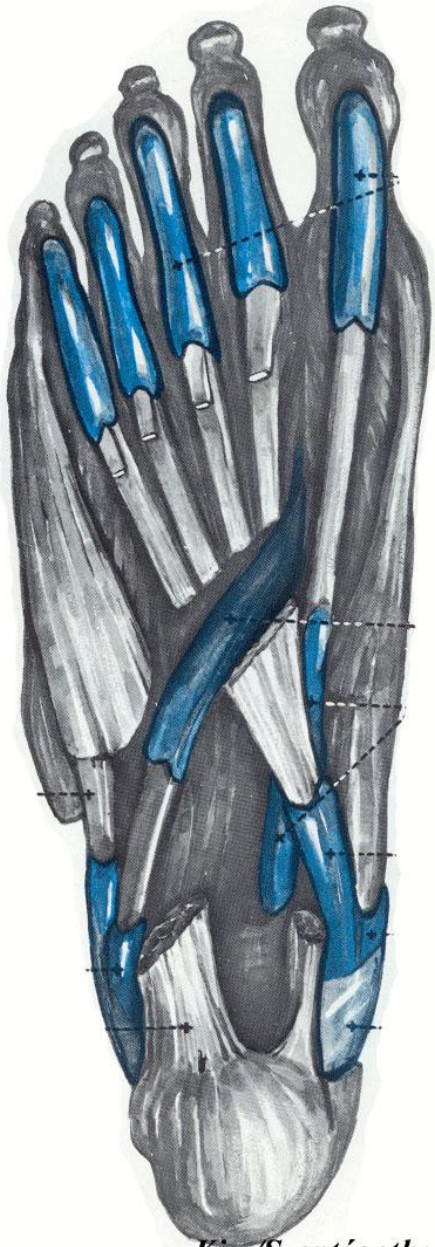

*Kiss/Szentágothai*

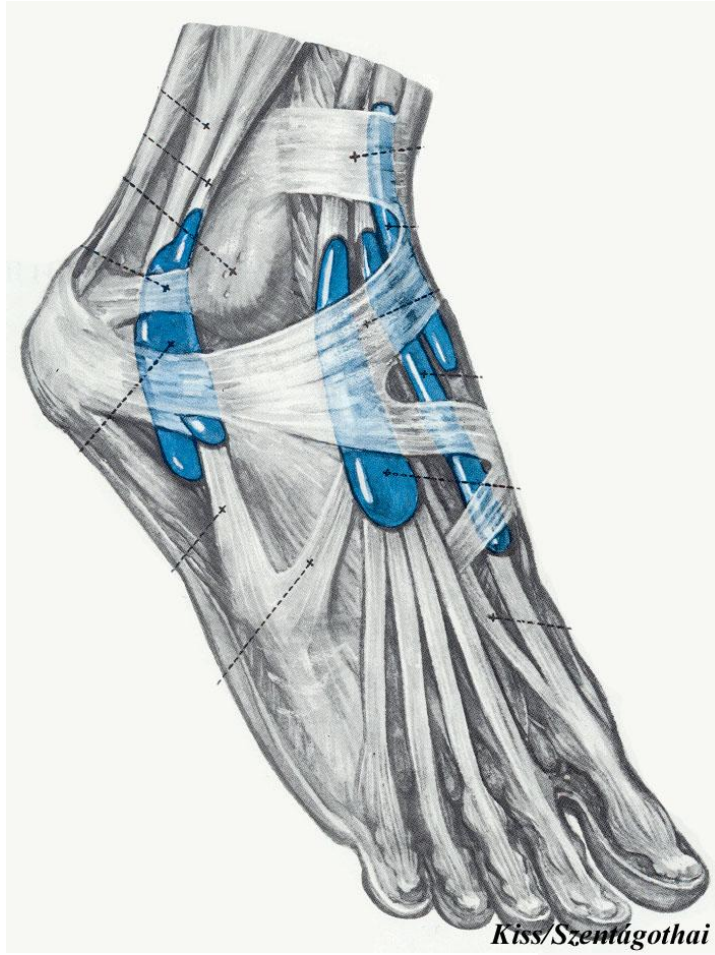
# Muscles of the foot



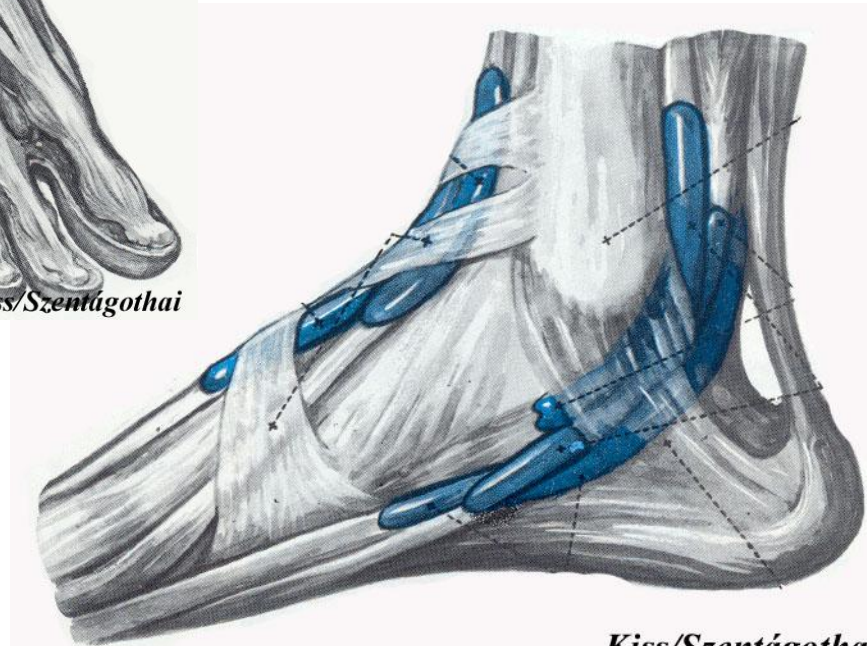
# Synovial sheaths on the foot



*Kiss/Szentágothai*



*Kiss/Szentágothai*



*Kiss/Szentágothai*