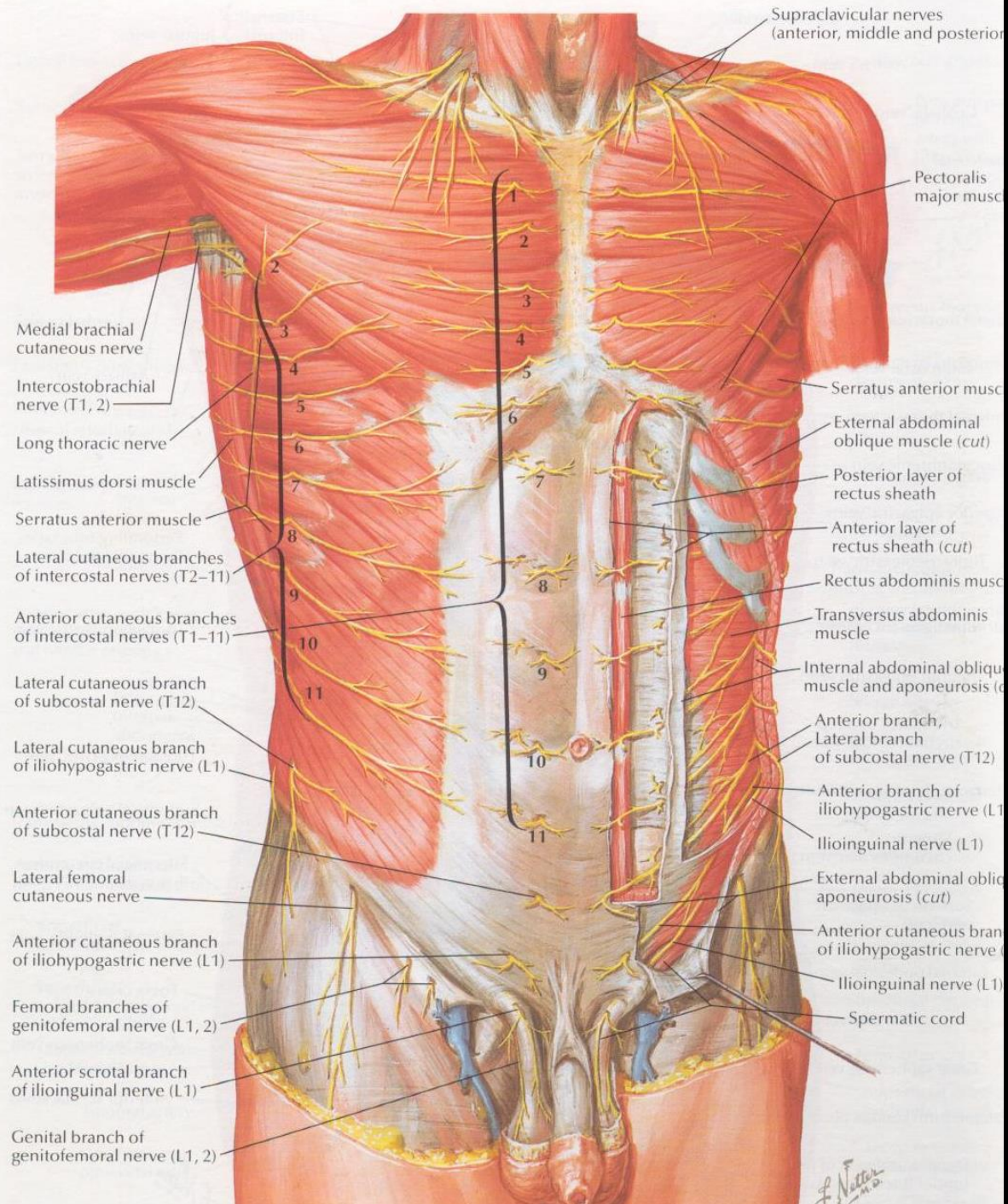
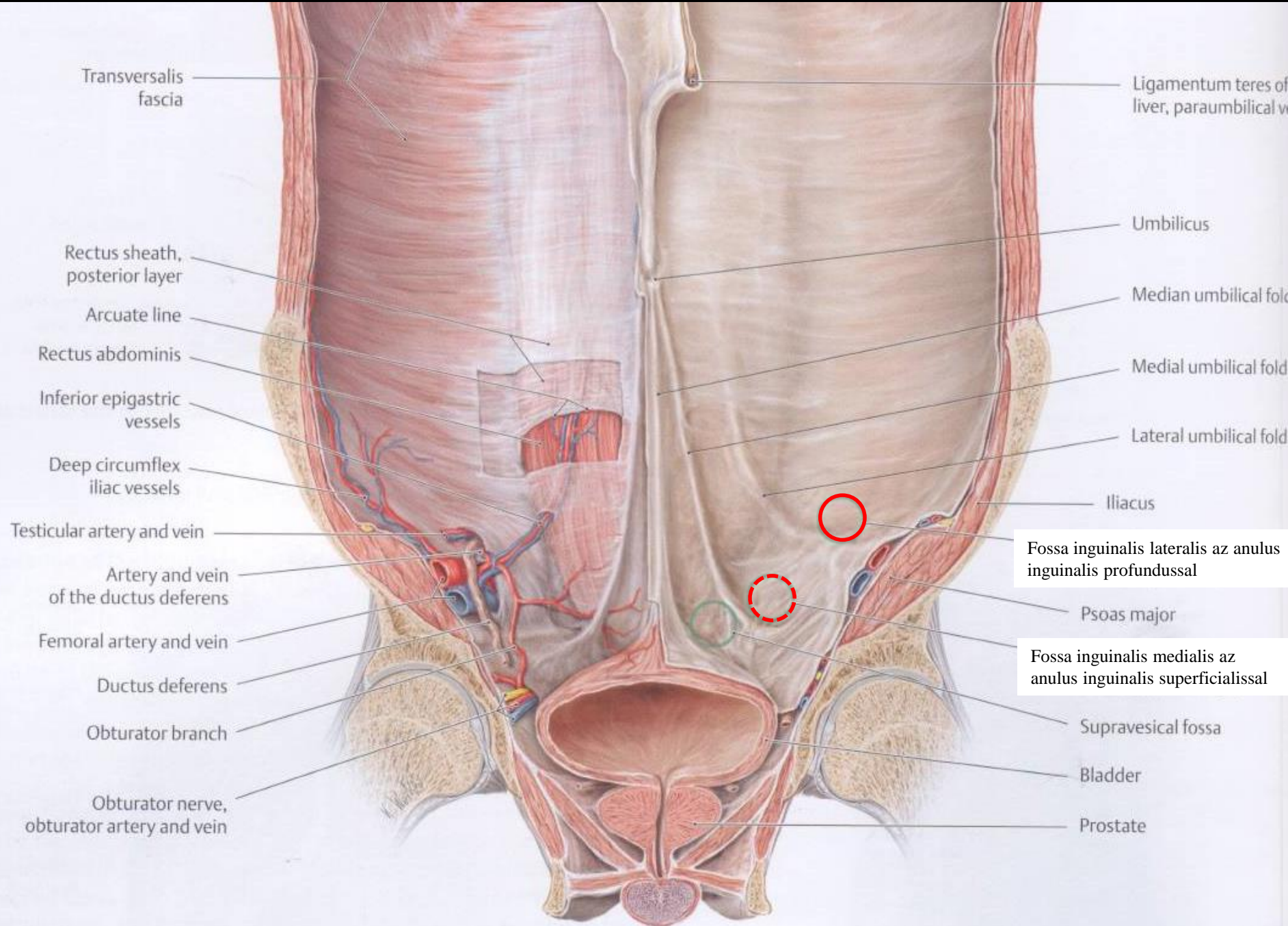


Hiatus subinguinalis, canalis femoralis, canalis inguinalis, és a canalis adductorius

Barna János





Transversalis fascia

Rectus sheath, posterior layer

Arcuate line

Rectus abdominis

Inferior epigastric vessels

Deep circumflex iliac vessels

Testicular artery and vein

Artery and vein of the ductus deferens

Femoral artery and vein

Ductus deferens

Obturator branch

Obturator nerve, obturator artery and vein

Ligamentum teres of liver, paraumbilical vein

Umbilicus

Median umbilical fold

Medial umbilical fold

Lateral umbilical fold

Iliacus

Fossa inguinalis lateralis az anulus inguinalis profundussal

Psoas major

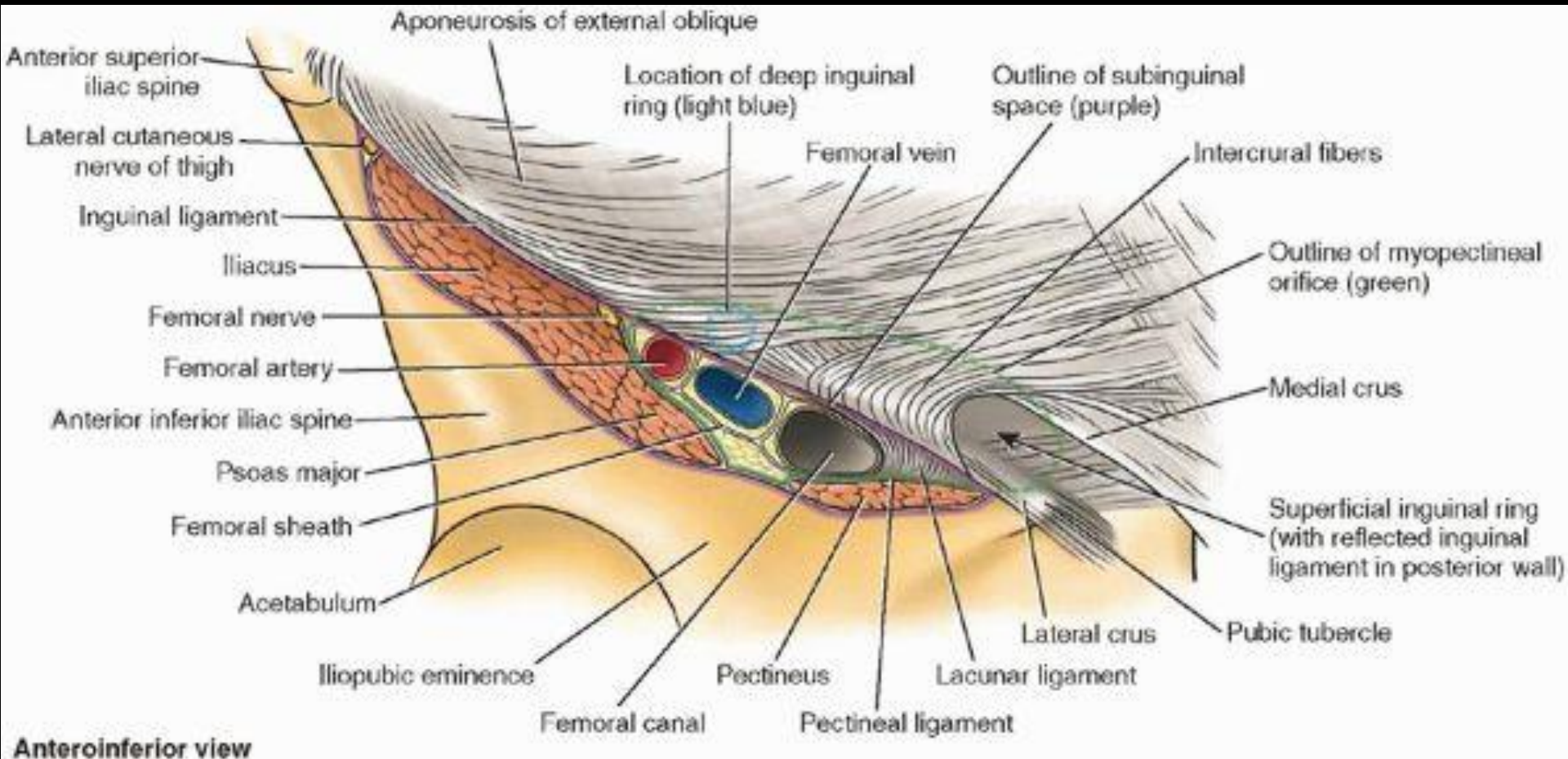
Fossa inguinalis medialis az anulus inguinalis superficialissal

Supravesical fossa

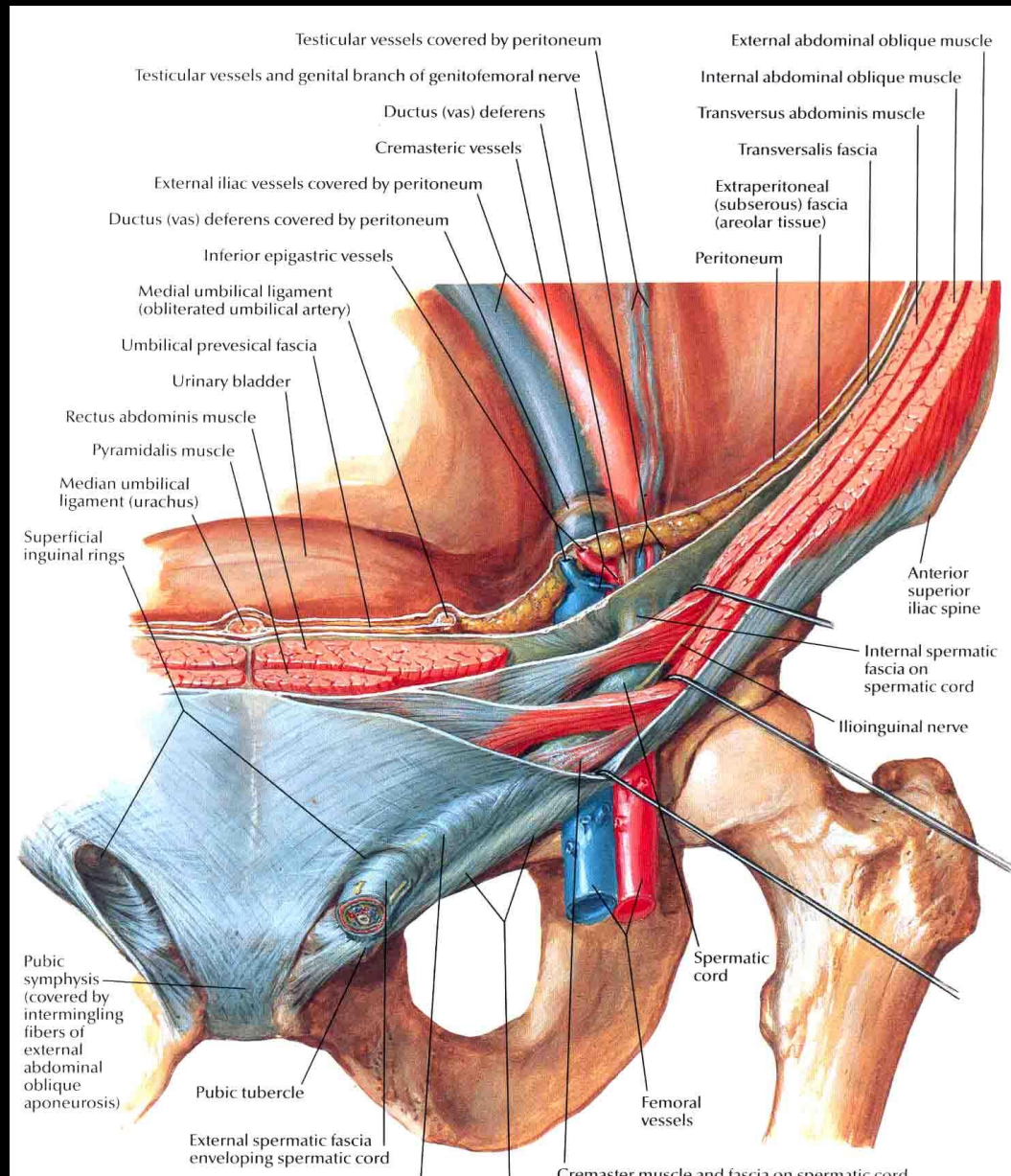
Bladder

Prostate

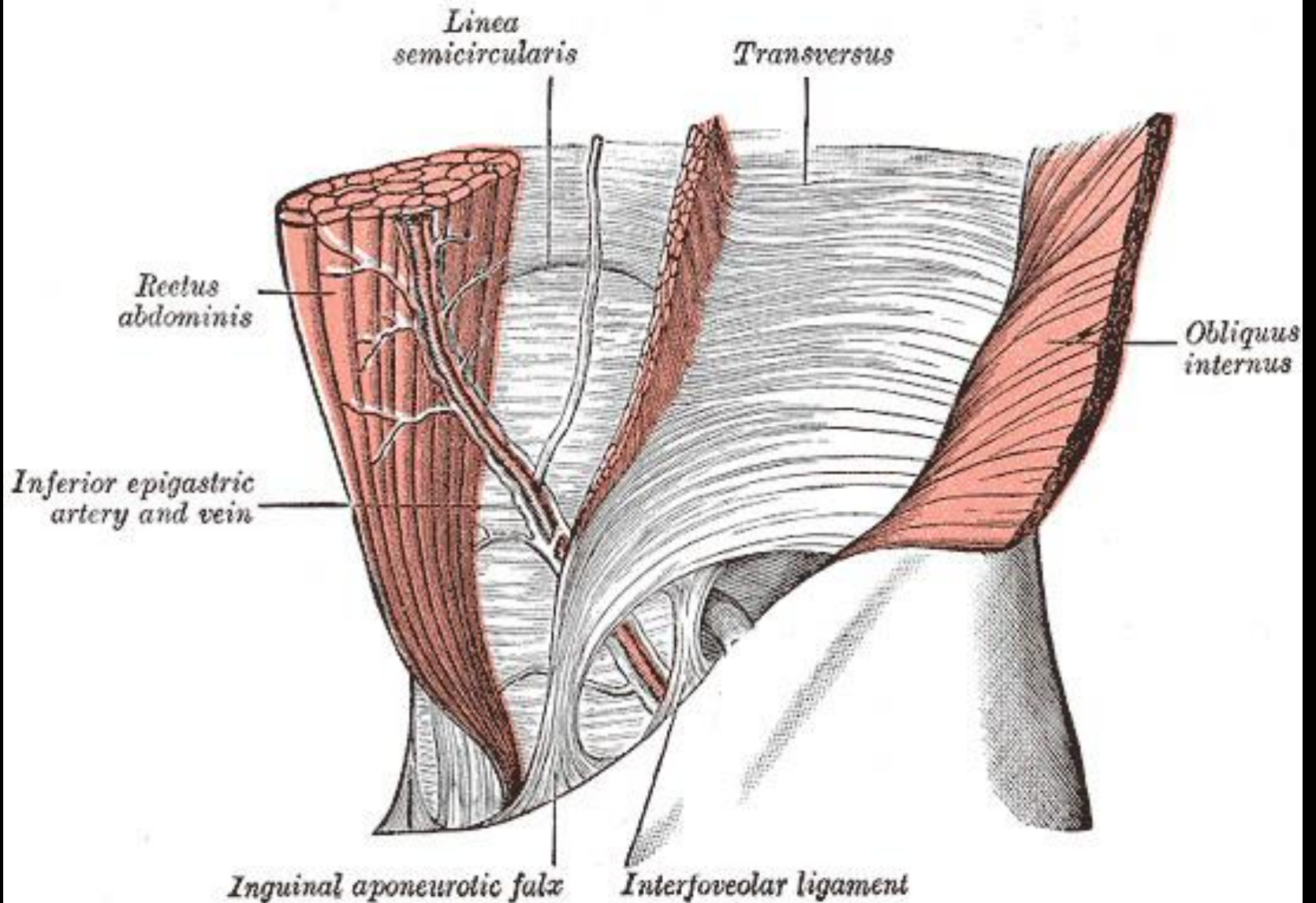
Canalis inguinalis



Canalis inguinalis



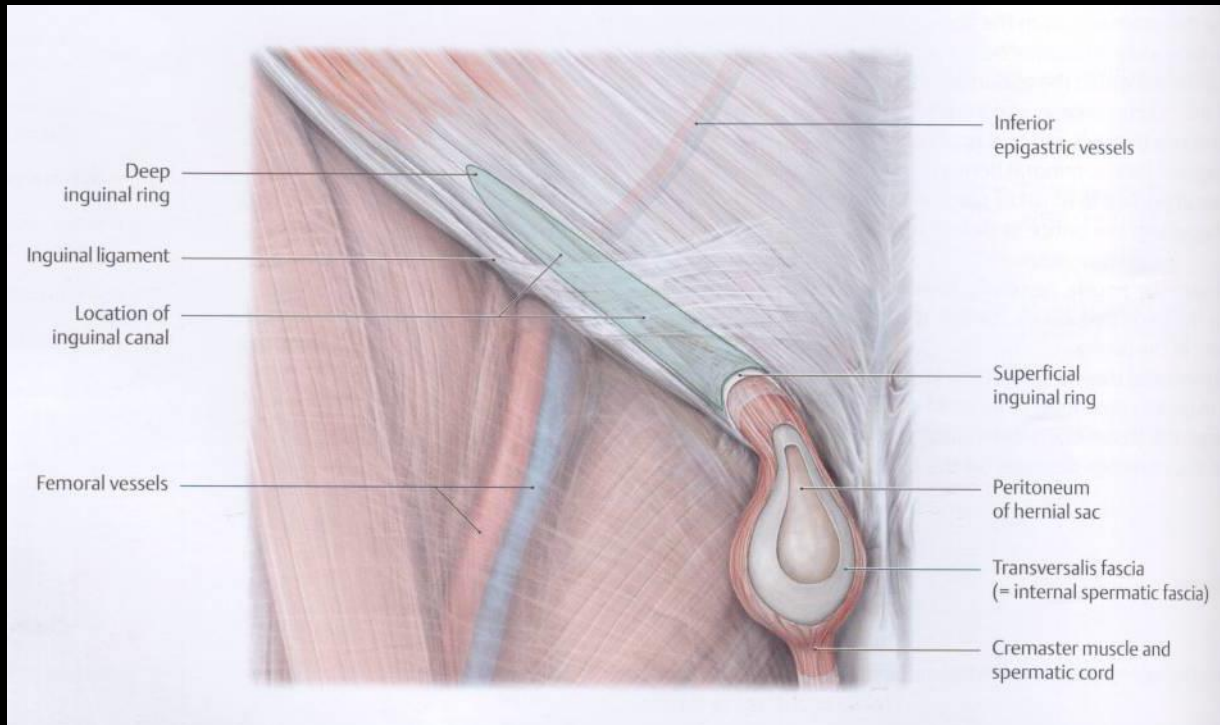
Canalis inguinalis



A hasfal gyenge pontjai (locus minoris resistentiae abdominis)

hernia inguinalis

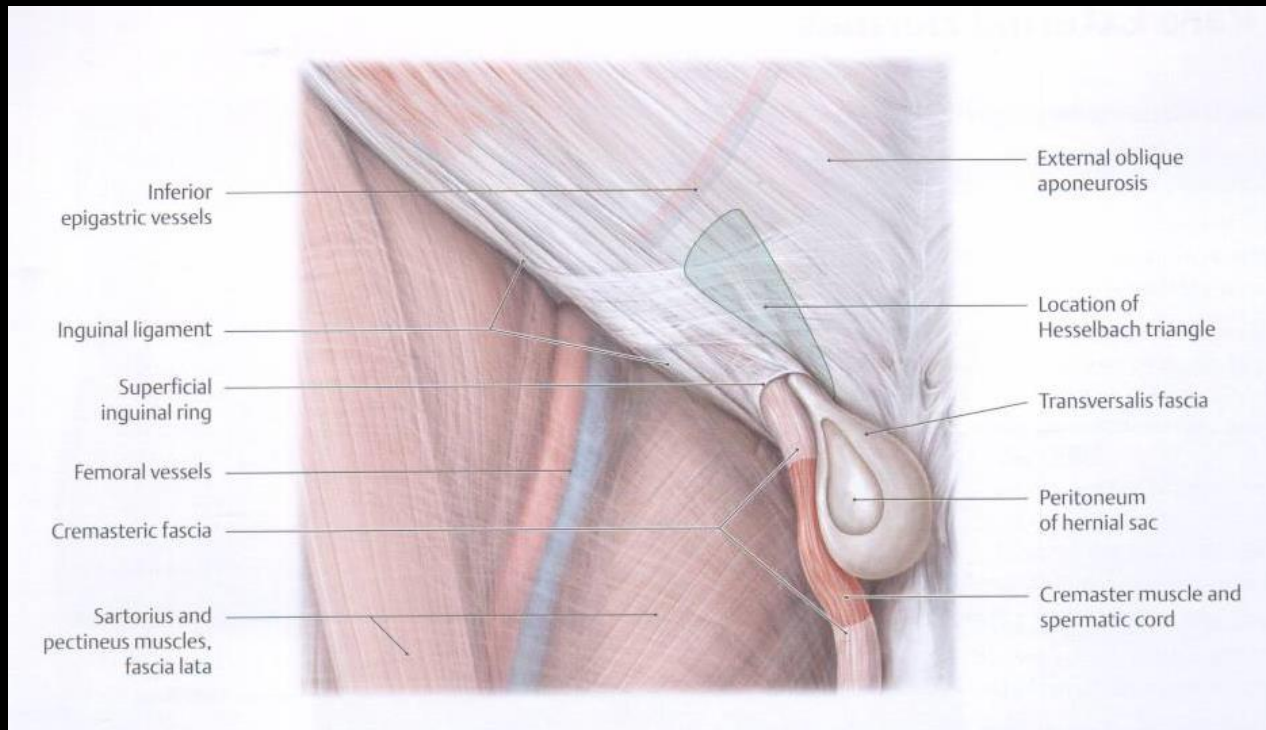
Hernia inguinalis lateralis/indirecta

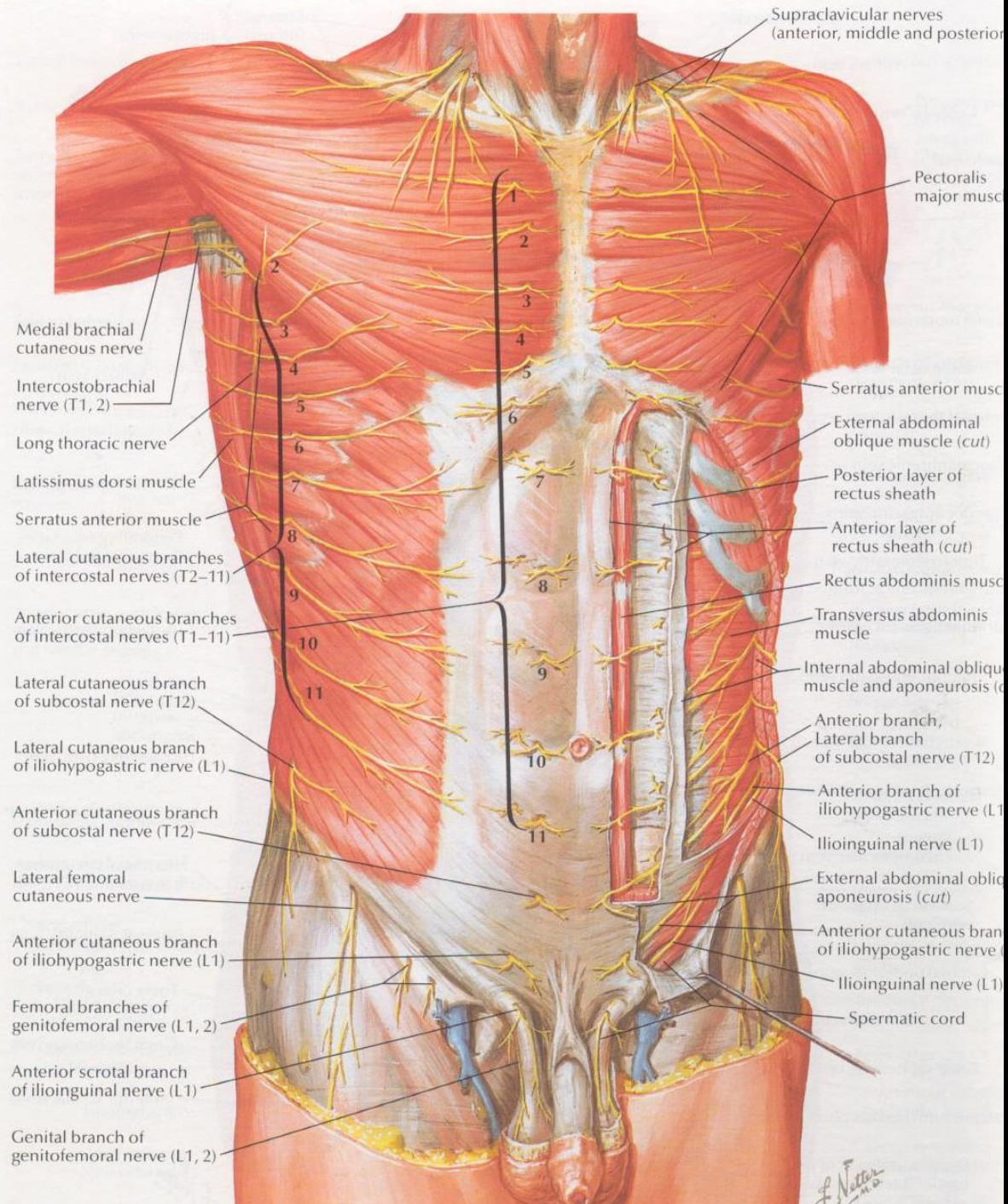


A hasfal gyenge pontjai (locus minoris resistentiae abdominis)

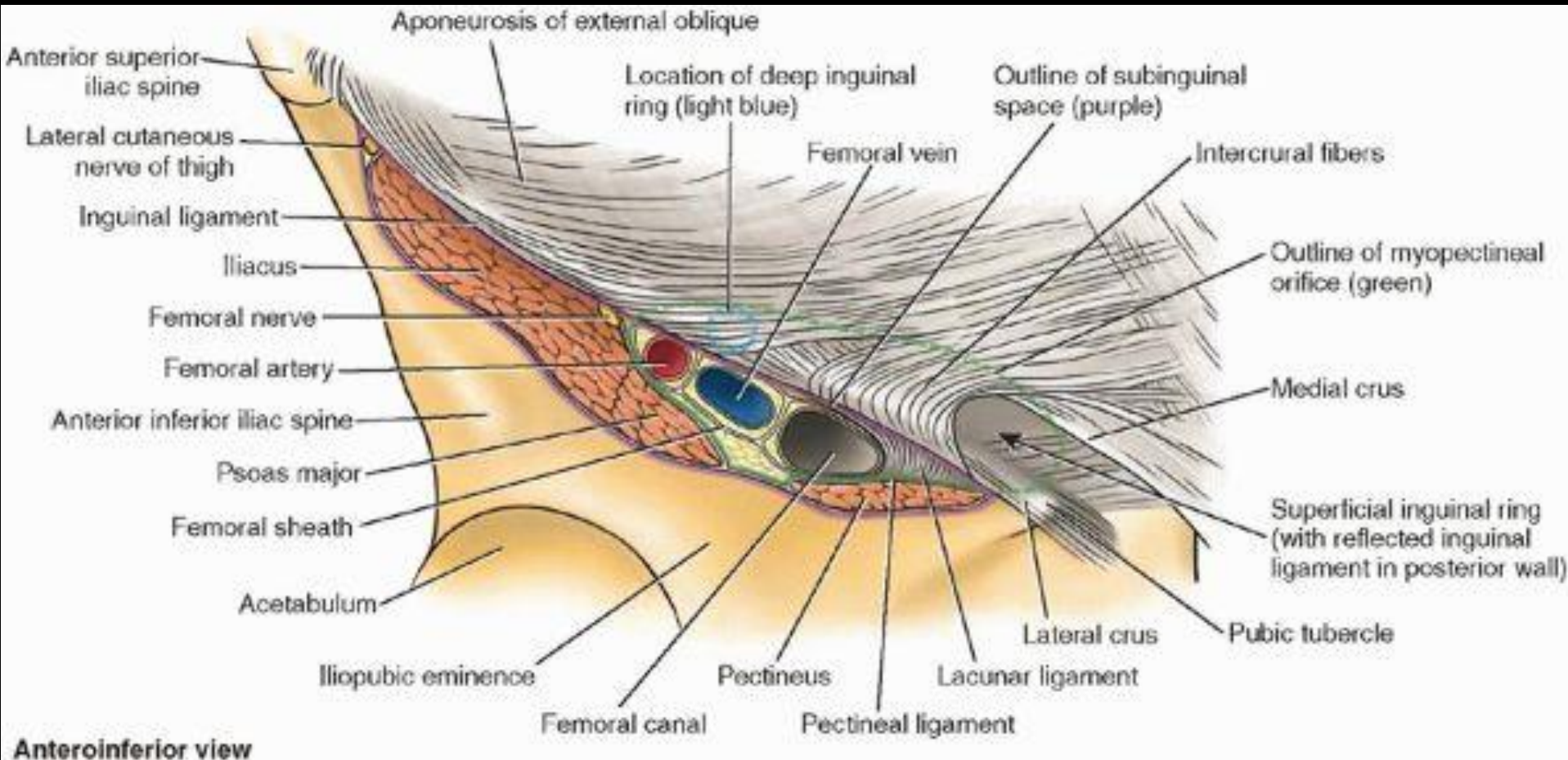
hernia inguinalis

Hernia inguinalis medialis/directa

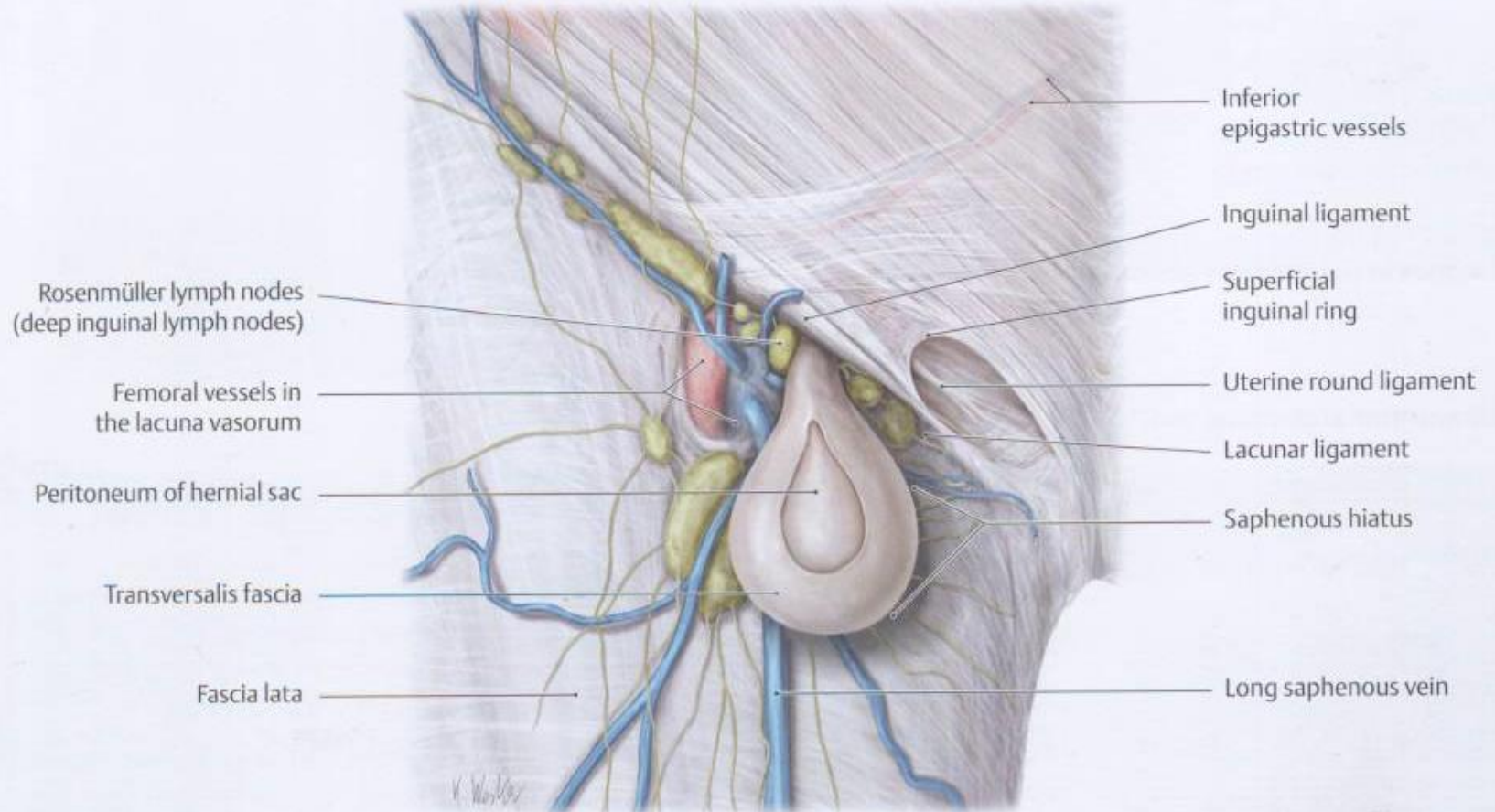




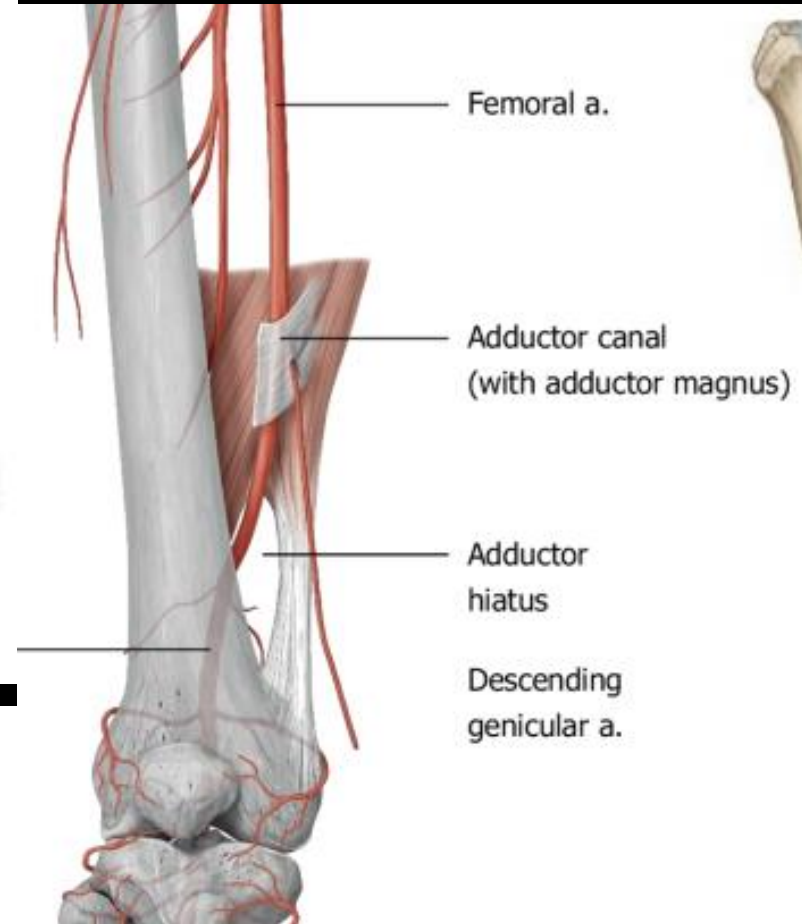
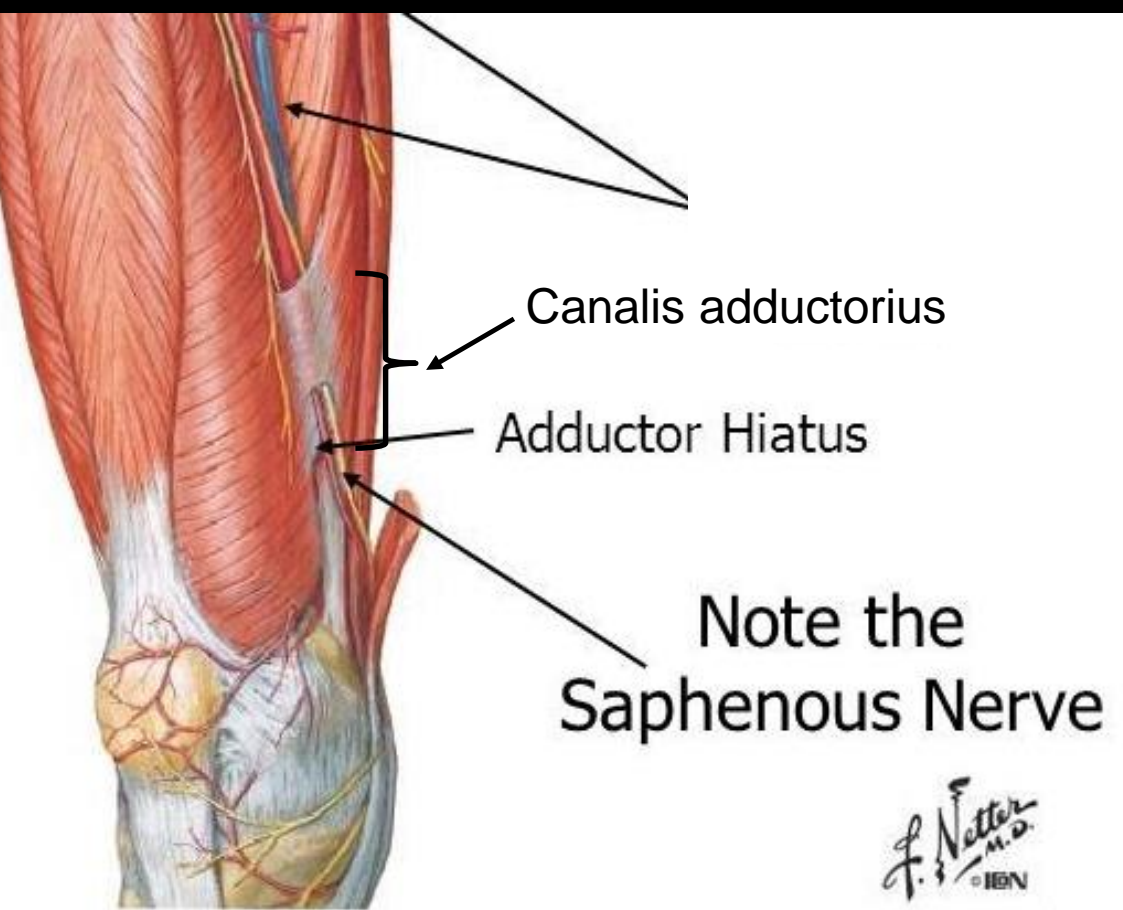
Hiatus subinguinalis



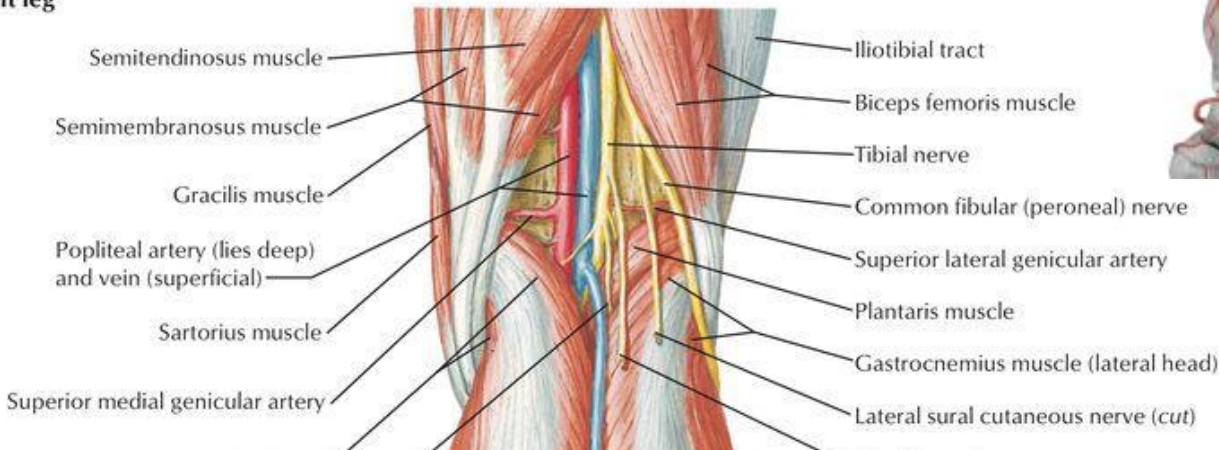
Hernia femoralis typica



Canalis adductorius



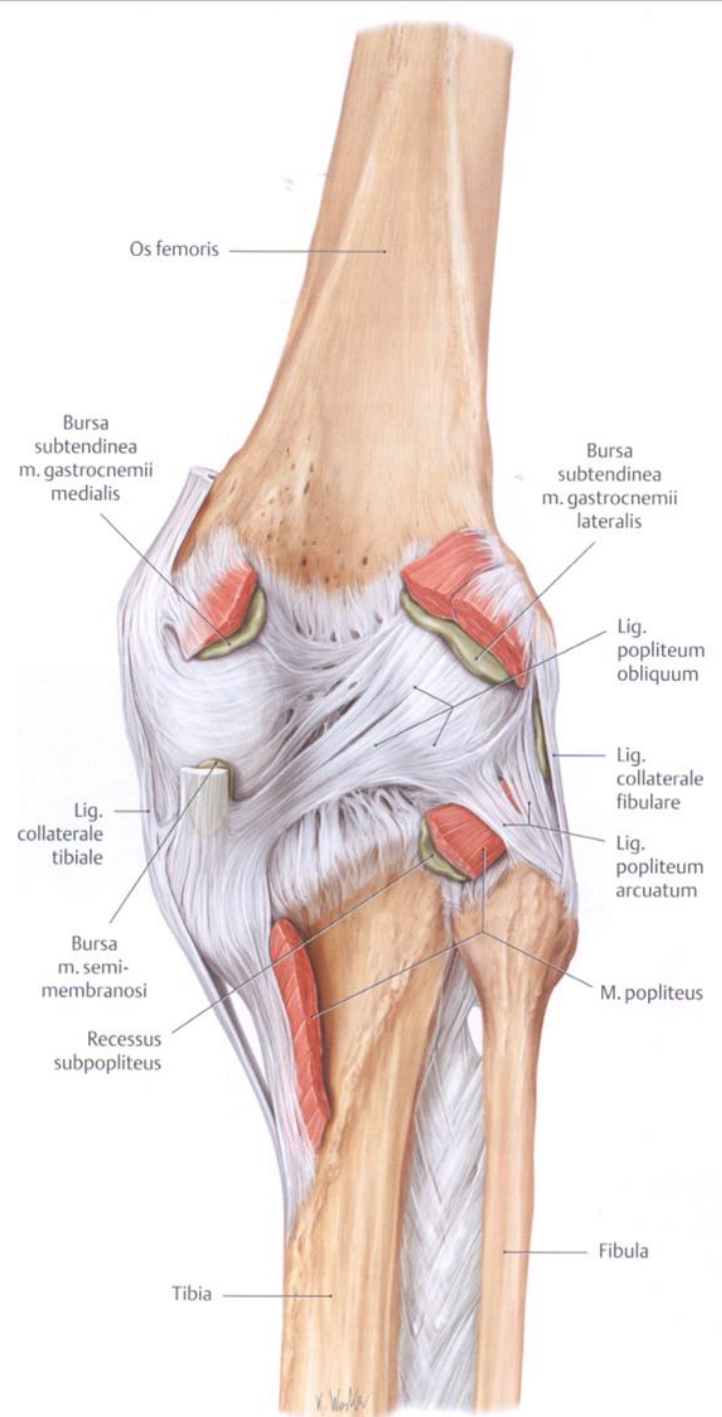
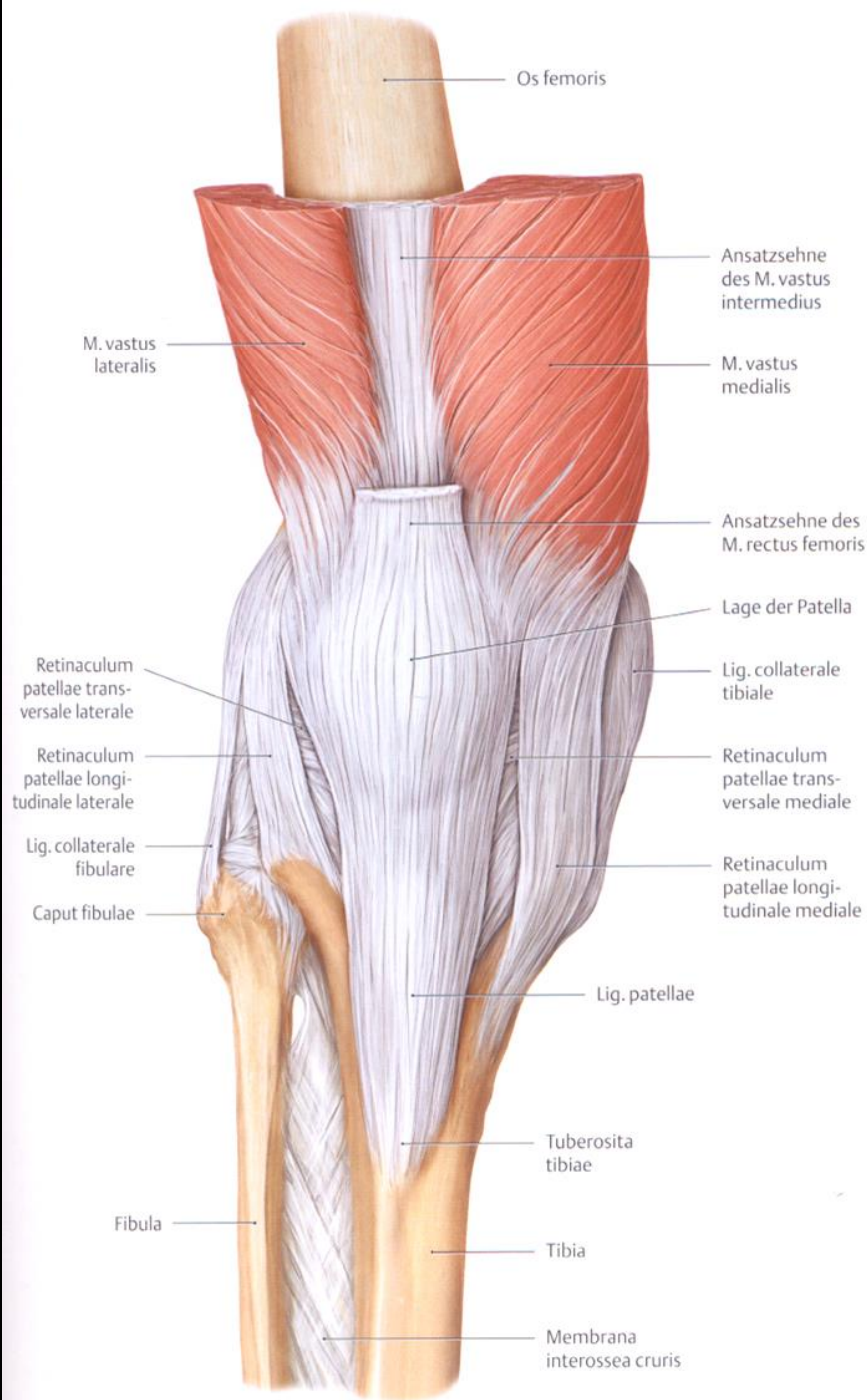
nt leg

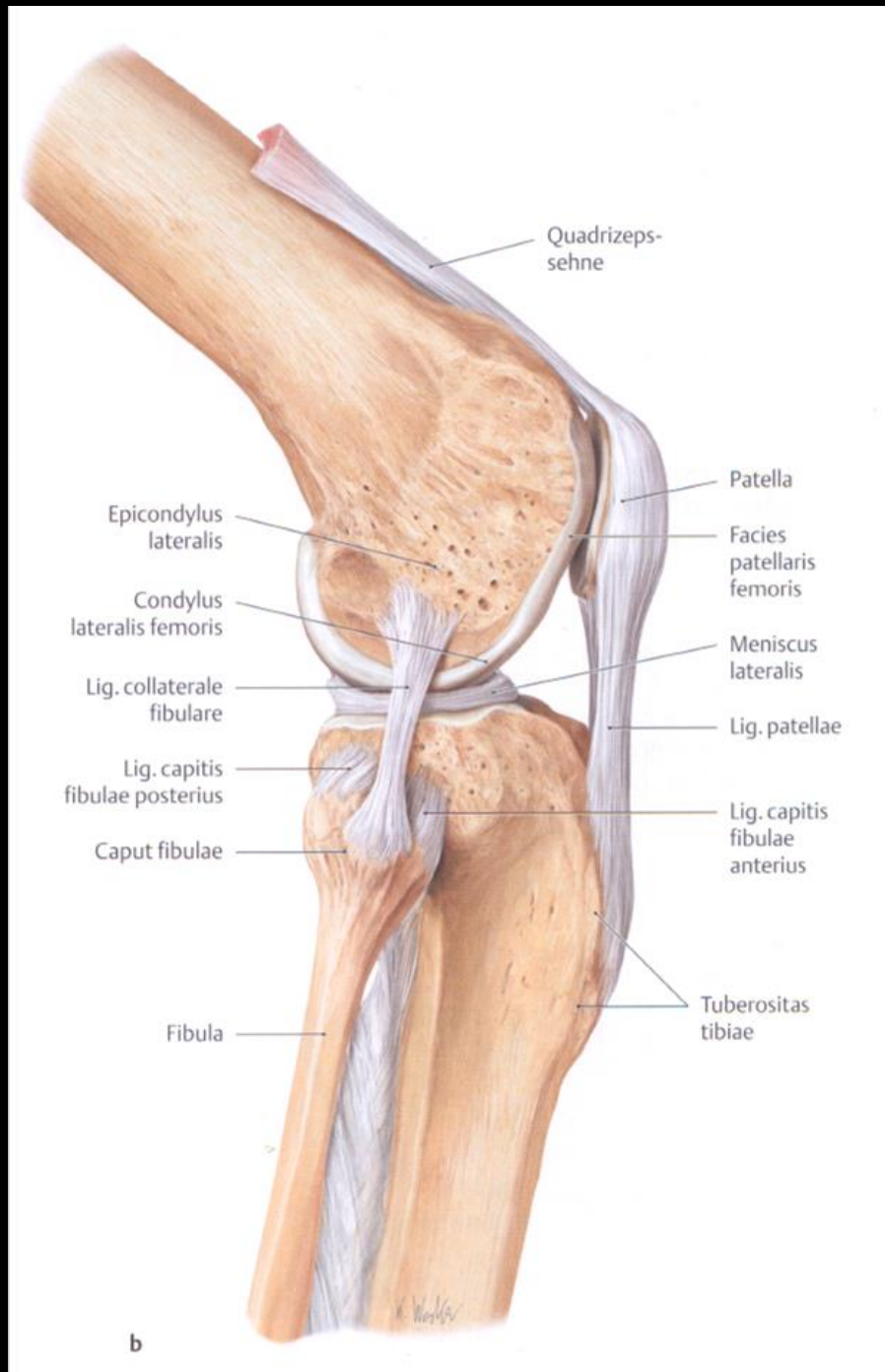
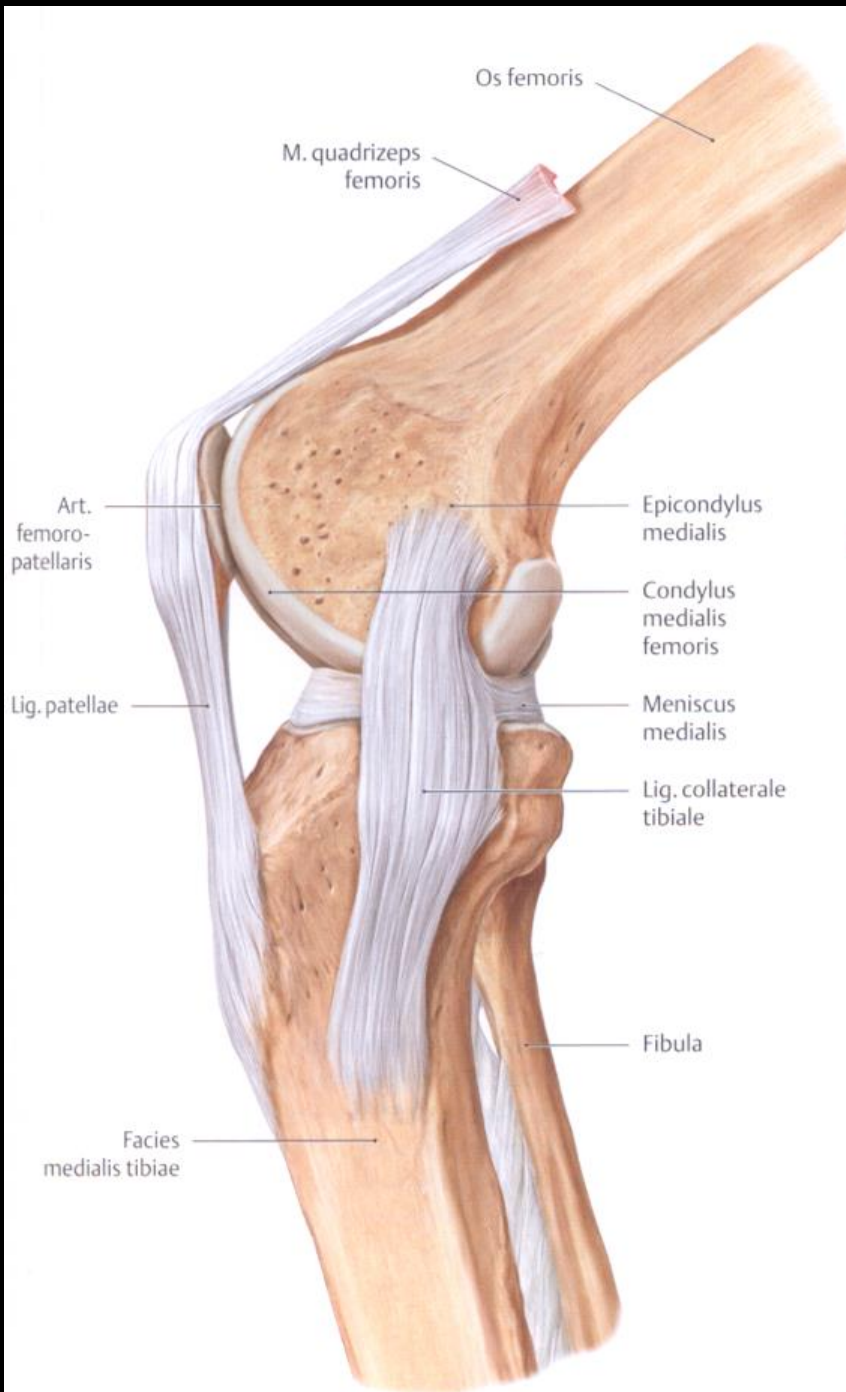


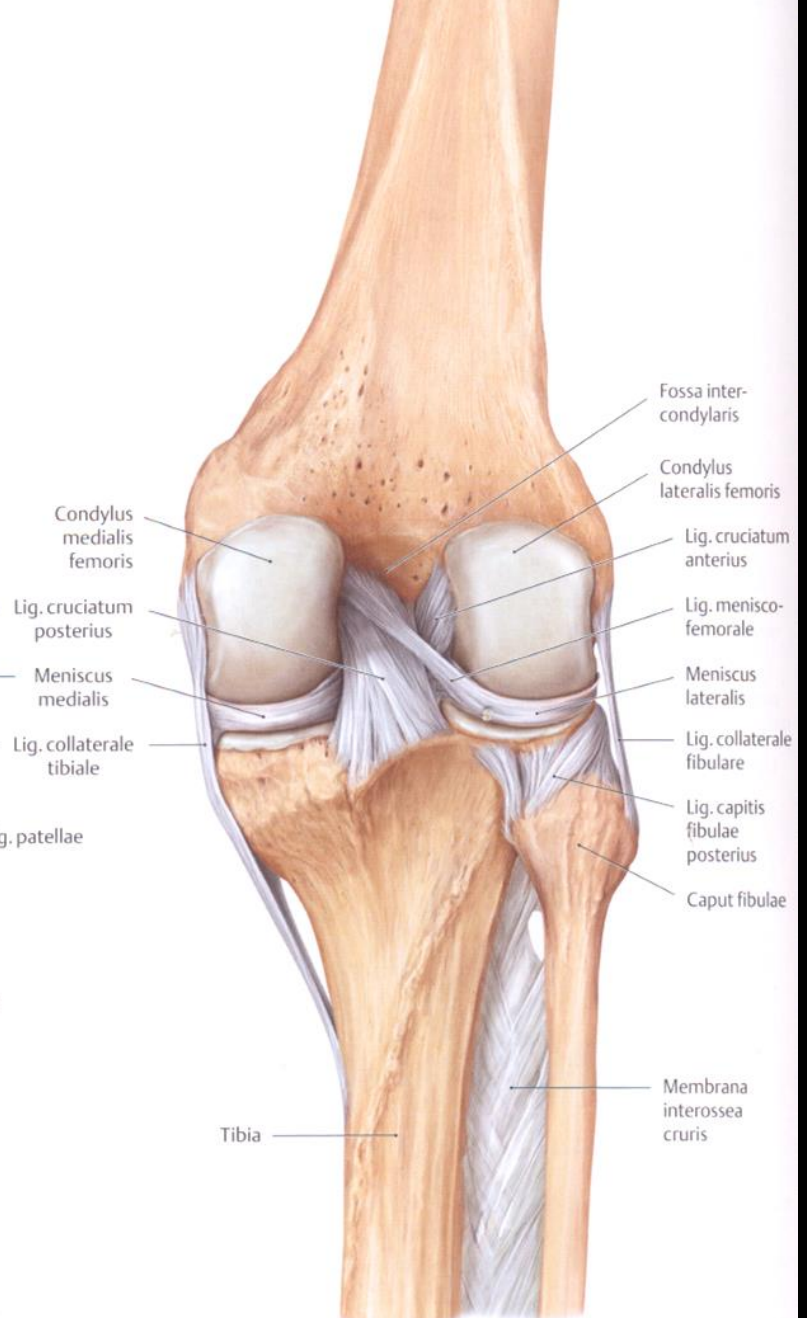
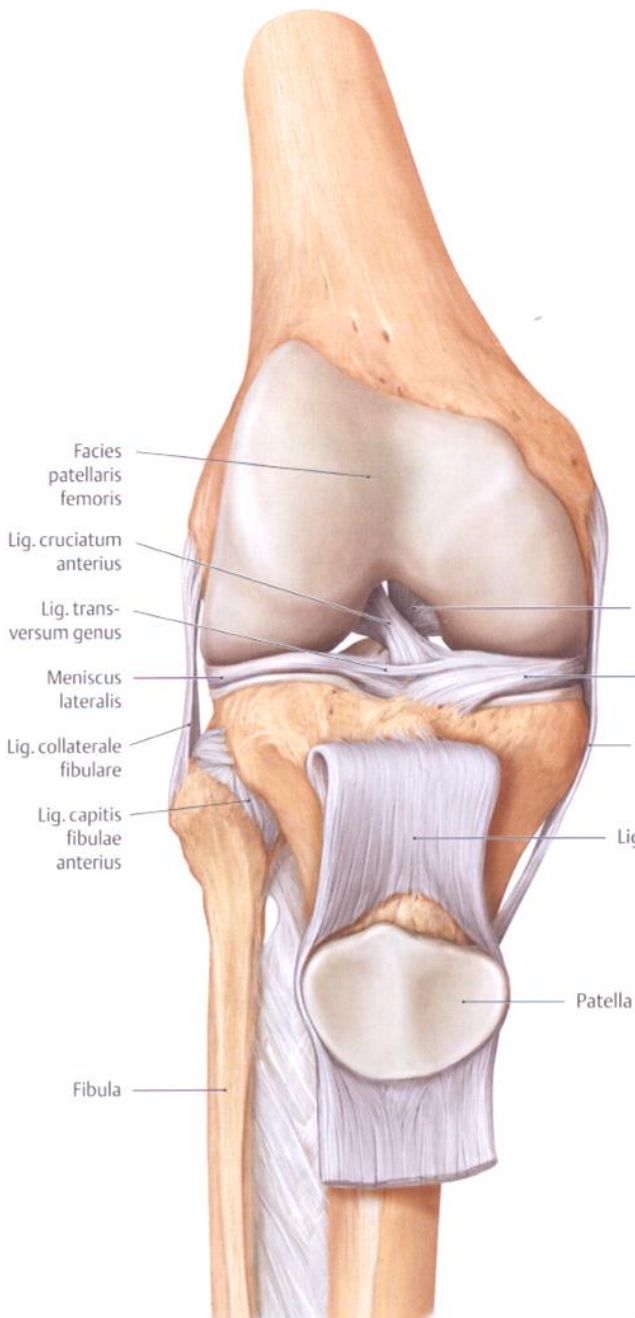
TÉRDÍZÜLET

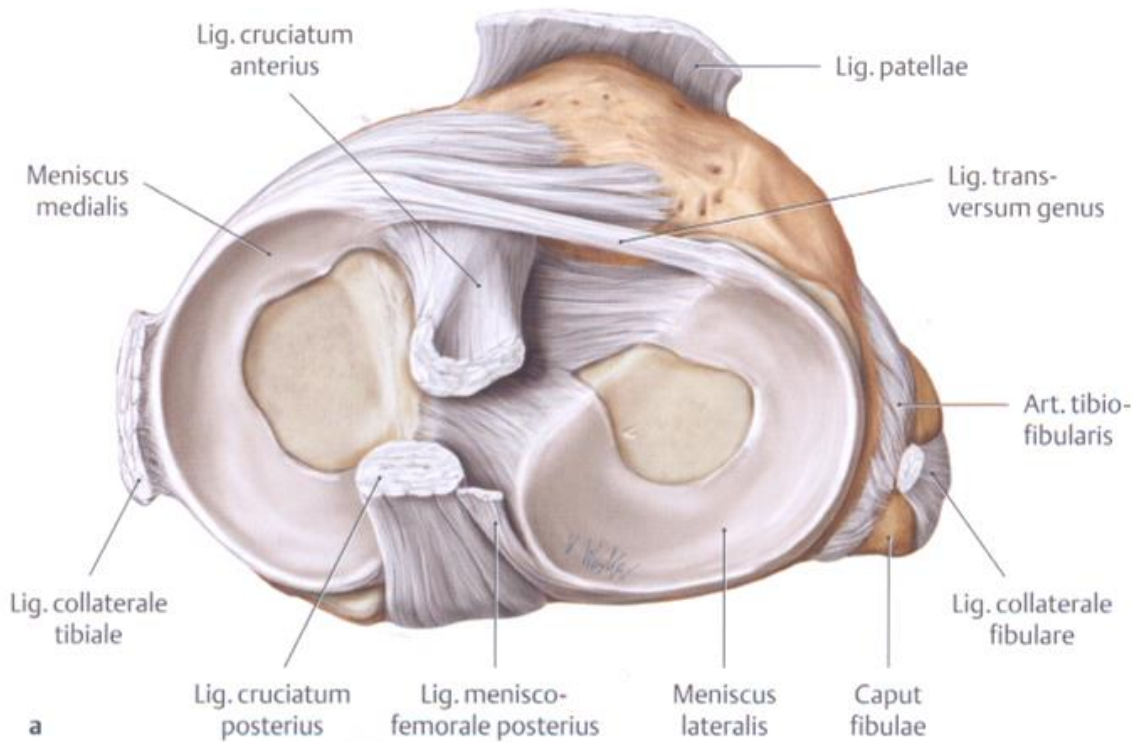
(articulatio genus)



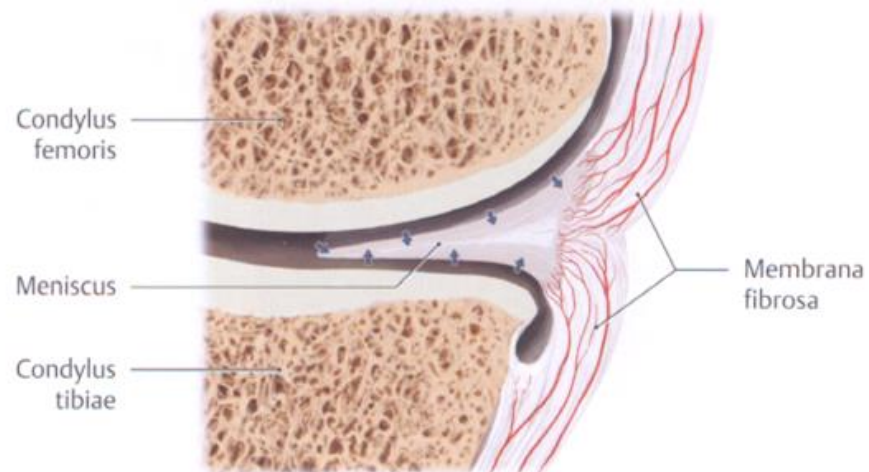
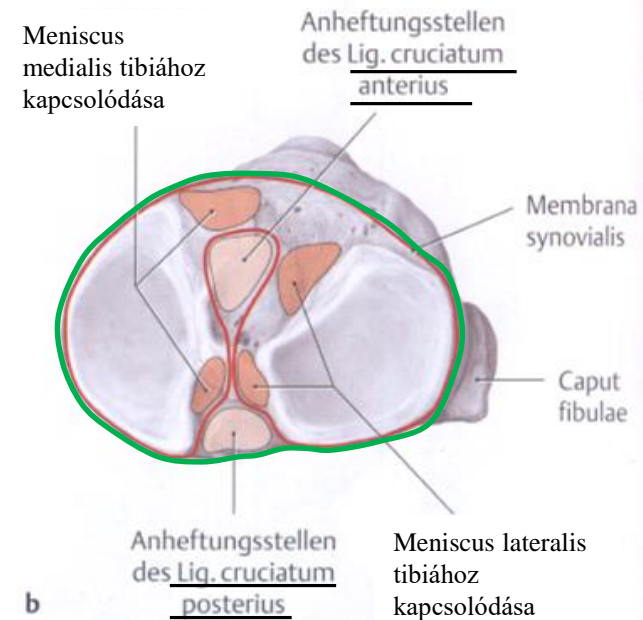


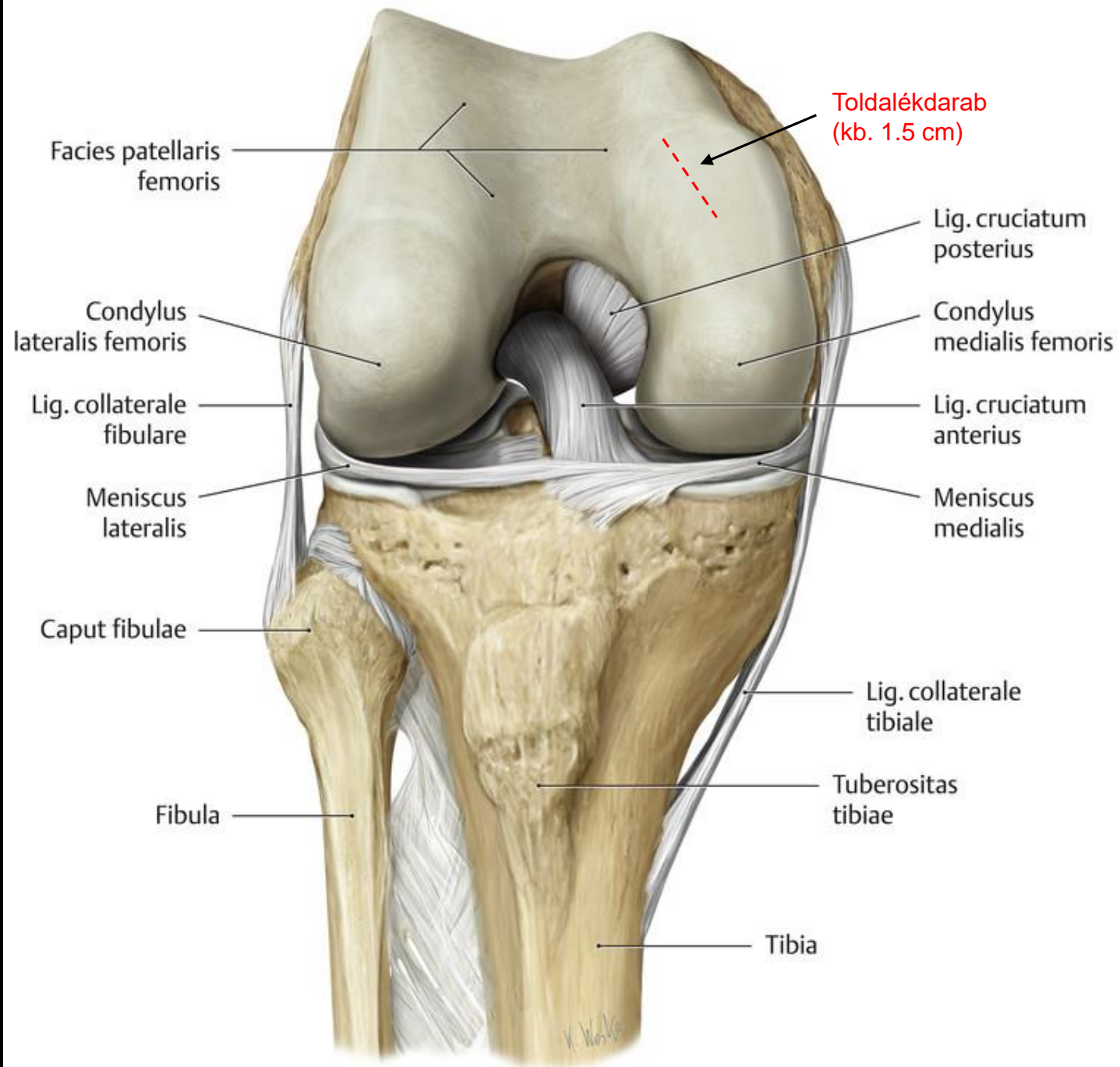


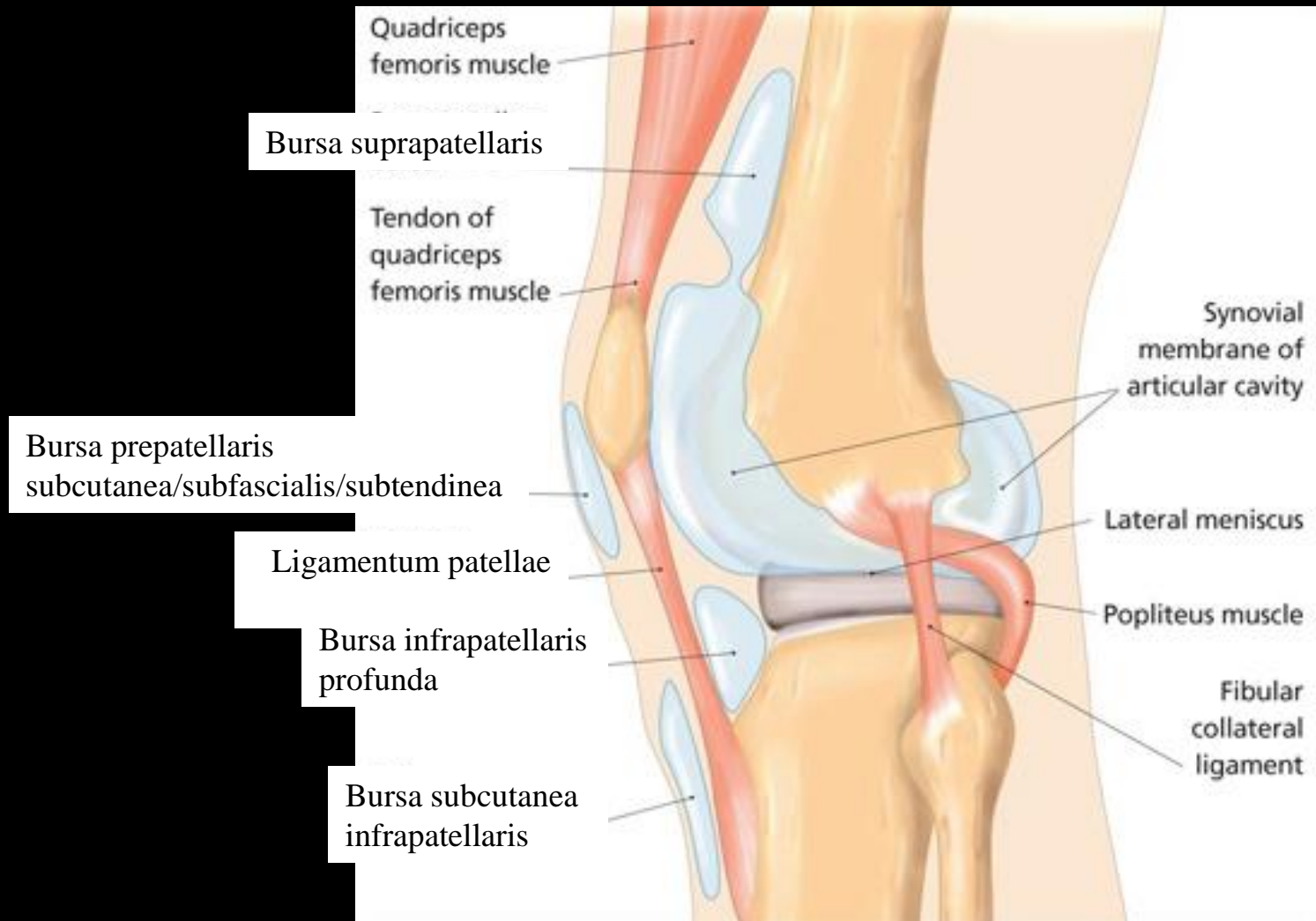




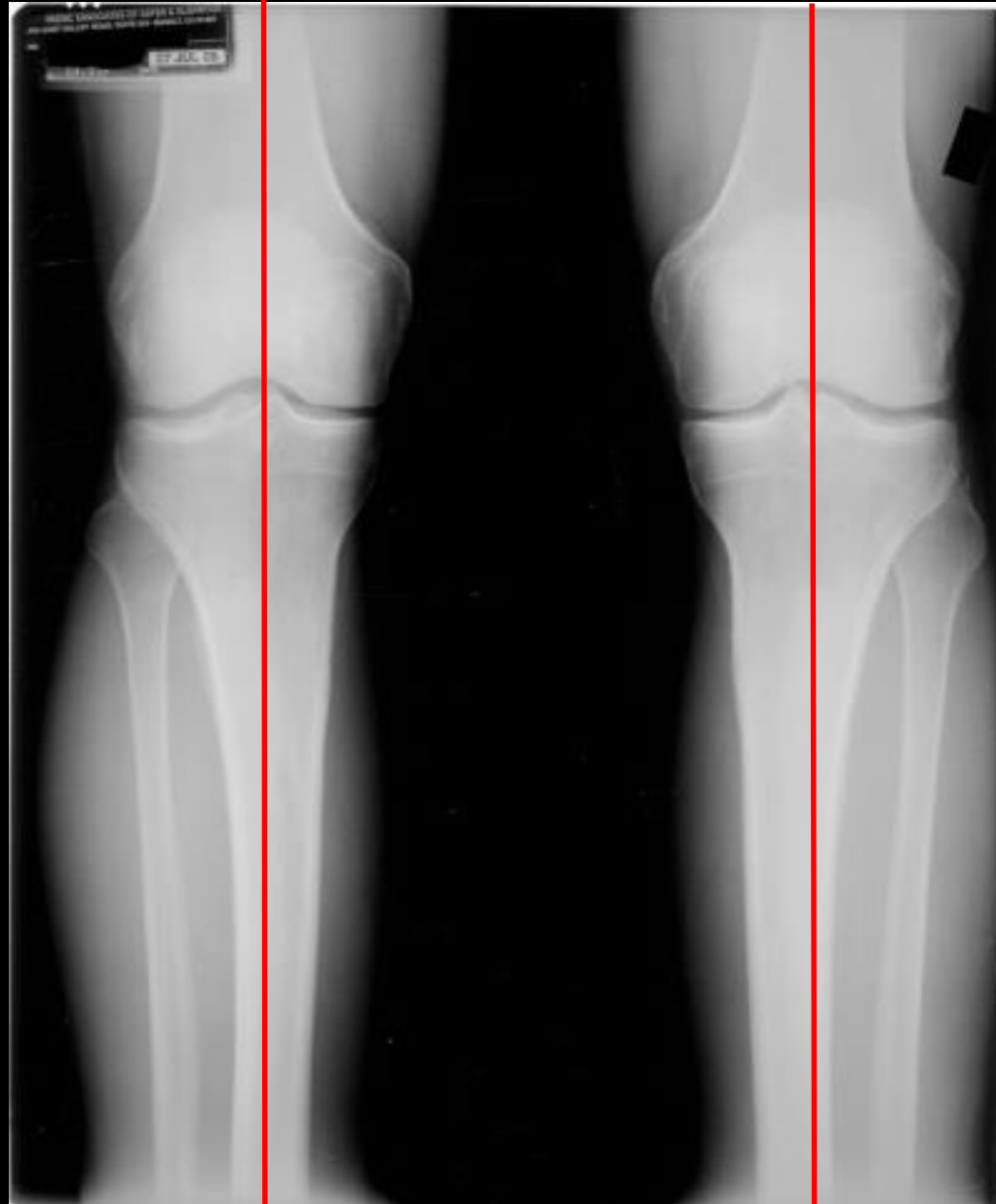
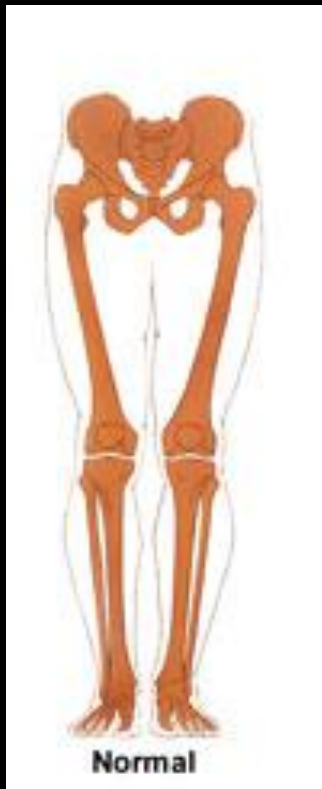Stratum fibrosum Stratum synoviale



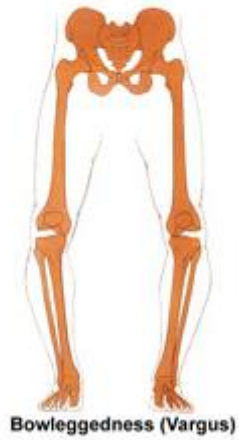



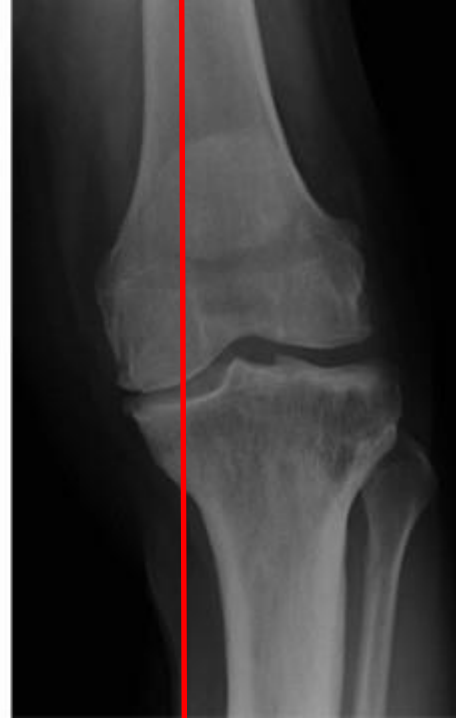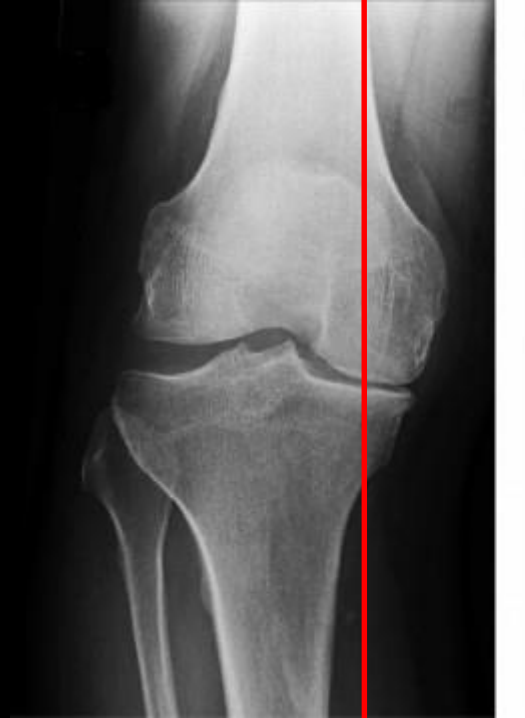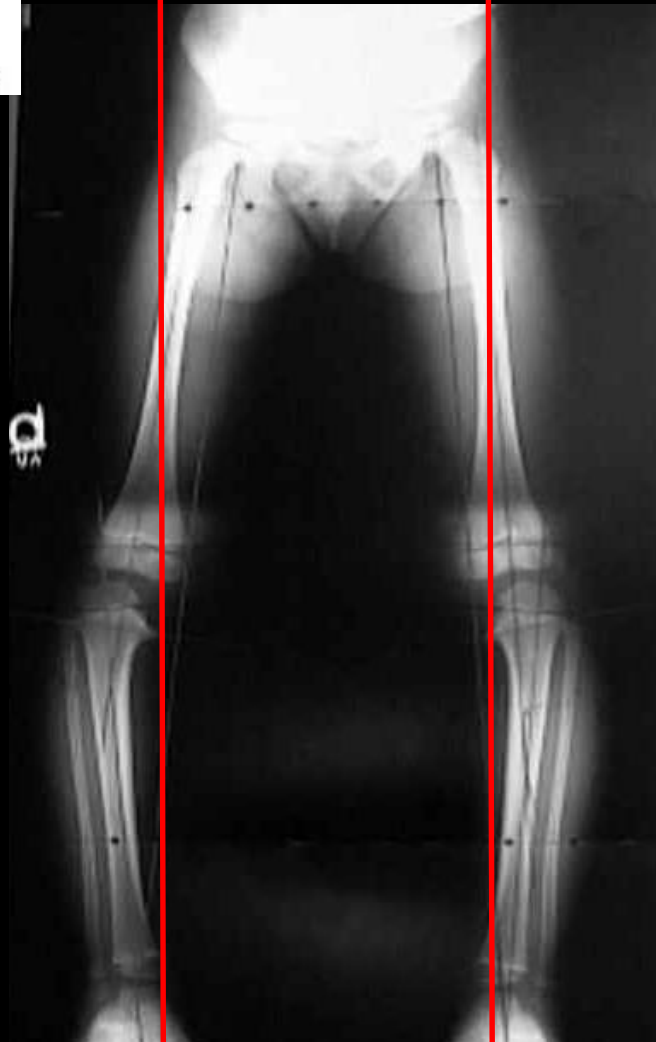
Genu rectum



Genu varum



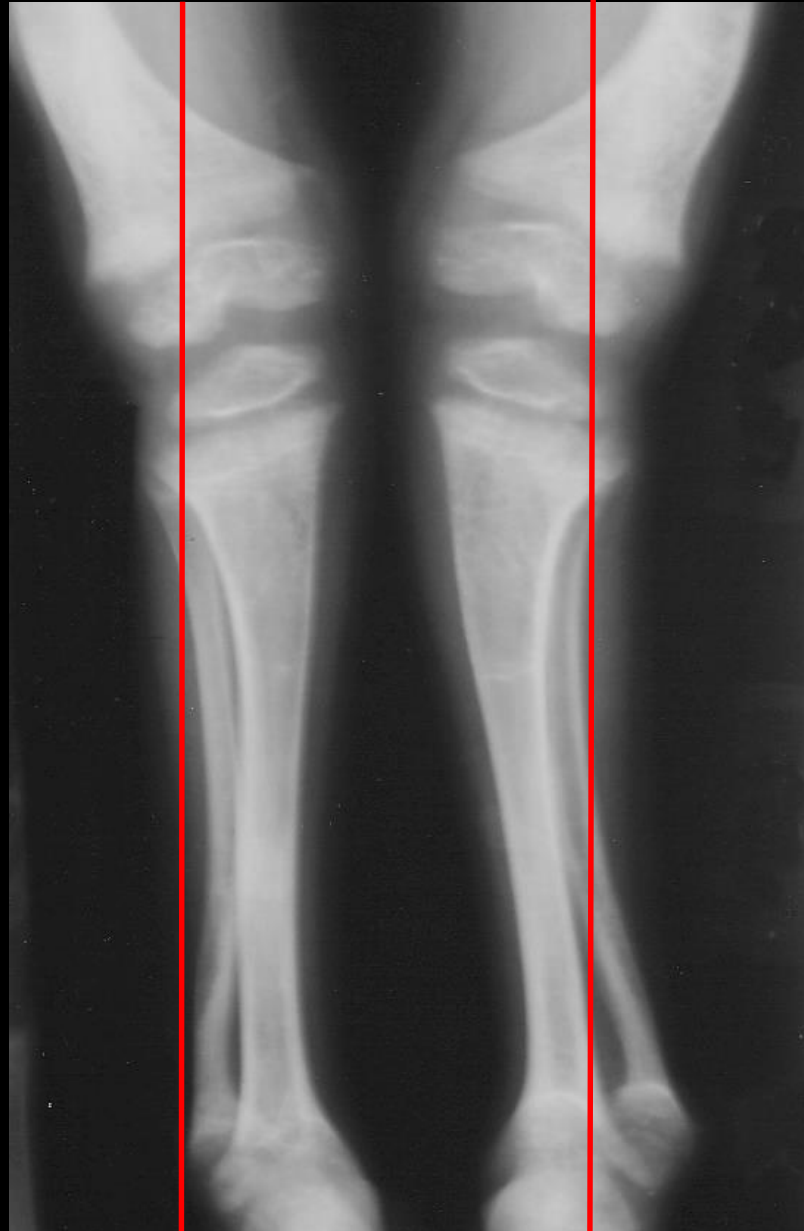Bowleggedness (Vargus)



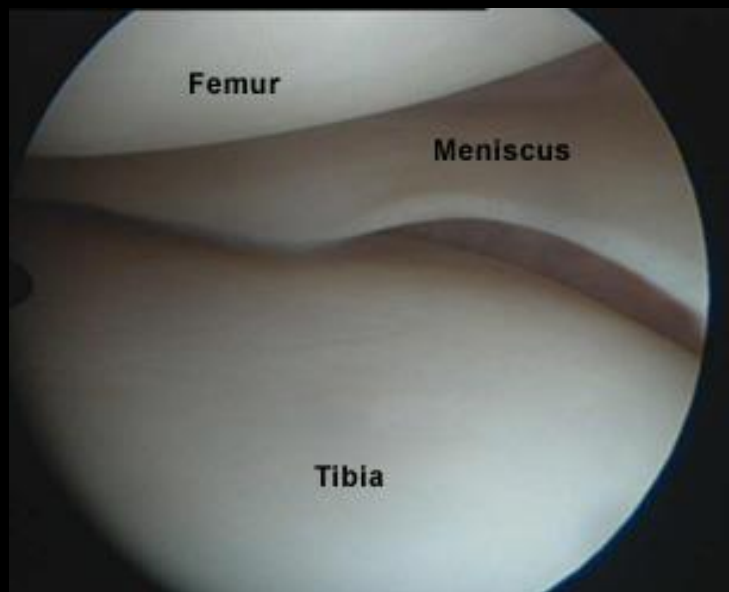
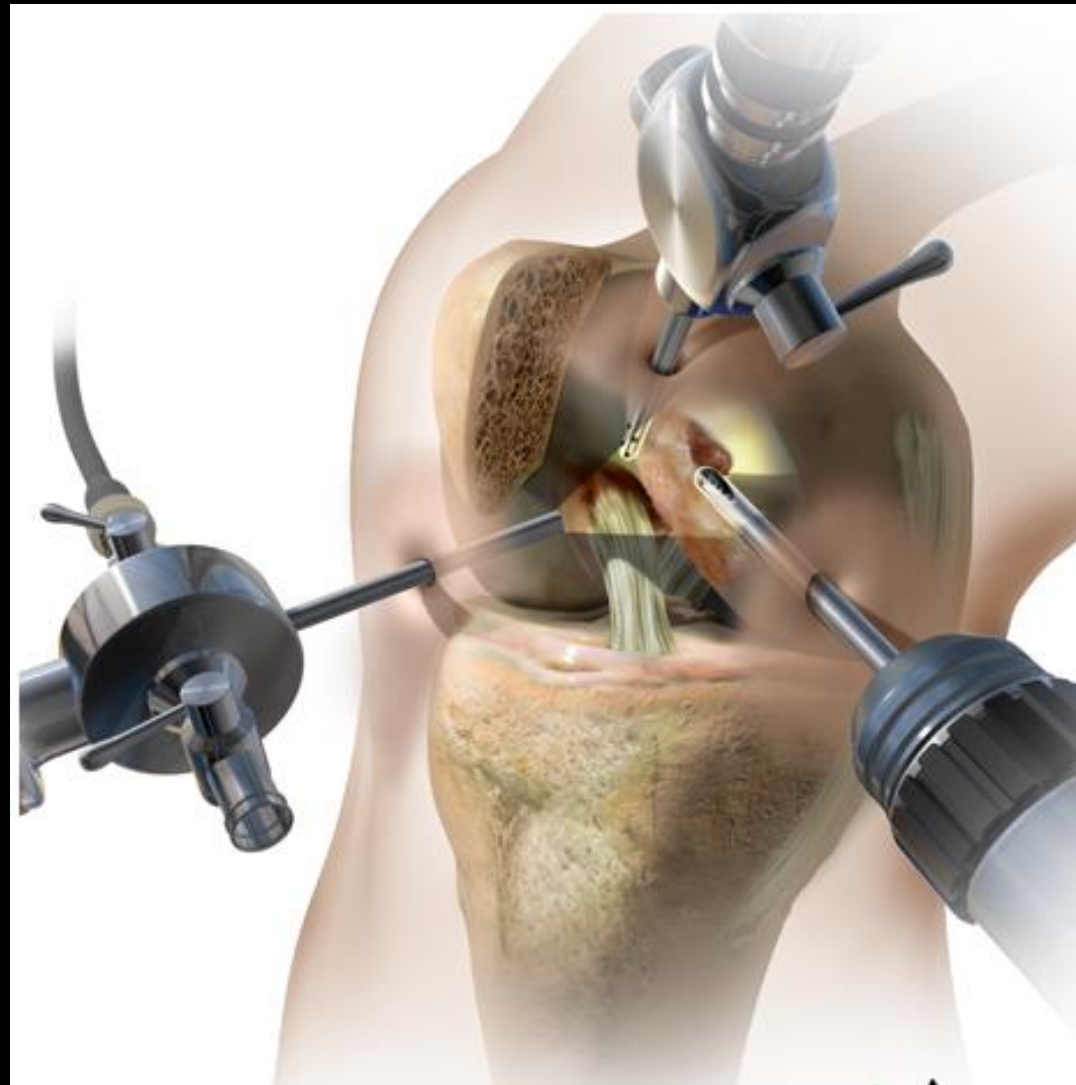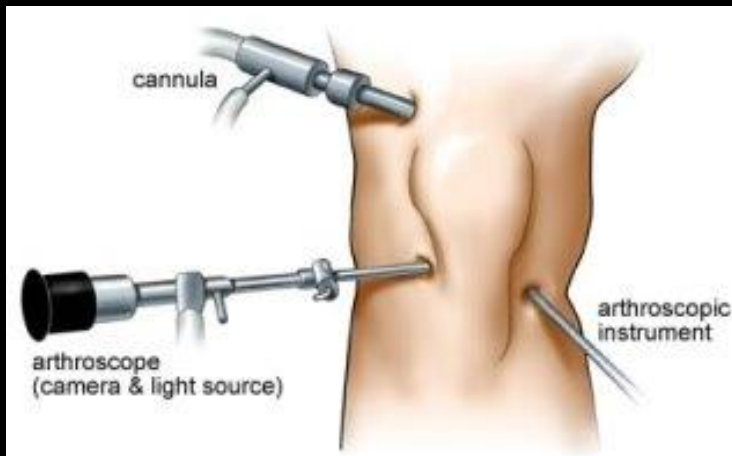
Genu valgum



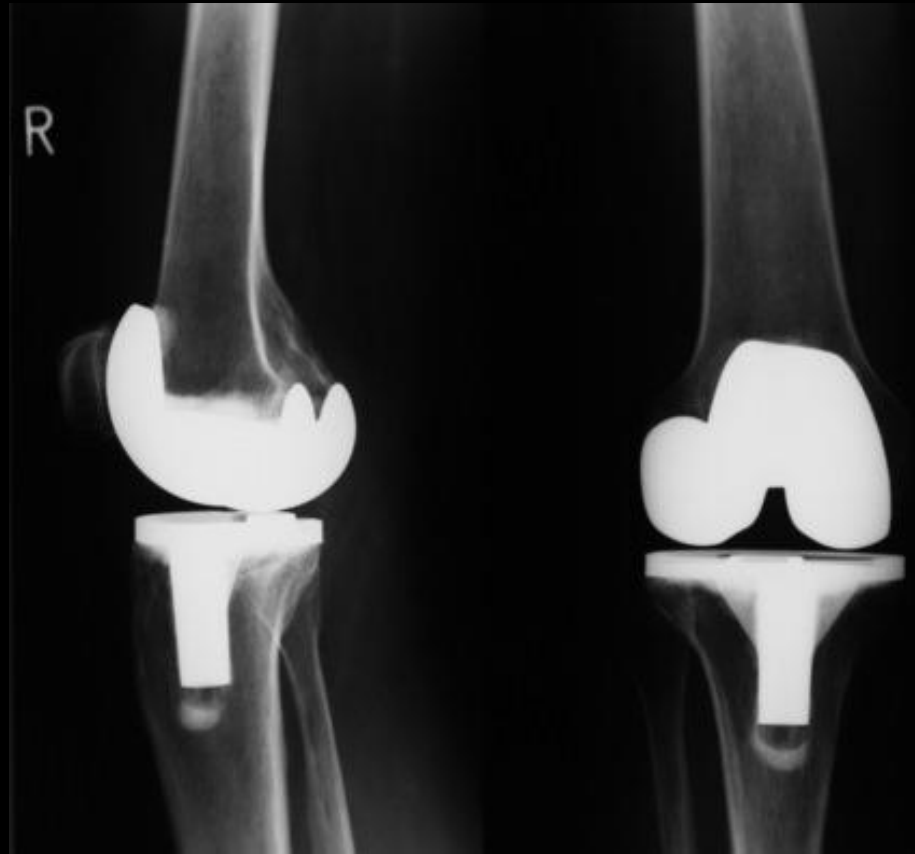
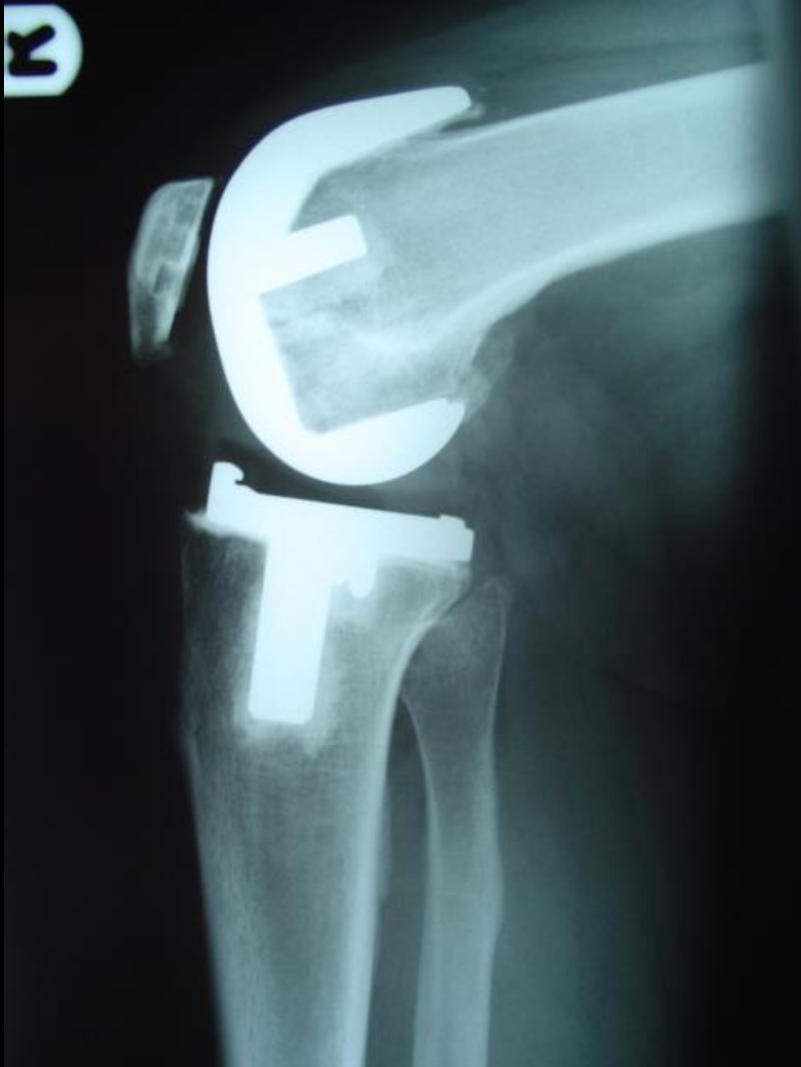Knock Knees (Valgus)



Arthroscopia

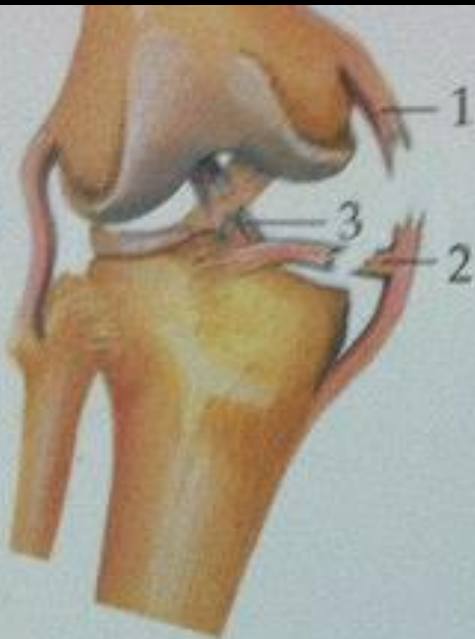

Térdprotézis



tear

3. Anterior cruciate
ligament tear



lateral collateral
ligament tear

Tackling can result in
the "unhappy triad."