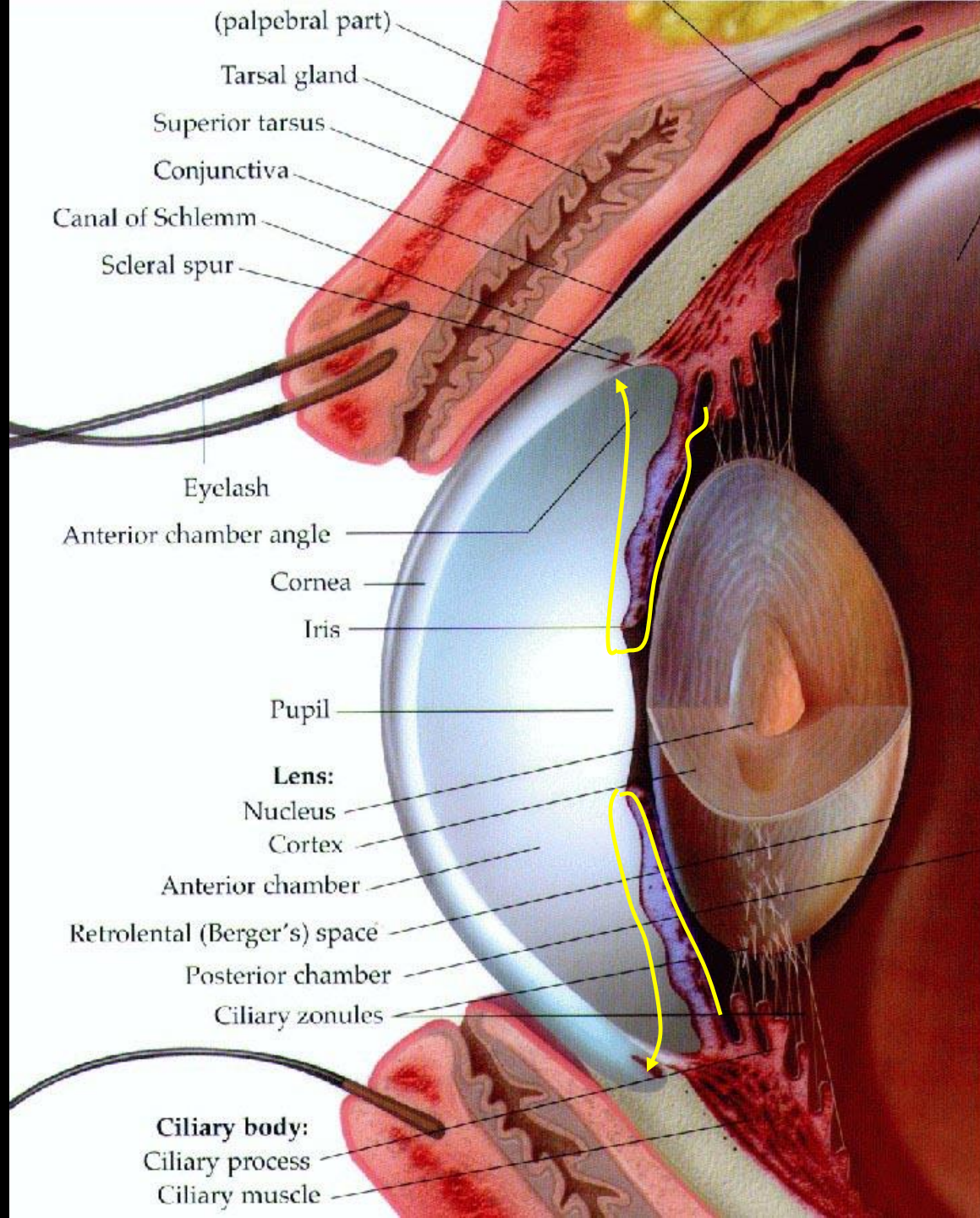


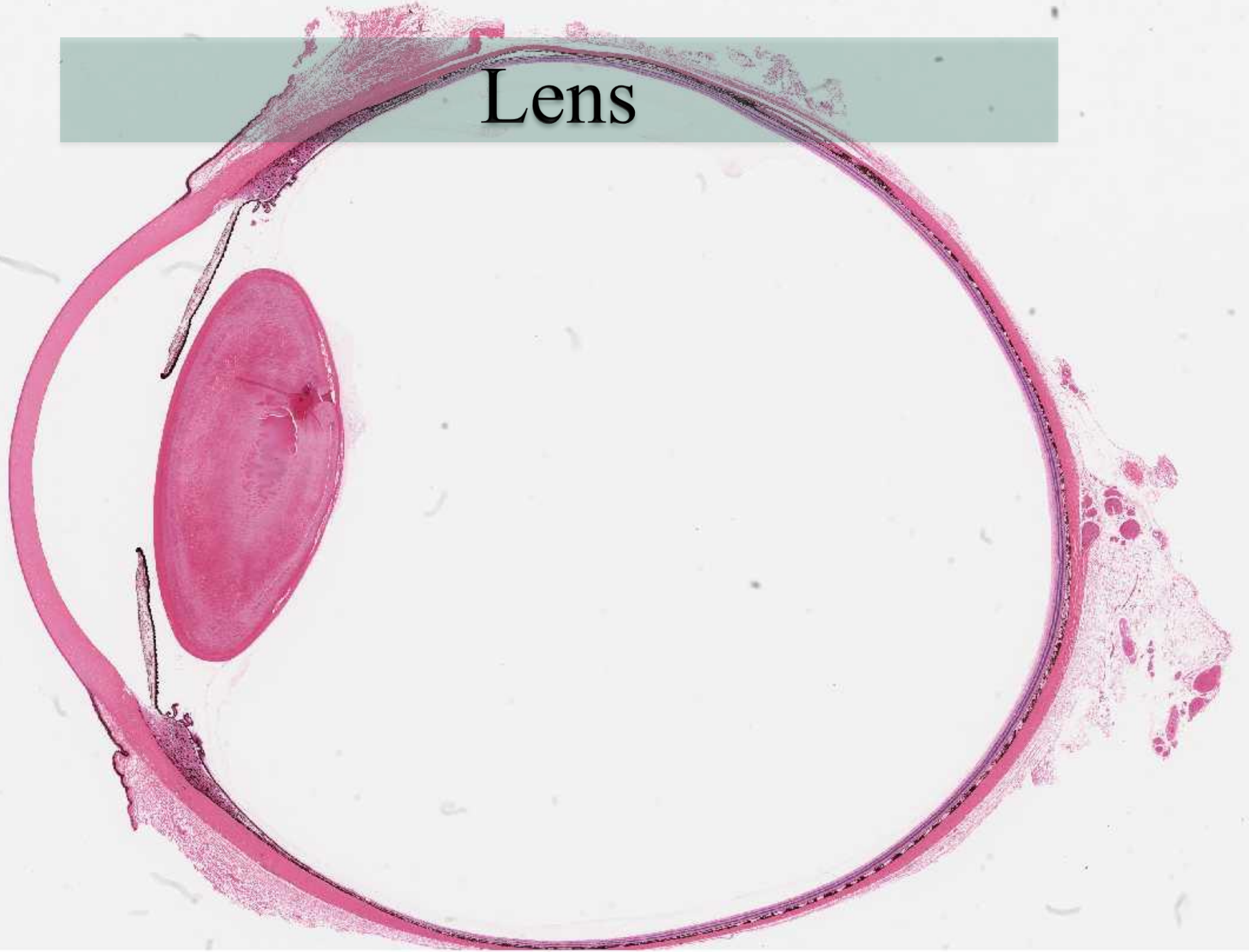
THE VISUAL ORGAN

János Barna

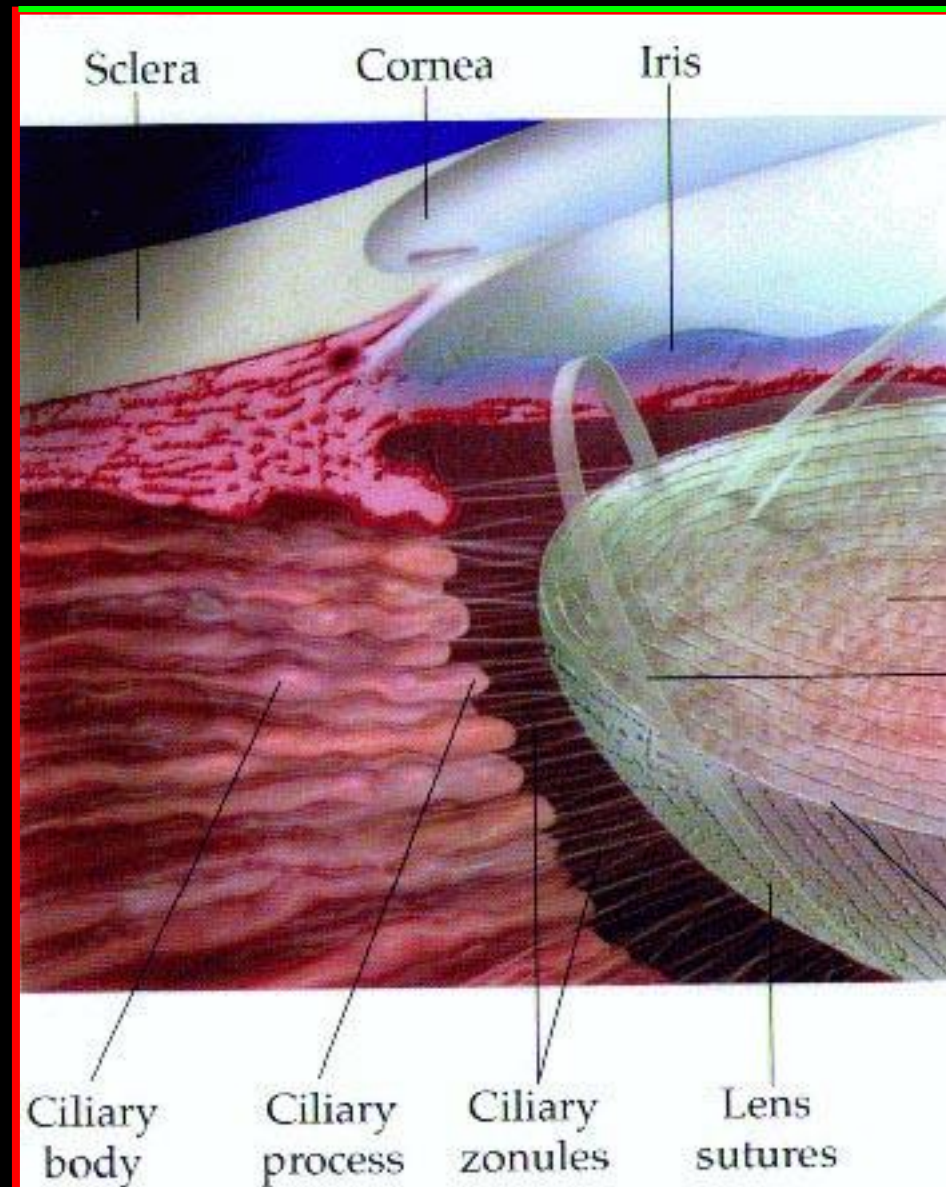
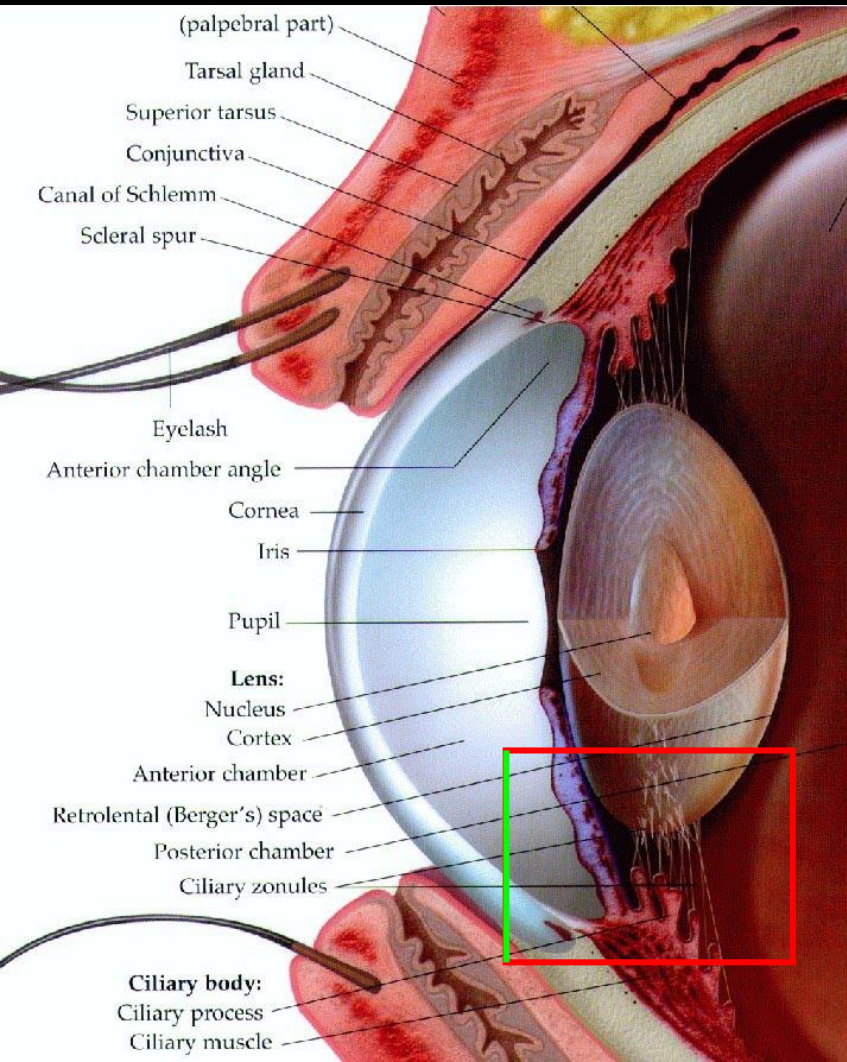
Drainage of aqueous humor



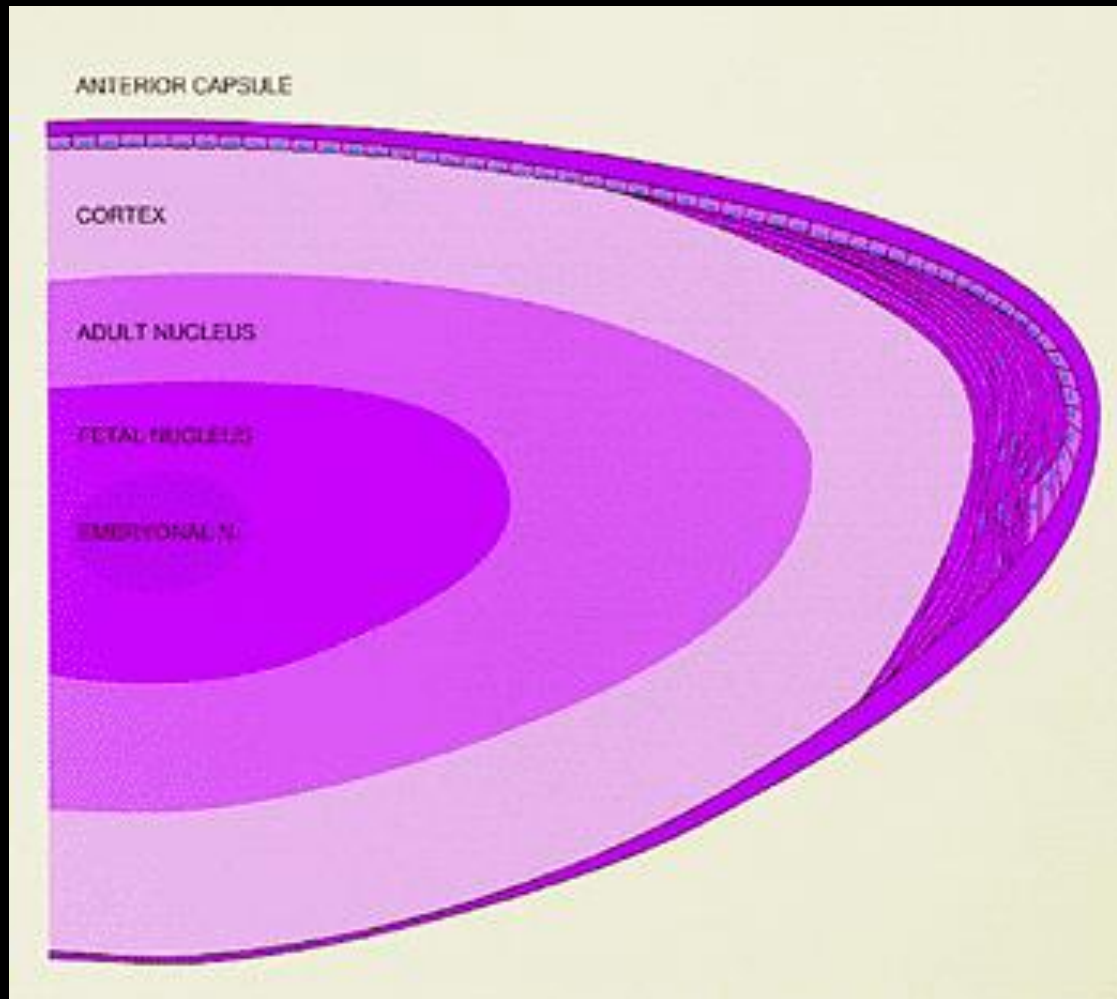
Lens



Ciliary body, zonular fibers



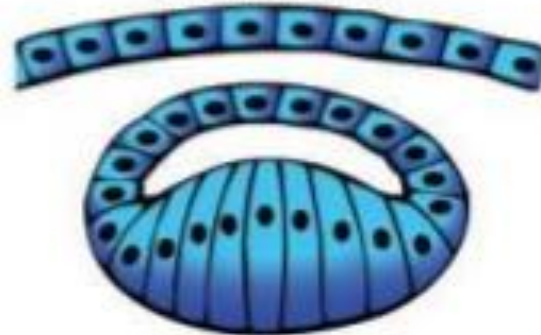Lens



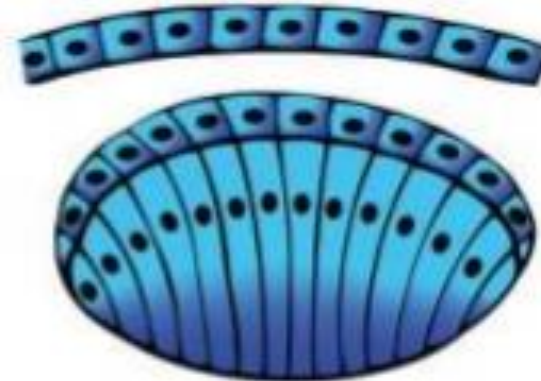
Lens vesicle (early)

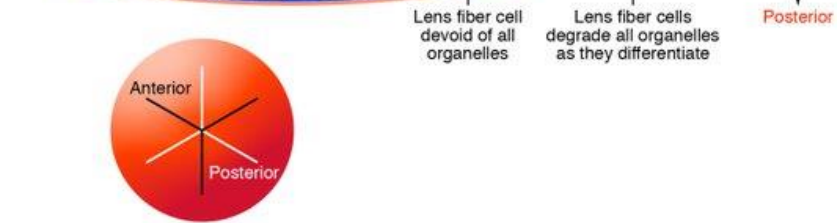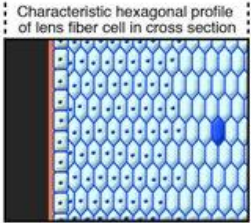
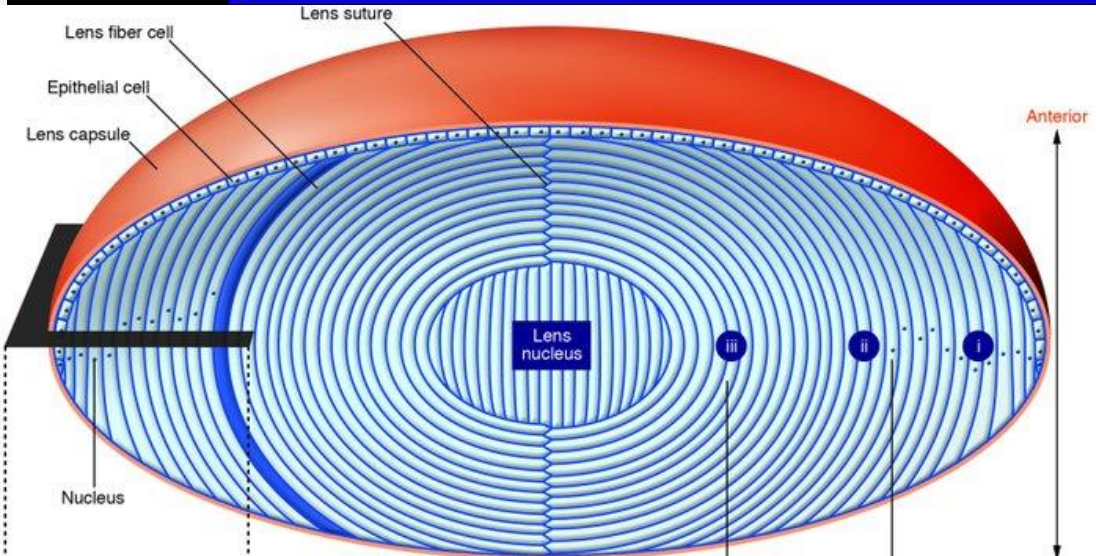
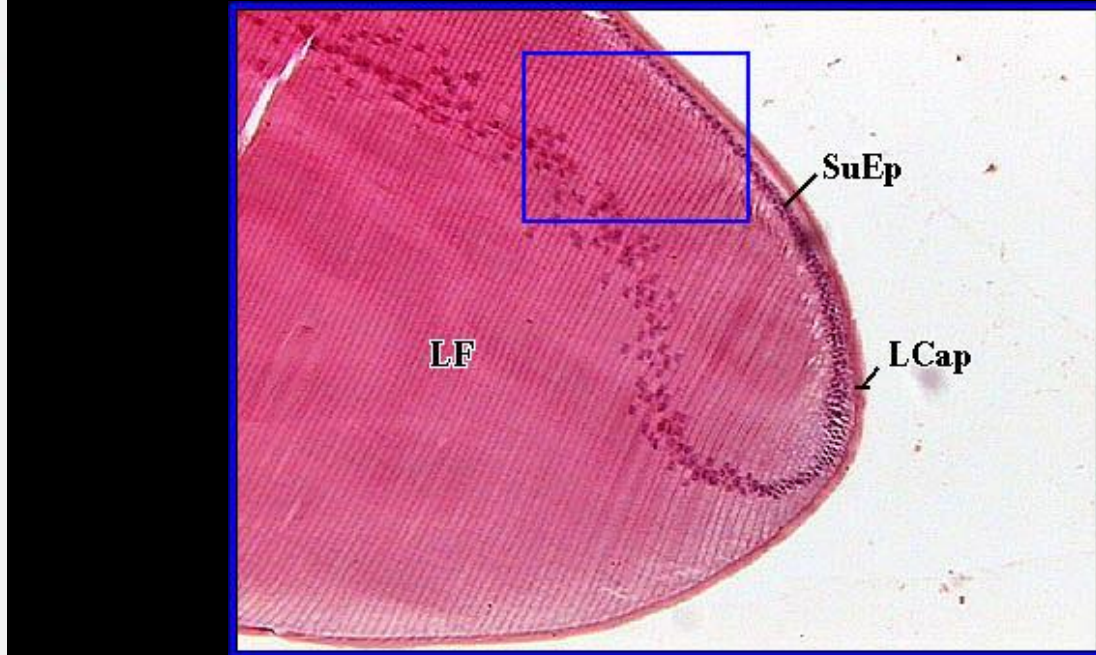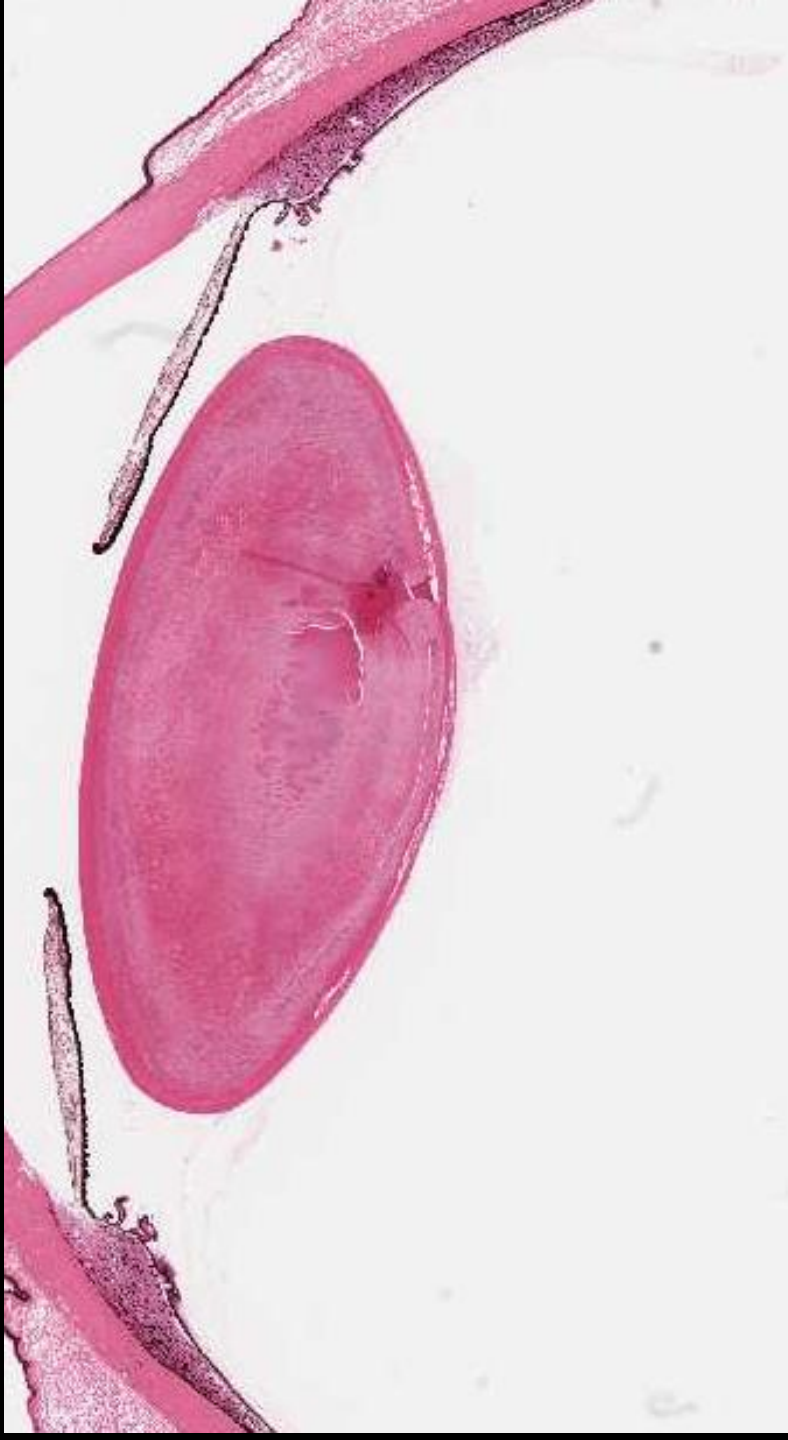


Lens vesicle (late)

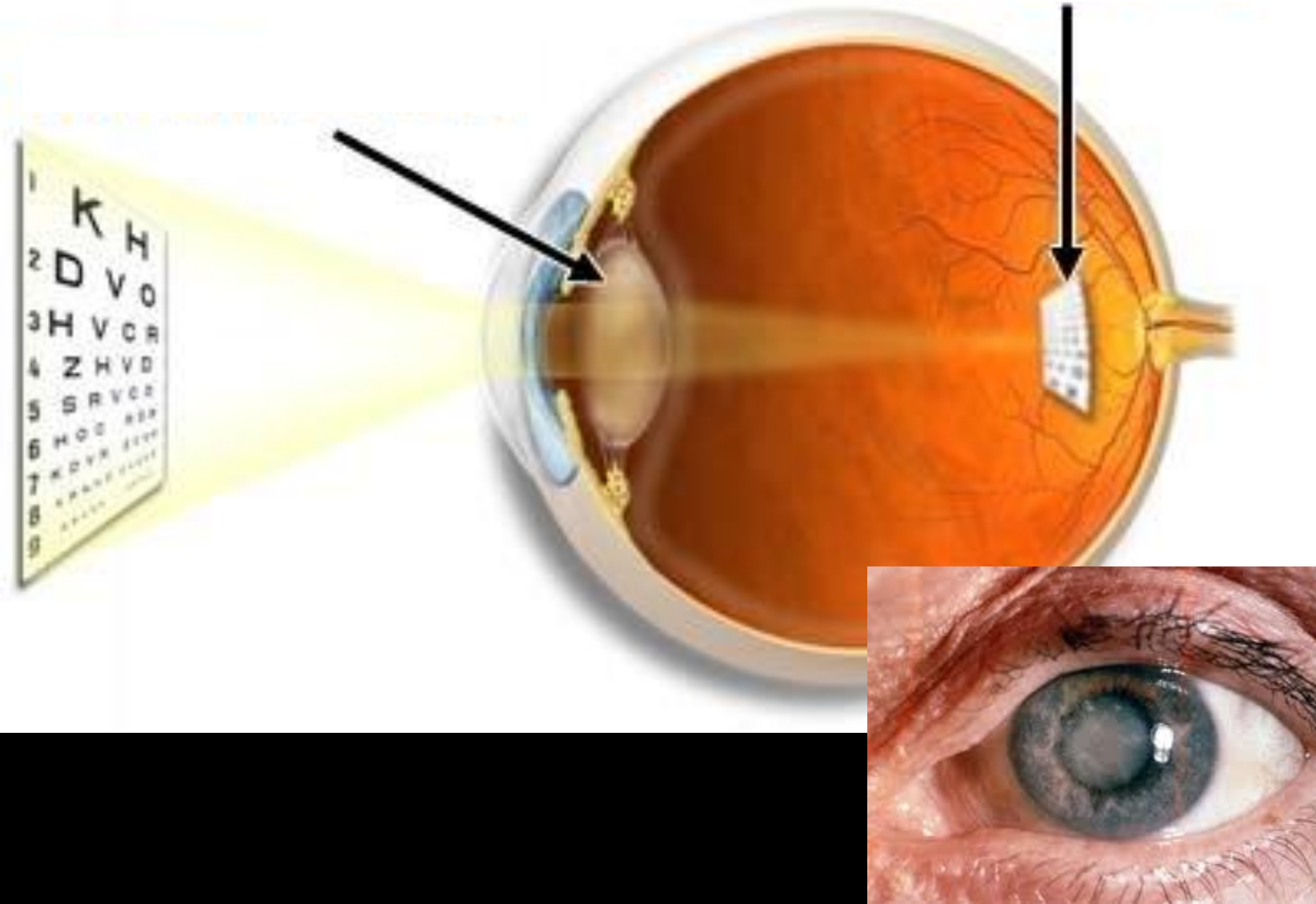


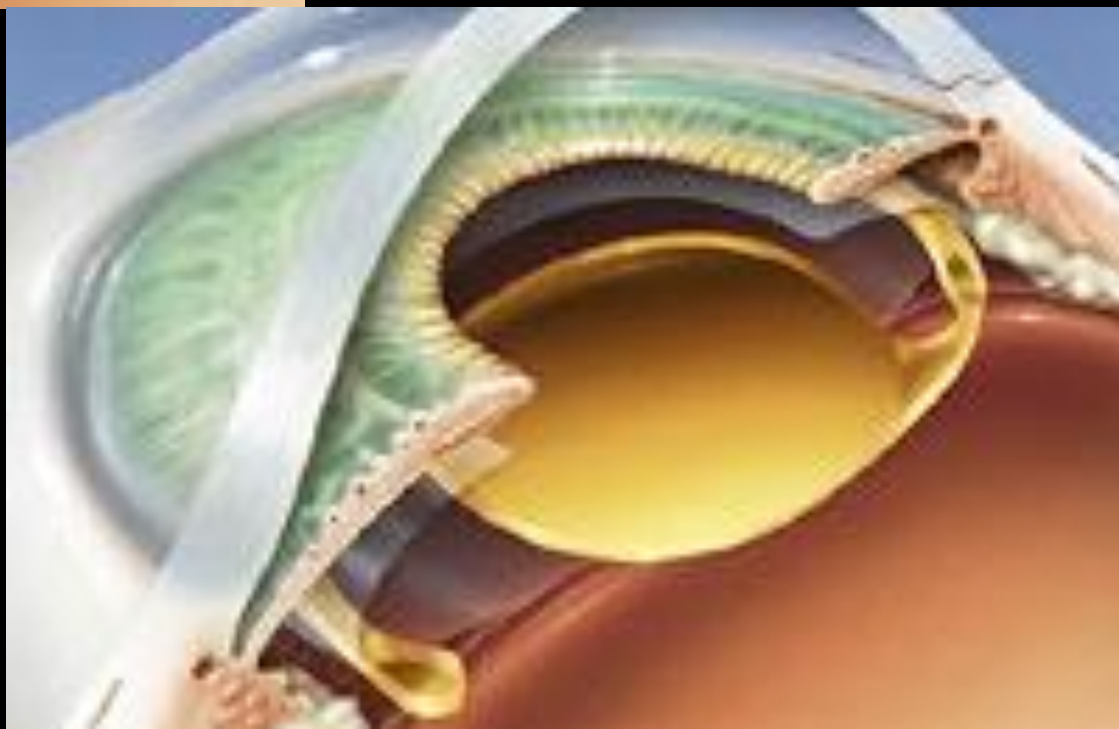
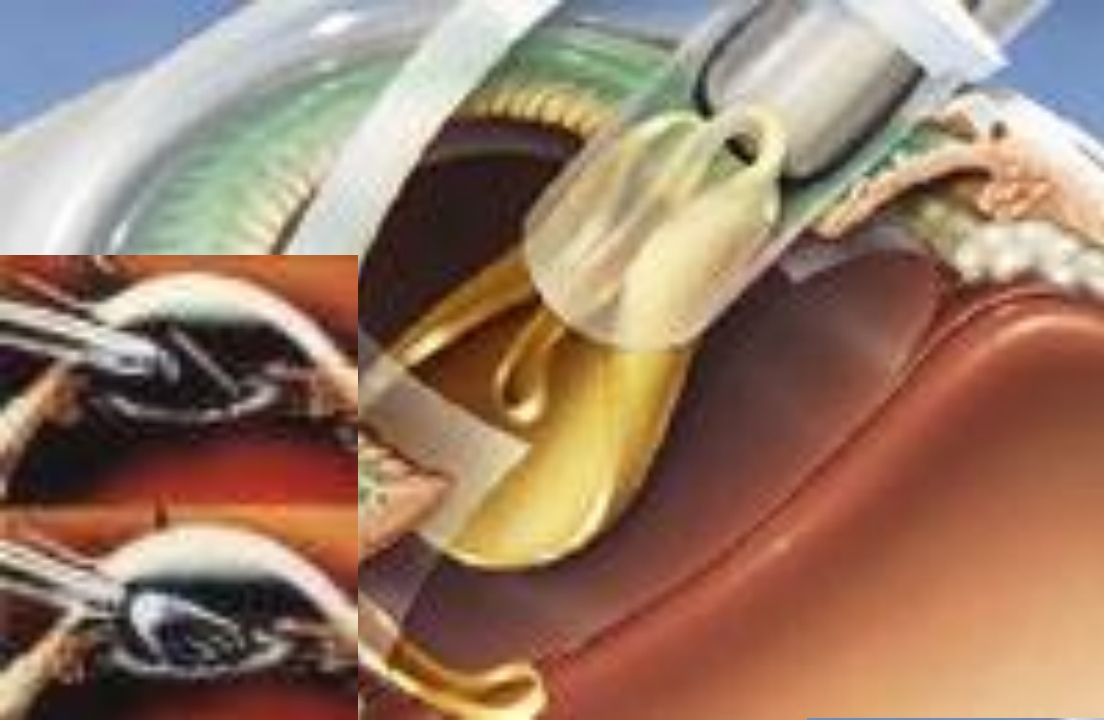
Embryonic lens (nucleus)



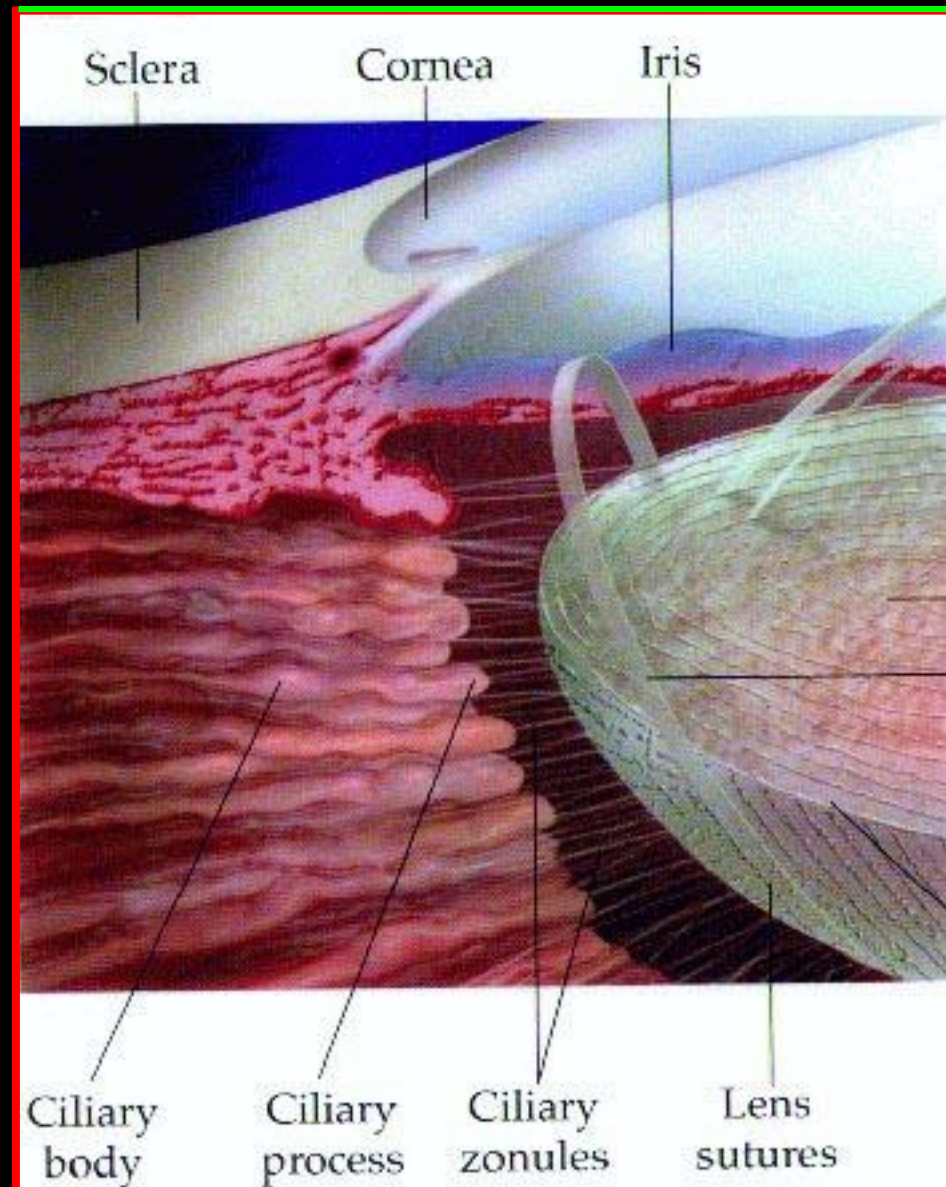
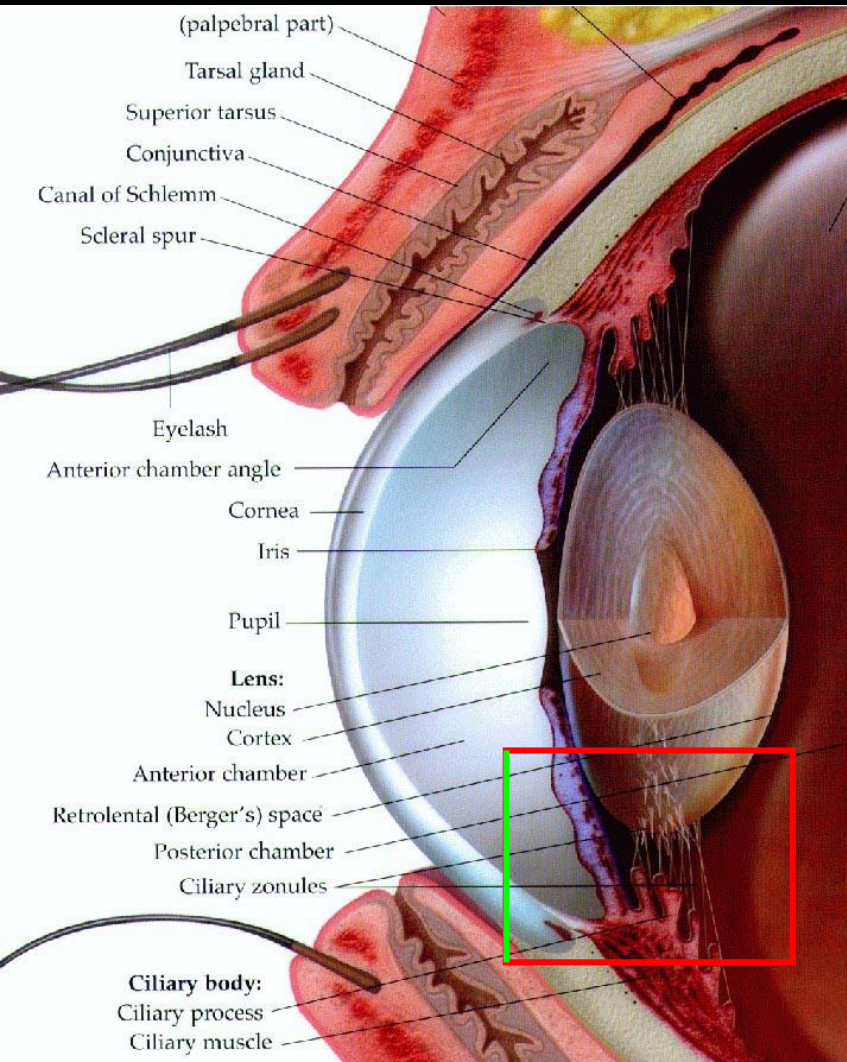


CATARACT

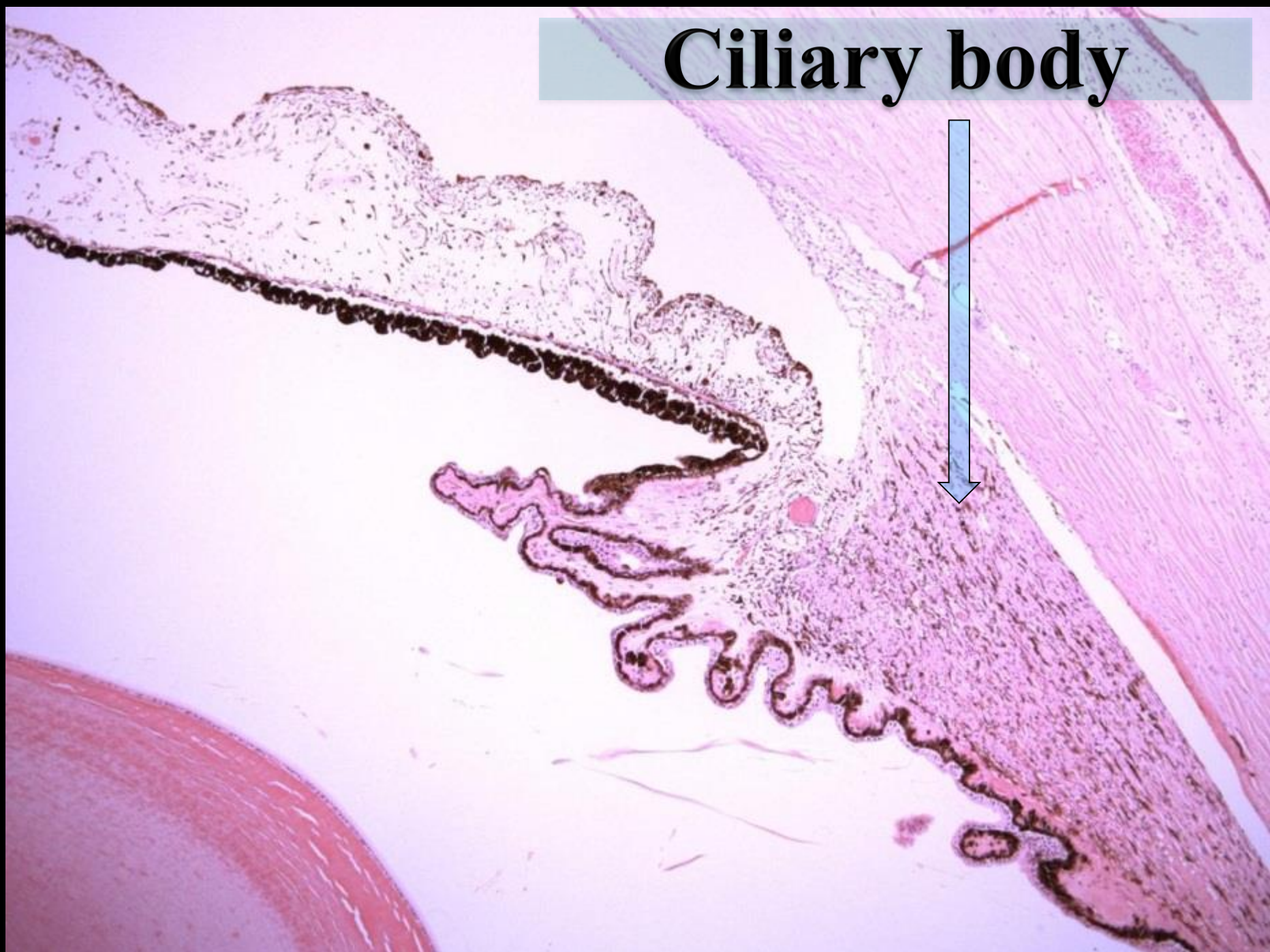


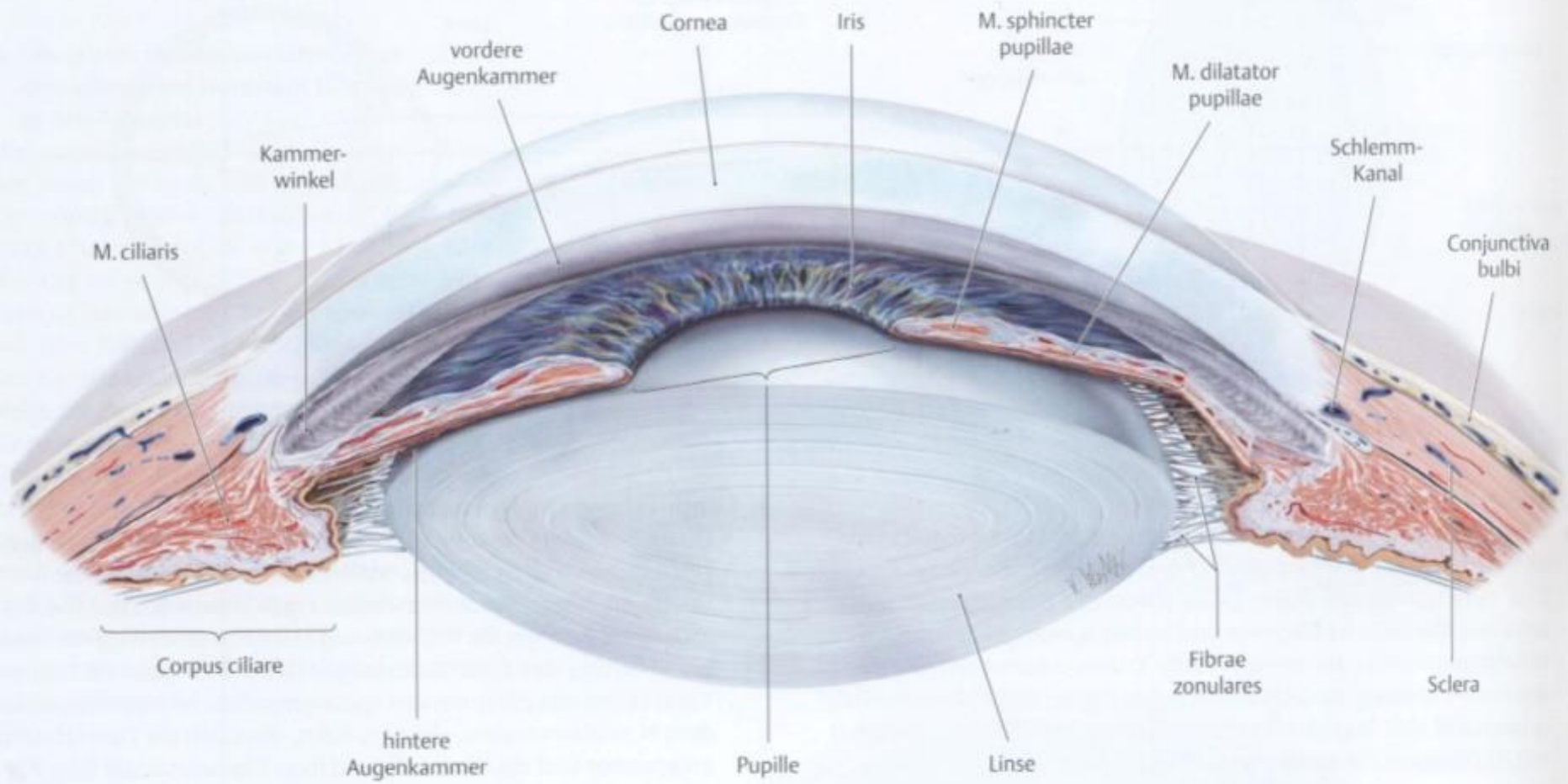


Ciliary body, zonular fibers



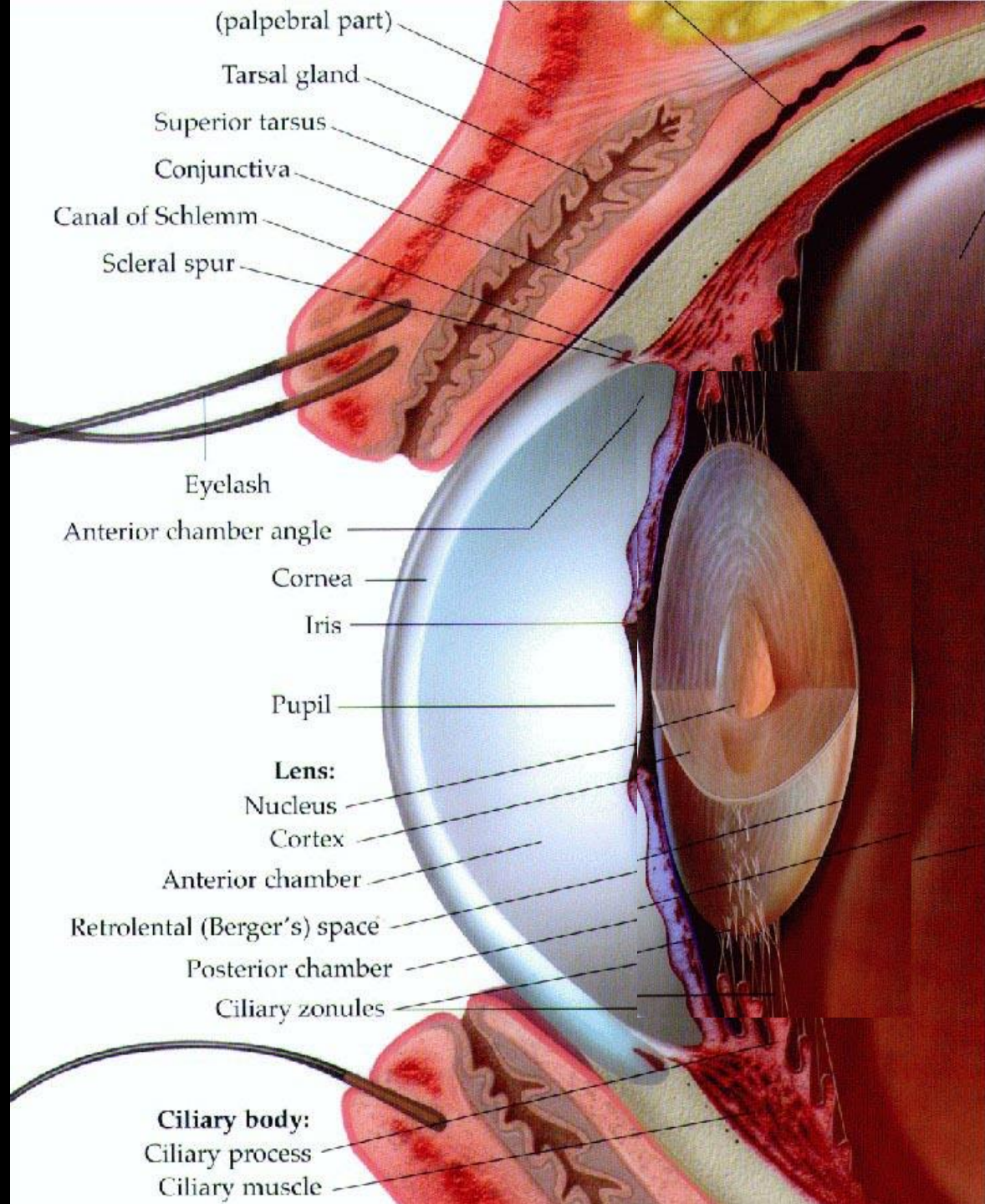
Ciliary body





Accomodation

Accommodation of the eye



Vitreous body

