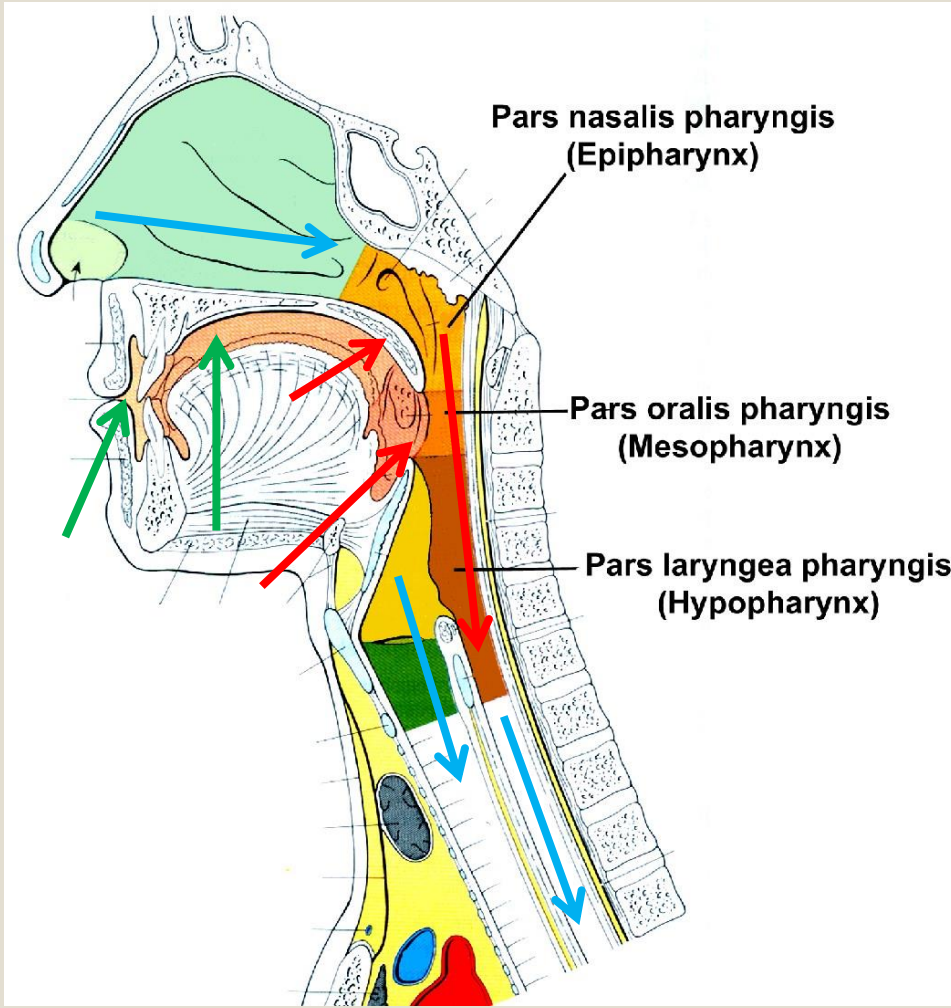


**Torokszoros,  
lány szájpad,  
garat**

**Dr. Hanics János**

# Volt – Van – Lesz

→ ↑ →



→ Szájüreg (cavum oris):  
 - Vestibulum oris  
 - Cavum oris proprium

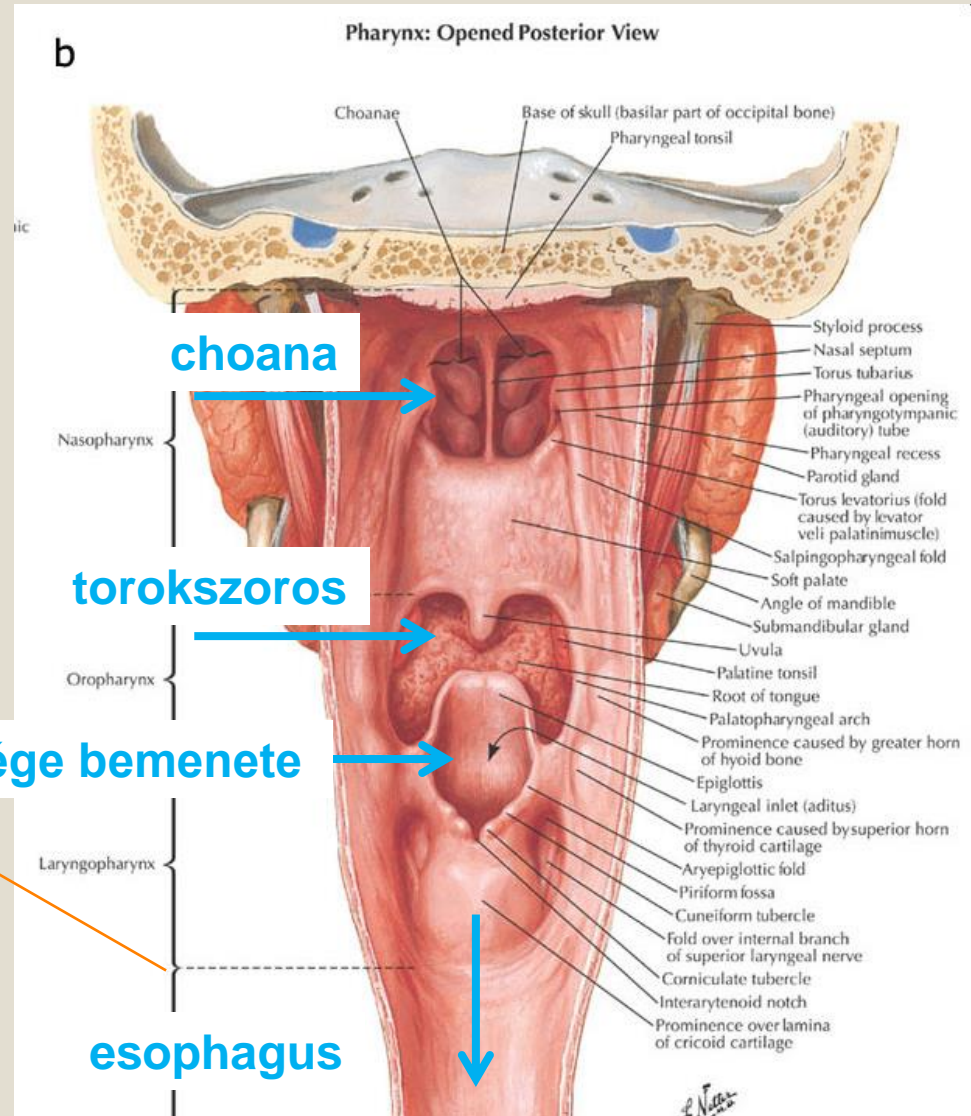
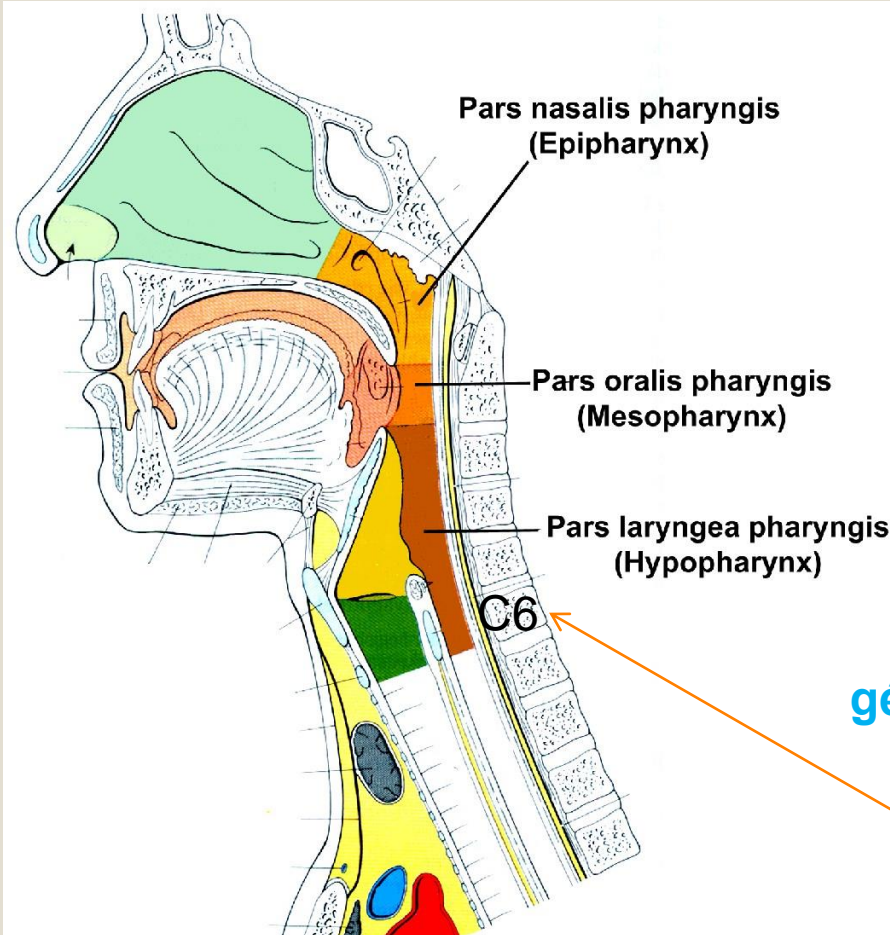
→ Lágy szájpad (velum palatinum)  
 Torokszoros (isthmus faucium)  
 Garat (pharynx)

→ Orrüreg (cavum nasi)  
 Gége (larynx)  
 Nyelőcső (esophagus)

# Garat (pharynx)

Elülső fala gyakorlatilag nincs -  
Helyette 3 kapcsolat (+ lefelé a cső folytatása)

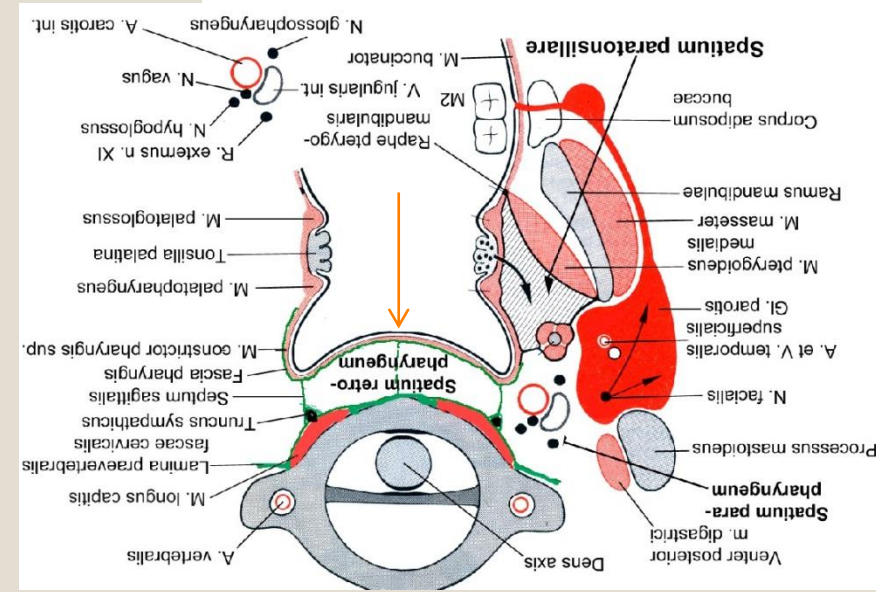
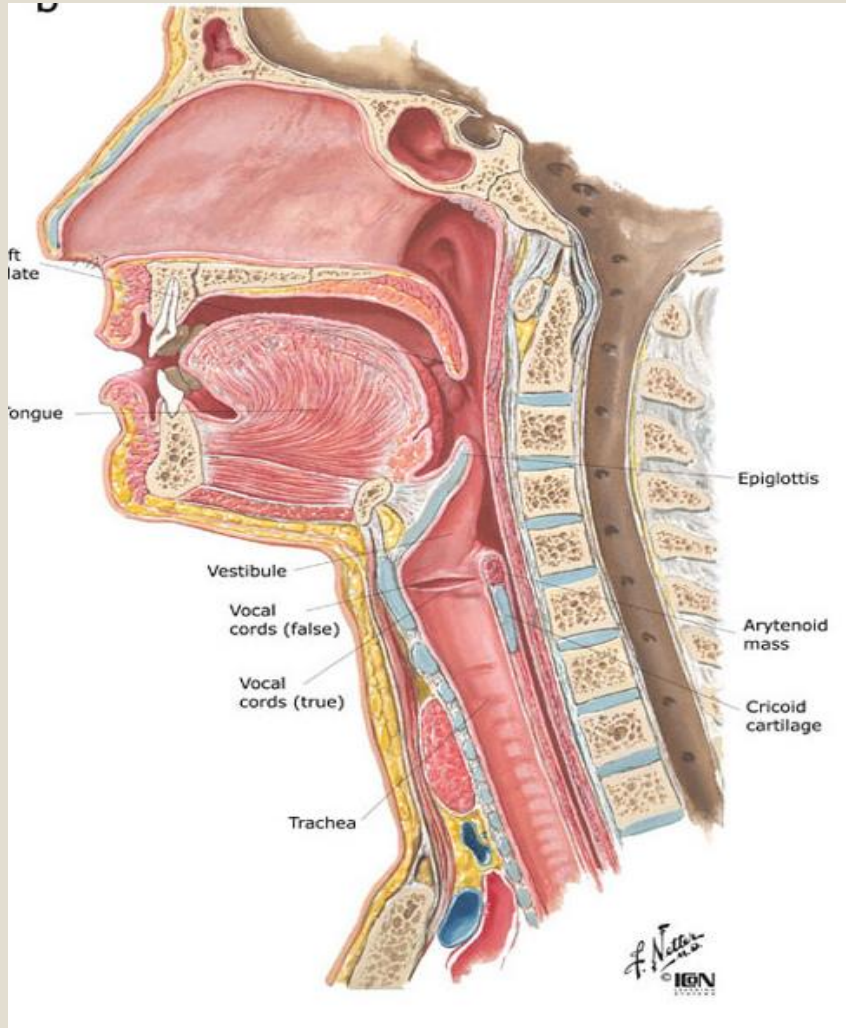
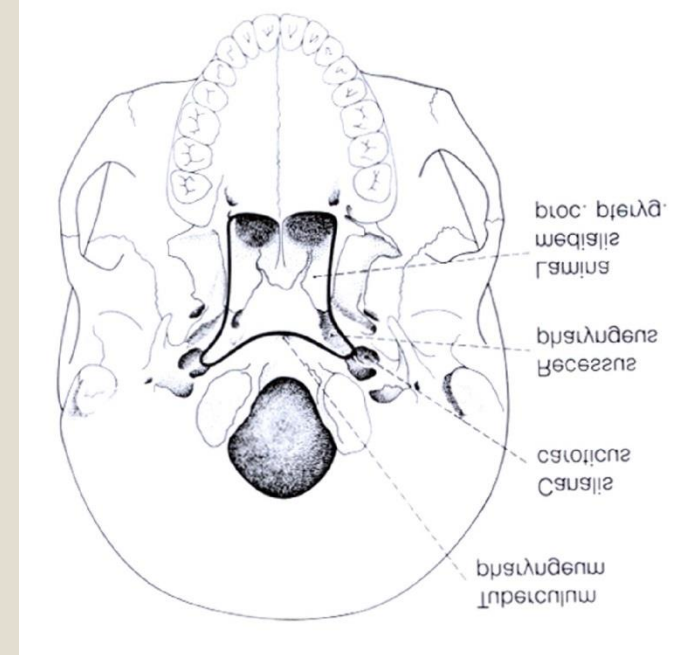
3 szintje van:



# Falára 4 réteg jellemző: **Garat (pharynx)**

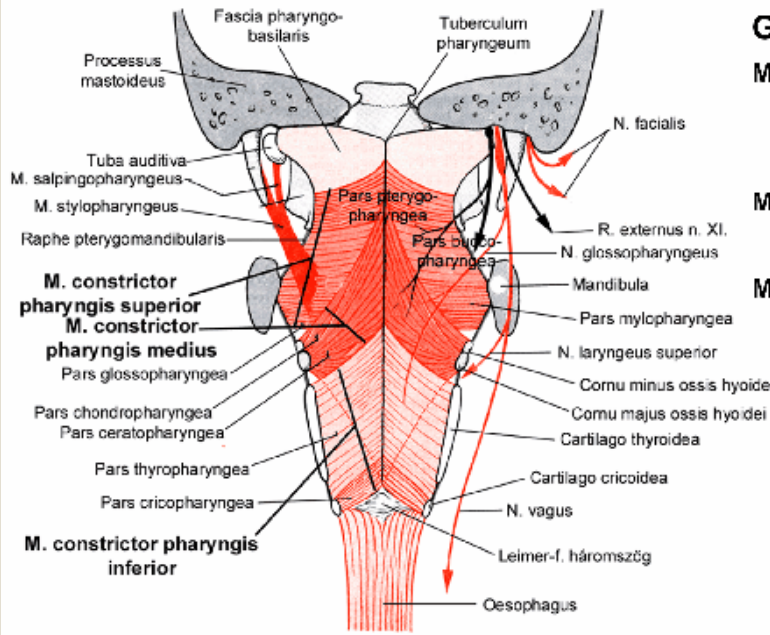
- 1) Tunica mucosa
- 2) Tunica fibrosa
- 3) **Tunica muscularis (h.cs.i)**
- 4) Tunica adventitia

Koponya alapi eredése:



# Tunica muscularis

Koponya alapi eredése:



## Garatfűző izmok:

### M. constrictor pharyngis superior:

1. pars pterygopalatina,
2. pars buccopharyngea,
3. pars mylopharyngea,
4. pars glossopharyngea;

### M. constrictor pharyngis medius:

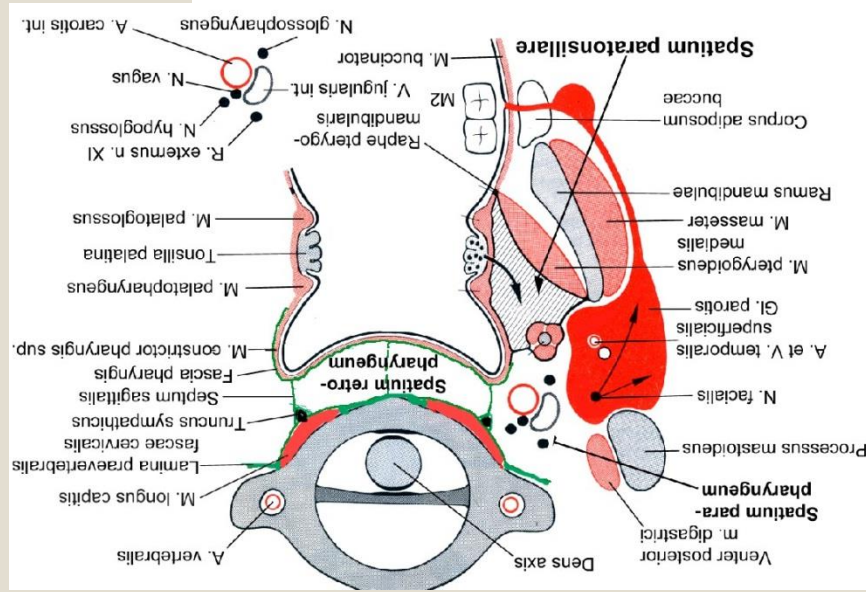
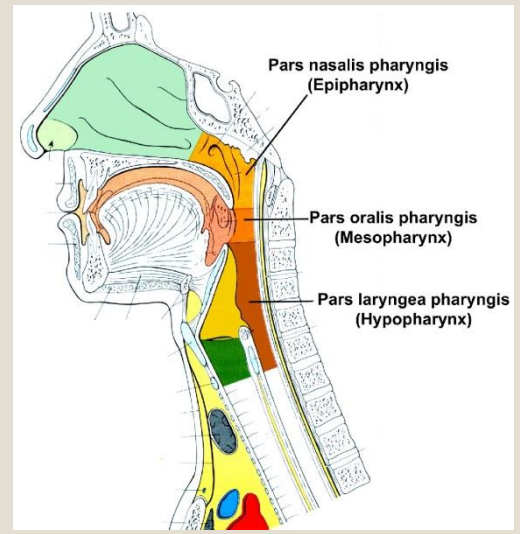
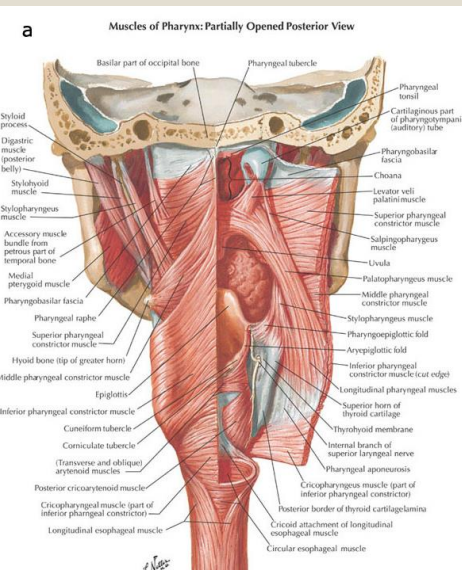
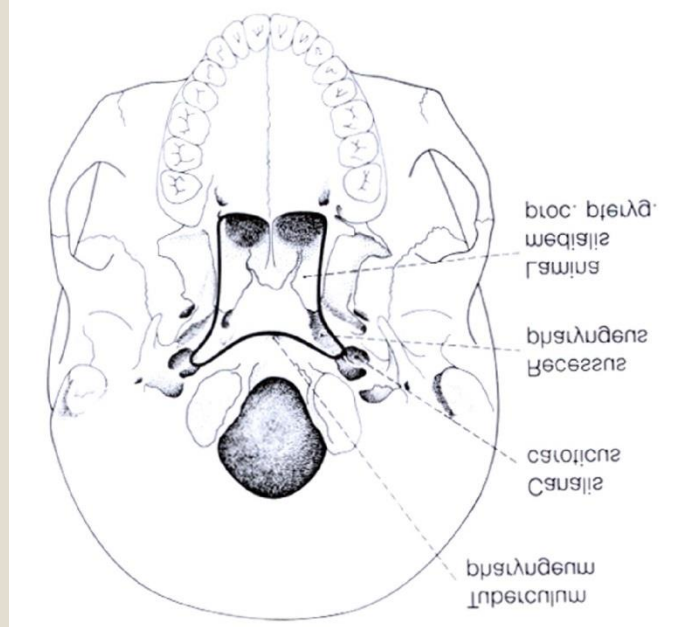
1. pars chondropharyngea,
2. pars ceratopharyngea;

### M. constrictor pharyngis inferior:

1. pars thyropharyngea,
2. pars cricopharyngea.

## Garatemelő izmok:

1. M. stylopharyngeus,
2. M. salpingopharyngeus,
3. M. palatopharyngeus



# A garat izmai

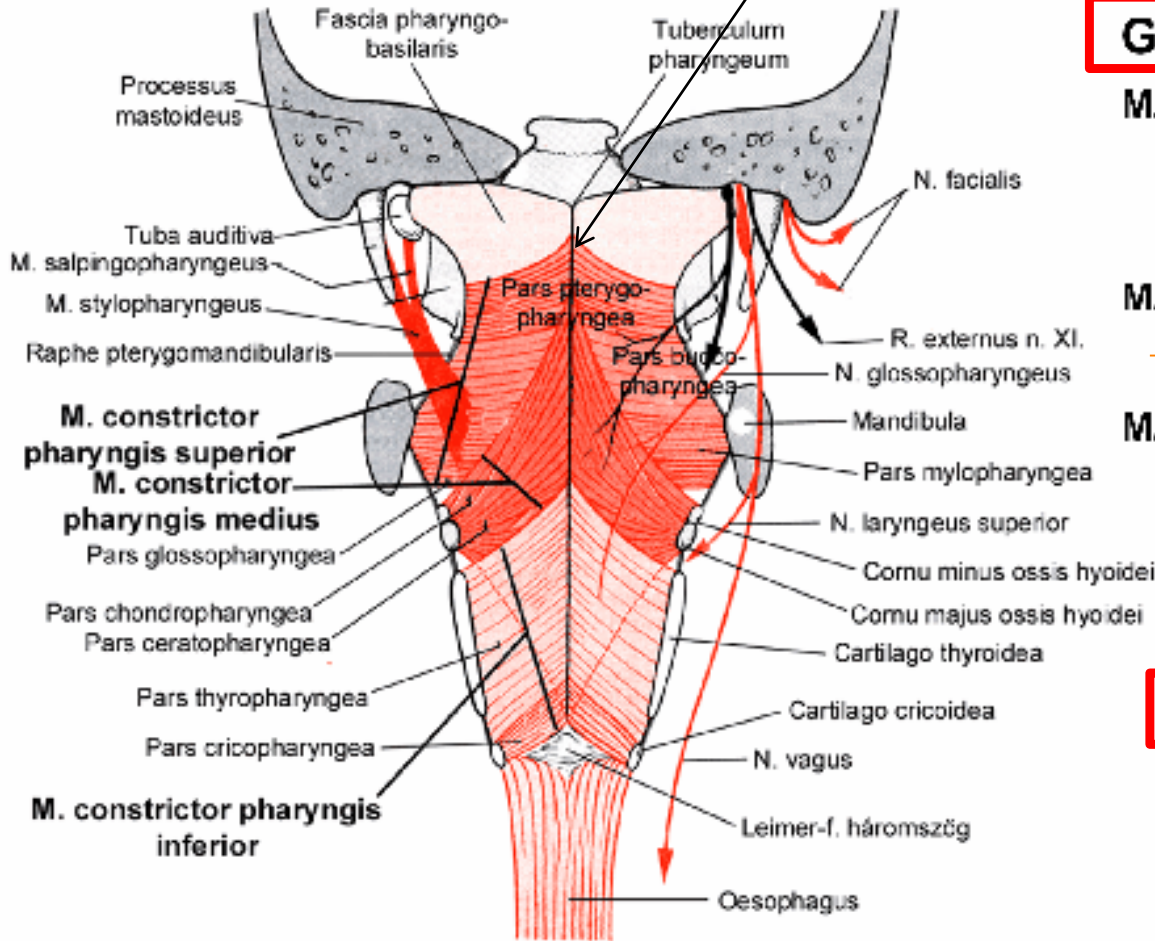
## Musculi constrictores pharyngis (3 csoport) - garatfűző

Nevük eredésükre utal!!!

Raphe pharyngis

## Musculi levatores pharyngis – Garatemelő

Nevük eredésükre utal!!!



### Garatfűző izmok:

#### M. constrictor pharyngis superior:

1. pars pterygopalatina,
2. pars buccopharyngea,
3. pars mylopharyngea,
4. pars glossopharyngea;

n. IX

#### M. constrictor pharyngis medius:

1. pars chondropharyngea,
2. pars ceratopharyngea;

#### M. constrictor pharyngis inferior:

1. pars thyropharyngea,
2. pars cricopharyngea.

n. X

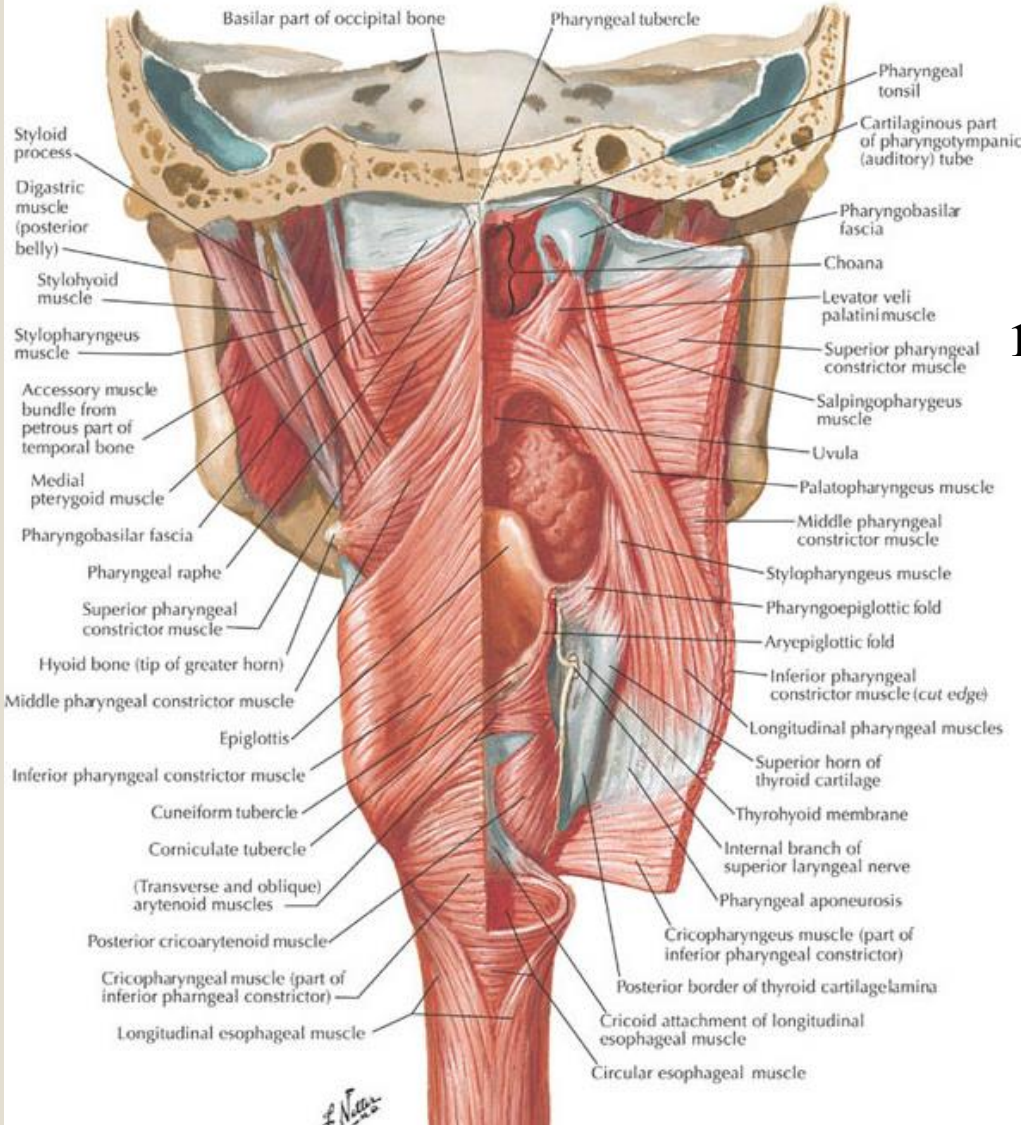
### Garatemelő izmok:

1. M. stylopharyngeus,
2. M. salpingopharyngeus,
3. M. palatopharyngeus

# Musculi levatores pharyngis

a

Muscles of Pharynx: Partially Opened Posterior View



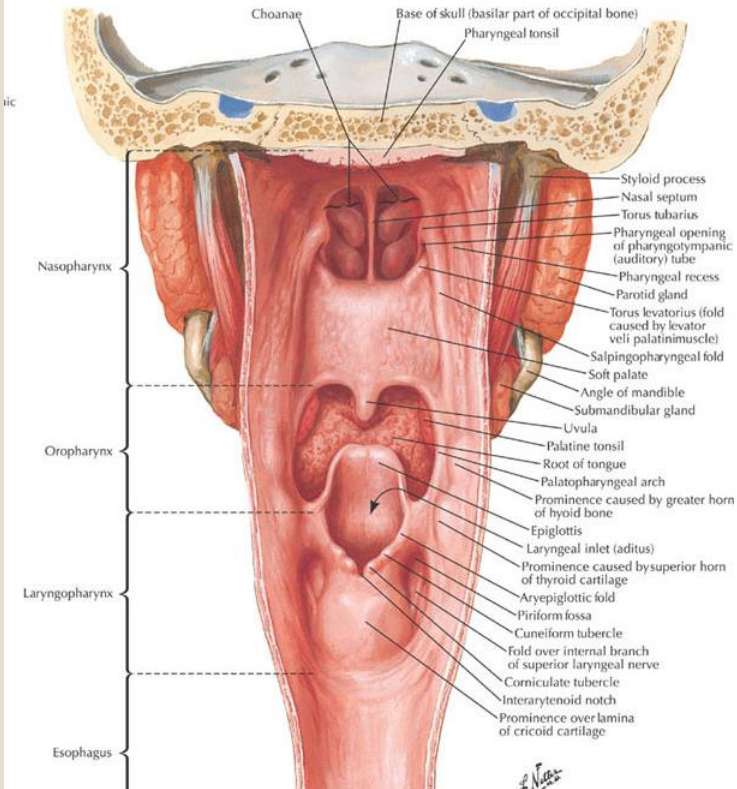
*M. stylopharyngeus* – proc.

styloideus (os temporale)


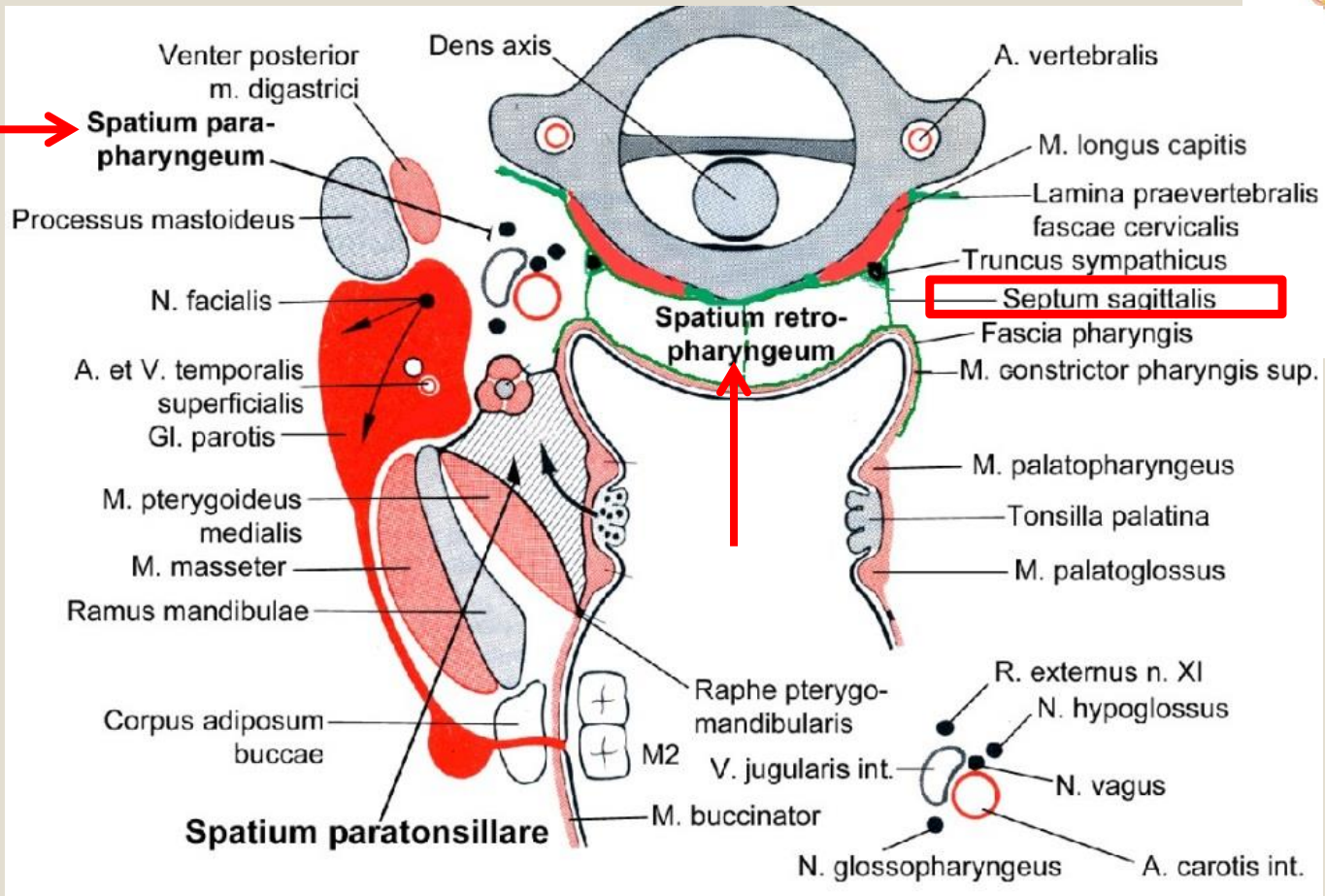
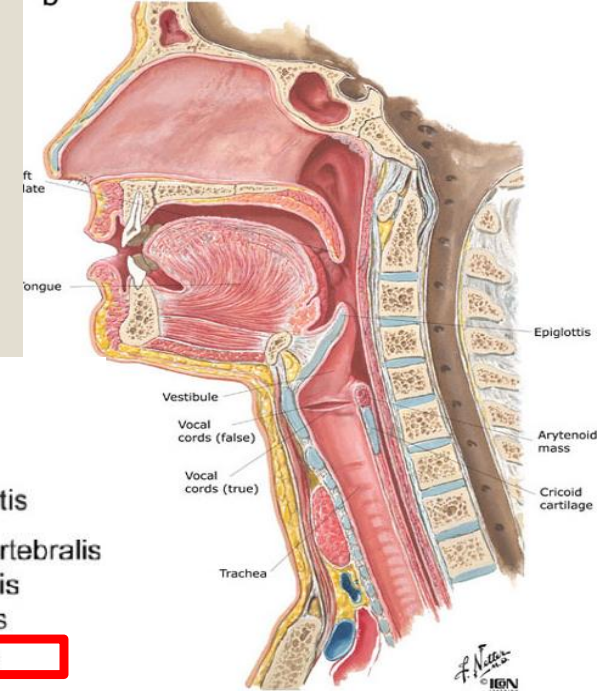
*M. salpingopharyngeus* – fülkürt  
porca, proc. pterygoideus lamina  
medialis

*M. palatopharyngeus* – velum  
palatinum állománya

1 külső + 2 belső (redő = plica)



# → Garat körüli térségek





# A fej-nyak régió artériái

- a. vertebralis

- ACI – intracranialis oszlás

- ACE:

**Au** – a. auricularis post

**Oc** – a. occipitalis

**StyM** – a. stylomastoidea

**Te** – a. temporalis superfic.

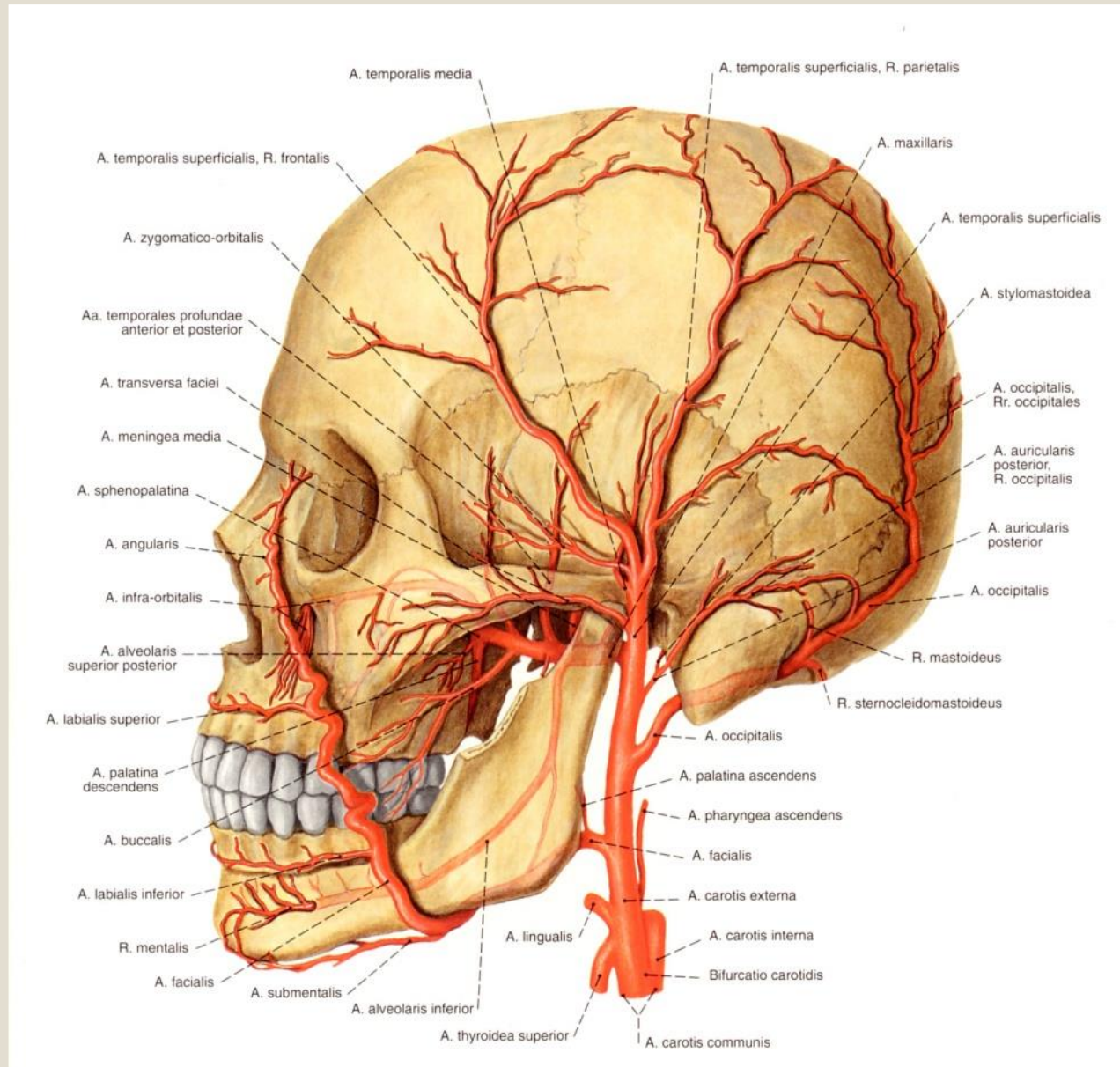
**Ma** – a. maxillaris

**Fa** – a. facialis a.

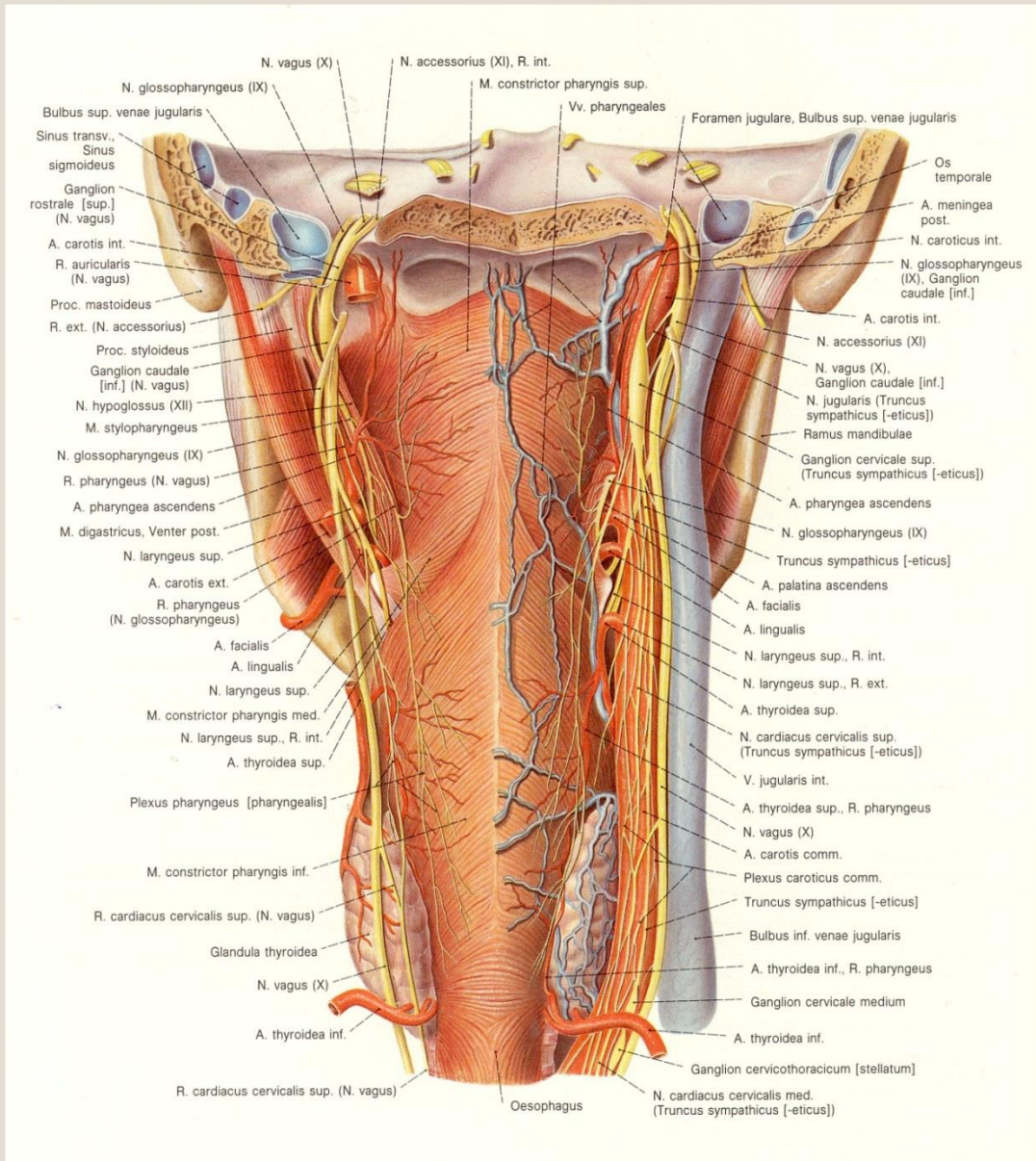
**Pha** – a. pharyngea asc.

**Ly** – a. lingualis

**Thy** – a. thyroid sup.



# A garat vérellátása és beidegzése



**aa. pharyngea asc.**  
**Rami pharyngeales:**  
**aa. thyroidea sup.**  
**aa. thyroidea inf.**

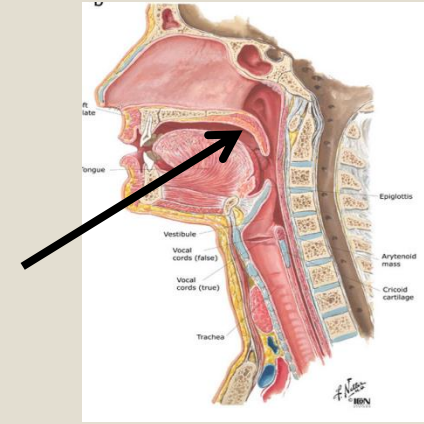
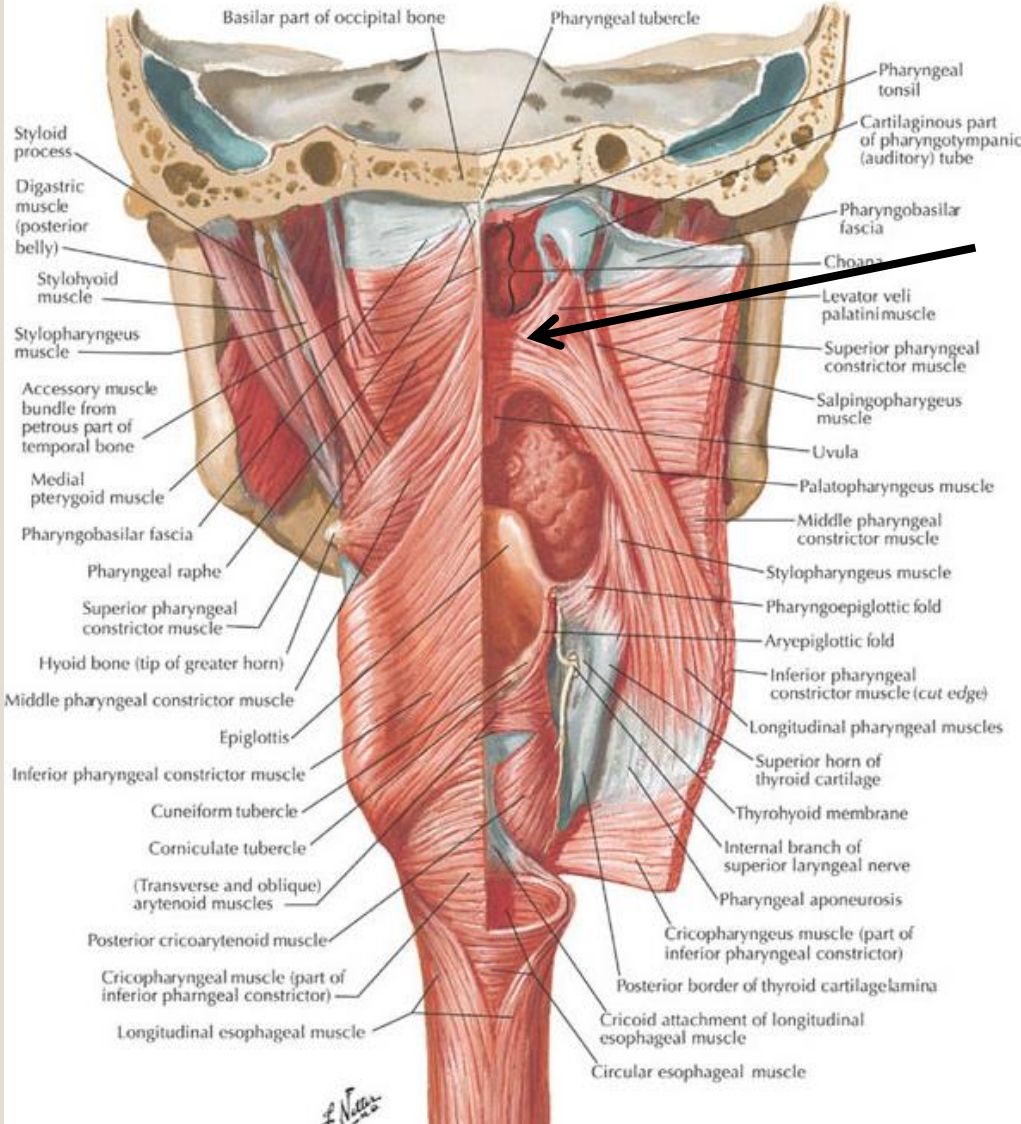
**vv. pharyngeales**

**Plexus pharyngeus:**  
**Nervus glossopharyngeus (N. IX)**  
**Nervus vagus (N. X)**

# Lágy szájpad – velum palatinum

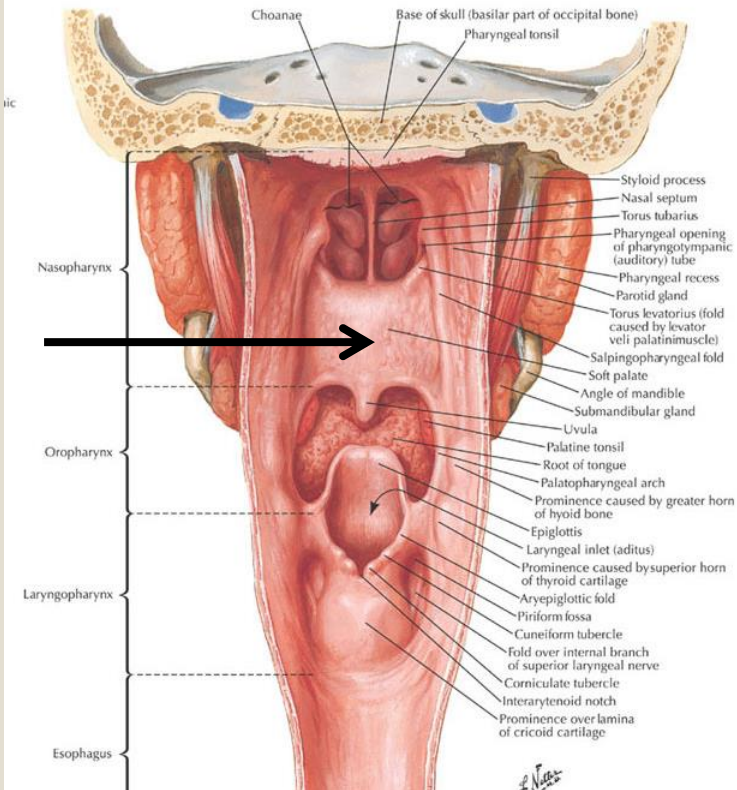
a

Muscles of Pharynx: Partially Opened Posterior View

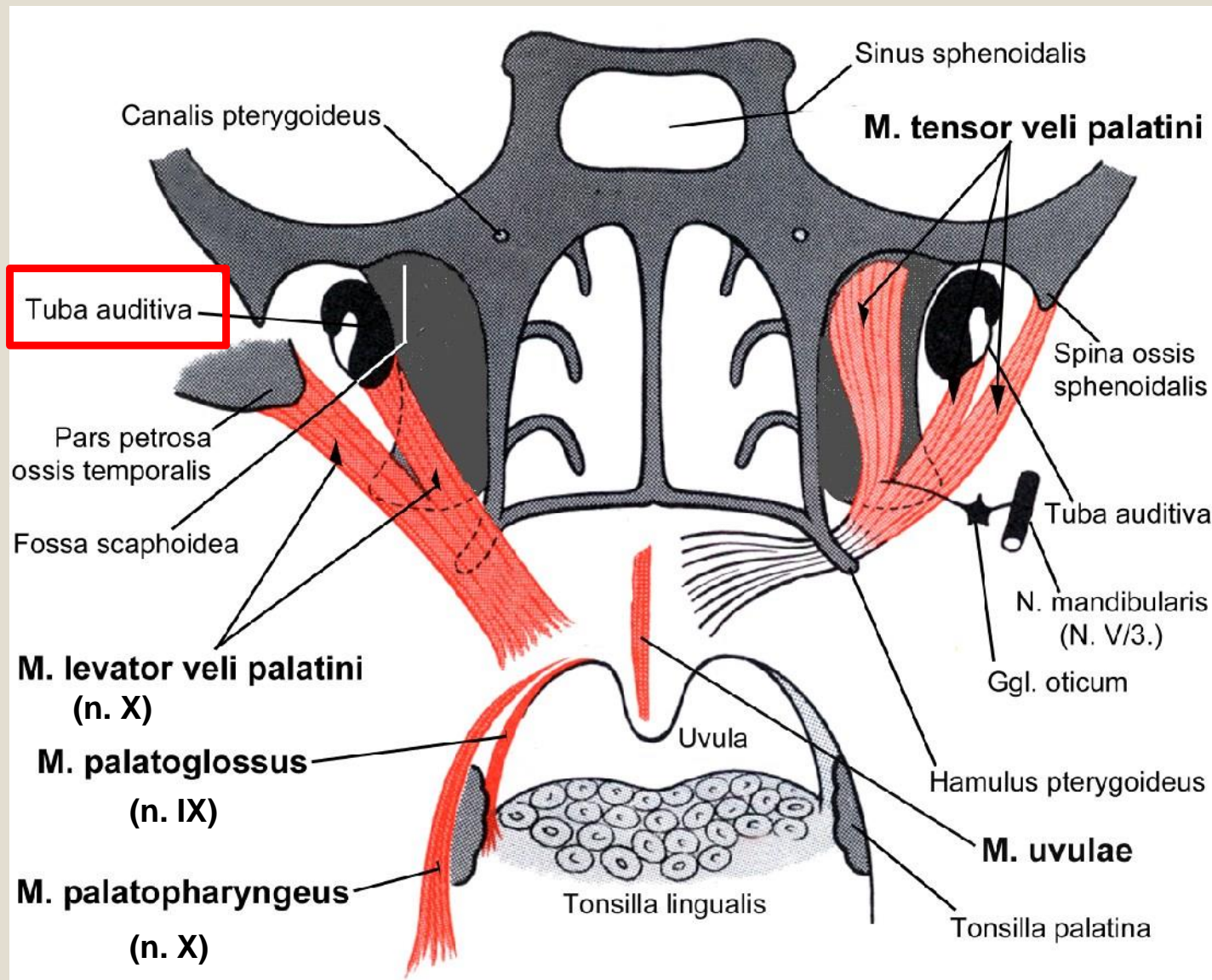


b

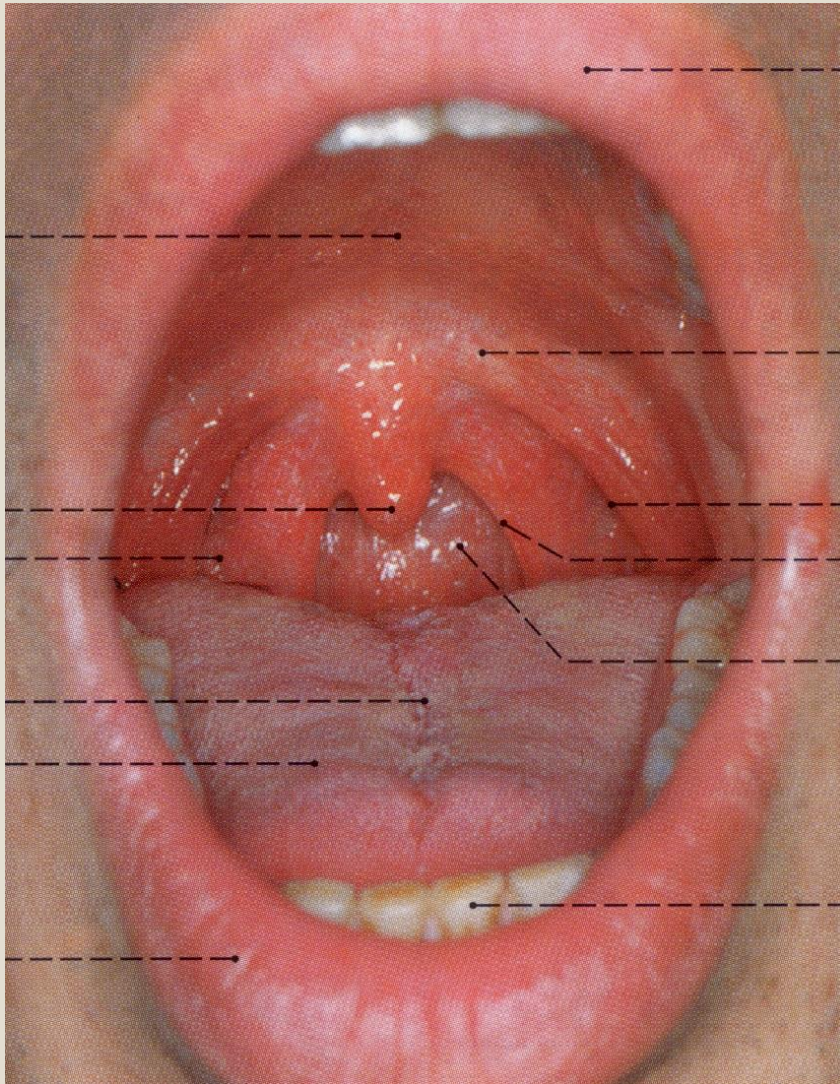
Pharynx: Opened Posterior View



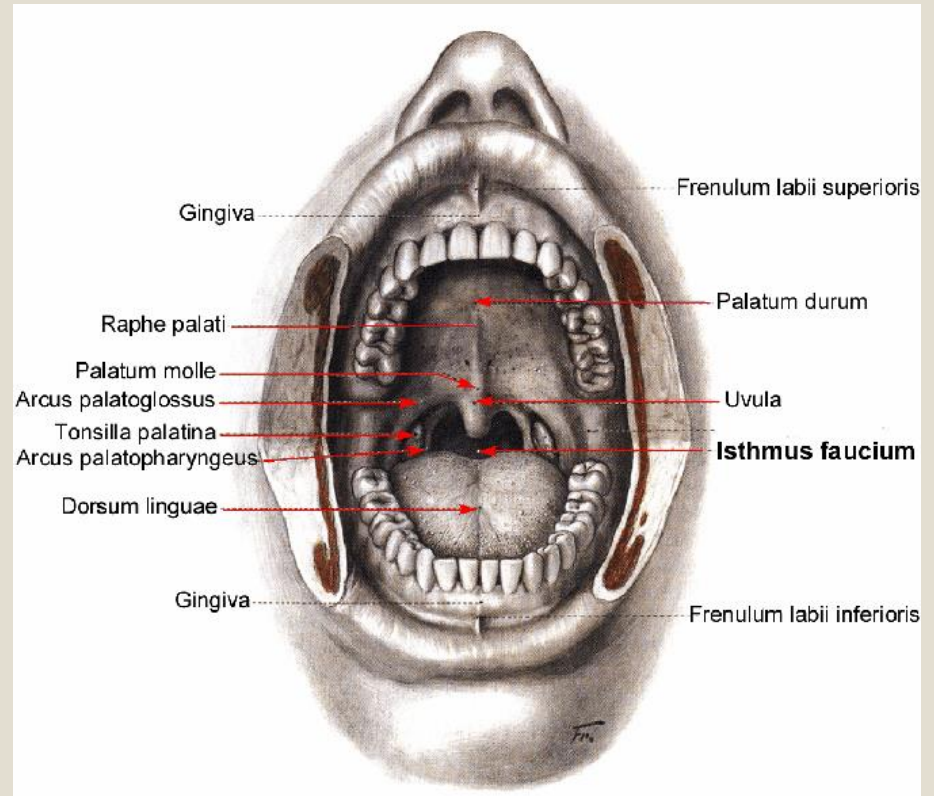
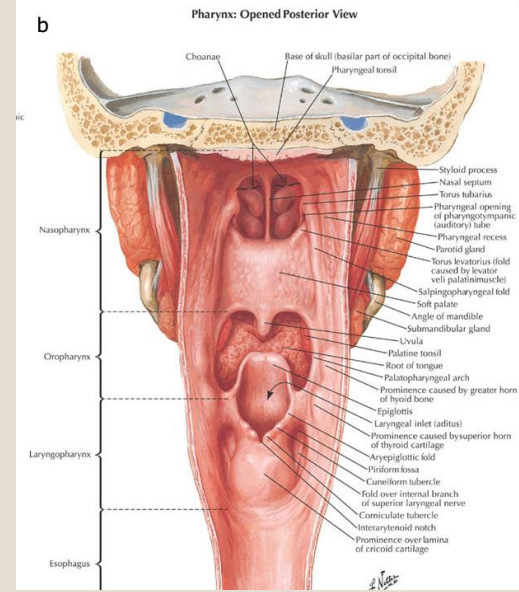
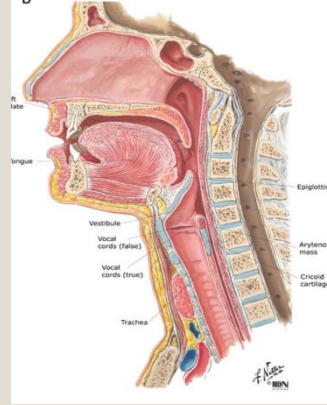
# Lágy szájpad – izmai (5)



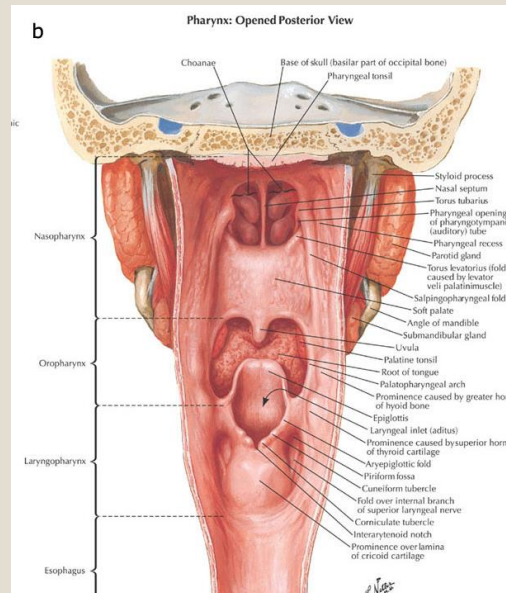
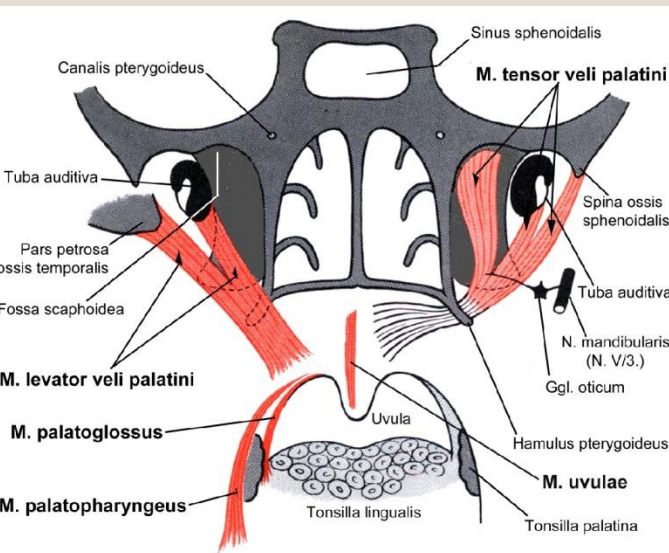
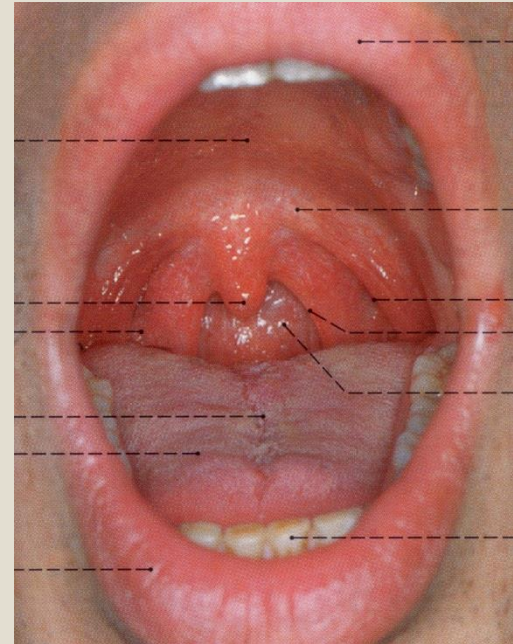
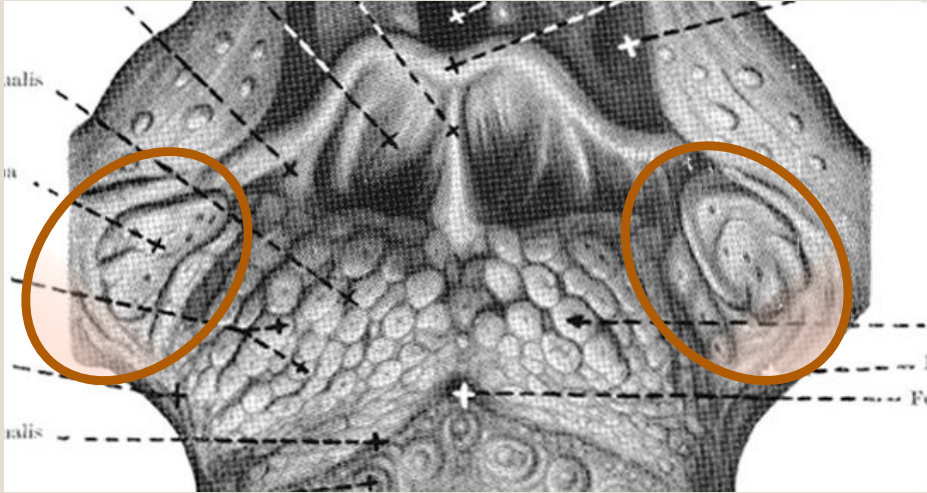
# Toroksoros –isthmus faucium



Arcus palatoglossus et palatopharyngeus



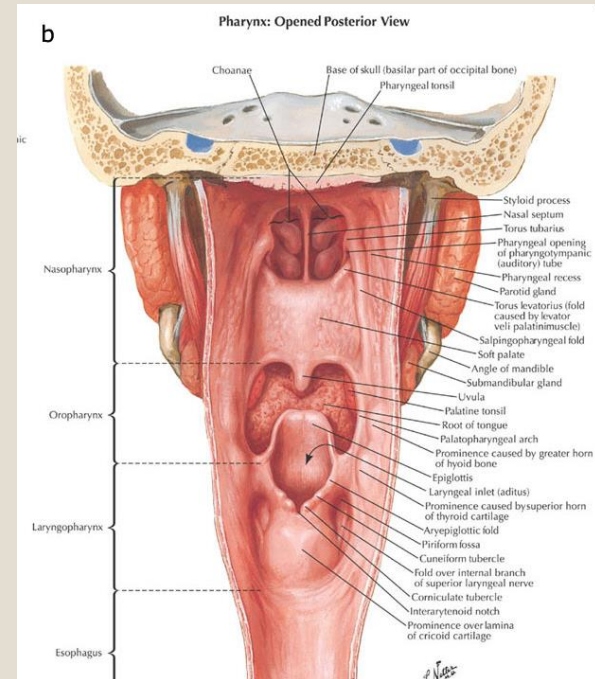
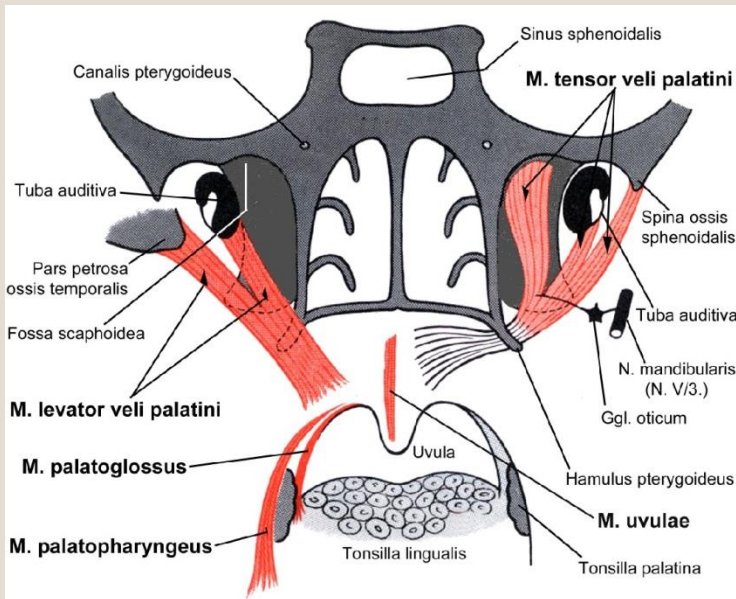
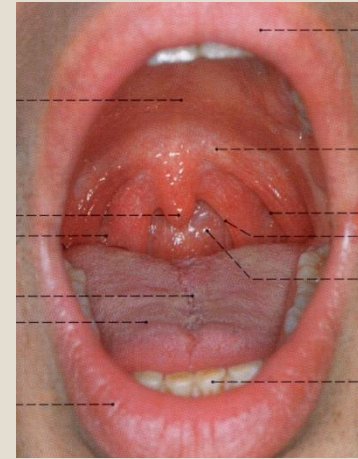
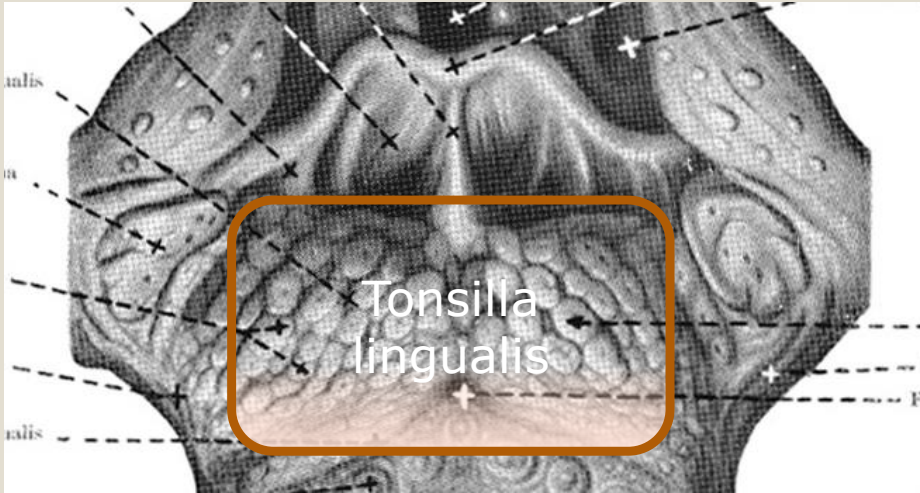# A toroksoros – oldalsó határának képletei



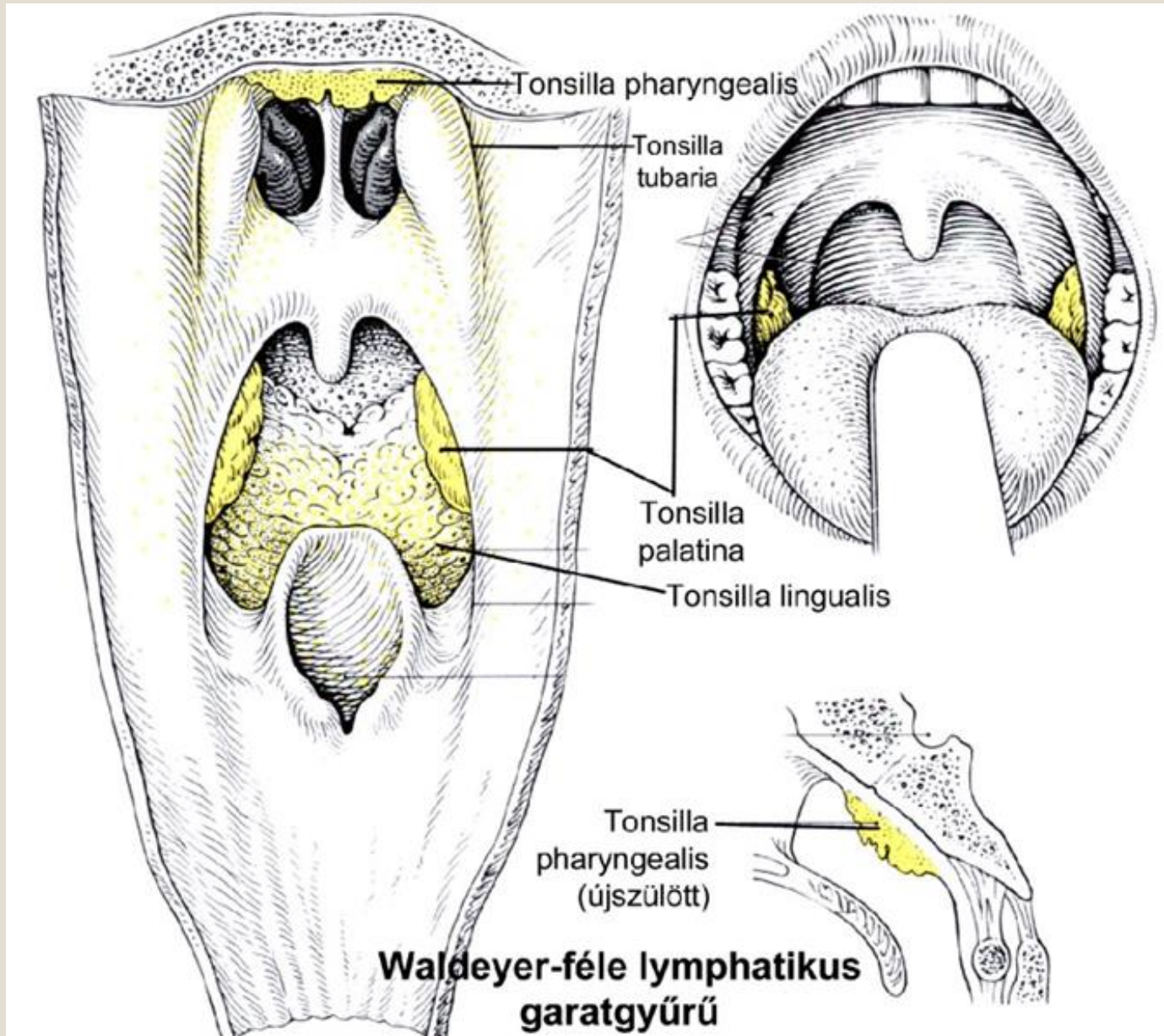
**Fossa tonsillaris –  
benne a  
tonsilla palatina**

**Vérellátás: A. CAROTIS EXTERNA**  
**a. palatina ascendens (a. facialis)**  
**a. palatina descendens (a. maxillaris)**  
**a. lingualis – ramus tonsillaris**  
**a. pharyngea ascendens – ramus tonsillaris**

# Torokszoros – alsó határa

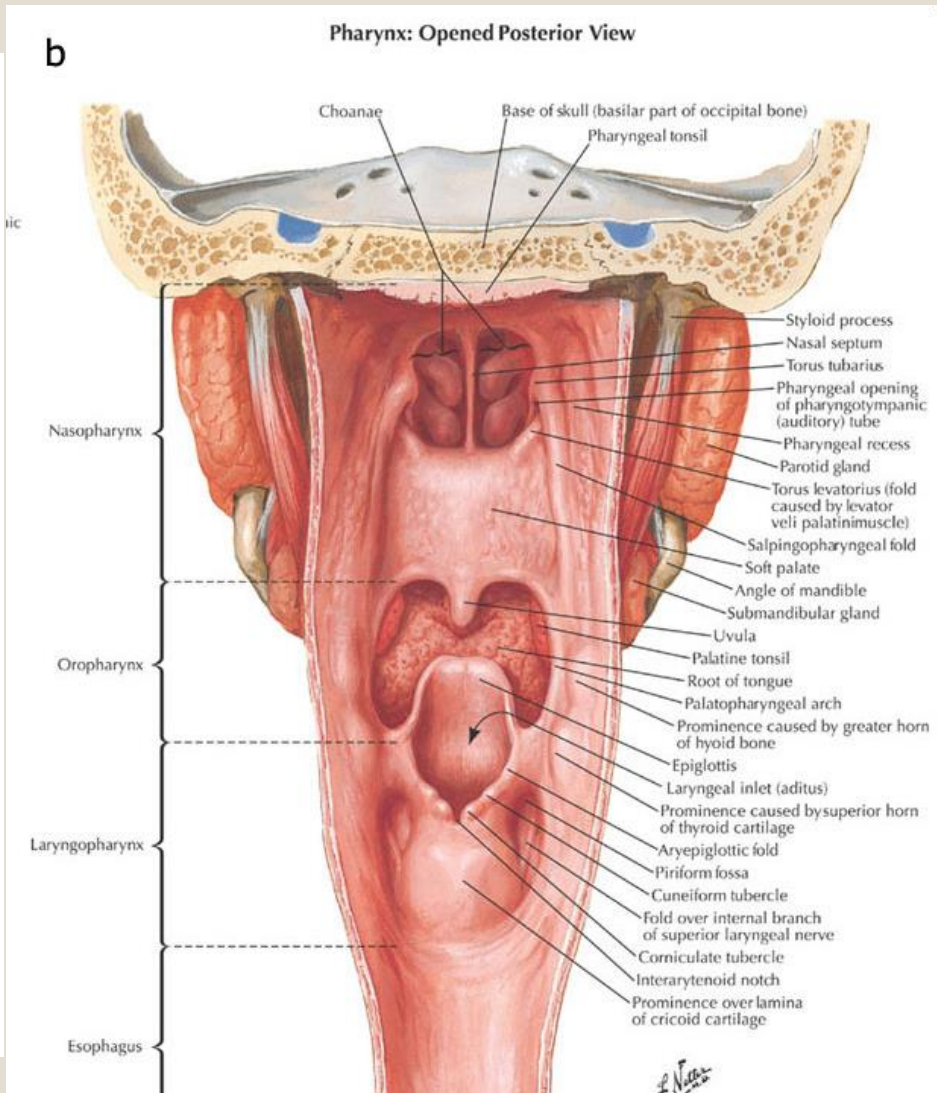
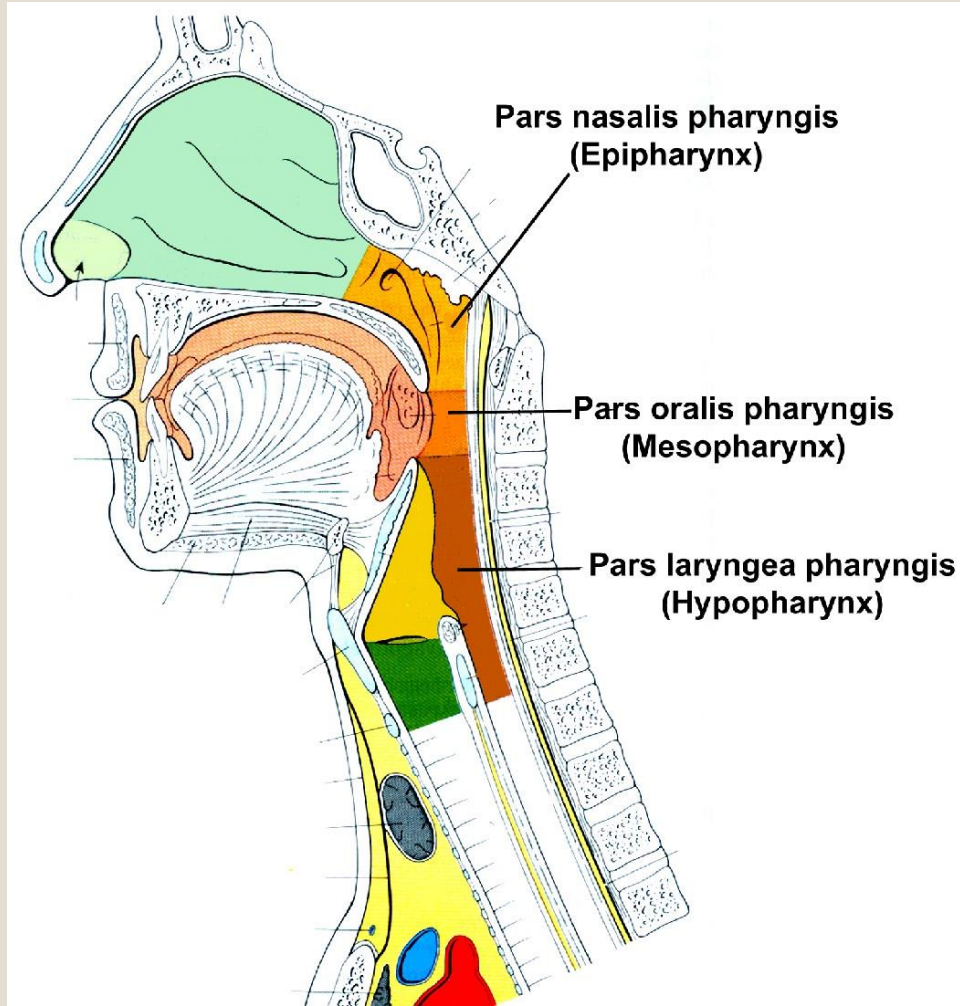


# A garat ürege – Waldeyer-féle lymphaticus garatgyűrű

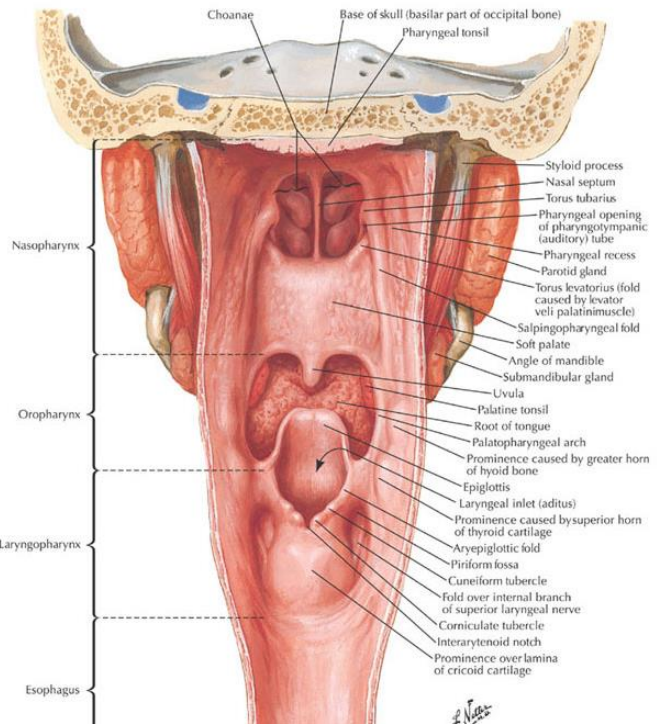




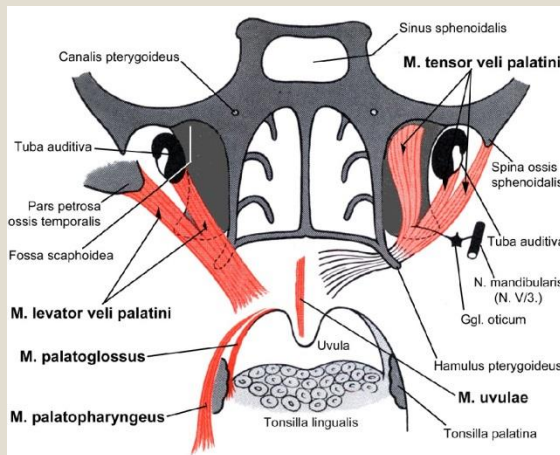
# A garat ürege



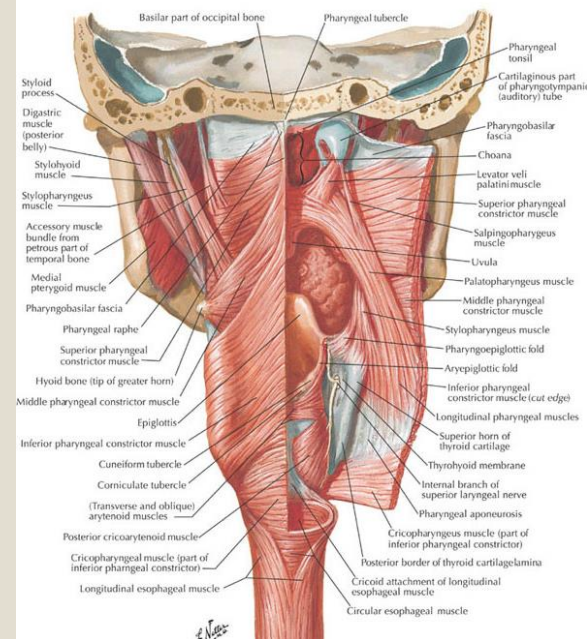
**b** Pharynx: Opened Posterior View



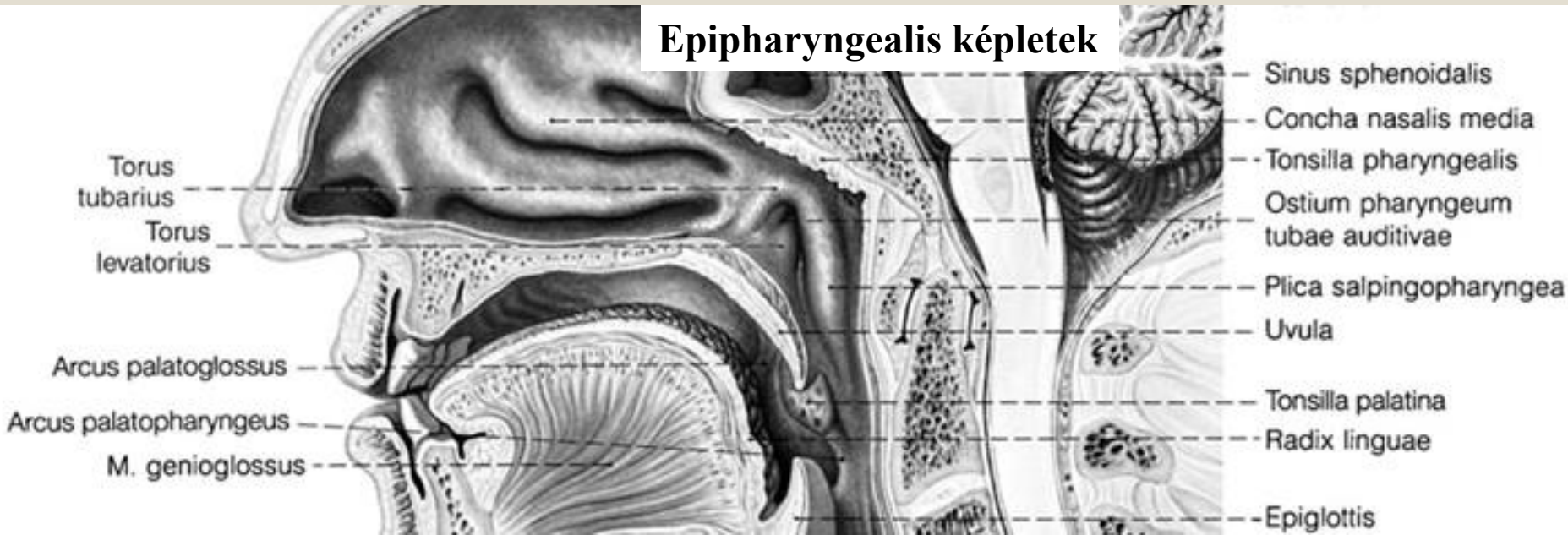
# A garat ürege



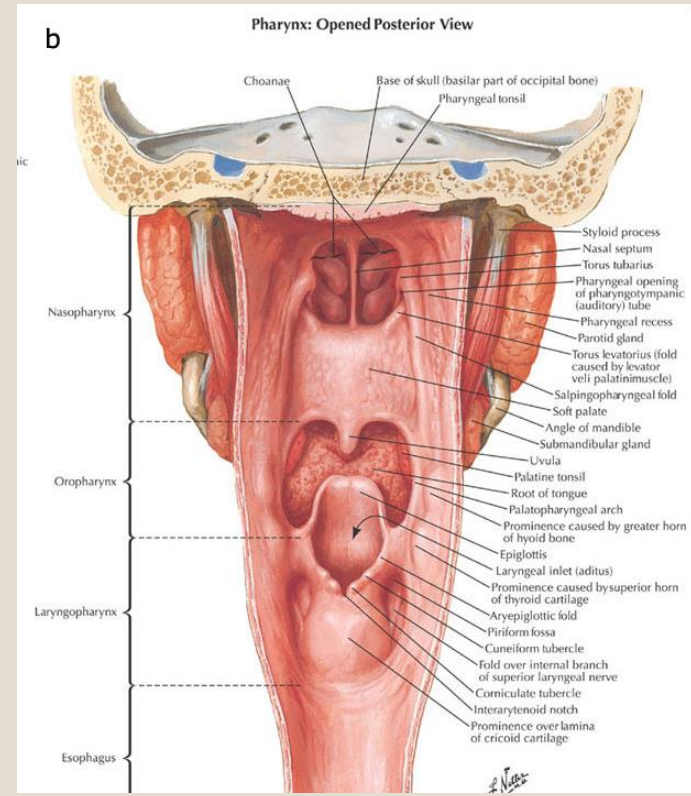
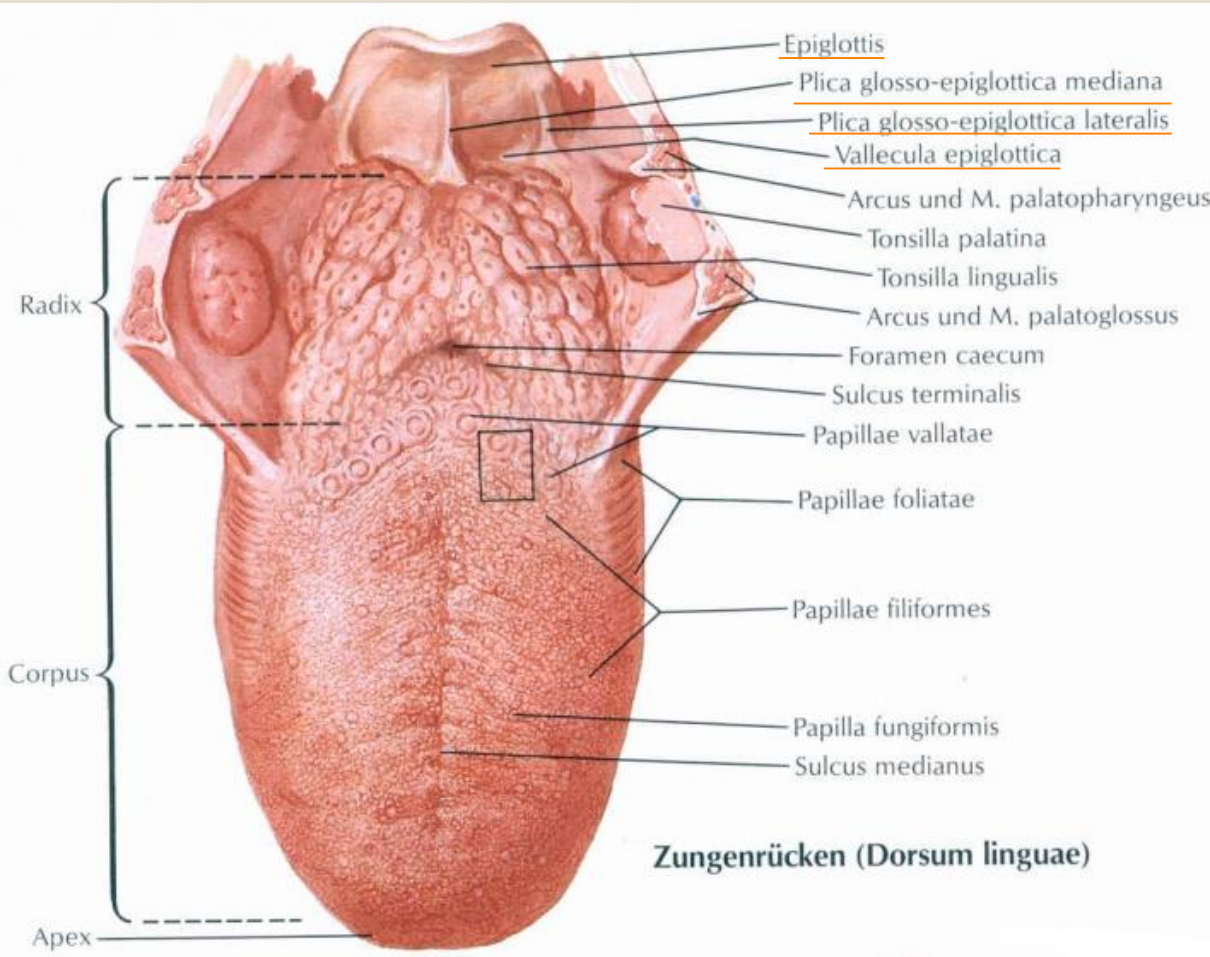
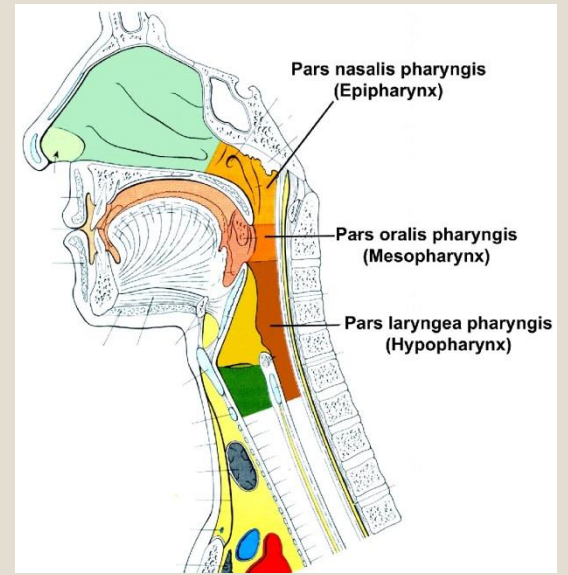
**a** Muscles of Pharynx: Partially Opened Posterior View



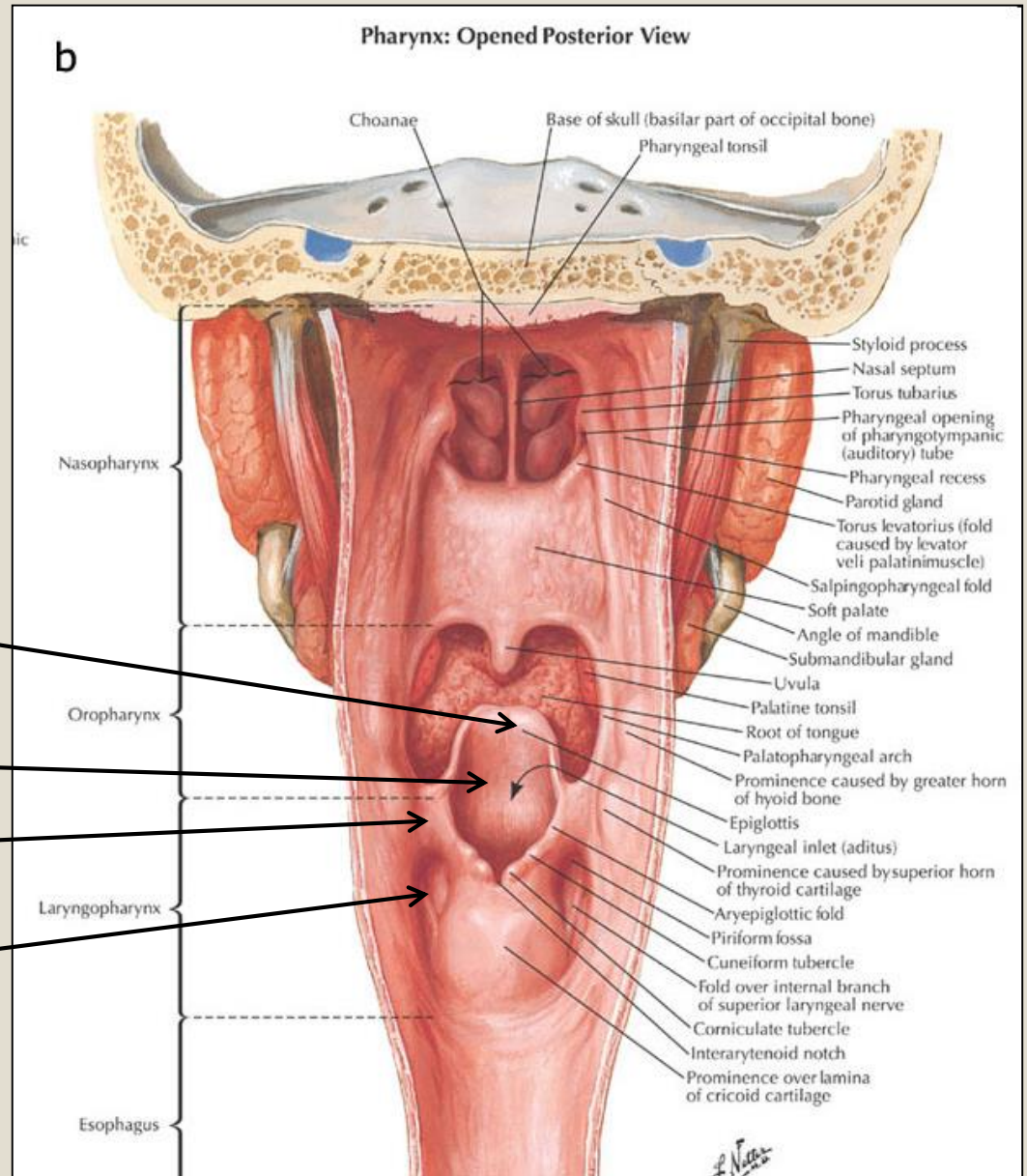
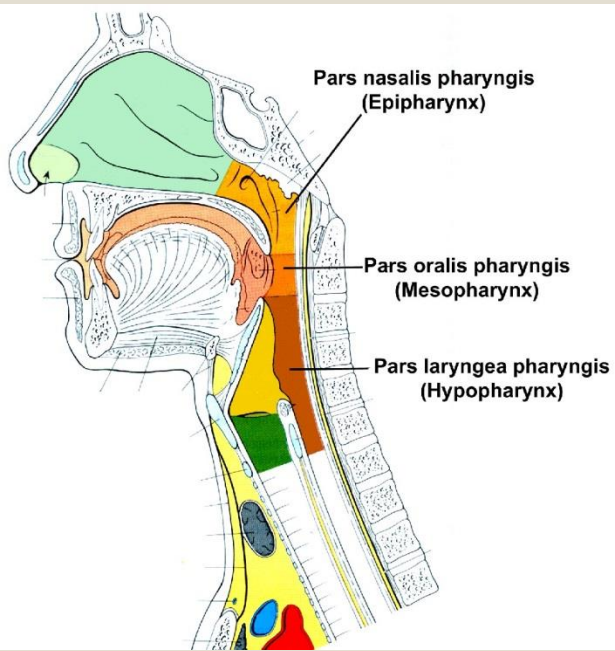
## Epipharyngealis képletek



# Garat ürege - oropharynx



# Garat ürege - hypopharynx



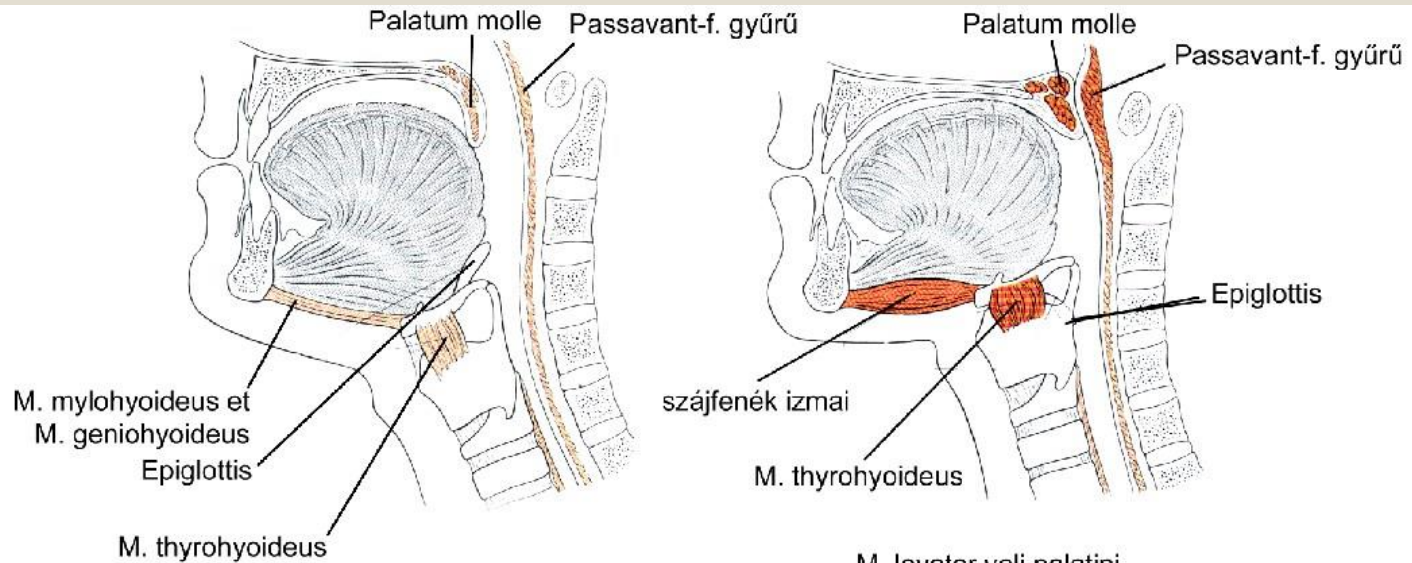
**Epiglottis**

**Aditus laryngis**

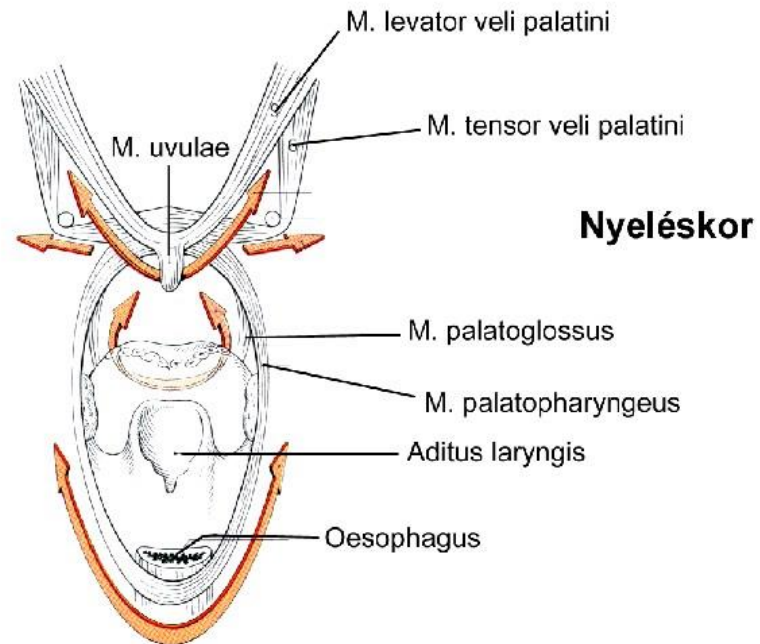
**Plica aryepiglottica**

**Recessus piriformis**

# A nyelés folyamata



## Légzéskor



## Nyeléskor

**Köszönöm megtisztelő figyelmüket!**

