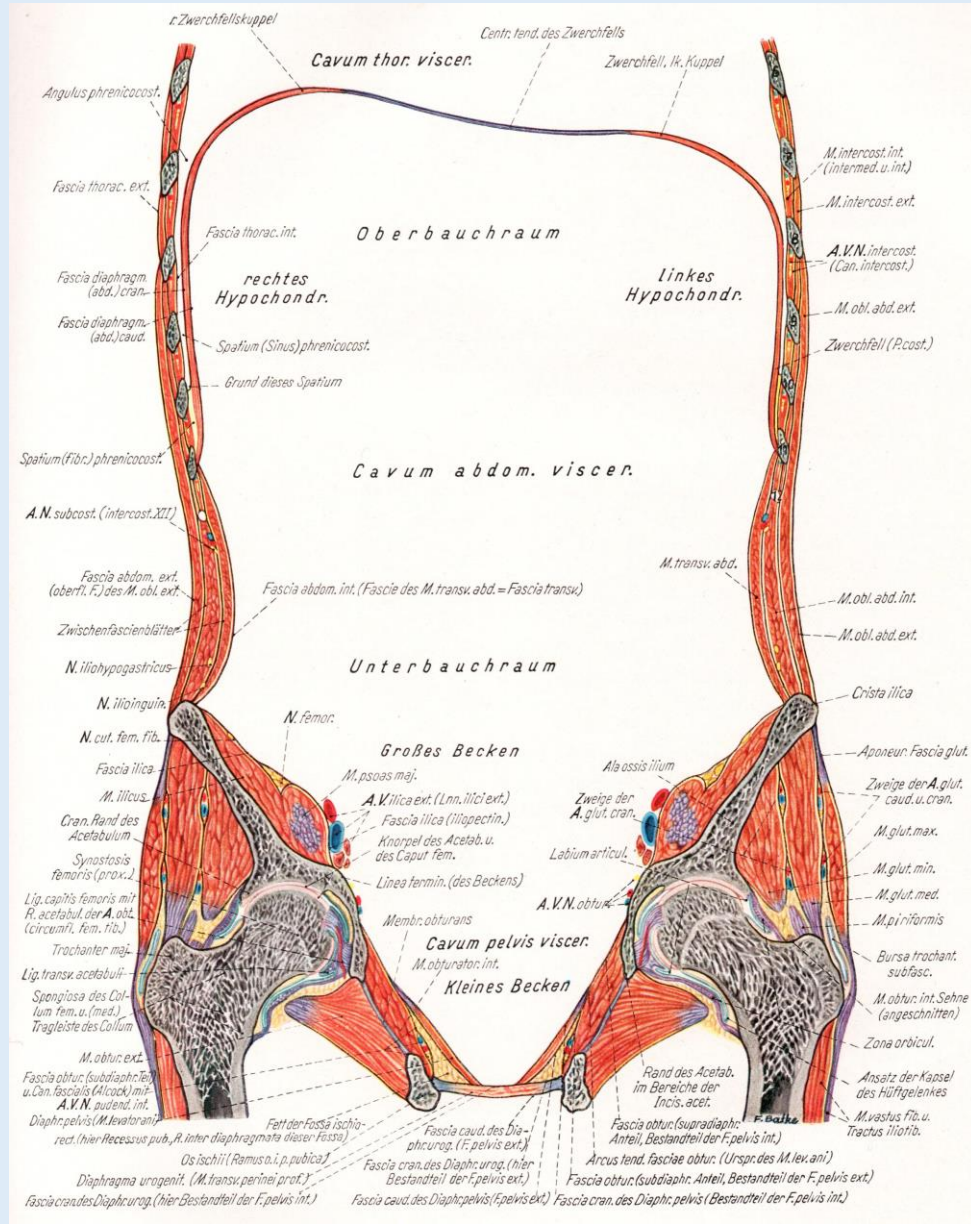
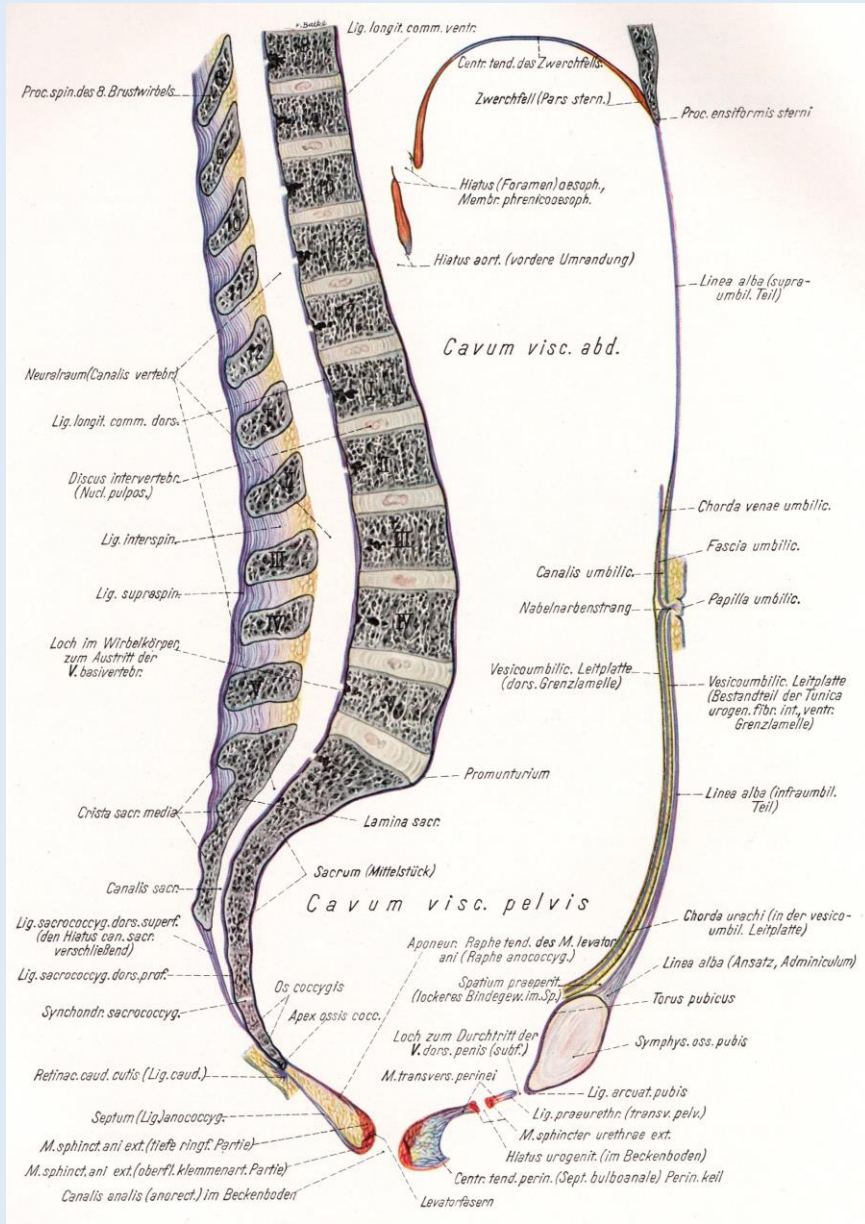


# **A férfi medence és gát topográfiája, valamint metszetanatómiája**

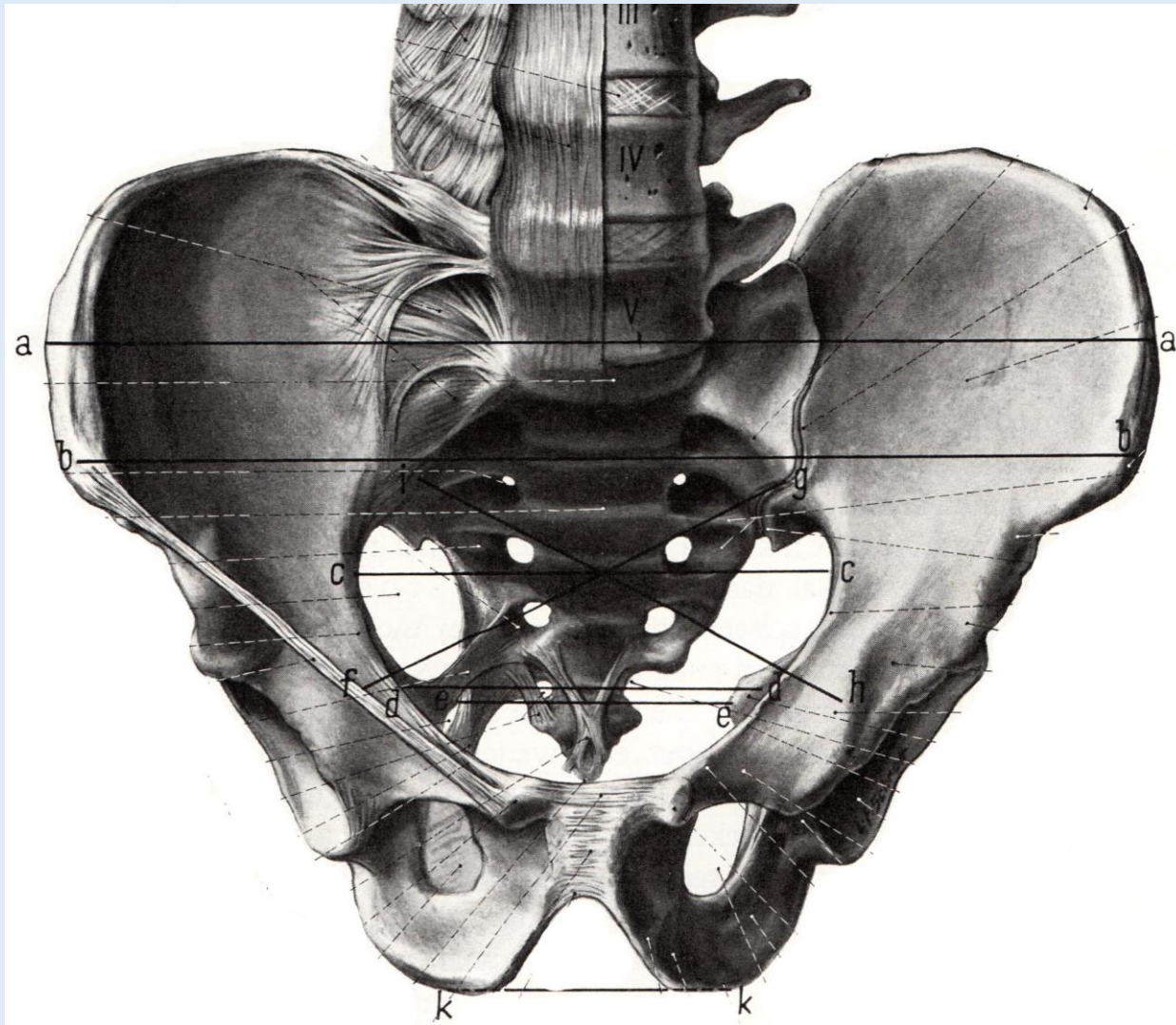
Dr. Ruttkay Tamás

Anatómiai, Szövet- és Fejlődéstani Intézet  
2018.

# Hasüreg és medence



# A medence nyílásai, lágyrészek átlépési helyei



Apertura pelvis superior  
(Linea terminalis)

Angulus subpubicus

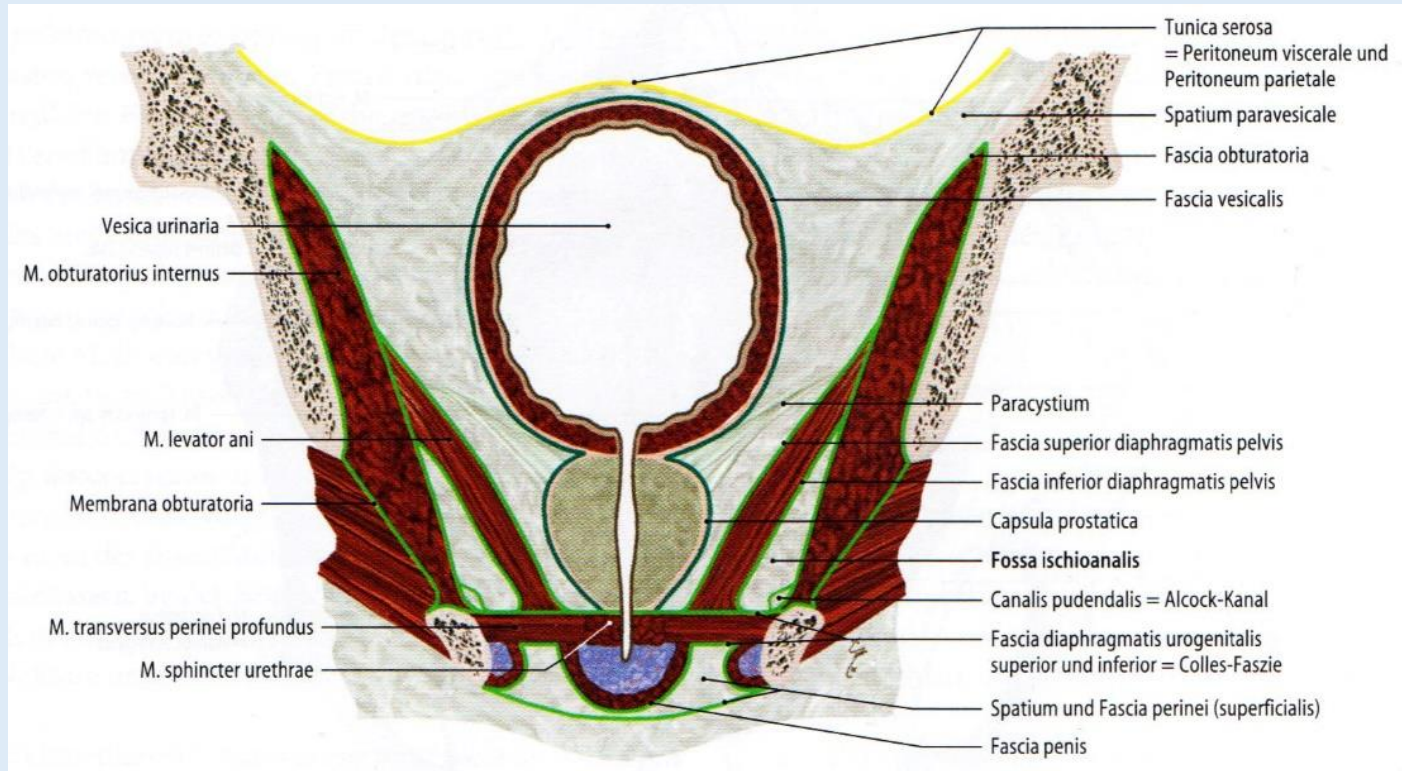
Foramen obturatum/  
Canalis obturatorius

Foramen ischiadicum majus  
Hiatus suprapiriformis  
Hiatus infrapiriformis

Foramen ischiadicum minus

# Medencefenék

Zilles-Tillmann



**Peritoneum**



**Kötszövetes térség**



**Diaphragma pelvis:**

Fascia diaphragmatis pelvis superior;  
Musculus levator ani;  
Fascis diaphragmatis pelvis inferior




**Hiatus genitalis und analis**



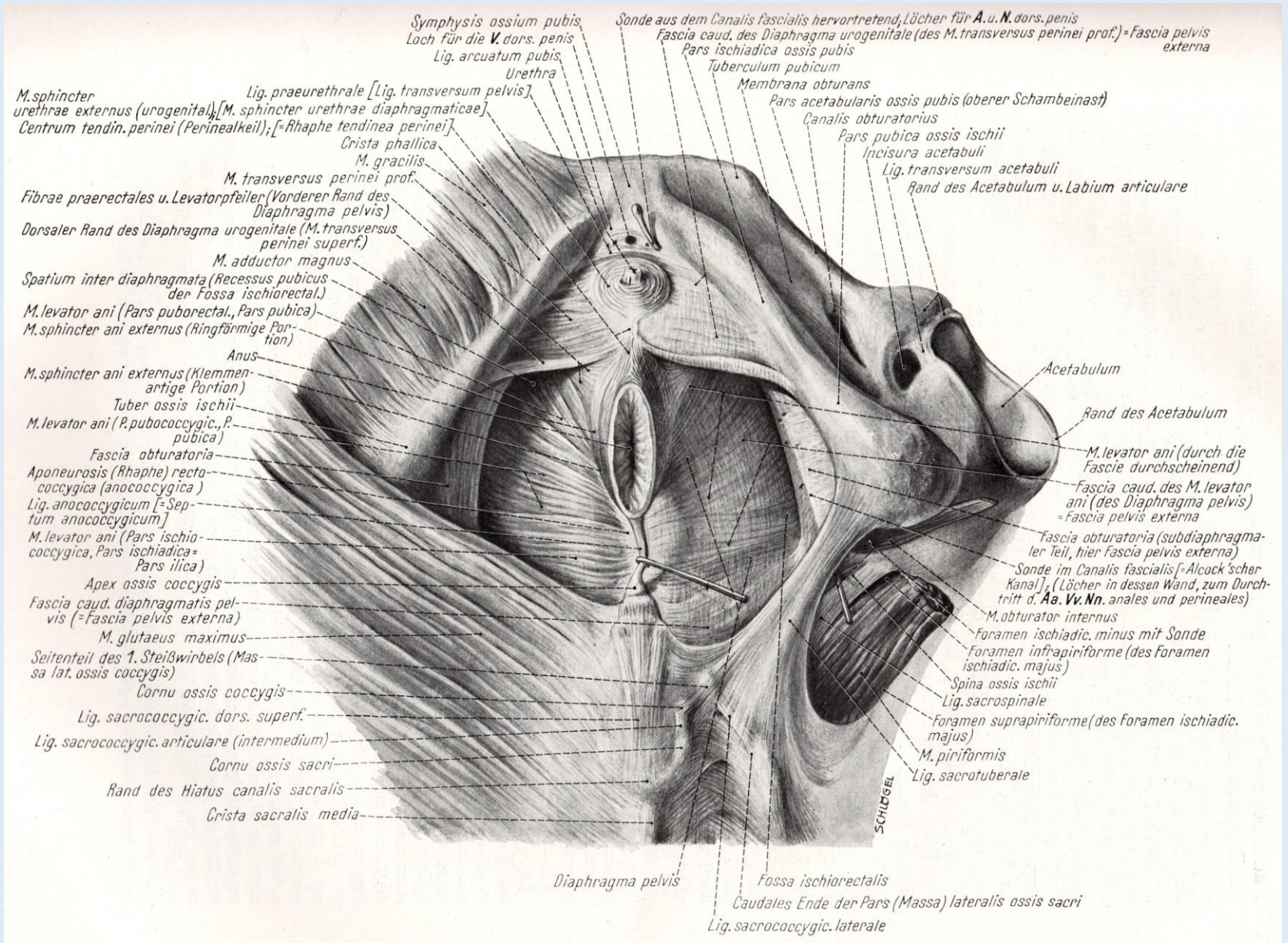
**Diaphragma urogenitale:**

Fascia diaphragmatis urogenitalis inferior;  
M. transversus perinei prof. és M. sphincter urethrae;  
Fascia diaphragmatis urogenitalis inferior



**Fossa ischiorectalis**

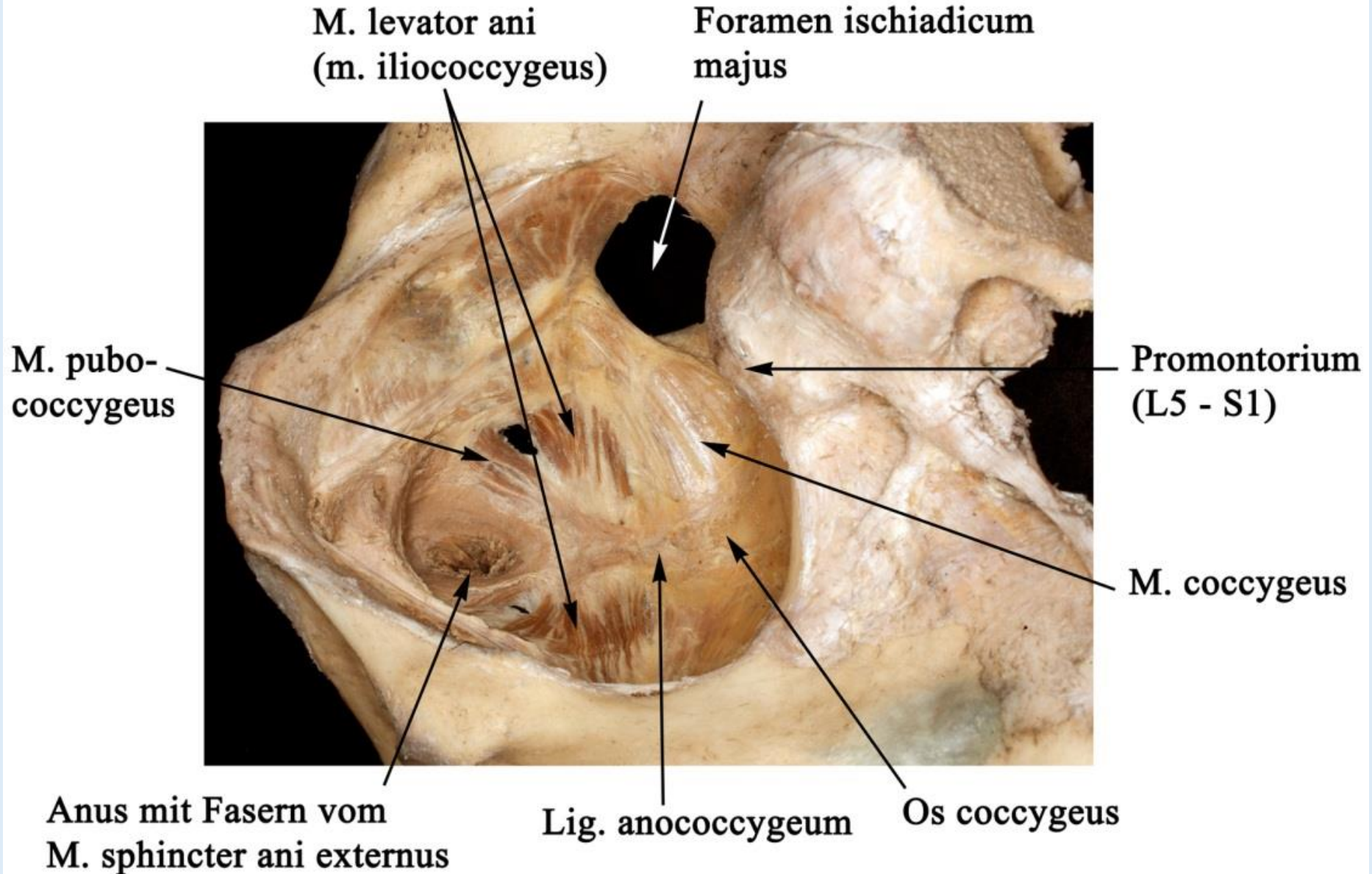
# Medencefenék



Diaphragma pelvis – Diaphragma urogenitale

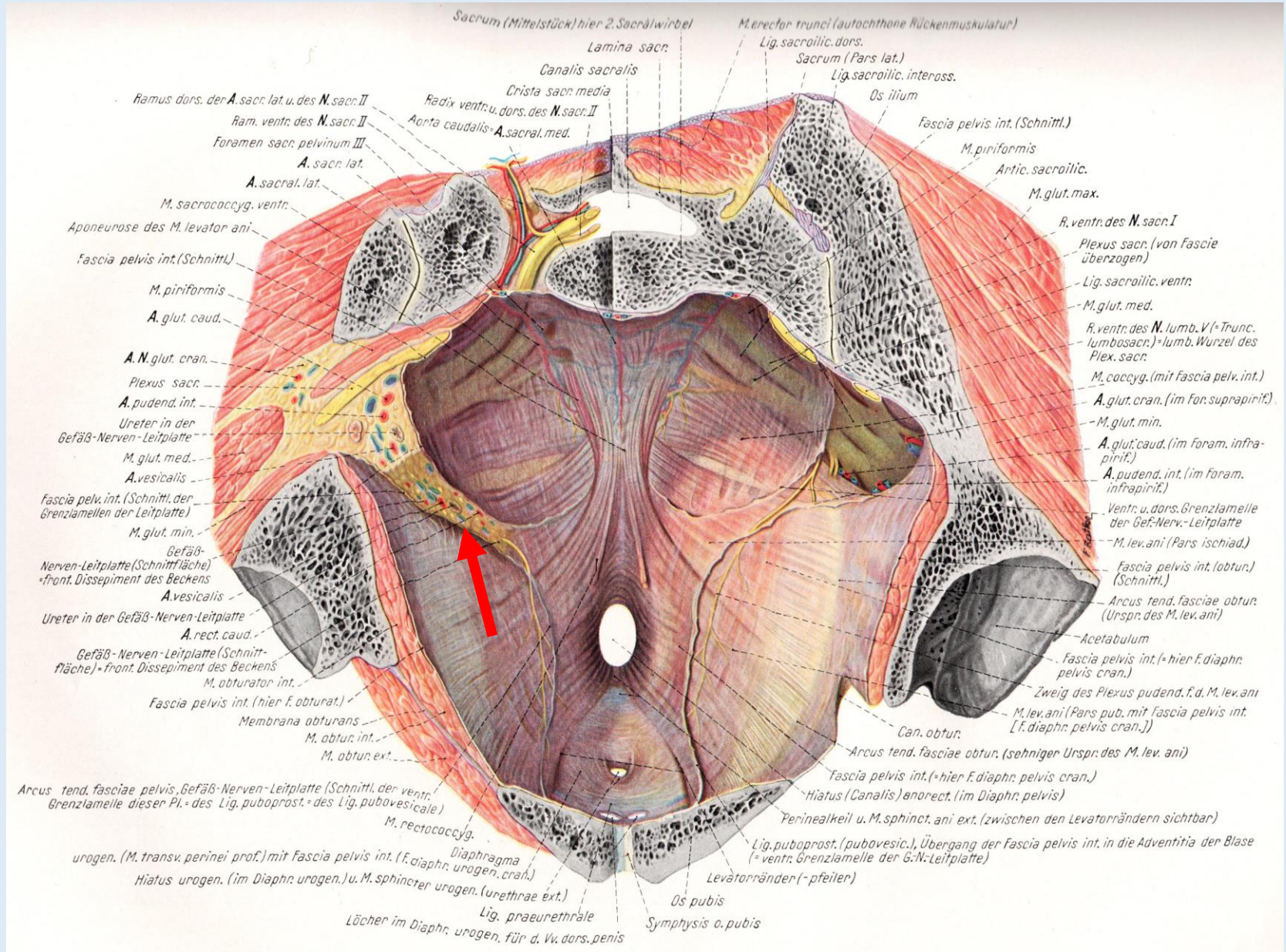
# „Levator – tölcsér”

Anatómiai Múzeum



# Medencefenék

Pernkopf

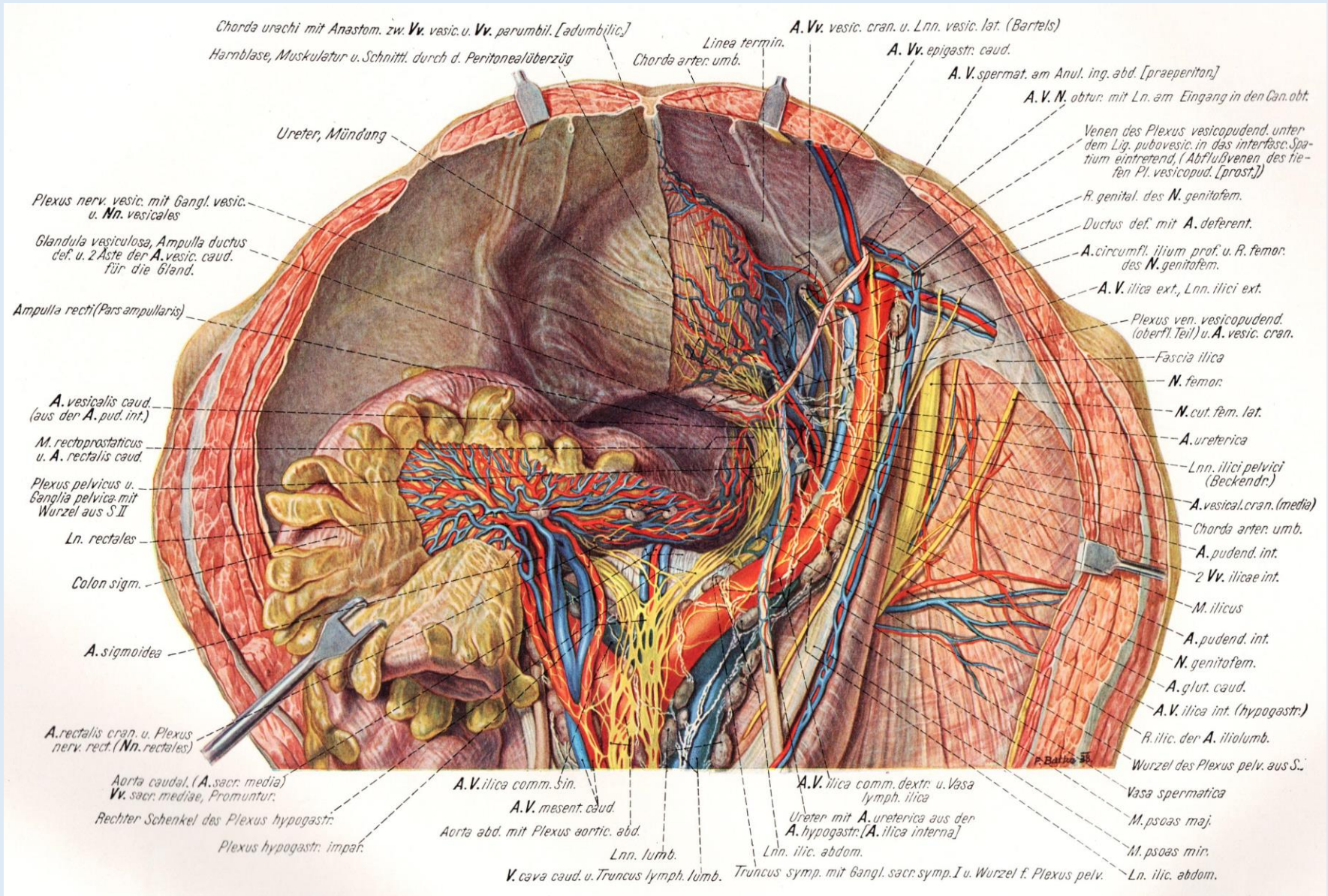




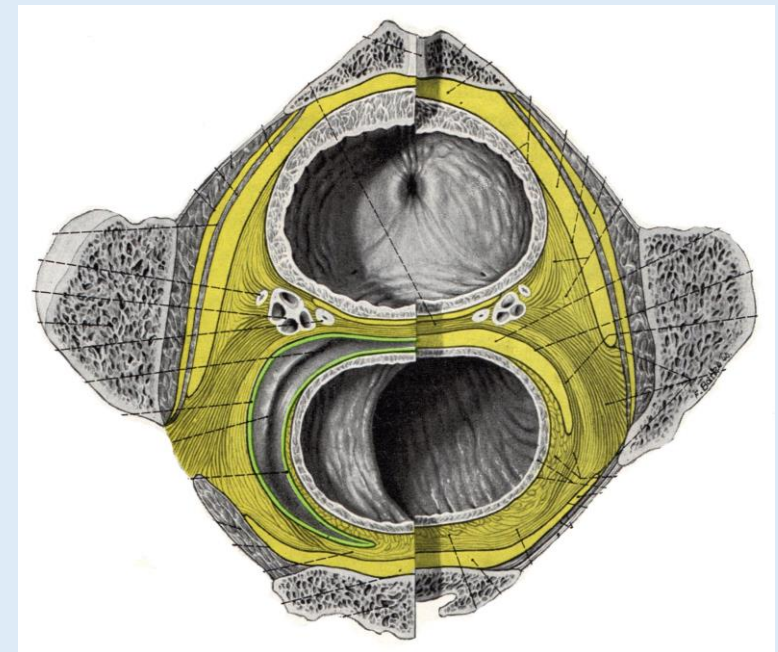
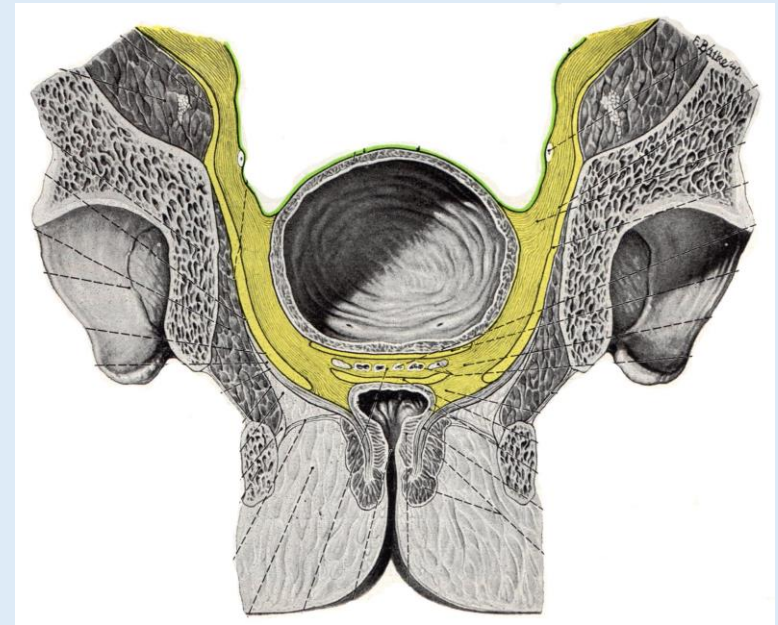
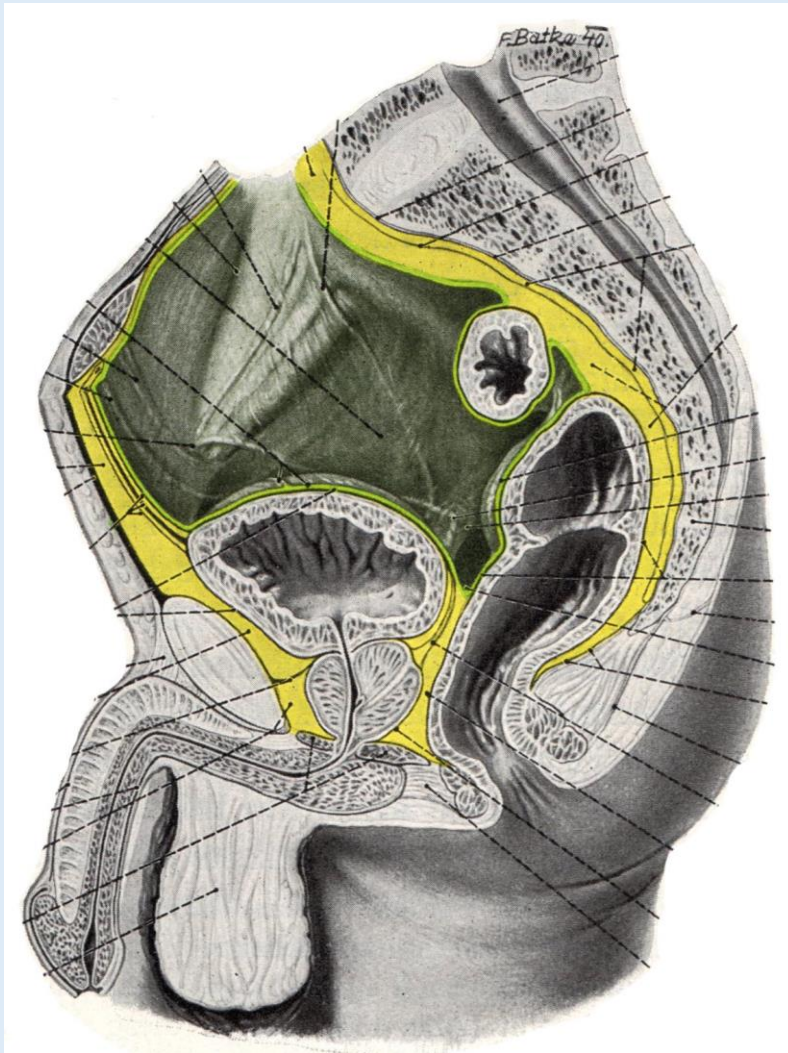


# A medence ér-, idegképletei

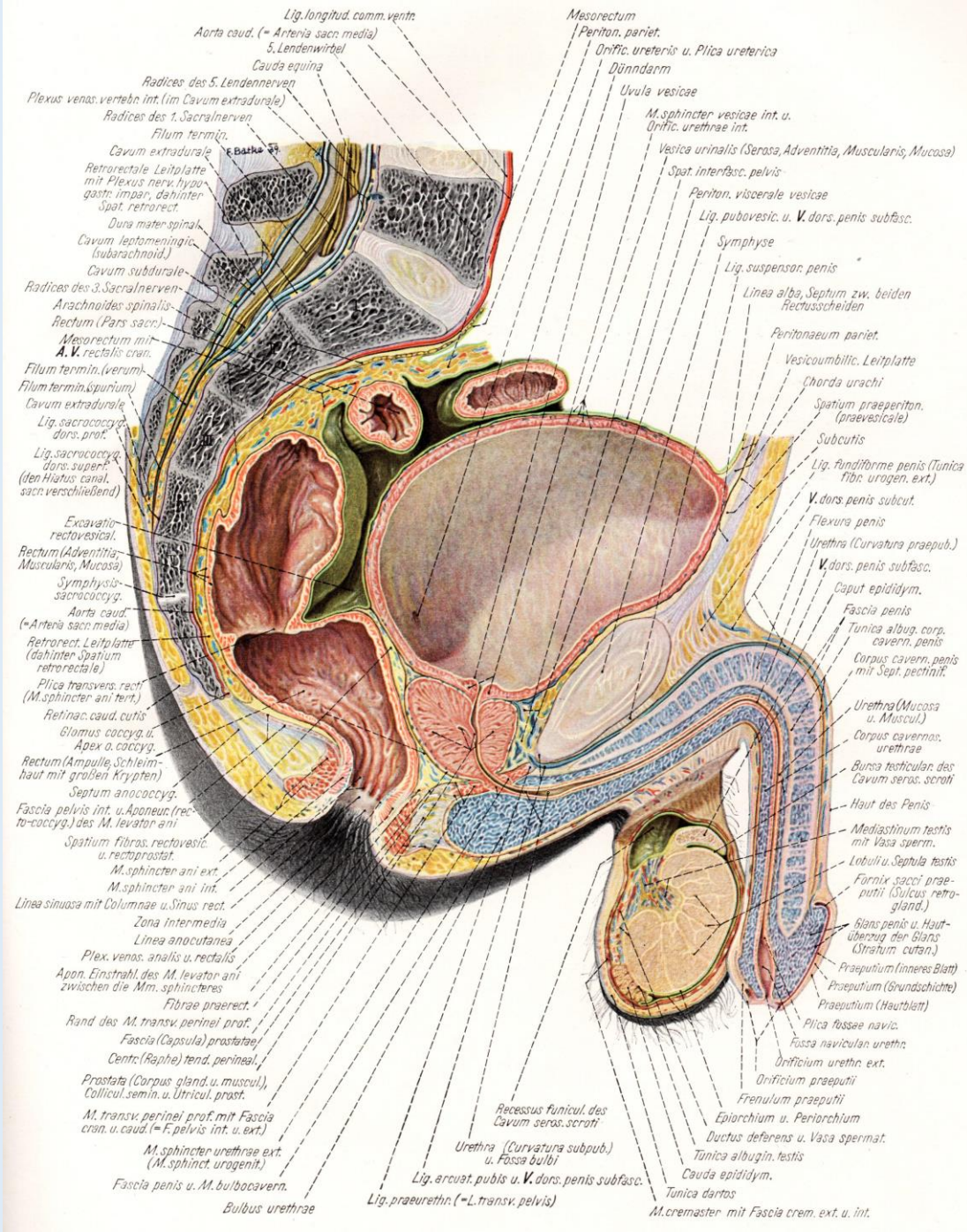
Pernkopf



# A peritoneum és a kötőszövetes térségek



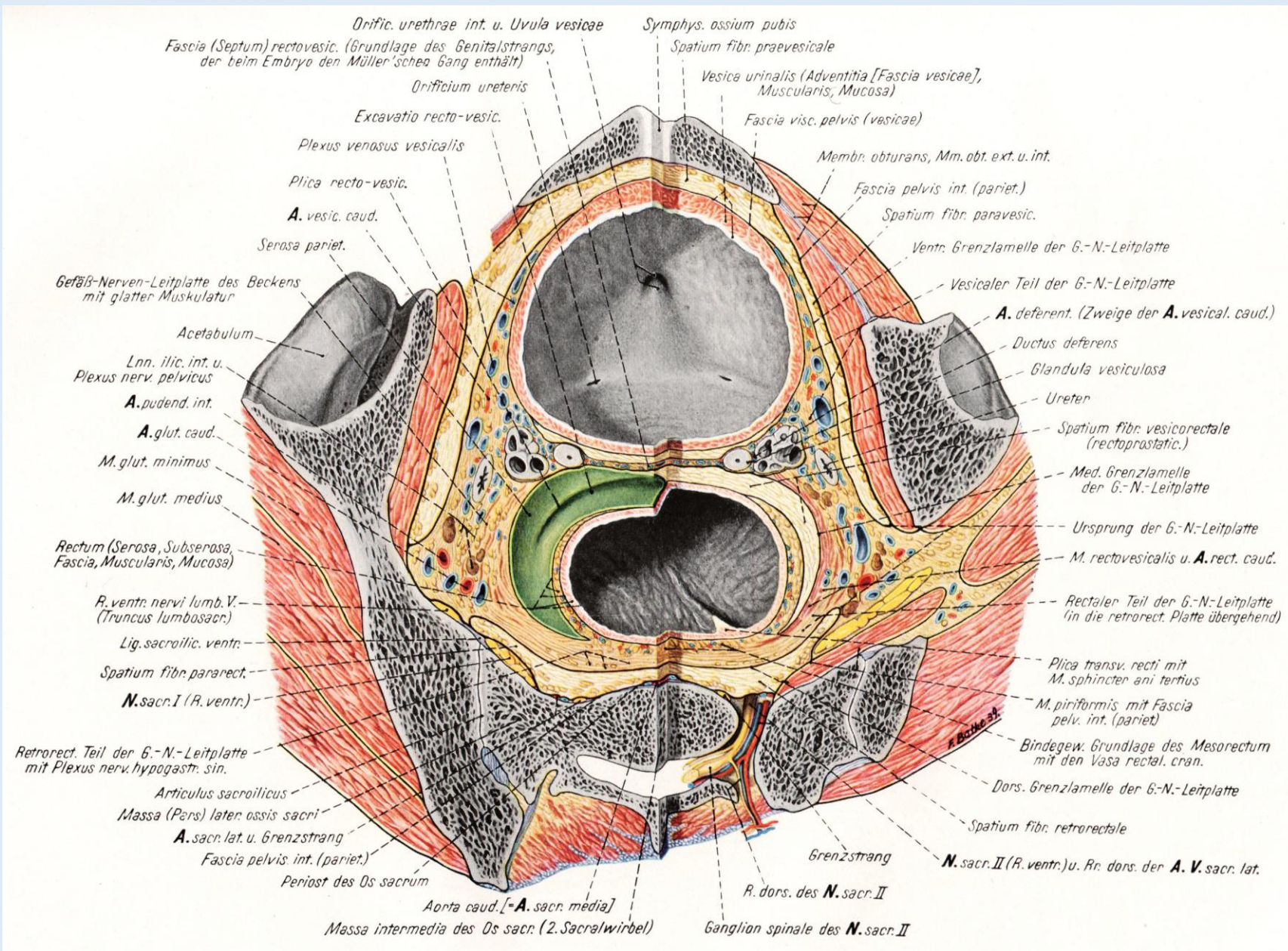
Paraproctium  
Paracysticum  
Paraprostaticum



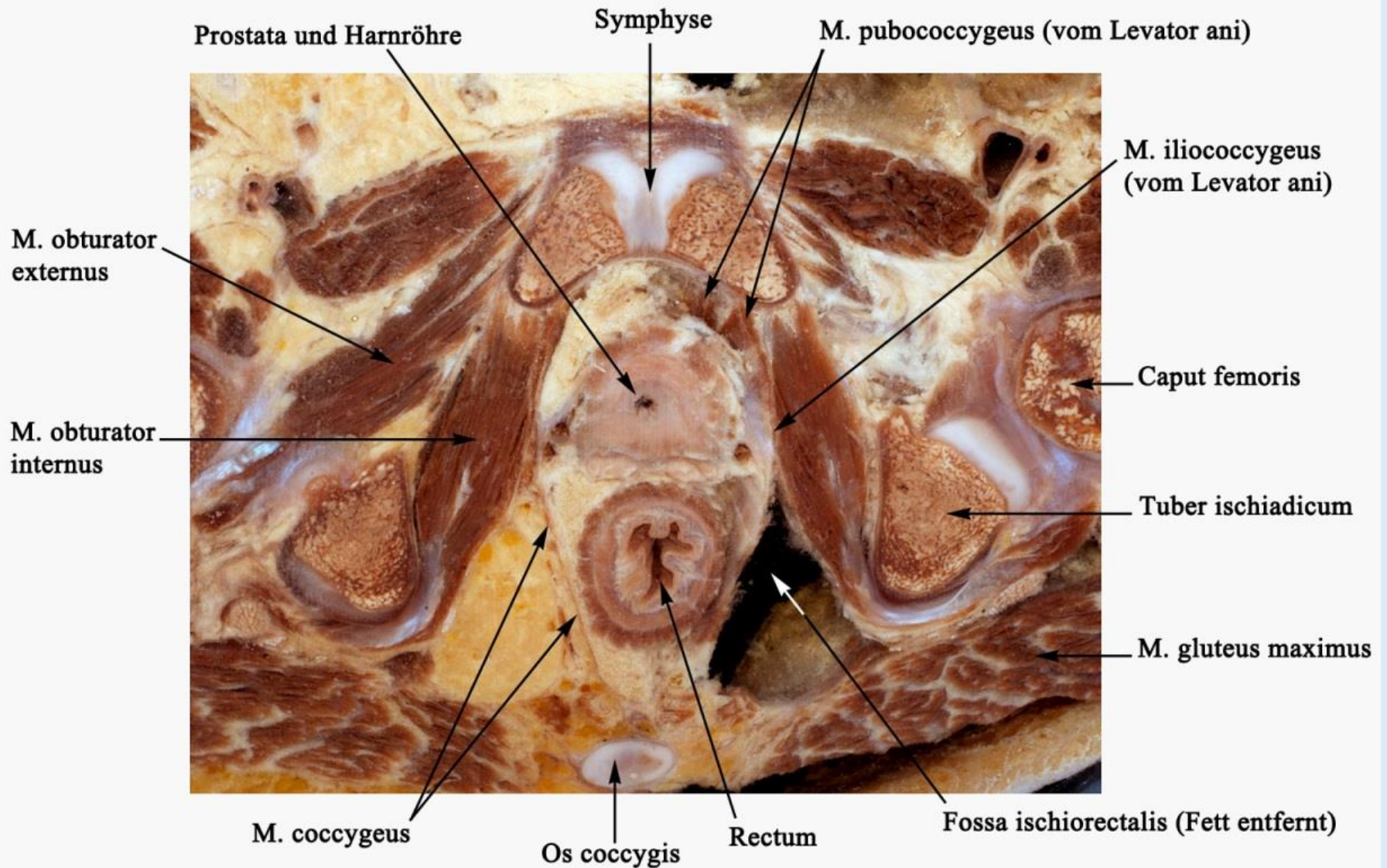
# A kismedence median-sagittalis metszete

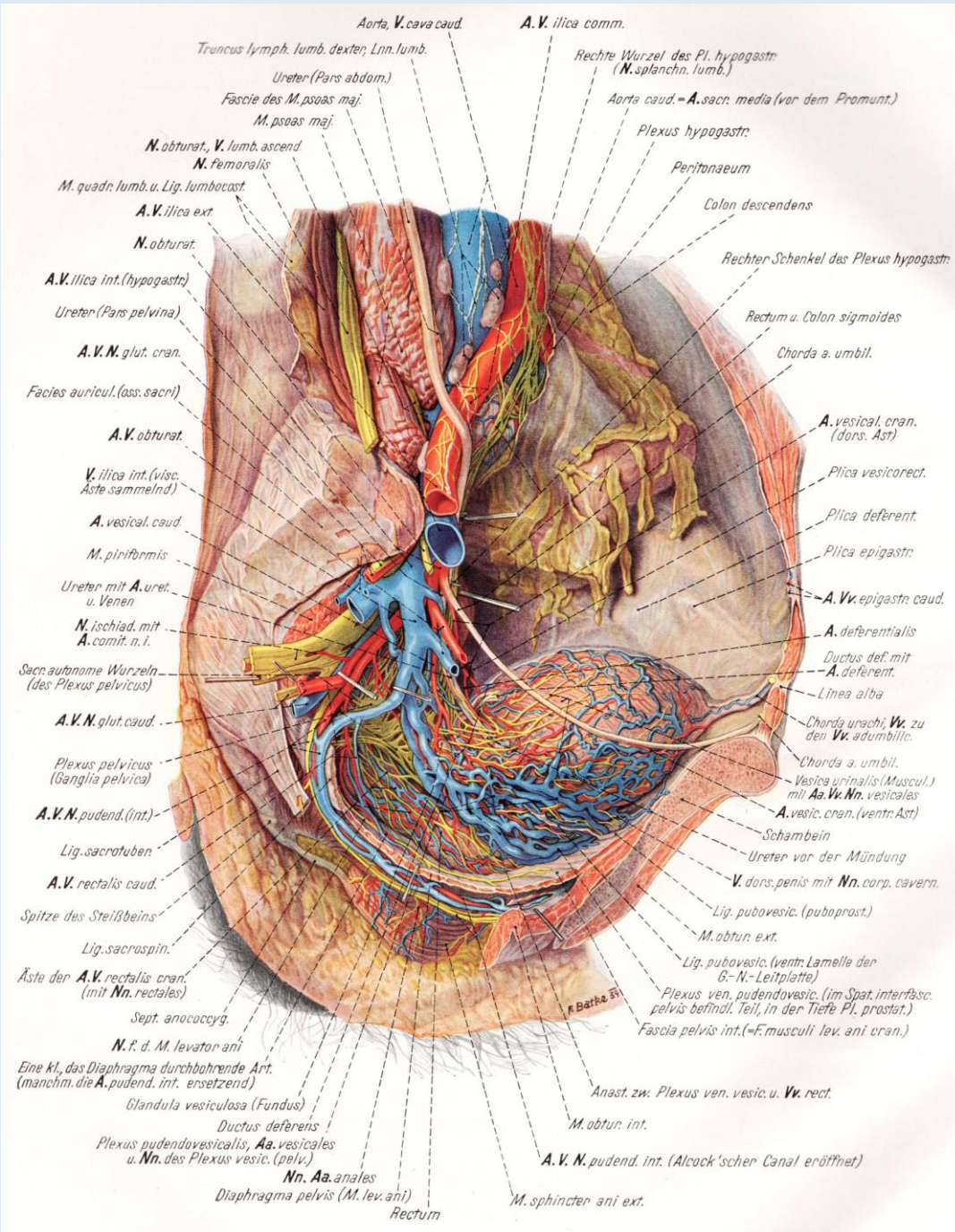
# A kismedence szeptanatómiája

Pernkopf



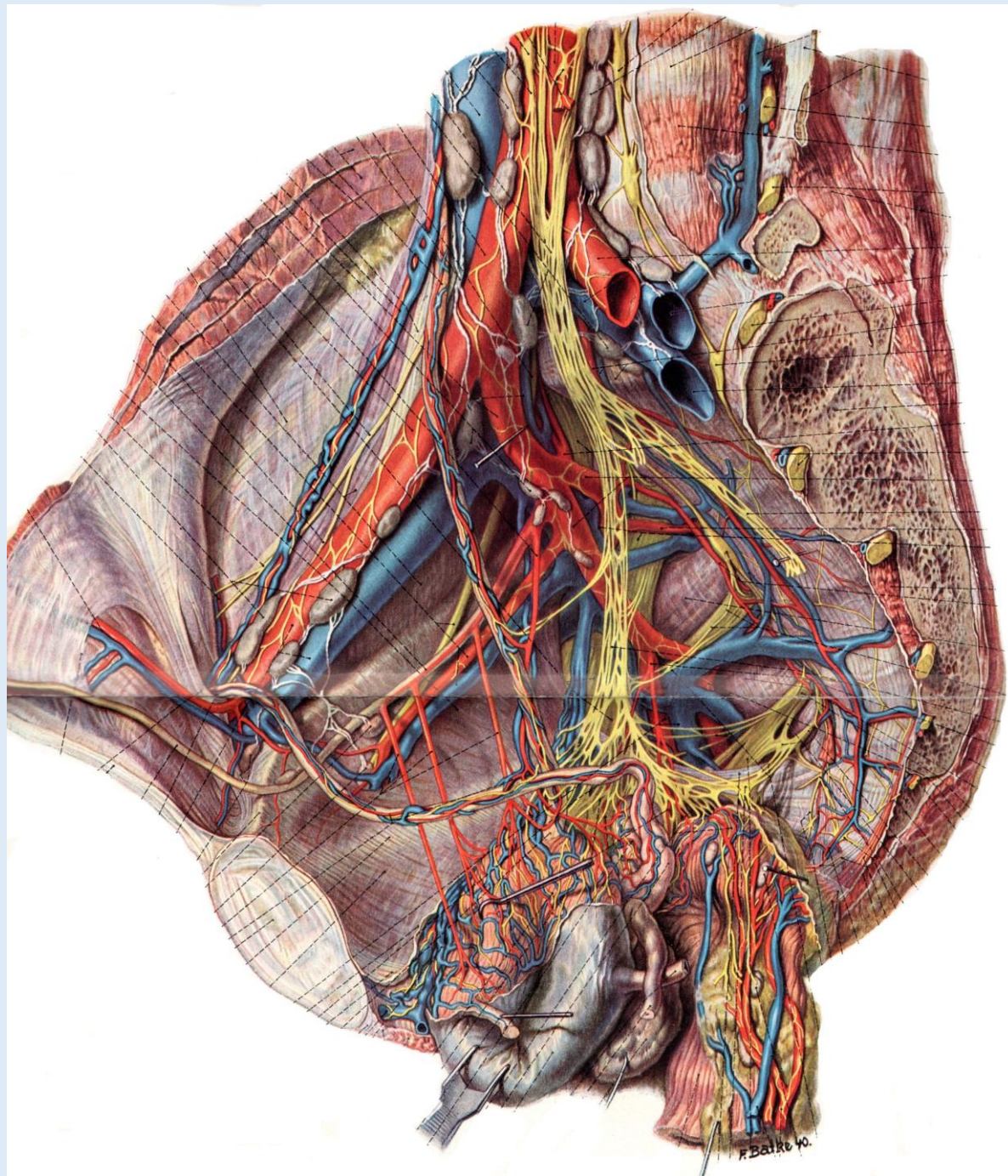
# A kismedence szeletanatómiája

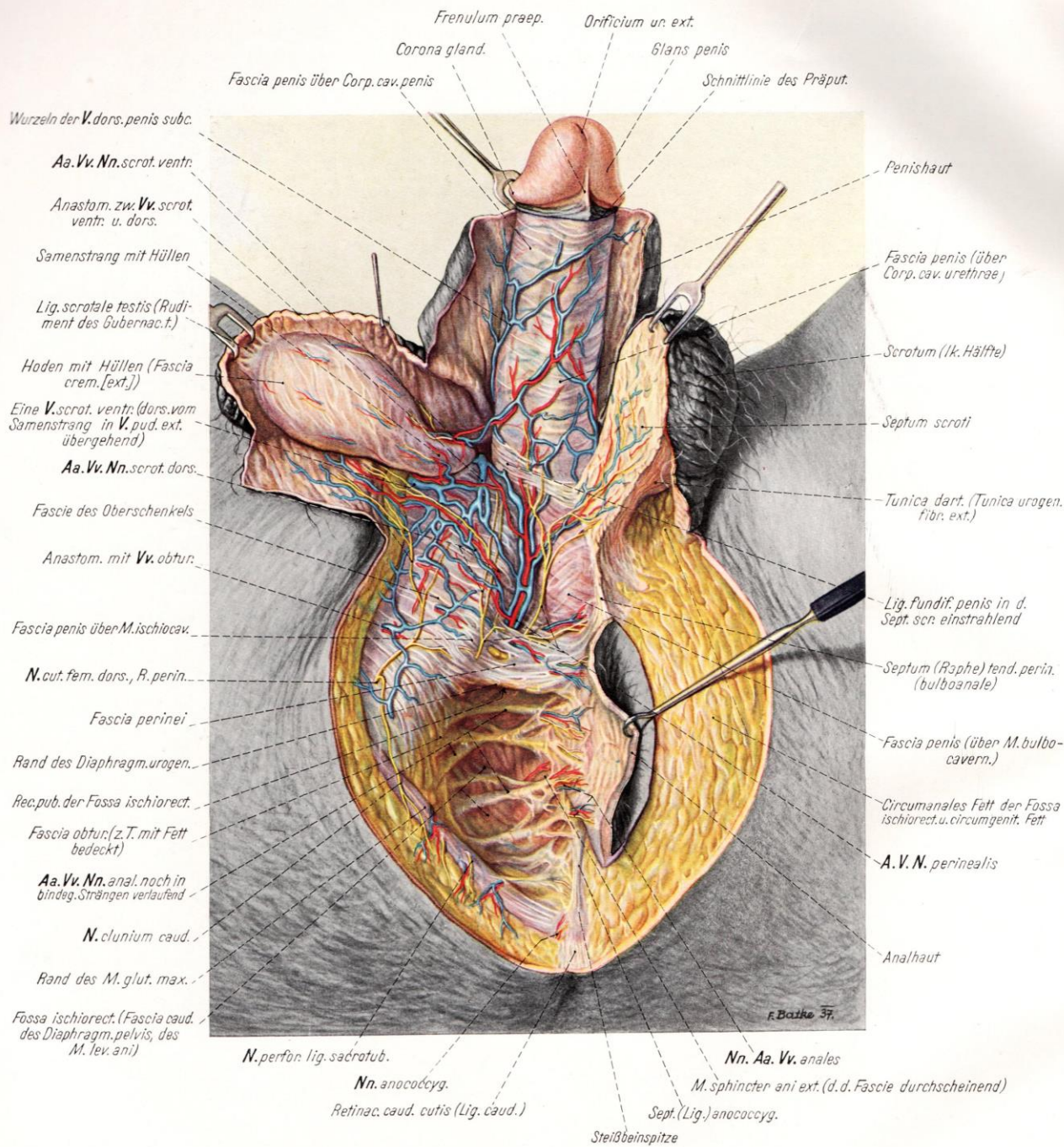




# A kismedence paramedian-sagittalis metszete

# A medence ér-, idegképletei





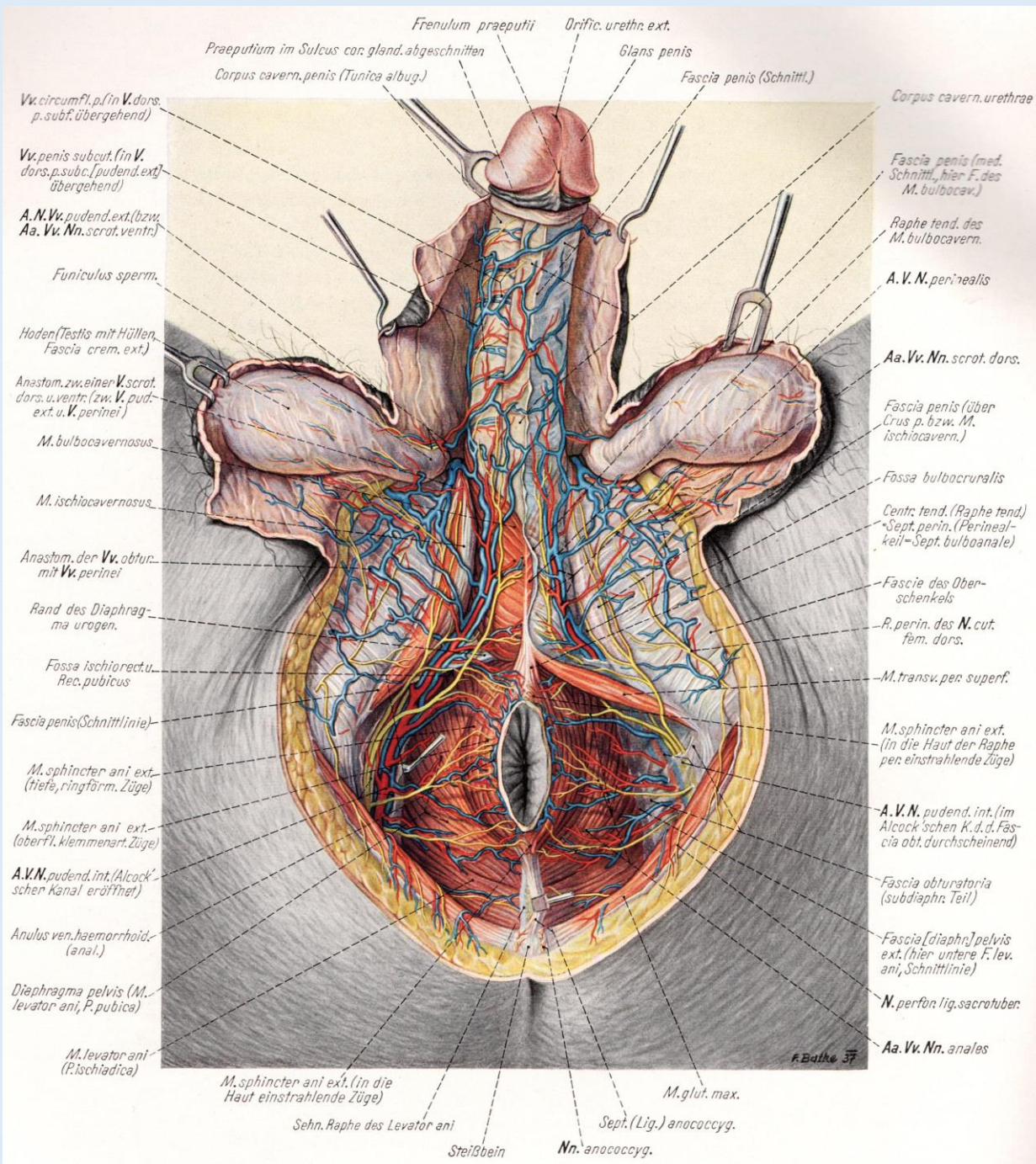
# A férfi gát felületes képletei

Arteria pudenda interna  
ex Arteria iliaca interna

Nervus pudendus  
ex Plexus pudendohaemorrhoidalis

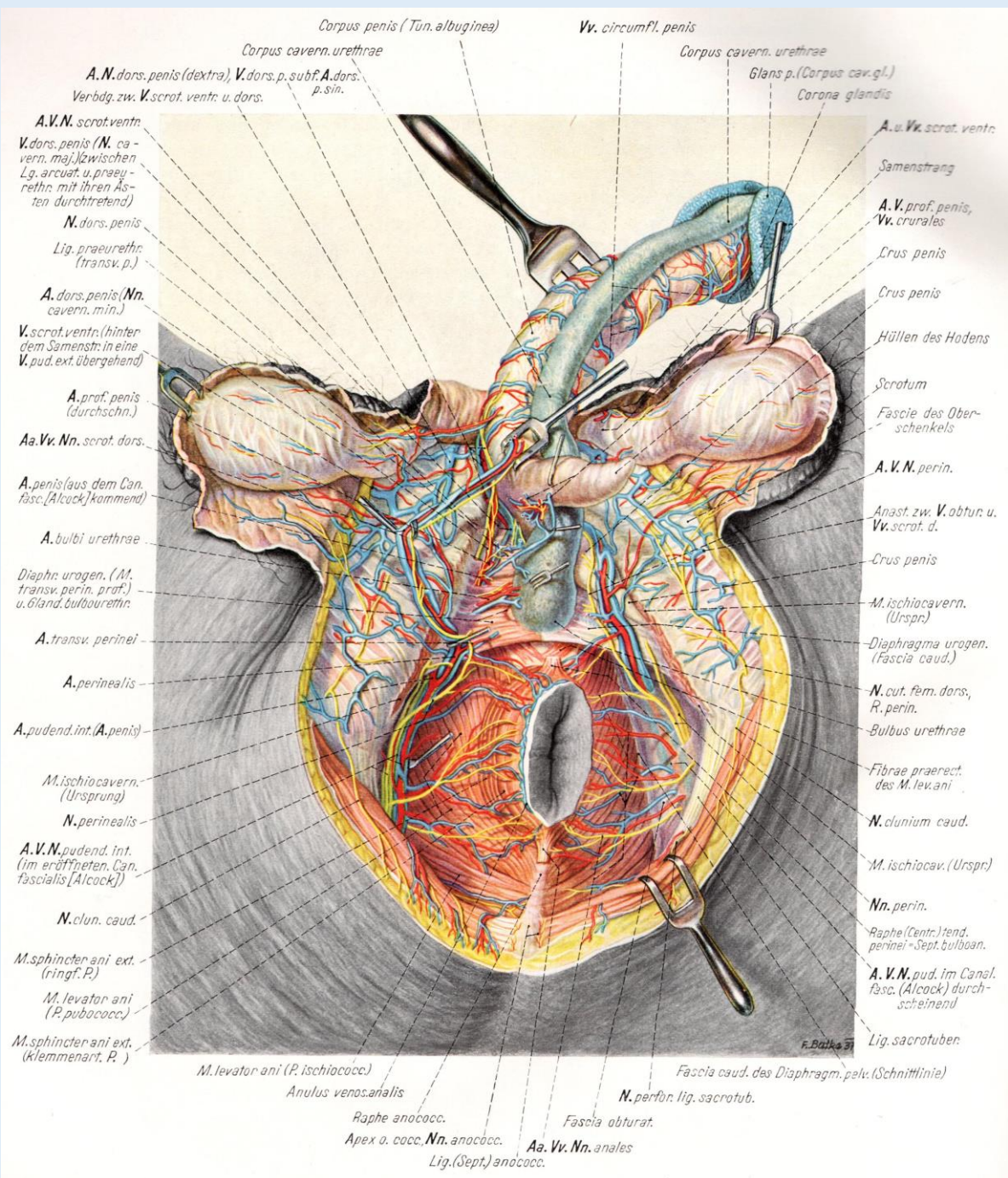
Pernkopf



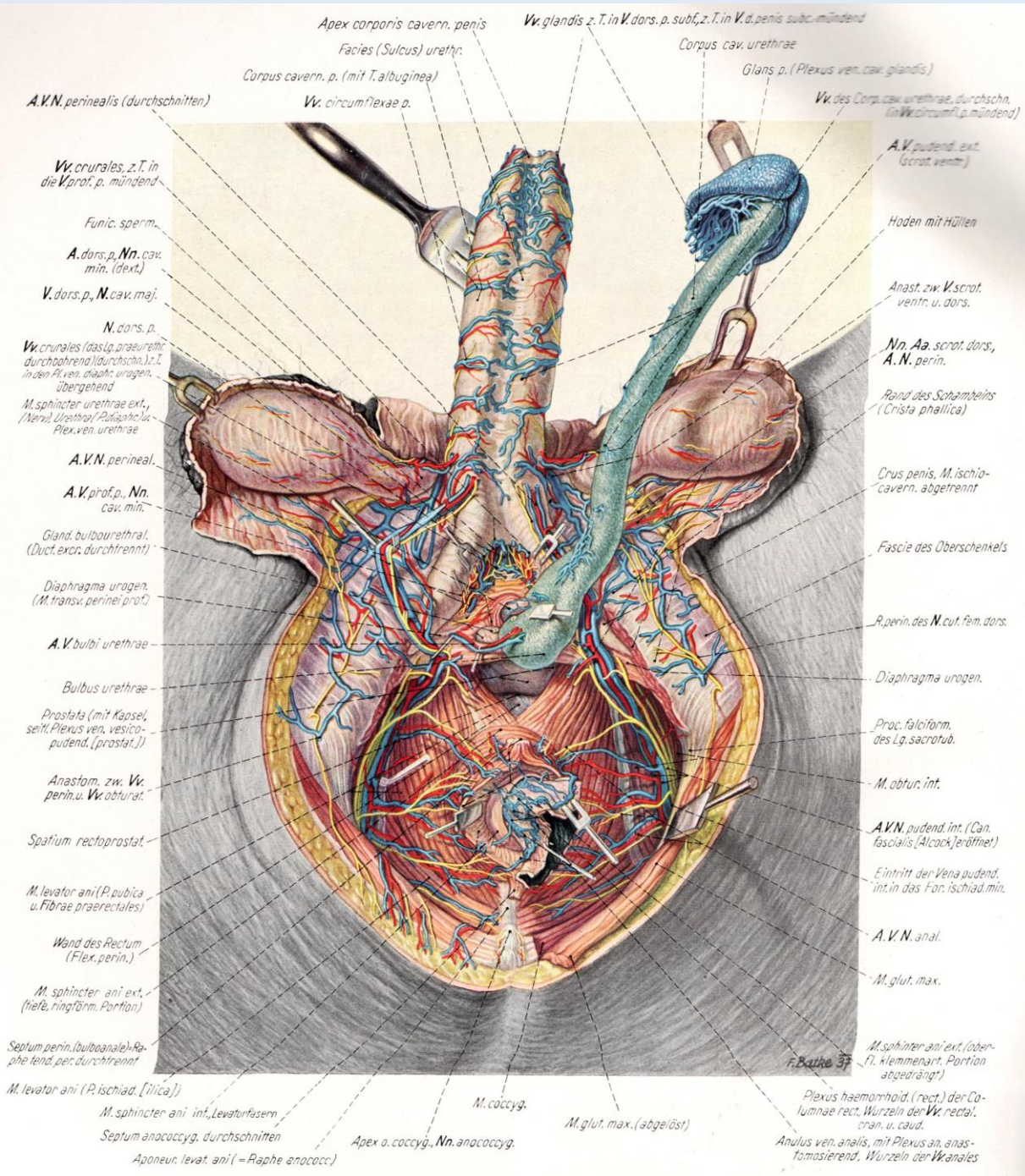


# A férfi gát felületes képletei

## Alcock-csatorna



# A férfi gát felületes képletei



# A férfi gát felületes képletei