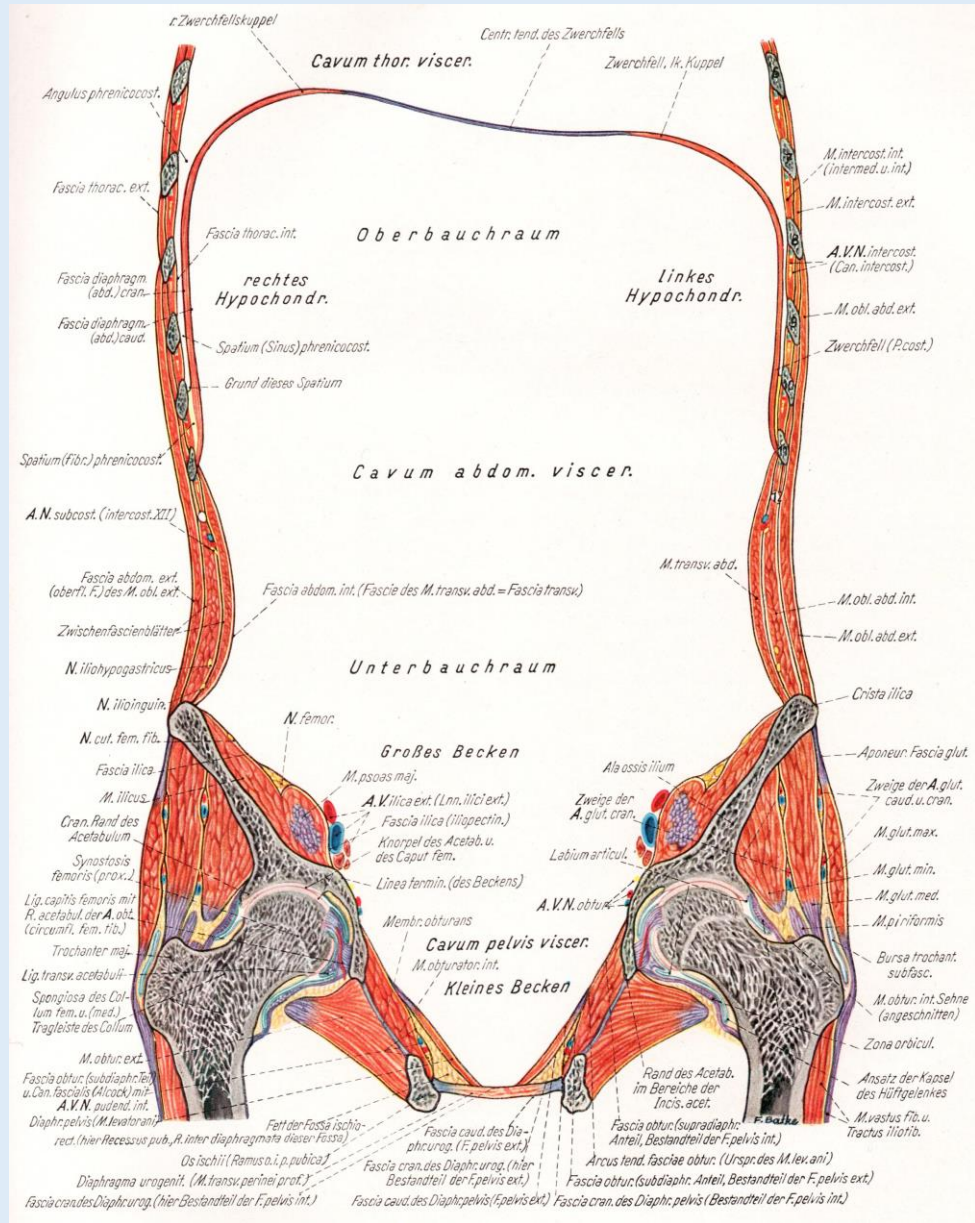
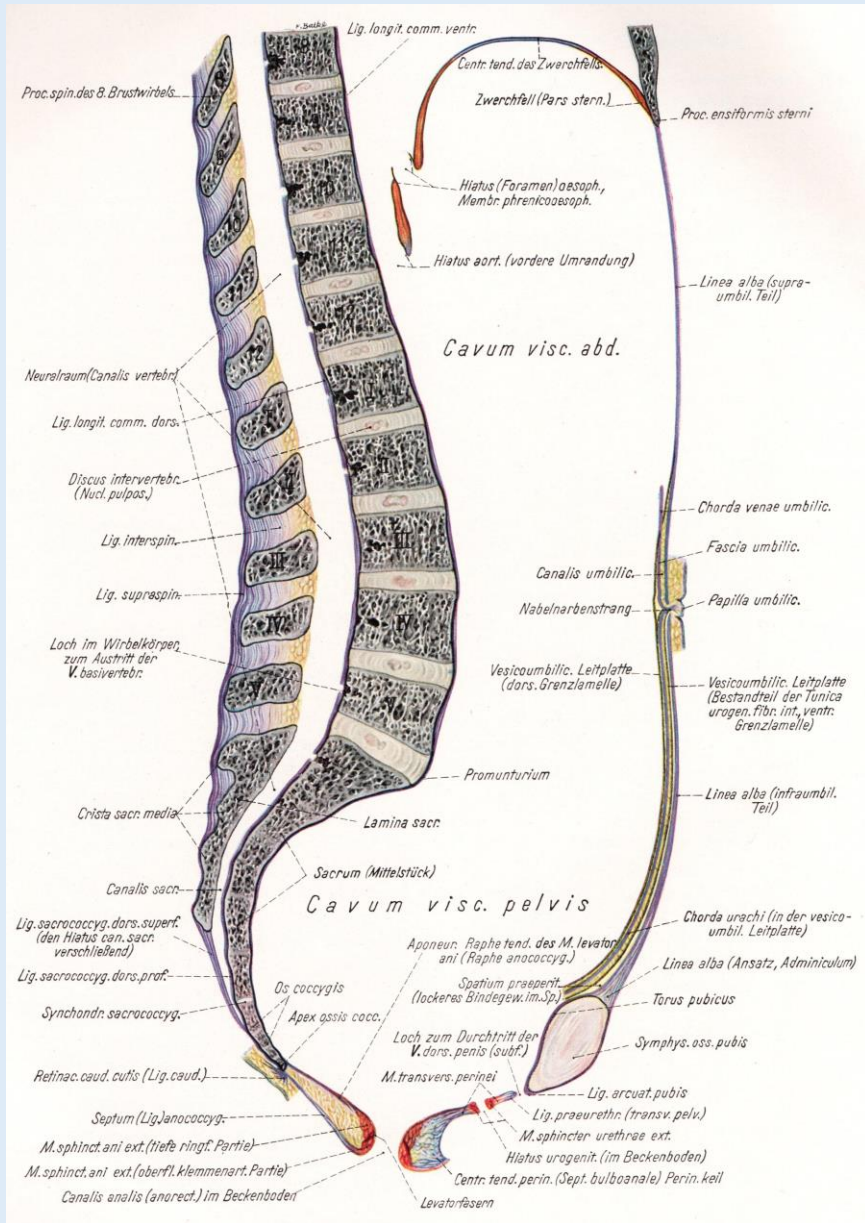


Topographische und Querschnittanatomie des männlichen Beckens und des Dammes

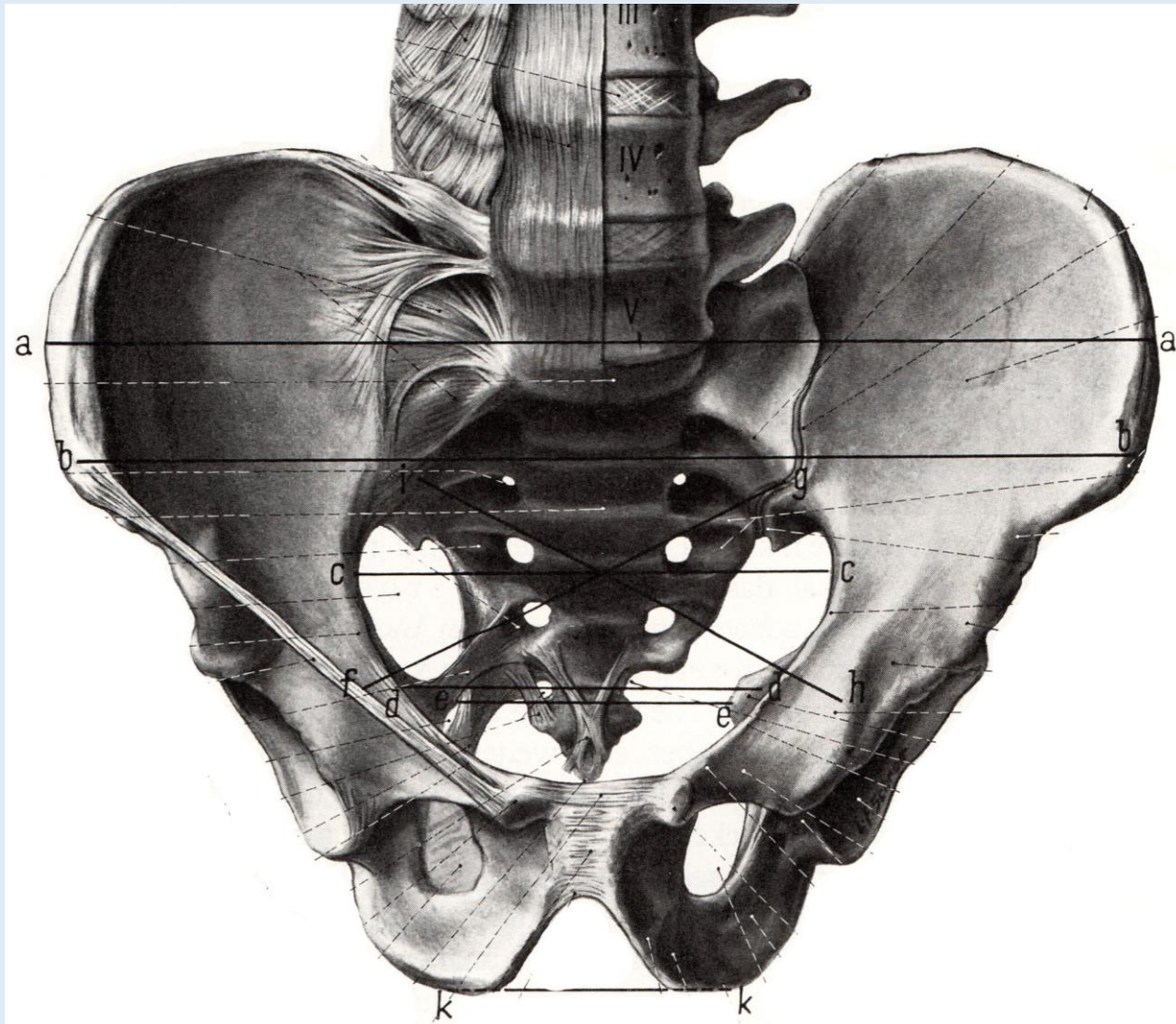
Dr. Tamás Ruttkay

Anatomisches, Histologisches und Embryologisches Institut
2018.

Bauchhöhle und Beckenhöhle



Durchtrittsstellen des Beckens



Apertura pelvis superior
(Linea terminalis)

Angulus subpubicus

Foramen obturatum/
Canalis obturatorius

Foramen ischiadicum majus
Hiatus suprapiriformis
Hiatus infrapiriformis

Foramen ischiadicum minus

Beckenboden

Zilles-Tillmann

Peritoneum



Bindegewebsraum




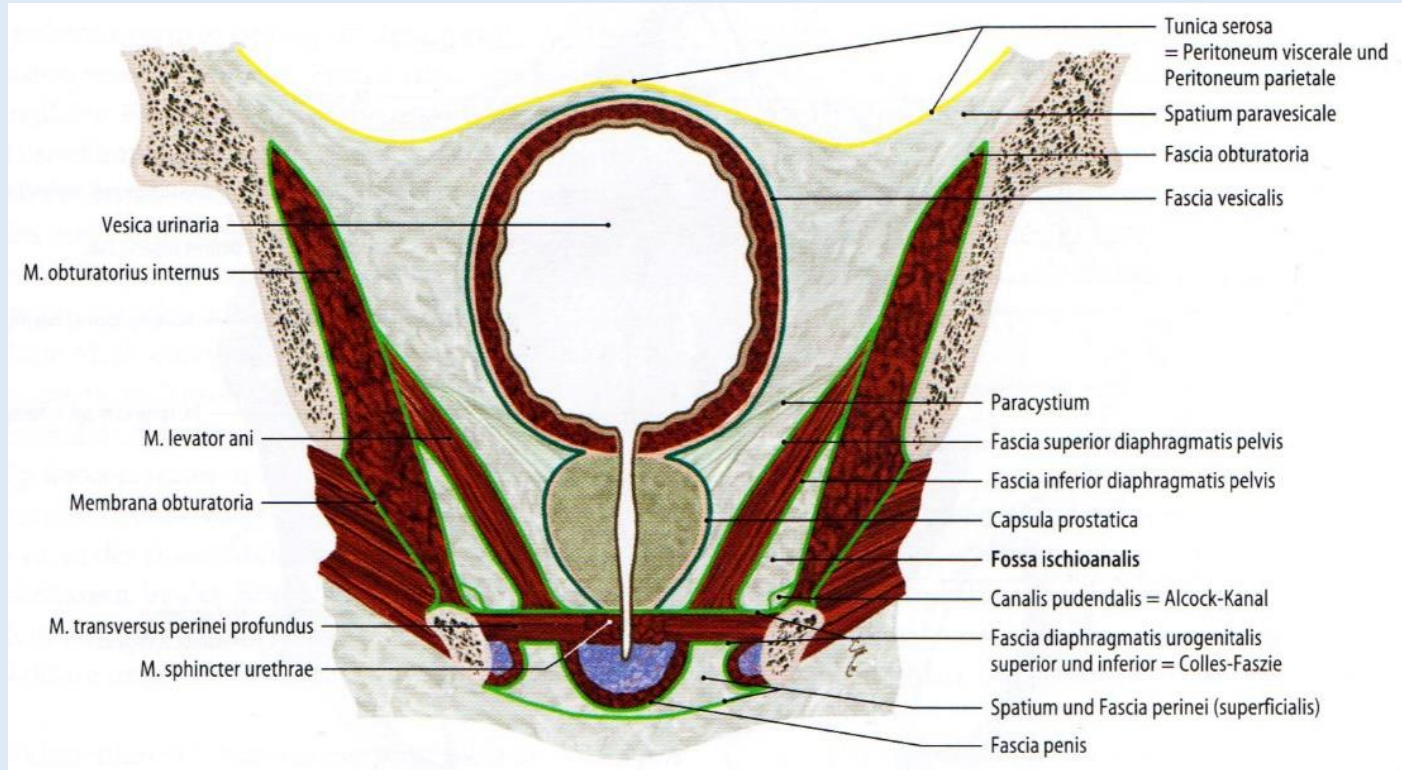
Diaphragma pelvis:
Fascia diaphragmatis pelvis superior;
Musculus levator ani;
Fascis diaphragmatis pelvis inferior



Hiatus genitalis und analis

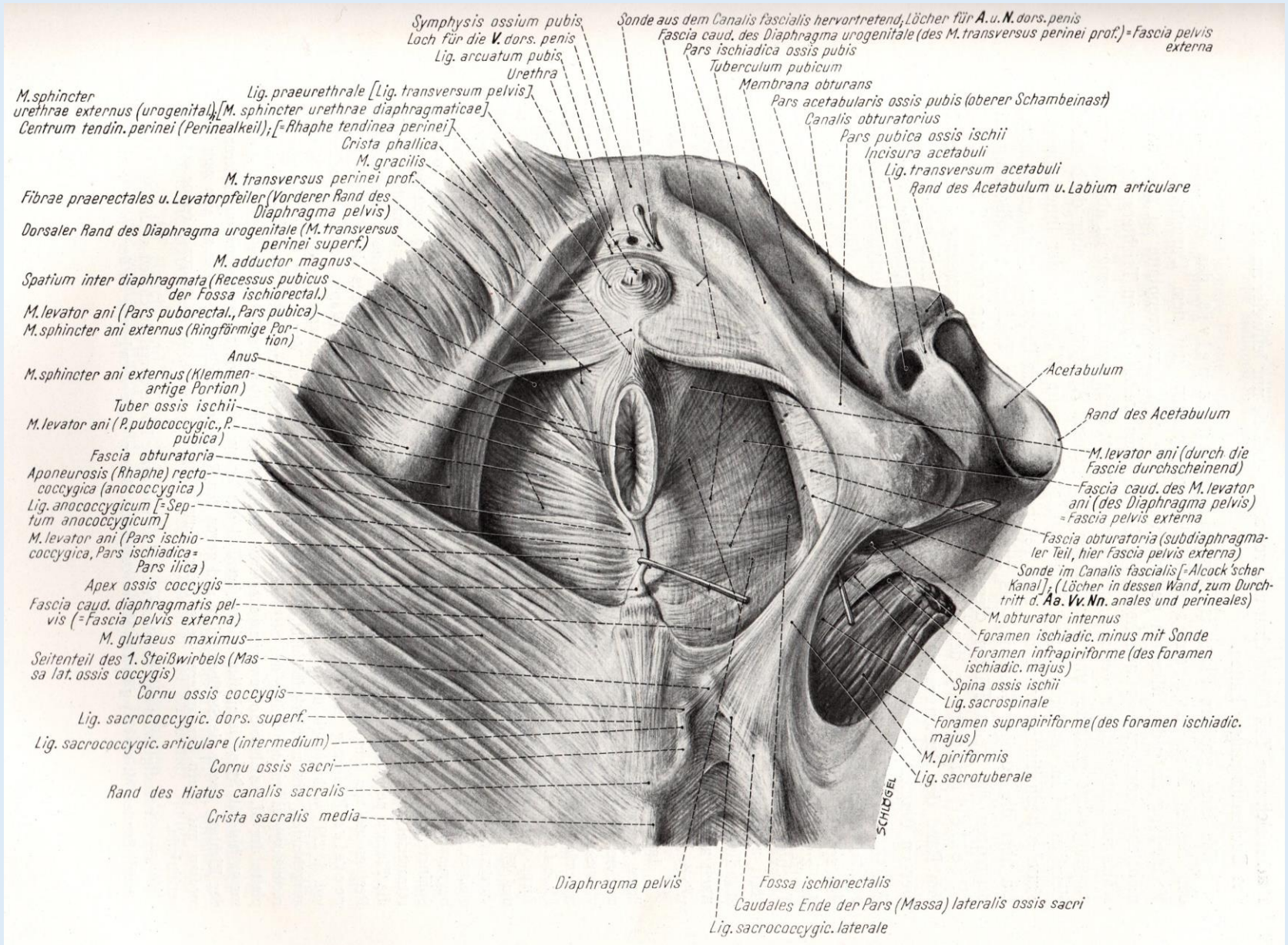


Diaphragma urogenitale:
Fascia diaphragmatis urogenitalis inferior;
M. transversus perinei prof. und M. sphincter urethrae;
Fascia diaphragmatis urogenitalis inferior



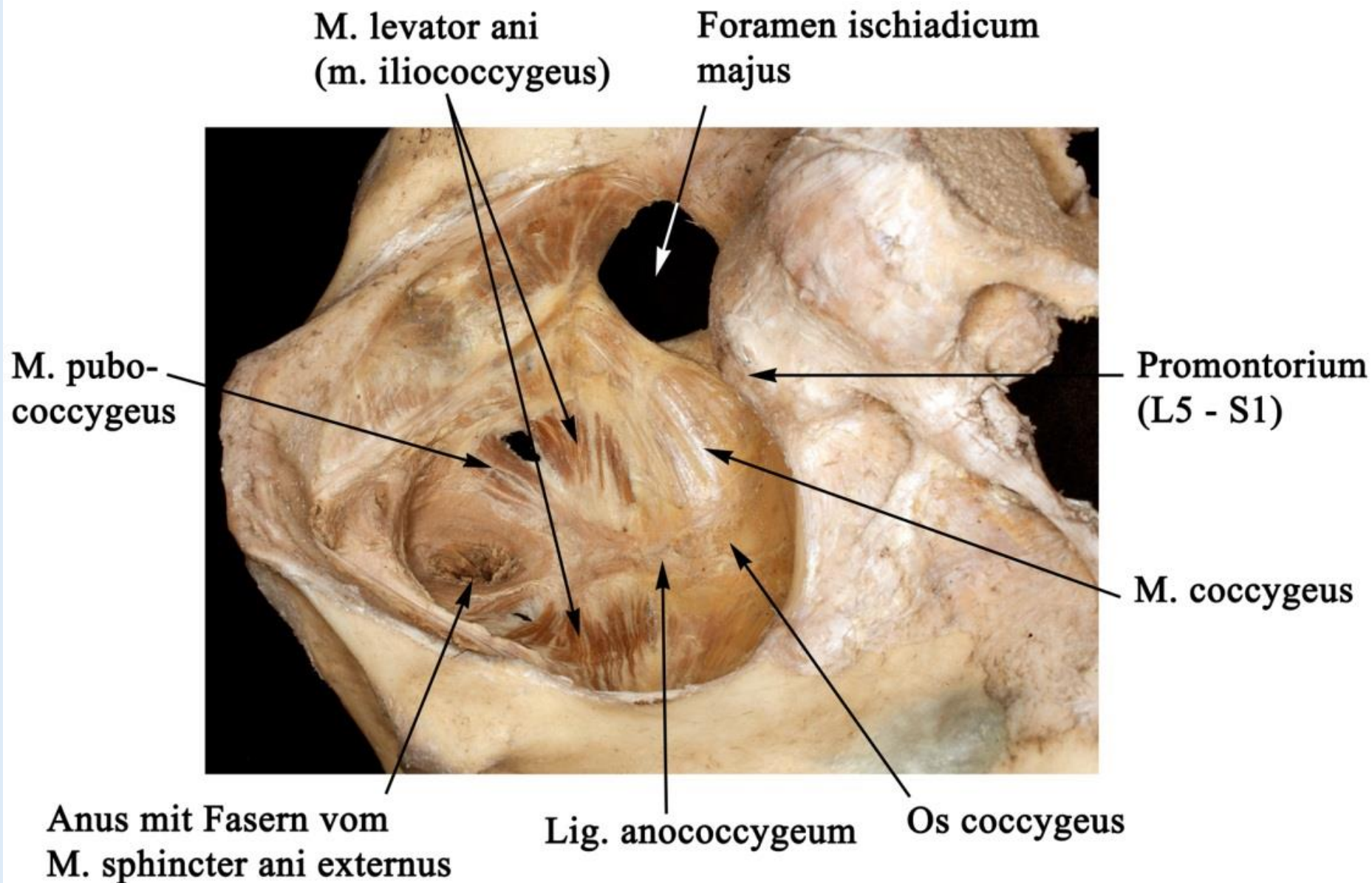
Fossa ischiorectalis

Beckenboden

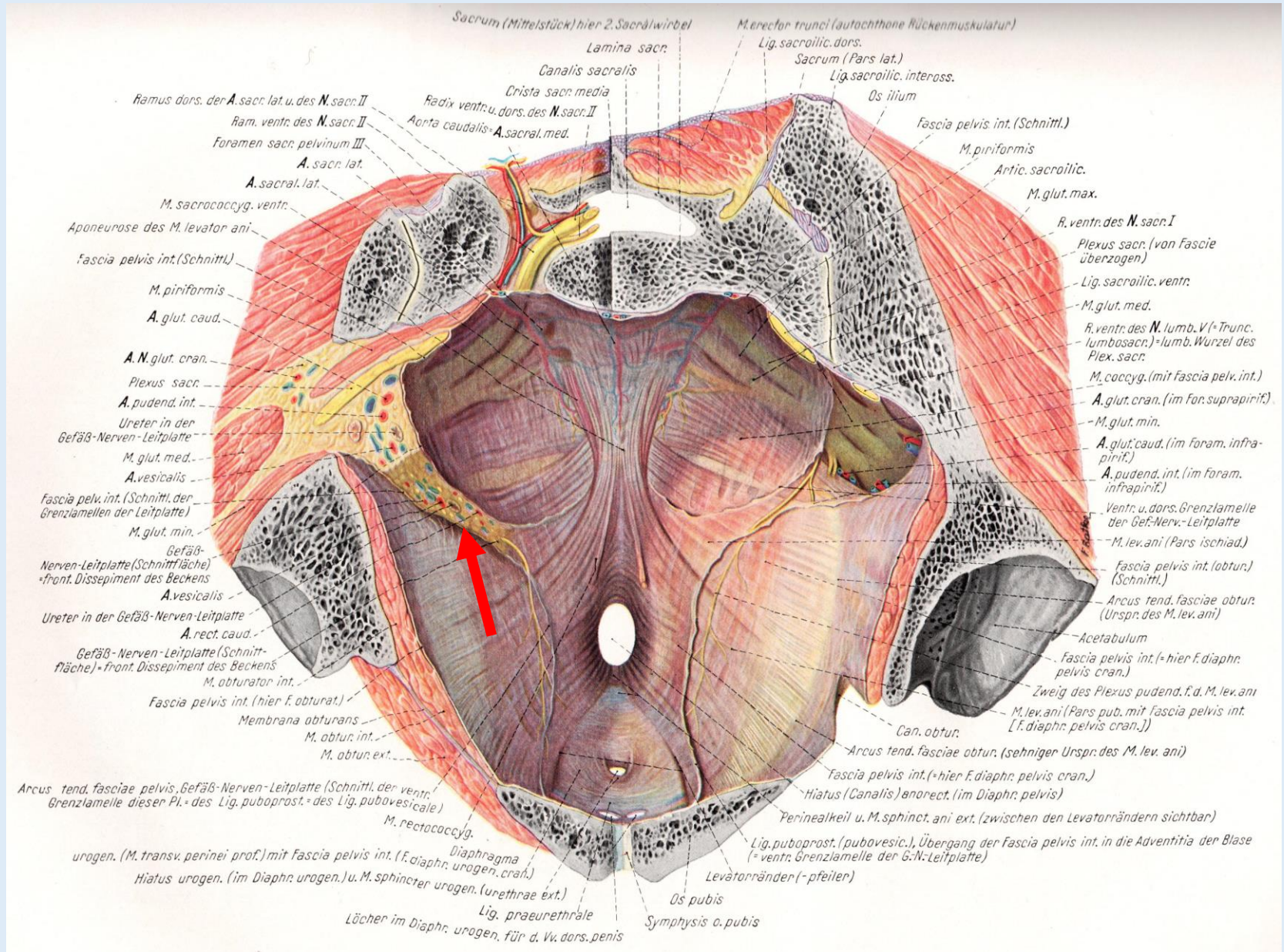


Diaphragma pelvis – Diaphragma urogenitale

„Levator – Trichter“

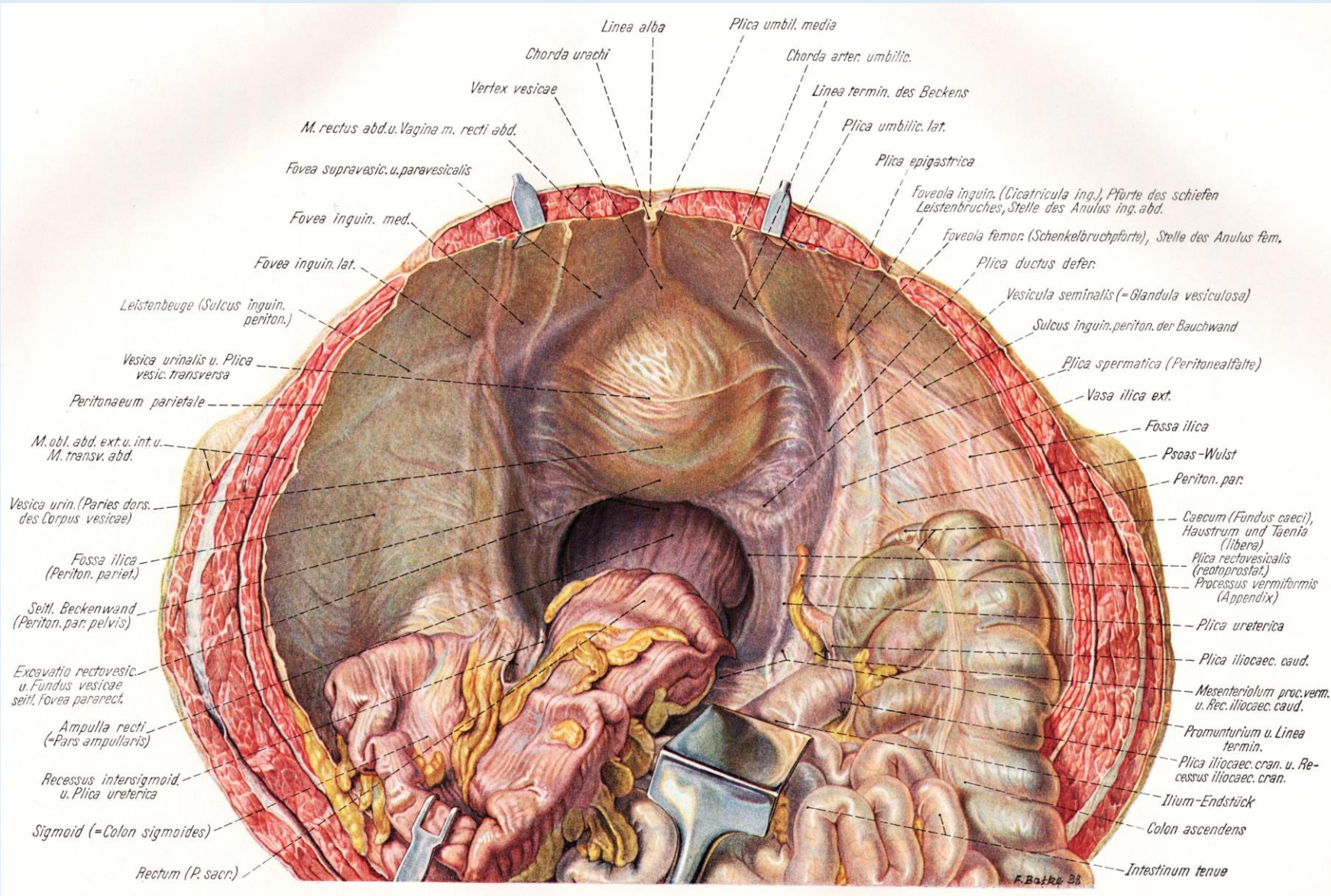


Beckenboden




Gefäß-Nerven-Leitplatte

Großes Becken



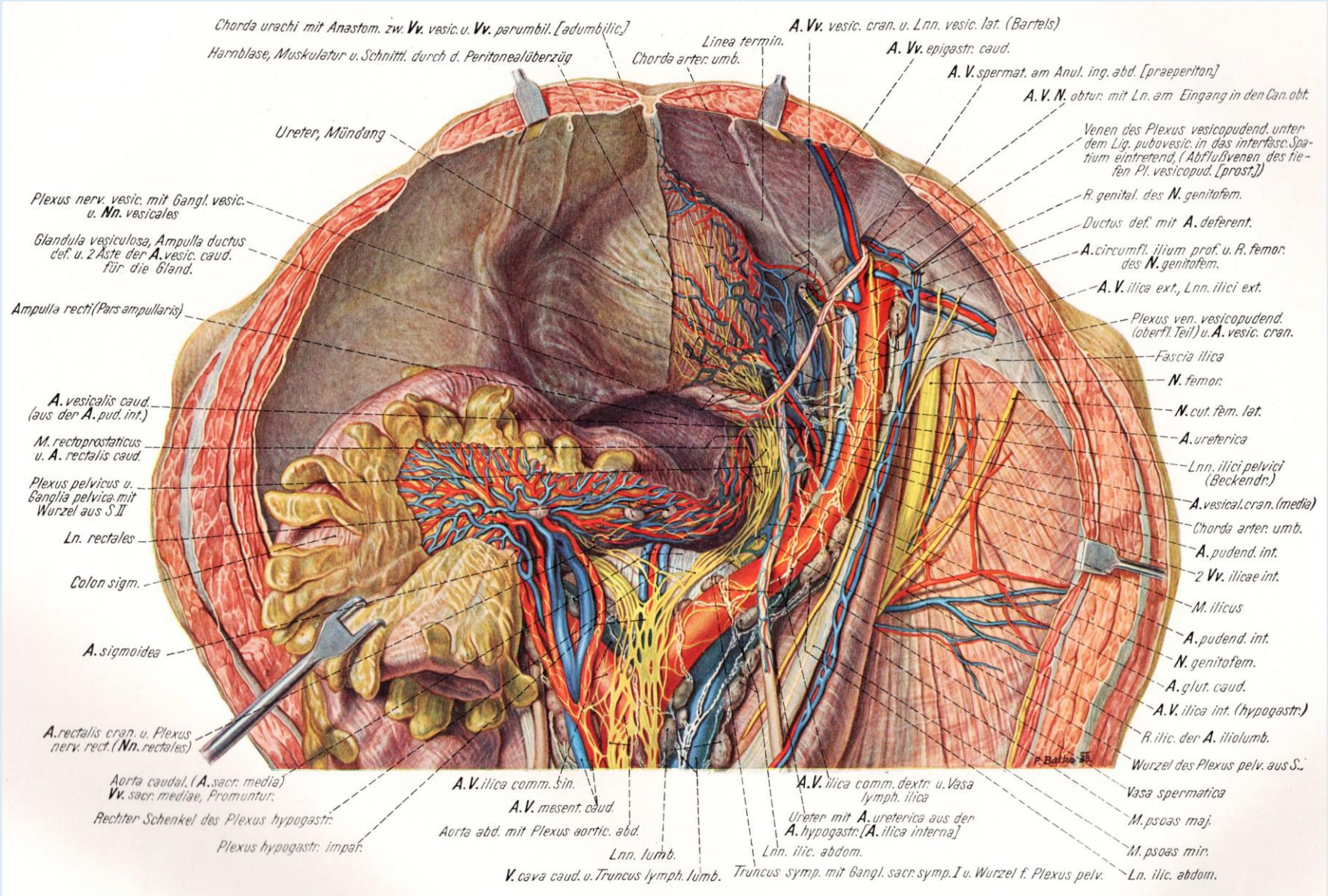
Plica umbilicalis mediana
 Plica umbilicalis medialis
 Plica umbilicalis lateralis



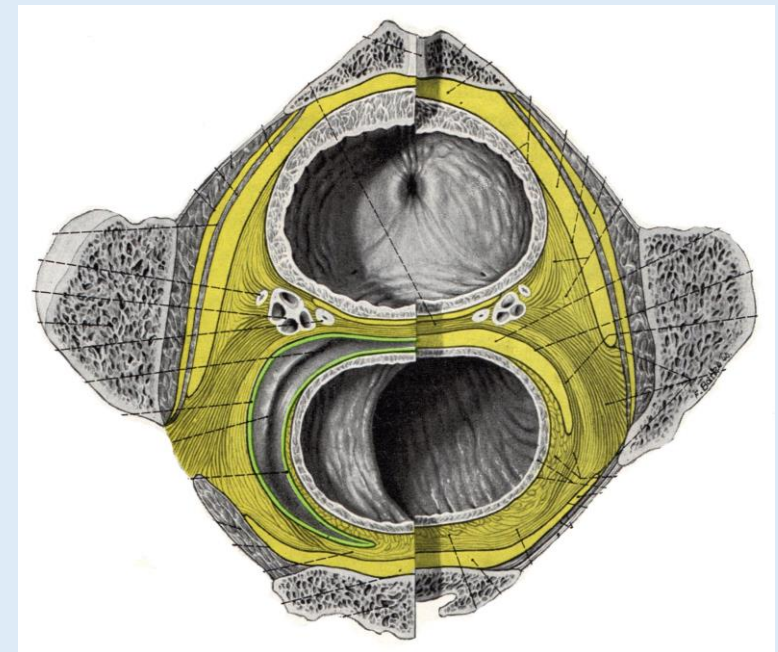
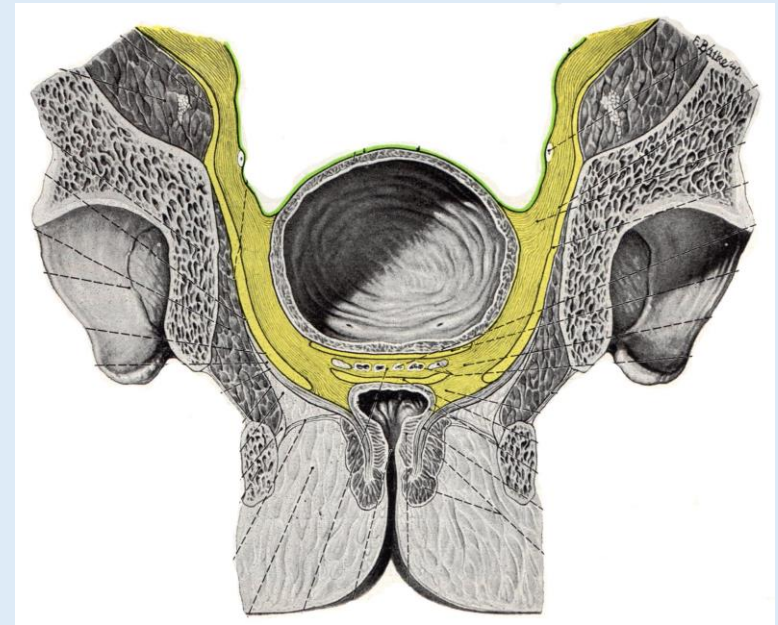
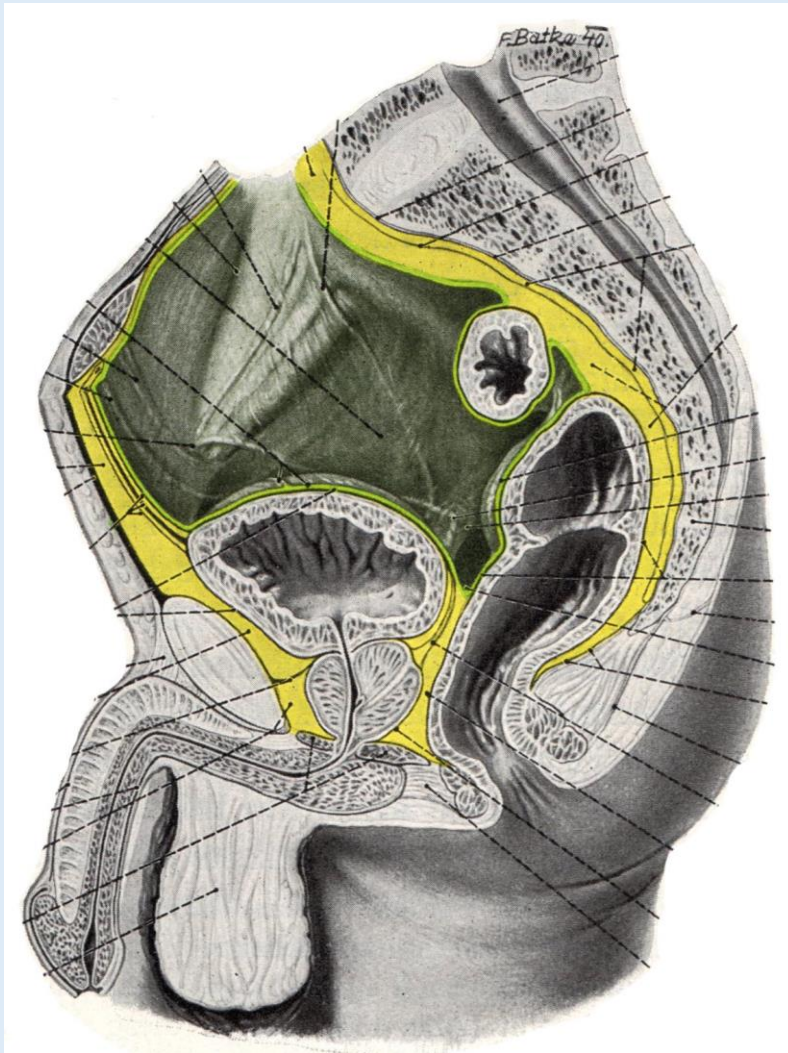
Fossa supravesicalis
 Fossa inguinalis medialis
 Fossa inguinalis lateralis

Gefäße und Nerven des Beckens

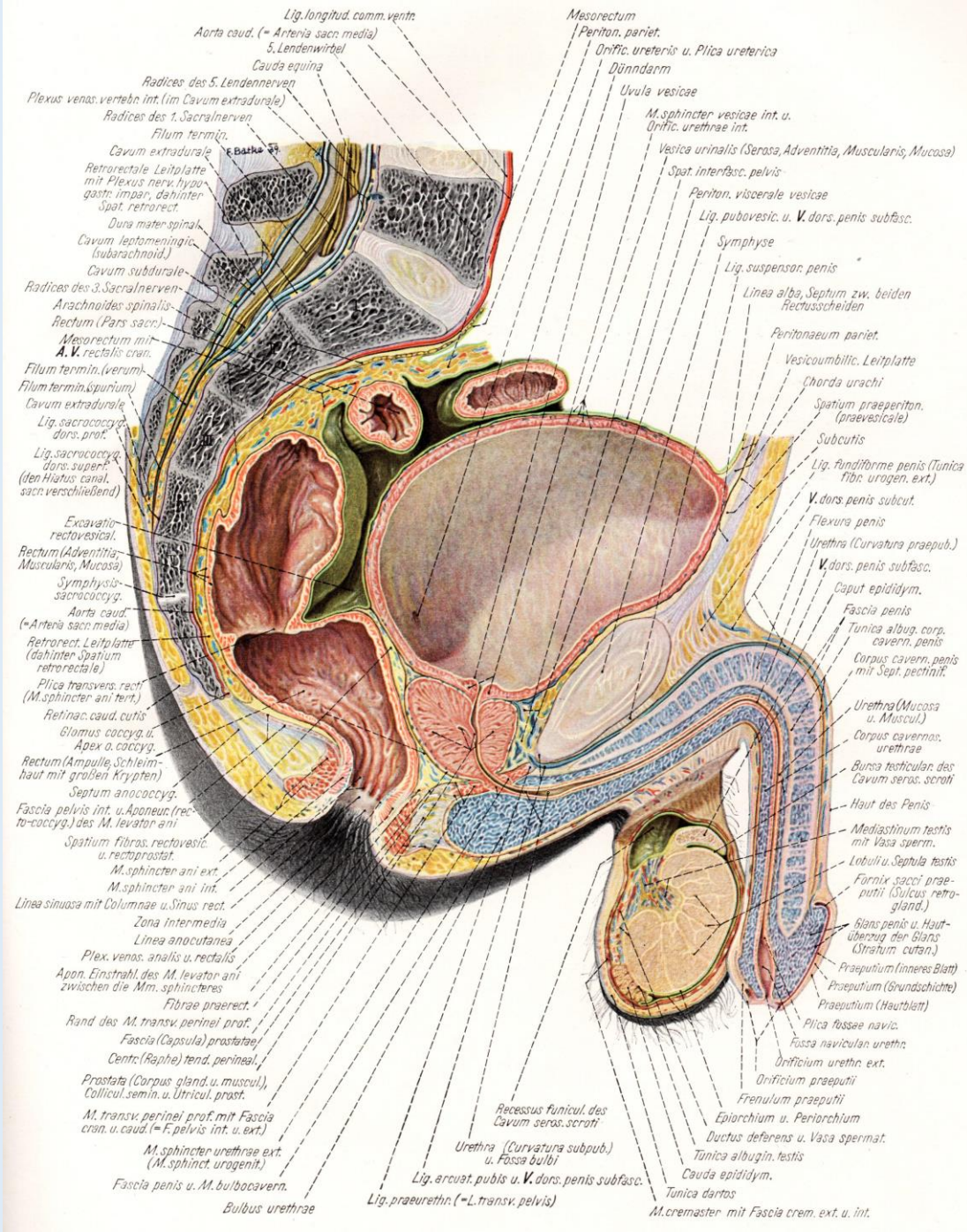
Pernkopf



Peritoneum und Bindegewebsräume



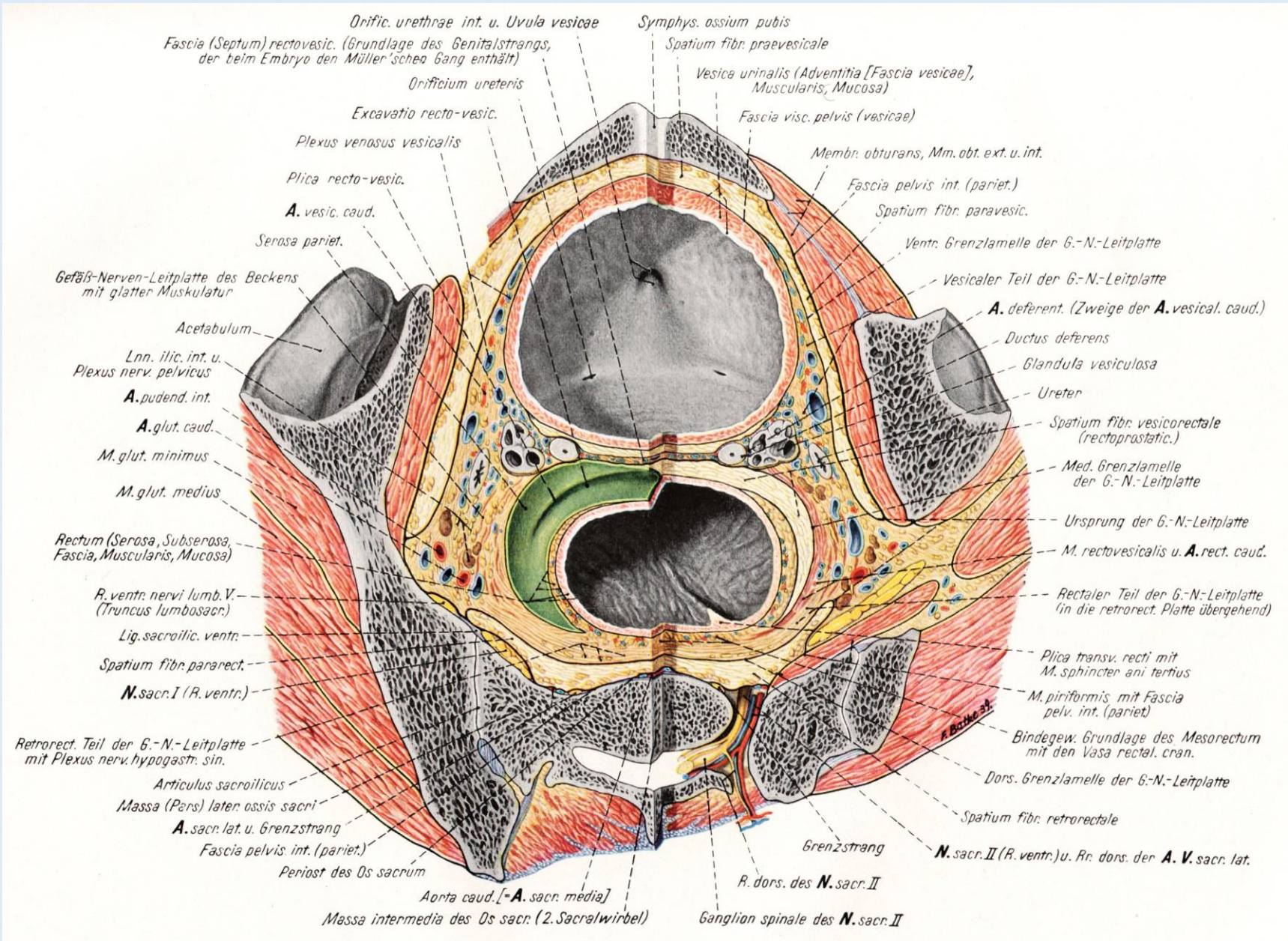
Paraproctium
Paracysticum
Paraprostaticum



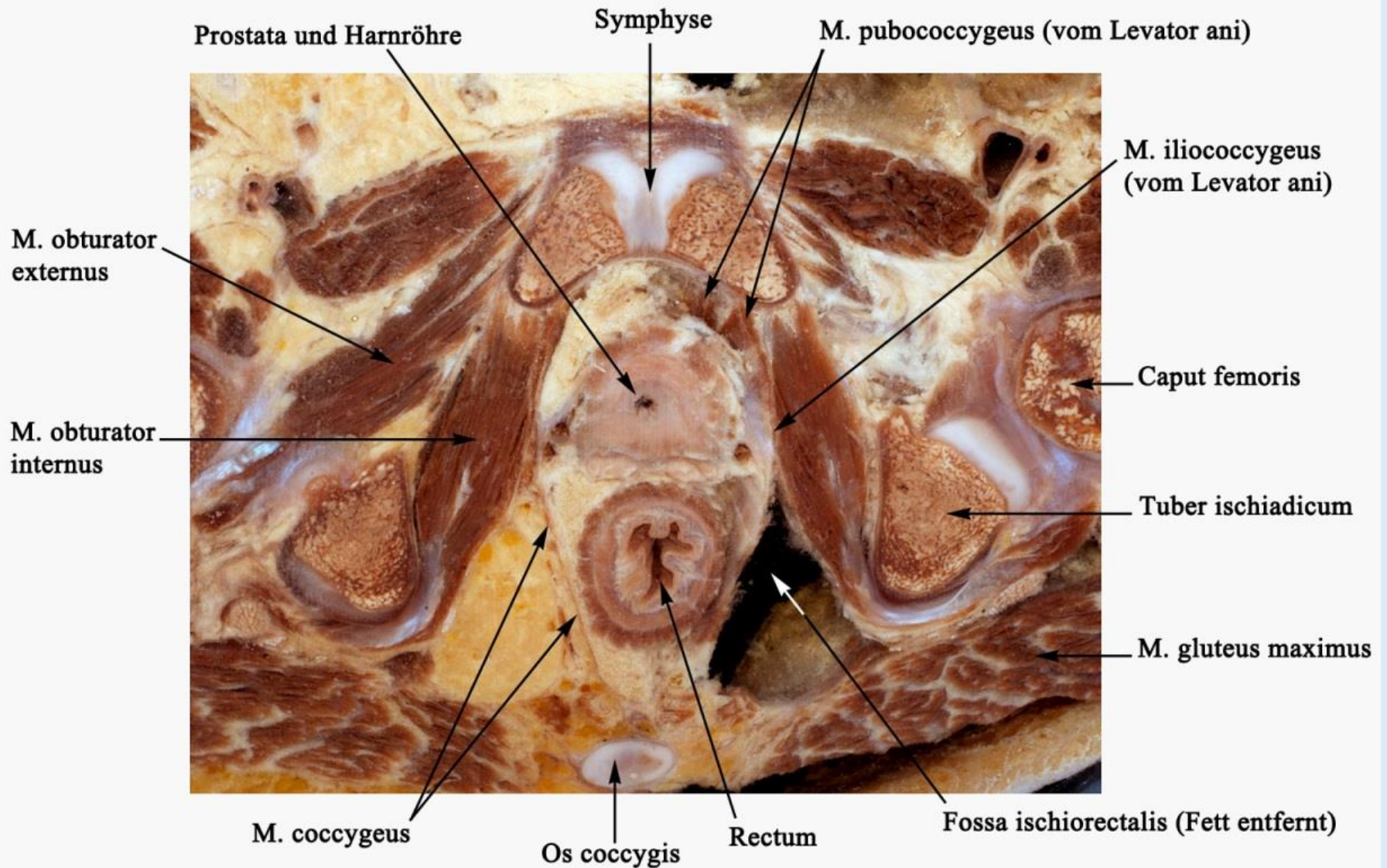
Median-sagittaler Schnitt des kleinen Beckens

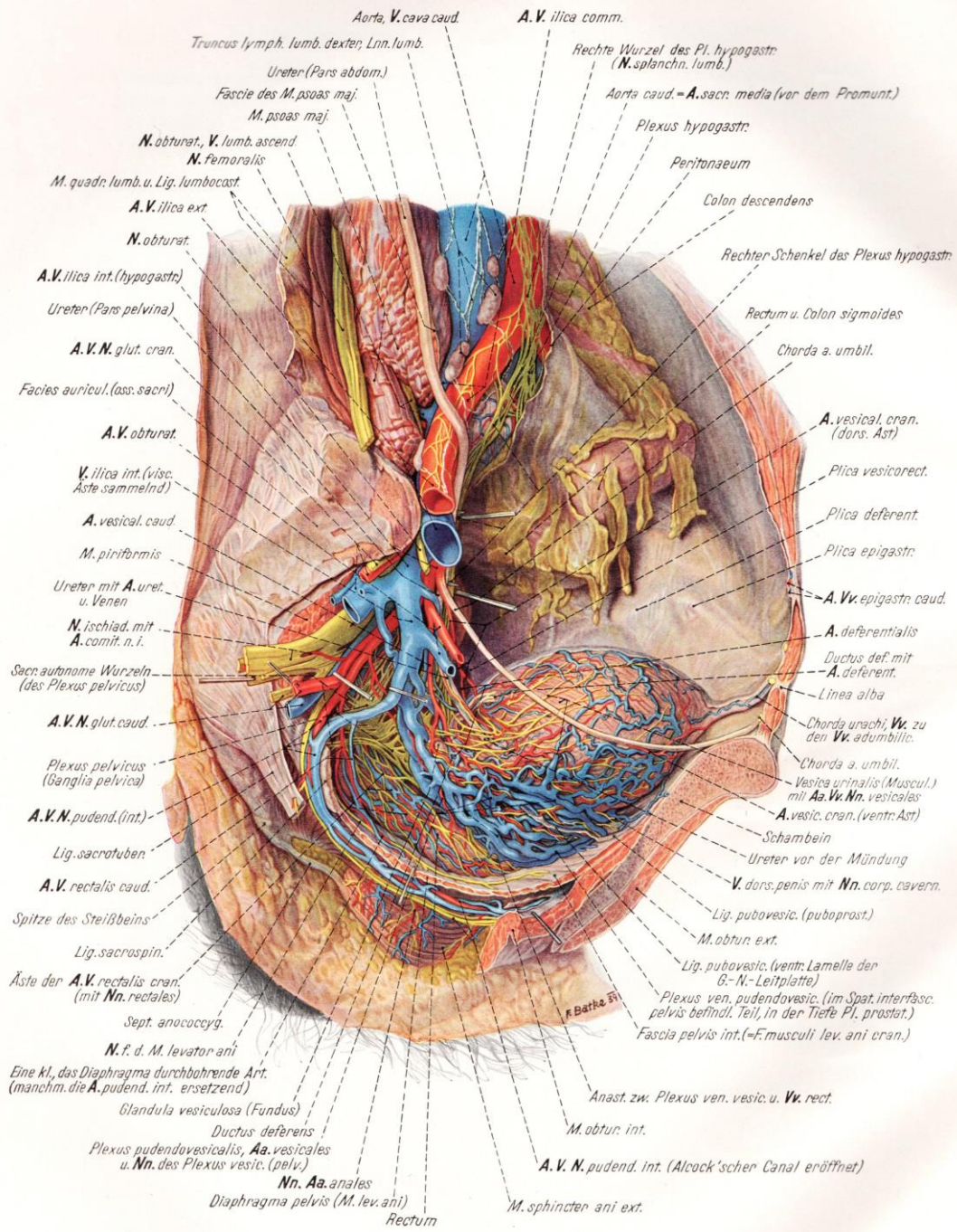
Querschnittanatomie des kleinen Beckens

Pernkopf



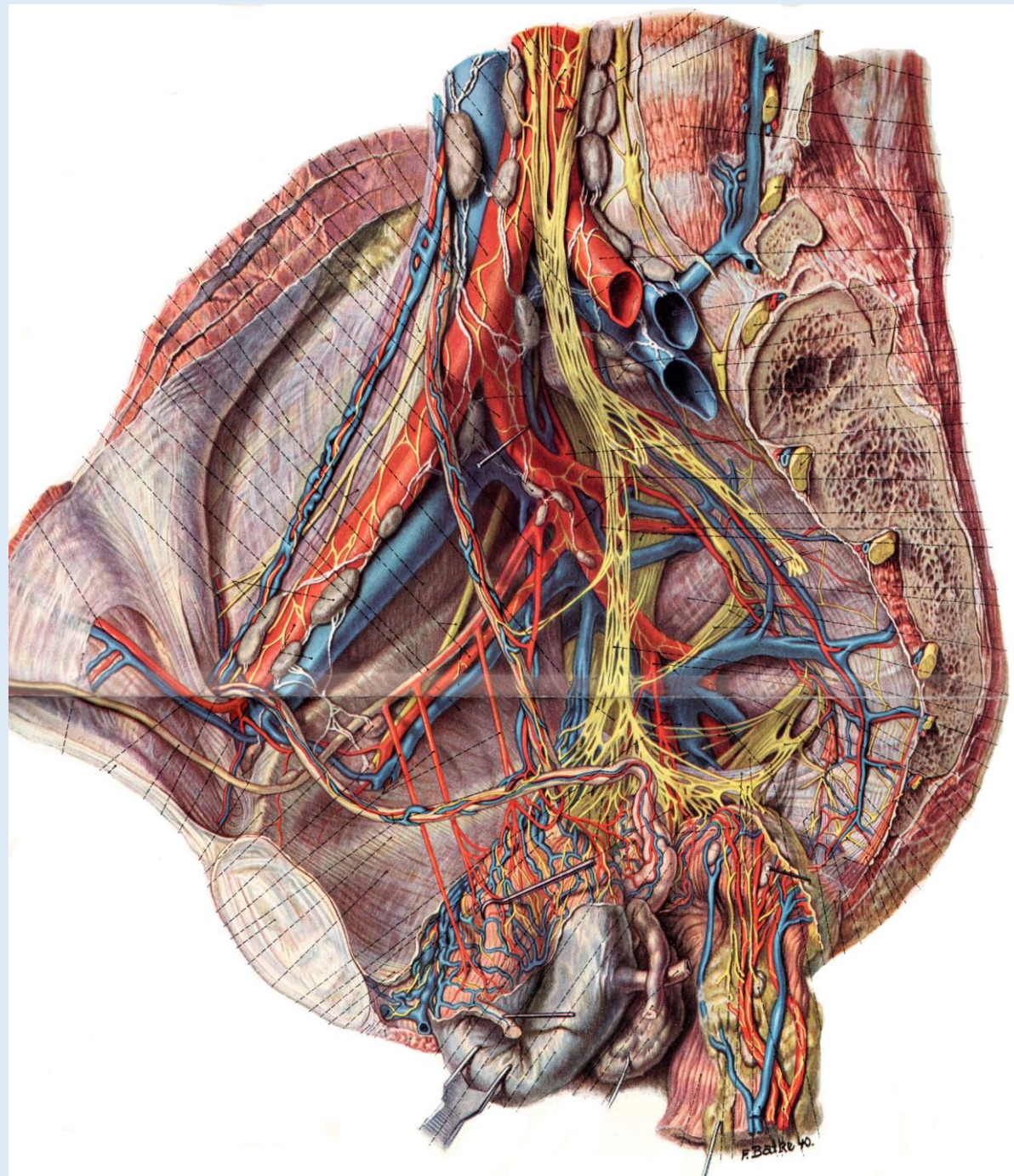
Querschnittanatomie des kleinen Beckens

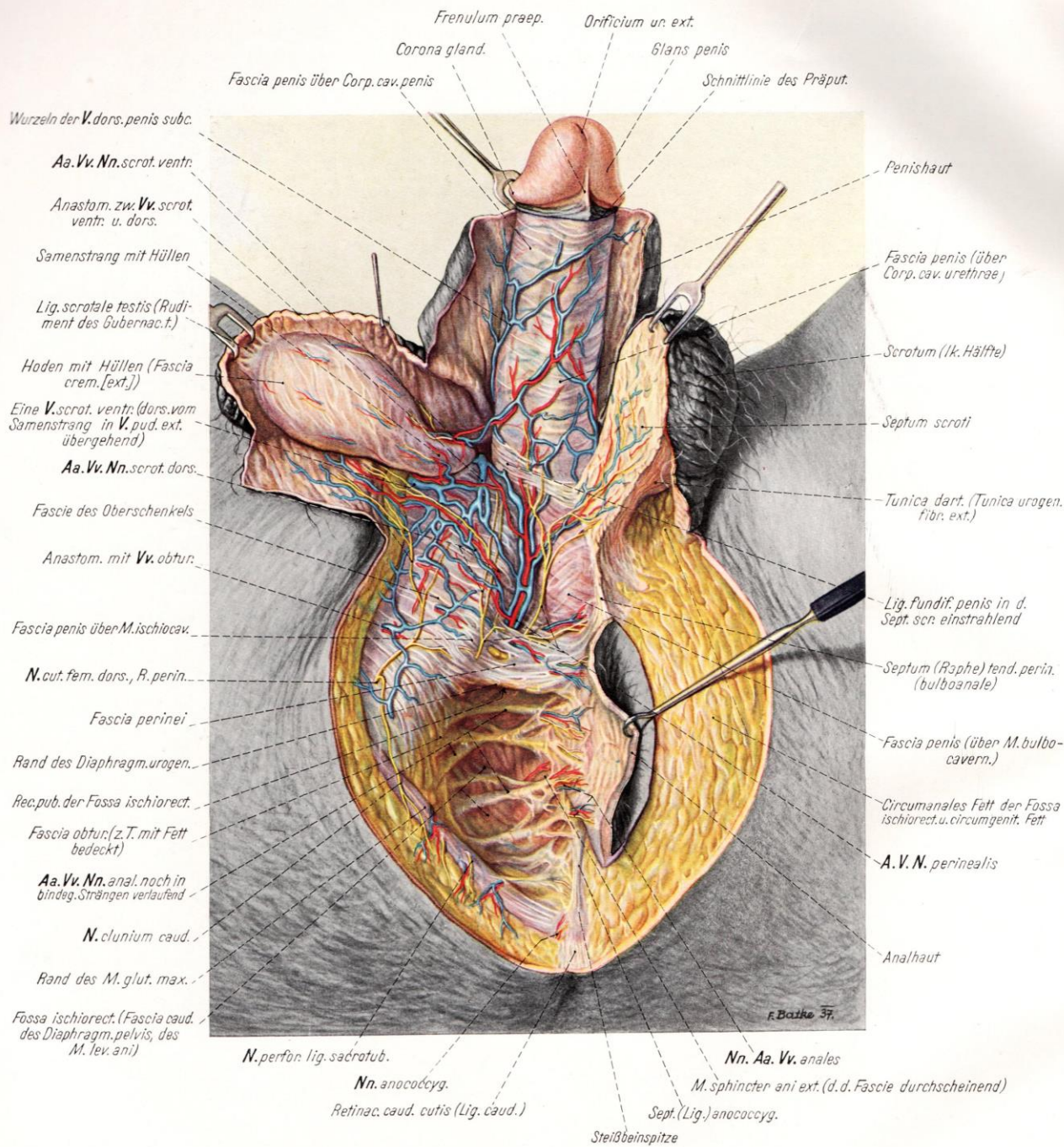




Paramedian-sagittaler Schnitt des kleinen Beckens

Gefäße und Nerven des Beckens



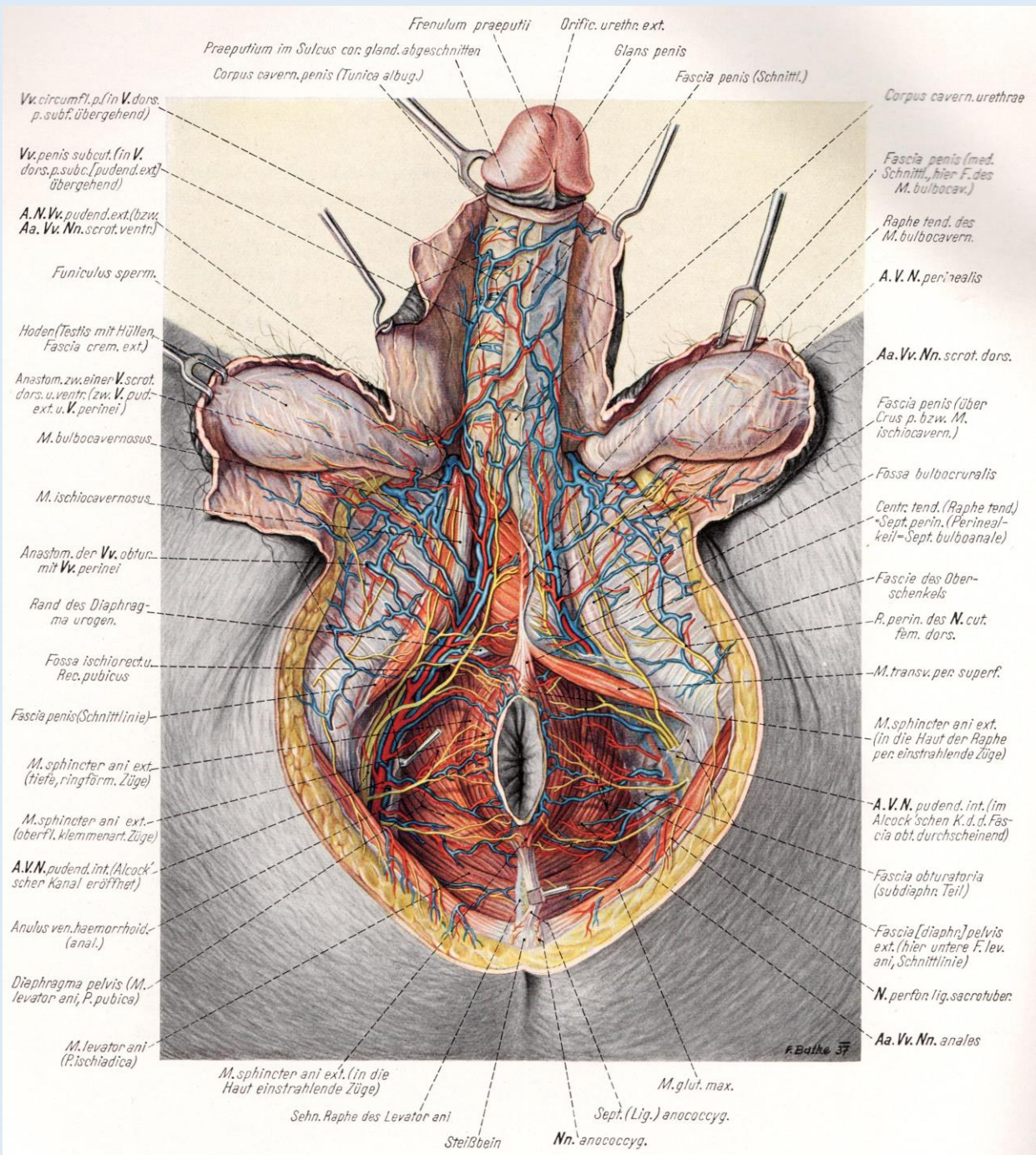


Oberflächenanatomie des männlichen Dammes

Arteria pudenda interna
ex Arteria iliaca interna

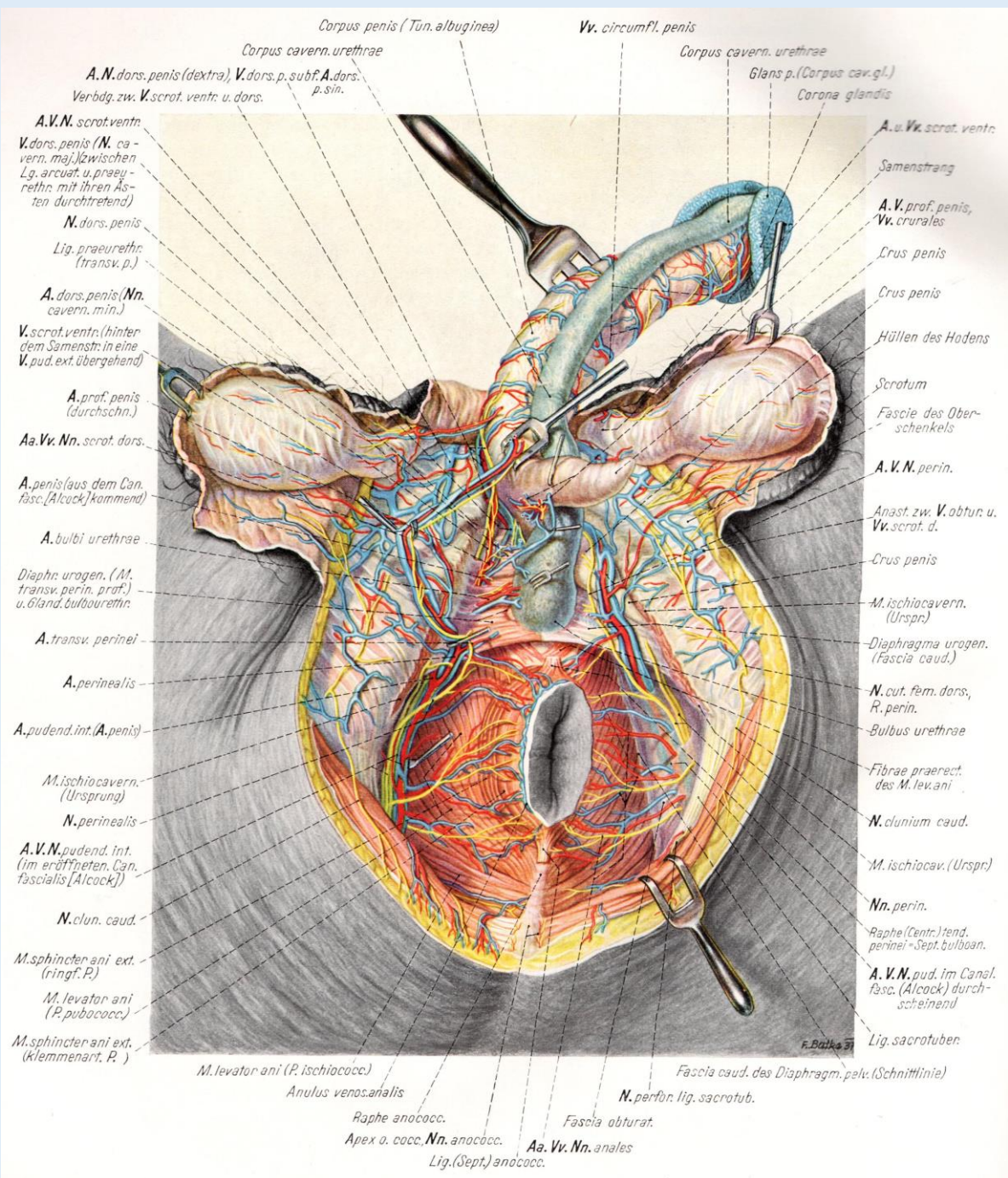
Nervus pudendus
ex Plexus pudendohaemorrhoidalis

Pernkopf

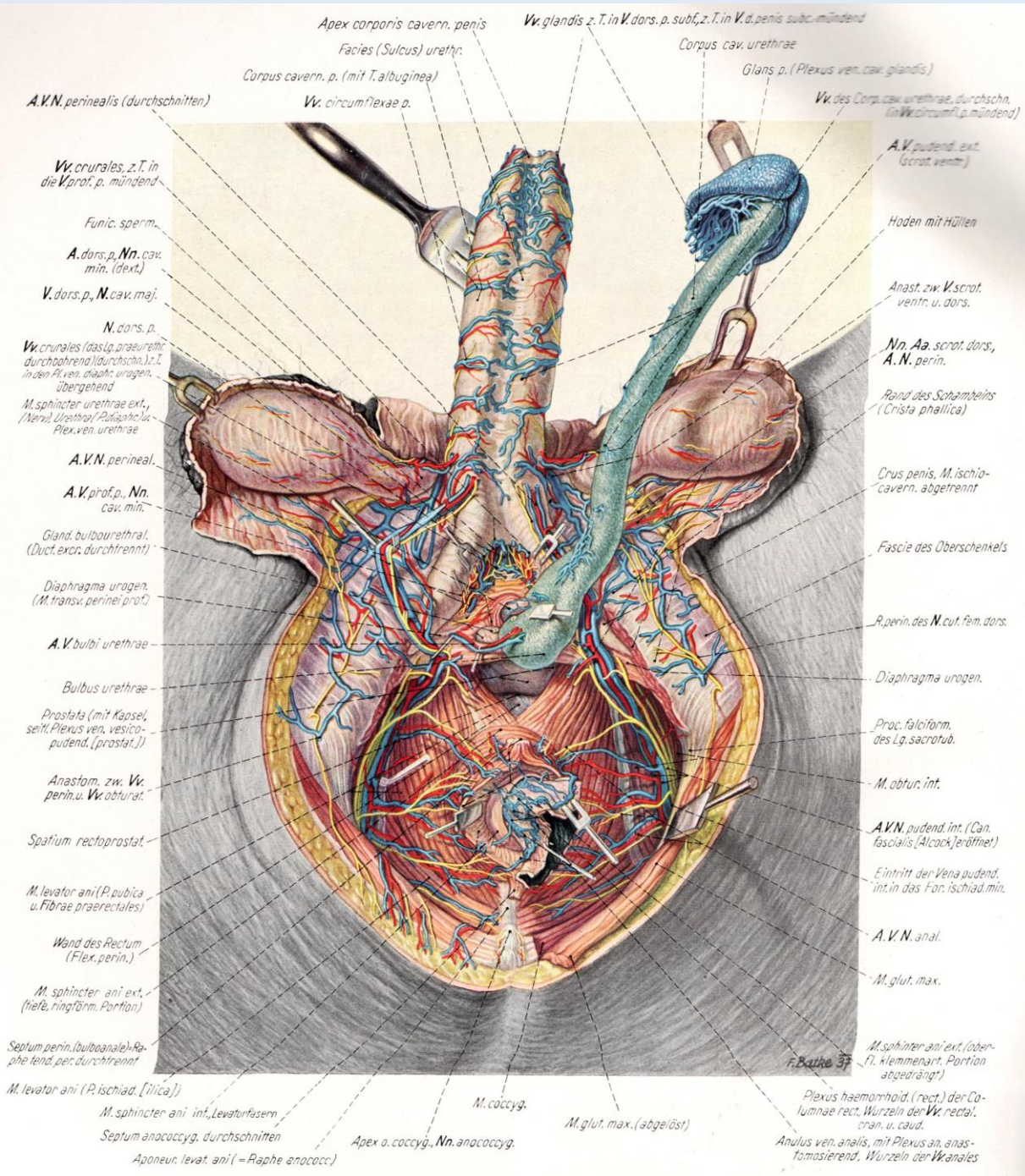


Oberflächenanatomie des männlichen Dammes

Alcock-Kanal



Oberflächenanatomie des männlichen Dammes



Oberflächenanatomie des männlichen Dammes