Histology of vascular system 2017

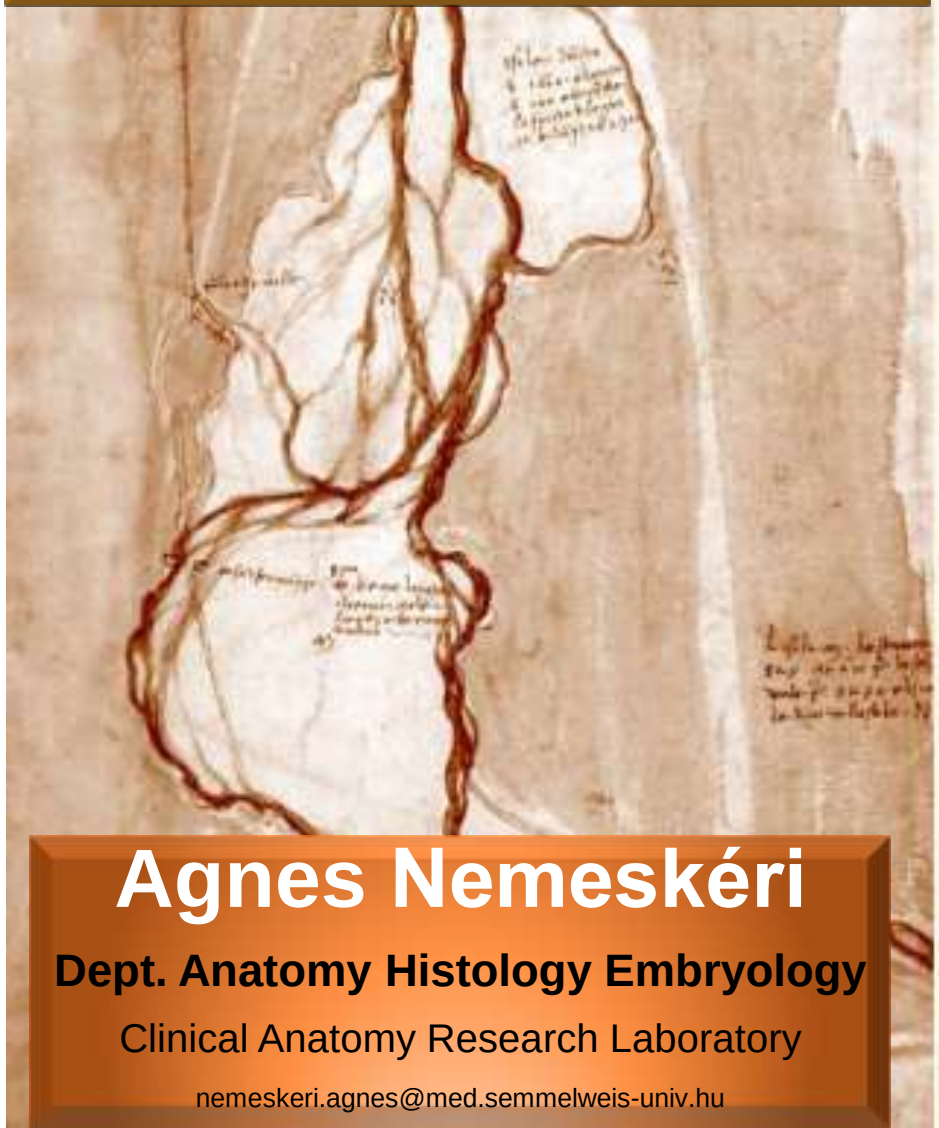

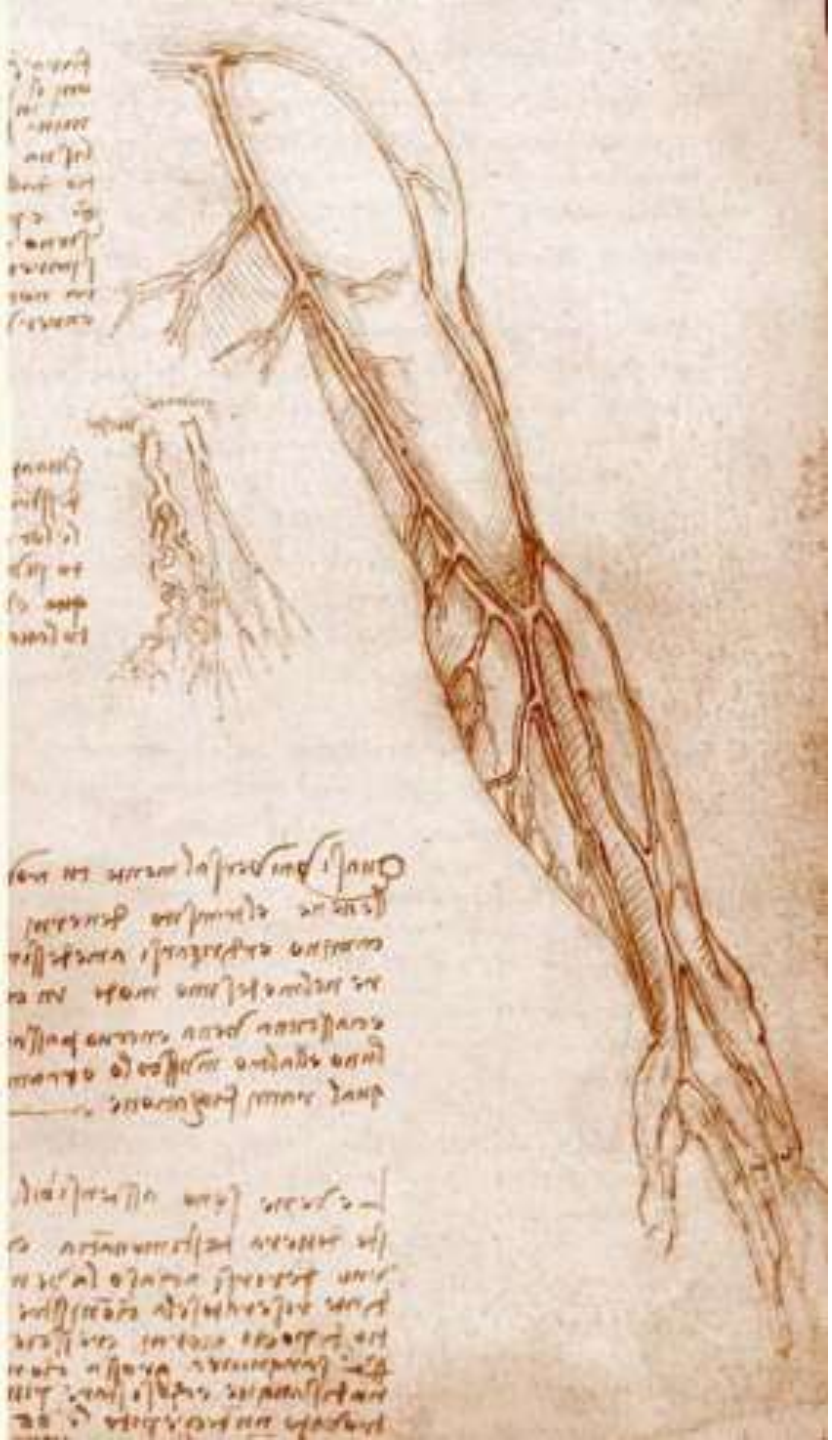

Agnes Nemeskéri

Dept. Anatomy Histology Embryology

Clinical Anatomy Research Laboratory

nemeskeri.agnes@med.semmelweis-univ.hu

Cardiovascular system

Heart

Blood Vessels

Arteries Veins

Lymphatic vessels

Transport system

- carries blood and lymph to and from the tissues of the body

General features of vascular system

Layers of vascular wall

three layers (tunics)

1.Tunica intima

a) endothelium
b) basal lamina
c) subendothelial layer

internal elastic membrane

2.Tunica media

vascular smooth muscle

external elastic membrane

3.Tunica adventitia

connective tissue

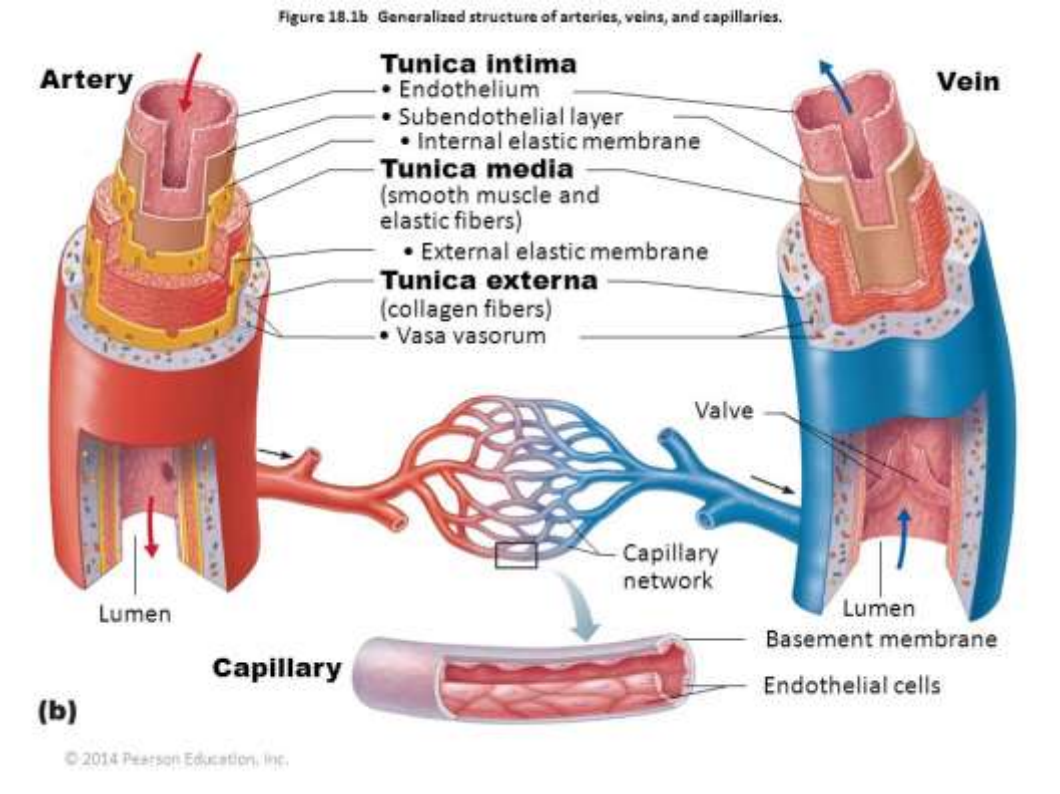

Vascular endothelium

Circulatory system of the body

- tubes lined by simple squamous epithelium

ENDOTHELIUM

- **flattened, elongated, polygonally shaped endothelial cells**
  – tight junctions

- their long axes are aligned in direction of the blood flow

- endothelial cells play an important role in blood homeostasis

- at luminal surface cells express surface adhesion molecules
  - low-density lipoprotein (LDL), insulin and histamine receptors

Advances in Physiology Education 2011 **Vol.** 35 **no.** 1, 5-15 **DOI:** 10.1152/advan.00074.2010

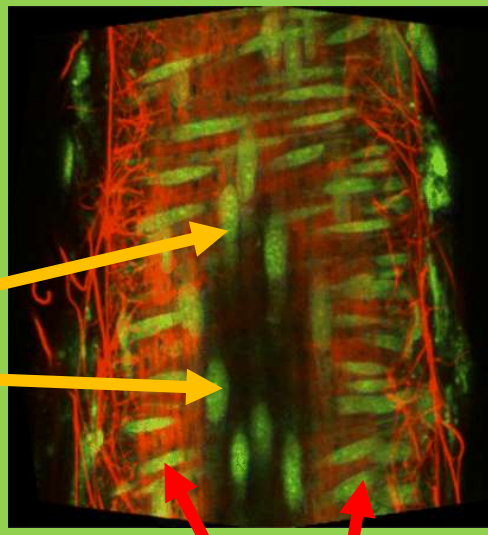

smooth muscle cells

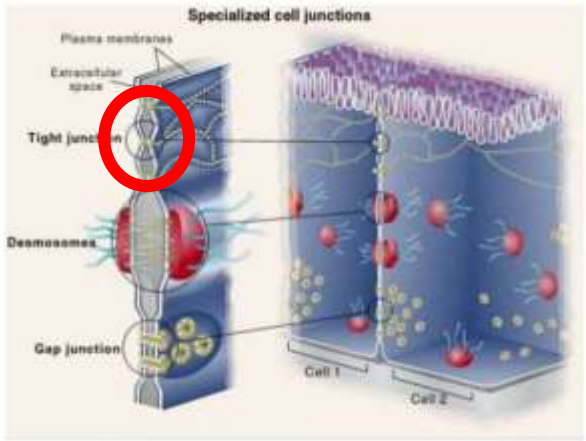

Endothelial cells

http://www.lab.anhb.uwa.edu.au/mb140/moreabout/MoAbPics/JMcGendo.jpg

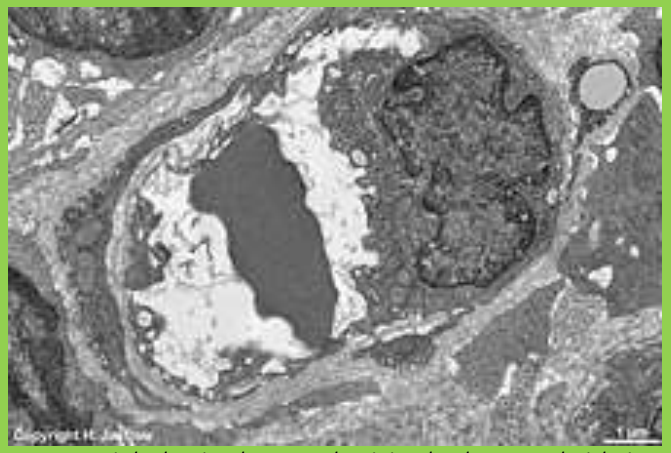

https://www.uni-mainz.de/FB/Medizin/Anatomie/workshop/EM/eigeneEM/Tph/Tph17Vck.jpg

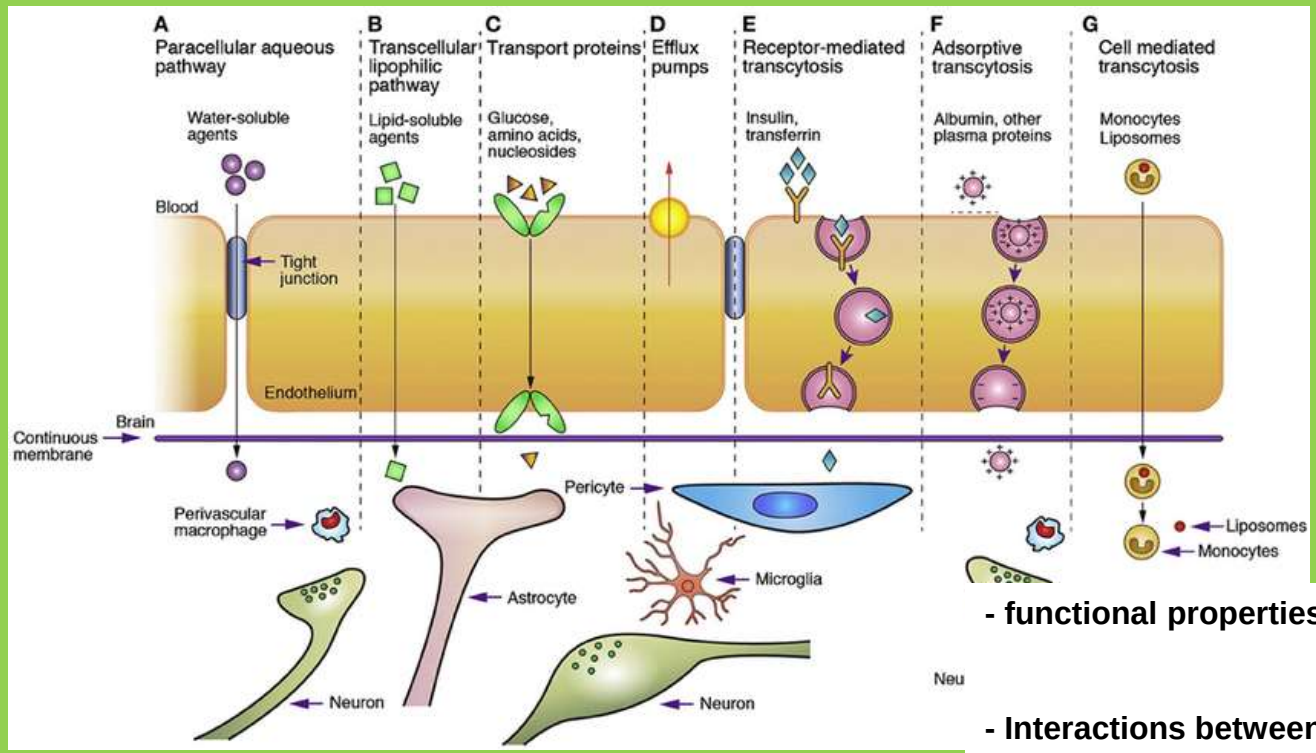

- functional properties change in response of stimuli

endothelial activation

- Interactions between blood and connective tissue

Endothelial cejt

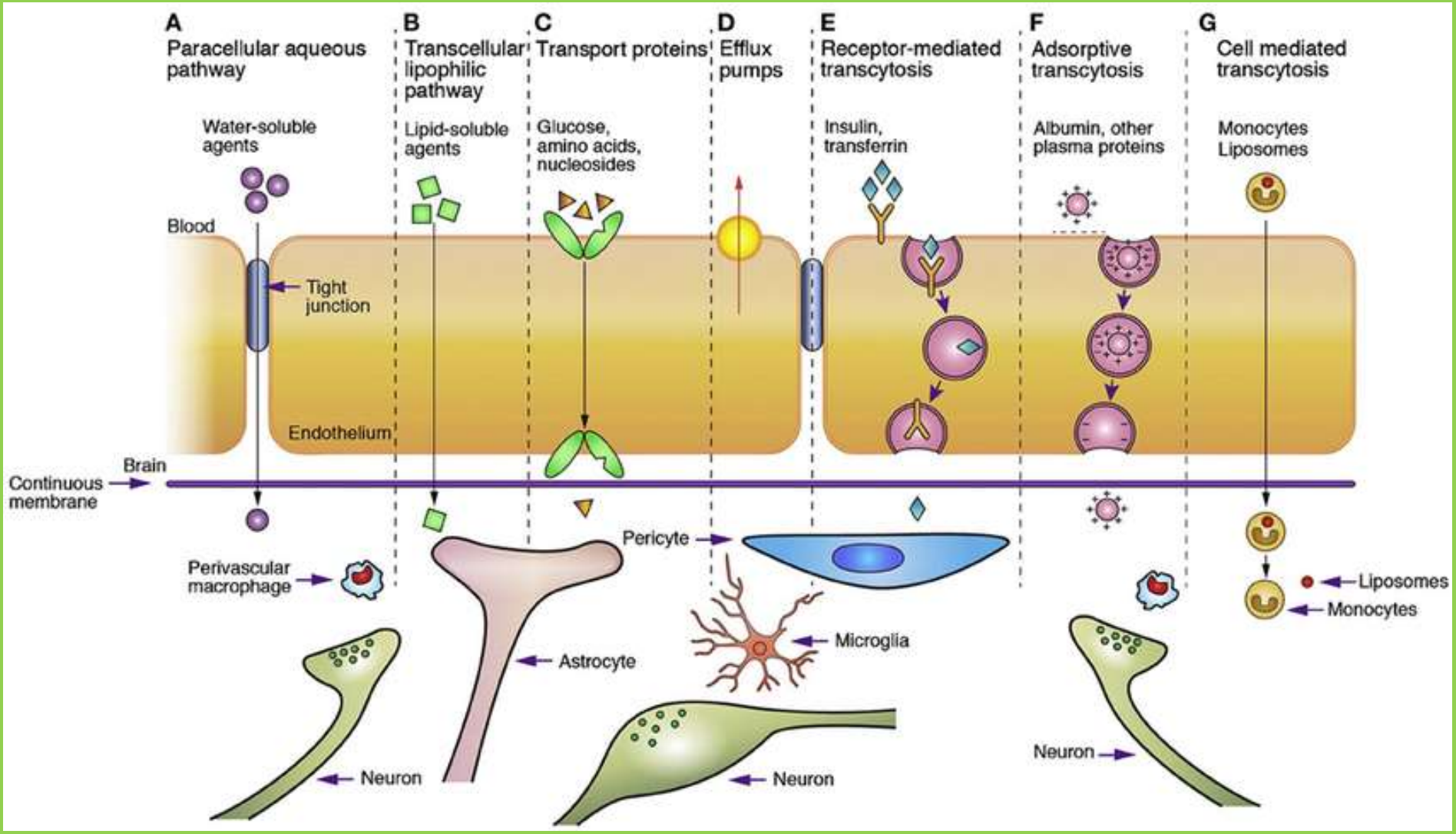

Endothelial cells

1. Maintenance of selective permeability barrier

- permeable to small hydrophobic molecules (oxygen, CO_2) – simple diffusion
- hydrophilic molecules (glucose, amino acids) do not diffuse passively
  - transcellular pathway
    - endocytosis
    - receptor-mediated endocytosis: cholesterol, transferrin
  - paracellular pathway
  - fenestrations

2. Maintenance of non-thrombogenic barrier

- production of anticoagulants (thrombomodulin)
- production of anti-thrombogenic substances that prevent platelet aggregation
- intact endothelium – no adherence of platelets
- injured endothelium releases pro-thrombogenic agents (Willebrand factor)

3. Modulation of blood flow and vascular resistance !!!!!!!!! local regulation

- secretion of vasoconstrictors (endothelin, angiotensin-converting enzyme)
- secretion of vasodilators (NO)

4. Regulation and modulation of immune response

- secretion of interleukins
- expression of adhesion molecules (interaction with lymphocytes)

5. Synthesis of growth factors and growth inhibitors

- hemopoietic colony-stimulating factors, fibroblast growth factor
- transforming growth factor

6. Modification of lipoproteins

- lipoproteins are oxidized by free radicals produced by endothelial cells

Diagrammatic representation of the molecular basis underlying the sequential steps in leukocyte recruitment to sites of inflammation

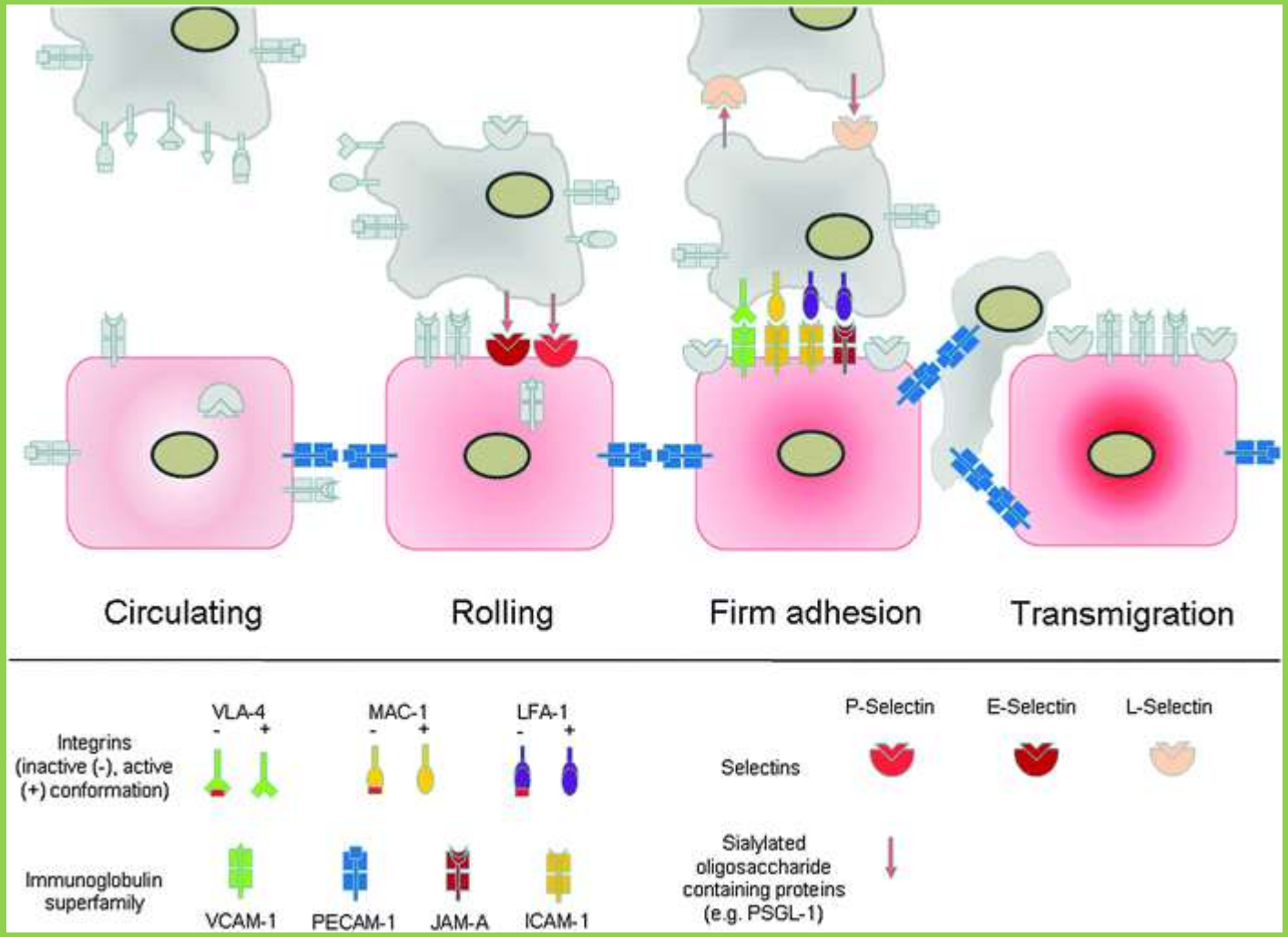

http://pubs.rsc.org/services/images/RSCpubs.ePlatform.Service.FreeContent.ImageService.svc/ImageService/Articleimage/2010/IB/c0ib00022a/c0ib00022a-f1.gif

Arteries

3 types according to the size and characteristics of t. media

Large arteries (elastic arteries)

Medium arteries (muscular arteries)

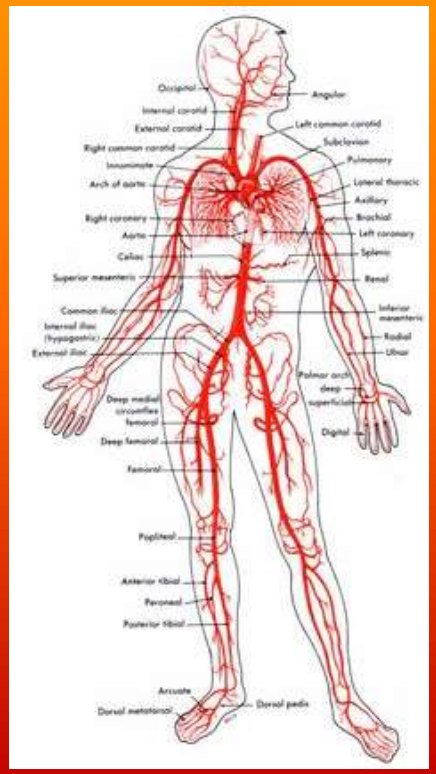

Small arteries and arterioles

Large or elastic arteries

- elastic fibers: 2 components
  - central core of elastin (protein)
  - surrounding network of fibrillin microfibrils (glycoprotein)

ELASTIN forms fibers of variable thickness
or
lamellar layers
- during elastogenesis absence of fibrillin microfibrils

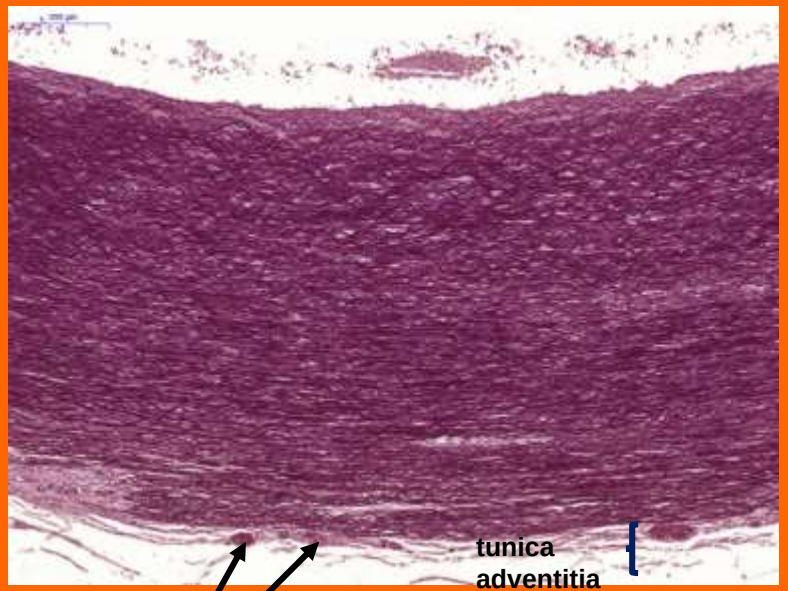

vasa vasorum

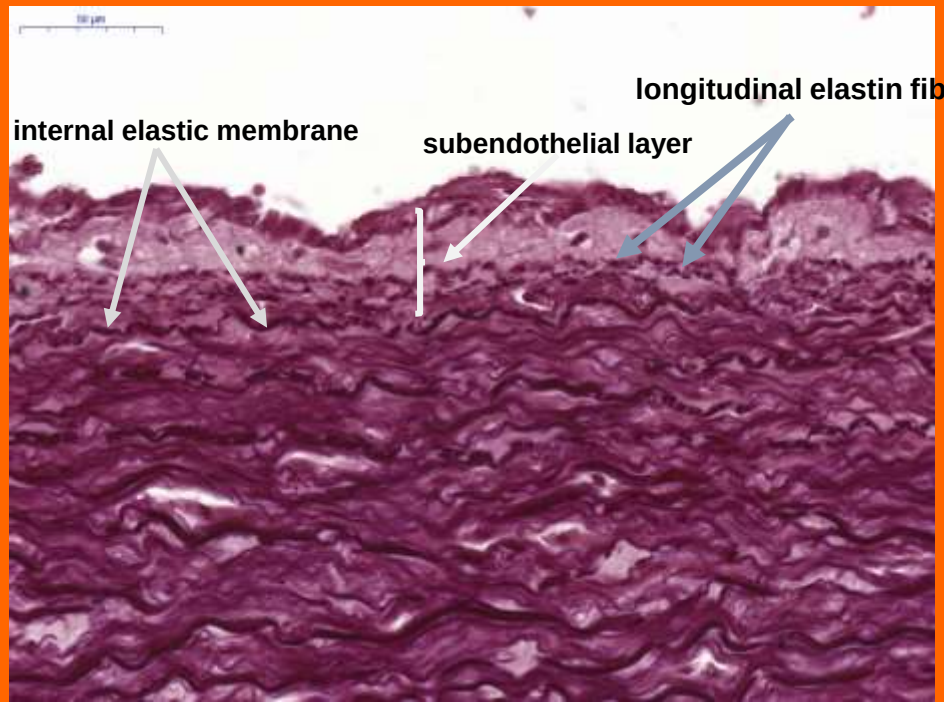

tunica intima - endothelium and basal lamina:
simple squamous epithelial cells joined by tight junctions
pinocytotic transport across membrane
- subendothelial connective tissue containing: elastin and collagen fibres

smooth muscle cells and occasional fibroblasts
-longitudinally oriented elastin fibres
-internal elastic lamina

tunica media - broad and elastic with
- concentric **fenestrated sheets of elastin** – 2-3 µm
- collagen
- relatively **few smooth muscle cells**
- **no fibroblast!**

Large or elastic arteries (conducting arteries)

- functional and morphological properties of elastic and muscular arteries differ considerably
- elastic arteries, such as the aorta and the carotid artery, contain **more elastin** per unit area
- important **pulse-smoothing properties** of the pressure wave originating in the left ventricle
- progressive **large artery stiffening with aging** is predominant cause of increased pulse pressure, a marker of cardiovascular risk in the general population

Leloup et al. Elastic and Muscular Artery Function Frontiers in Physiology 2015

Tunica intima:

- **endothelium** and **basal lamina**:
  - simple squam. epithelial cells (tight junctions)
  - pinocytotic transport across membrane
  - **subendothelial connective tissue** containing:
    - **elastin** and **collagen fibres**
    - **smooth muscle cells** and fibroblasts
  - longitudinally oriented elastin fibres
  - **internal elastic lamina**

Tunica media

- ~50 sheets of interconnected fenestrated **elastic laminae** arranged in a concentric, coiled manner
- between each sheet (5-20 μm) is a layer of **smooth muscle cells**:
  - spiral in wall of vessel
  - smooth muscle cells connected via gap junctions
  - secrete elastin and collagen fibres (types I,III and IV)

Tunica adventitia:

- thinnest of the layers
- greater proportion of **collagen fibres** in deference to elastin fibres; probably an adaptation to prevent over-distention of the vessels wall
- cellular elements include **macrophages** and **fibroblasts**
- **vasa vasorum** pass along this layer:
  - vascular supply to the outer layers of the artery send perforating branches in to the tunica media and the subendothelial layer
- nervi vasorum

http://www.gpnotebook.co.uk/simplepage.cfm?ID=778764346

Elastic arteries

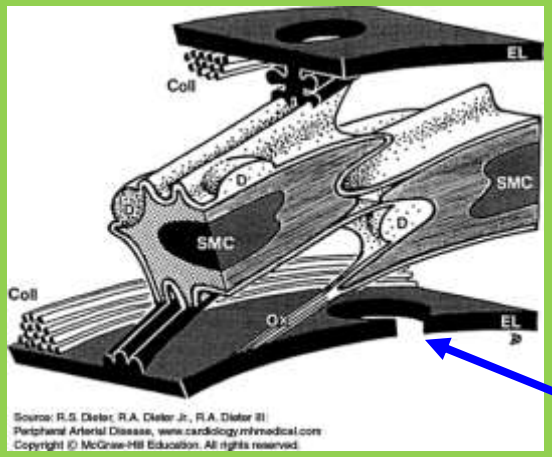

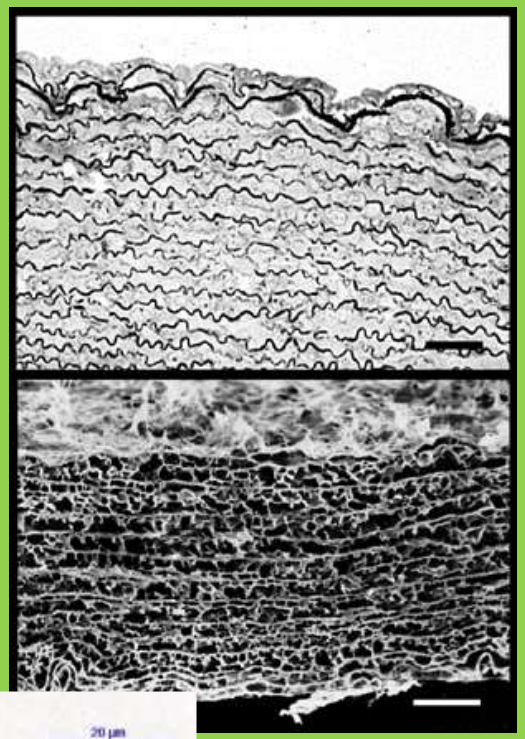

Fenestrations of elastic laminae

- facilitates diffusion

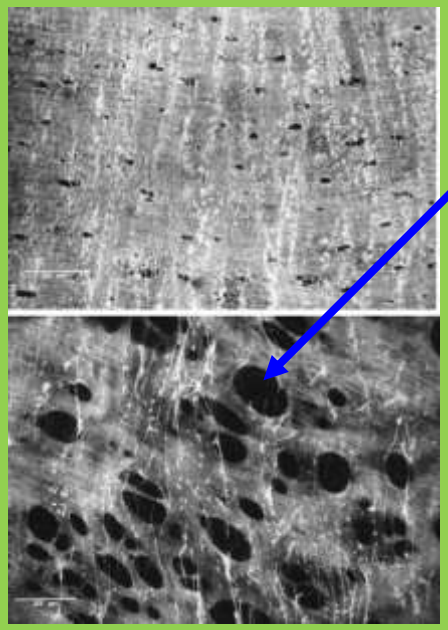

Lisa C. Y. Wong, and B. Lowell Langille
Circ Res. 1996;78:799-805

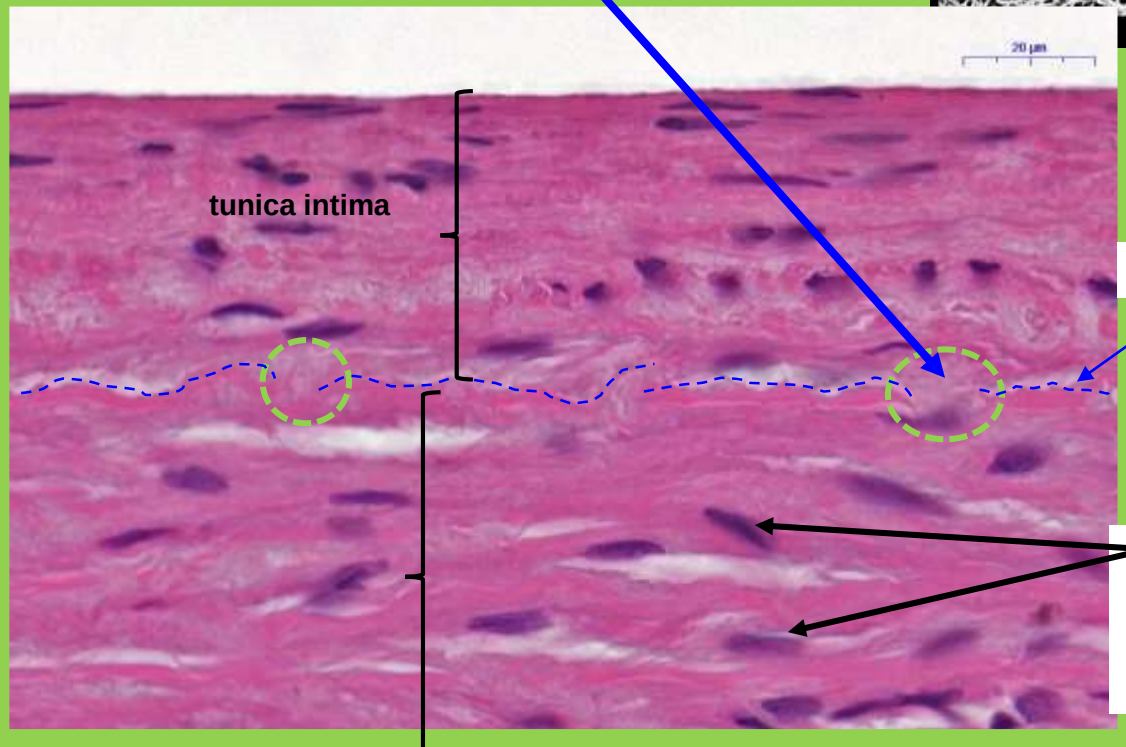

internal elastic lamina

vascular smooth muscle cells in spiral way

- synthesize collagen, elstin, ECM

Muscular arteries

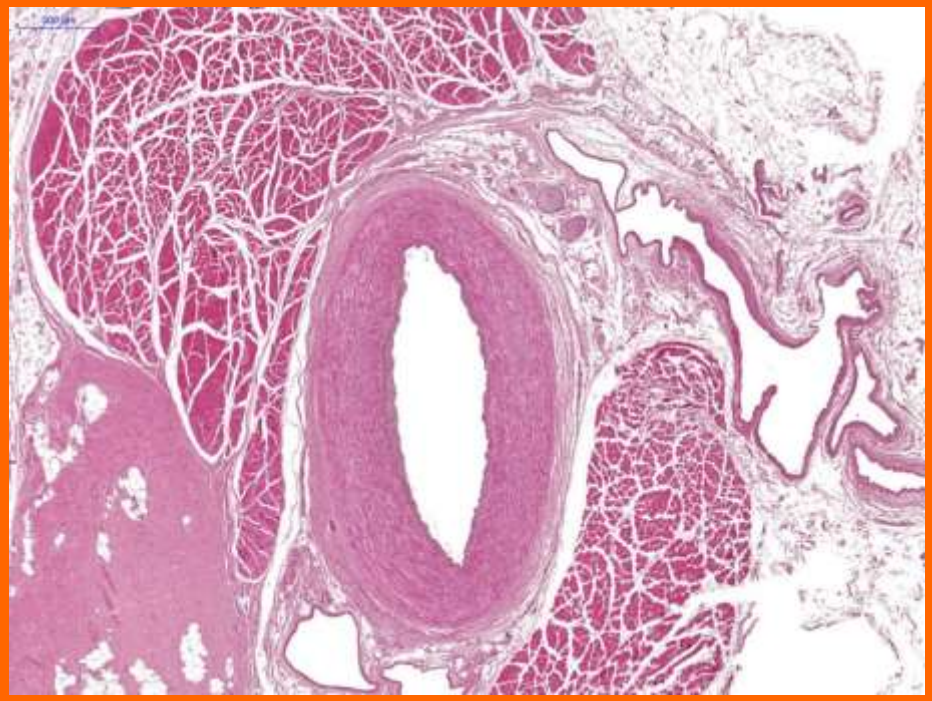

lingual artery (human)

Muscular arteries (distributing arteries)

- femoral, brachial, external carotid, tibial, mesenteric arteries have a relatively **higher smooth muscle** to elastin content
- distribute blood according to moment-to-moment needs
- are more capable of **vasoconstriction** and **dilation**
- prominent internal elastic membrane
- well visible external elastic membrane

Tunica intima

- thinner, sparse subendothelial connective tissue
- some longitudinally oriented smooth muscle cells
- prominent **internal elastic membrane** wavy structure (contraction of smooth muscle)

Tunica media

- vascular smooth muscle cells, arranged **spiral manner** larger muscular arteries:10 to 40 layers of smooth m. cells
- in smaller muscular arteries: 3 to 10 layers
- little elastic material
- collagen fibers
- **no fibroblasts**
- smooth muscle cells produce collagen, elastin, ground substance
- smooth m. cells – surrounded by basal lamina – except at the sites of gap junctions
- often external elastic lamina

Tunica adventitia

- relatively thick
- firoblasts, elastic fibers, scattered adipocytes
- in large muscular arteries vasa vasorum, nervi vasorum

Small muscular artery and arteriole

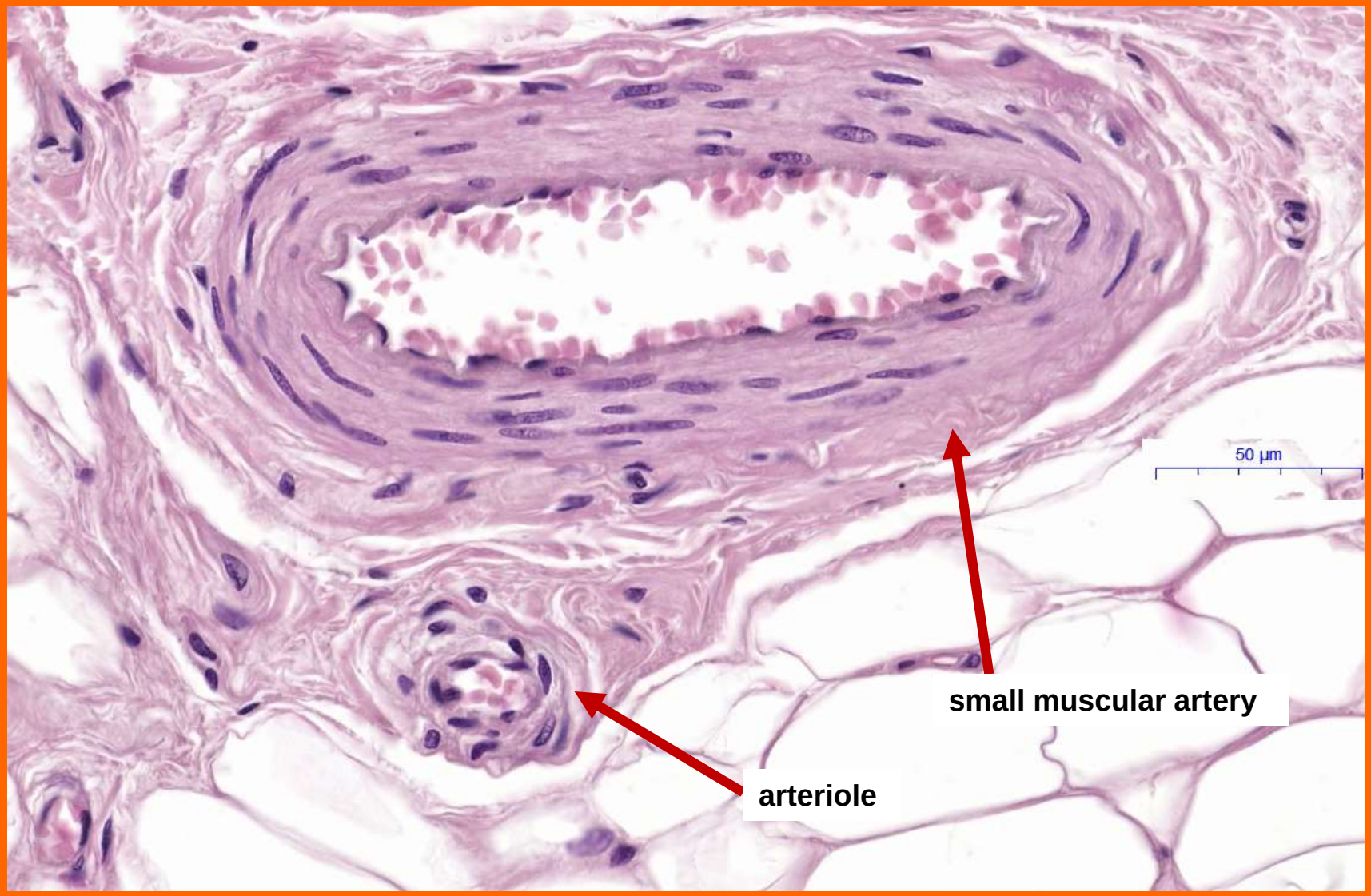

Arteriole: 1 or 2 layers of smooth muscle cells

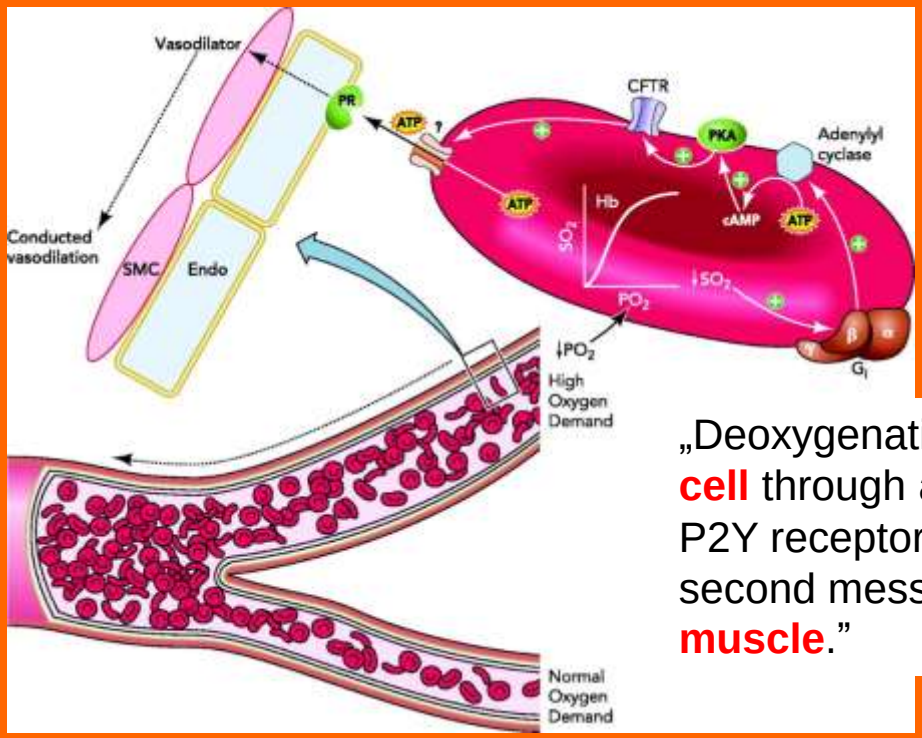

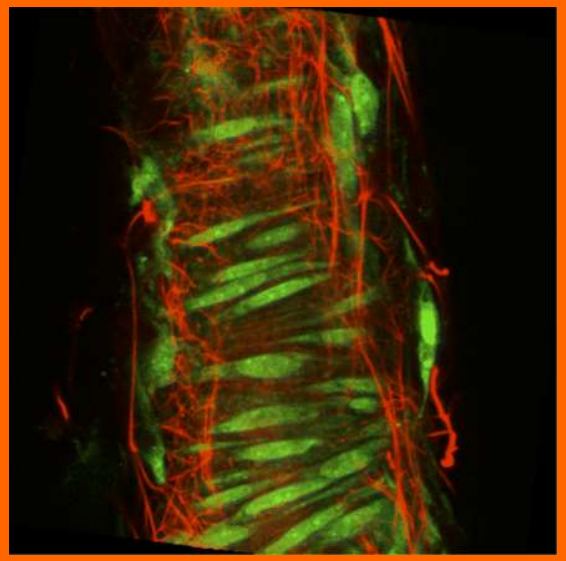

„Deoxygenation causes release of ATP from **red blood cell** through a process linked to G proteins. ATP acts at P2Y receptors on the **endothelium**, which release a second messenger to cause the relaxation of **smooth muscle**."

Advances in Physiology Education 2011 **Vol.** 35 **no.** 1, 5-15 **DOI:** 10.1152/advan.00074.2010

„Local arteriolar diameter influences **organ blood flow** and systemic **blood pressure**.

All cell types in the blood vessel wall can affect vessel diameter.
The influence of local control mechanisms (including myogenic, metabolic, flow-mediated, and conducted responses) varies over time, from tissue to tissue, and among vessel generations."

Arterioles

http://www.histology.leeds.ac.uk/circulatory/assets/Arteriole_TEM.jpg

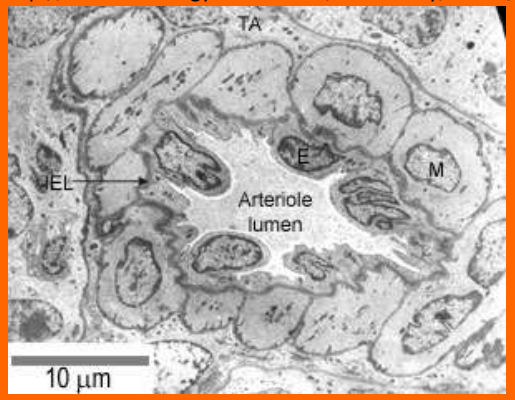

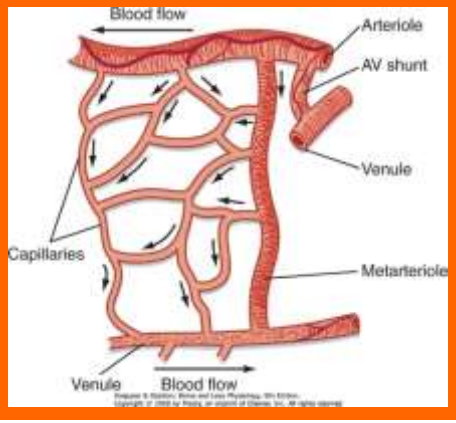

Tunica intima
- subendothelial layer is lacking
- only **endothelium**
- occasionally fenestrated internal elastic lamina
- in terminal aterioles internal elastic lamina disappears

Tunica media
- variable thickness
- 1 or 2 layers of smooth muscle cells
- few muscle layers

Tunica adventitia
- no definite external elastic membrane
- decreases

Compared to lumen the wall is thick

Gap junction between the endothelium and smooth muscle cells

- **terminal arteriole – metarteriole (10-20 µm)**
  - **do not have continuous media**
  - **– precapillary sphincter 1 separate smooth muscle cell**

Arterioles control the flow of blood into capillary bed
- **diameter: less than 100 µm**
- **they are primary regulators of blood pressure !!!!**

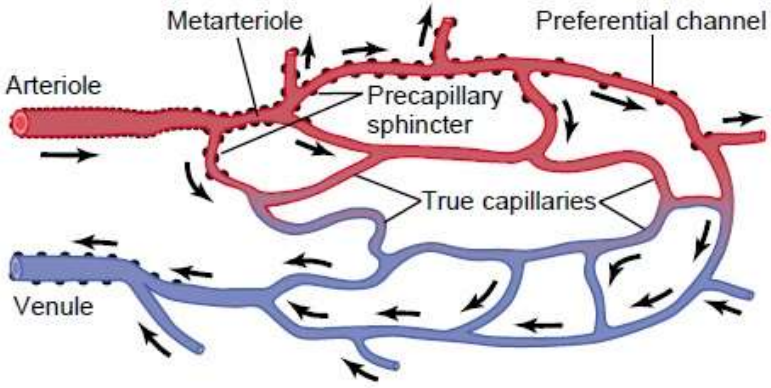

Figure 16–1

Structure of the mesenteric capillary bed. (Redrawn from Zweifach BW: Factors Regulating Blood Pressure. New York: Josiah Macy, Jr., Foundation, 1950.)

The muscular arterioles are the primary sites of **peripheral resistance** (PR), which affects blood pressure - local regulation

Capillaries

true capillary

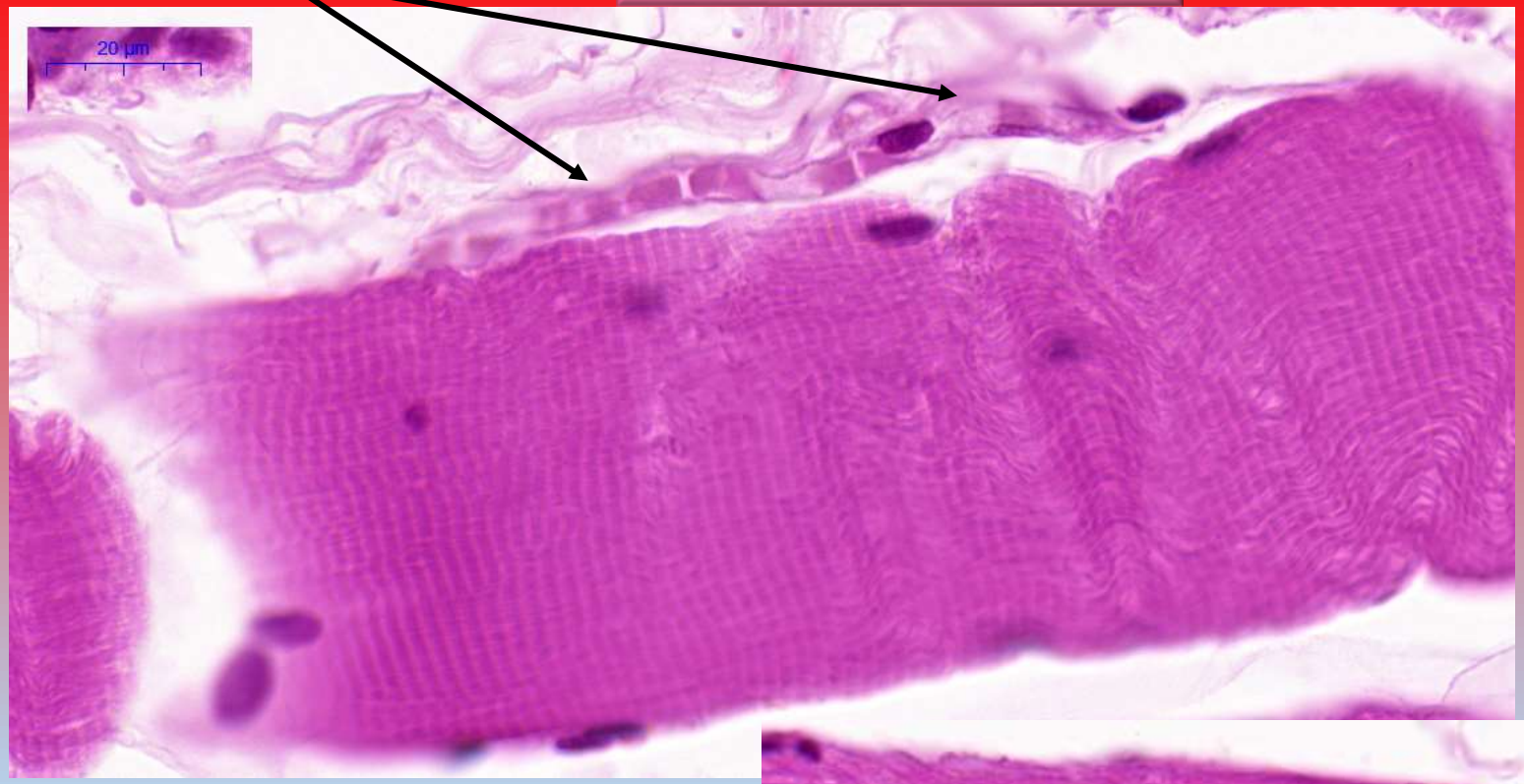

post-capillary pericytic venule

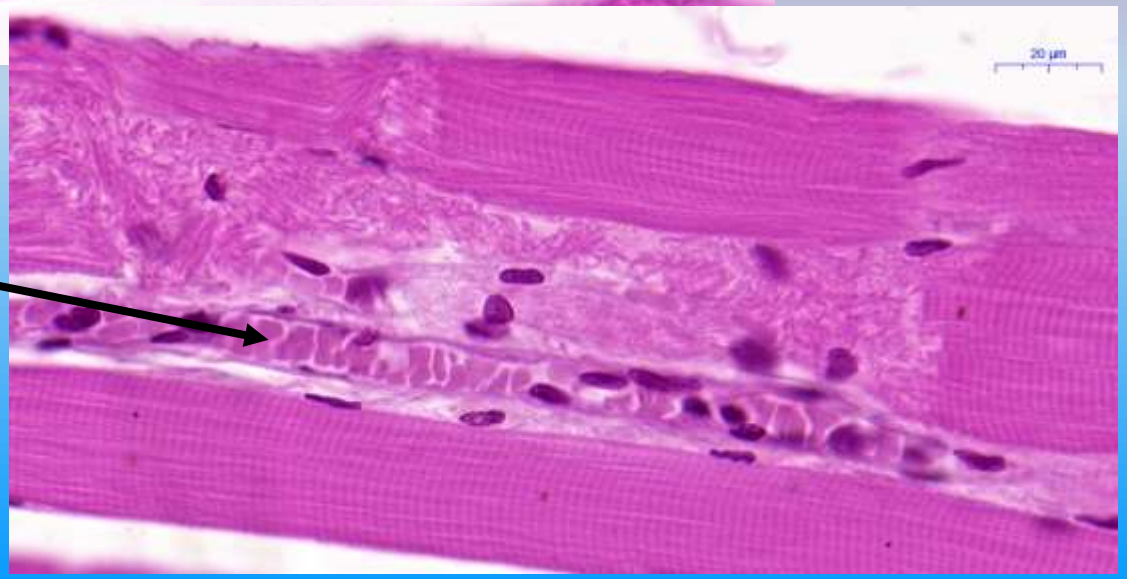

Capillaries

- vessels of small diameter (4 to 10 microns)
- endothelium surrounded by a basement membrane, a few pericytes, and connective tissue
- 3 different types of capillaries can be resolved based on the morphology of their endothelial layer:

1. <u>Capillaries with a continuous endothelium</u>

   - less permeable and are present in muscles, lung, connective tissue, and skin.

2. <u>Capillaries with a fenestrated endothelium</u>

   - gaps between endothelial cells, basement membrane is continuous
   - in renal glomeruli, endocrine glands, intestinal villi, and exocrine pancreas

3. <u>Capillaries with a discontinuous endothelium</u>

   - large gaps between cells, a discontinuous basement membrane
   - capillaries are called sinusoids
   - in liver, in blood-forming and lymphoid organs

http://www.columbia.edu/
itc/hs/medical/sbpm_histology_old/micrographs/47.jpg

http://medcell.med.yale.edu/
histology/blood_vessels_lab.php

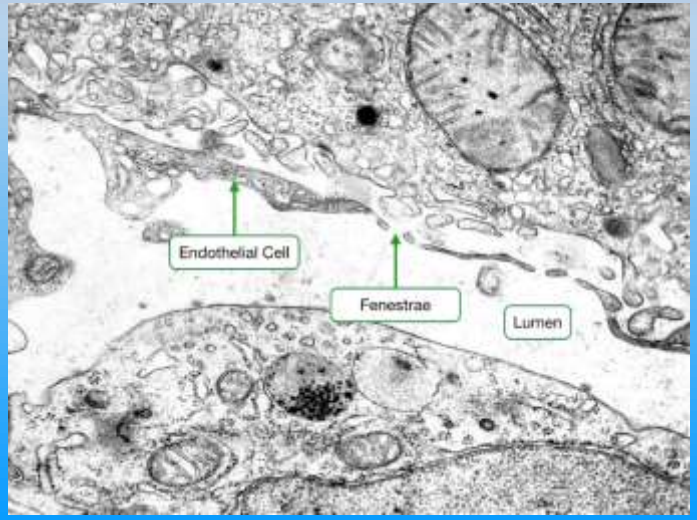

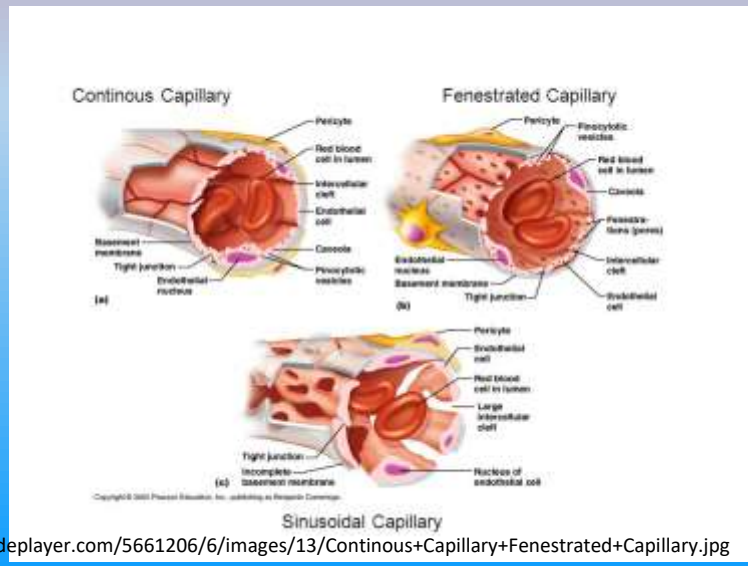

http://slideplayer.com/5661206/6/images/13/Continous+Capillary+Fenestrated+Capillary.jpg

Capillary - Pericyte

- present in microvessels: capillaries, postcapillary venules, and terminal arterioles

- pericytes are in close contact with endothelial cells
- extend long cytoplasmic processes across several Endothelial Cells to encircle the vascular tubes

- they share a basement membrane and physically interact via numerous contacts such as for example **peg-socket junctions**, **adhesion plaques**, or **gap junctions**
- **- pericyte is required for stabilization of the endothelium and for regulation of blood flow**

Dysfunctional interplay between pericytes and the endothelium:
- cause or consequence of many diseases resulting in **increased vascular permeability,** inflammation
- cancer cells, for instance, can induce **detachment of pericytes** from quiescent vasculature

- pericyte is required for stabilization of the endothelium and for regulation of blood flow

- at peg and socket sites, gap junctions can be formed which allow the pericytes and neighboring cells to exchange ions and other small molecules.
- molecules in these intercellular connections include N-cadherin, fibronectin, connexin and various integrins

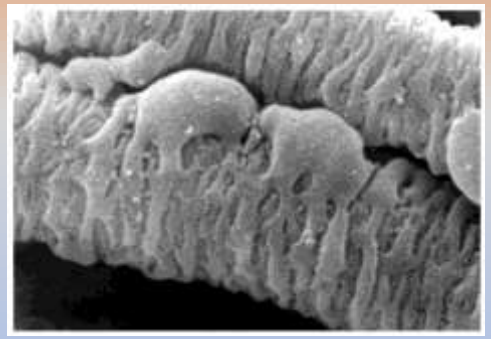

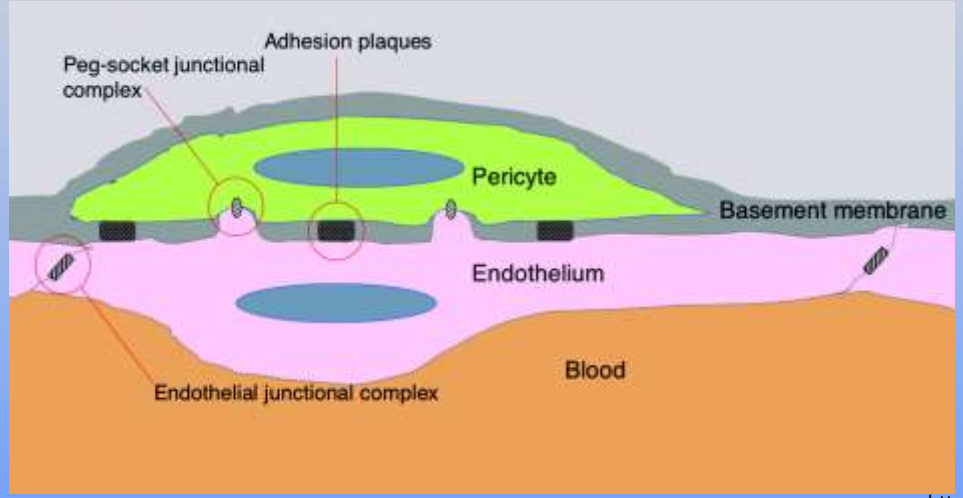

http://circres.ahajournals.org/content/circresaha/97/6/512/F1.large.jpg

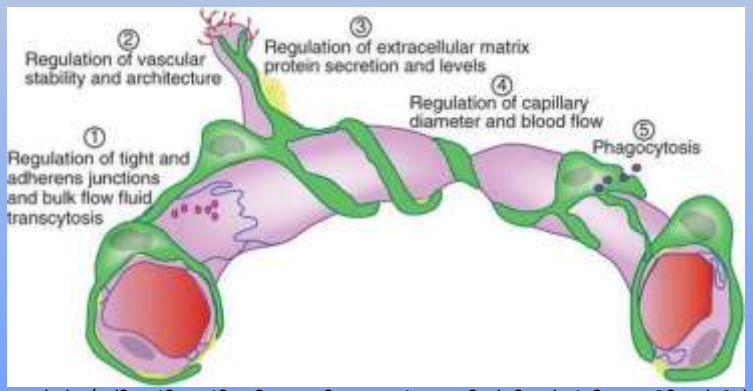

https://www.google.hu/url?sa=i&rct=j&q=&esrc=s&source=images&cd=&cad=rja&uact=8&ved=0ahUKEwi37bfCwbzXAhWHo6QKHdZsCVUQjRwIBw&url=http%3A%2F%2Fwww.writeopinions.com%2Fpericytes&psig=AOvVaw0OeBK2CaUeoK2Wu1cr8GBJ&ust=1510695123373873

Pericyte functions and their contributions to wound healing

Angiogenesis

-Structural support of existing blood vessels
-Regulation of EC proliferation and migration to form new vessels
-Prevention of capillary tube regression by TIMP-3 expression
-Stabilisation of newly formed capillaries

Inflammation

-Regulation of vessel permeability
-Regulation of neutrophil extravasation
-Regulation of macrophage extravasation
-Control of leukocyte trafficking
-Control of T cell activation
-Response to inflammatory signals

Re-epithelialisation

-Regulation of keratinocyte migration

Fibrosis

-Production of collagen
-Differentiation into myofibroblasts

Tissue regeneration

-**M**esenchymal **S**tem **C**ell-like properties: differentiation potential includes adipocytes,osteoblasts, chondrocytes, phagocytes and granulocytes

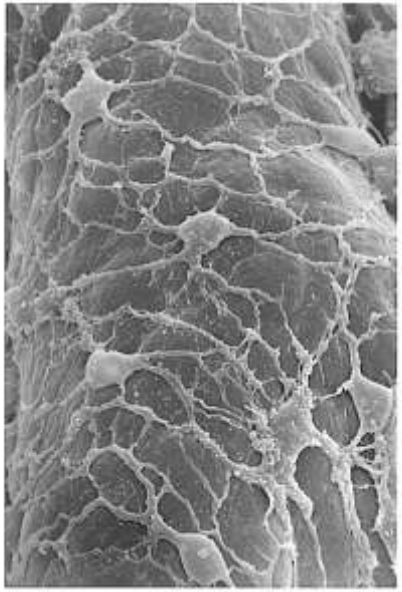

Pericyte

Anti-Actin, α-Smooth Muscle Actin

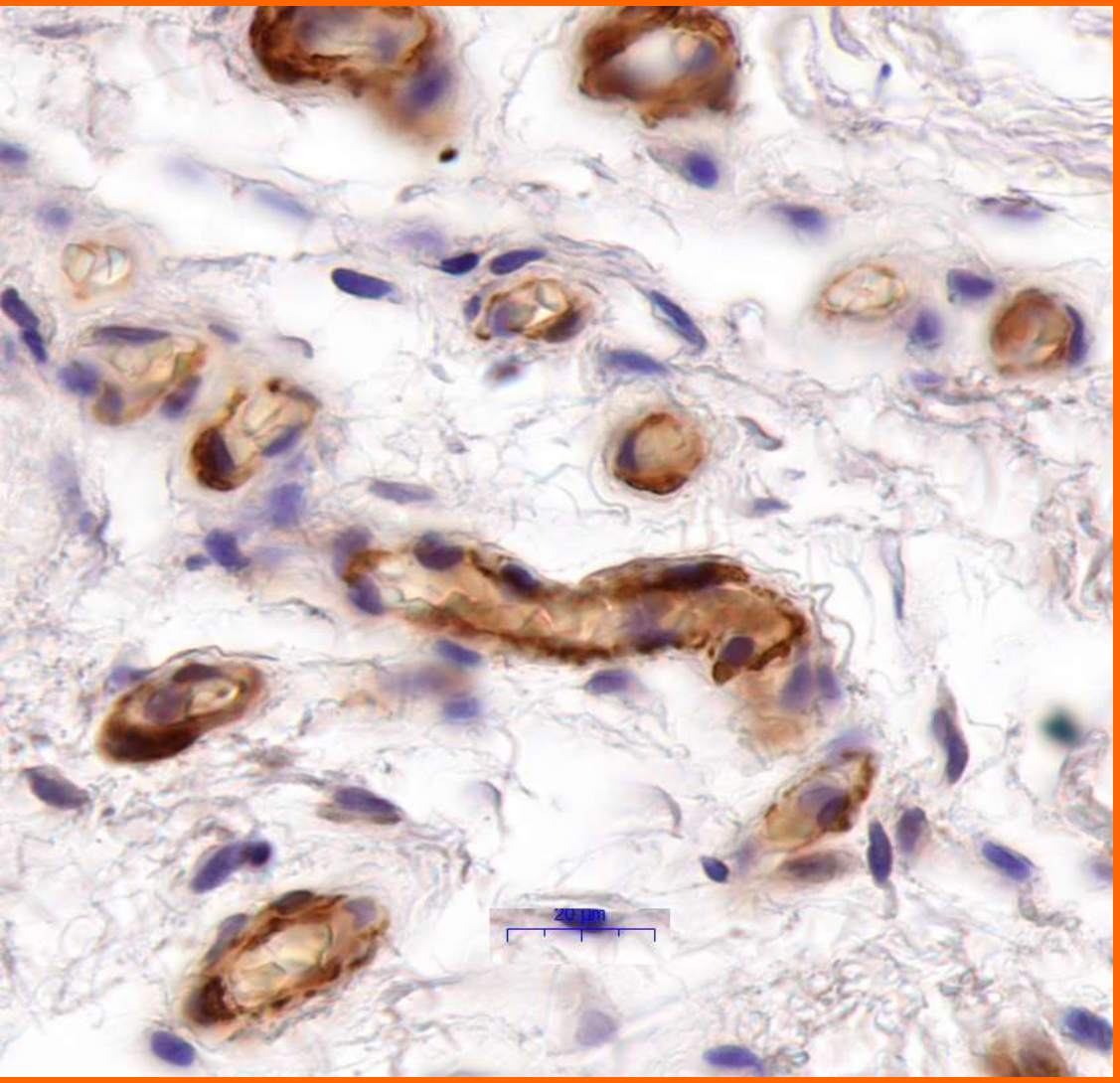

- contractile cells

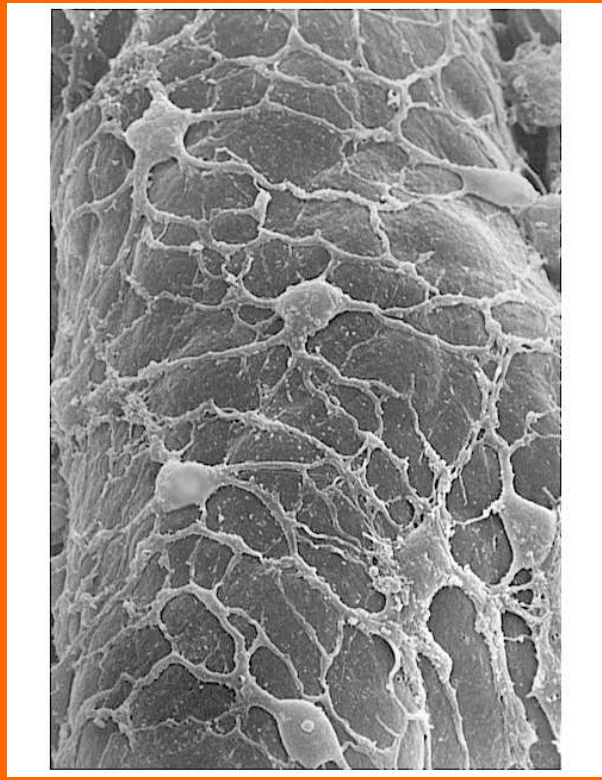

Capillary bed

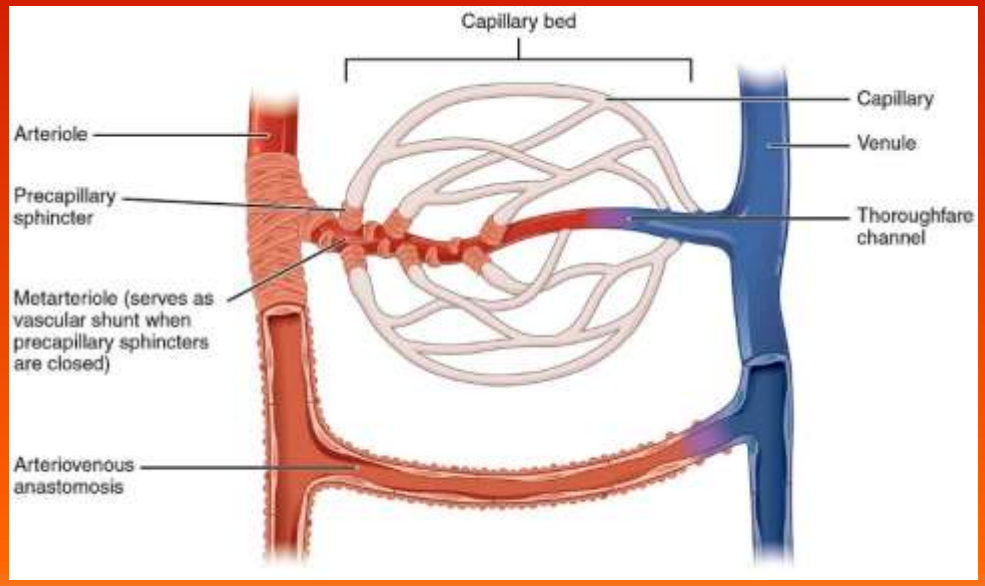

https://upload.wikimedia.org/wikipedia/commons/thumb/4/49/2105_Capillary_Bed.jpg/1200px-2105_Capillary_Bed.jpg

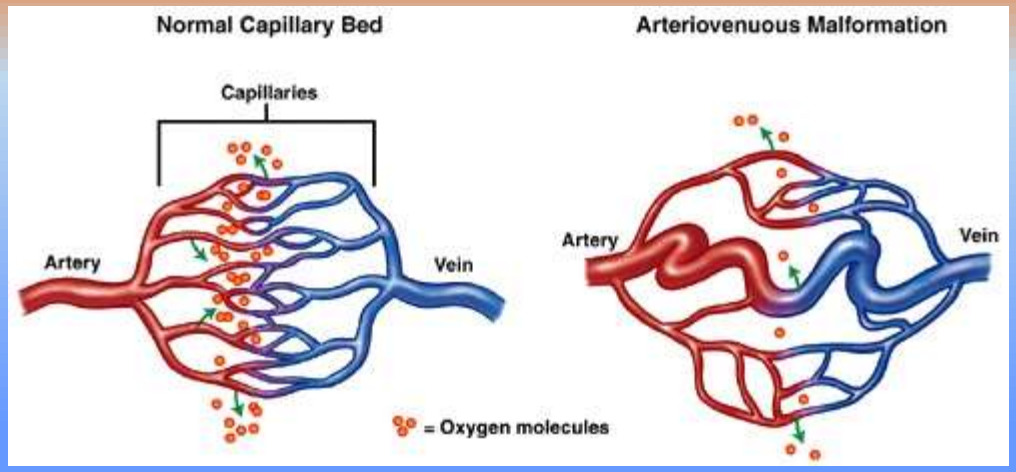

http://cmtc.nl/images/Arteriovenous_malformation.jpg

Veins

4 types according to the size and characteristics of t. media

Venules

a) Postcapillary - pericytic
b) Muscular venules

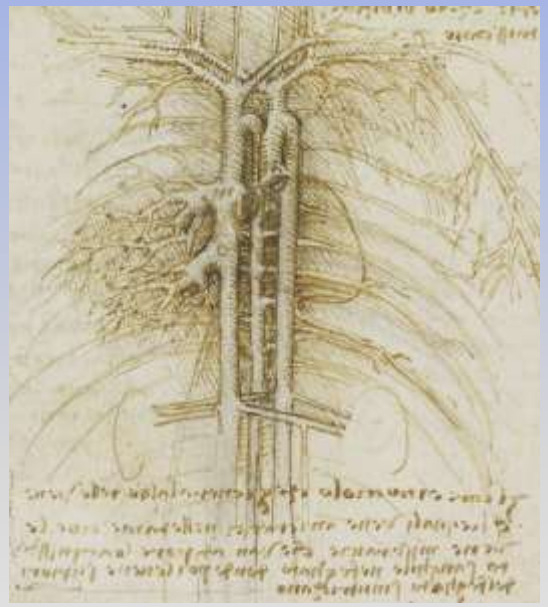

Small veins

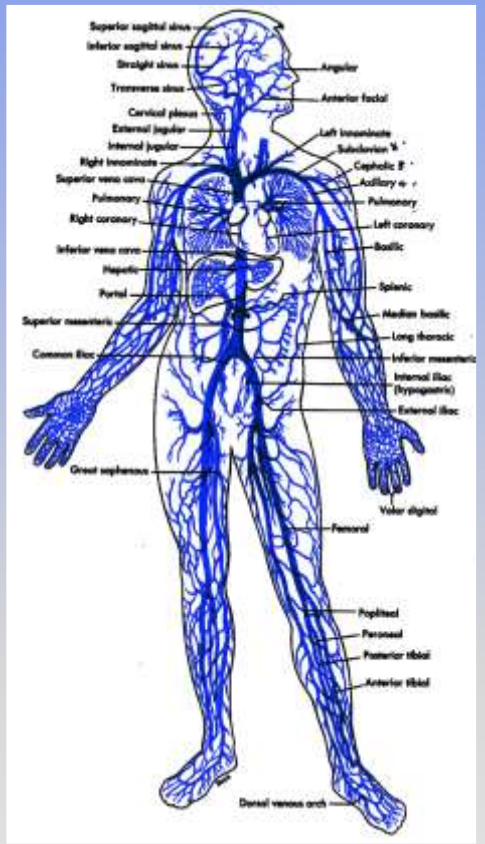

Medium veins

Large veins

http://www.cheap-auto-insurance-in-florida.com/wp-content/uploads/2016/12/veins-of-the-body-arteries-and-vein-study-buddies-pinterest-superfical-temporal-facial-superior-vena-cava-gonadal-popliteal-small-saphenous.gif

Veins

At arteriolar end of a capillary, blood pressure exceeds osmotic pressure, so fluid moves out of the capillary into the interstitial fluid.

At venular end of the capillary, blood pressure lower than osmotic pressure, so fluid moves into the capillary from the interstitial fluid by osmosis

~ nine-tenths of fluid that moves from the arteriolar end of a capillary into the interstitial fluid
-returns into the venular end of the capillary

The remainder is picked up by the lymphoid system and ultimately is returned to the blood

Because nearly 60% of the blood volume is in veins at any instant, veins may be considered as storage areas for blood that can be carried to other parts of the body in times of need.

- Venous sinusoids in the liver and spleen are especially important reservoirs
- If blood is lost by hemorrhage, both blood volume and pressure decline

sympathetic division
- sends nerve impulses to constrict the muscular walls of the veins
- reduces the venous volume while increasing blood volume and pressure
- compensates for the blood loss
- similar effect during muscular activity - to increase the blood flow to skeletal muscles

By Dr. Joseph H Volker | July 24th, 2017

Valves of veins

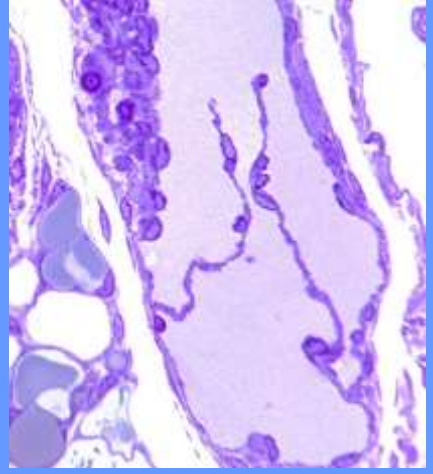

http://medcell.med.yale.edu/histology/blood_vessels_lab/images/quiz3.jpg

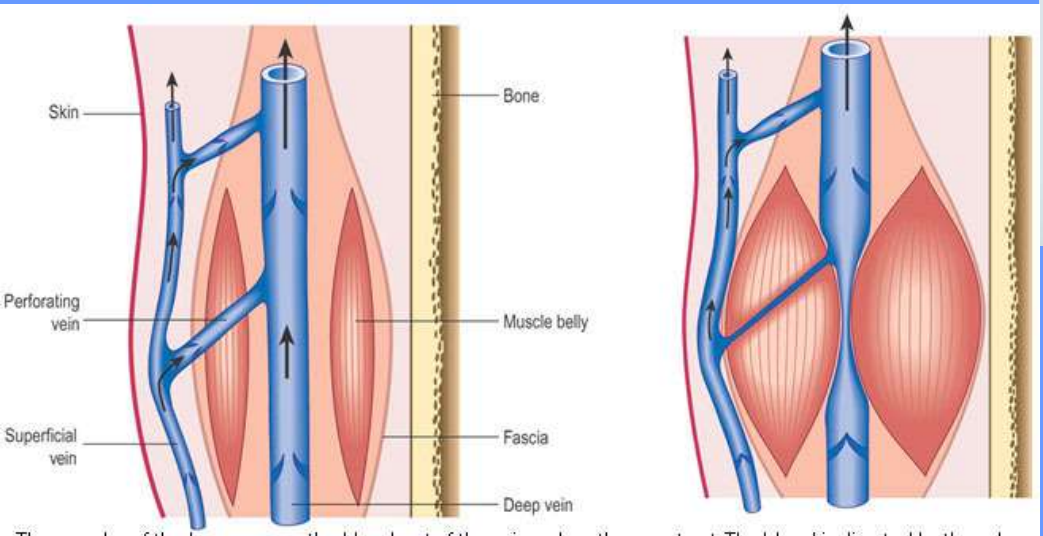

The muscles of the legs squeeze the blood out of the veins when they contract. The blood is directed by the valves, which force the blood to move upward and out of the legs. They also hinder the blood from "falling" back down into the legs when the muscles relax.

Left: Blood flow during relaxation immediately after a muscle contraction.

Right: During maximal contraction, the blood flow is locally blocked by the muscles, but above the muscles the blood is pushed upward. Below the muscles the valves close to keep the blood from being pushed downward by the muscle contraction.

Venules and small veins

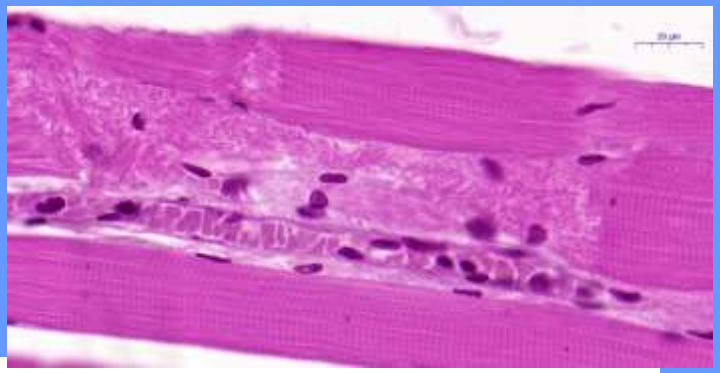

Venules are tubes of endothelium.

Small venules (pericytic) (up to 40-50 µm diameter)
- **surrounded by pericytes (contractile cells)**
- **with long, branching processes that are involved in the control of blood flow**

Large venules (muscular venules) (50-100 µm diameter)
- **surrounded by 1 or 2 layers of smooth muscle cells**
- **pericytes**
- **a thin layer of connective tissue**

- **venular endothelium has labile junctions which "open" in inflammatory reactions under the influence of histamine, serotonin, bradykinin and other agents.**
- **result is increased permeability and local swelling**
- **diapedesis, the exit of leukocytes from the vasculature, occurs also at this level of the microvasculature**

Small veins (100 µm-1000 µm diameter)
- **thin media - only a few layers of smooth muscle cells**
- **much thicker adventitia - collagen and occasionally some**
- **<u>longitudinal smooth muscle fibers</u>**

- **In general, veins are larger in diameter and have thinner walls than arteries**
- **tunica adventitia makes up the greater part of the venous wall of large veins and is usually considerably thicker than the tunica media**

http://medcell.med.yale.edu/histology/blood_vessels_lab.php

Medium veins

Diameter: 1-10 mm

- and occasionally some <u>longitudinal smooth muscle fibers</u>
- most deep veins accompanying arteries in this category
- radial, tibial, popliteal veins
- valves are characteristic
- deep veins are site of thrombus formation: deep venous thrombosis

Tunica intima

- endothelium + basal lamina
- thin subendothelial layer (occasional smooth muscle cells)
- in some cases discontinous internal elastic membrane

Tunica media

- much thinner than in medium-sized arteries
- some layers of circular smooth muscle
- collagen and elastic fibers
- longitudinally oriented smooth muscle cells may be present beneath adventitia

Tunica adventitia

- thicker than tunica media
- collagen fibers and network of elastin fibers

Large veins

Diameter: ≥ 10 mm
- subclavian, portal veins, venae cavae

Tunica intima
- endothelium + basal lamina
- thin subendothelial layer (some smooth muscle cells)

Tunica media
- much thinner than in medium-sized arteries
- some layers of circular smooth muscle
- collagen elastic fibers and fibroblasts
- longitudinally oriented smooth muscle cells may be present beneath adventitia

Tunica adventitia
- thickest layer
- collagen fibers and network of elastin fibers
- longitudinally oriented smooth muscle bundles

Special veins

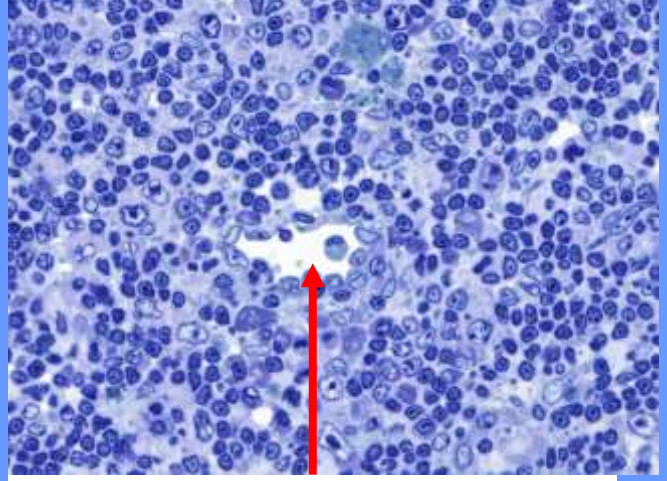

1. High endothelial venule

2. Central adrenomedullary vein

3. Great saphenous vein

4. Dural venous sinuses

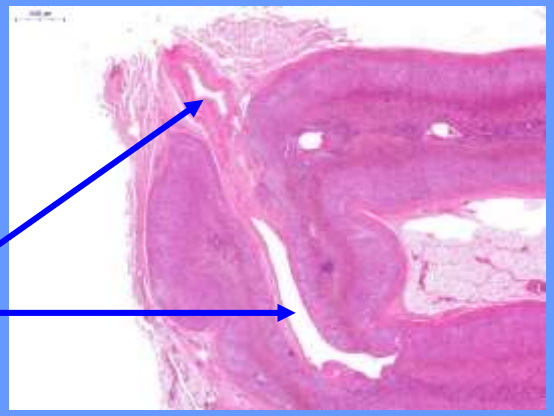

longitudinal section of the vein

longitudinally oriented smooth muscle cells - in longitudinal section

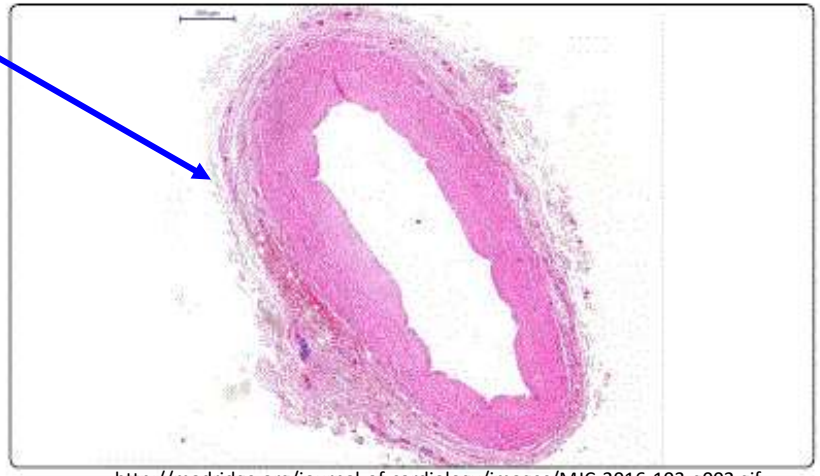

http://madridge.org/journal-of-cardiology/images/MJC-2016-103-g002.gif

Lymphatic vessels

https://tools.ndm.ox.ac.uk/pinfox/importers/pinfox/RDM/images/dcinmouseearlv_fit_900x600.jpg

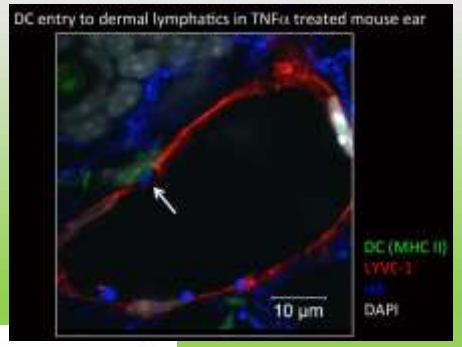

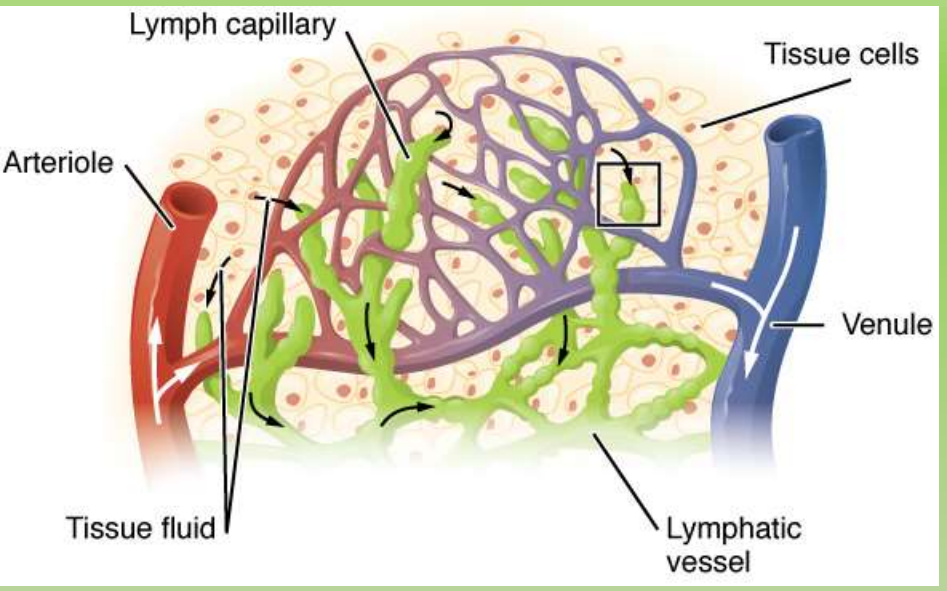

https://upload.wikimedia.org/wikipedia/commons/1/15/2202_Lymphatic_Capillaries_big.png

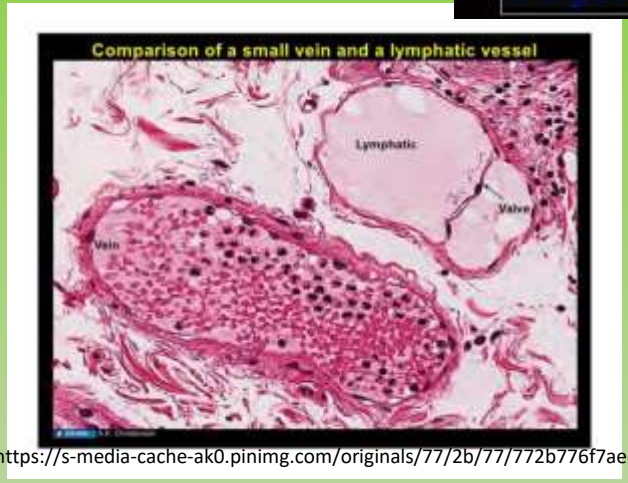

https://s-media-cache-ak0.pinimg.com/originals/77/2b/77/772b776f7aec76d80c8e8f8437c2cb26.jpg

Lymphatic vessels convey fluids from tissues to bloodstream – unidirectional

Lymphatic capillaries

- **begin as blind ended tubes of endothelium – content is the lymph**
- **lack a continuous basal lamina!!**
- **anchoring filaments (fibrillin microfibrils) between the incomplete basal lamina and perivascular collagen**
- **great permeability – remove protein-rich fluid from the intercellular space**
- **they uptake inflammatory molecules, lipids, immune cells**

Lymphatic vessels

- **no permeability: continuous basal lamina, tight junction between endothelial cells, smooth muscle cells**
- **valves! prevent backflow**

Pathology of vascular system

Atherosclerosis

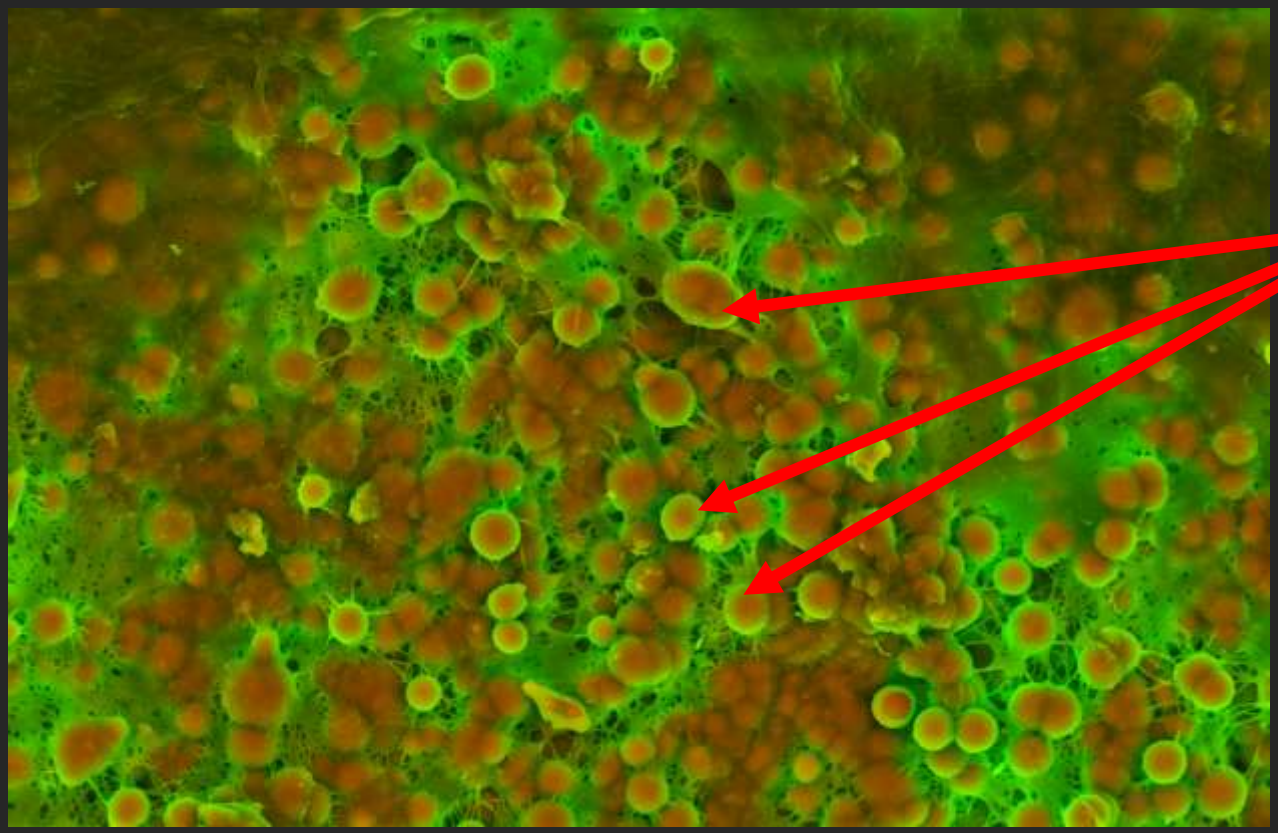

calcium phospate spherical particles

https://upload.wikimedia.org/wikipedia/commons/thumb/c/c9/Cardiovascular_calcification_-_Sergio_Bertazzo.tif/lossy-page1-220px-Cardiovascular_calcification_-_Sergio_Bertazzo.tif.jpg

Density-Dependent Colour Scanning Electron Micrograph SEM (DDC-SEM) of cardiovascular calcification, showing in orange calcium phosphate spherical particles (denser material) and, in green, the extracellular matrix (less dense material).

Pathology of vascular system

Varicosity of veins

Treatment

- endovenous laser treatment, radiofrequency ablation
foam sclerotherapy

Surgical therapy

- stripping
- stripping consists of removal of all or part the saphenous vein main trunk

leaflets of the valves no longer meet properly

- veins become varicose
- valves do not work (valvular incompetence)
- blood flows backwards
- veins enlarge even more

Varicose veins are most common in the superficial veins of the legs

- subject to high pressure when standing
- blood clotting within affected veins, termed superficial thrombophlebitis

Varicose veins are more common in women than in men, and are linked with heredity

Pathology of vascular system

Lymphedema may be inherited (primary) or caused by injury to the lymphatic vessels (secondary)

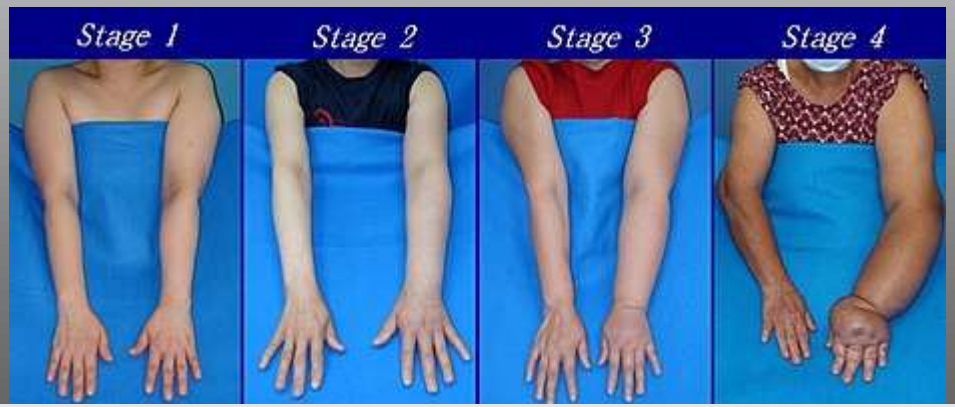

https://www.google.hu/imgres?imgurl=https%3A%2F%2Fimg.medscapestatic.com%2Fpi%2Fmeds%2Fckb%2F88%2F28488tn.jpg&imgrefurl=http%3A%2F%2Femedicine.medscape.com%2Farticle%2F1087313-overview&docid=68-mqej8bvTKbM&tbnid=pq2kA4VN0PJWEM%3A&vet=10ahUKEwiJgcjY2crXAhUDDuwKHQg3A2oQMwgnKAIwAg..i&w=380&h=201&bih=949&biw=1920&q=lymphedema&ved=0ahUKEwiJgcjY2crXAhUDDuwKHQg3A2oQMwgnKAIwAg&iact=mrc&uact=8

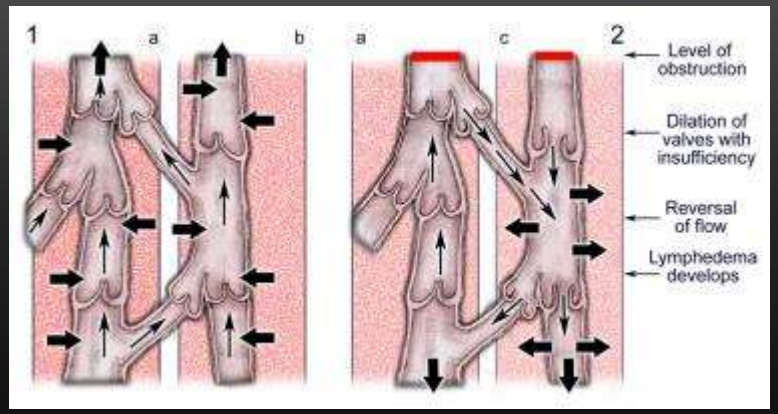

Between 38 and 89% of **breast cancer patients** suffer from lymphedema due to axillary lymph node dissection and/or radiation

https://ars.els-cdn.com/content/image/1-s2.0-S1748681511000076-gr2.jpg

Head and neck lymphedema can be caused by surgery or radiation therapy for **tongue or throat cancer**

Do you want to learn more than the science of yesterday?????

This paper introduces you to the science of today and tomorrow!!!!!!

Developmental Cell Review

Pericytes: Developmental, Physiological,and Pathological Perspectives, Problems, and Promises

Annika Armulik, Guillem Genove, Christer Betsholtz

Pericytes, the mural cells of blood microvessels, have recently come into focus as regulators of vascular morphogenesis and function during development, cardiovascular homeostasis, and disease. Pericytes are implicated in the development of diabetic retinopathy and tissue fibrosis, and they are potential stromal targets for cancer therapy. Some pericytes are probably mesenchymal stem or progenitor cells, which give rise to adipocytes, cartilage, bone, and muscle. However, there is still confusion about the identity, ontogeny, and progeny of pericytes. Here, we review the history of these investigations, indicate emerging concepts, and point out problems and promise in the field of pericyte biology.

Von Willebrand Factor is a large multimeric glycoprotein present in blood plasma and produced constitutively as ultra-large vWF in endothelium (in the Weibel-Palade bodies), megakaryocytes (α-granules of platelets), and subendothelial connective tissue

Krause's Essential Human Histology 2005