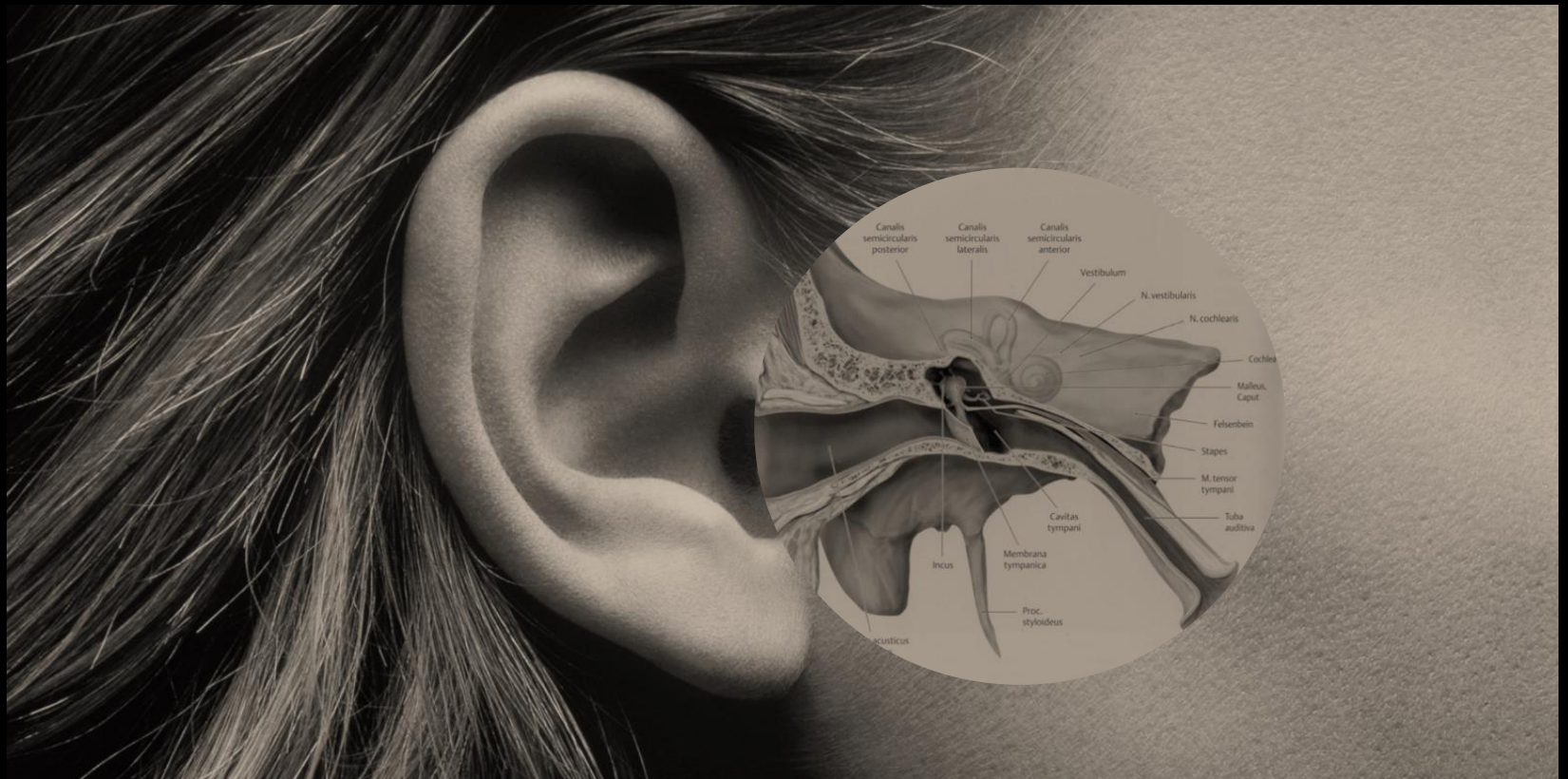
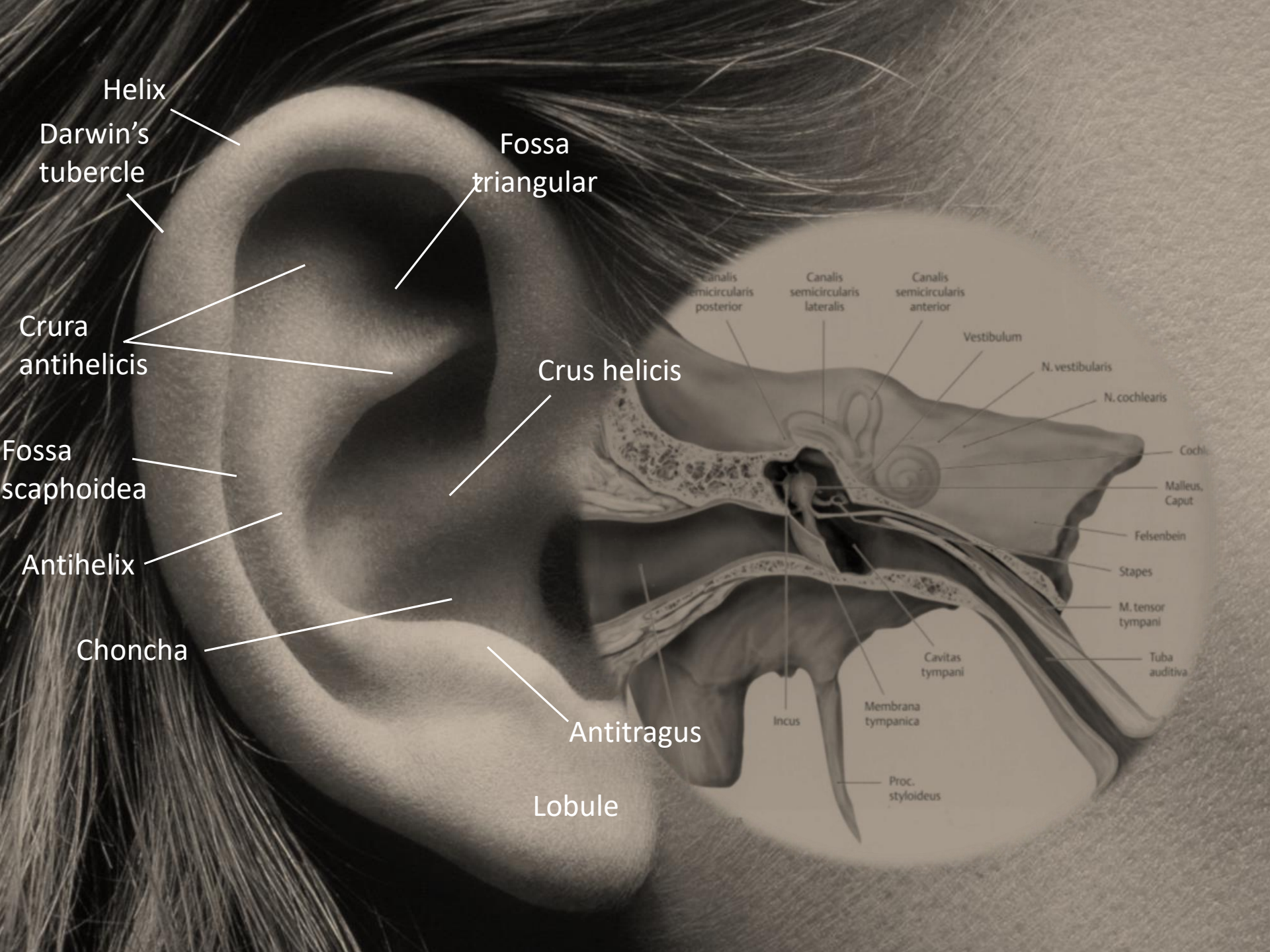


AUDITORY SYSTEM I.

(External and middle ear)





Helix

Darwin's
tubercle

Fossa
triangular

Crura
antihelicis

Crus helcis

Fossa
scaphoidea

Antihelix

Choncha

Antitragus

Lobule

Canalis
semicircularis
posterior

Canalis
semicircularis
lateralis

Canalis
semicircularis
anterior

Vestibulum

N. vestibularis

N. cochlearis

Cochl.

Malleus,
Caput

Felsenbein

Stapes

M. tensor
tympani

Tuba
auditiva

Cavitas
tympani

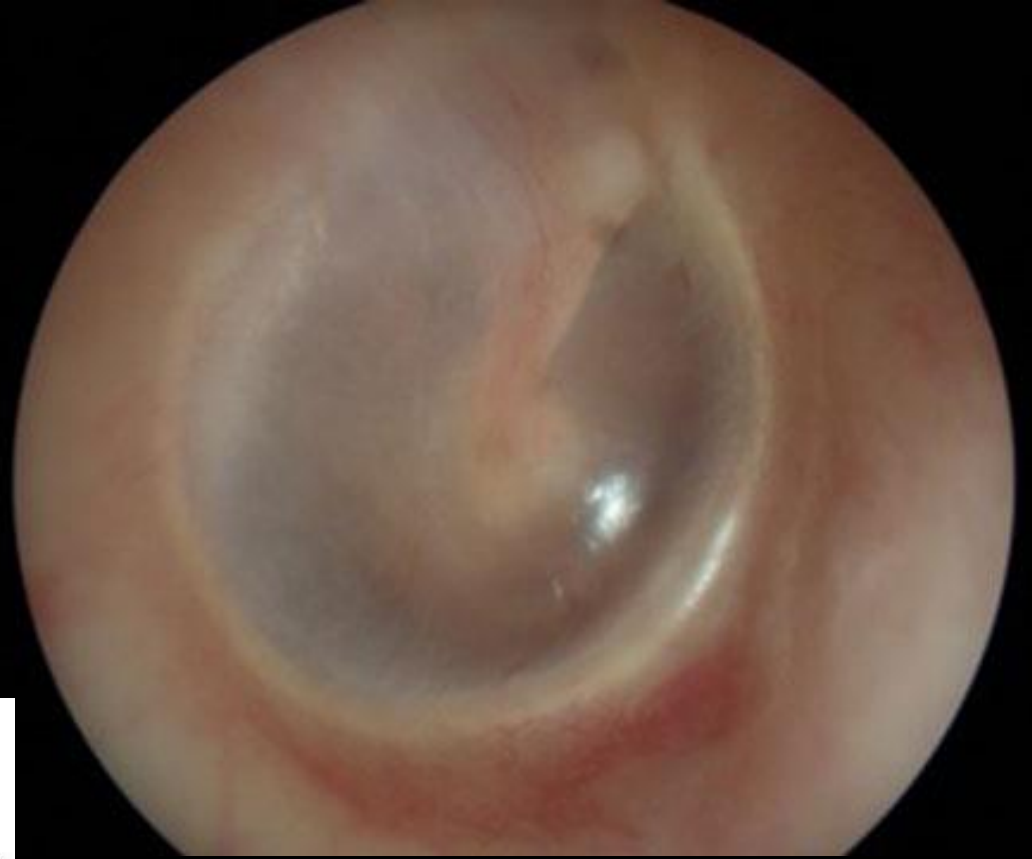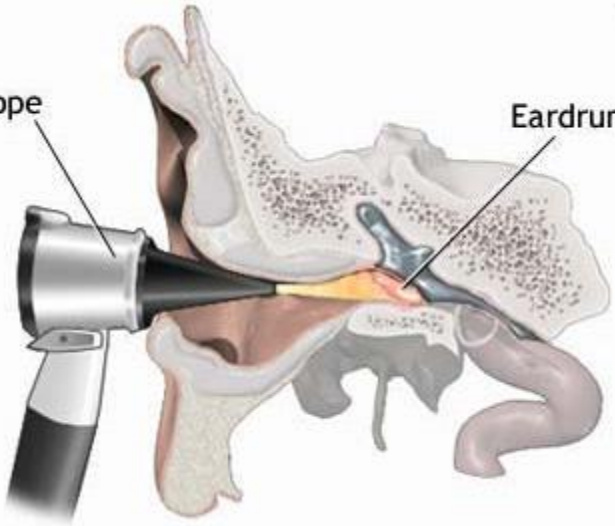
Incus

Membrana
tympanica

Proc.
styloideus

Otoscope

Eardrum



Posterior fold

Pars flaccida

Anterior fold

Incus

Short process of malleus

Umbo

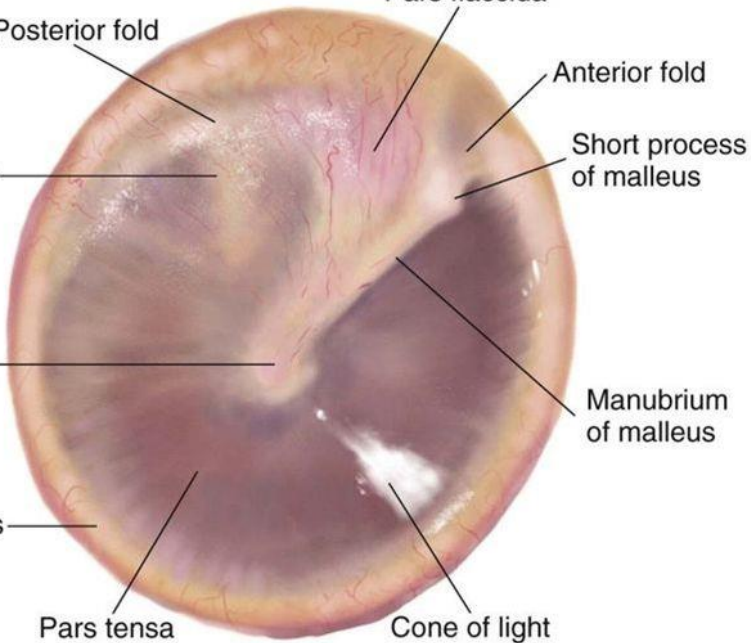
Manubrium of malleus

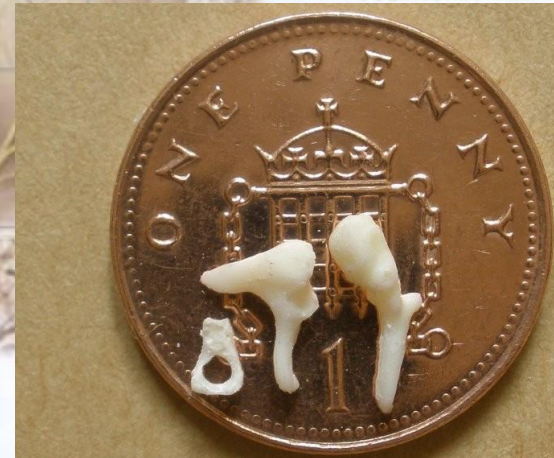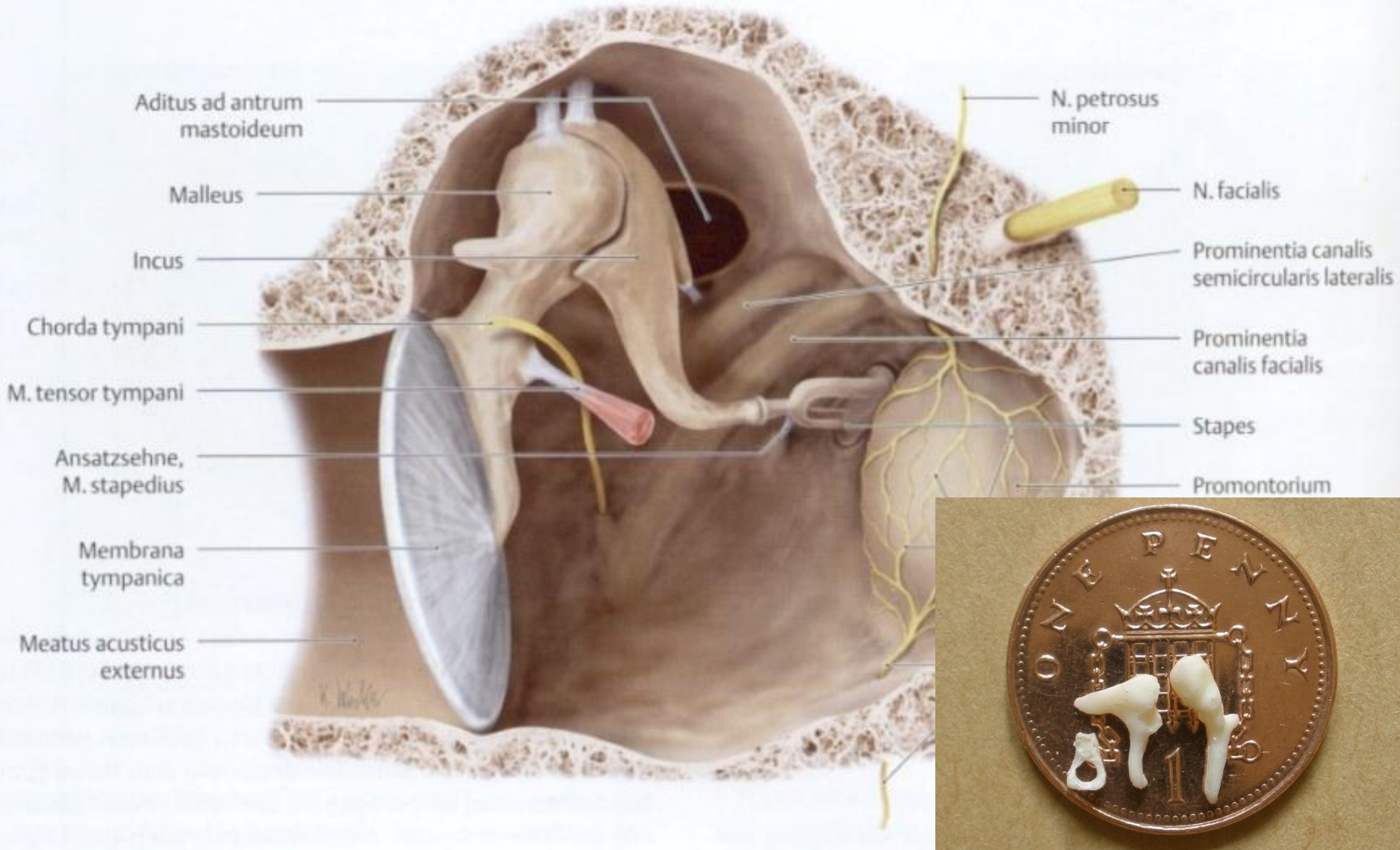
Annulus

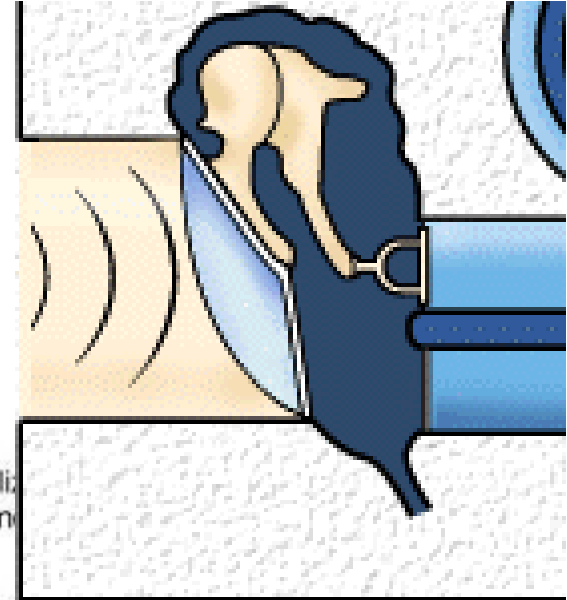
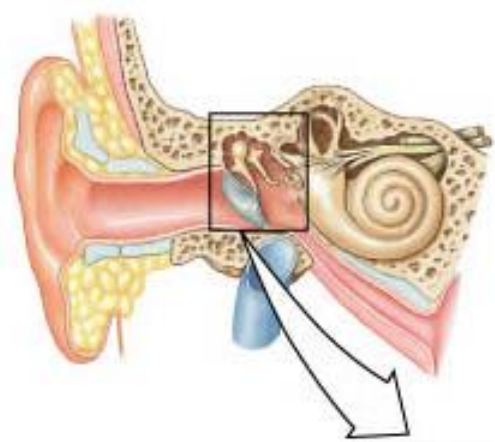
Pars tensa

Cone of light

TYMPANIC MEMBRANE





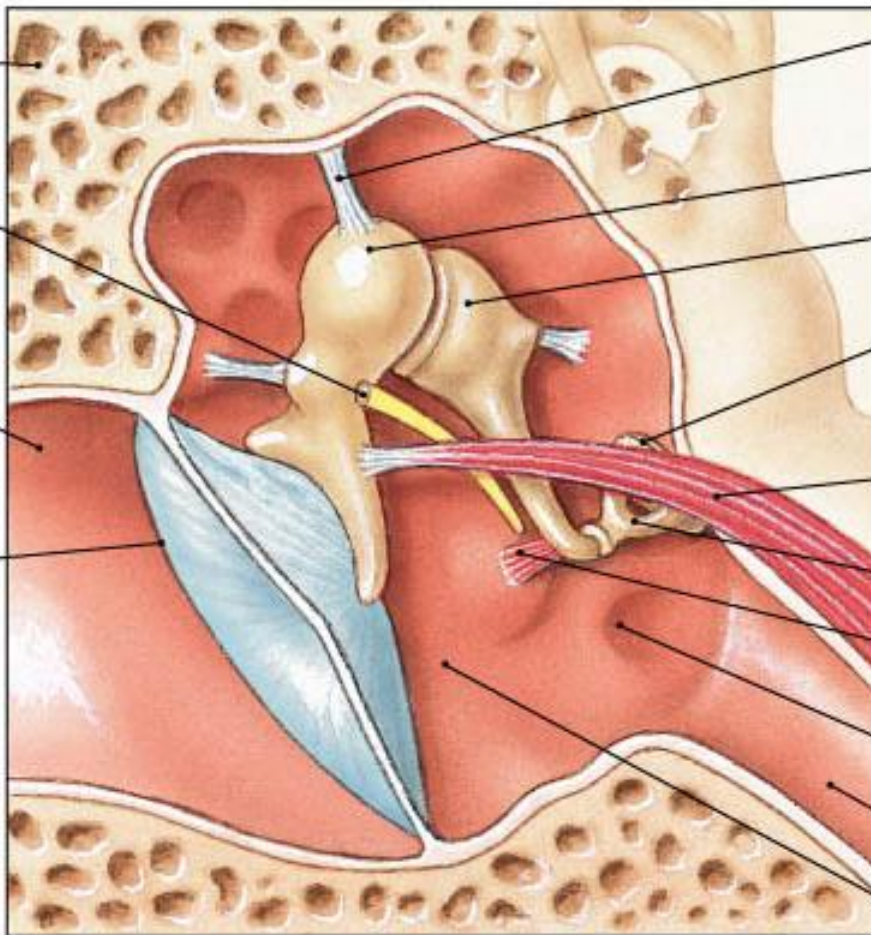


Temporal bone
(petrous portion)

Chorda tympani
nerve (cut), a
branch of N VII

External
acoustic
meatus

Tympanic
membrane
(tympanum)



Stabiliz
ligam

Malleus

Incus

Base of
stapes at
oval window

Tensor tympani
muscle

Stapes

Stapedius
muscle

Round window

Auditory tube

Tympanic cavity
(middle ear)

(b) The middle ear

