

**Semmelweis University**  
**Department of Anatomy, Histology and Embryology**

**Faculty of Dentistry**  
**2nd year, 2nd semester**

# **ANATOMY HANDBOOK**



Dr. Andrea D. Székely  
Associate Professor  
Course Director of the English Language Program

Dr. Ágoston Szél  
Full Professor  
Head of Department, Rector of the Semmelweis University

Dr. Gábor Gerber  
Associate Professor  
Deputy Head and Dean of the Faculty of Dentistry



# Anatomy, Histology and Embryology for ED students

## TEACHING DEPARTMENT:

SEMMELWEIS UNIVERSITY

Department of Anatomy, Histology and Embryology

Budapest, Tűzoltó utca 58.

H-1094 Budapest

[www.ana.sote.hu](http://www.ana.sote.hu)

## LEARNING OBJECTIVES

**Aims of the lectures in Anatomy** - Presentation of important and/or complicated topics such as: 1<sup>st</sup> semester - the structure of the body wall (e.g. thorax, pelvis), extremities and the cranium, 2<sup>nd</sup> semester - the morphology of internal organs including the cardiovascular, digestive and urogenital systems; 3<sup>rd</sup> semester - the composition of the central nervous system, together with the organs of special senses and topography of body regions, and the 4<sup>th</sup> semester is devoted entirely to maxillofacial topographical anatomy.

**Aims of the lectures in Histology** - Presentation of the cell, basic principles in cellular morphology, detailed description of the epithelial, connective, muscle and nervous tissues. During the 3 semesters, the lectures contribute to the gross anatomical description of organs with a detailed presentation of their fine structures, including ultrastructural details. Important chapters: basic tissues, viscera, central nervous system.

**Aims of the lectures in Embryology** - Presentation of the early development from the differentiation of the germ cells to the formation of the human embryo (basic embryology) as well as the development of the locomotor system (1<sup>st</sup> semester). In the 2<sup>nd</sup> and 3<sup>rd</sup> semesters, the embryology topics will complement the gross anatomy and histology lectures of the organs and systems, also mentioning the most frequent malformations.

For the deeper understanding of relatively difficult questions small group discussions may be organized during the practical dissection room classes.

**Aims of the practical dissection classes** - In the first three semesters, based on their weekly programs, the students will study the morphology of the human body using anatomical specimens (bones, joints, muscles, viscera, brain) as well as learning the basic principles of dissection, including the proper usage of tools (scalpel, forceps, scissors) under the supervision of their lab instructors. The anatomy of the locomotor system and the peripheral nervous system will be principally taught in the dissecting room.

**Aims of the histology practical classes** - Under supervision by the lab instructor, the students will learn the use of the light microscope and the individual viewing of histology slides will facilitate the understanding of the basic tissues (epithelial, connective, muscle and nervous) and the fine structure of the organs.

The knowledge of students will be tested by regular **mid-term examinations** and a Semester-end Dissection Test.

### Lectures:

First semester: 3x 45 min; second semester: 3x 45 min;

third semester: 3x 45 min; fourth semester: 3x 45 min.

**Topics:**

**First semester:** Gross anatomy of the bones, joints and muscles, basic histology, general embryology, development of the skull, spine and limbs.

**Second semester:** Morphology, histology and embryology of the heart and vessels, lymphatic organs, viscera, body cavities and serous membranes. Sectional anatomy of the thorax, abdomen and pelvis. Description of the diaphragmas.

**Third semester:** Morphology, histology and embryology of the central and peripheral nervous systems, the organs of special senses, as well as of the endocrine organs; topographical anatomy of the extremities.

**Fourth semester:** Maxillofacial anatomy - organs, cavities, nervous and vascular supply of the head and neck regions, including topographical and cross sectional anatomy. Revision of the topics of the first three semesters.

**Practical course:**

First semester 5x 45 min; second semester: 4x 45 min;

third semester: 4x 45 min; fourth semester: 2x 45 min;

**First semester:** Gross anatomy of the bones, joints and muscles, basic histology, general embryology, development of the skull, spine and limbs.

**Second semester:** Morphology, histology and embryology of the heart and vessels, lymphatic organs, viscera, body cavities and serous membranes. Sectional anatomy of the thorax, abdomen and pelvis. Description of the diaphragmas

**Third semester:** Morphology, histology and embryology of the central and peripheral nervous systems, the organs of special senses, as well as of the endocrine organs; topographical anatomy of the extremities.

**Fourth semester:** Topographical anatomy of the head and neck. Individual revision of the subjects taught and studied during the four semesters.

**Type of exams:** first, second and third semesters: semifinal examination, fourth semester: final exam from the subjects of the four semesters.

**ECTS credits:** four semesters together: 27 (first semester: 8; second semester: 7; third semester: 7; fourth semester: 5)

# MAXILLOFACIAL ANATOMY ANNOUNCEMENTS

**Signing of the lecture book:** active participation in lectures, and dissection room sessions is obligatory for every student. Students should attend at least 75% of the scheduled hours to gain a signature proving the validity of the semester. Absences are therefore limited in **25%**. Presence will be recorded in the lectures and in the dissection room classes.

**Midterm examination:** During the 4th semester, both practical and theoretical knowledge will be regularly evaluated. The midterms will be either oral and written exams. The **maxillofacial midterm** includes the identification of a number of anatomical and histological features in projected images as well as theoretical questions related to the subject. The **anatomy midterm** includes both the identification of several structures on the specimen and oral theoretical questions related to the subject.

The date of the tests is always set previously. The results of all tests will appear on the personal achievement cards. There is no exemption on the basis of good midterm results in the 4<sup>th</sup> semester.

**Evaluation** is made using a five-grade scale (1-5)

Those who fail, or absent from, both of the midterms will have to sit for an oral practical retake (exact date TBA) during the last two weeks of the semester.

*N.B. – In case neither the first nor the repeated takes of a final exam have been successful, the students may sit for a CV final examination in the **subsequent winter examination period**, in case they have „chances“ left, or, may repeat the semester in the following year.*

## **RULES AND REGULATIONS IN THE DISSECTING ROOM**

**IT IS STRICTLY FORBIDDEN to eat, drink, smoke, to chew gums, or to use music devices or phones.**

**Bags and coats should be left in the lockers before entering the dissecting room.**

**The lockers will have to be locked using your padlocks.**

**Please, remember to keep your valuables always on you, or lock them in the lockers since the department takes no responsibility for lost items.**

Everybody is supposed to behave in the dissecting room conforming to the spirit of the site. Loud speech, out-of-place jokes and any kind of behaviour, disregarding the dignity of human corpses, should strictly be avoided.

**Students are expected to be prepared for the practical work.**

Students should take care of the furniture and equipment of the dissecting room. Do not sit on the dissection tables or stand on the tripod stools to avoid accidents. **Fire and work safety regulations** should be maintained. The dissection room is a hazard area. **Cleanliness and order** should be kept.

**Working** in the dissection room involves the use of **sharp and pointed tools**, injuries should be reported to the lab instructor. The technical personnel will provide first aid when necessary.

The white lab coats should be worn while in the dissection room, but should be removed before leaving the dissection room area. The purpose of wearing the lab coats is to protect one's clothing from contacting the cadaver specimen. Furthermore we advise you to wear closed toed shoes and clothing covering the legs. In the end of the class, lab coats should be emptied and left in order on the coat hangers. The department is not responsible for valuables left in the dissecting room.

Only the members of the study group can participate in the sessions, visitors may be present only with prior permission by the lab instructor. Students can leave the sessions only with the approval of the lab instructor.

**Photos, or videos can only be made with the agreement and in the presence of the lab instructor.**

Specimen preparations should be wrapped and labeled. Dissection materials of other groups or individuals should not be handled. Dissected cadaver pieces should be discarded in a designated container and discarded blades have to be collected separately.

Dissecting rooms are closed between 6:00 PM to 8:00 AM and over the weekends Students may not stay in the dissecting room without the supervision of one of the assistants of the department. In the absence of an instructor, the technical personnel should ask the students to leave the dissecting room.

**SMOKING IS STRICTLY FORBIDDEN  
ON THE DEPARTMENTAL PREMISES,  
INCLUDING THE GARDEN AND THE YARD!**

# ED II MAXILLOFACIAL ANATOMY

## Subject matter of the 4th semester

The topics of the semester include the chapters of maxillofacial anatomy as well as the entire material of the previous semesters.

### Test I.

Place: Lecture hall (written test)  
Topic: The lectures of the first 6 weeks  
Date: 6th study week, March 11.

### Test II.

Place: Dissection room (practical test)  
Topic: Topographical and sectional anatomy of the head and neck  
Date: 13th study week, May 2.

### Final examination

**Topics:** Subject matter of the 4 semesters in Anatomy, Histology and Embryology

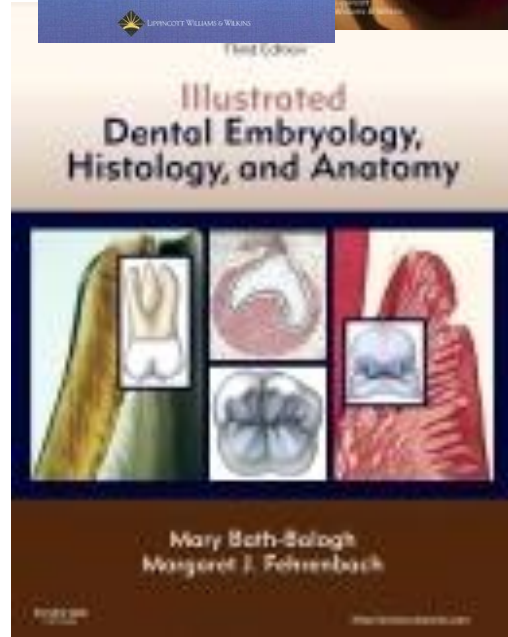
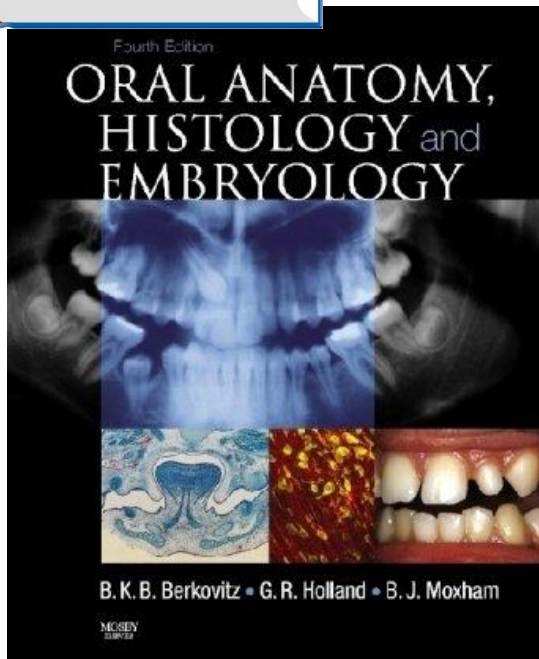

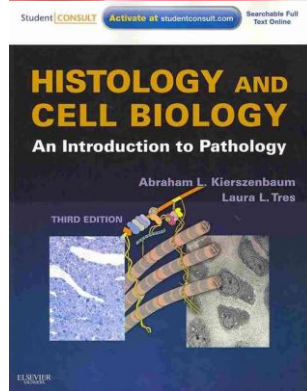
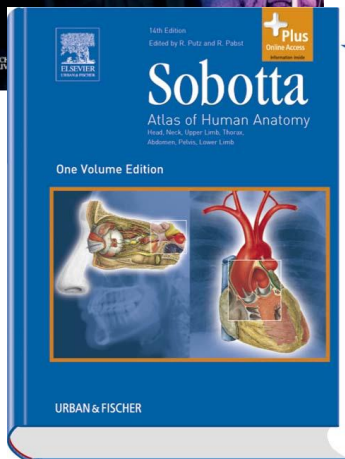
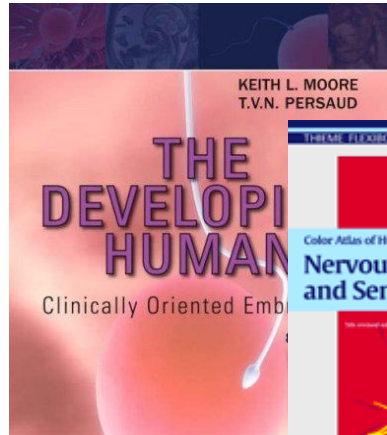
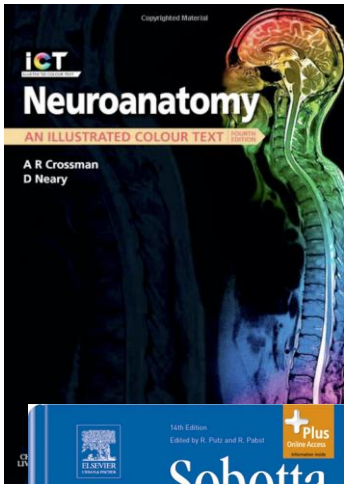
The final exam consists of three parts:

1. Macroscopical anatomy
2. Histology (2 slides)
3. Theoretical part (6 topics including Maxillofacial anatomy)

**ED II. Academic year 2015/2016 Second Semester**  
**Maxillofacial Anatomy**

<b>Week</b>	<b>Lectures</b> Monday 10.00 – 11.40 Thursday 13.00 - 13.45	<b>Dissection room</b> Monday 8.00 - 9.30
Week 1 Febr 1- 5	1. Introduction, the composition and development of the skull 2. Maxilla, mandible. The temporomandibular joint, masticatory muscles, mechanism of mastication 3. Walls and parts of the oral cavity, the oral mucosa	Bones and spaces of the skull, content of the orbit
Week 2 Febr 8 - 12	4. Anatomy, histology and innervation of the tongue 5. Topography, histology, innervation of the salivary glands 6. The palate and the faucial isthmus	Prosected specimen: demonstration of the head@neck: oral cavity, tongue and the salivary glands
Week 3 Febr 15 - 19	7. Nasal cavity and paranasal sinuses 8. The pharynx and the parapharyngeal spaces 9. The cavity, muscles and the mucosa of the larynx	Prosected specimen: demonstration of the head@neck: oral cavity, tongue, salivary glands pahrynx, larynx. Mediansagittal section of head
Week 4 Febr 22 - 26	10. Development of the face, malformations 11. Pharyngeal pouches, development of the tongue 12. Anatomy of the teeth I	Prosected specimen: demonstration of the head@neck: oral cavity, tongue, salivary glands pahrynx, larynx. Mediansagittal head section Teeth
Week 5 Febr 29 – March 4  <b>March 5</b> <b>Monday classes</b> <b>on Saturday</b>	13. Anatomy of the teeth II. 14. Histology of the teeth I. 15. Histology of the teeth II.  16. Parodontium 17. Bone formation, bone remodelling and supplementation	Prosected specimen: demonstration of the head@neck: oral cavity, tongue, salivary glands pahrynx, larynx. Mediansagittal head section Teeth, morphology and histology (photos)  <b>Dissection class on Saturday March 5.</b>
Week 6 March 7 - 11	18. Tooth development, malformations 19. <i>Anatomical relevances in gnathology</i> 20. <b>1st Midterm (written): lectures 1-19.</b>	Prosected specimen: demonstration of the head@neck: oral cavity, tongue, salivary glands pahrynx, larynx. Mediansagittal head section Teeth, morphology and histology (photos)
Week 7 March 14 - 18	-- <b>March 15th holiday</b> -- <b>March 15th holiday</b> 21. Blood vessels of the head&neck region	<b>March 15th holiday</b>
March 21 – 25	<b>Easter Break</b>	
Week 8 March 29 – April 1	23. -- <b>Easter Monday</b> 22. -- <b>Easter Monday</b> 24. The lymphatic system of the head&neck region	Maxilla, mandible. Prosected specimen: demonstration of the temporomandibular joint, muscles of mastication and facial expression.
Week 9 April 4 - 8	25. Nerves of the head&neck region I.: CN 5 26. Innervation of the teeth and the gingiva, the anatomy of dental local anaesthesia 27. The reflex arc of mastication, the clinical anatomy of trigeminal neuralgia	<b>Easter Monday</b>
Week 10 April 11 - 15	28. Nerves of the head&neck region II. CN 7 and 9 29. Nerves of the head&neck region III CN 10, 11 and 12 30. Topography of the viscerocranium. The orbit	Prosected specimen (torso and head): demonstration of the vessels and nerves of the head&neck regions. Regional anatomy of the head
Week 11 April 18 - 22	31. Superficial regions and muscles of the head 32. Deep regions and sectional anatomy of the head 33. The concept of the spinal nerve, dorsal branches, branches of the cervical plexus	Prosected specimen (torso and head): demonstration of the vessels and nerves of the head&neck regions. Regional anatomy of the head
Week 12 April 25 – 29 <i>Competition 1st round</i>	34. Superficial regions, muscles and fasciae of the neck 35. Deep regions and sectional anatomy of the neck 36. The cutaneous innervation of the head&neck region	Prosected specimen (torso and head): demonstration of the vessels and nerves of the head&neck regions. Demonstration of the final's specimen: parapharyngeal space, cross section of the head and the neck
Week 13 May 2 - 6 <i>Competition 2nd round</i>	37. Topography of the neurocranium 38. The cranial parasymphetic and sympathetic system 39. Surgical relevances of the head and neck region	<b>2nd Midterm: Topographical and sectional anatomy of the head and neck regions including their internal organs</b>
Week 14 May 9 - 13	40. Imaging anatomy of the jaws, teeth and the maxillary sinus (Radiology lecture) 41. Histology revision 1. 42. Histology revision 2. <i>Announcement of the competition results</i>	<b>Revision</b>

# RECOMMENDED BOOKS

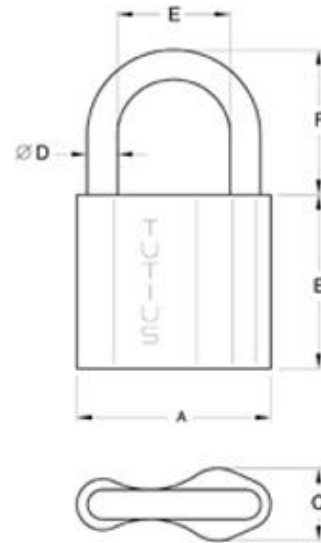




**During dissection classes keep your belongings in the lockers and lock them with your padlock!**


**PADLOCK SIZE: 6 mm**

Please, remember to keep your valuables always on you, or lock them in the lockers since the department takes no responsibility for lost items.



### **DISSECTION ROOM TOOLS**

#### **SCALPEL**



**OR**



#### **A PAIR OF ANATOMICAL FORCEPS**



#### **RUBBER GLOVES**



#### **PROTECTIVE CLOTHING (LABCOAT)**

#### **GOGGLES**



# TOPICS OF THE FINAL EXAMINATION IN ANATOMY, HISTOLOGY AND EMBRYOLOGY

**1.:Embryology**

**2.: Histology**

**3.: Locomotor system**

**4.: Circulatory system or organs of special senses**

**5.: Splanchnology (viscera)**

**6.: Nervous system**

## EMBRYOLOGY

Spermatogenesis

Oogenesis, Female reproductive cycles

Fertilization, cleavage of the zygote

Blastocyst formation. The bilaminar embryonic disc

Implantation

Gastrulation, The notochord

Neurulation

Development and differentiation of the neural tube

Derivatives of the ectoderm

Derivatives of the endoderm

Differentiation of the mesoderm. Formation and derivatives of the somites

Derivatives of the mesoderm

Lateral mesoderm and its derivatives

Folding of the embryo

Development of the primitive cardiovascular system and the placental circulation

The structure of the placenta

Fetal membranes.Umbilical cord

The embryonic and fetal periods. Parturition, multiple birth

Stages of human prenatal development

Development of the limbs

Development of the skull

Development of the muscular system

Early development of the heart. Folding of the heart tube.

Development and partitioning of the primitive atrium

Development and partitioning of the primitive ventricle.

The aorticopulmonary septum.

Development of the great arteries. Derivatives of the aortic arches.

Development of the inferior vena cava and the portal vein.

Development of the superior vena cava, the azygos and hemiazygos veins.

The fetal and neonatal circulation

Development of the face and palate  
Development of nasal cavity and paranasal sinuses  
Development of the teeth and the tongue  
Development of the branchial arches and their derivatives  
Development of laryngo-tracheal tube, bronchi and the lung  
Development of branchial grooves, the pharyngeal pouches and their derivatives  
The formation and differentiation of the foregut  
Formation and development of the midgut  
Development of liver and pancreas  
The formation and differentiation of hindgut  
Development of the kidneys  
Development of the urinary passages  
Development of the gonads  
Development of the male genital ducts and auxiliary glands  
Development of the female genital ducts and auxiliary glands  
Development of the male and female external genitalia  
Formation and division of the body cavities  
Development of the peritoneum  
Development and differentiation of the spinal cord  
Development of the forebrain  
Development of the peripheral nervous system  
Development of the eye and optic nerve  
Development of the organs of hearing and equilibration.

## **HISTOLOGY**

Concept of basic tissues .  
Definition and classification of epithelial tissue  
Simple epithelia  
Stratified epithelia  
Membrane specialisations of epithelia  
Glandular epithelia  
Pigment epithelium and sensory epithelium  
Cells of connective tissue  
Ground substance and fibres of connective tissue  
Types of connective tissue  
Blood and the formed elements of blood  
Bone marrow maturation of erythrocytes and platelets  
Maturation of granulocytes, lymphocytes and monocytes.  
Histology of cartilage  
Histology of the bone  
Intramembranous ossification  
Endochondral ossification  
Growth and remodeling of bone  
Smooth muscle and myoepithelial cells  
Histology skeletal muscle

Cardiac muscle  
Sarcoplasmic reticulum and transverse tubule system  
Histology of the neuron  
Microscopic structure of neurons in the CNS  
Neuroglia  
Nervous and supporting cells in the CNS  
Neurons and supporting cells of the neural crest  
Nerve fibres, Myelin sheath  
Receptors. Effectors. Motor end-plate  
Interneuronal synapses  
Gross anatomy of pituitary gland. Histology and development of neurohypophysis  
Blood supply of pituitary. Histology of adenohypophysis  
Gross anatomy and histology of pineal body  
Gross anatomy, histology and development of the thyroid gland  
Gross anatomy, histology and development of the parathyroid glands  
Microscopic anatomy and development of adrenal cortex  
Gross anatomy of adrenal glands, Histology and development of adrenal medulla  
Histology of pancreas and the islets of Langerhans  
Microscopic anatomy of lymph nodes  
Gross and microscopic anatomy of the spleen  
Microscopic anatomy of thymus  
Microscopic anatomy of tonsils  
Microscopic anatomy of arteries and arterioles  
Microscopic anatomy of capillaries and veins  
Microscopic anatomy of skin  
Microscopic anatomy of epidermal appendages of skin and mammary glands  
Microscopic structure of the wall in the gastrointestinal tract  
Microscopic structure of exocrine glands  
Microscopic structure of intestinal villi

## **LOCOMOTOR SYSTEM**

Architecture and classification of bones  
Fibrous and cartilaginous joints  
Components of synovial joints  
Classification of synovial joints. Movements and mechanisms  
Structure and actions of somatic muscles  
Structure of the vertebral column and the muscles responsible for its movements  
Movements of the head and the muscles participating in them  
Osteofibrous structure of the thoracic cage  
Joints of the shoulder girdle and the muscles acting on them  
The shoulder joint and the muscles acting on it  
The axilla, the quadrangular and triangular spaces  
The elbow joint, movements and muscles acting on it  
The cubital fossa  
Muscles and cross section of the arm

Muscles and cross section of forearm  
Structure and movements at the wrist joint and the muscles acting on it  
Osteofibrous spaces and muscle compartments of the hand  
Joints of fingers and muscles concerned in their movements  
Joints of the thumb and the muscles concerned in their movements  
Structure of the osteofibrous pelvis  
Muscles of the buttock, the posterior abdominal wall and the pelvis (external and internal muscles of the hip).  
The hip joint and muscles concerned in its movements  
Osteofibrous compartments, muscles and cross section of the thigh  
The knee joint and muscles concerned in its movements  
Popliteal fossa  
Femoral sheath, vascular and muscular compartments. Adductor canal  
Osteofibrous compartments, muscles and the cross section of the leg  
Ankle joint and muscles concerned in its movements  
Subtalar and talocalcaneonavicular joints and muscles acting on them  
Structure of the foot. Arches of the foot  
Osteofibrous compartments of the foot  
Mechanism of walking  
Anterior cranial fossa (composition, boundaries, connections)  
Middle cranial fossa (composition, boundaries, connections)  
Posterior cranial fossa (composition, boundaries, connections)  
Walls and connections of the orbit  
Walls and connection of the nasal cavity  
Inferior surface and connections of the base of the skull  
Bony walls of the oral cavity, the temporal and infratemporal fossa  
Walls and connections of the pterygopalatine fossa  
Temporomandibular joint and the muscles concerned in its movements  
Diaphragm  
Lateral superficial abdominal muscles and fasciae  
Rectus abdominis muscle and its sheath  
Inguinal canal  
Femoral canal  
Muscles of the pelvic floor  
Superficial muscles of the neck and the muscle triangles  
Deep muscles of the neck and the laminae of the cervical fascia  
Muscles of facial expression

## **CIRCULATION**

Shape and surfaces of the heart  
Skeleton of the heart  
Structure of the myocardium  
Chambers of the heart  
Endocardium and the valves of the heart  
Conducting system of the heart

Blood supply of the heart  
Pericardium  
Surface anatomy of the heart. Heart sounds  
Position and radiology of the heart.  
The pulmonary circulation  
Subdivisions and topography of the aorta  
Arch of the aorta and its branches  
Subclavian artery and its branches  
Axillary artery and its branches  
Arteries and veins of the arm and forearm  
Vessels of the hand  
External carotid artery and its branches  
Maxillary artery and its branches  
Course and distribution of the internal carotid artery  
Venous drainage of the head  
Course and branches of the thoracic aorta  
Course and branches of the abdominal aorta  
Coeliac trunk and its branches  
Superior mesenteric artery and its branches  
Inferior mesenteric artery and its branches  
Branches of the internal and external iliac arteries  
Vessels of the thigh and leg  
Vessels of the foot  
Course and tributaries of superior vena cava  
Course and tributaries of inferior vena cava  
Portal system of veins. Communication between portal and systemic veins  
Venous and lymphatic drainage of the body wall including the breast  
Lymph nodes and lymphatic drainage of head and neck  
Lymphatic drainage of upper limb  
Lymphatic drainage of lower limb  
Thoracic and the right lymphatic ducts.

## **ORGANS OF SPECIAL SENSES**

Fibrous coat of the eyeball  
Vascular coat of the eyeball  
Retina  
Visual pathways  
Optic lens and the convergence-accomodation reaction  
Chambers of eye and vitreous body  
Extrinsic muscles of the eyeball  
Eyelids, conjunctiva, fascial sheath of eyeball. Lacrimal apparatus  
External ear and tympanic membrane  
Walls of the tympanic cavity. Auditory tube  
Shape, joints and muscles of auditory ossicles.  
Bony and membranous labyrinth

Bony cochlea and cochlear duct  
Auditory pathways  
Organs of taste and olfaction

## **INTERNAL ORGANS**

Oral cavity  
Gross anatomy and histology of tongue  
Morphology of the permanent teeth, blood and nerve supply  
Fine structure of dentin and enamel  
Histology of cementum and periodontium  
Development of teeth. Dentition  
Gross anatomy, histology and topography of salivary glands  
Isthmus of fauces  
Gross anatomy and muscles of pharynx  
Microscopic anatomy, blood and nerve supply of pharynx  
Topography of pharynx. Para and retropharyngeal spaces  
Gross anatomy, histology and topography of oesophagus  
Gross anatomy and peritoneal relations of stomach  
Microscopic anatomy of stomach  
Gross anatomy of duodenum  
Gross anatomy of jejunum and ileum  
Microscopic anatomy of small intestines  
Microscopic structure of intestinal villi  
Gross anatomy of large intestines and vermiform appendix  
Microscopic anatomy of large intestines  
Gross anatomy and histology of rectum and anal canal  
Gross anatomy and peritoneal relations of liver  
Microscopic structure of liver  
Gross and microscopic anatomy of gall bladder and bile ducts  
Gross anatomy and topography of pancreas  
Structure of nasal cavity and paranasal sinuses  
Skeleton of larynx. Joints and fibroelastic membranes  
Cavity of larynx. Mucous membrane and muscles  
Gross anatomy and histology of trachea  
Bronchial tree. Histology of the lung  
Gross anatomy of the lung  
Pleura  
Subdivision and contents of mediastinum  
Gross anatomy of the kidney  
Microscopic anatomy of the kidney  
Gross anatomy and histology of renal pelvis and ureter  
Gross and microscopic anatomy of urinary bladder  
Gross anatomy and histology of male and female urethra  
Gross anatomy of the testis  
Histology of the testis

Gross and microscopic anatomy of epididymis and ductus deferens  
Spermatic cord, scrotum and coverings of testis  
Gross anatomy and histology of seminal vesicle and prostate  
Gross anatomy and histology of penis. Mechanism of erection  
Gross anatomy of the ovary  
Histology of the ovary  
Gross and microscopic anatomy of the uterine tube  
Gross anatomy and fixation of the uterus  
Histology of the uterus. Menstrual cycle  
Gross anatomy and histology of vagina and female external genitalia  
Topography of female genital organs in the pelvis. Connective tissue spaces, peritoneal relations  
Topography of male genital organs in the pelvis. Connective tissue spaces, peritoneal relations  
Anatomy of peritoneum. Lesser and greater omentum. Omental bursa, mesentery.

## **NERVOUS SYSTEM**

Gross anatomy of spinal cord. Spinal segment. Spinal nerve. Blood supply and meninges of the spinal cord  
Microscopic structure of spinal cord  
Spinal proprioceptive reflex arc  
Spinal flexor (withdrawal) reflex arc  
Spinal autonomic reflexes  
Fourth ventricle  
Gross and microscopic anatomy of medulla oblongata  
Gross and microscopic anatomy of pons  
Gross and microscopic anatomy of midbrain  
Cranial nerve nuclei  
Tracts of the brainstem  
Reticular formation and monoaminergic brainstem systems  
Gross and microscopic anatomy of cerebellum  
Afferent and efferent connections of cerebellum  
Anatomy, blood supply and development of the diencephalon  
Third ventricle  
Gross and microscopic anatomy of thalamus  
Hypothalamo-hypophyseal systems  
Gross anatomy of hemispheres  
Gross and microscopic anatomy of basal nuclei  
Lateral ventricles  
Arterial circle of Willis and veins of the brain  
Microscopic structure of cerebral cortex. Cortical areas  
Spinothalamic tract  
Dorsal funiculus-medial lemniscus system  
Pyramidal tract



Extrapyramidal system

Limbic system

Cranial dura mater and its sinuses

Arachnoid and pia mater. Subarachnoid cisterns Cerebrospinal fluid

Central nuclei and peripheral distribution of cranial nerves III., IV., VI.

Nuclei of trigeminal nerve and distribution of ophthalmic nerve

Peripheral distribution of maxillary nerve

Peripheral distribution of mandibular nerve

Central nuclei and peripheral distribution of facial nerve

Central nuclei and peripheral distribution of glossopharyngeal nerve

Central nuclei and peripheral distribution of vagus nerve

Nuclei and branches of accessory and hypoglossal nerves

Cervical plexus

Brachial plexus

Dorsal rami of spinal nerves. Intercostal nerves

Lumbar plexus

Sacral plexus

General structure of autonomic nervous system

Cervical and thoracic part of sympathetic trunk

Abdominal and pelvic part of sympathetic trunk

Cranial parasympathetic

Sacral parasympathetic

# **MAXILLOFACIAL ANATOMY TOPICS FOR THE FINAL EXAMINATION**

- 1. Composition of enamel**
- 2. Amelogenesis**
- 3. Composition of dentin**
- 4. Dentinogenesis**
- 5. Fine structure of the dental pulp**
- 6. Composition and formation of the cementum**
- 7. Parodontium**
- 8. Parts and histology of the gingiva**
- 9. Development of teeth, malformations**
- 10. Eruption of teeth**
- 11. Development of the maxilla and the mandible**
- 12. Development of the face, malformations**
- 13. Frontal section of the oral cavity**
- 14. Gross morphology, histology and development of the primary and secondary palate**
- 15. Gross morphology, histology and development of the tongue**
- 16. Topographical anatomy of the oral diaphragm**
- 17. Morphology of the incisors and the canine teeth**
- 18. Morphology of the premolar teeth**
- 19. Morphology of the molar teeth**
- 20. Dentition and exfoliation**
- 21. Blood supply and innervation of the upper teeth**
- 22. Blood supply and innervation of the lower teeth**
- 23. Temporomandibular joint**
- 24. Muscles concerned with the opening and closure of the mouth**
- 25. Muscles of facial expression and mastication**
- 26. Mechanism of mastication**
- 27. Reflex arc of mastication**
- 28. Morphological background of taste perception (gustatory organ, pathways)**
- 29. Gross morphology and histology of the parotid gland, nidus parotideus**
- 30. Gross morphology and histology of the submandibular gland, submandibular region**
- 31. Gross morphology and histology of the sublingual gland, sublingual region**
- 32. Neuroanatomy of trigeminal pain**
- 33. Autonomic innervation of the salivary glands**