



Helyreállító sebészet




**„Minden műtét, mely
veleszületett vagy szerzett
betegség, baleset vagy sebészi
beavatkozást követően
visszamaradt szövethiány,
fejlődési rendellenesség és
mozgászavar megszüntetését,
helyreállítását célozza, a
sebészet egy külön ágát képezi,
melyet helyreállító sebészetnek
nevezünk.”**

Helyreállító sebészeti módszerek alkalmazása szükséges:

- különböző maxillofaciális tumorok gyógyításakor
- maxillofaciális sérültek ellátásakor, balesetektől eredő szövethiányok pótlásakor
- különböző fejlődési rendellenességek okozta szövethiányok, deformitások primer és secunder rekonstrukciójához
- funkciókiesések helyreállításakor

Esztétika



Rágás


Beszéd



TUMOR



Orbita tumor



Orbita tumor

Enucleatio

+ orbita exenteratio

+ maxilla resectio

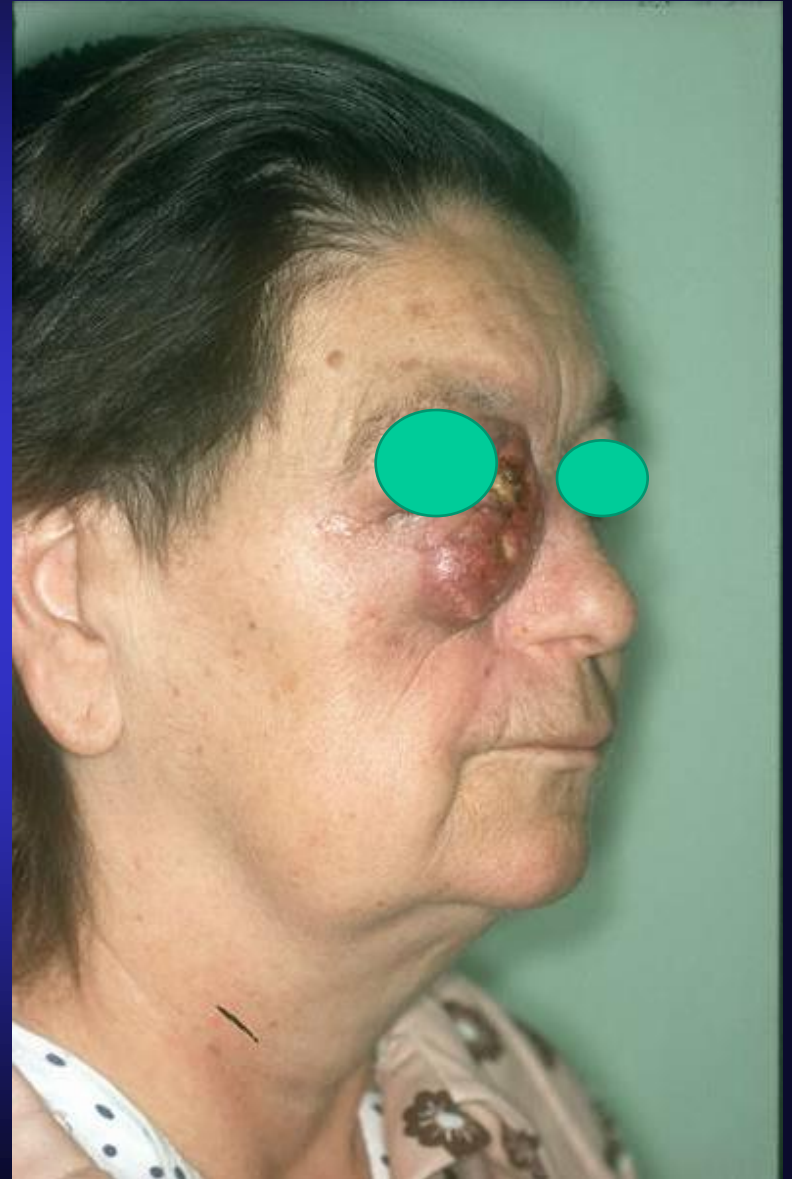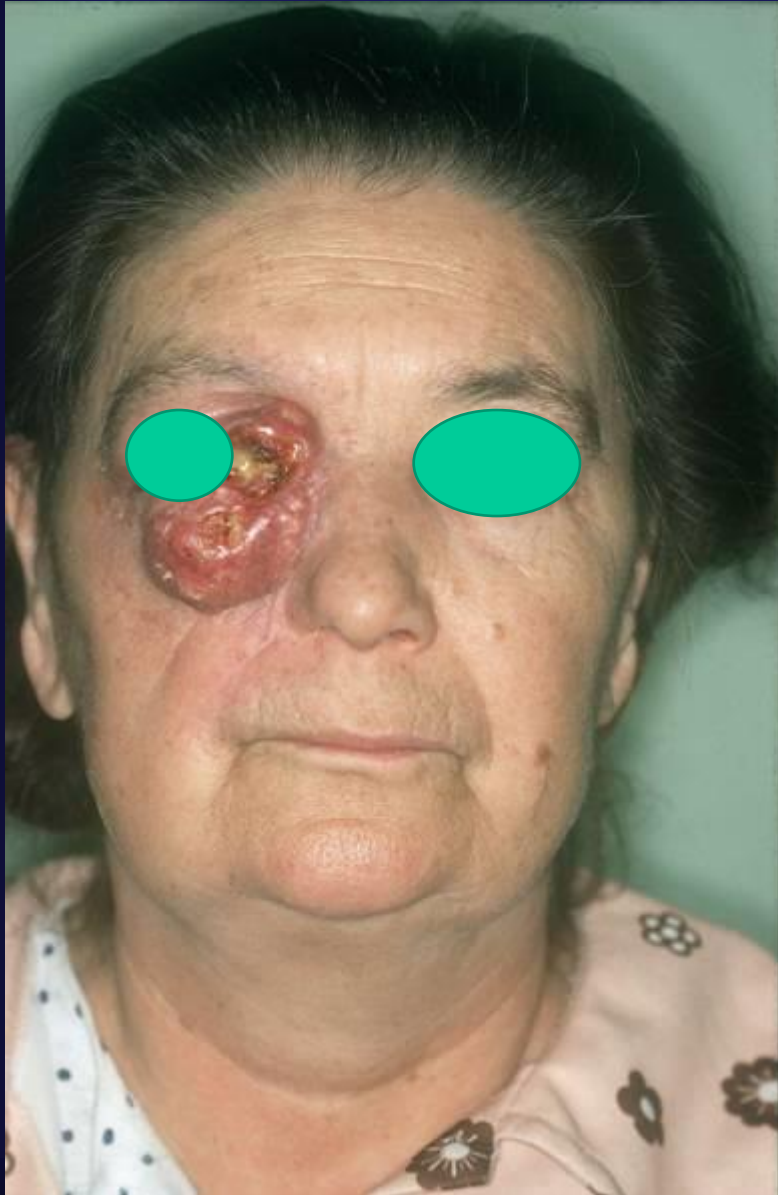Reconstructio

elforgatott musculus
temporalis lebennyel

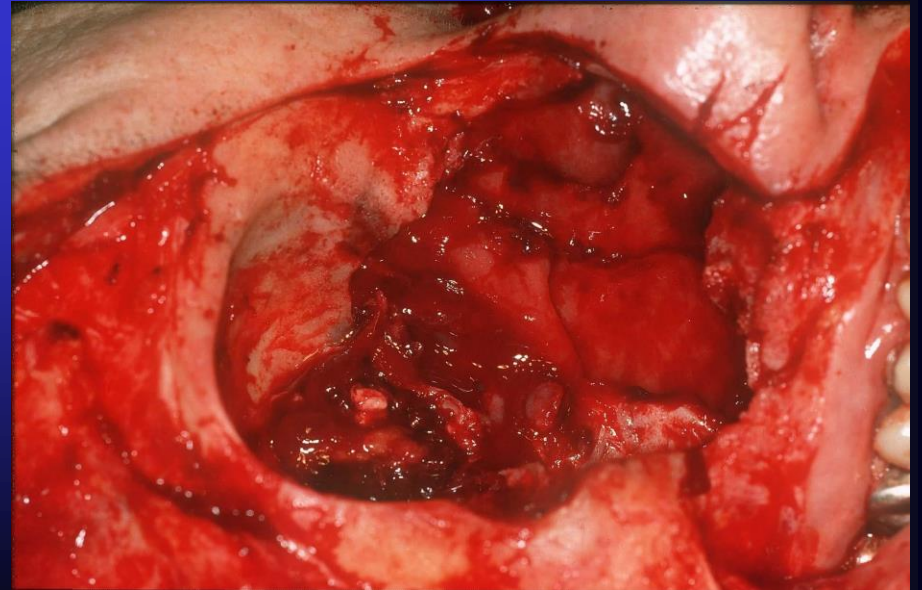
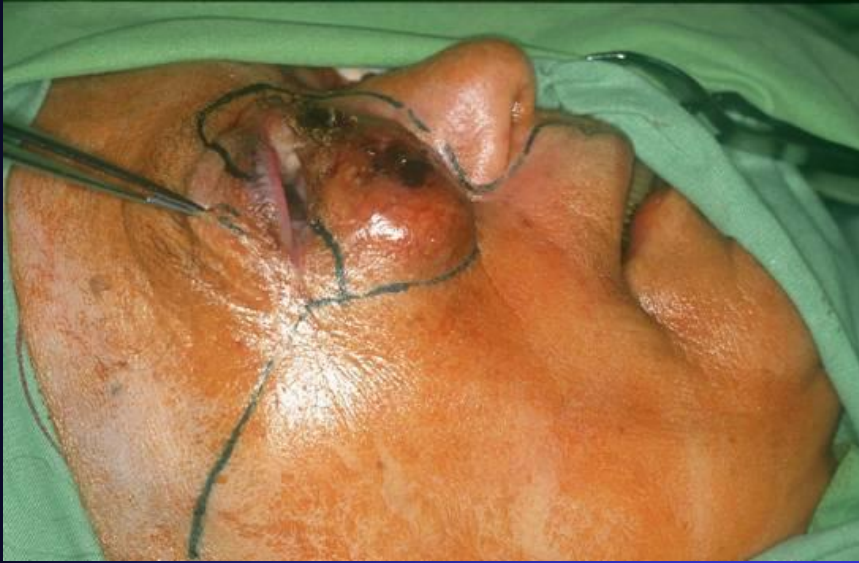+ arteria radialis fascio-
cutan alkarlebennyel

(„kínai lebeny”)

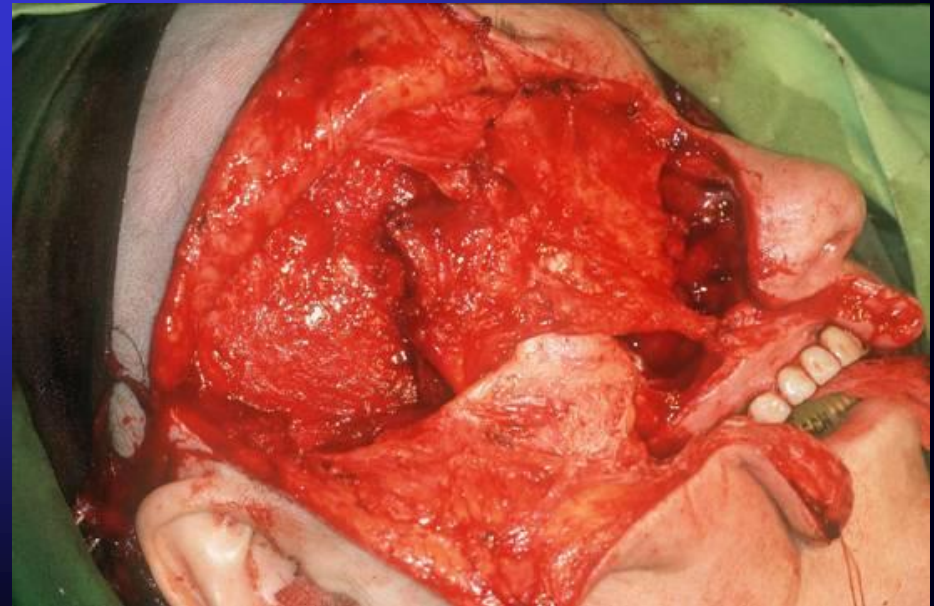
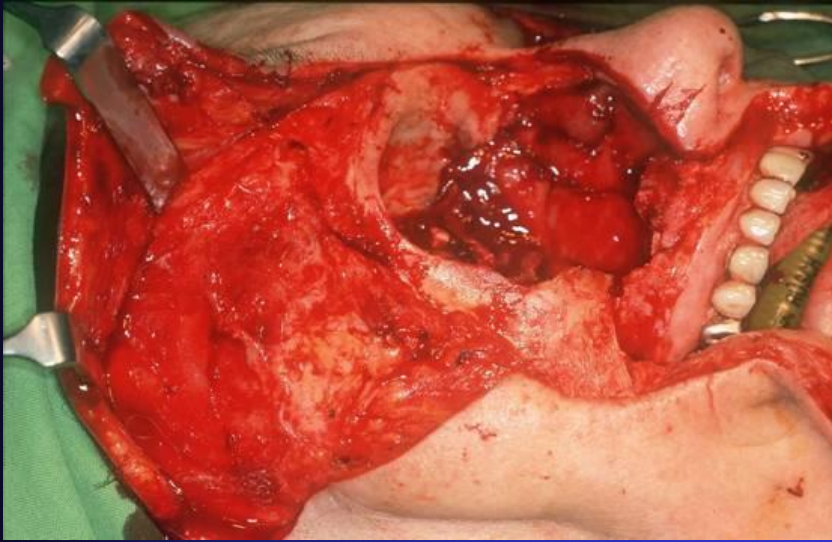Orbita tumor



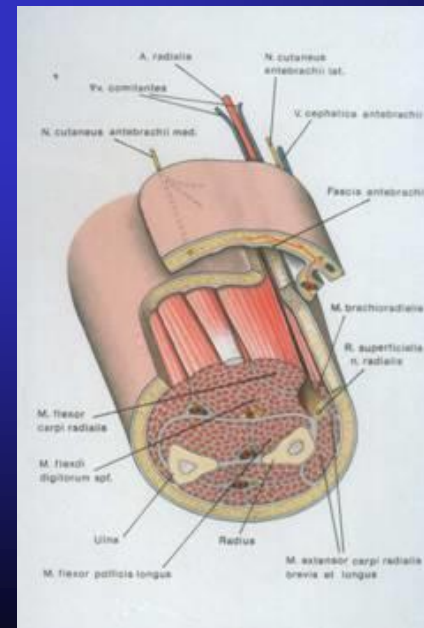
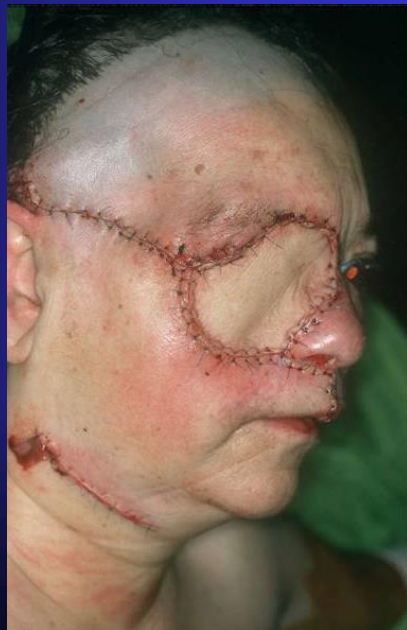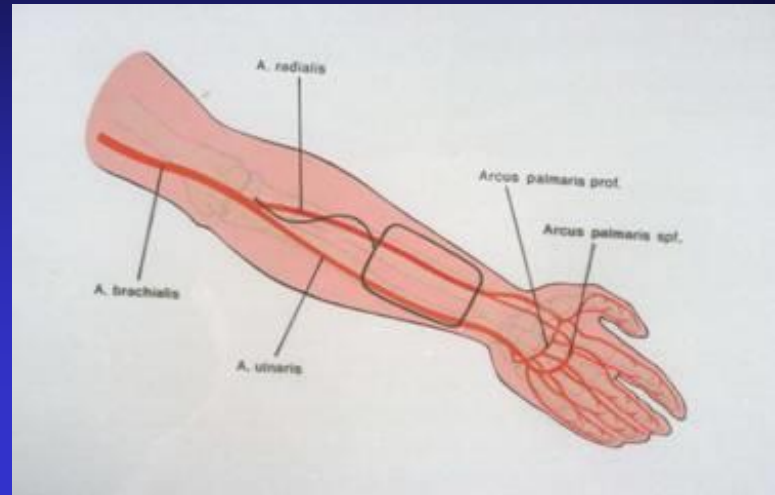
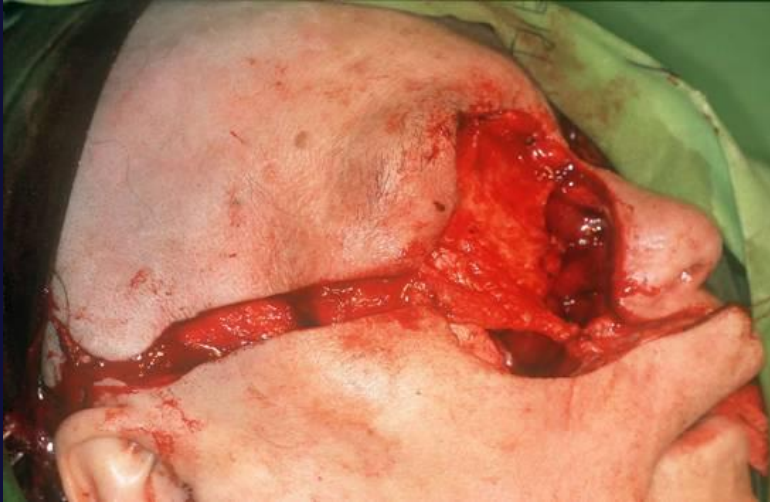Orbita tumor



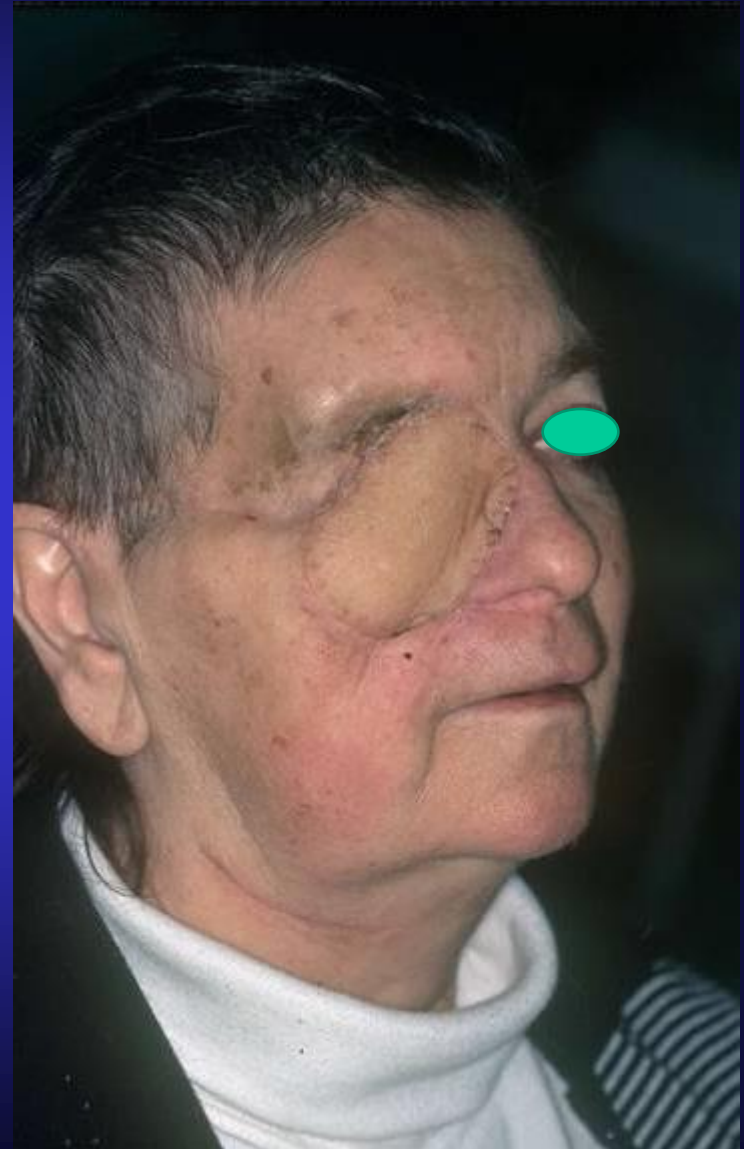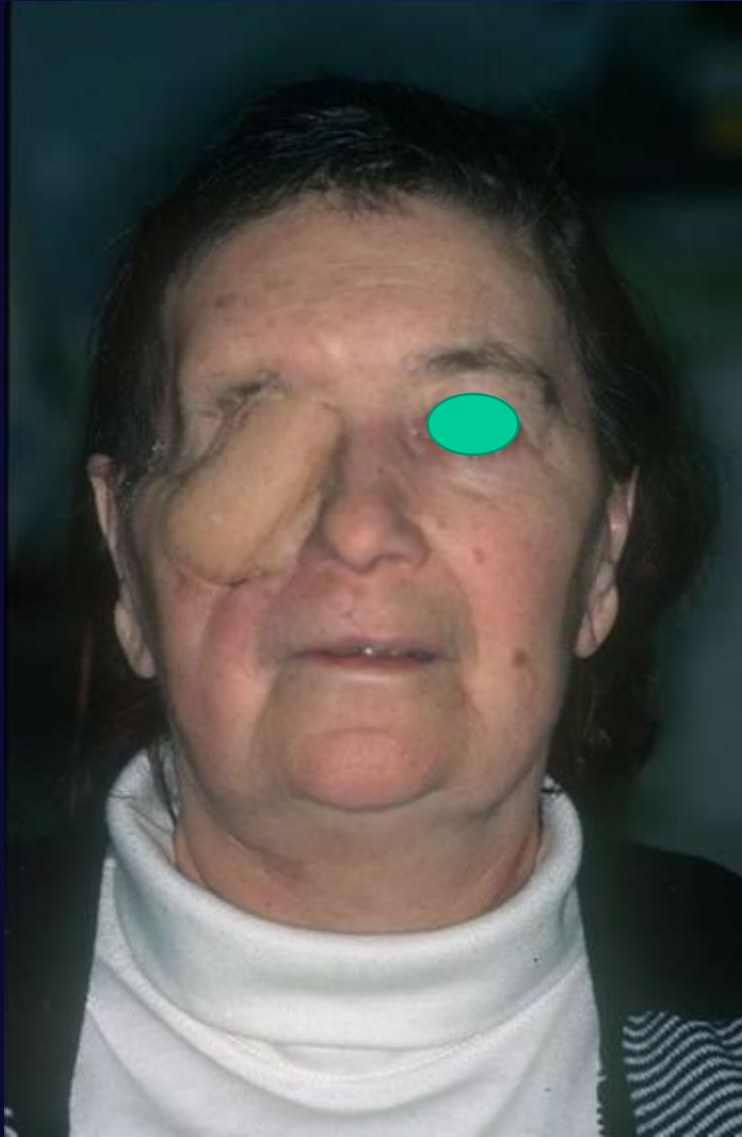Orbita tumor



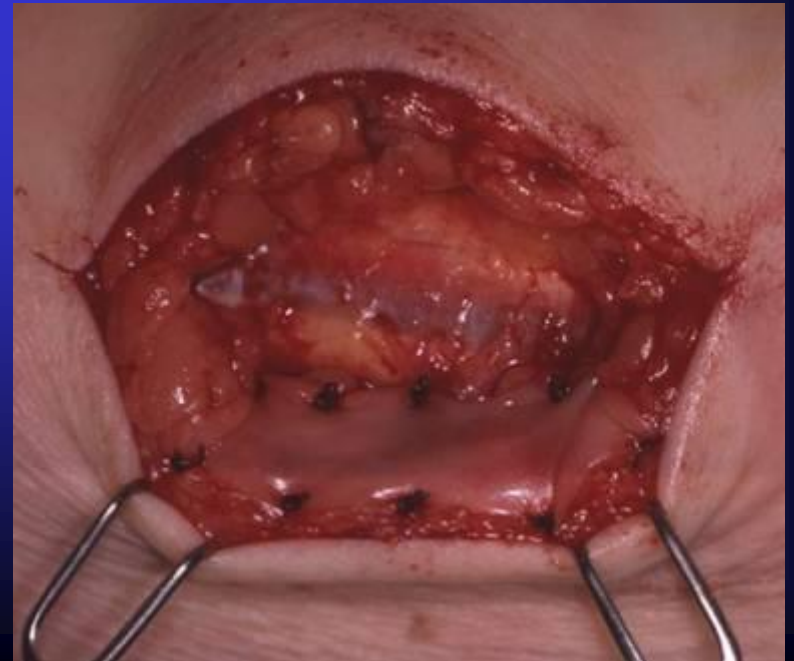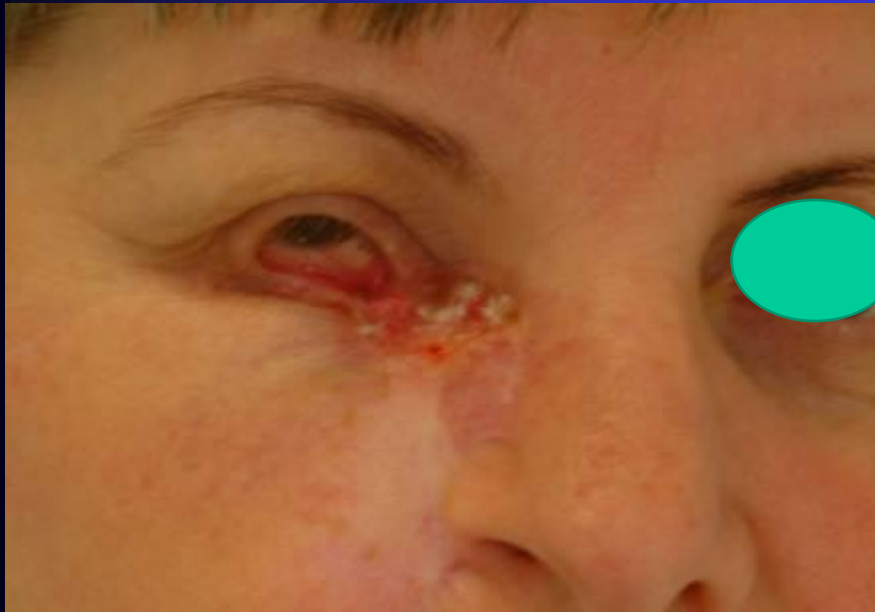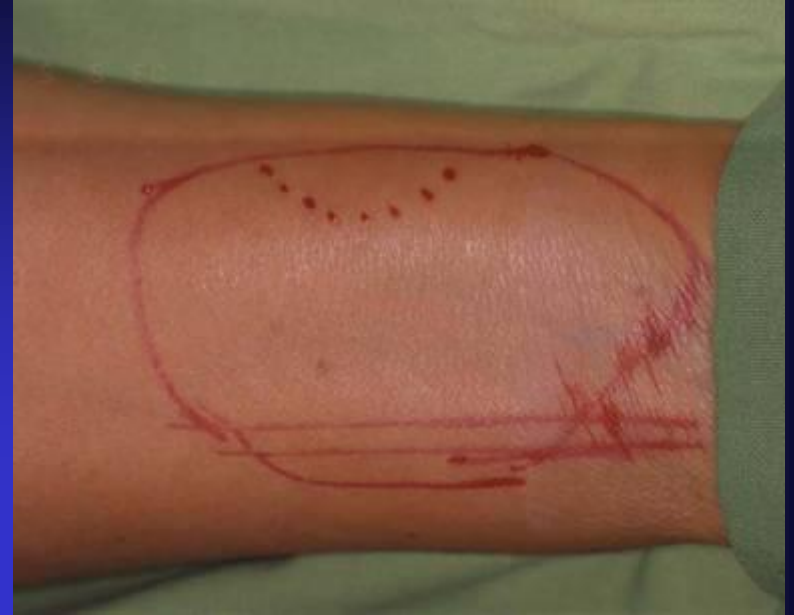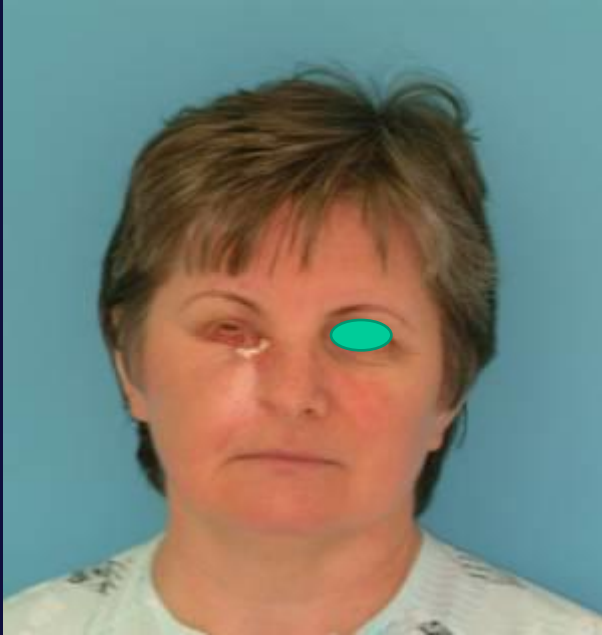Orbita tumor



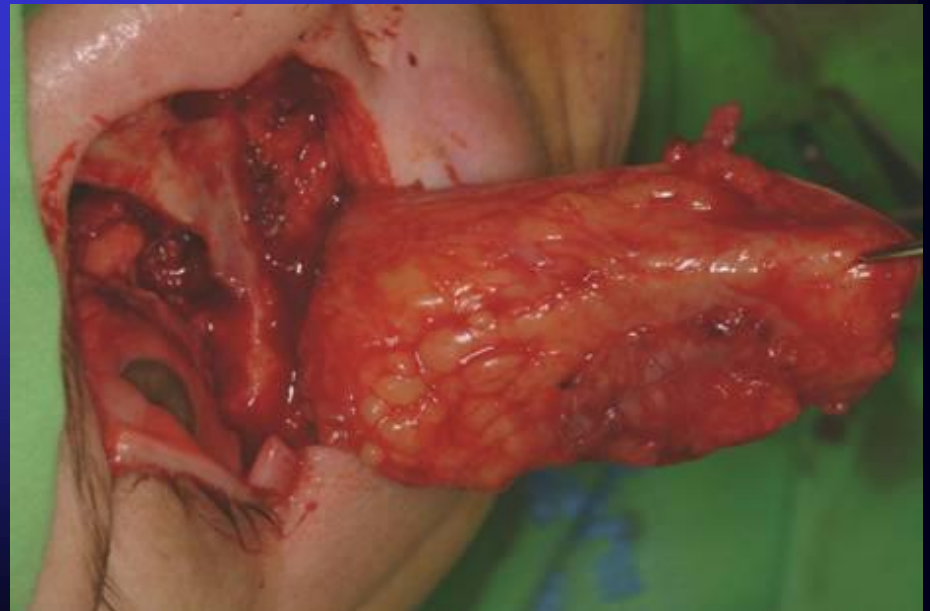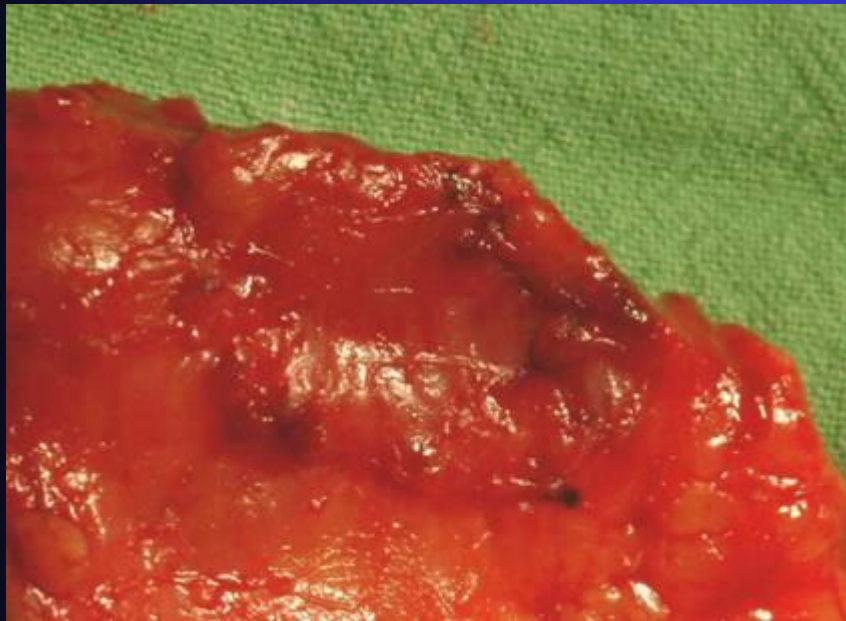
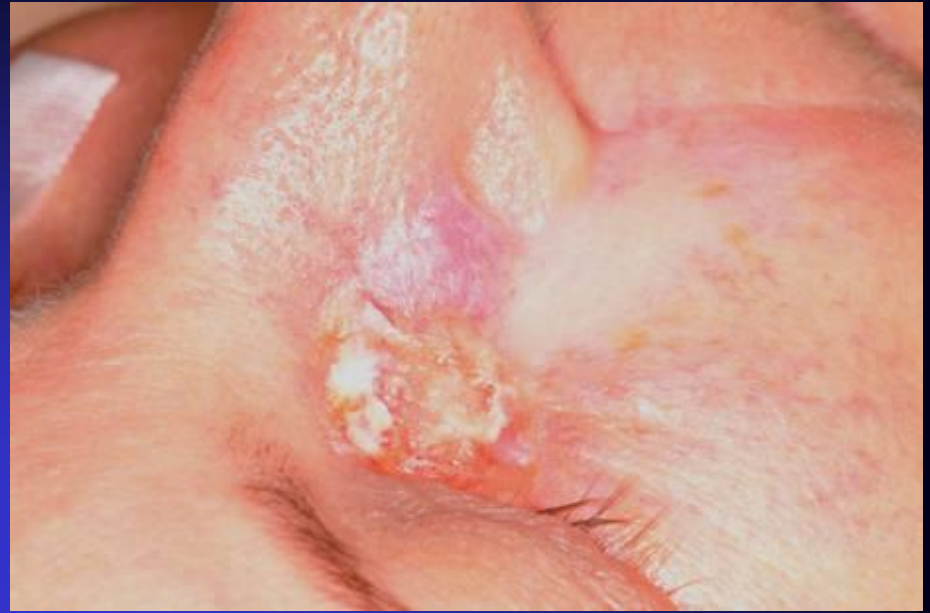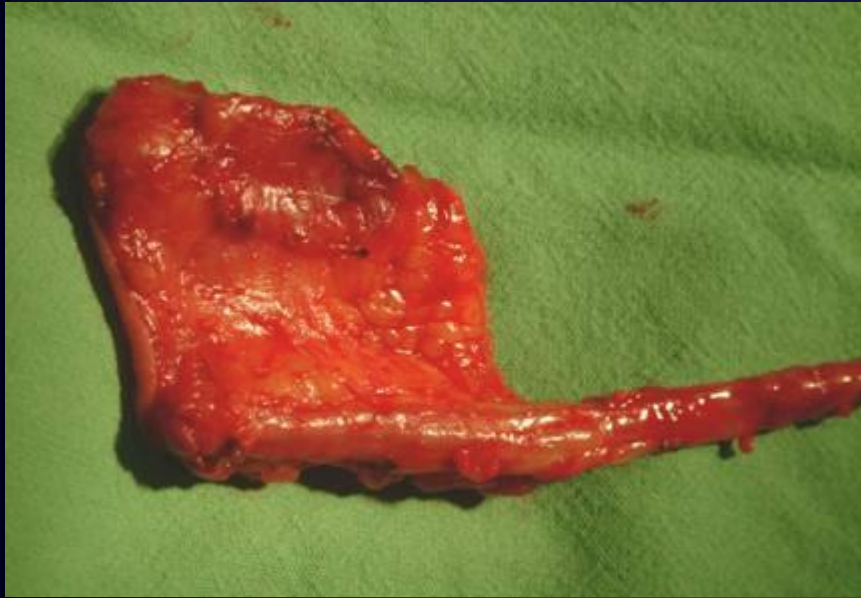Orbita tumor



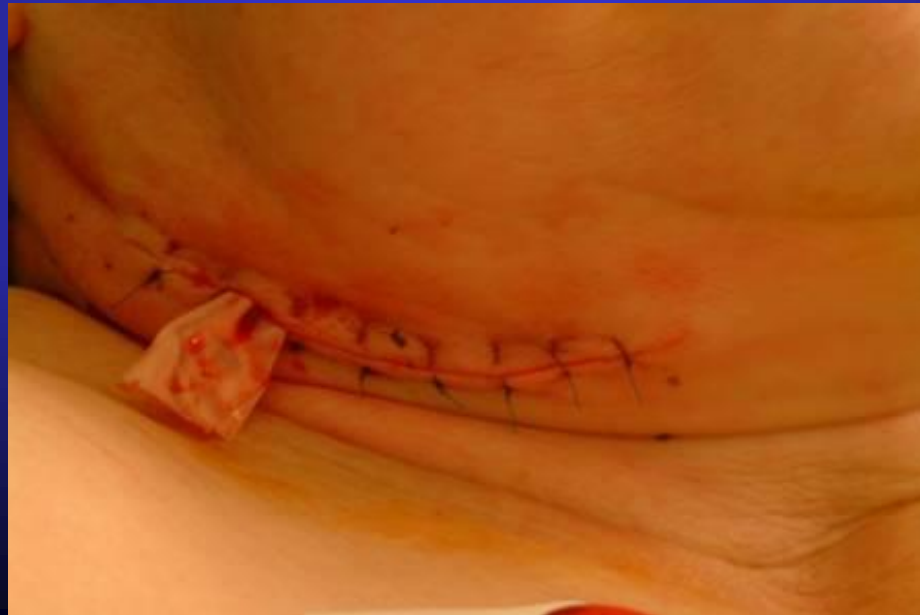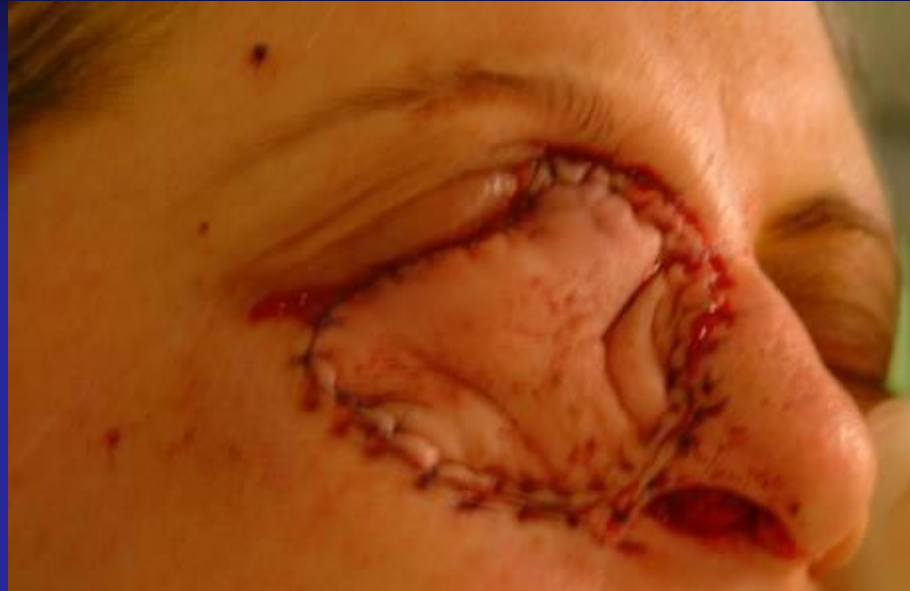Orbita tumor



Orbita tumor



Orbita tumor





Orr-alap - praemaxilla - felsőajak tumor műtét utáni defektus

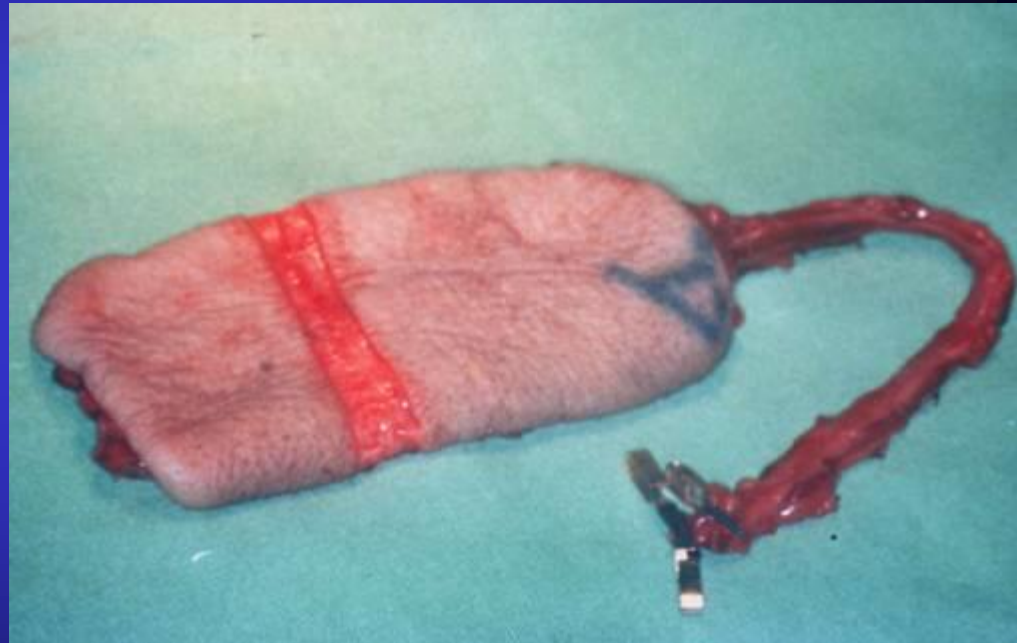
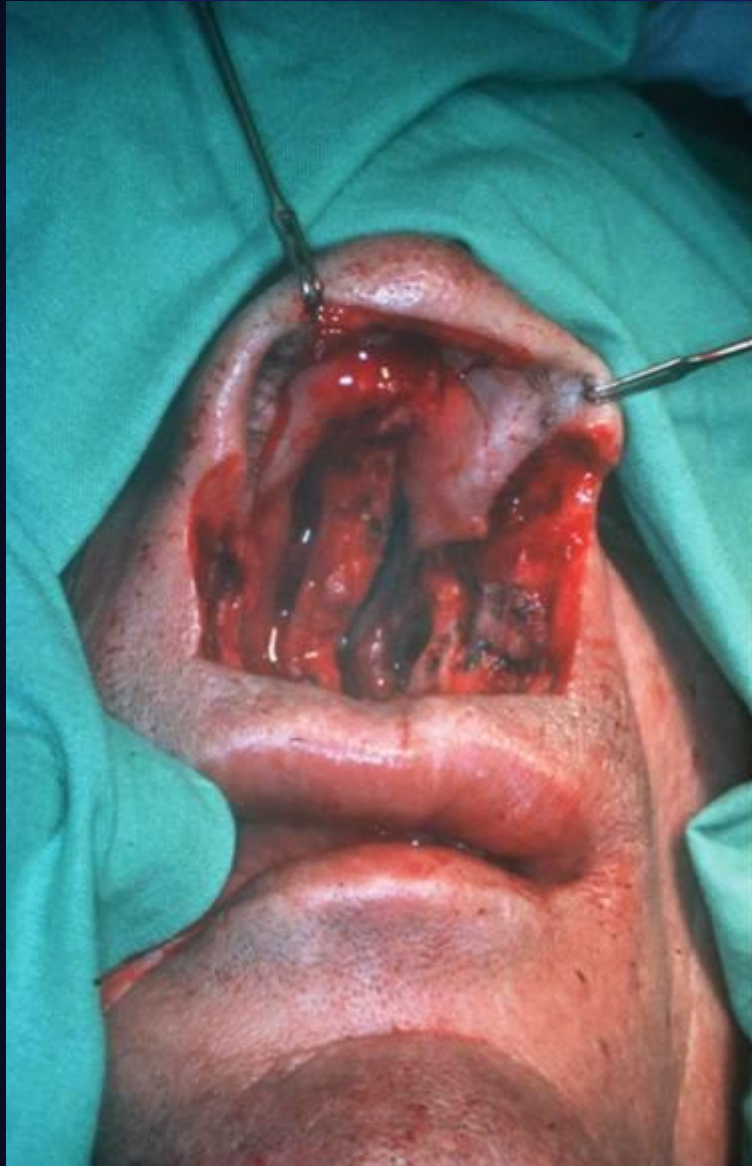
Orr-alap - praemaxilla - felsőajak tumor

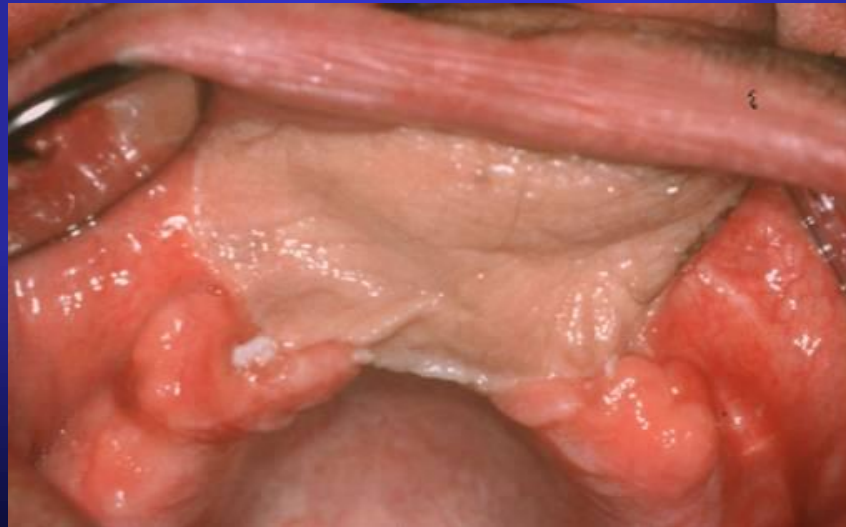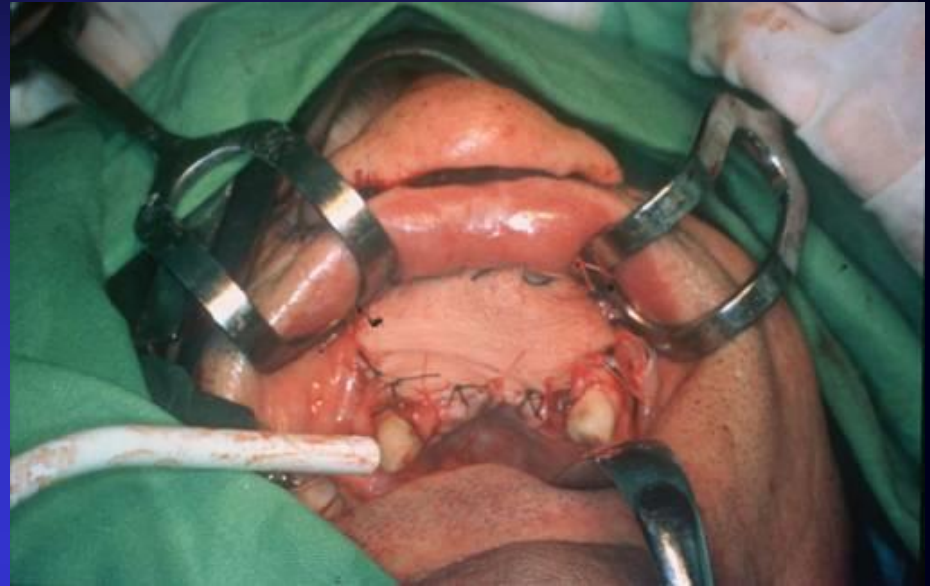
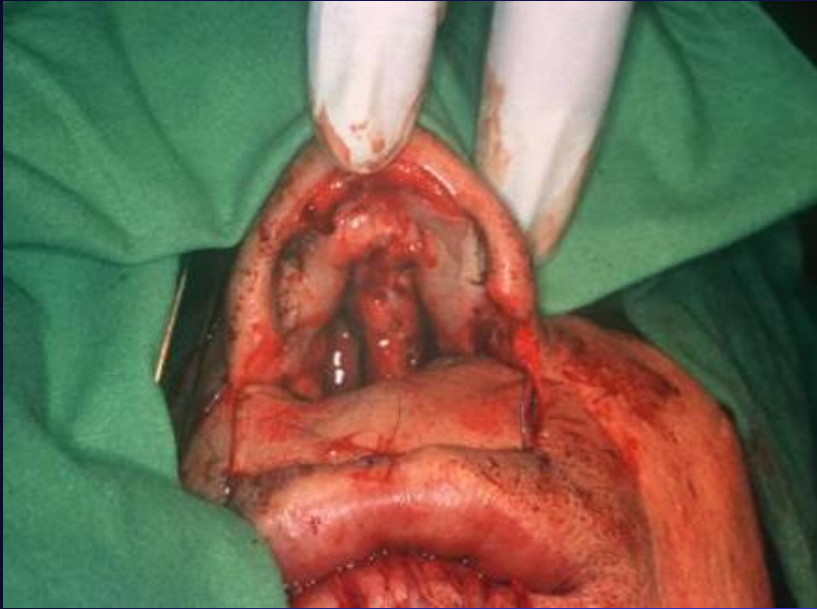**Rekonstrukció
arteria radialis
alkarlebennyel**

**Az ajak funkciójának
megőrzése céljából a
musculus orbicularis oris
folytonosságát
megtartottuk**

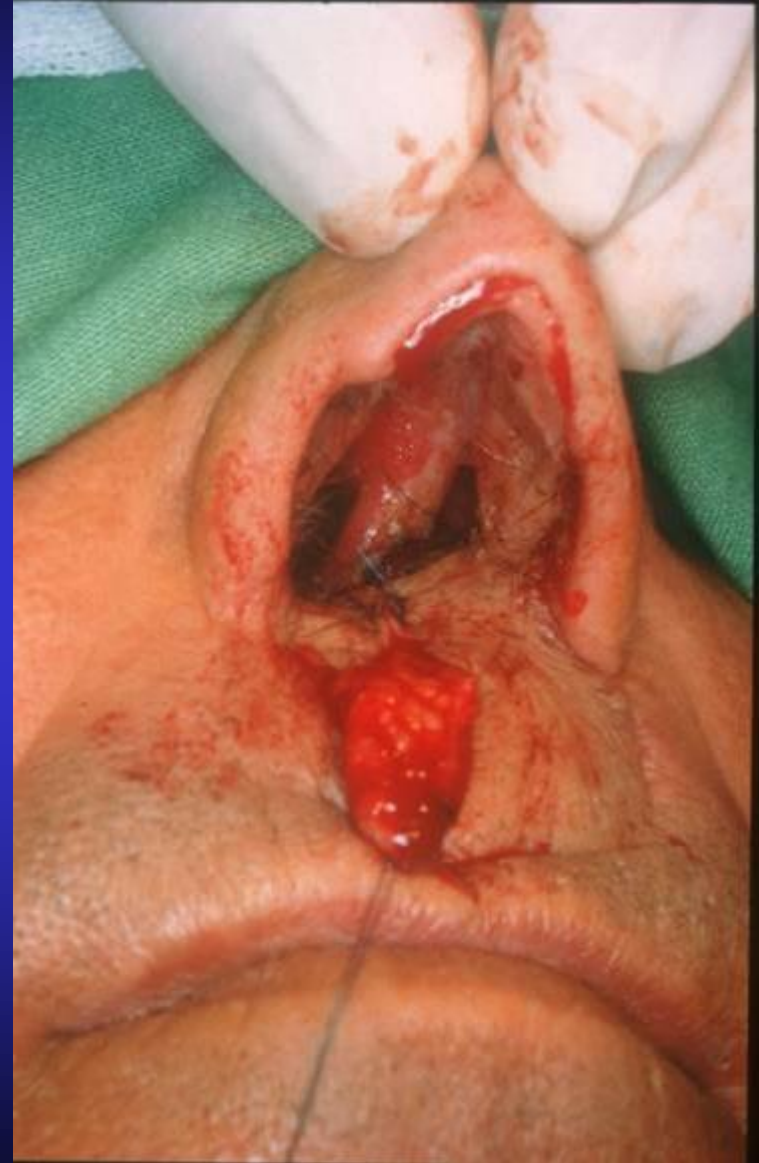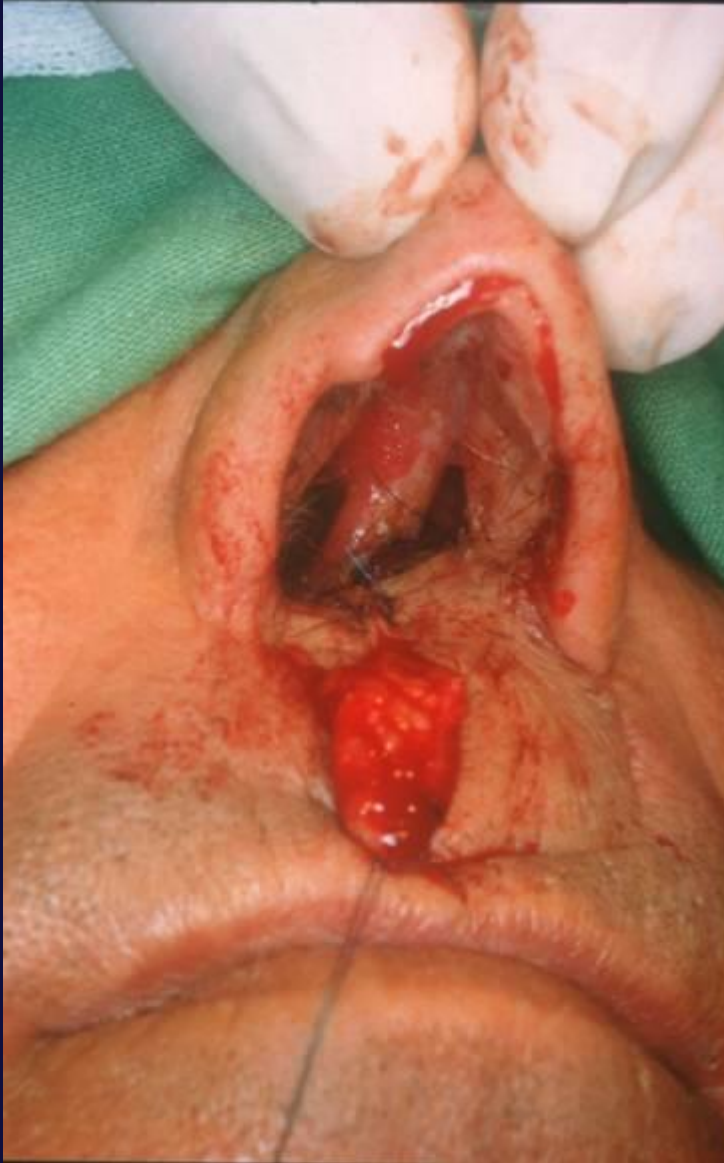Orr-alap - praemaxilla - felsőajak tumor



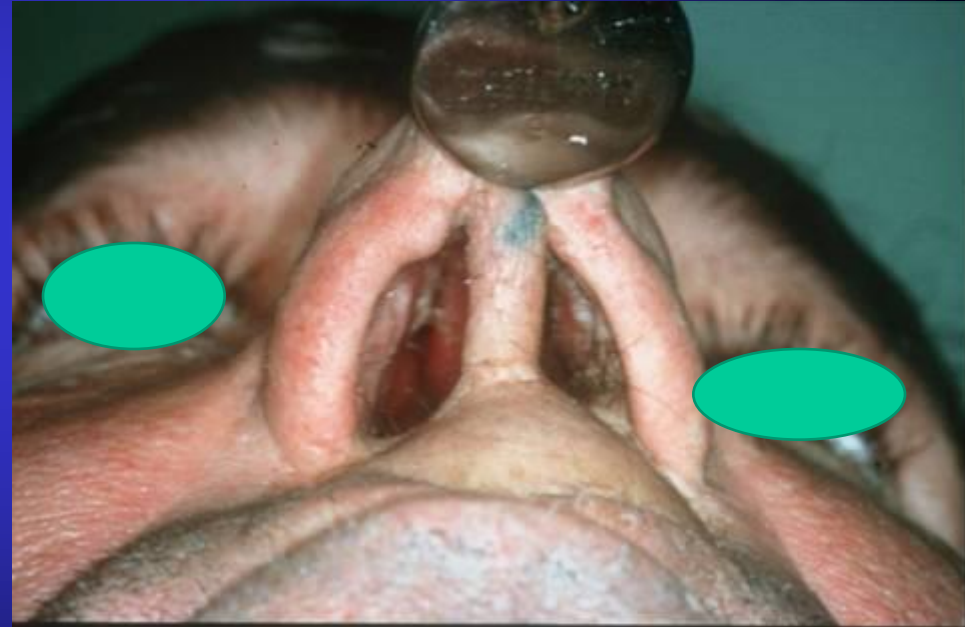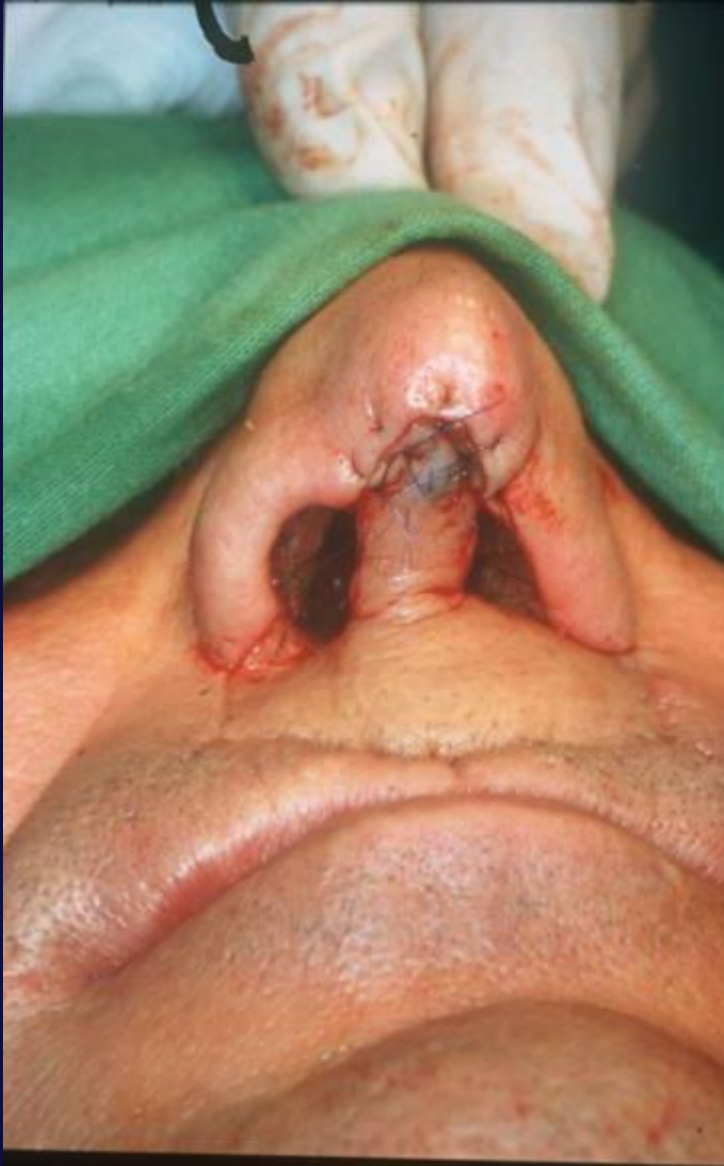Orr-alap - praemaxilla - felsőajak tumor



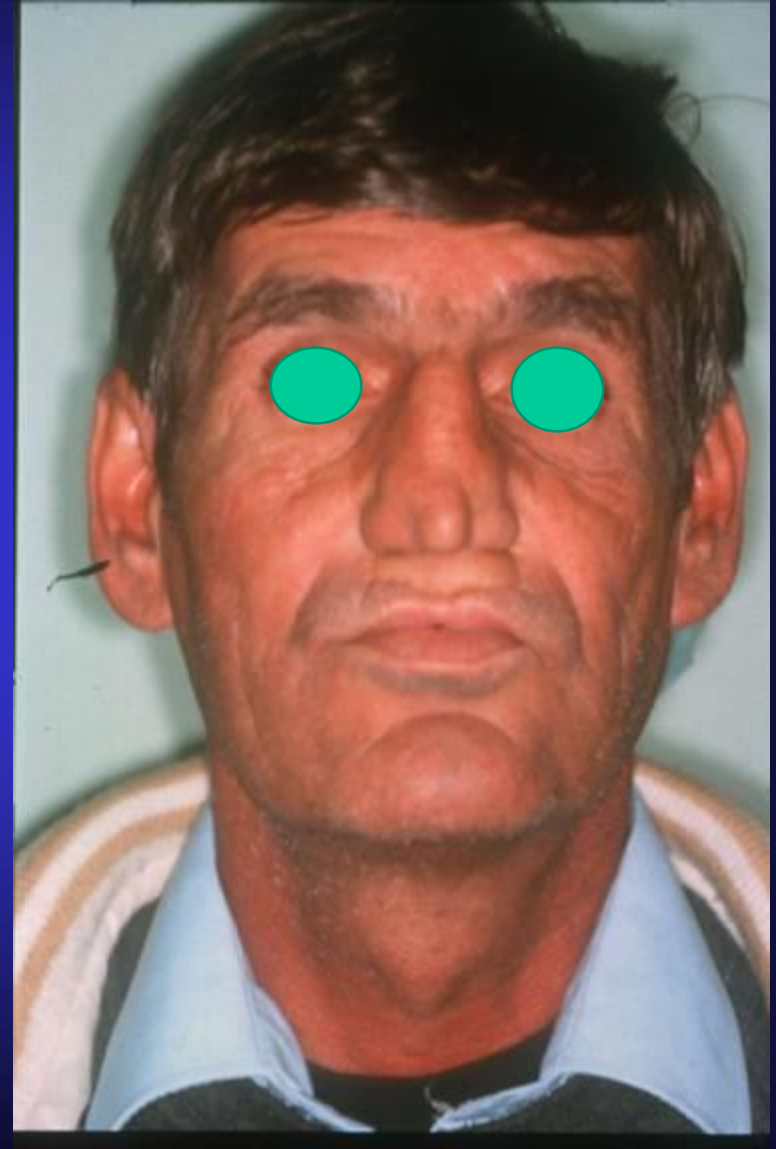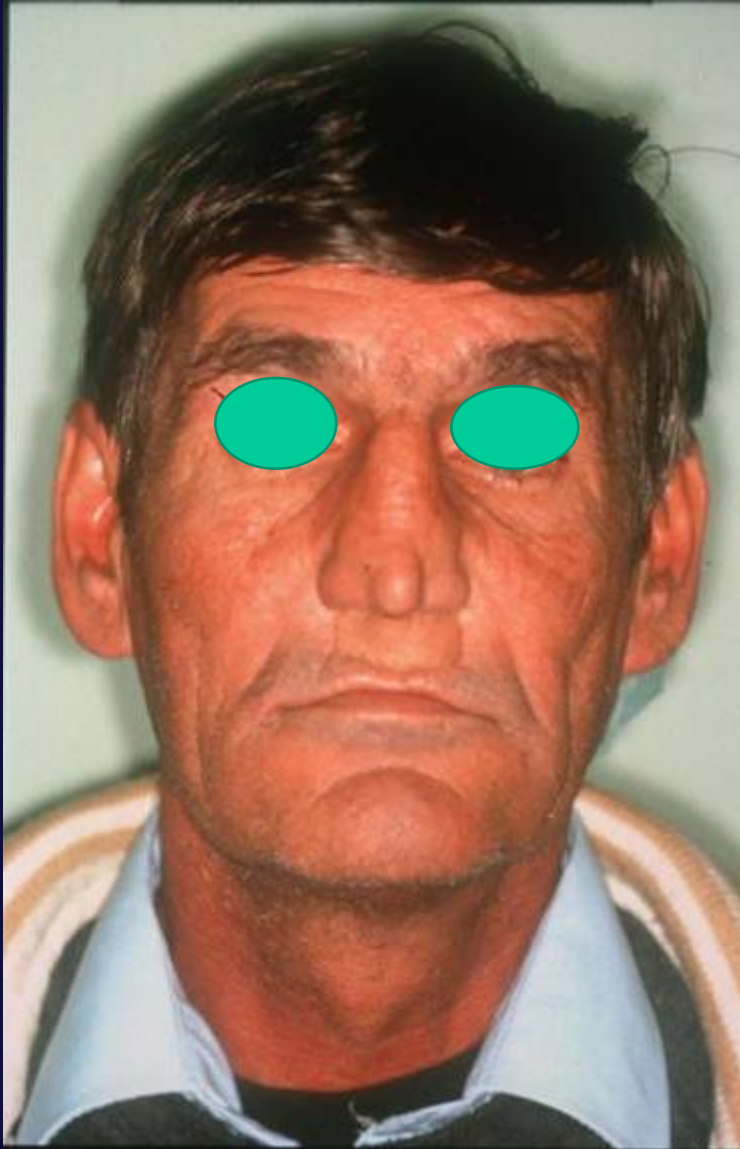Orr-alap - praemaxilla - felsőajak tumor



Orr-alap - praemaxilla - felsőajak tumor



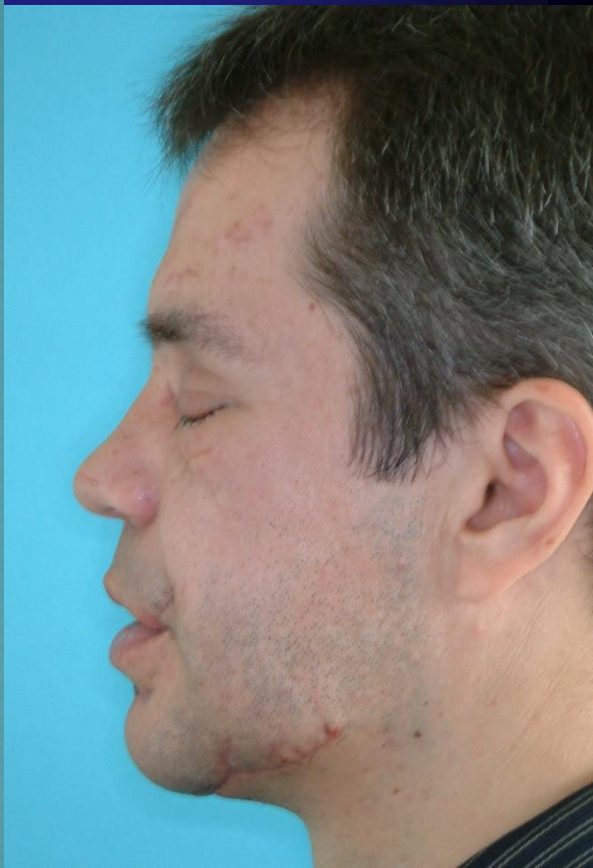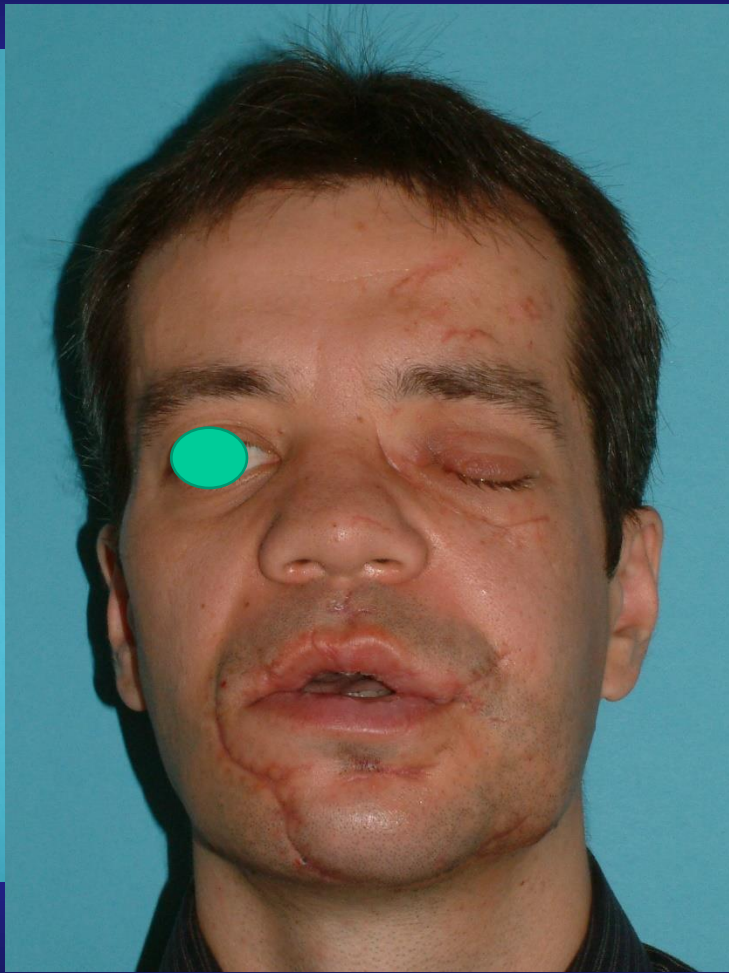
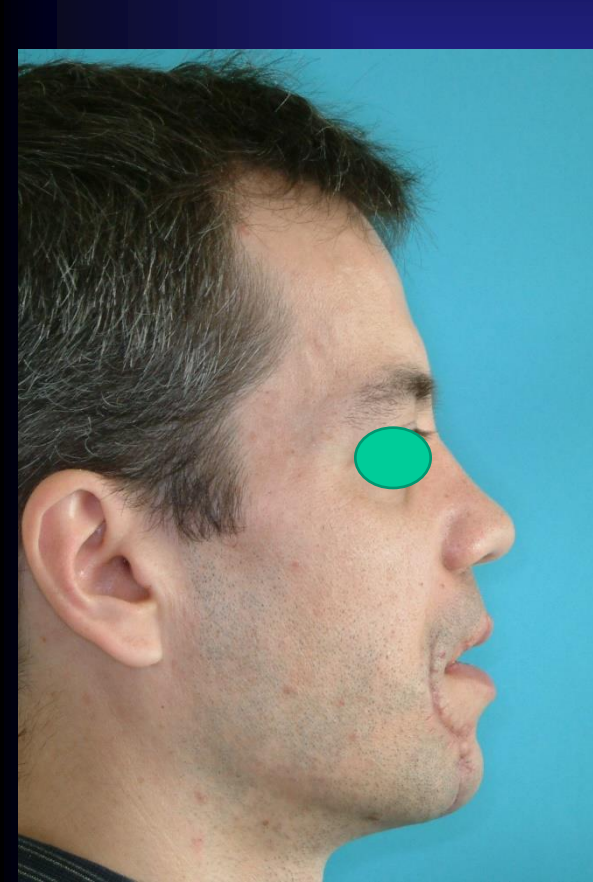
Orr-alap - praemaxilla - felsőajak tumor

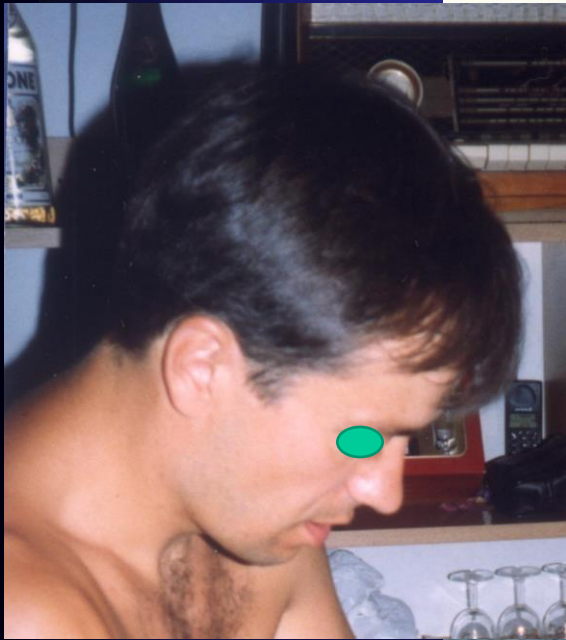
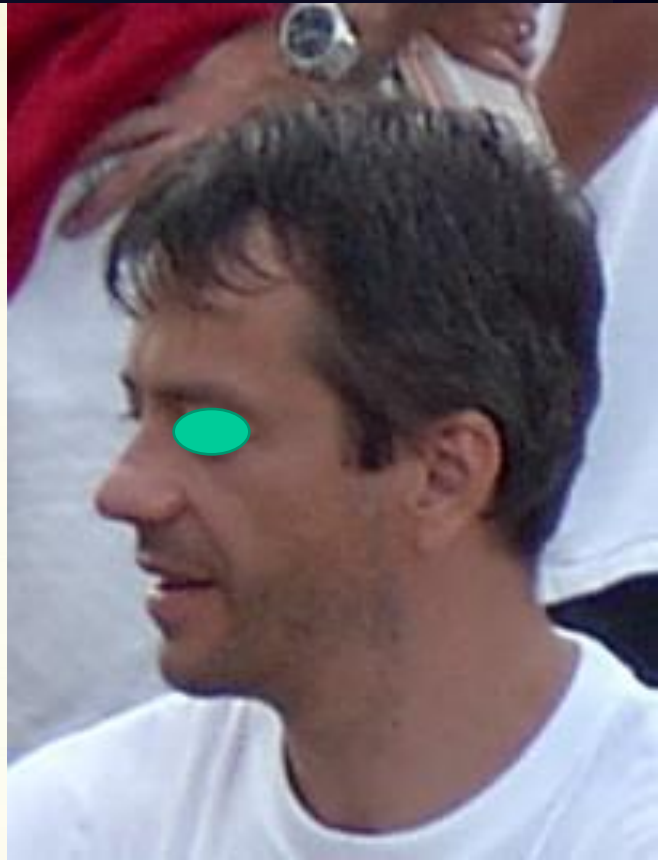
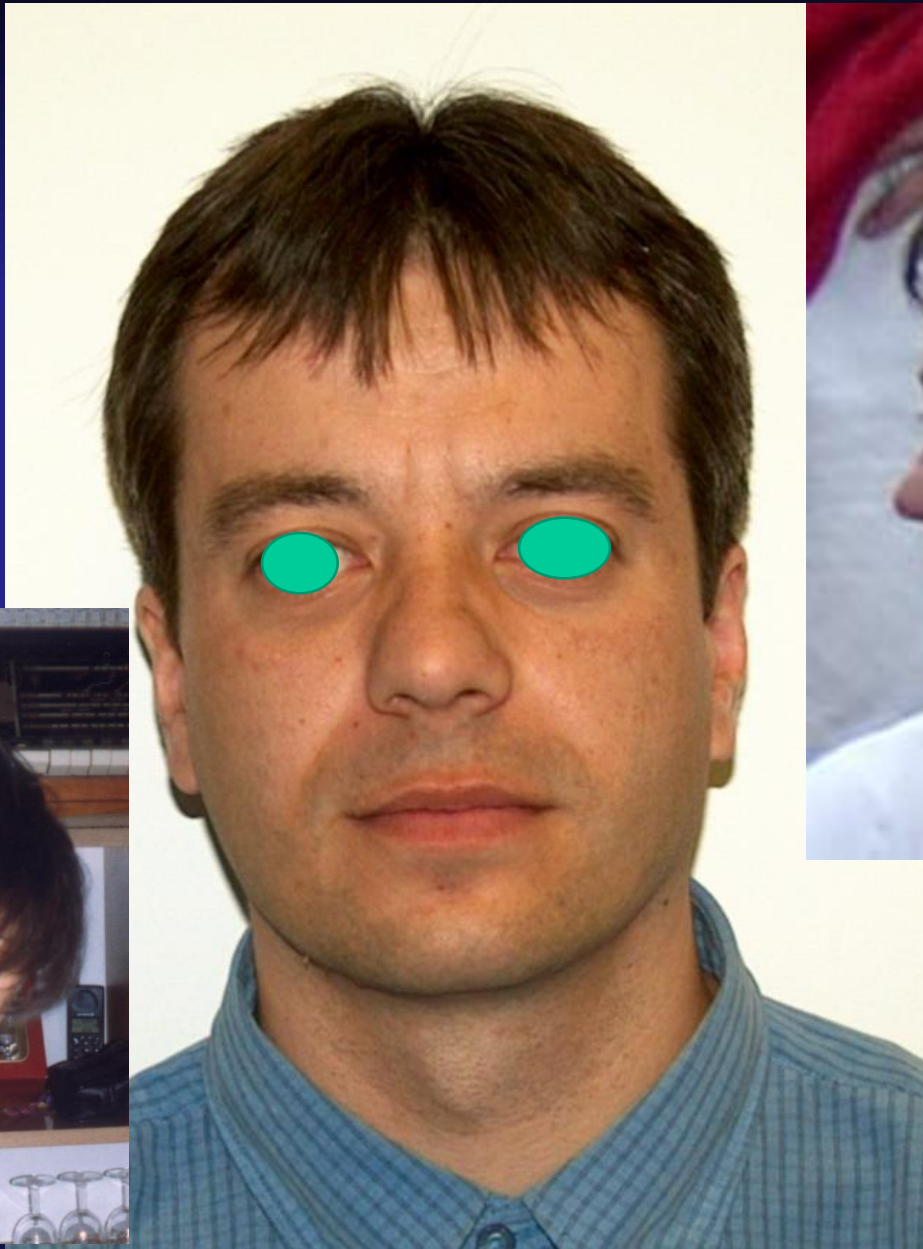
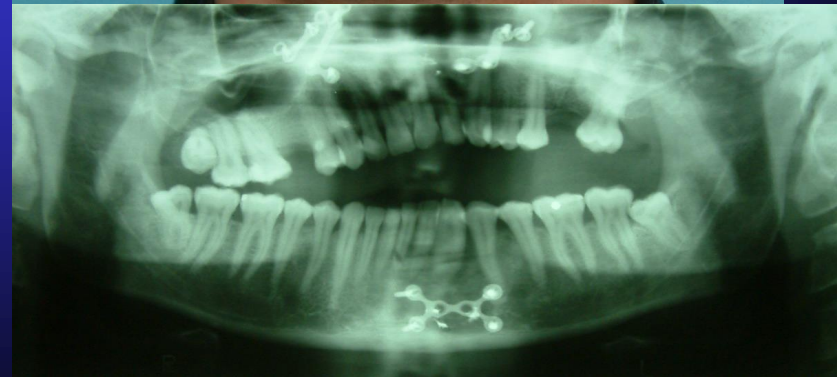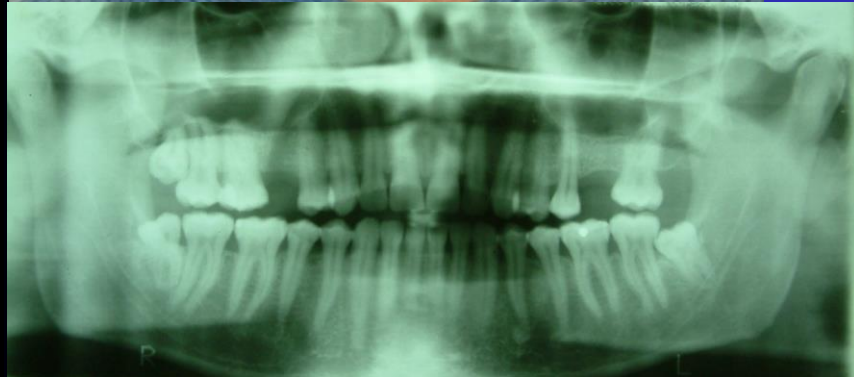
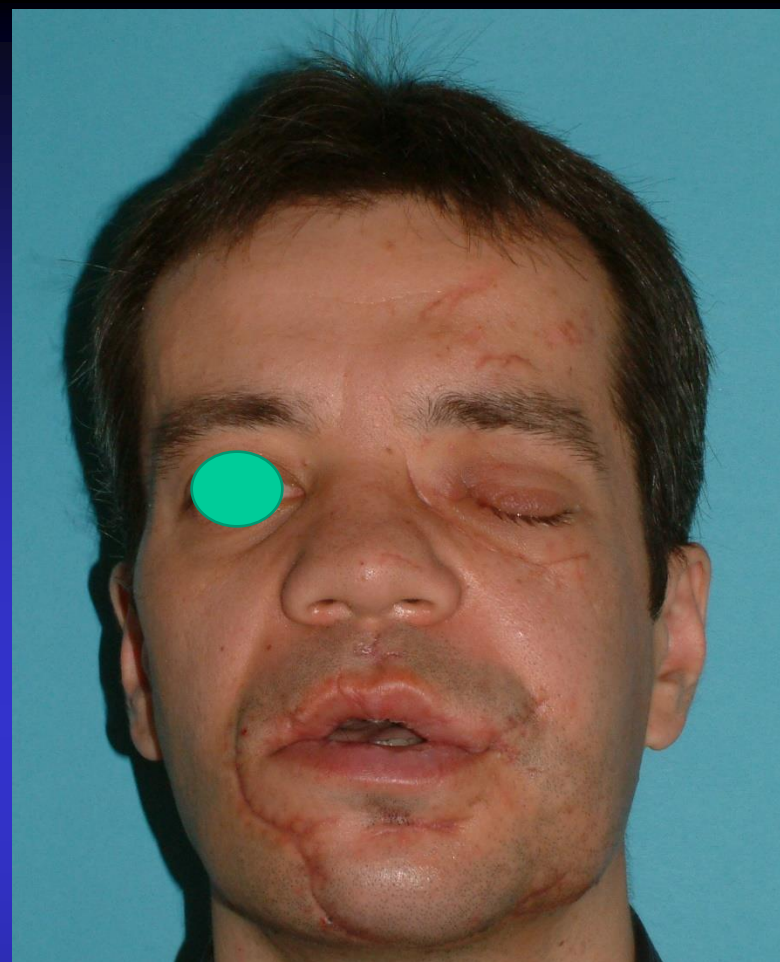
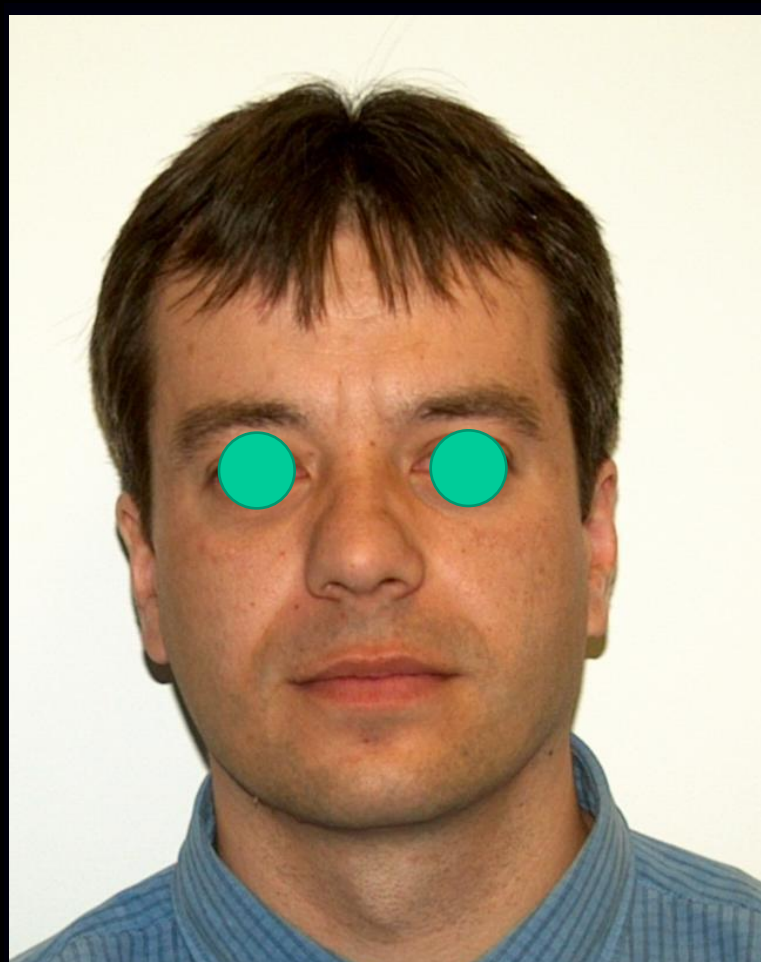


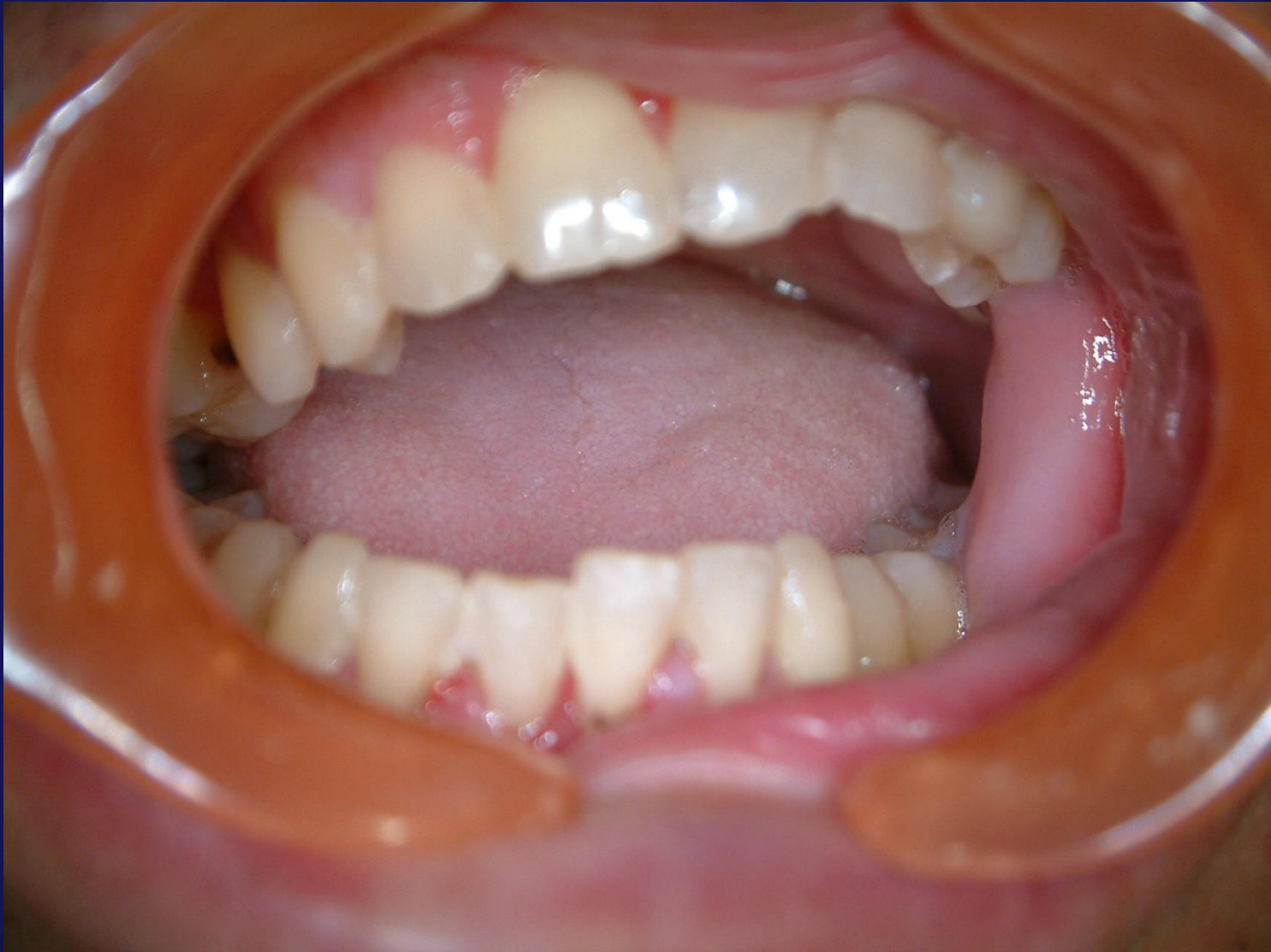
TRAUMA

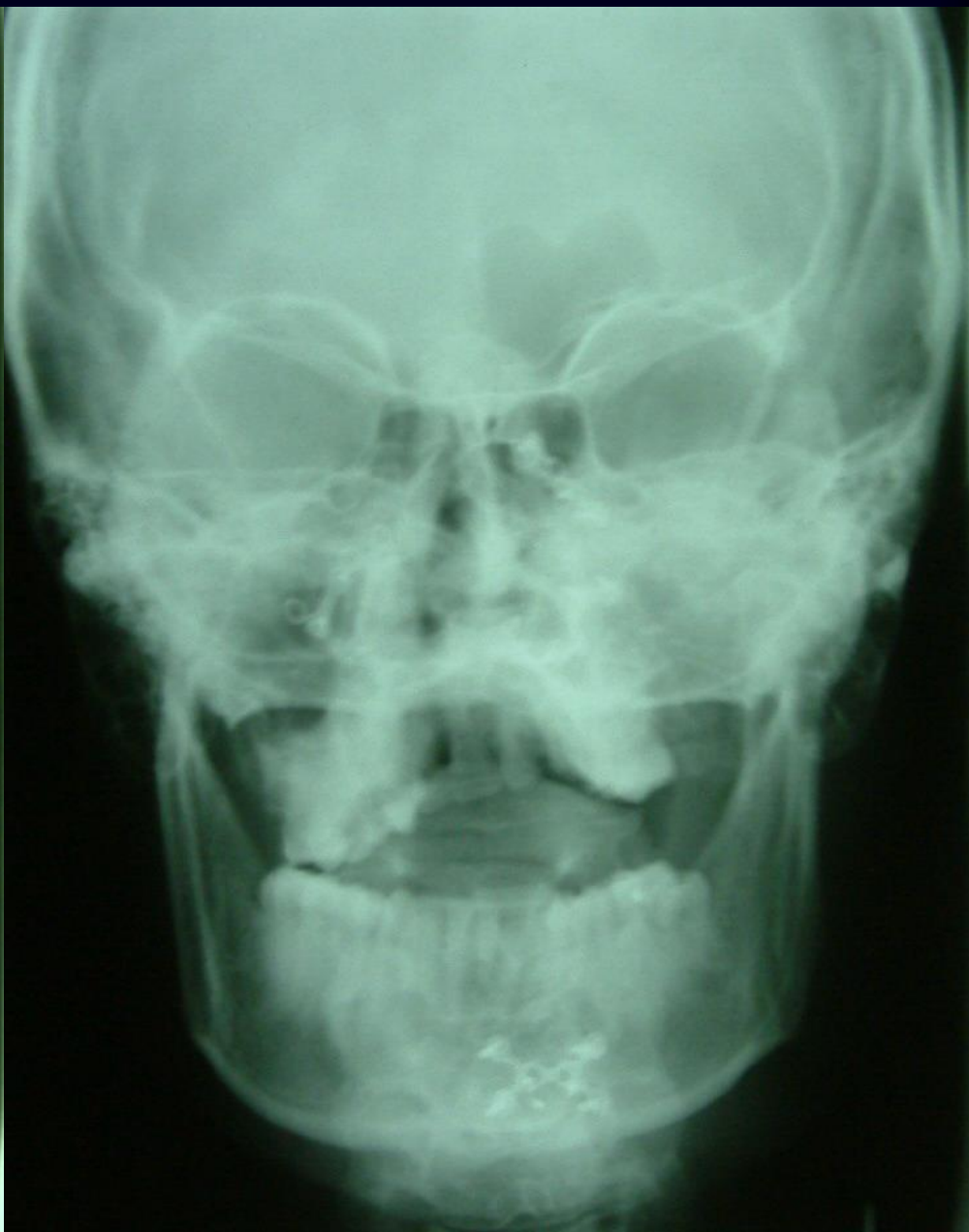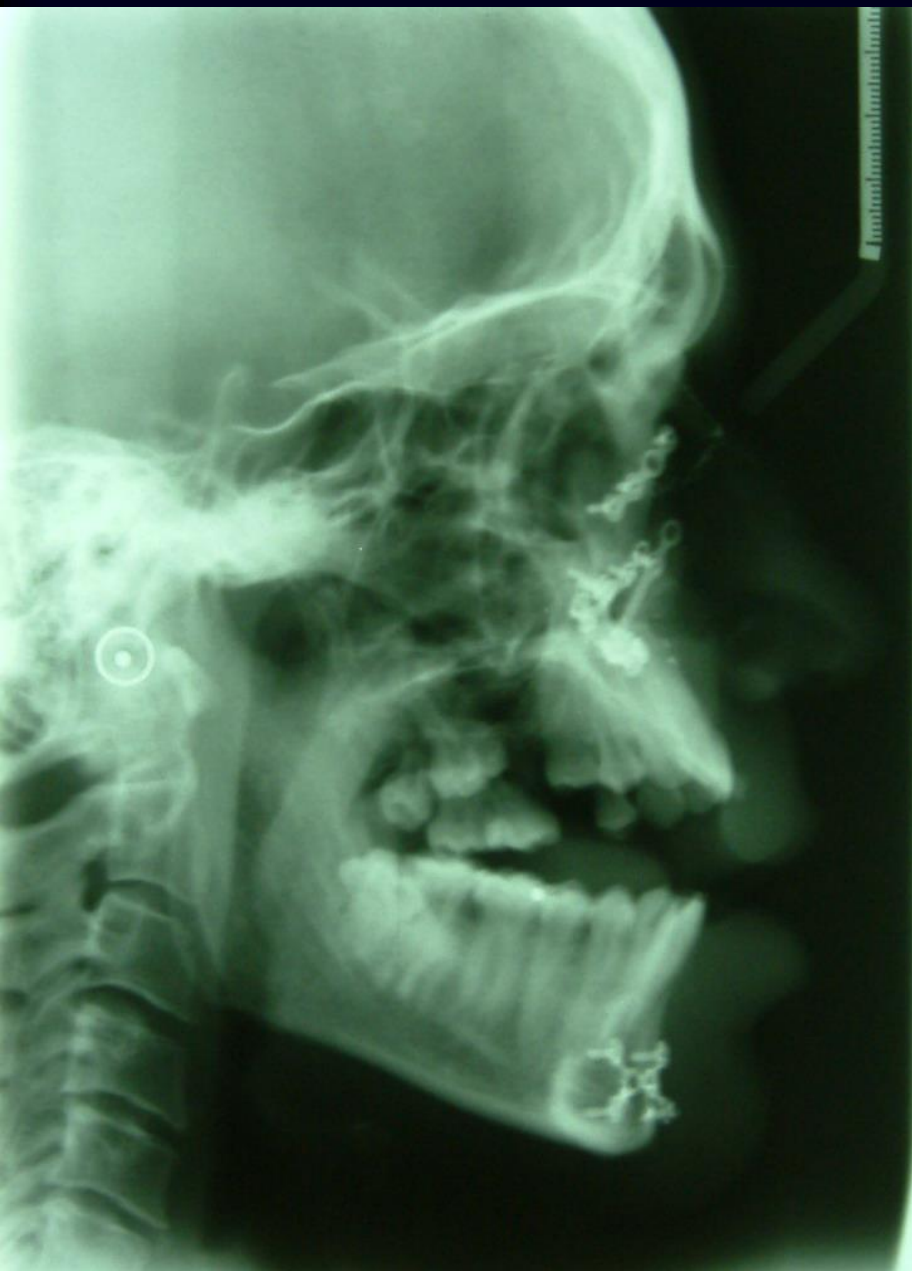**Többszörös osteotomia +
osteodystractio
(arc romtörés utáni állapot)**

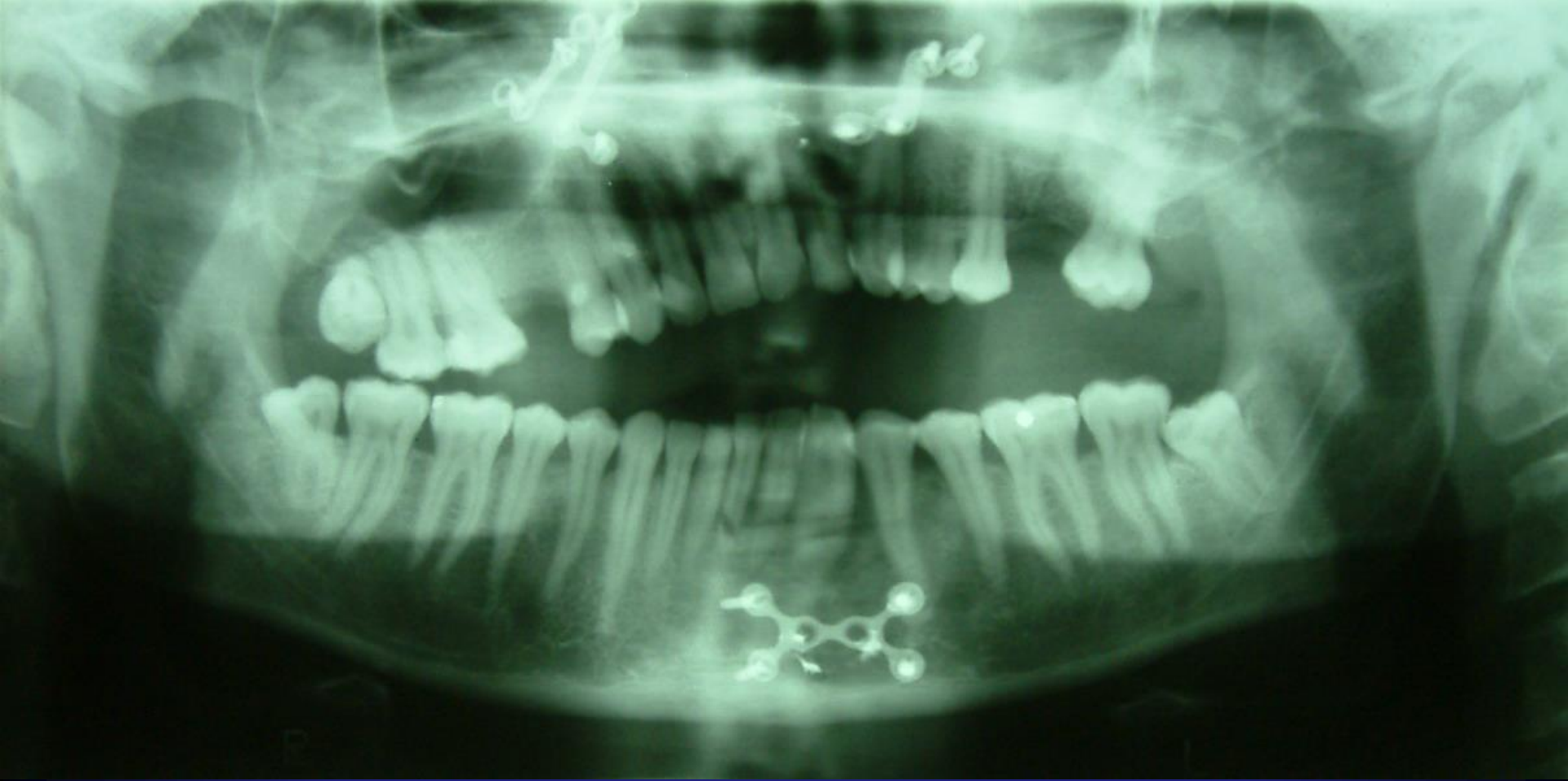


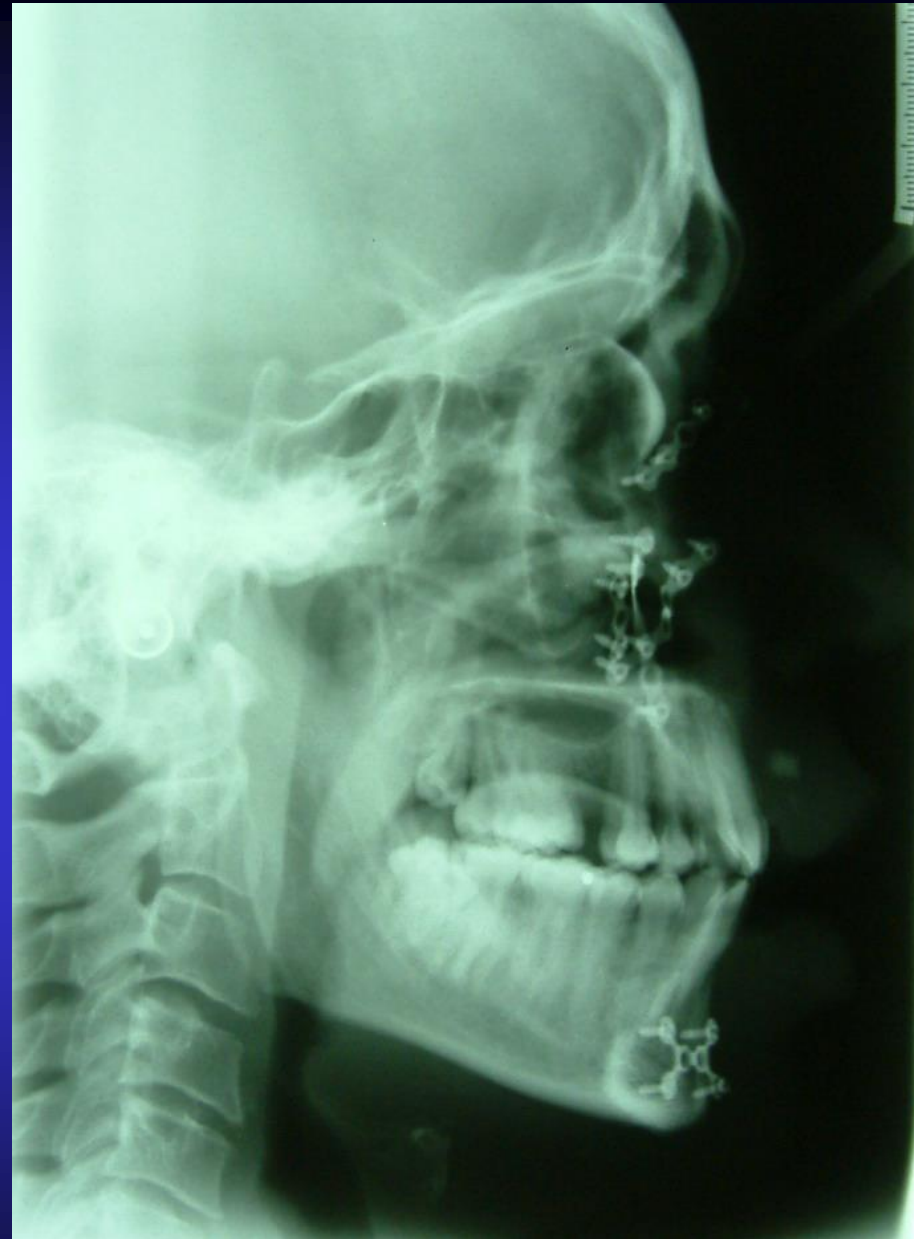
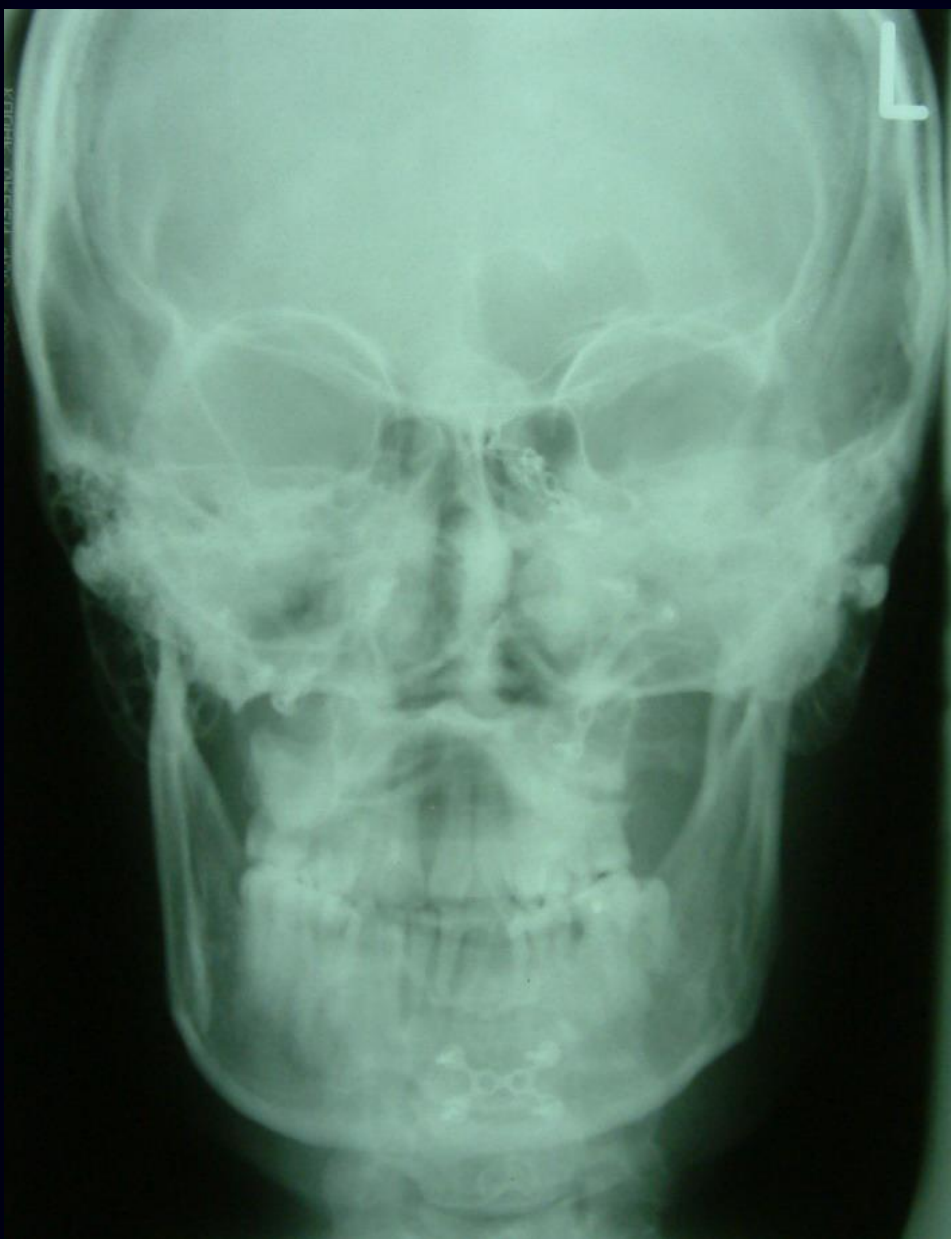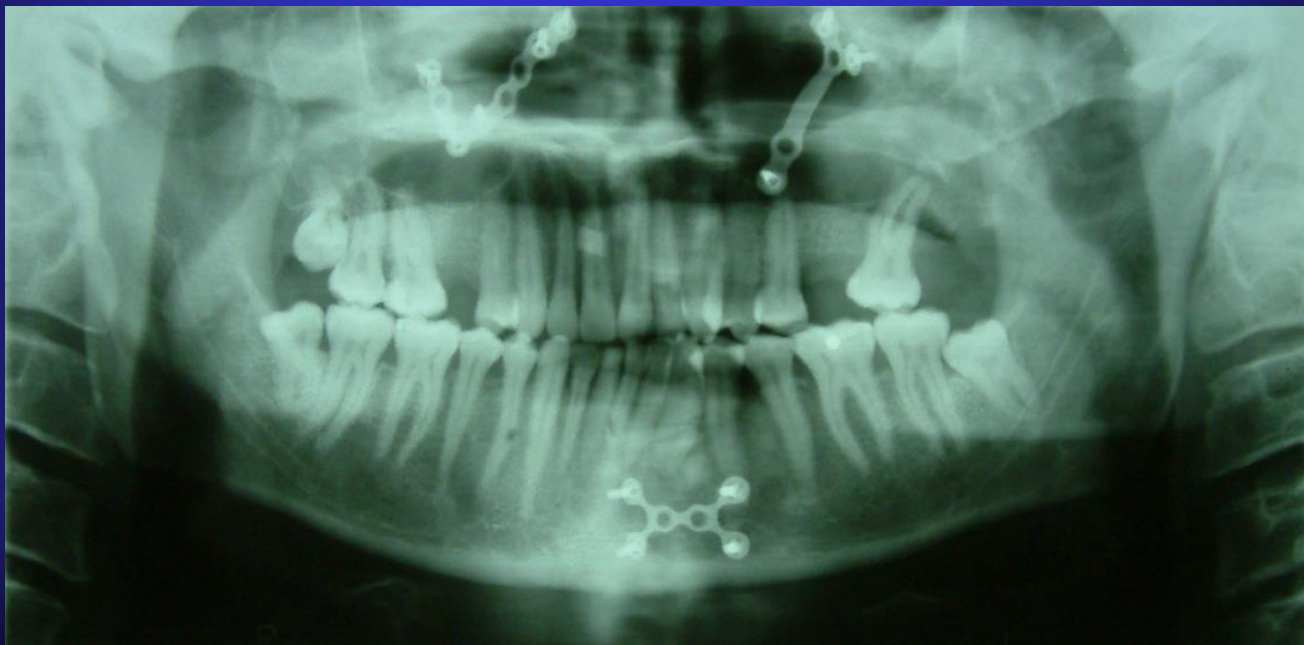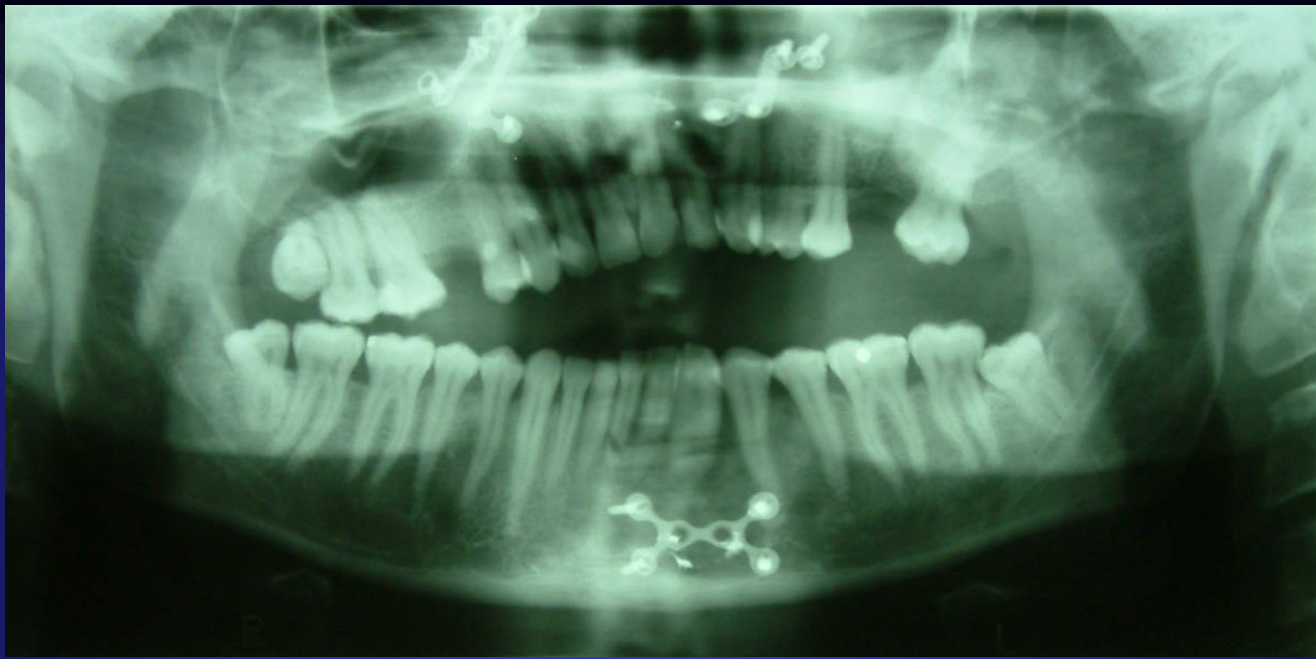


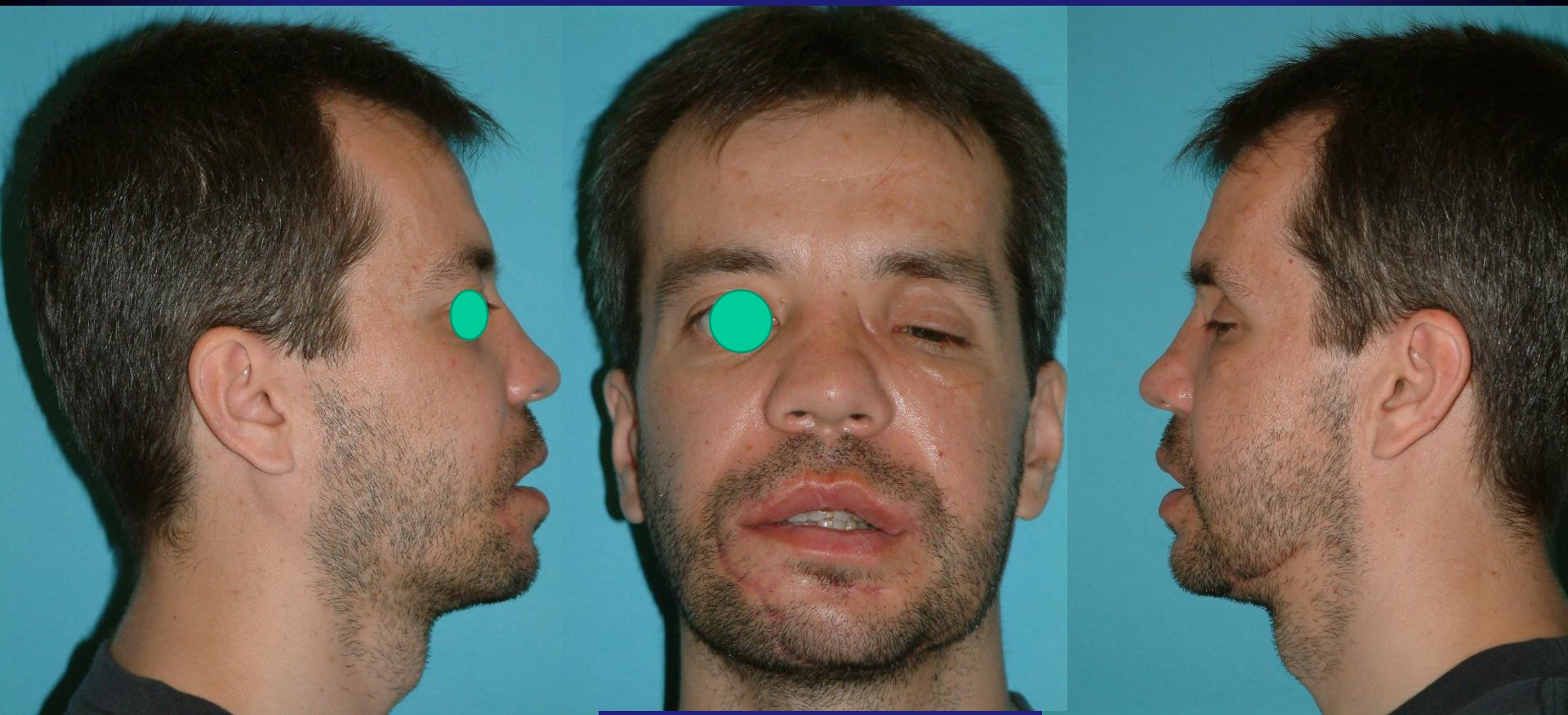


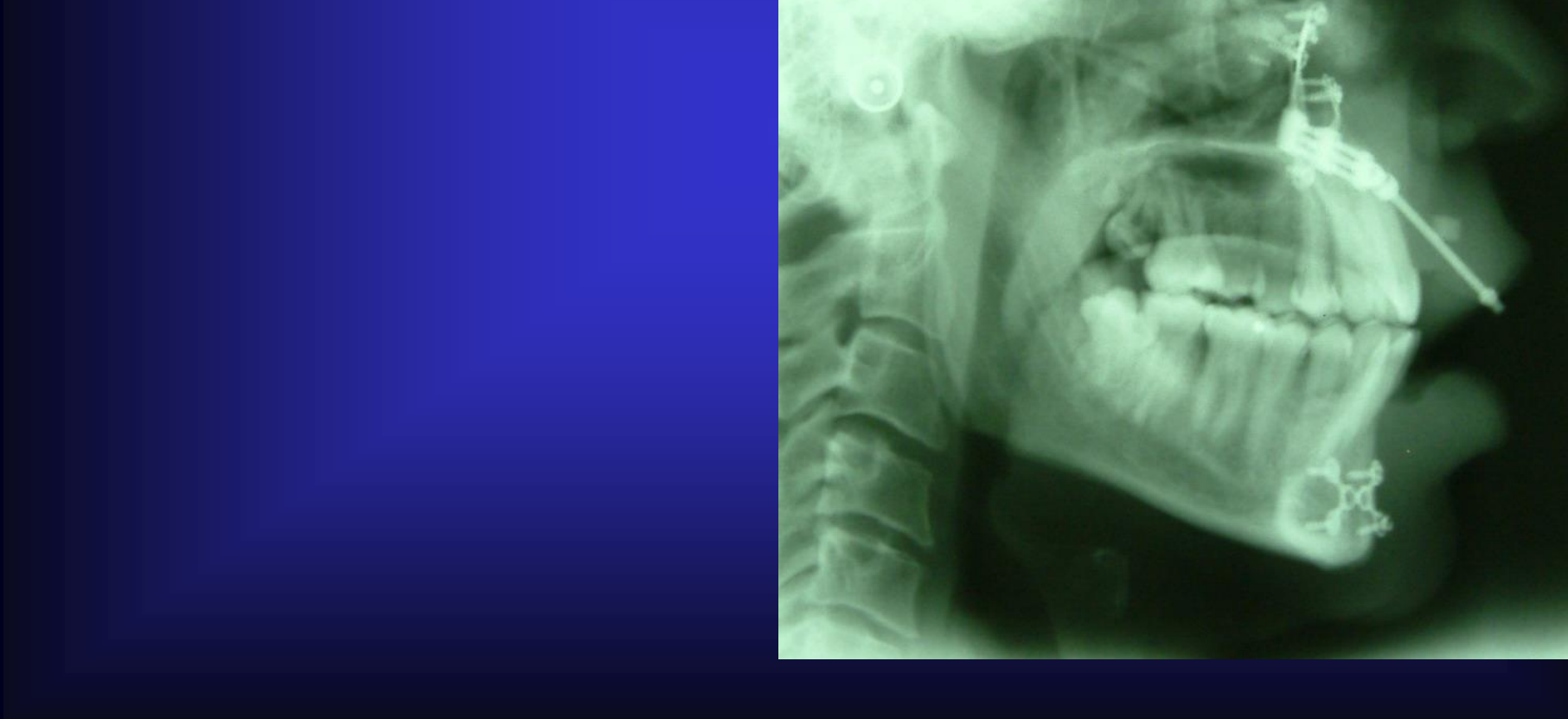
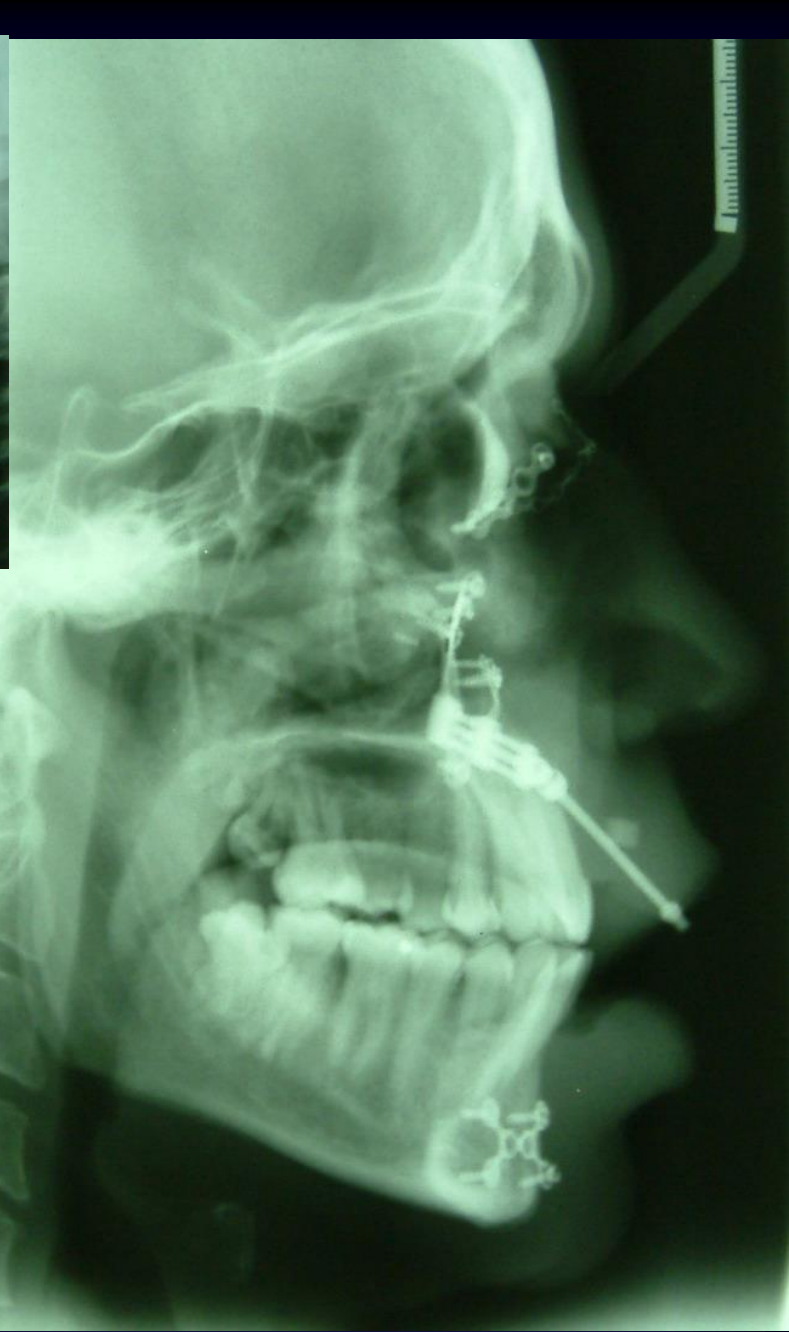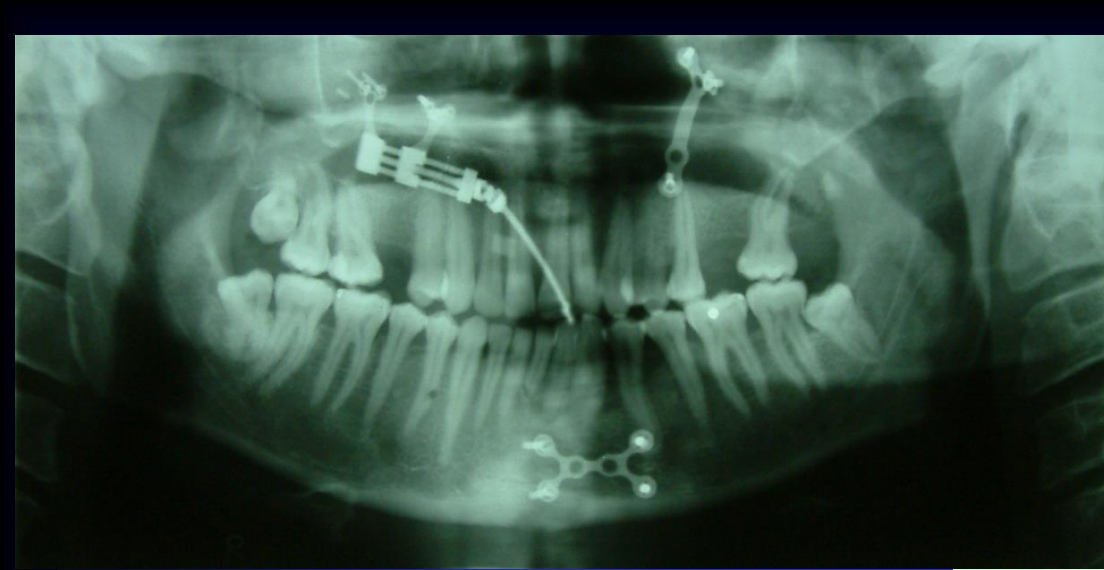







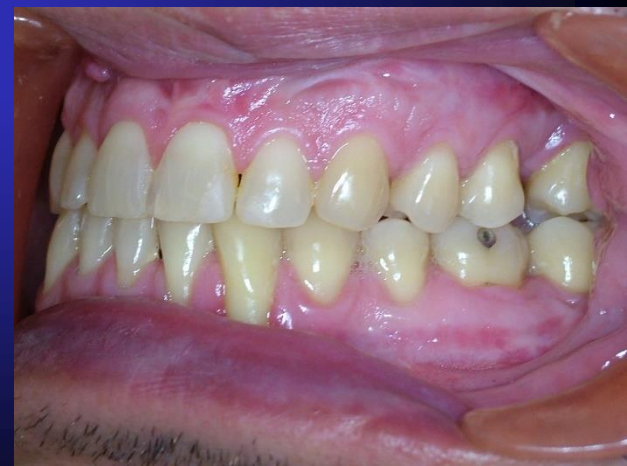
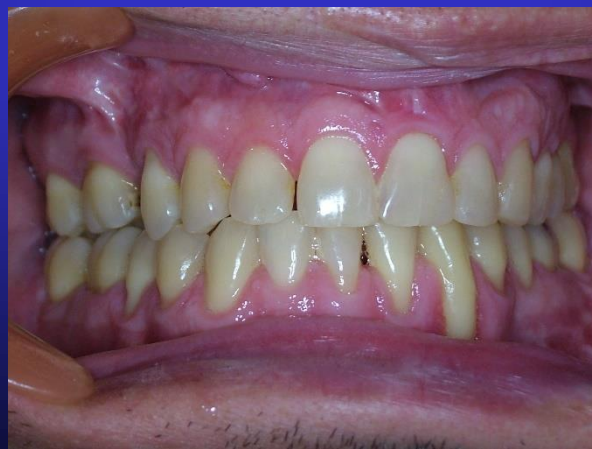
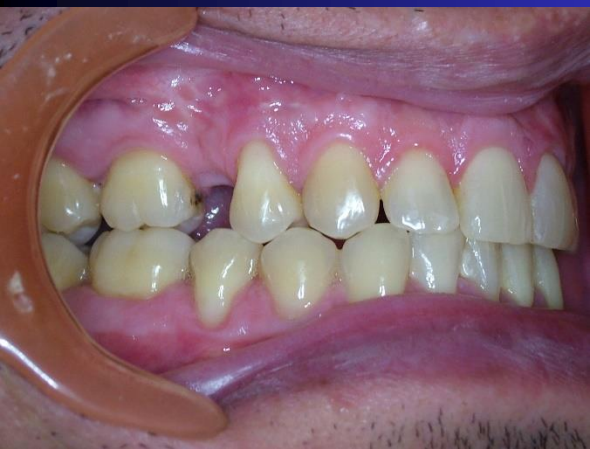
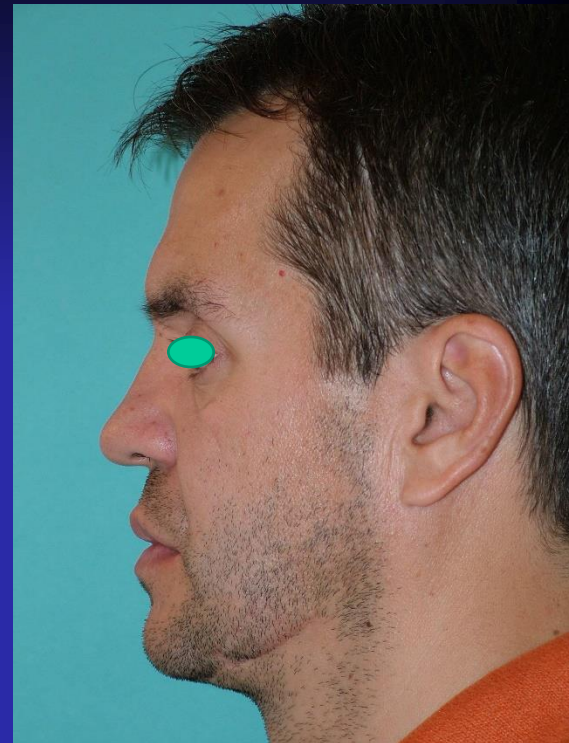
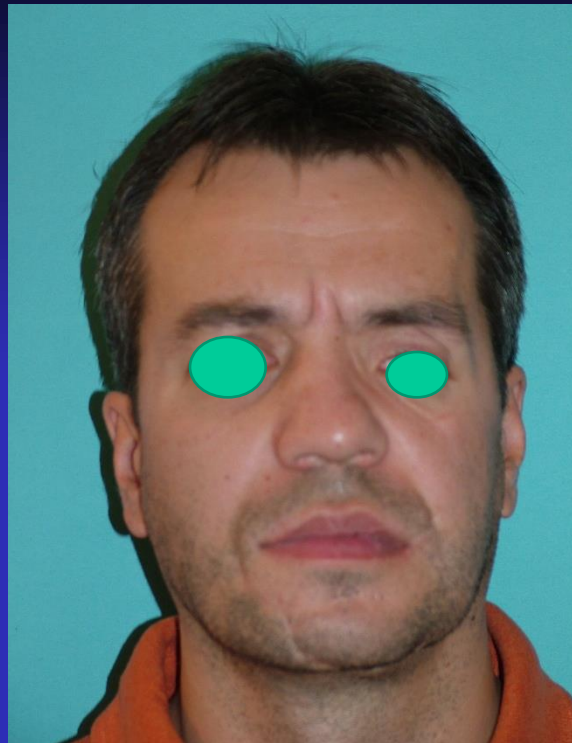
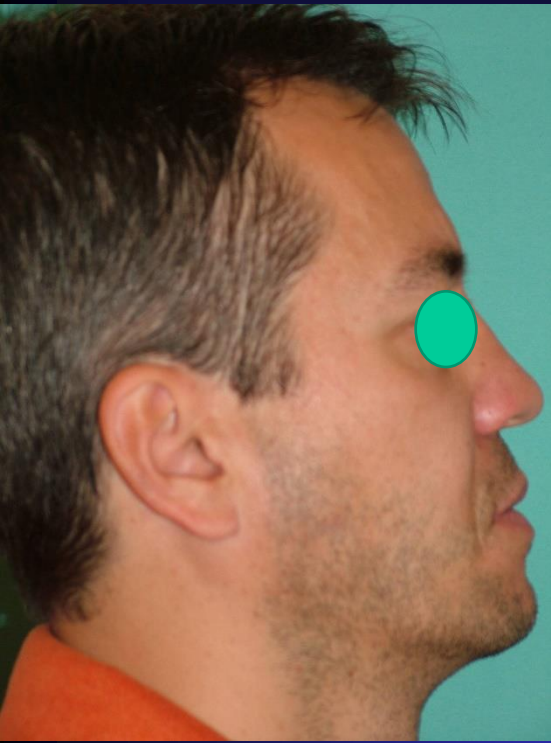




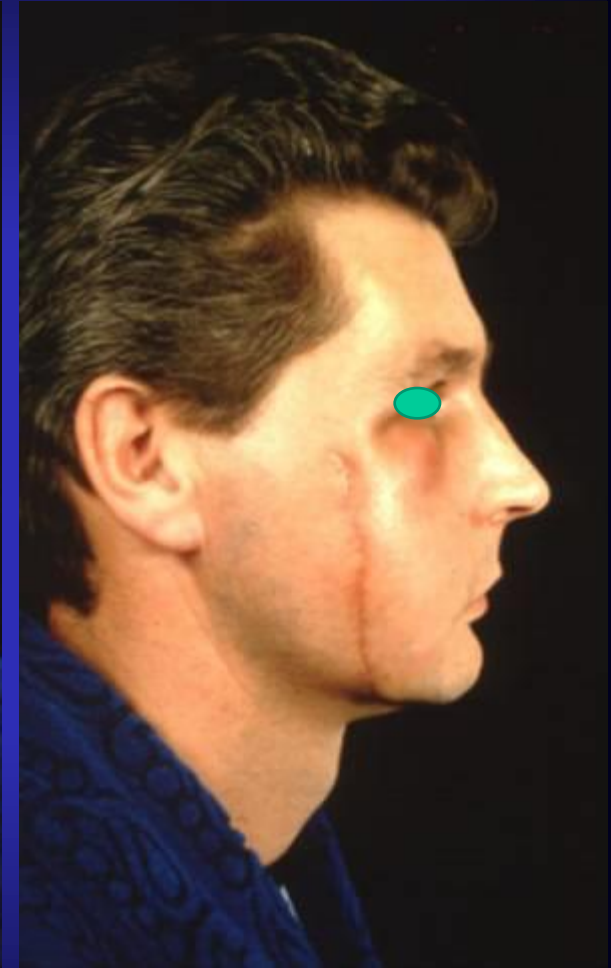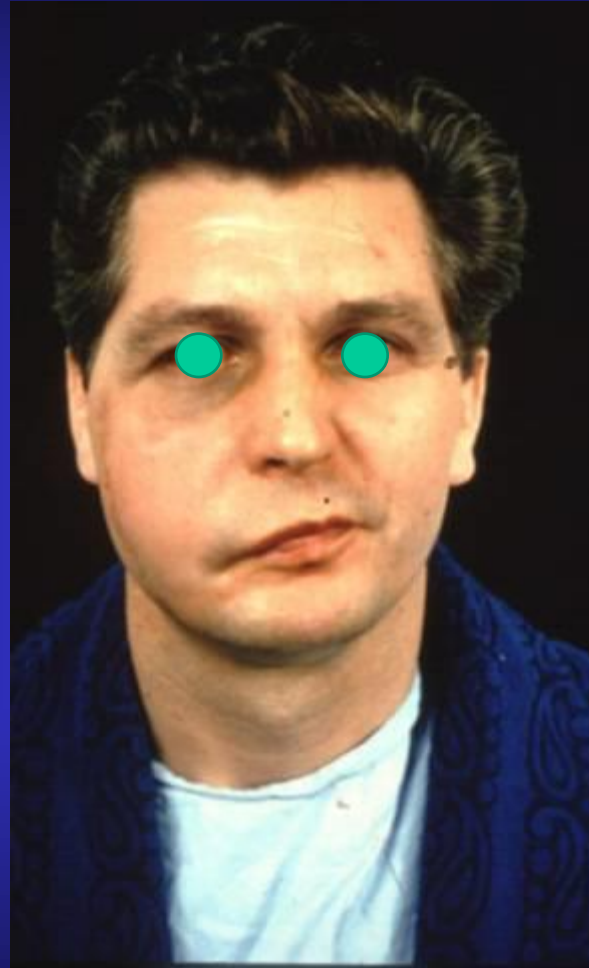Arc-lágyrész sérülés

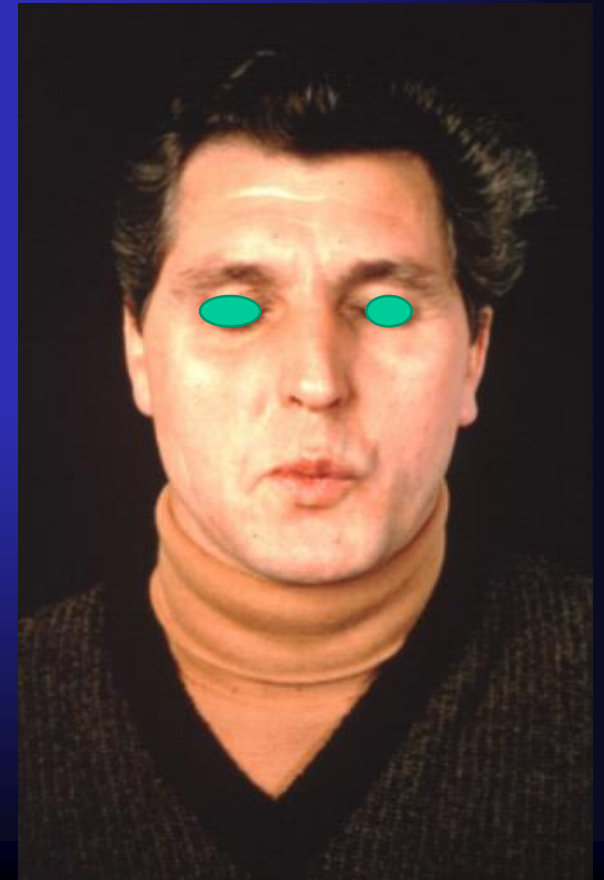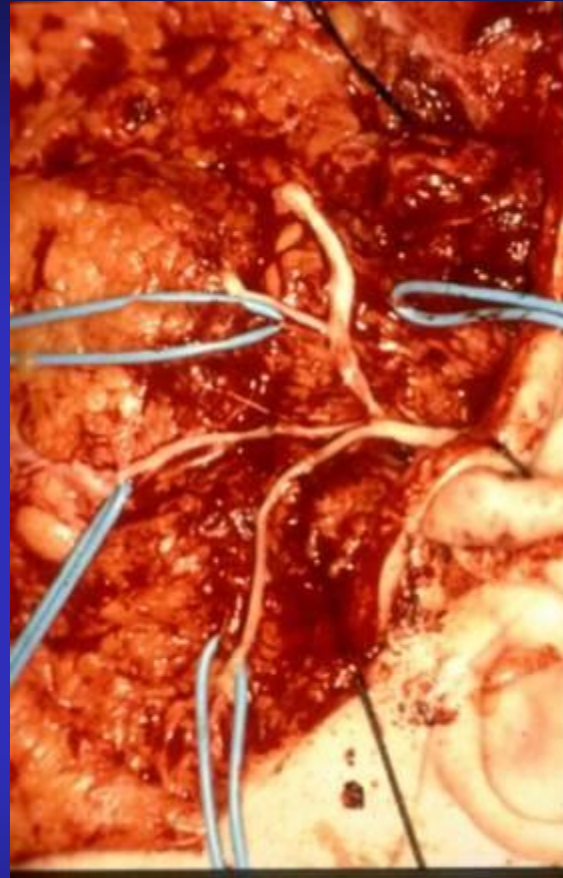
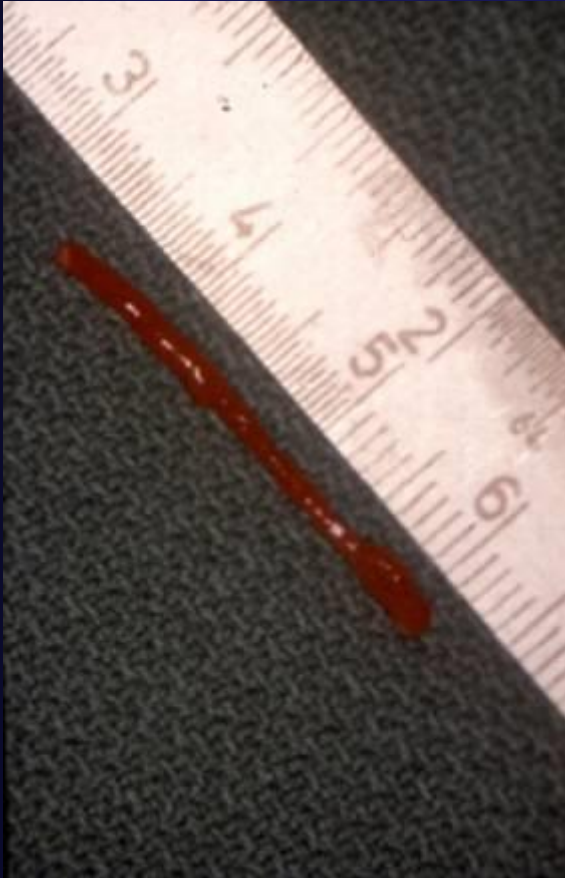


Arc-lágyrész sérülés

Szekunder
idegrekonstrukció



Arc-lágyrész sérülés





FEJLŐDÉSI RENDELLENESÉGEK





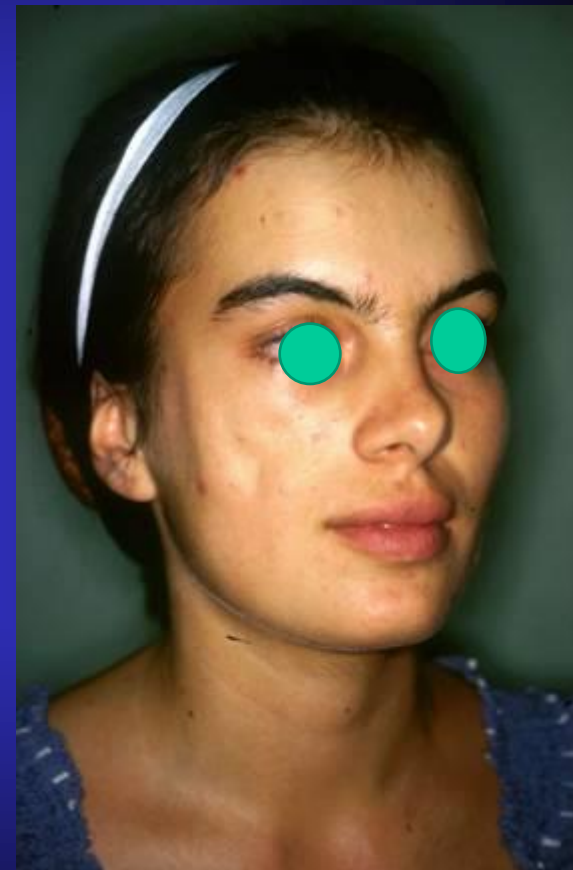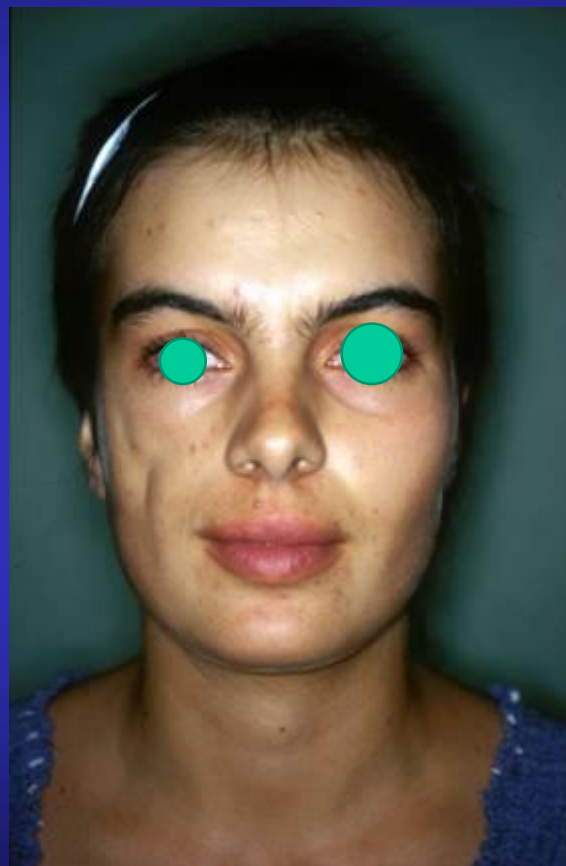Hemiatrophia faciei



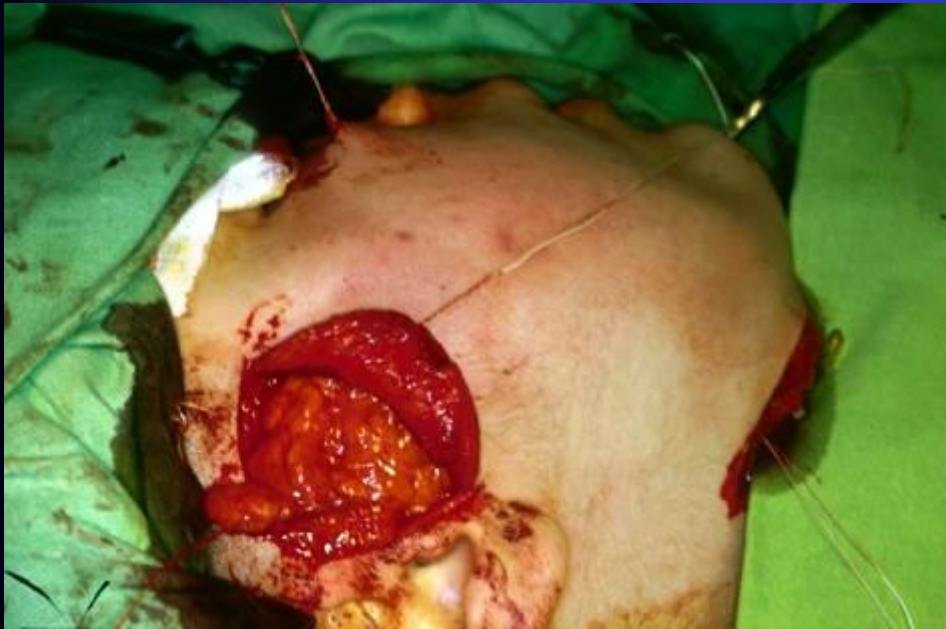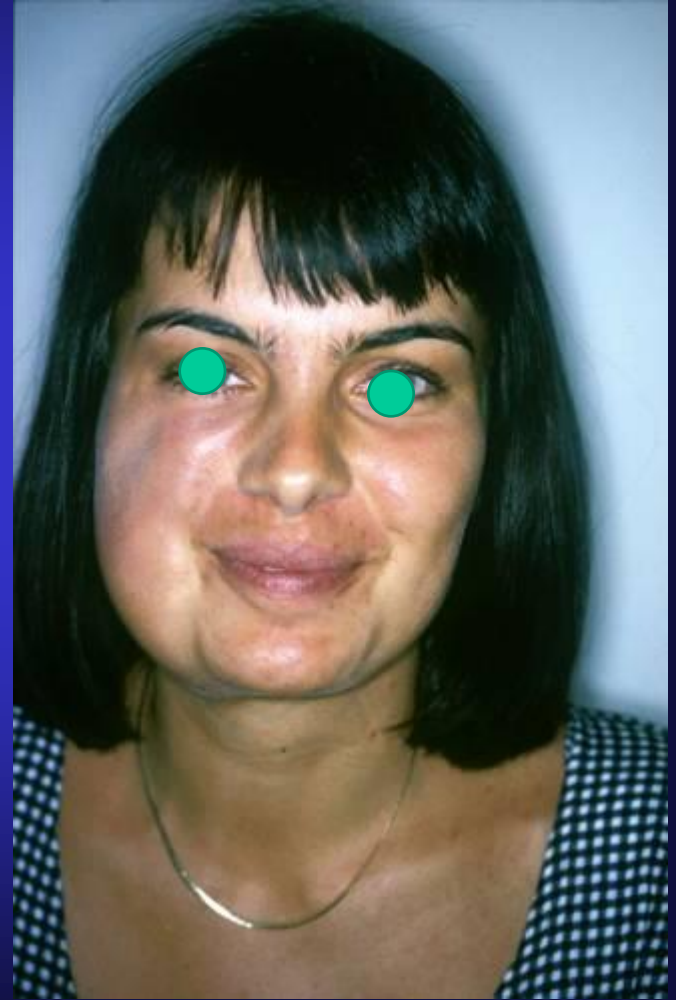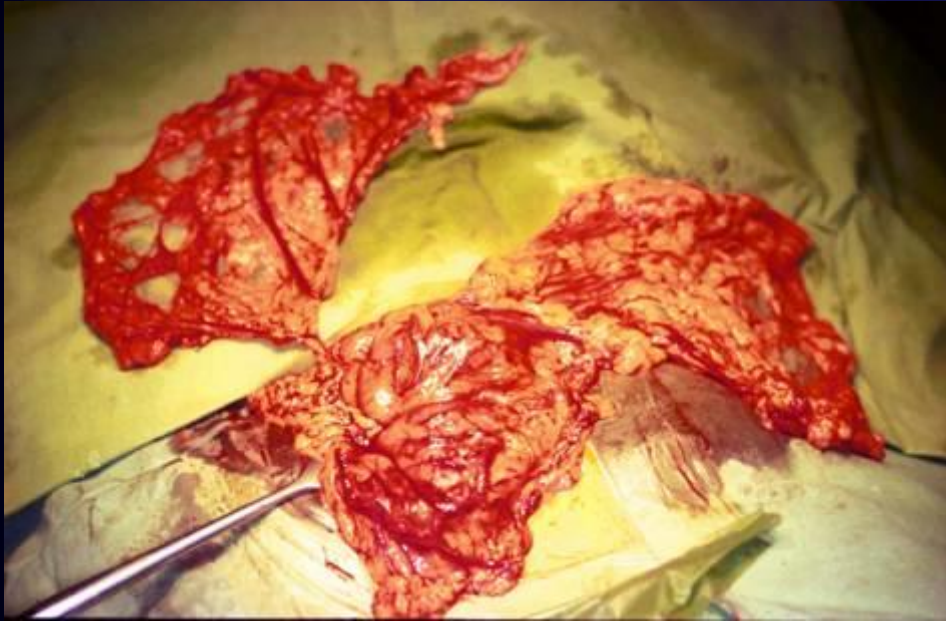Hemiatrophia faciei

Romberg syndroma

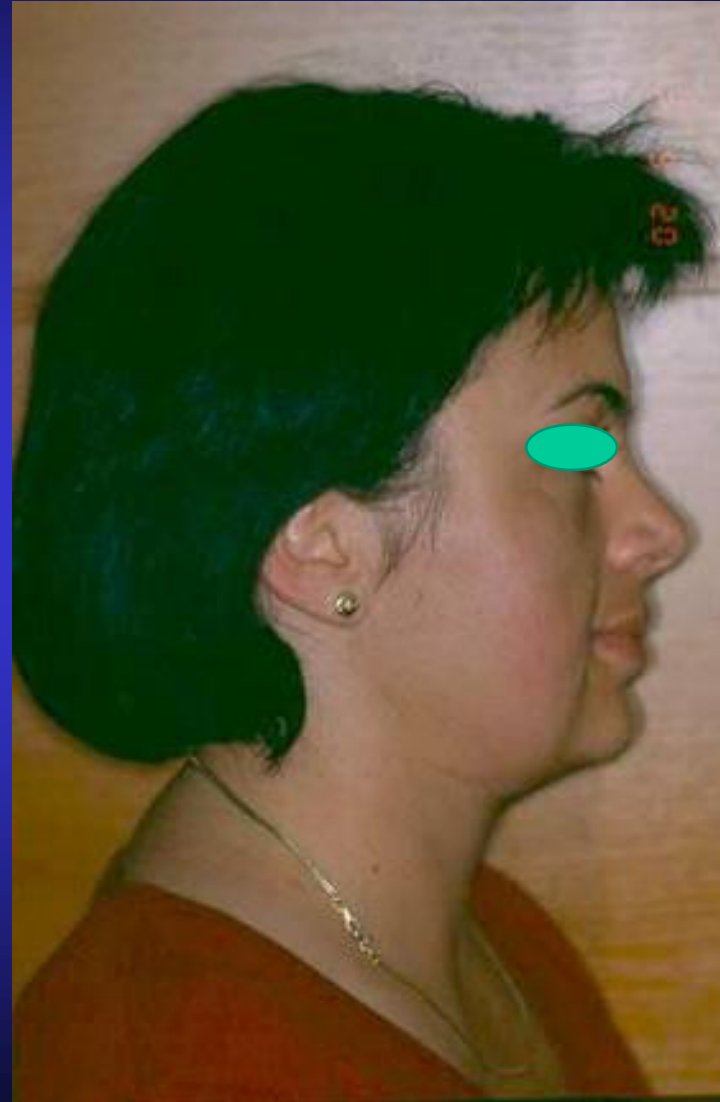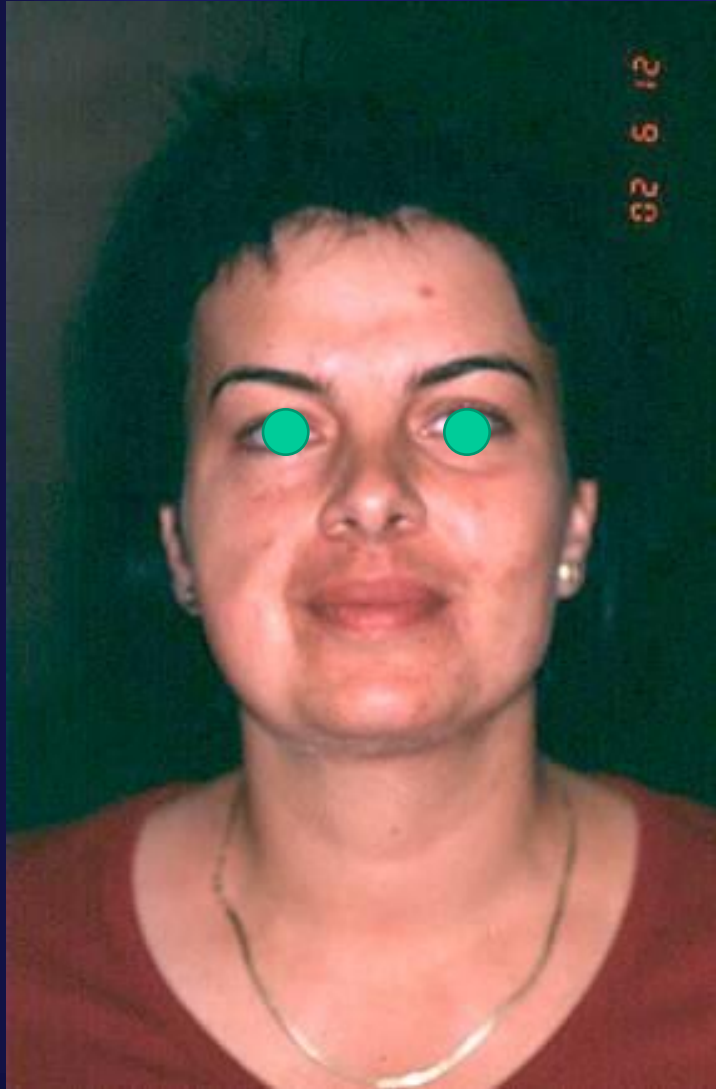**Rekonstrukció
omentum majus
lebennyel**



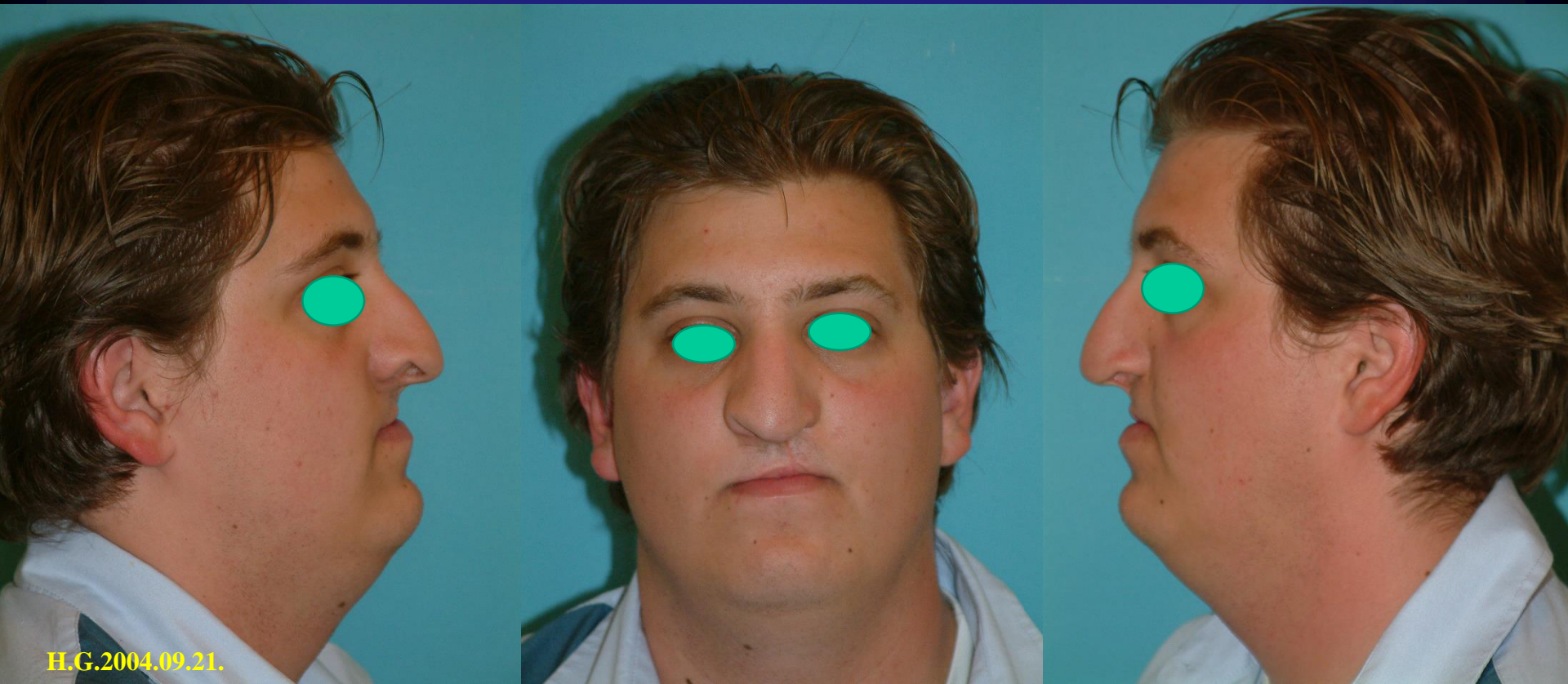Hemiatrophia faciei



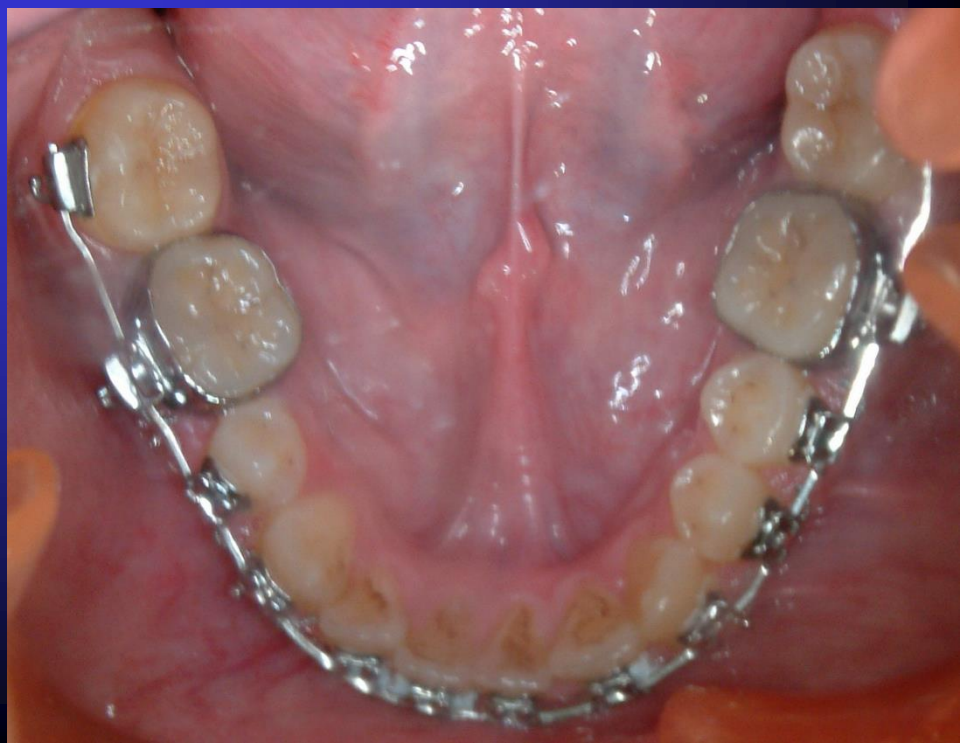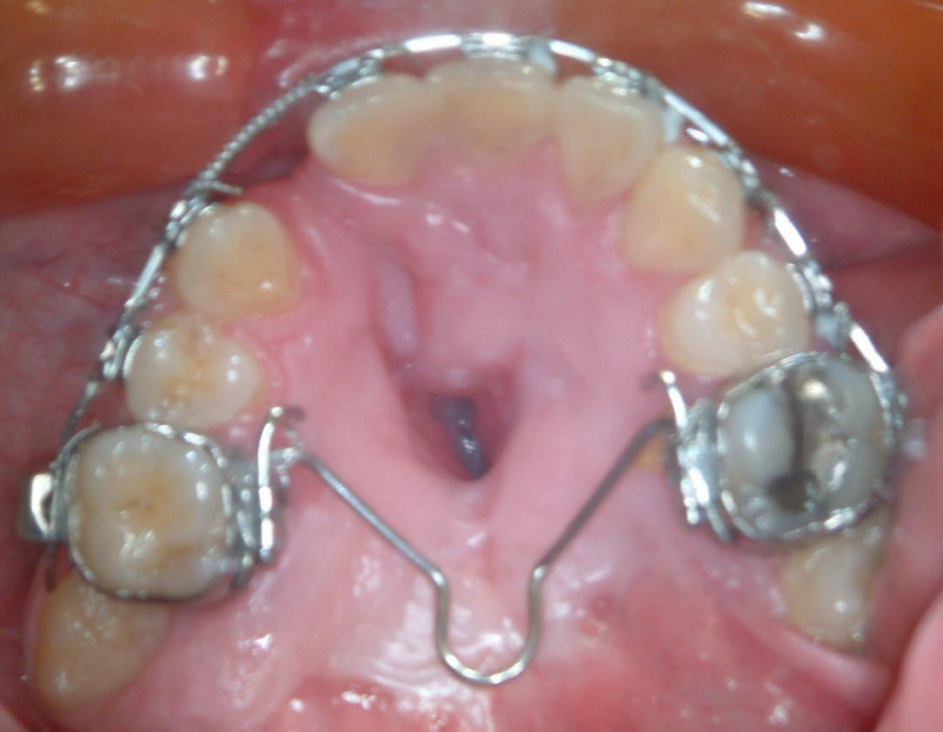Hemiatrophia faciei

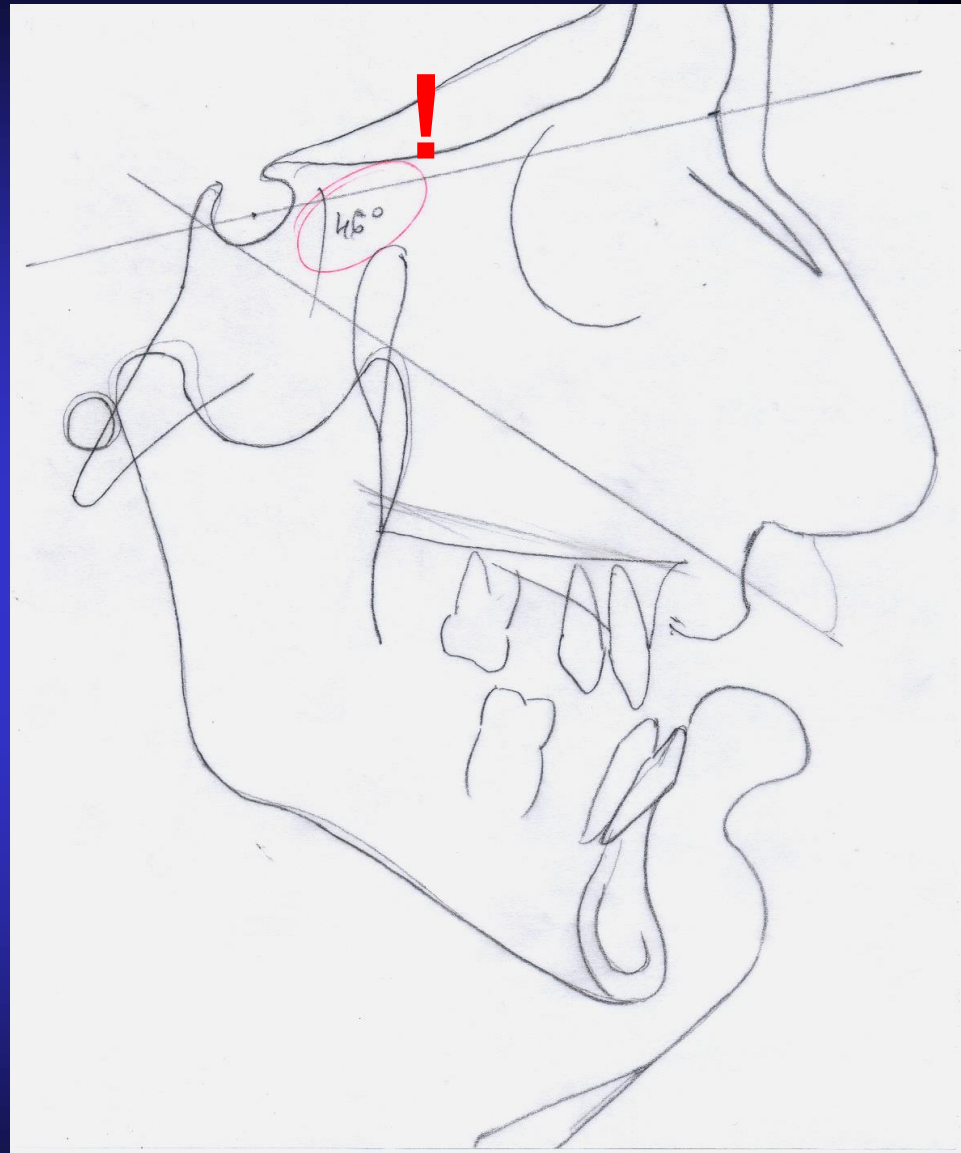
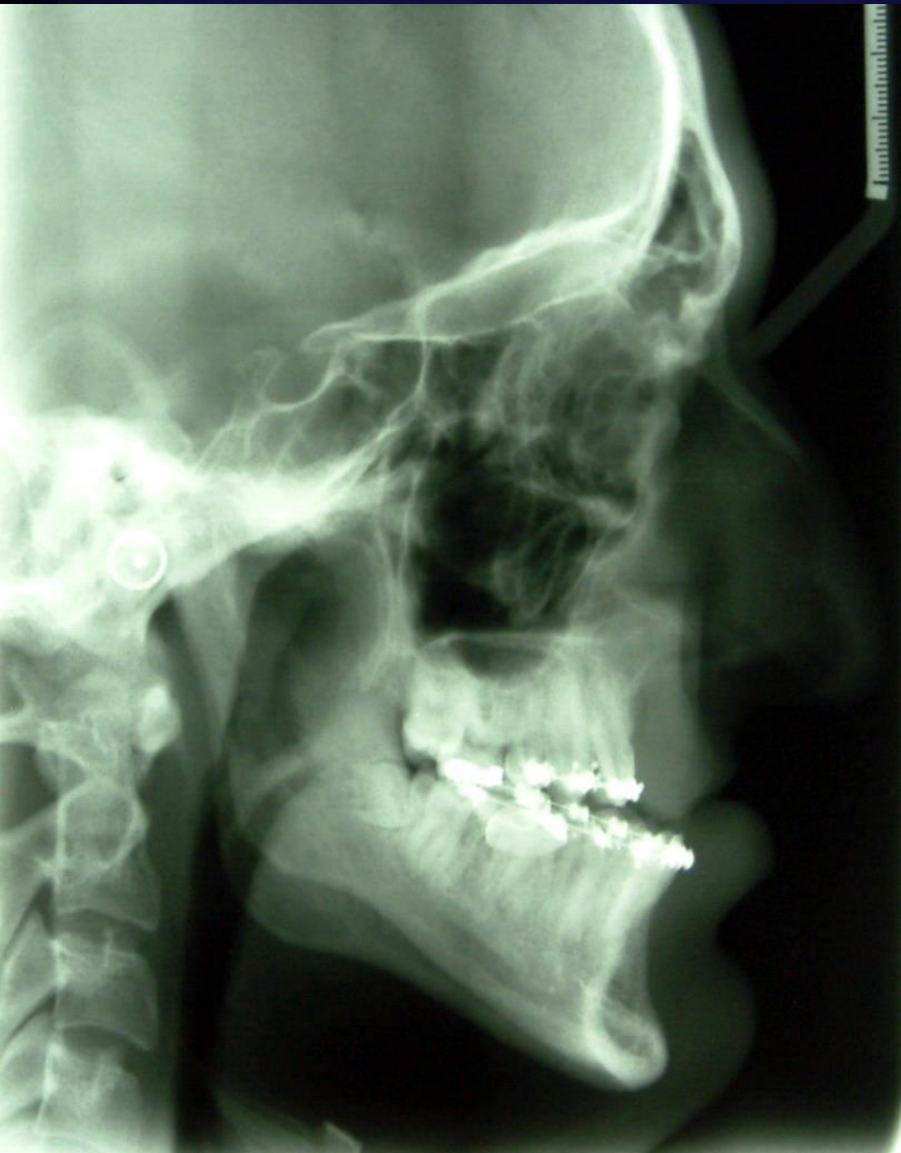

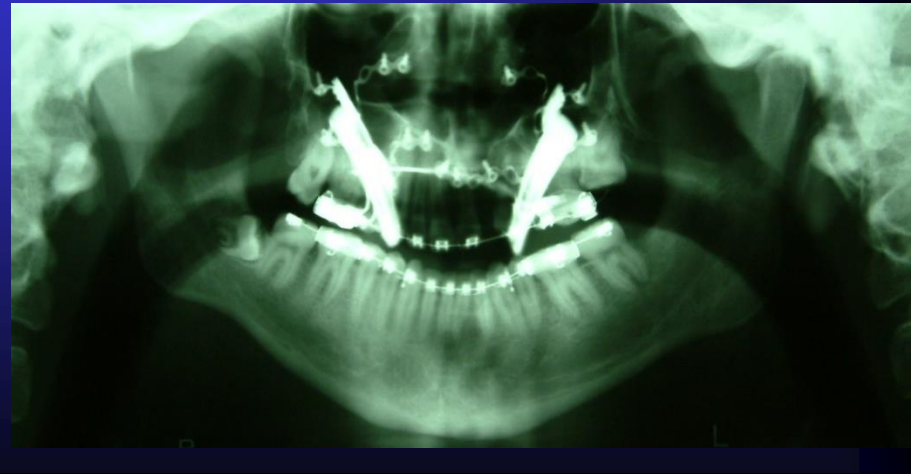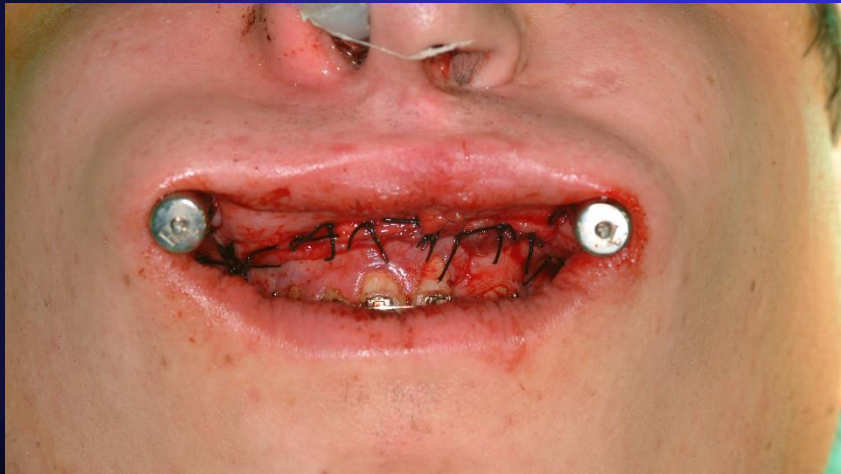
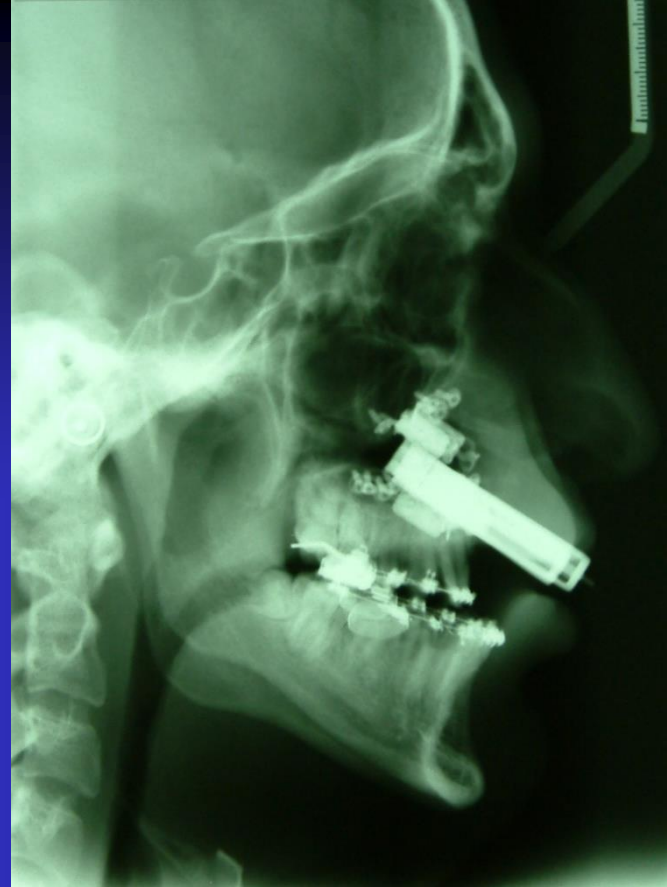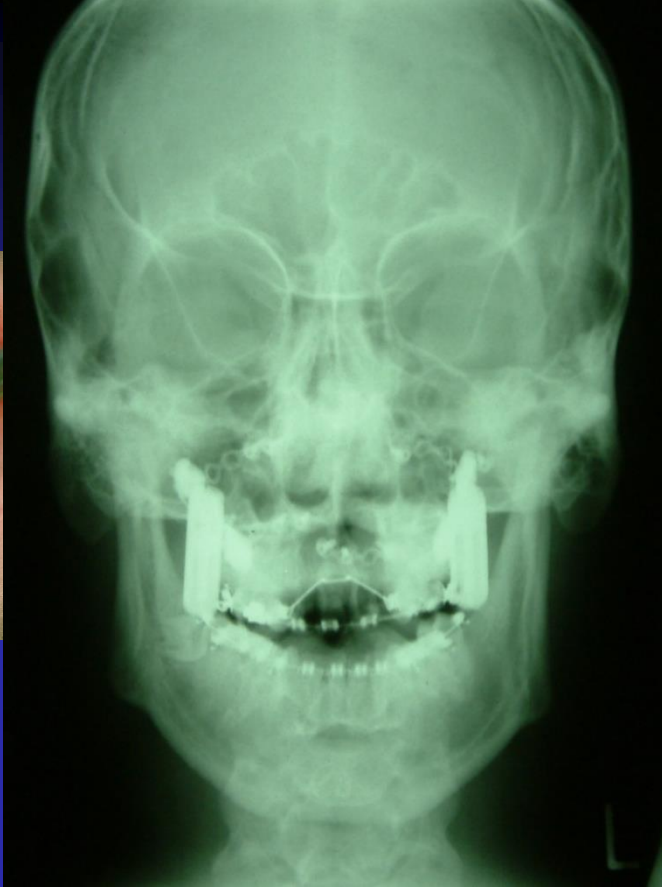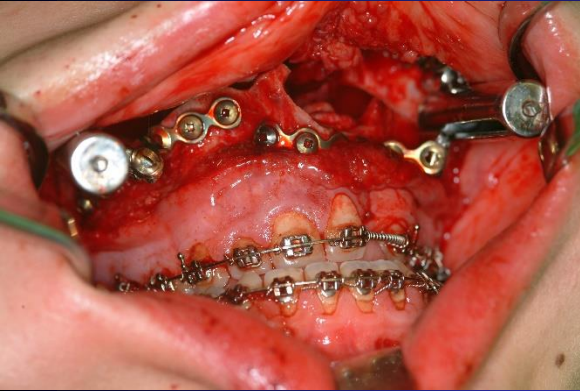
**Bal oldali ajak,- állcsont,-
szájpad hasadék
Micro és retromaxillia**

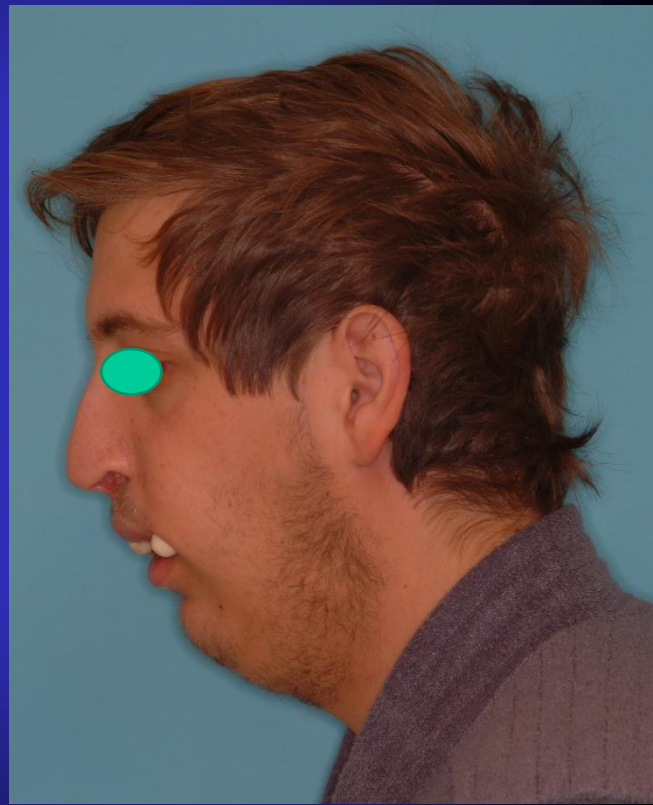
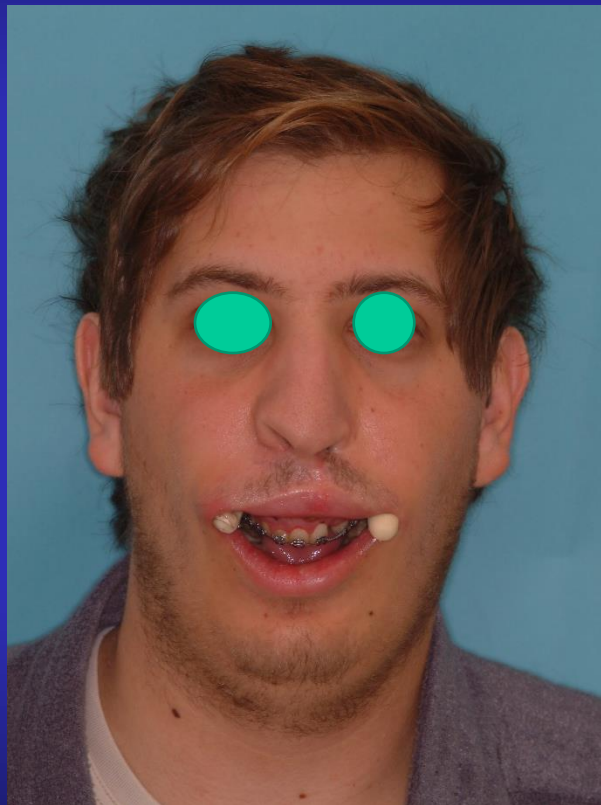
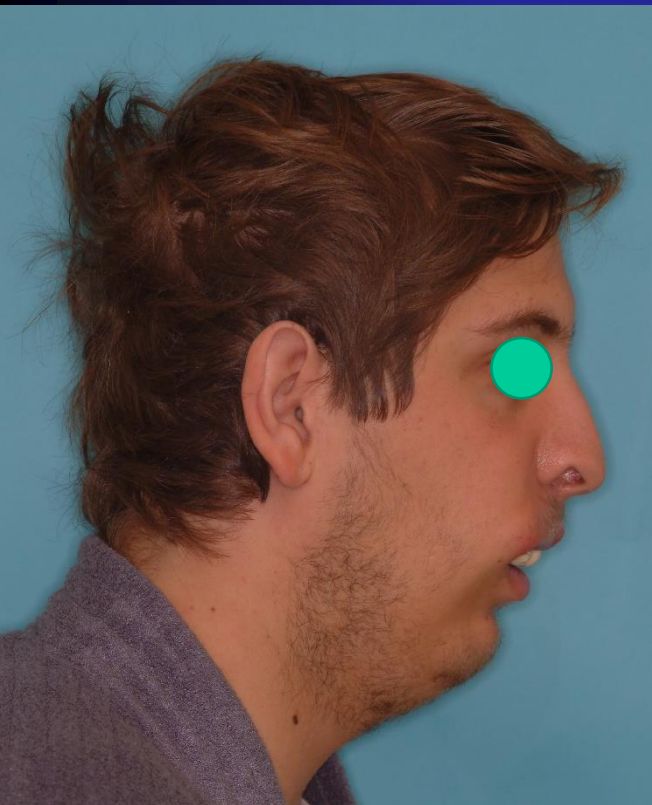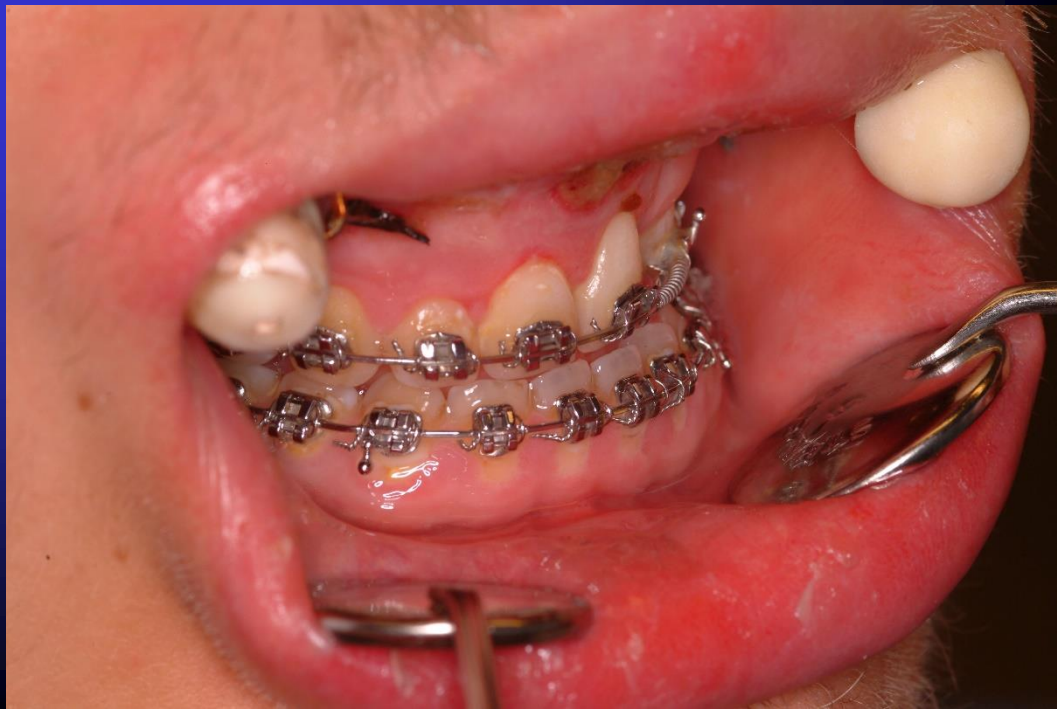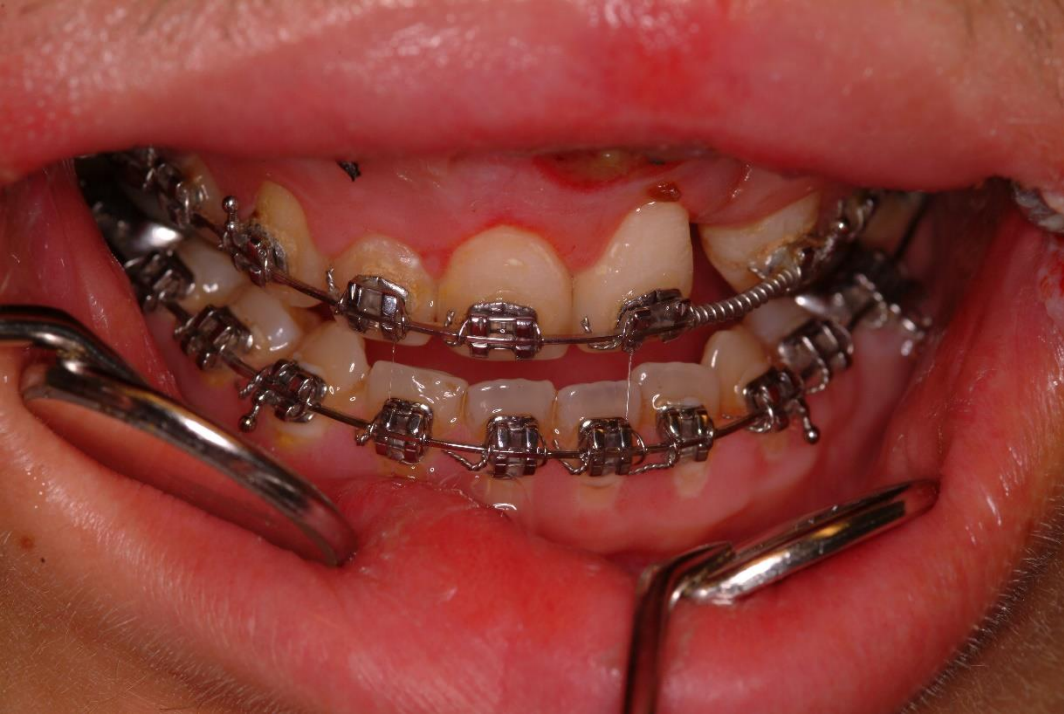H.G.2004.09.21.

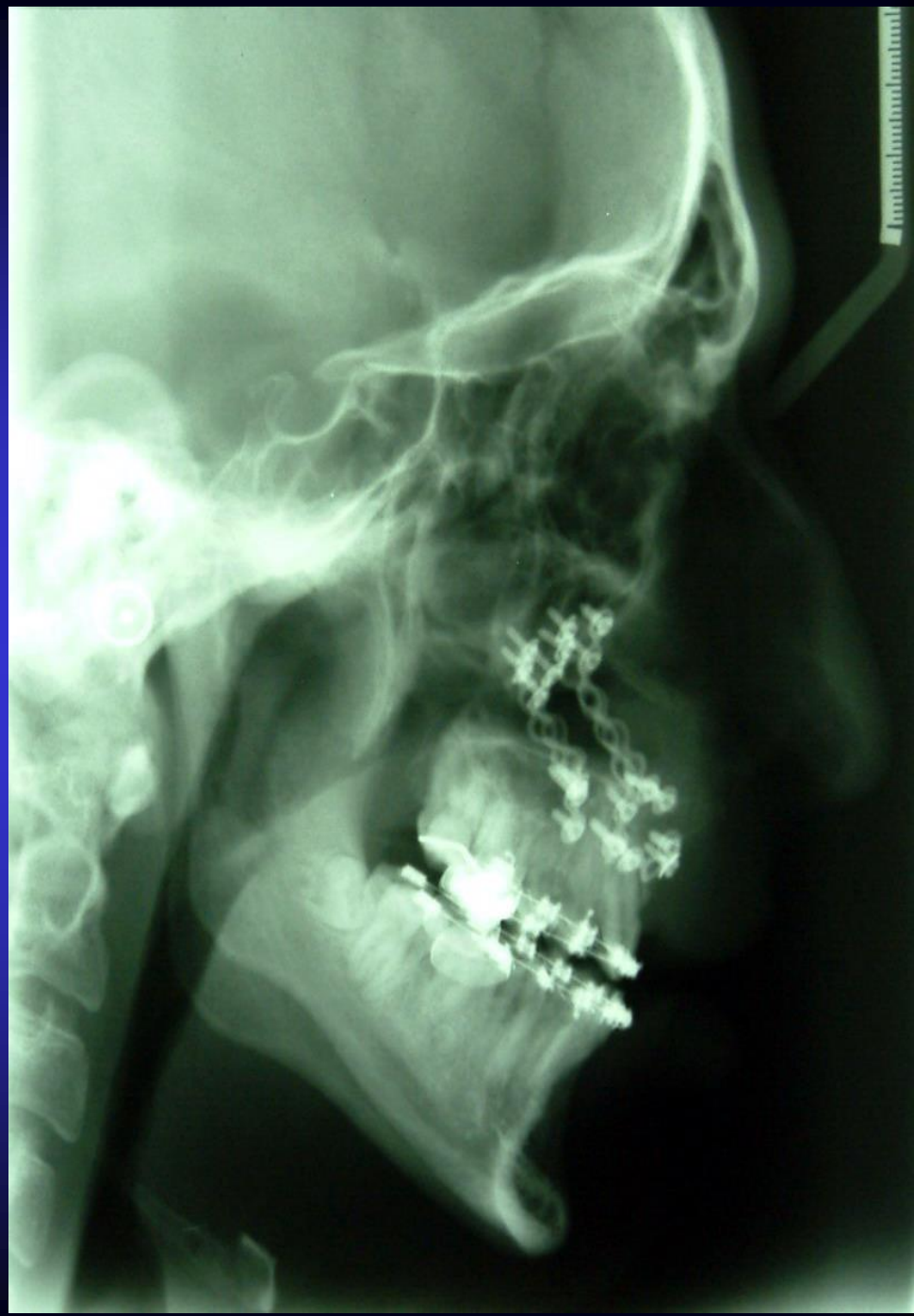
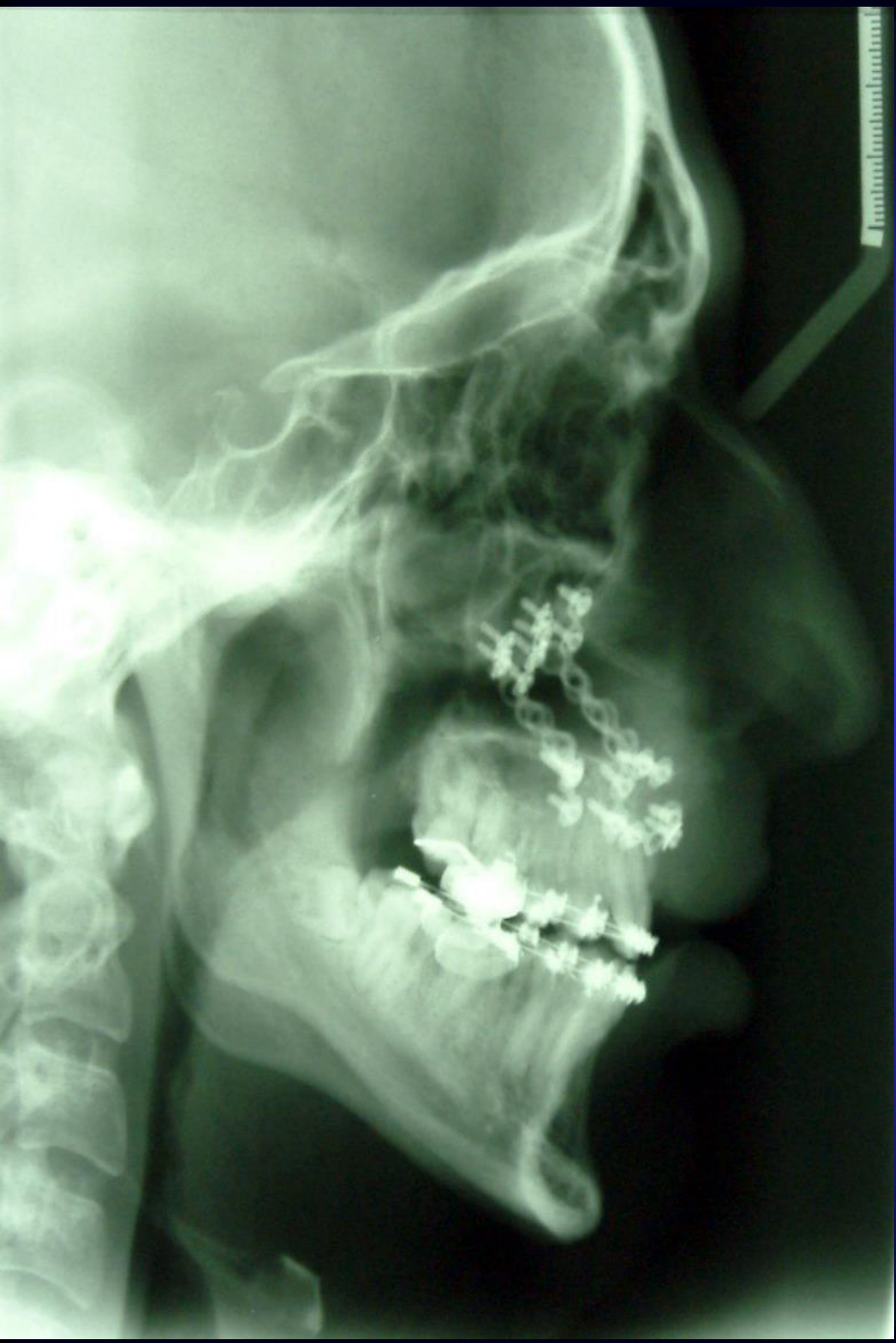
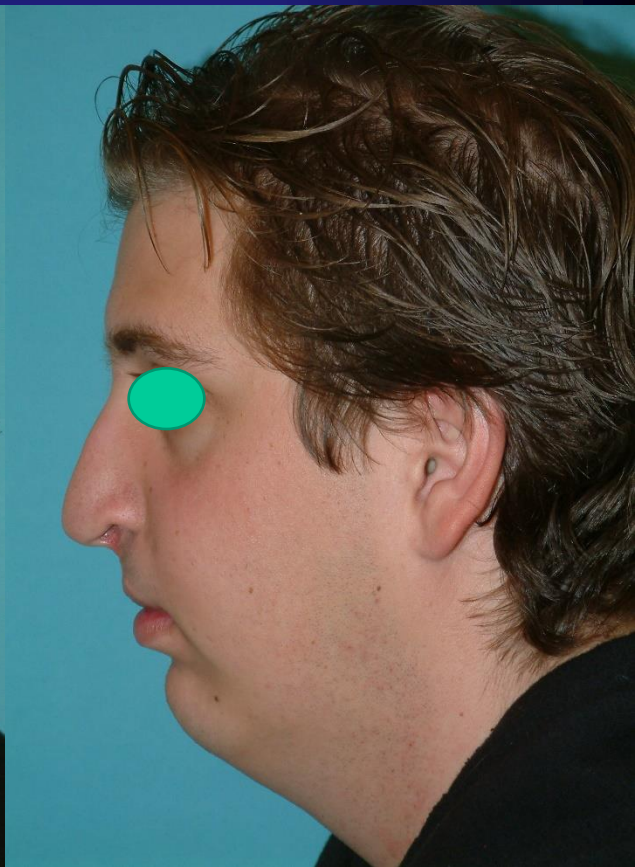
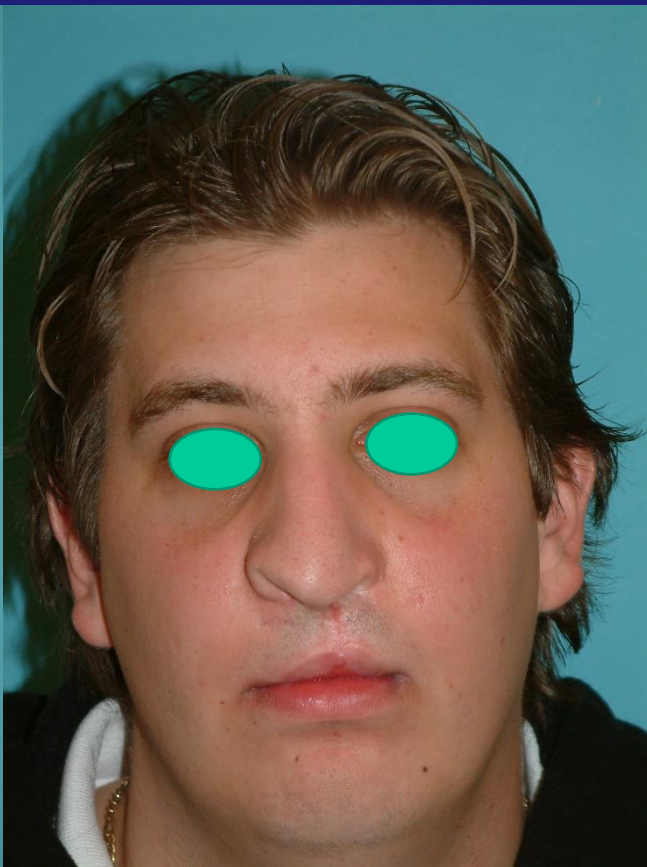


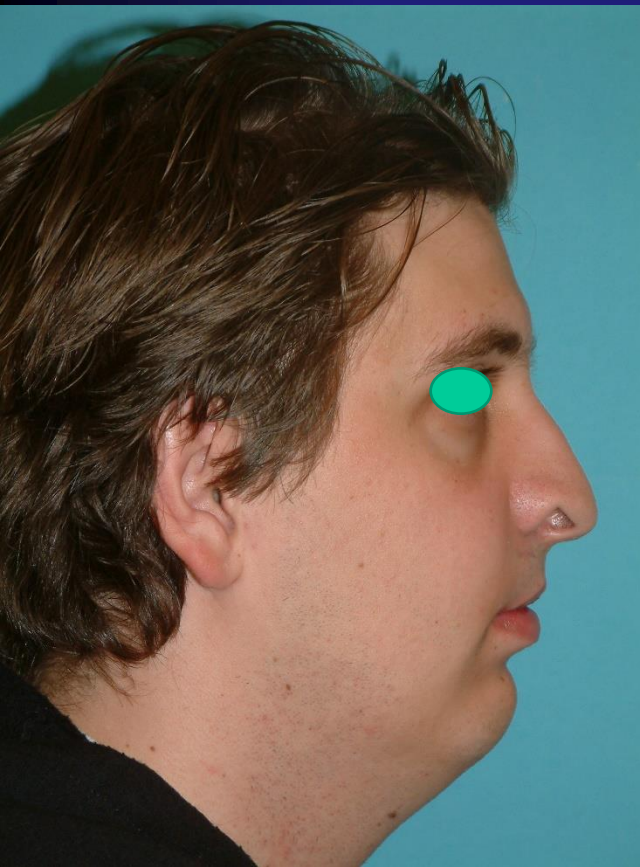


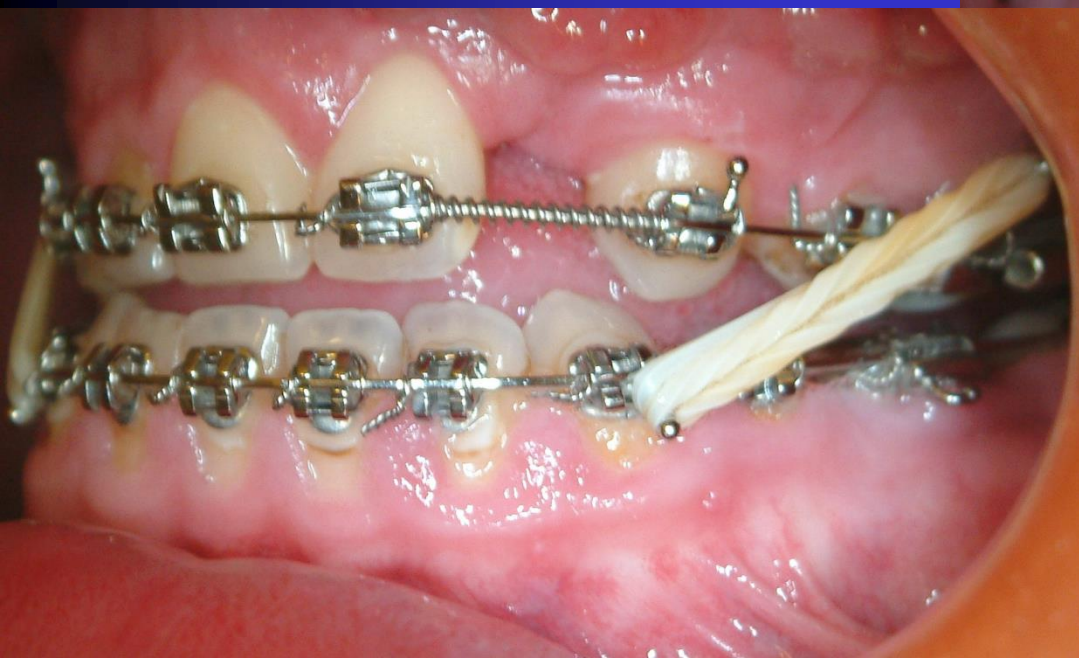
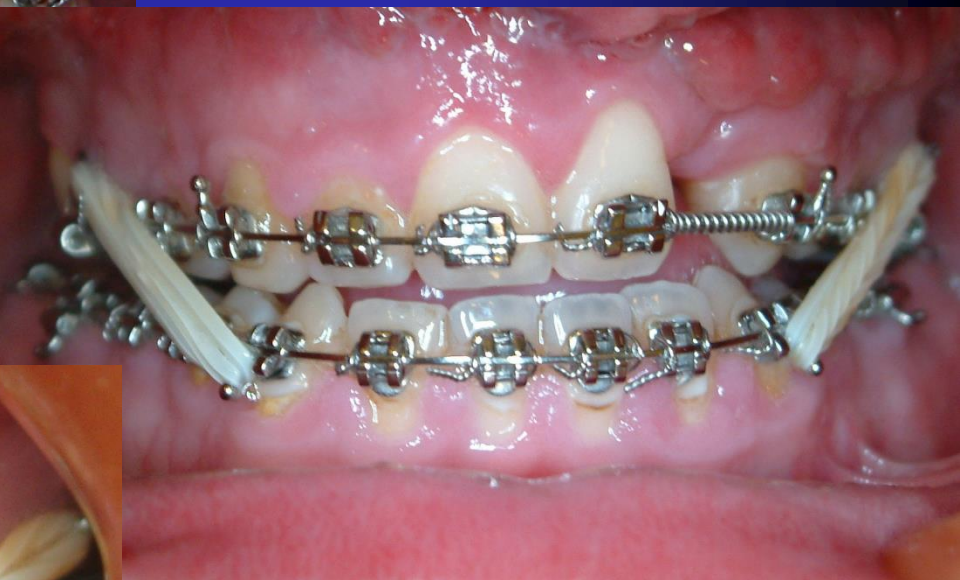
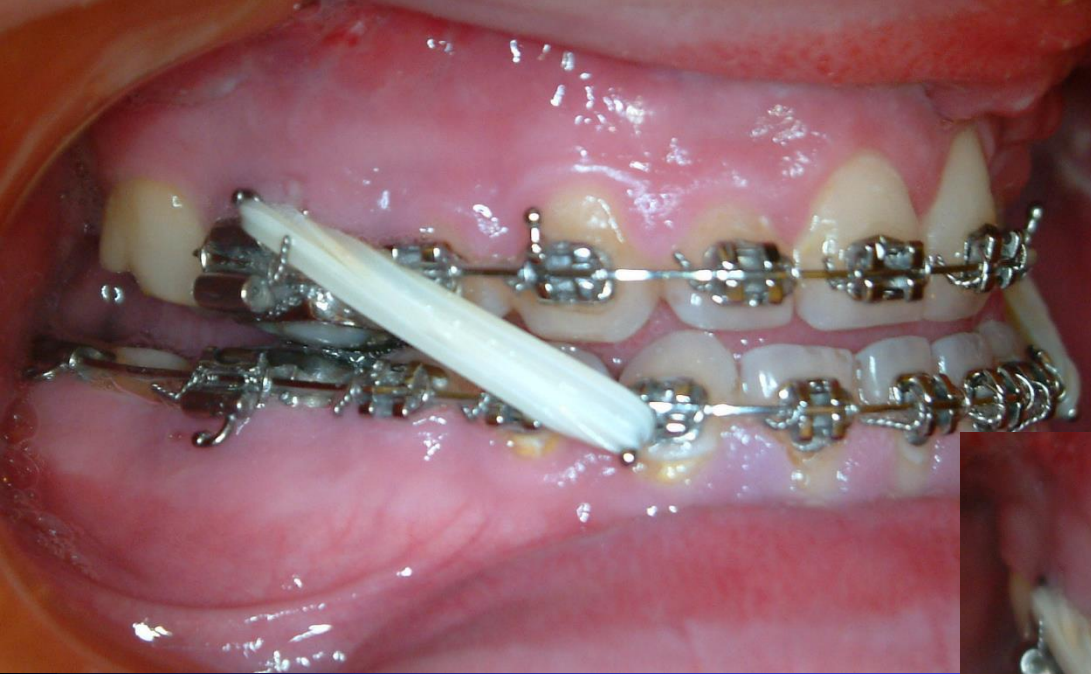


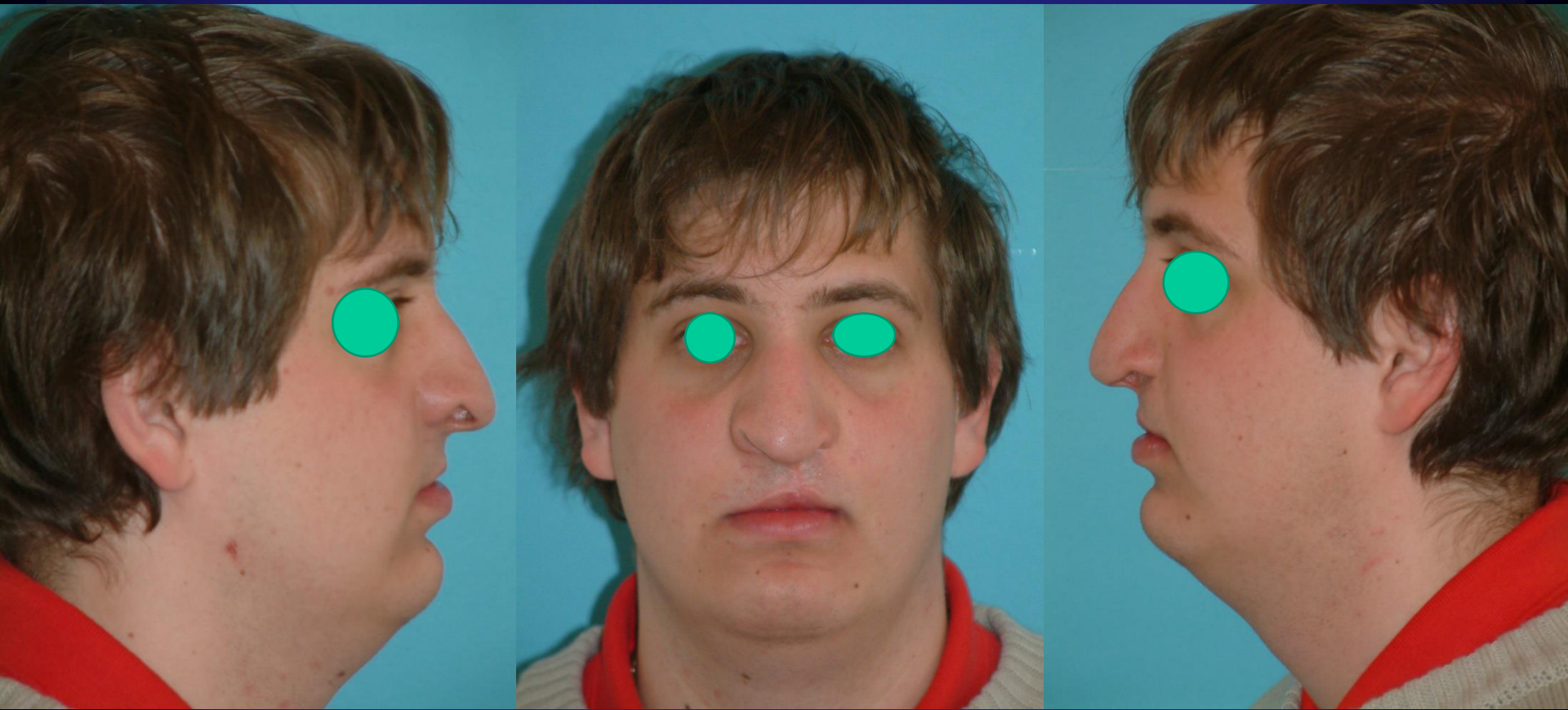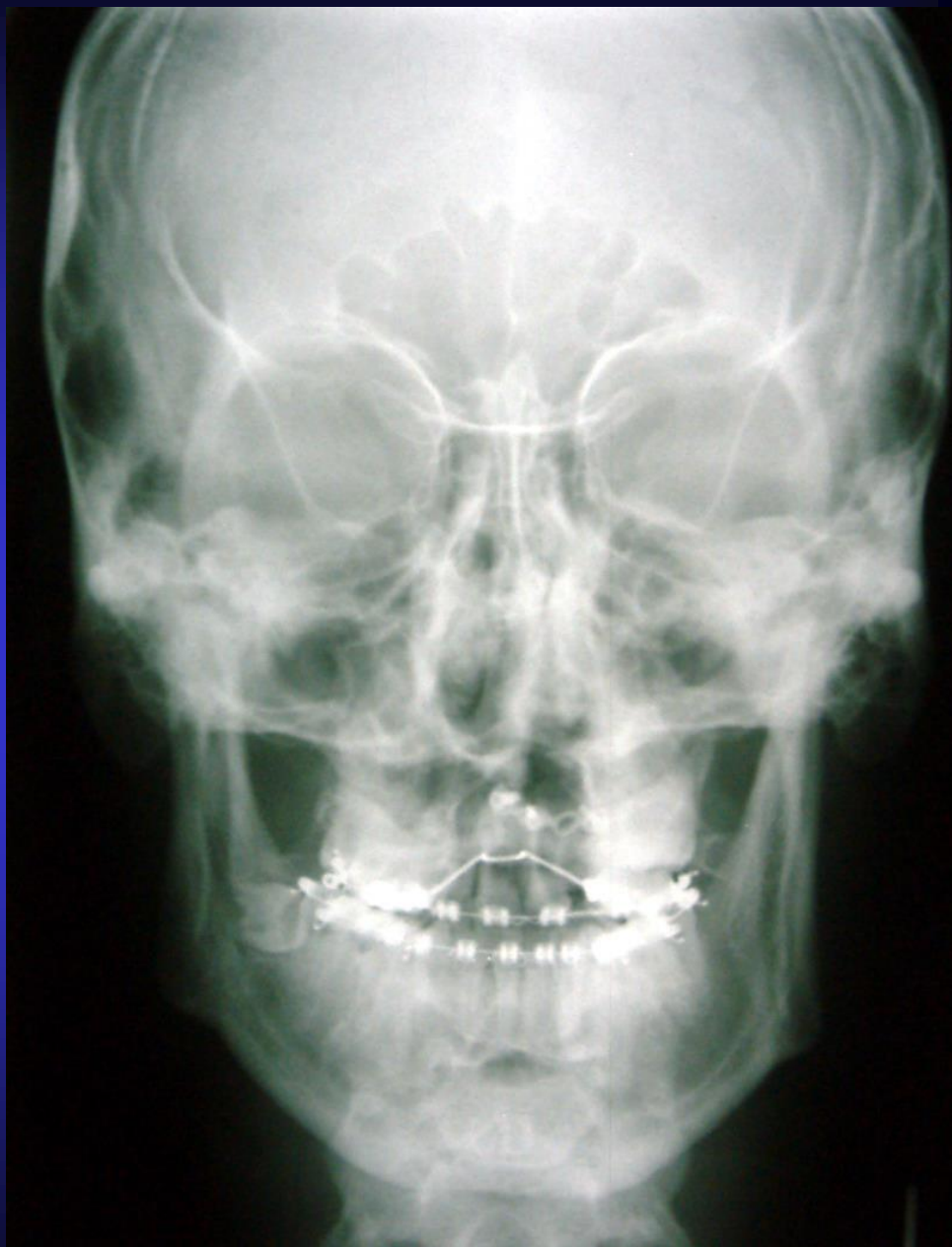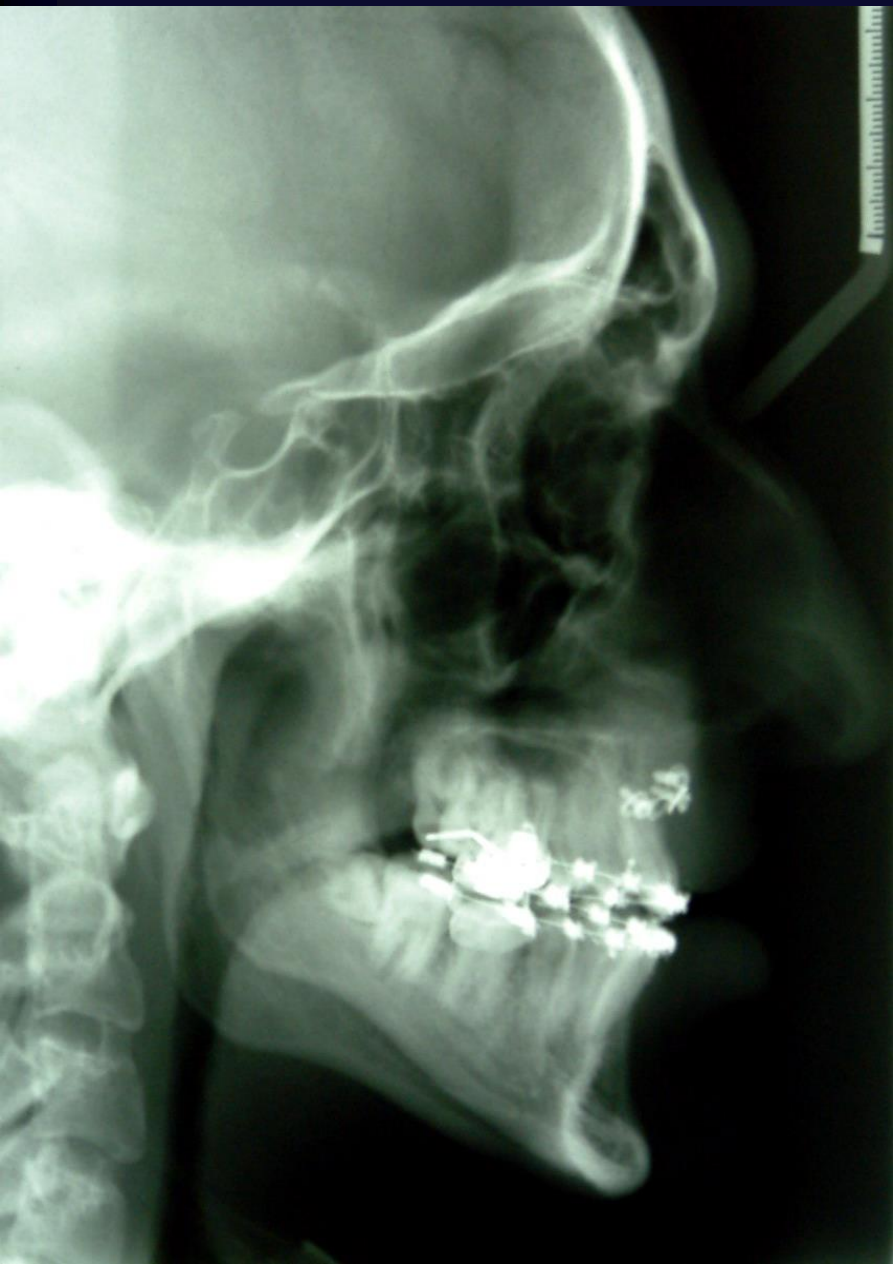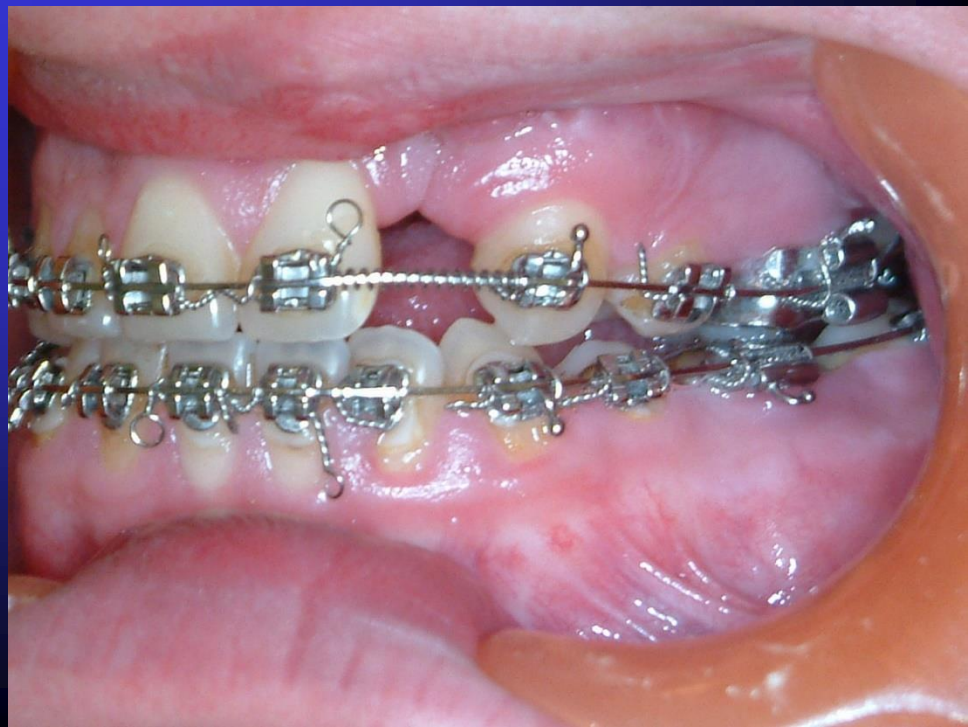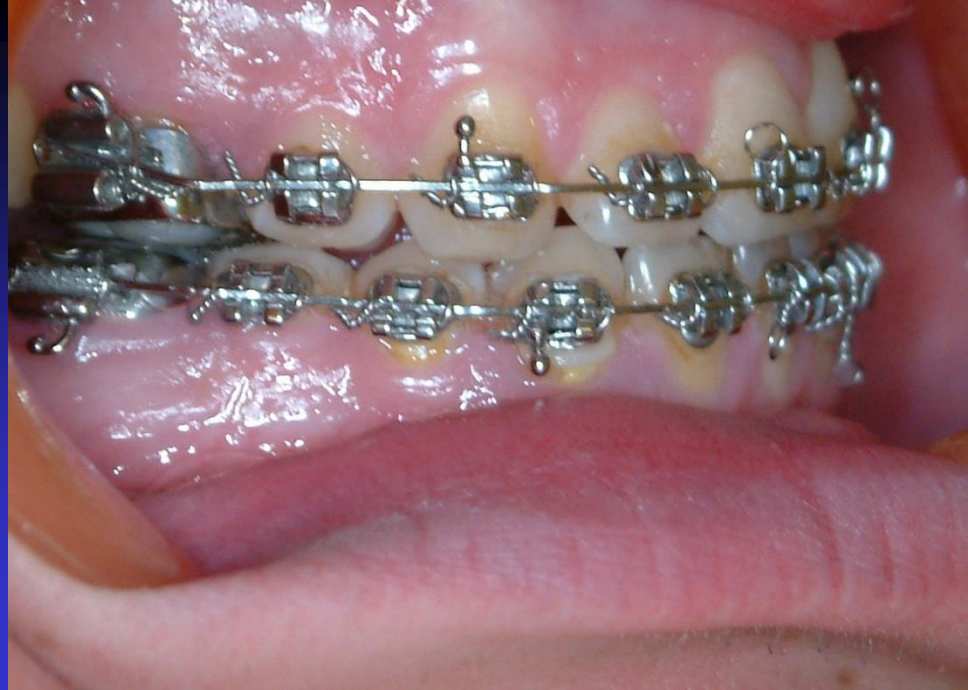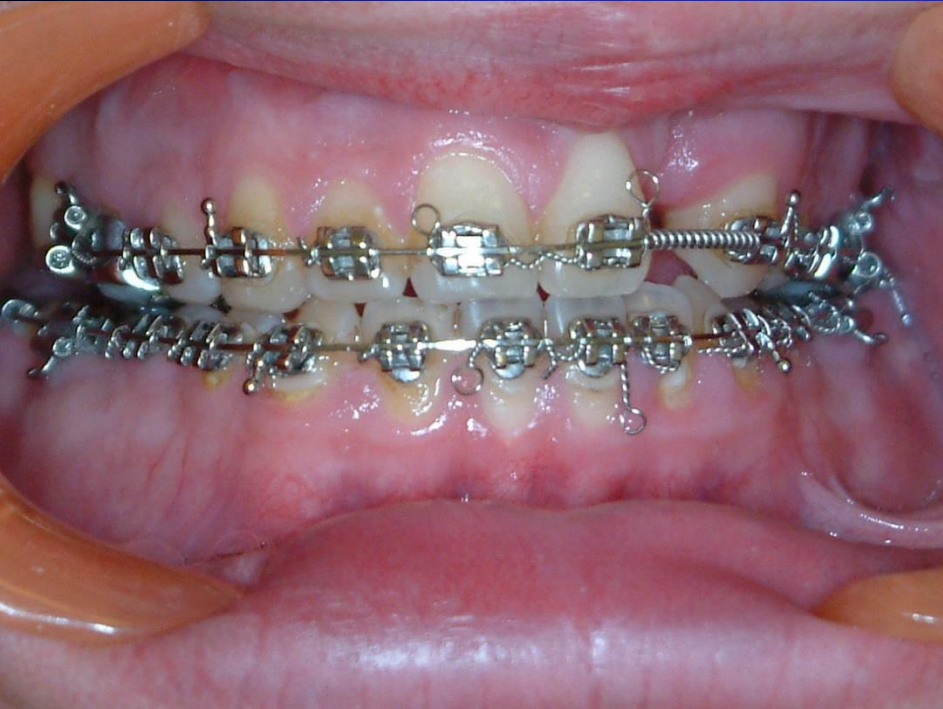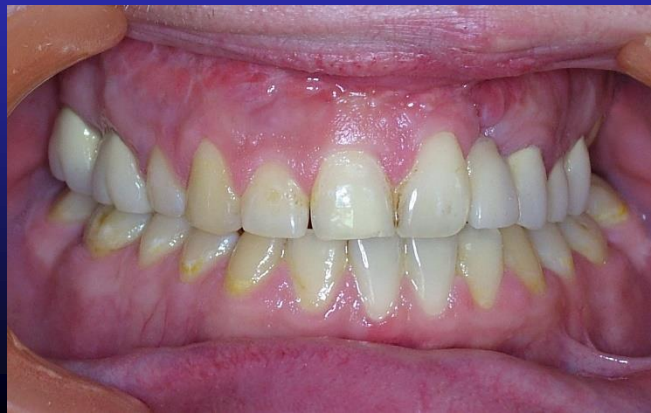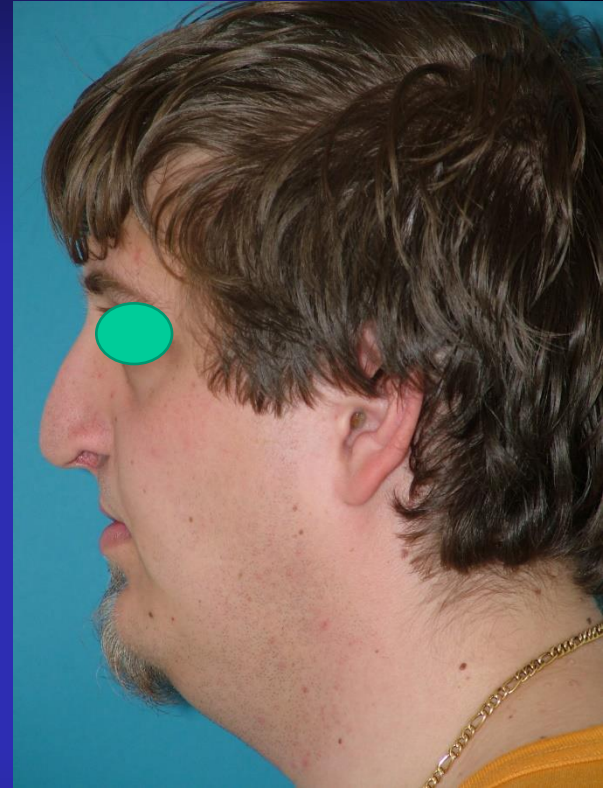




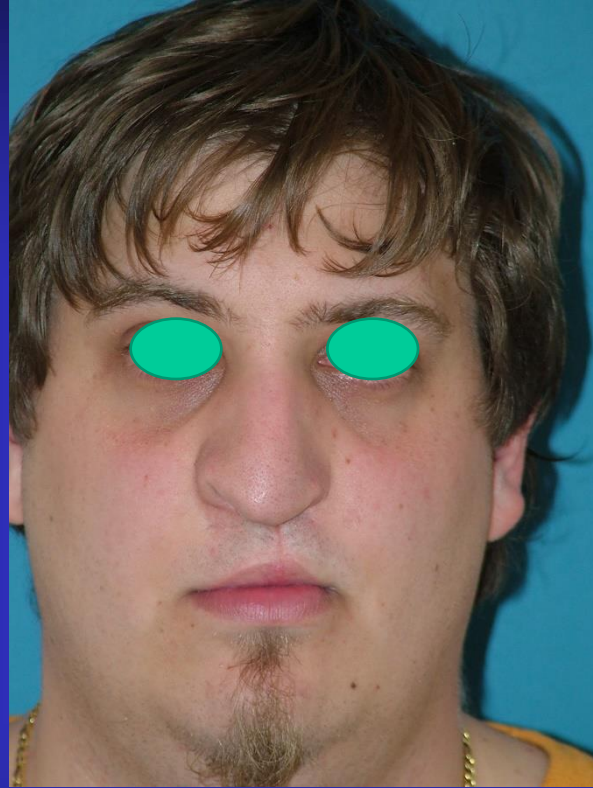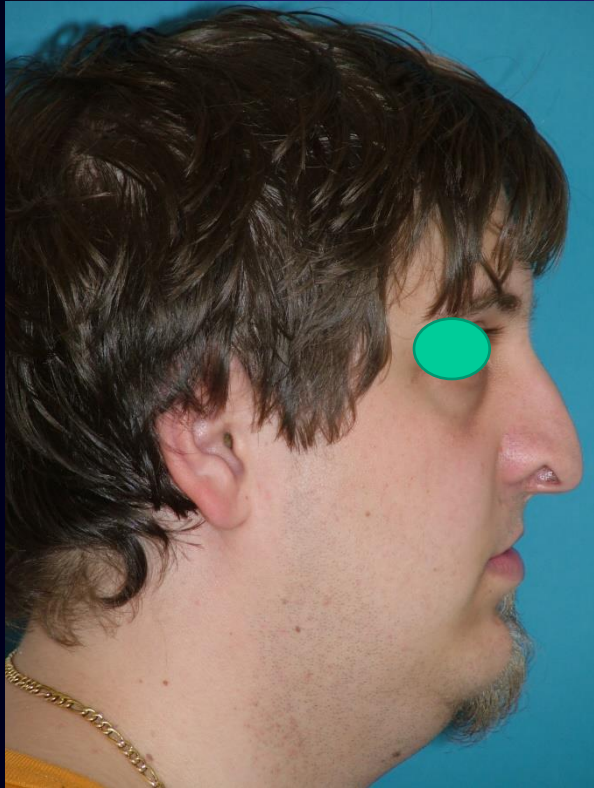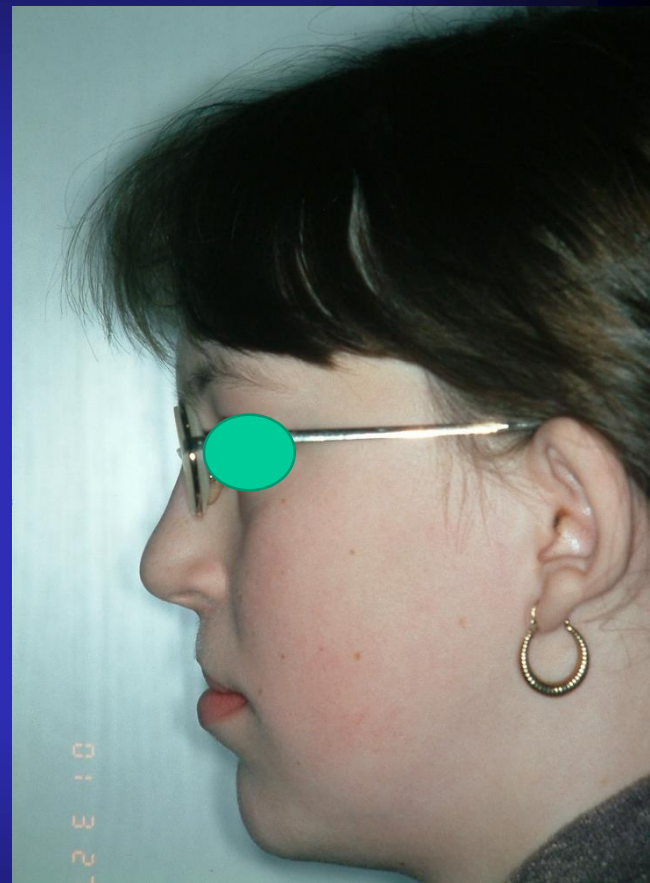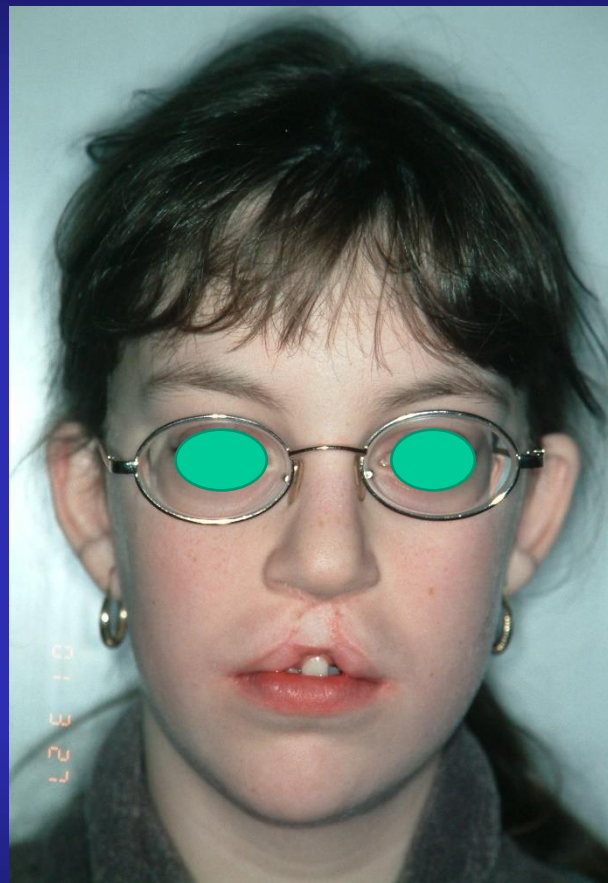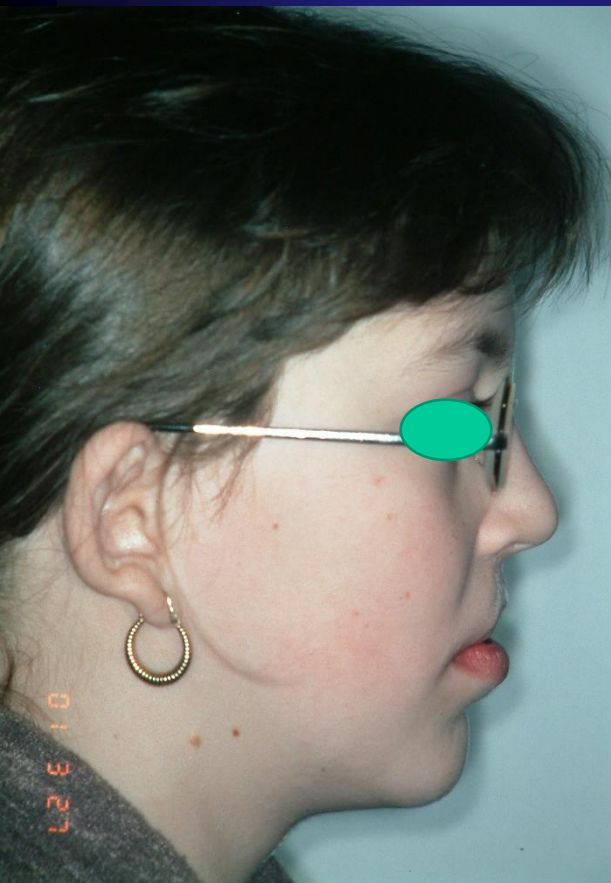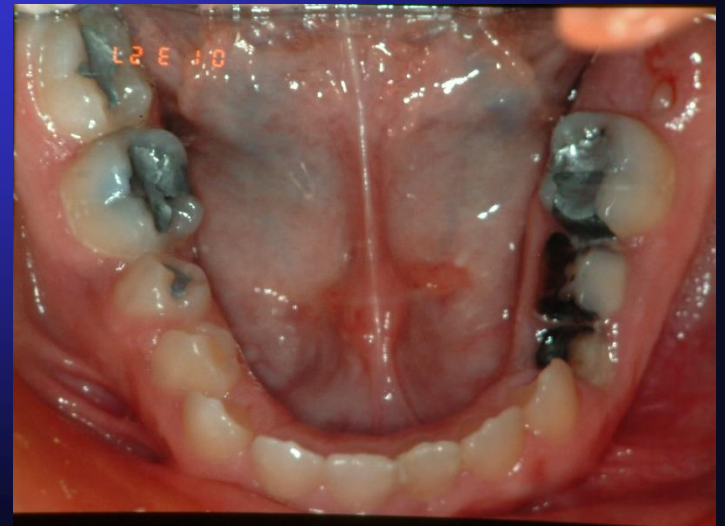


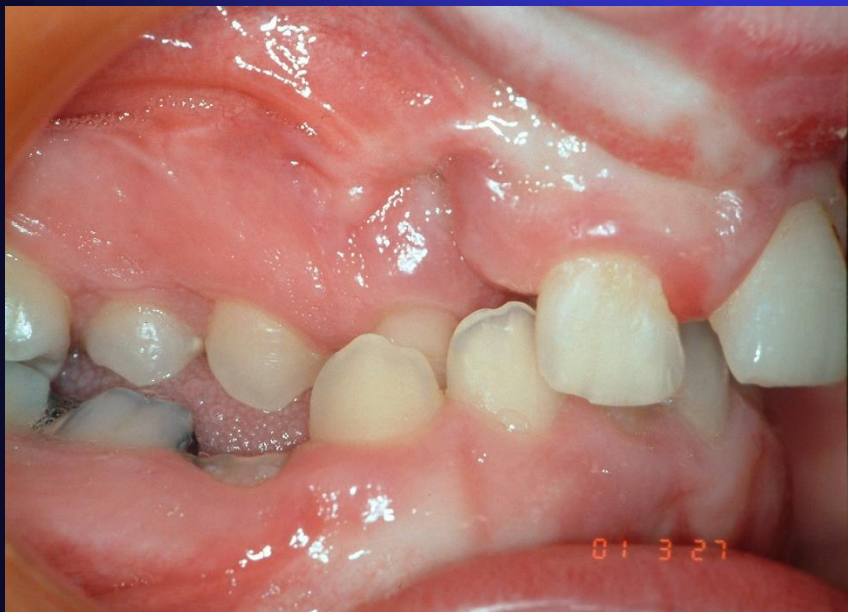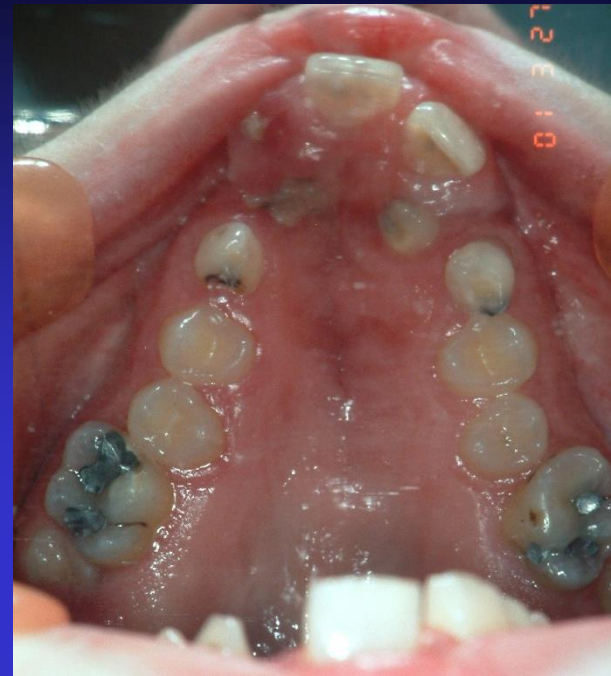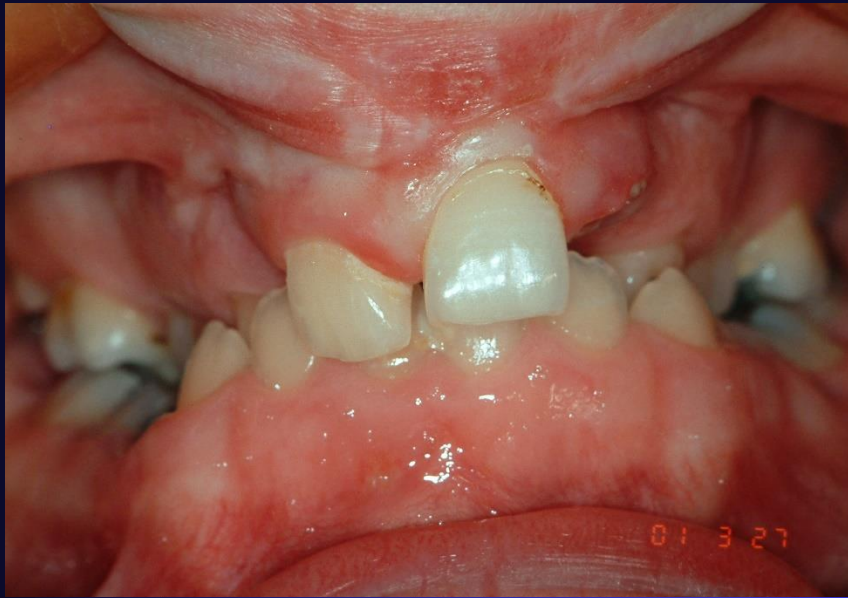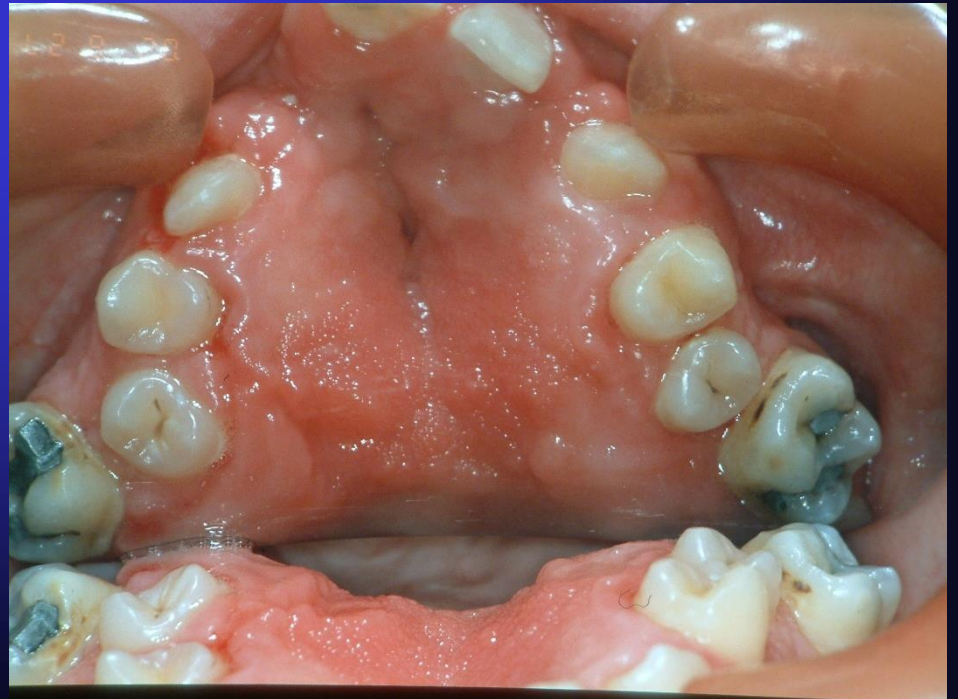
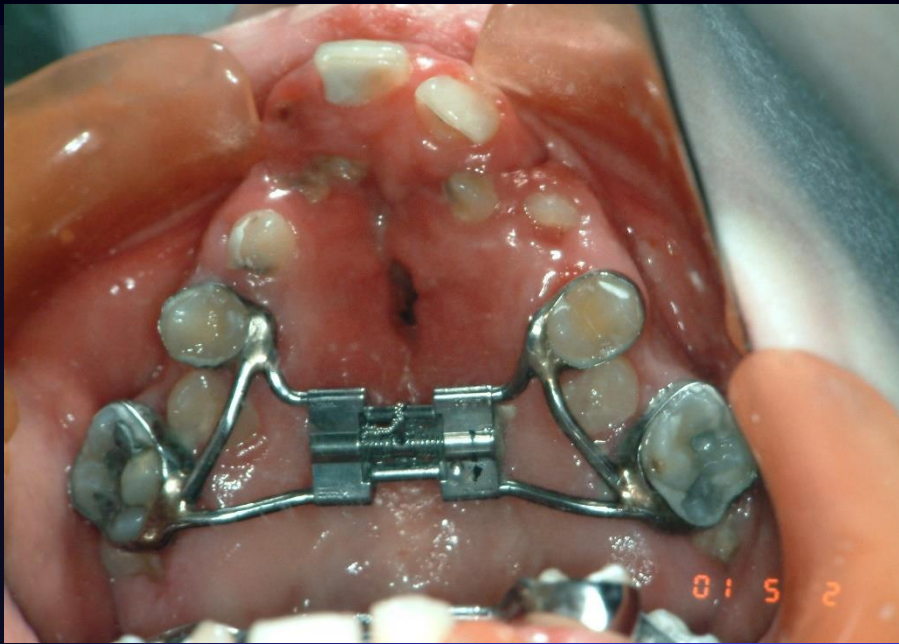


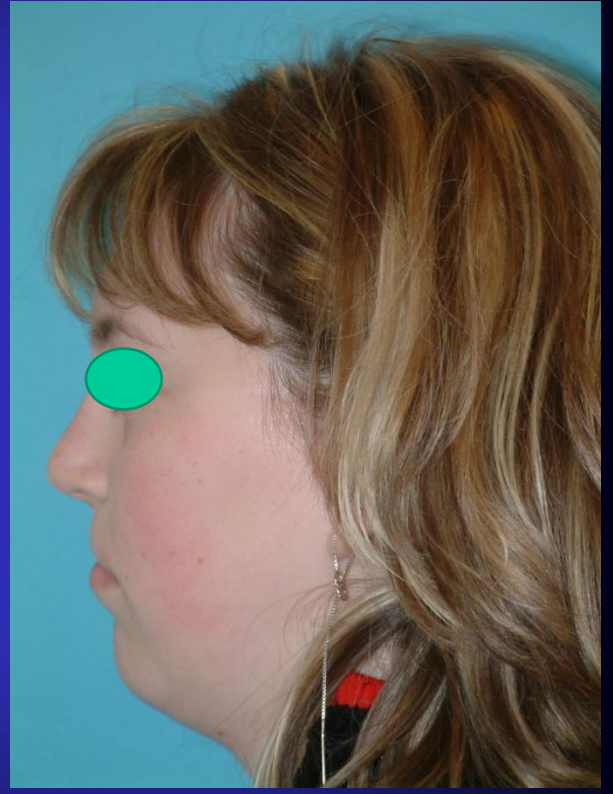




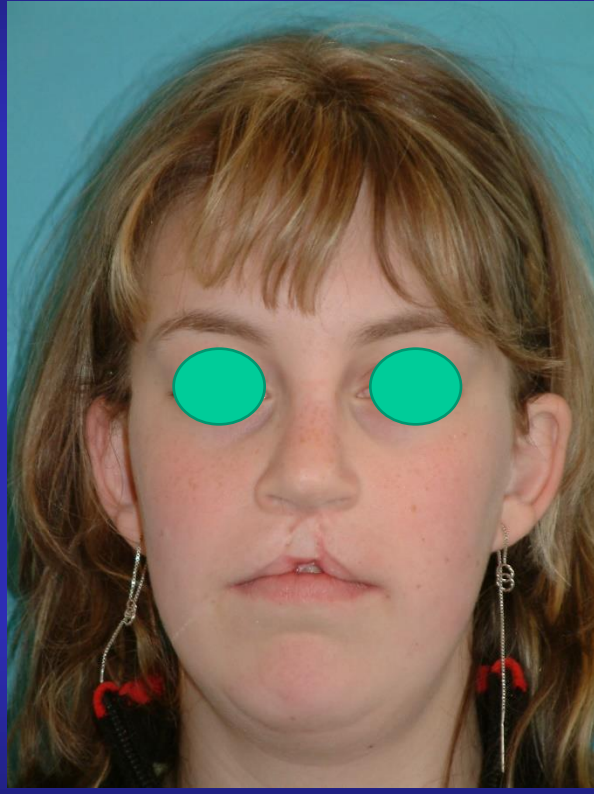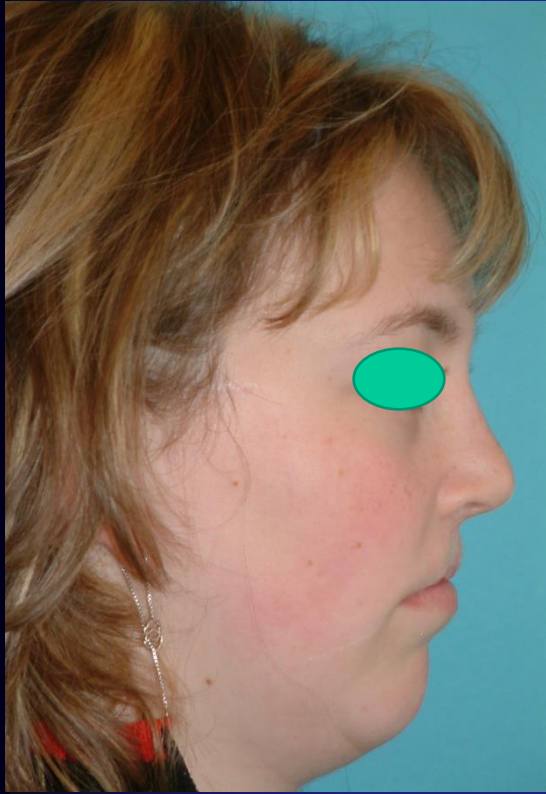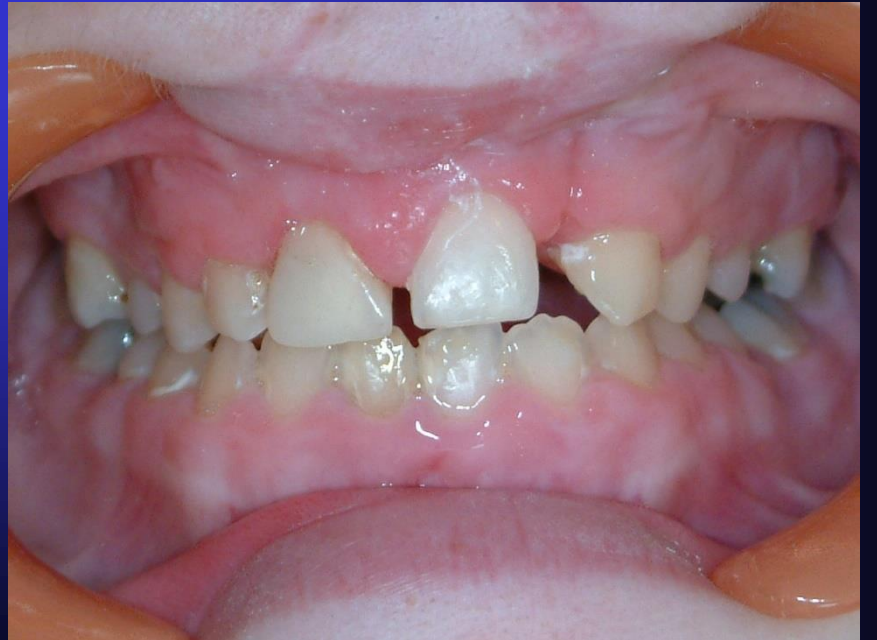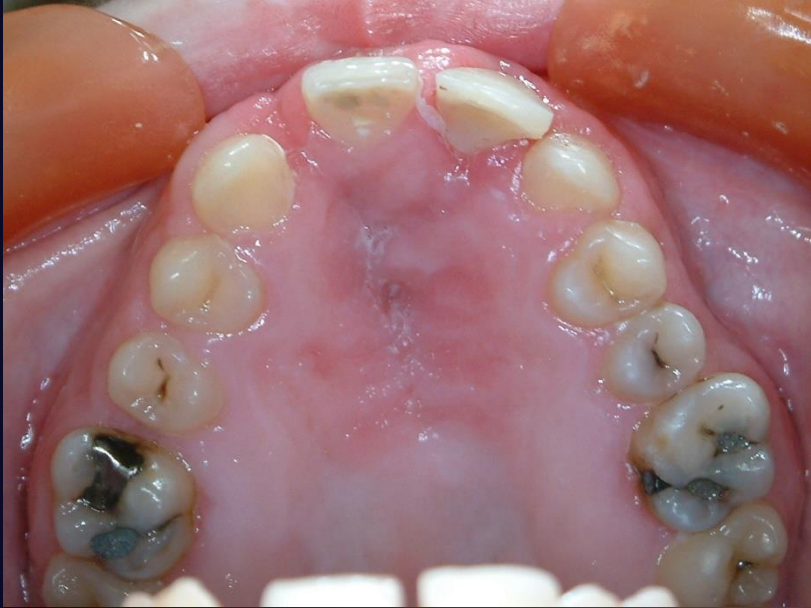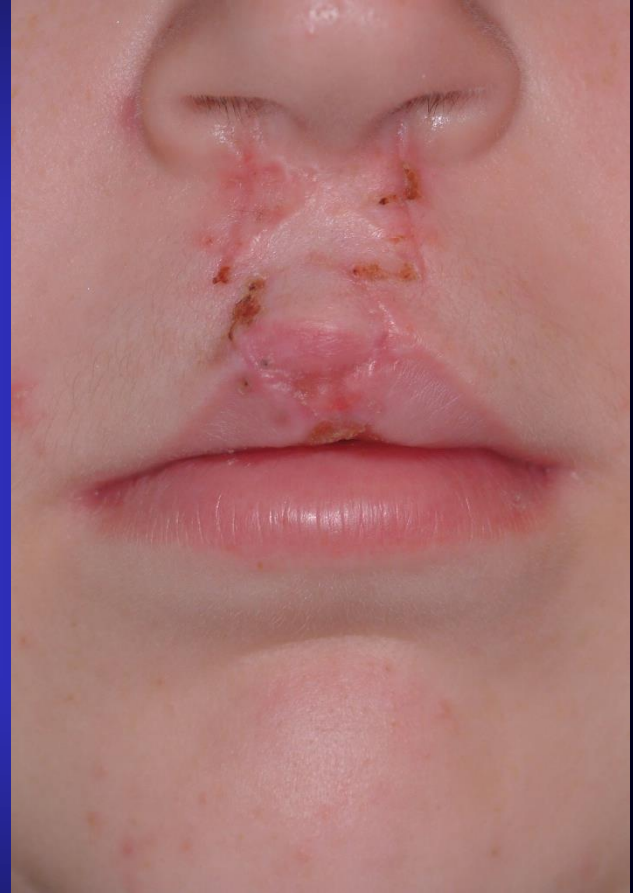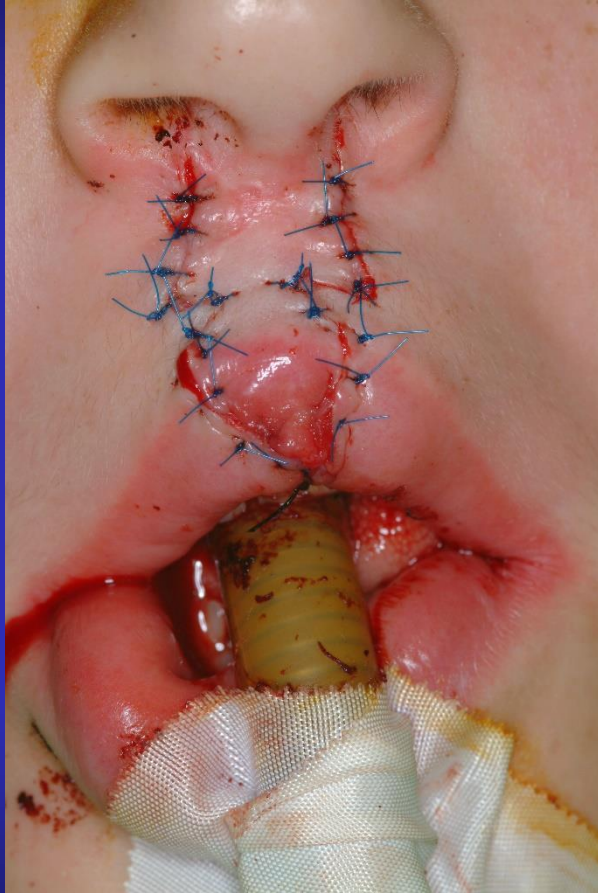
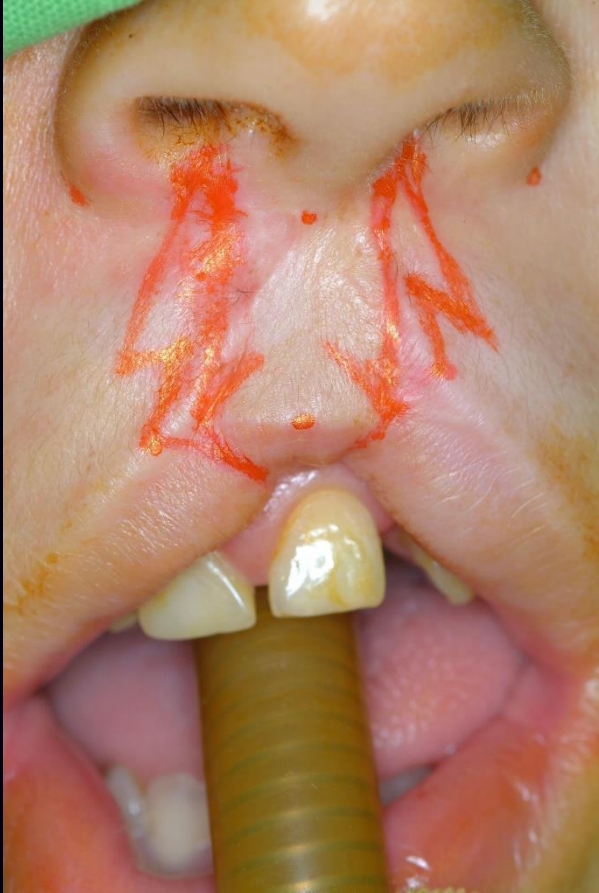



















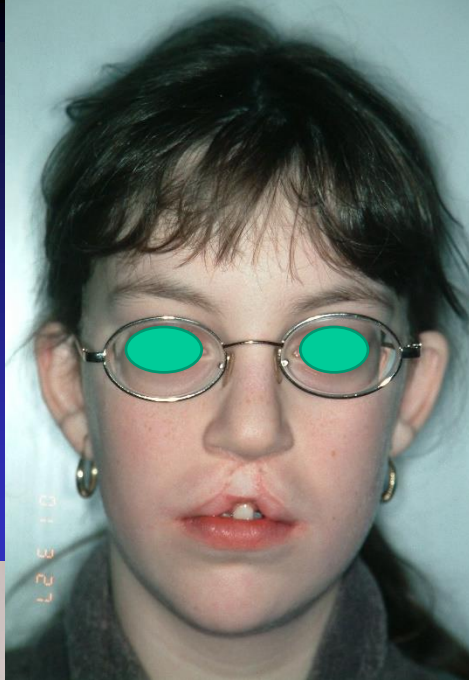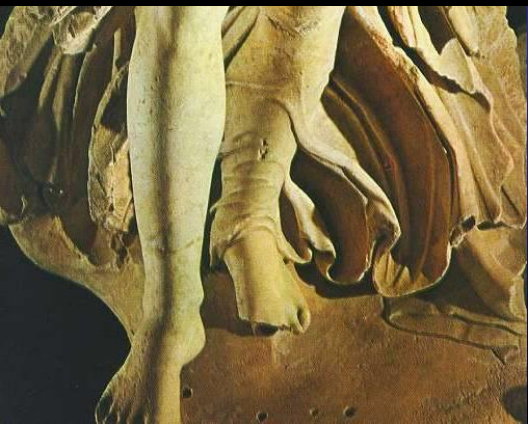FUNKCIÓKIESÉS HELYREÁLLÍTÁSA



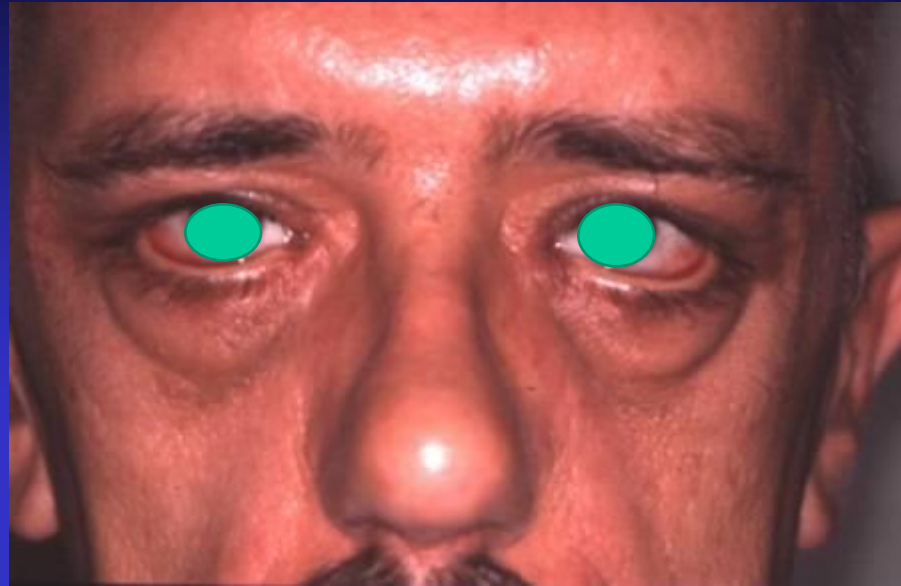

A bénult arc rehabilitációja

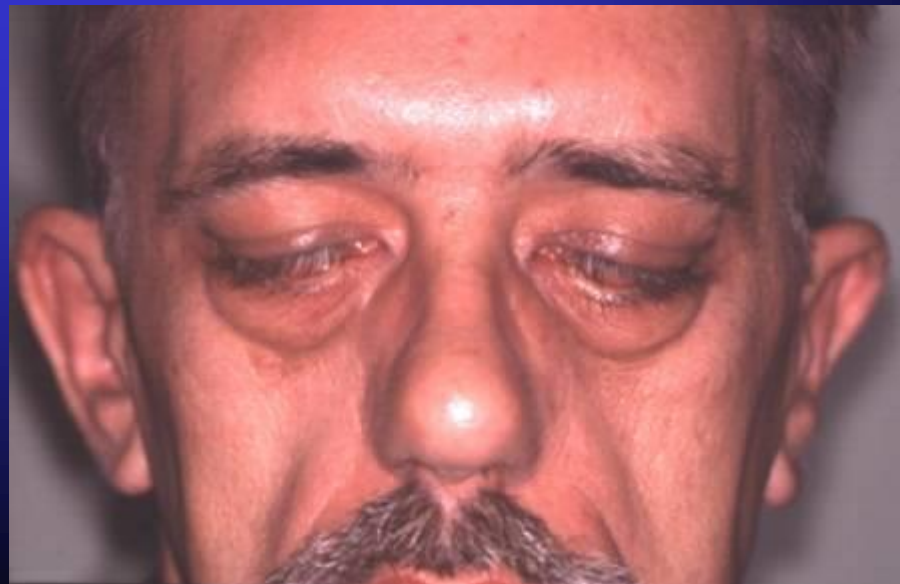


A bénult arc rehabilitációja

**Kétoldali nervus
facialis bénulás**

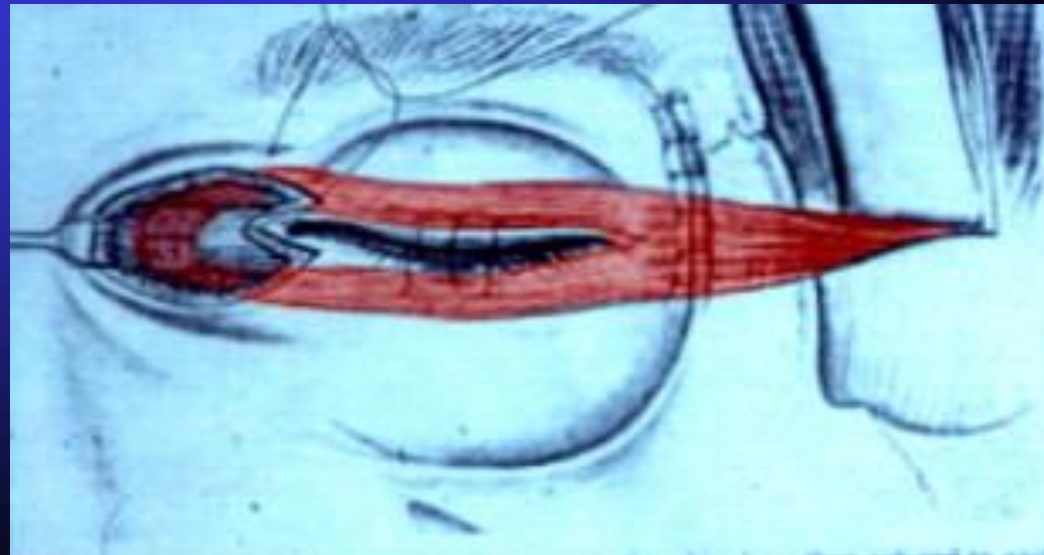
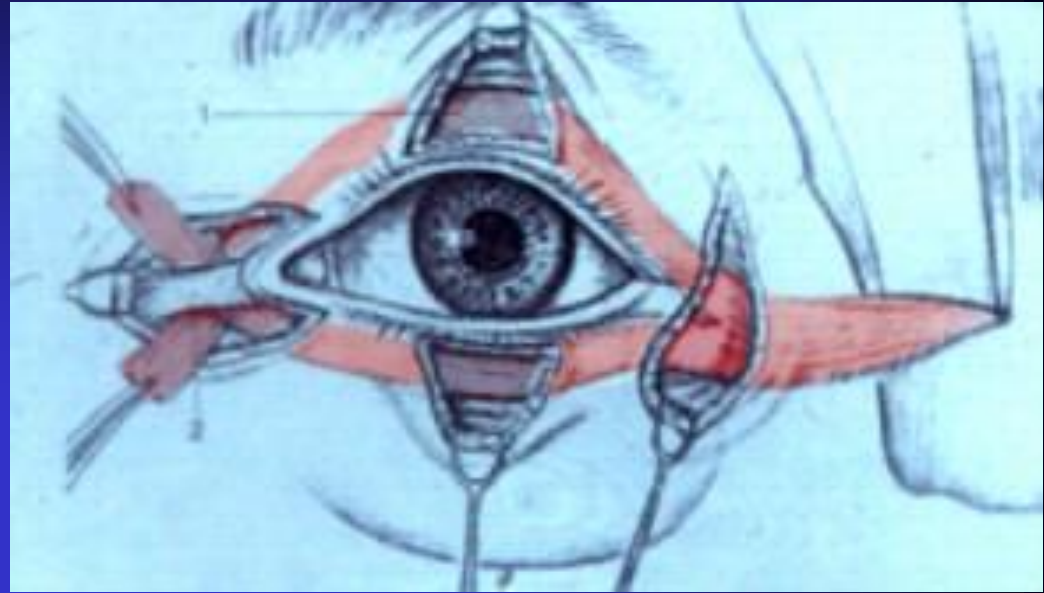
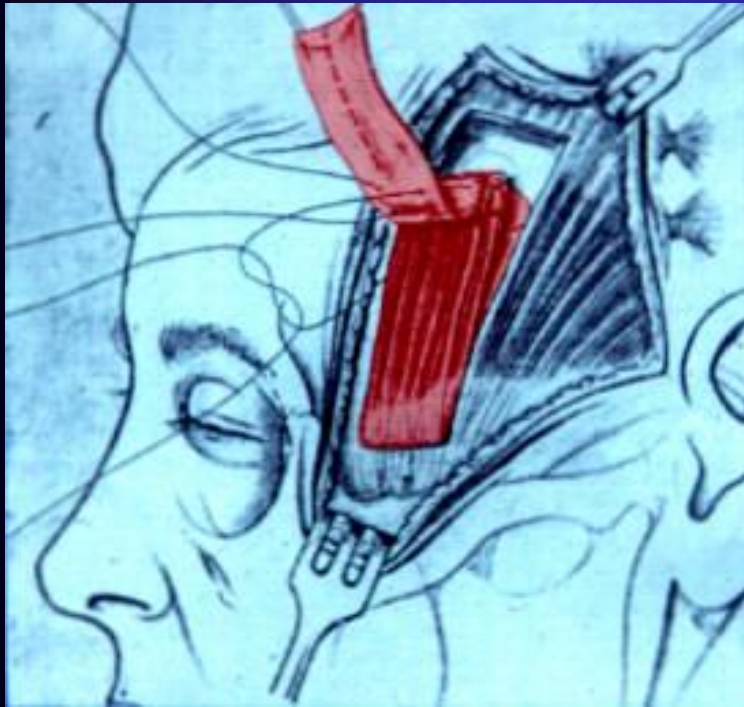


**Idegrekonstrukció
nem lehetséges!**

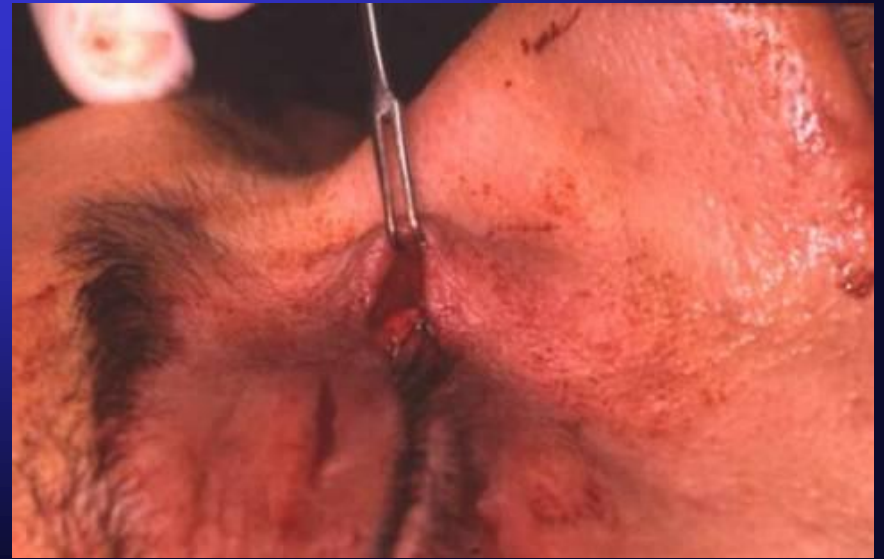
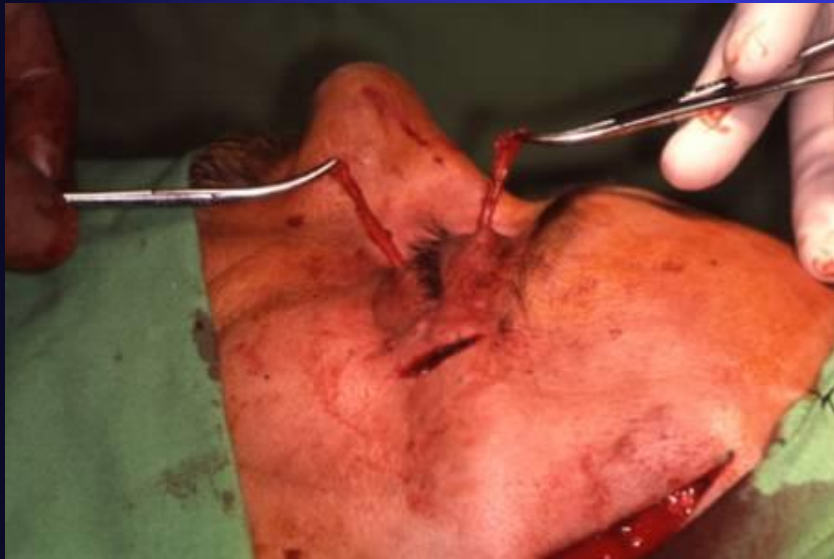
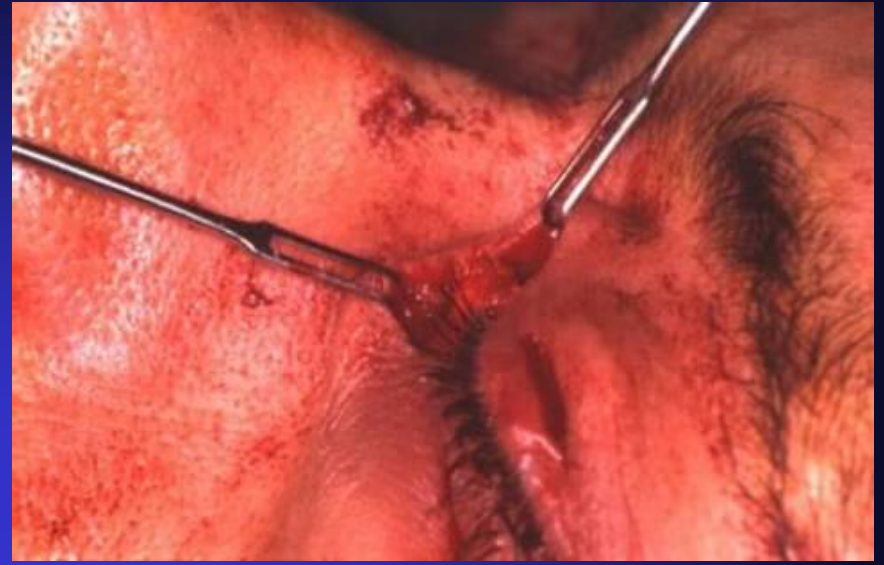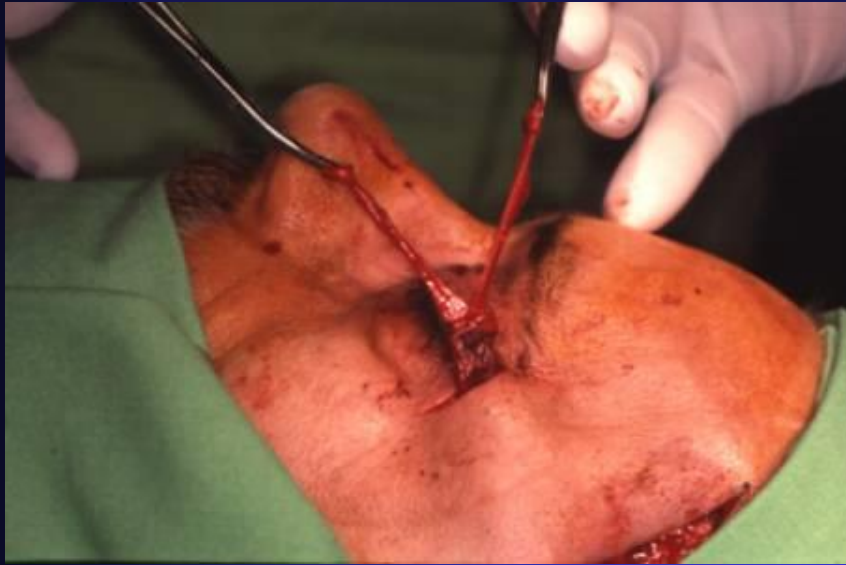**Musculus temporalis
transpositio**

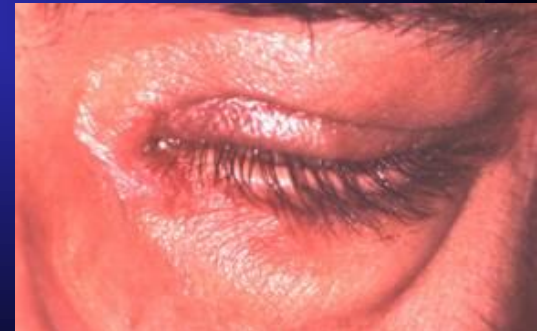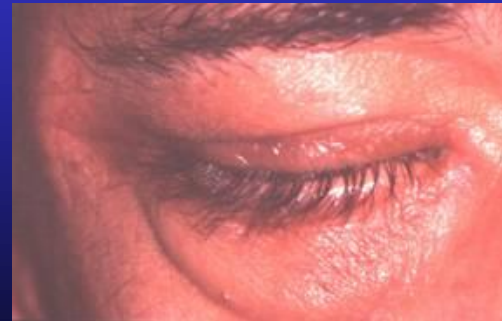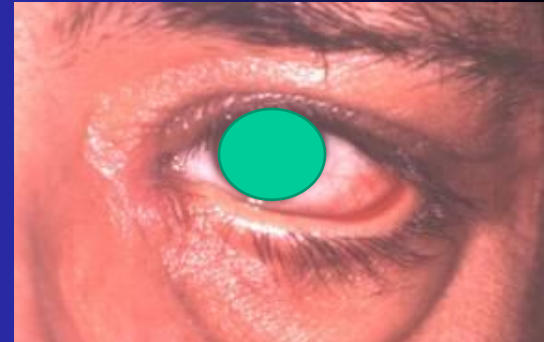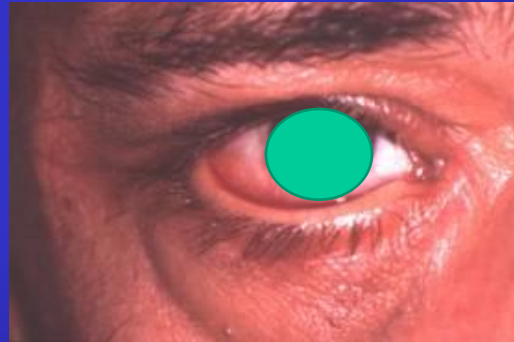
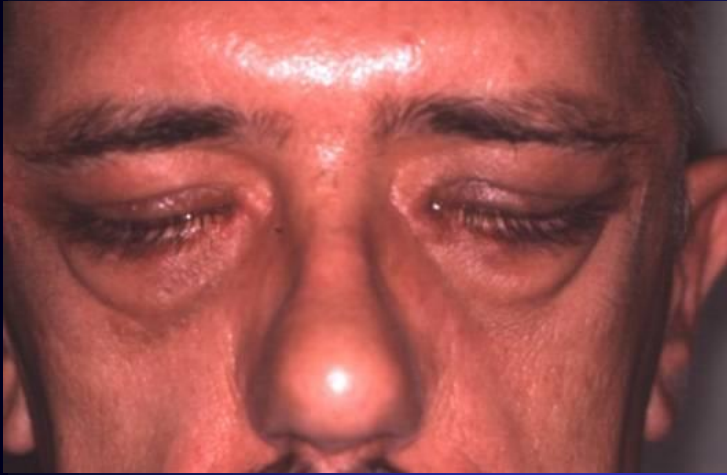A bénult arc rehabilitációja



A bénult arc rehabilitációja



A bénult arc rehabilitációja





Állcsont atrophiák



Állcsont atrophciák

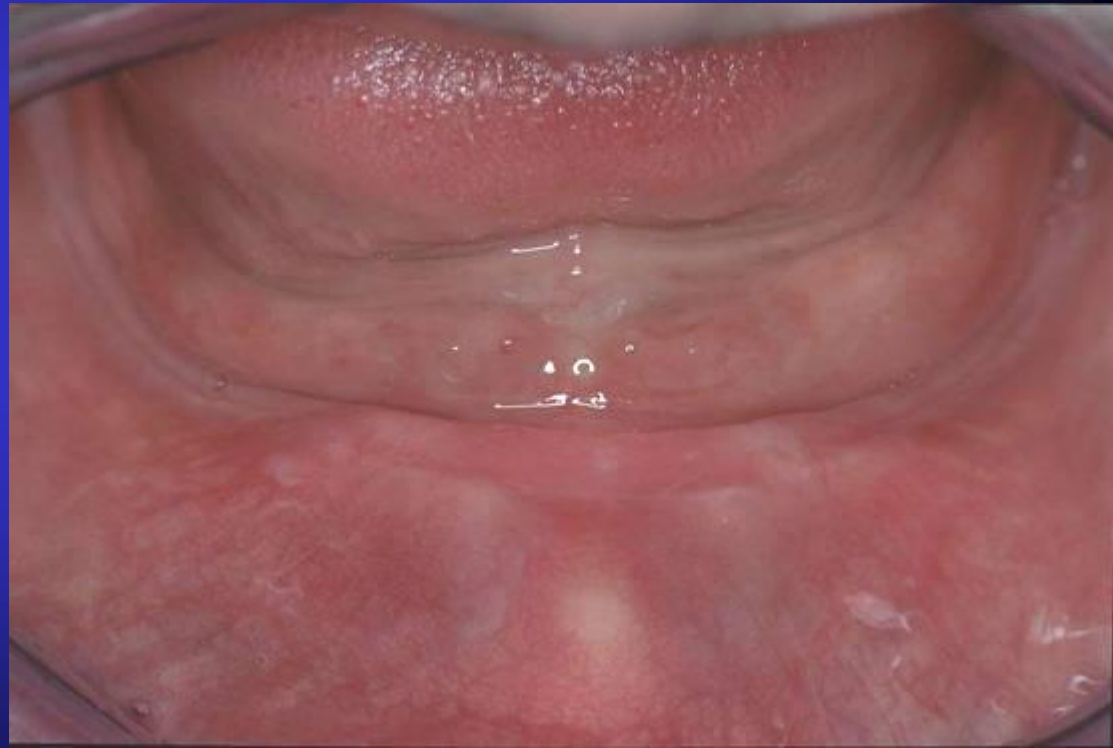Maxilla és mandibula

Cawood VI.

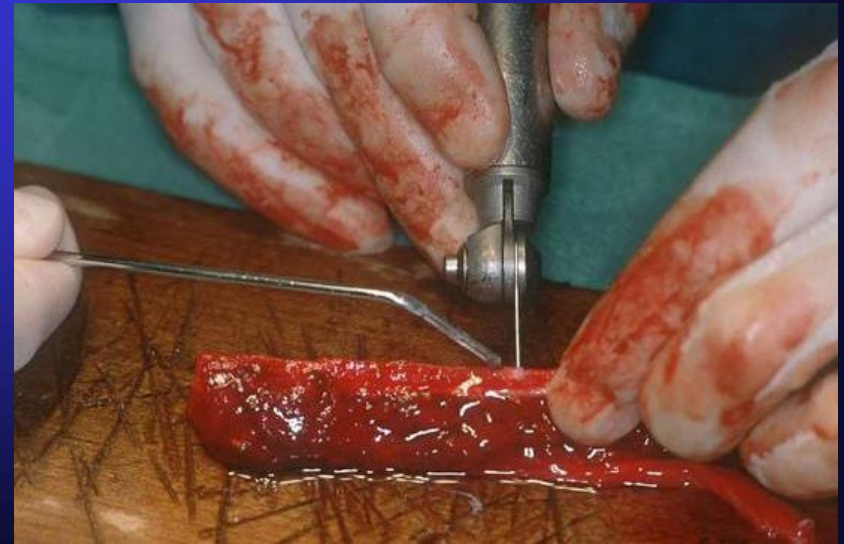
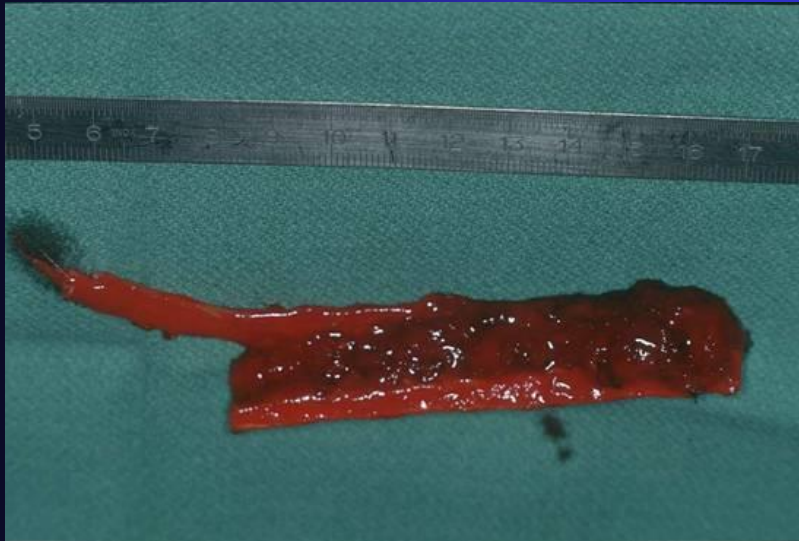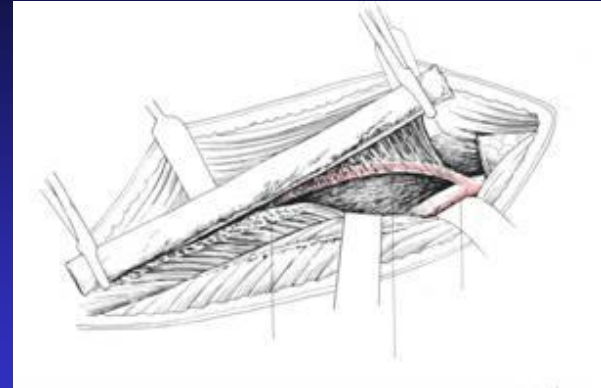
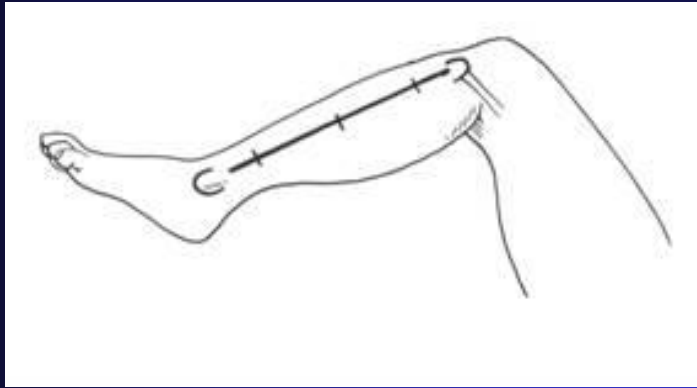
**Állcsont ortopédiai
analízis és előkészítés
után**

**mikrovascularis
fibula**

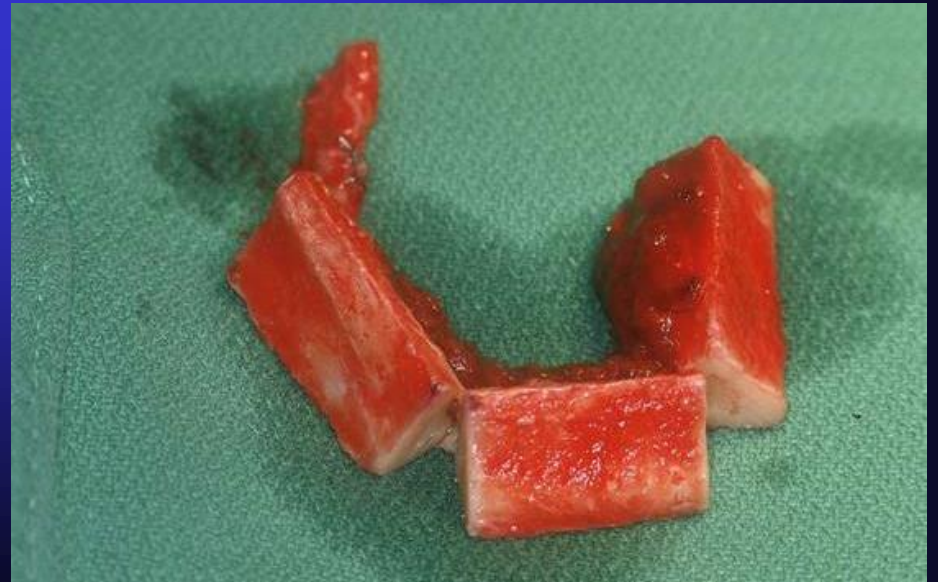
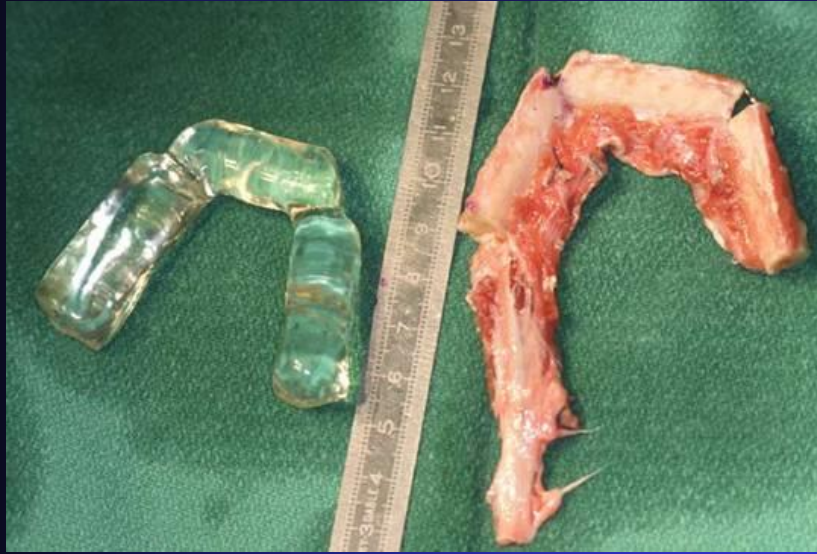**transplantátummal
augmentatio**



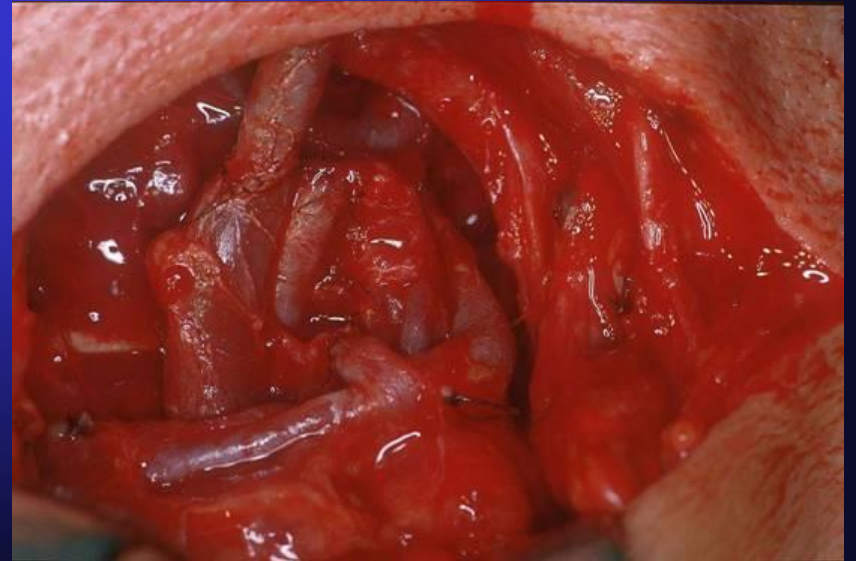
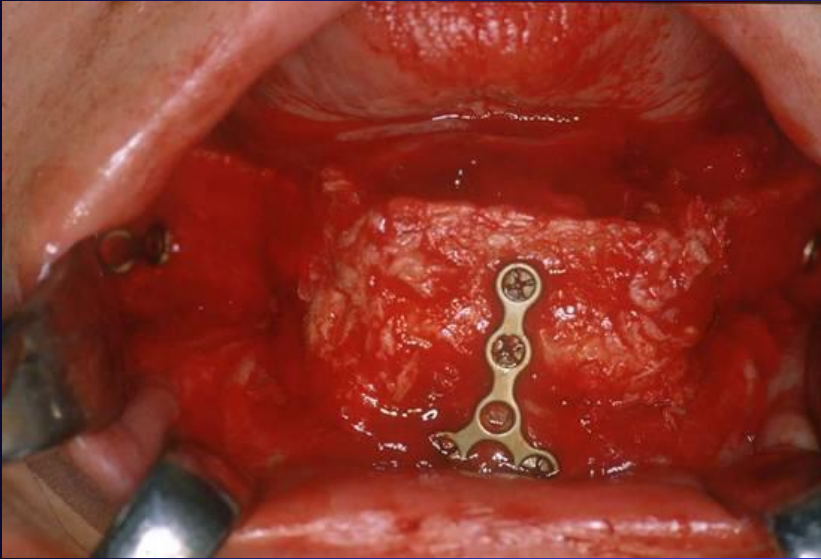
Állcsont atrophhiák



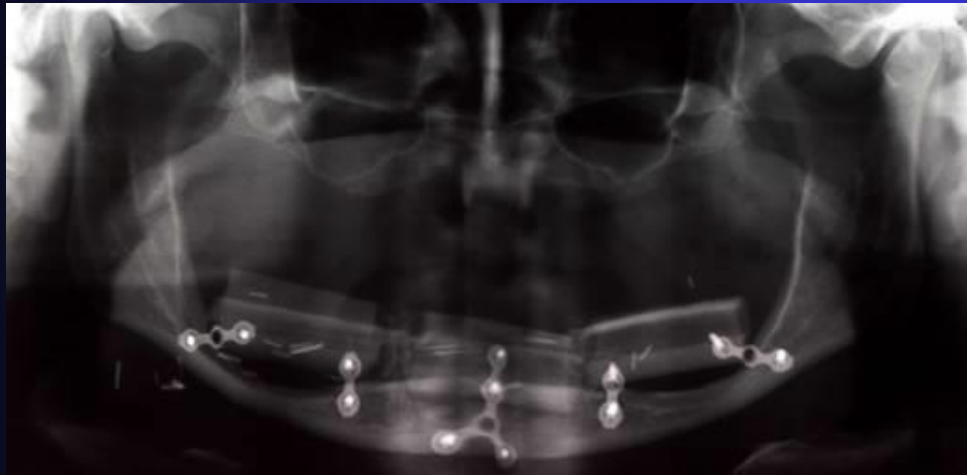
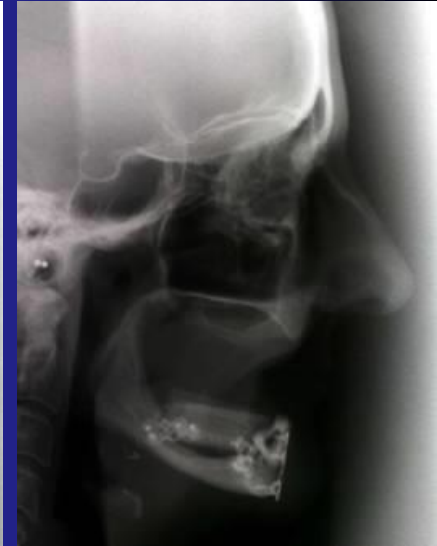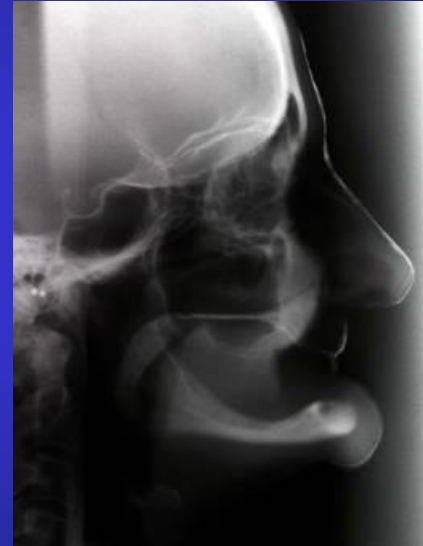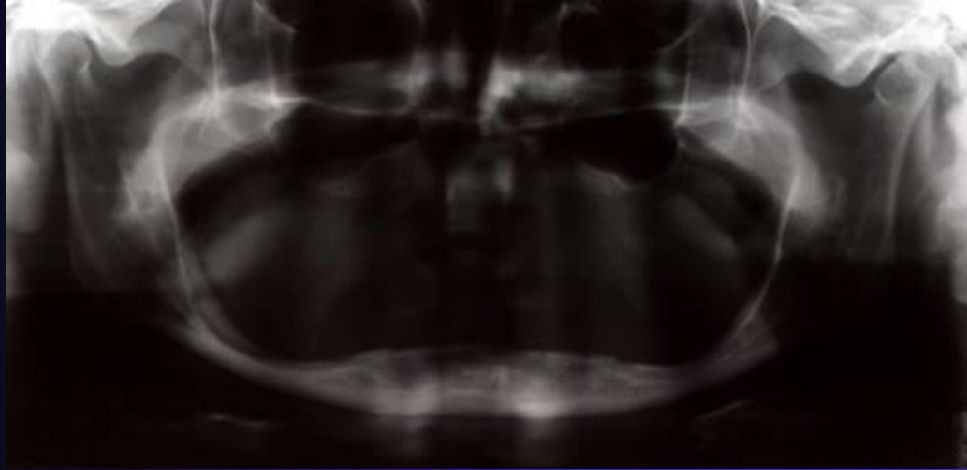
Állcsont atrophhiák



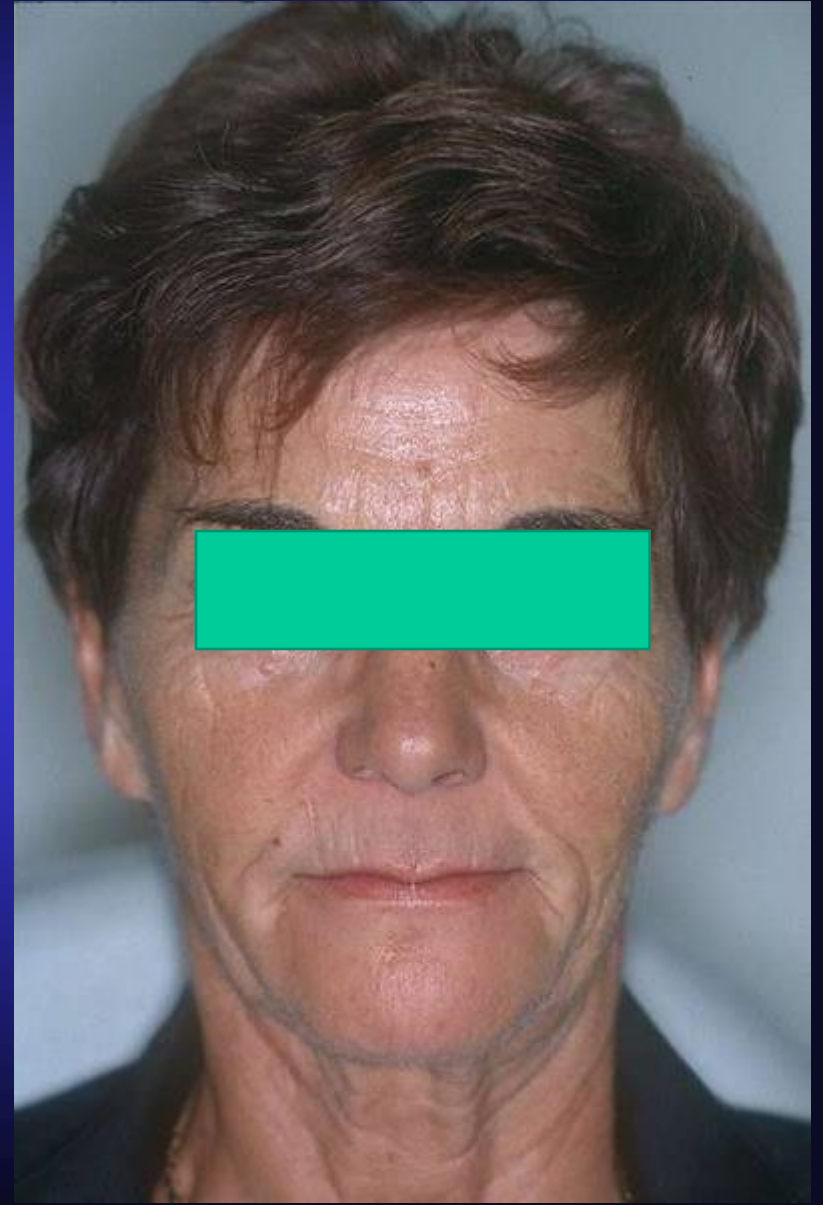
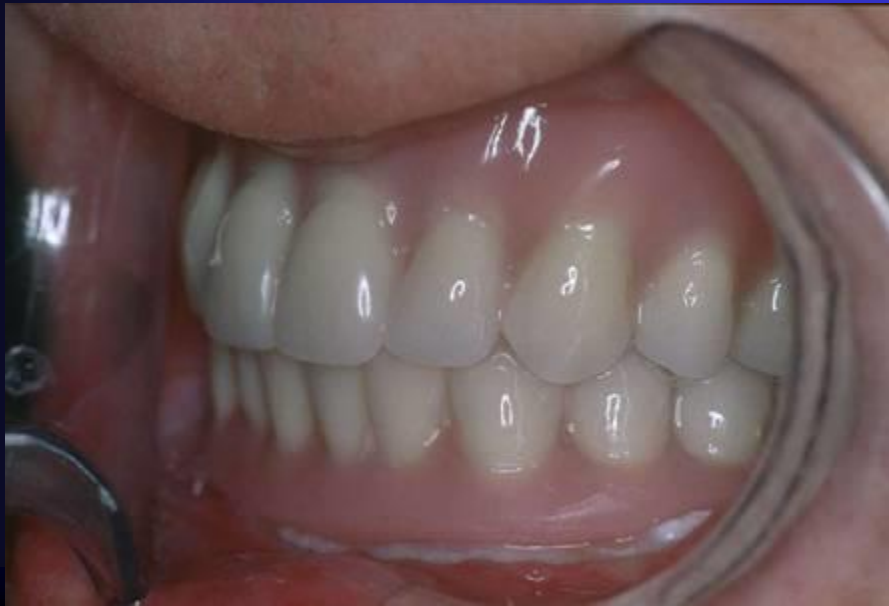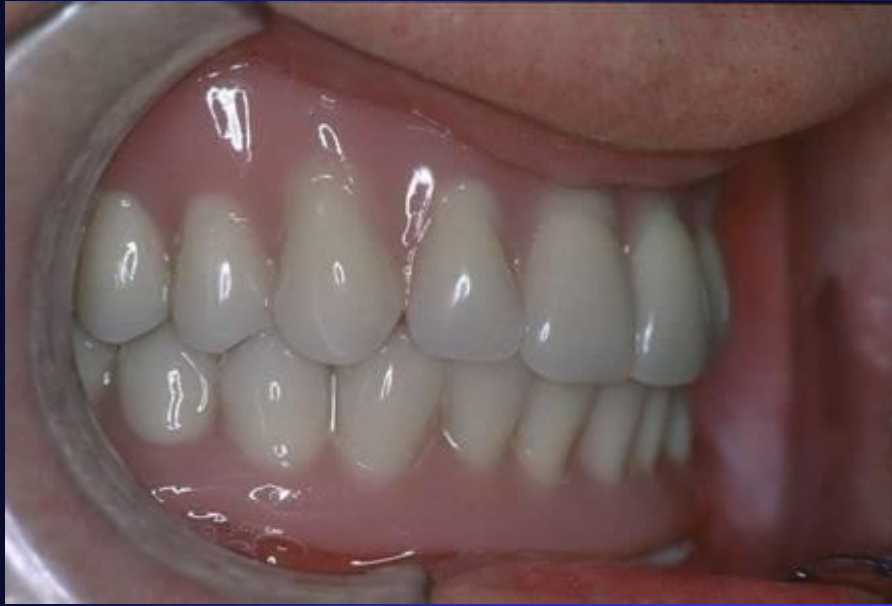Állcsont atrophhiák




Állcsont atrophhiák



Állcsont atrophhiák





Köszönöm a figyelmüket!