

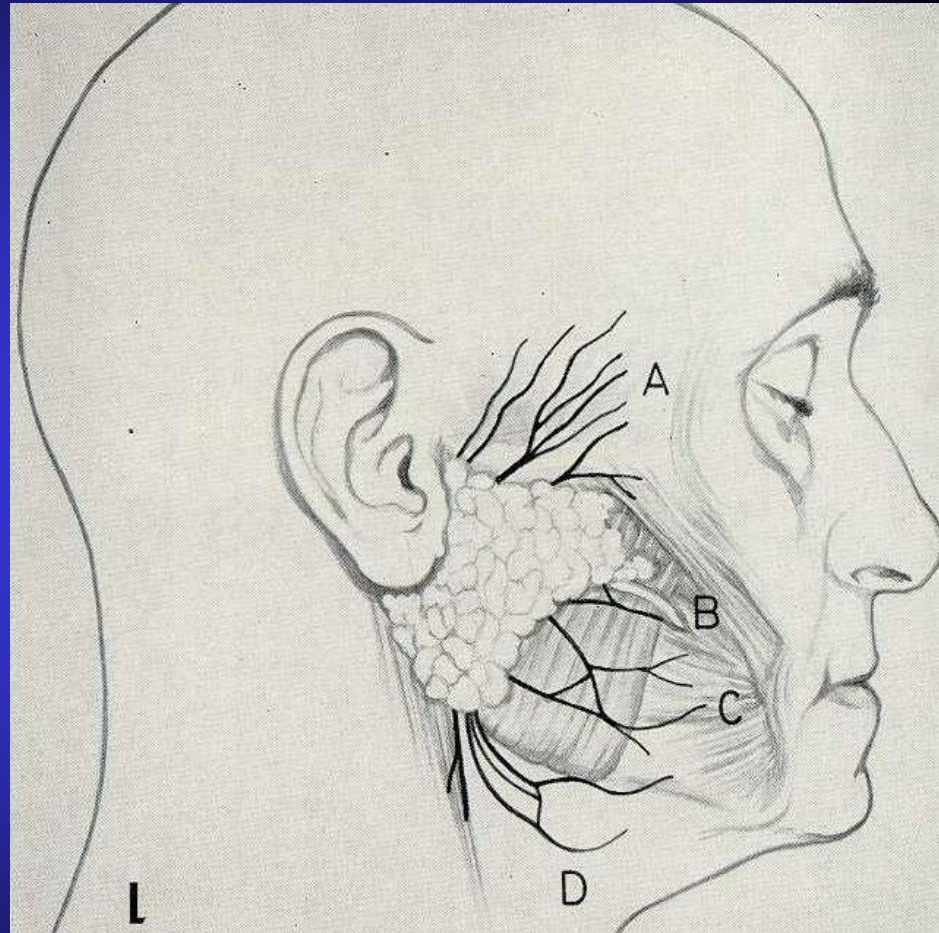
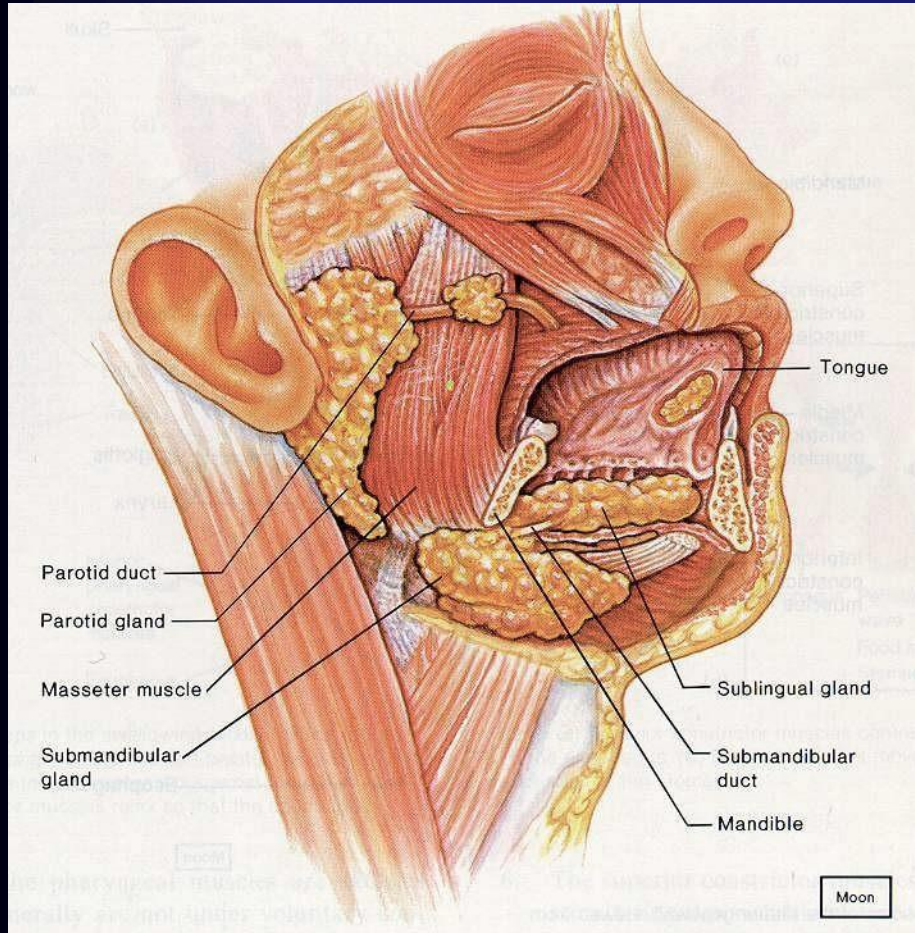


# Nyálmirigyek betegségei

Diagnosztikai módszerek

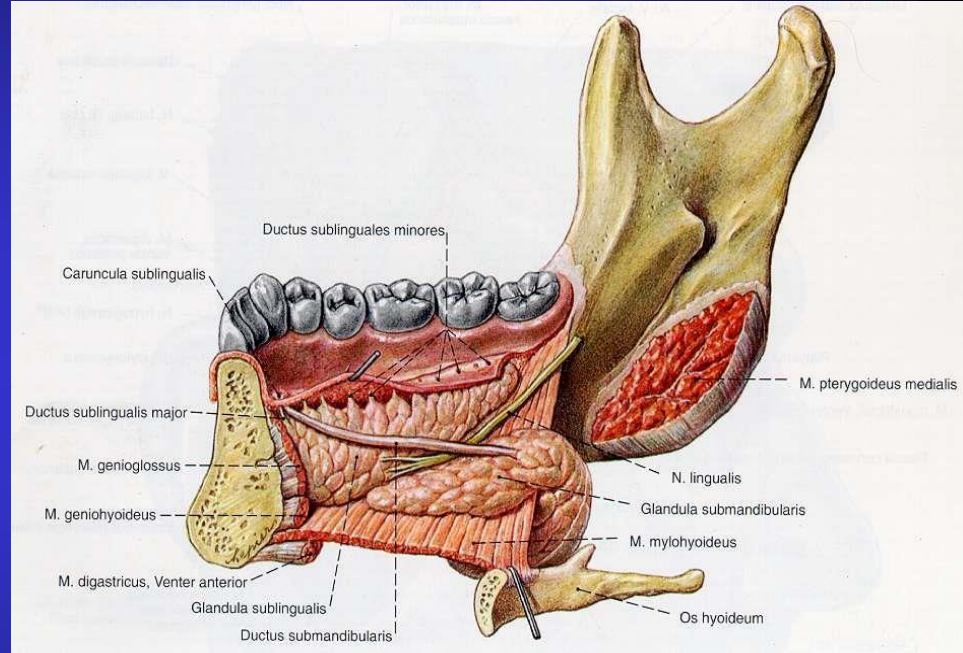
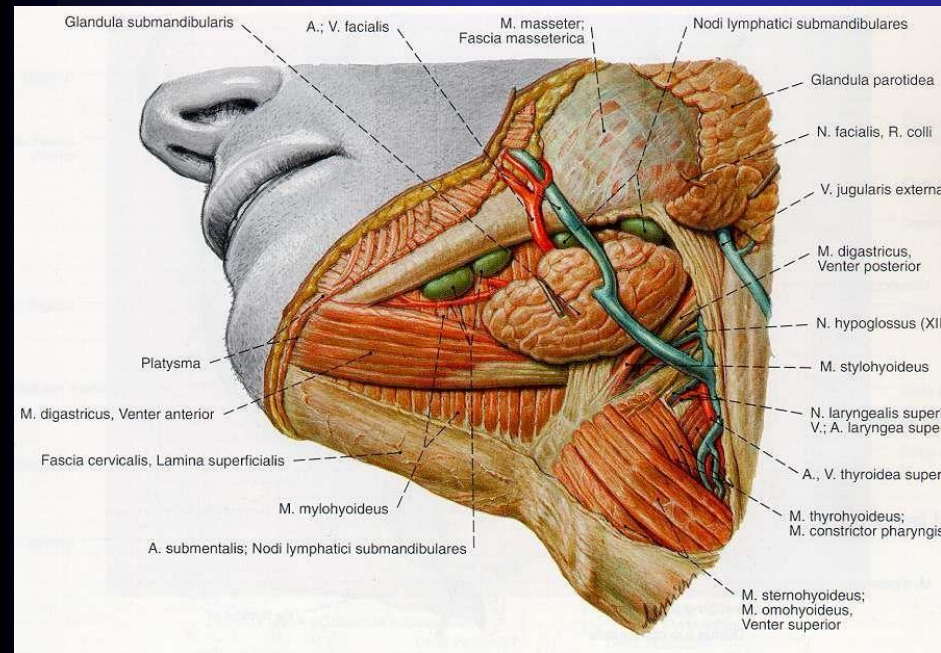
Kezelés

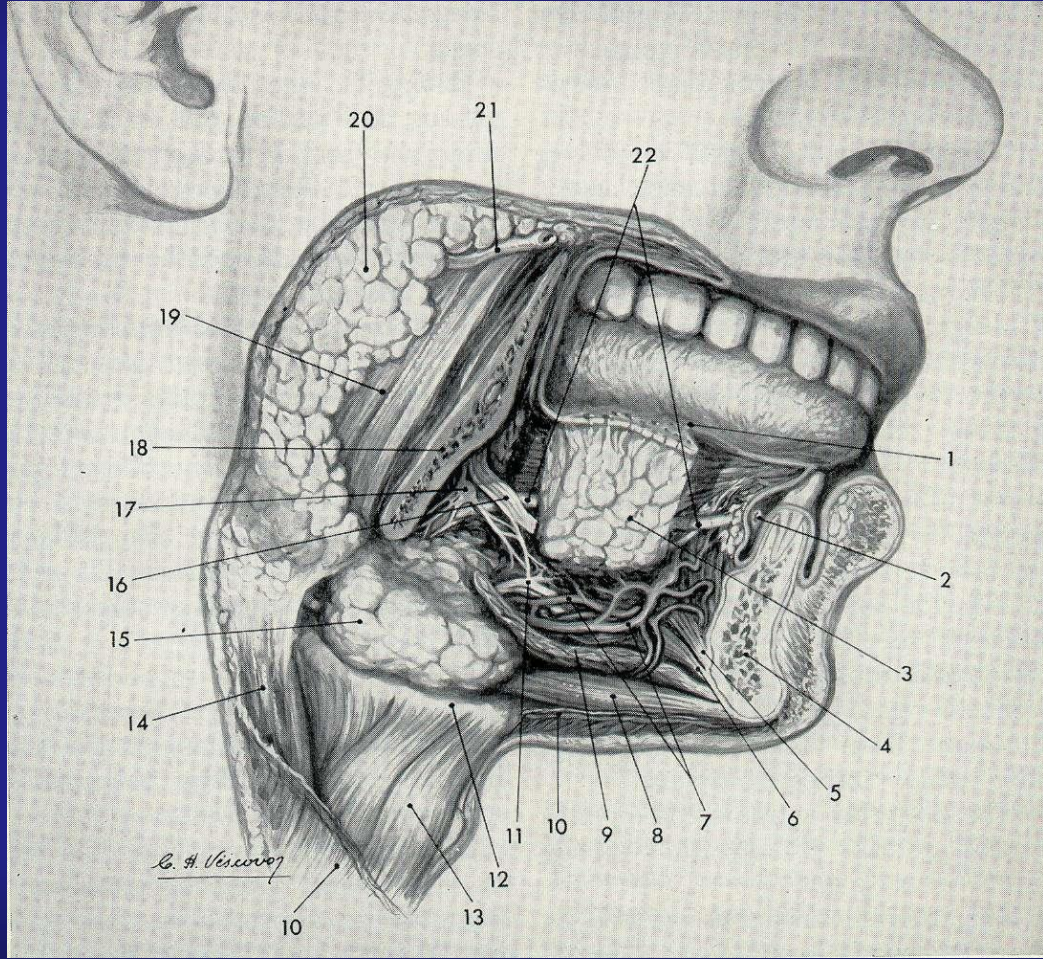
# Glandula parotis



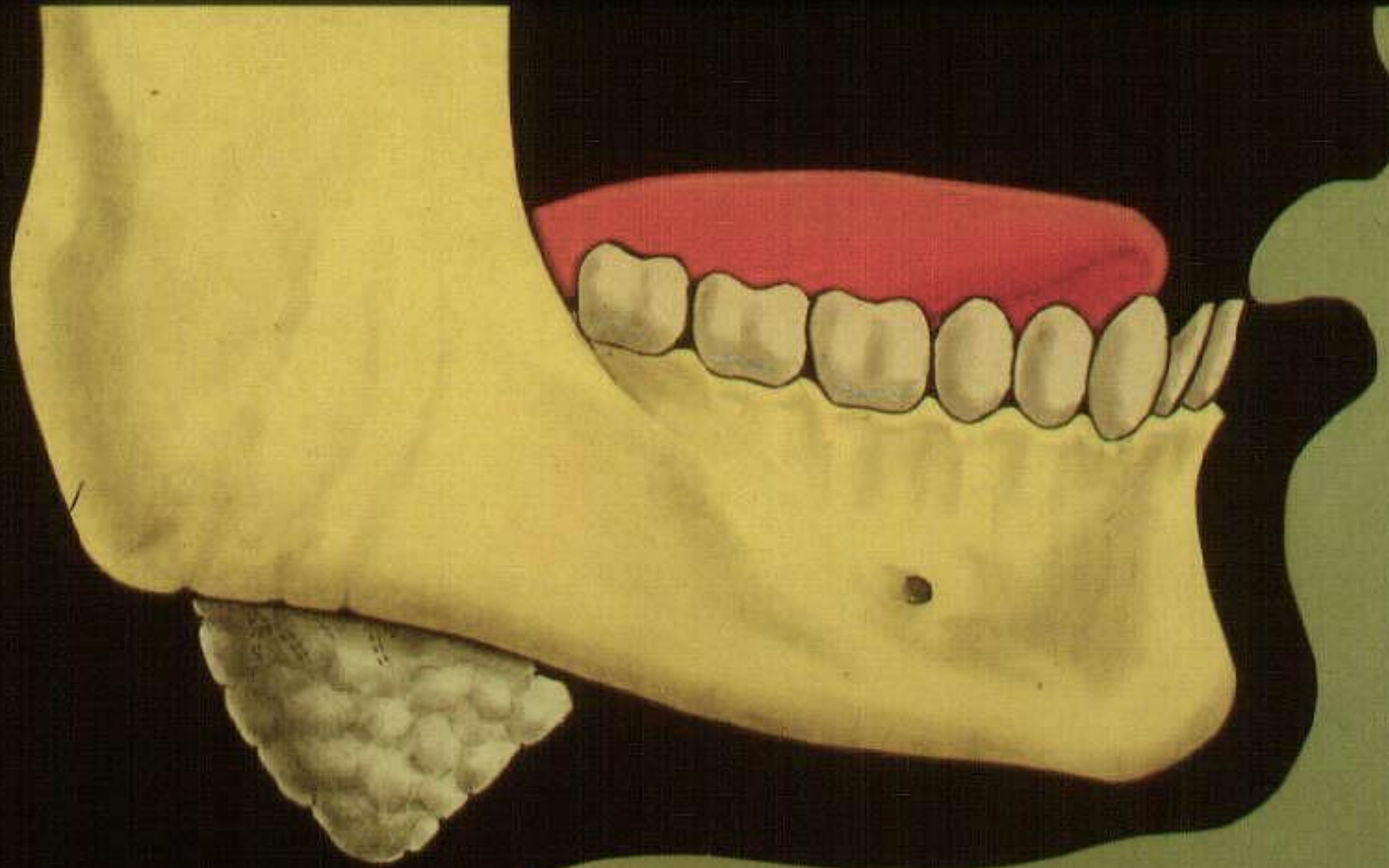


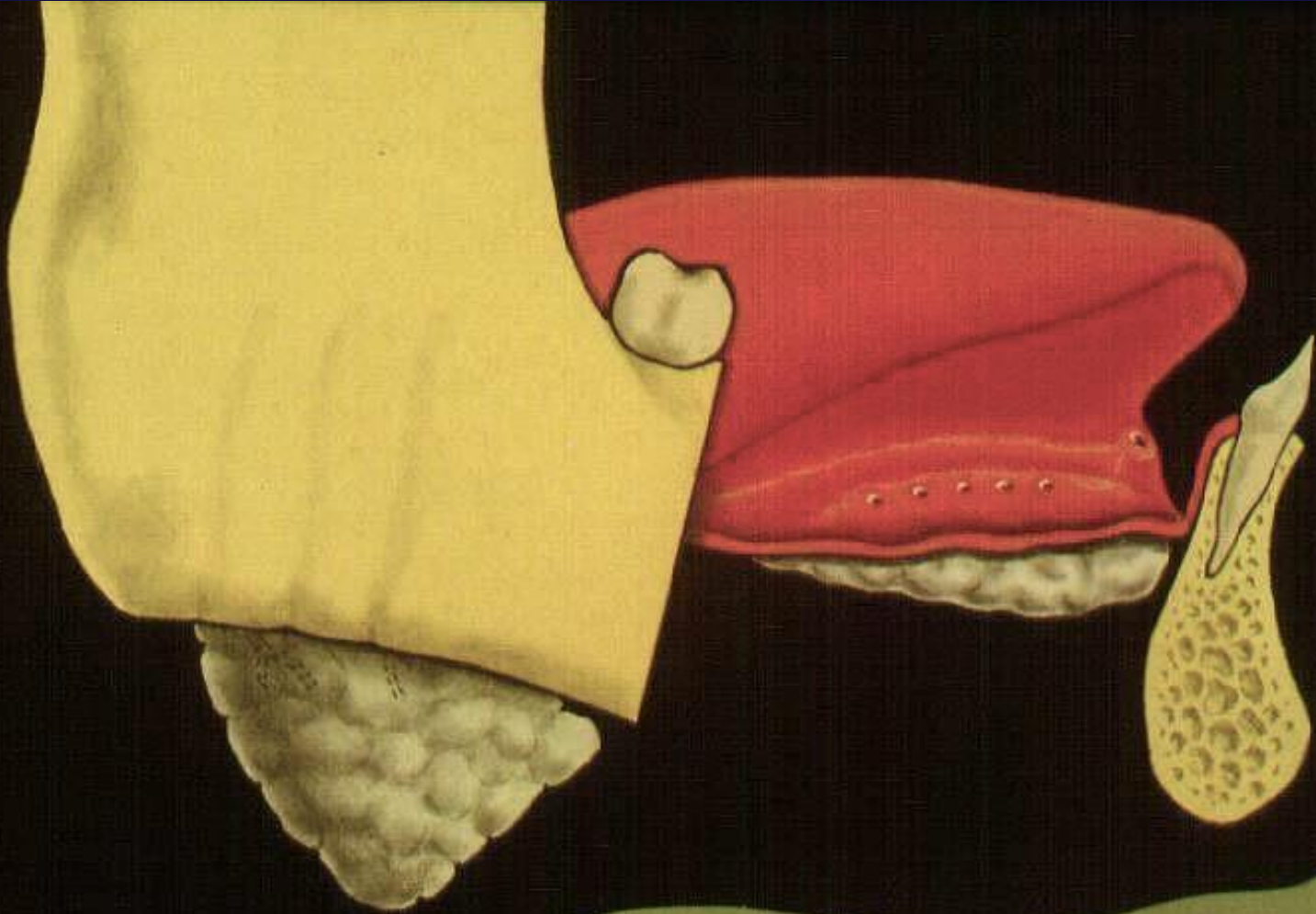
# Glandula submandibularis



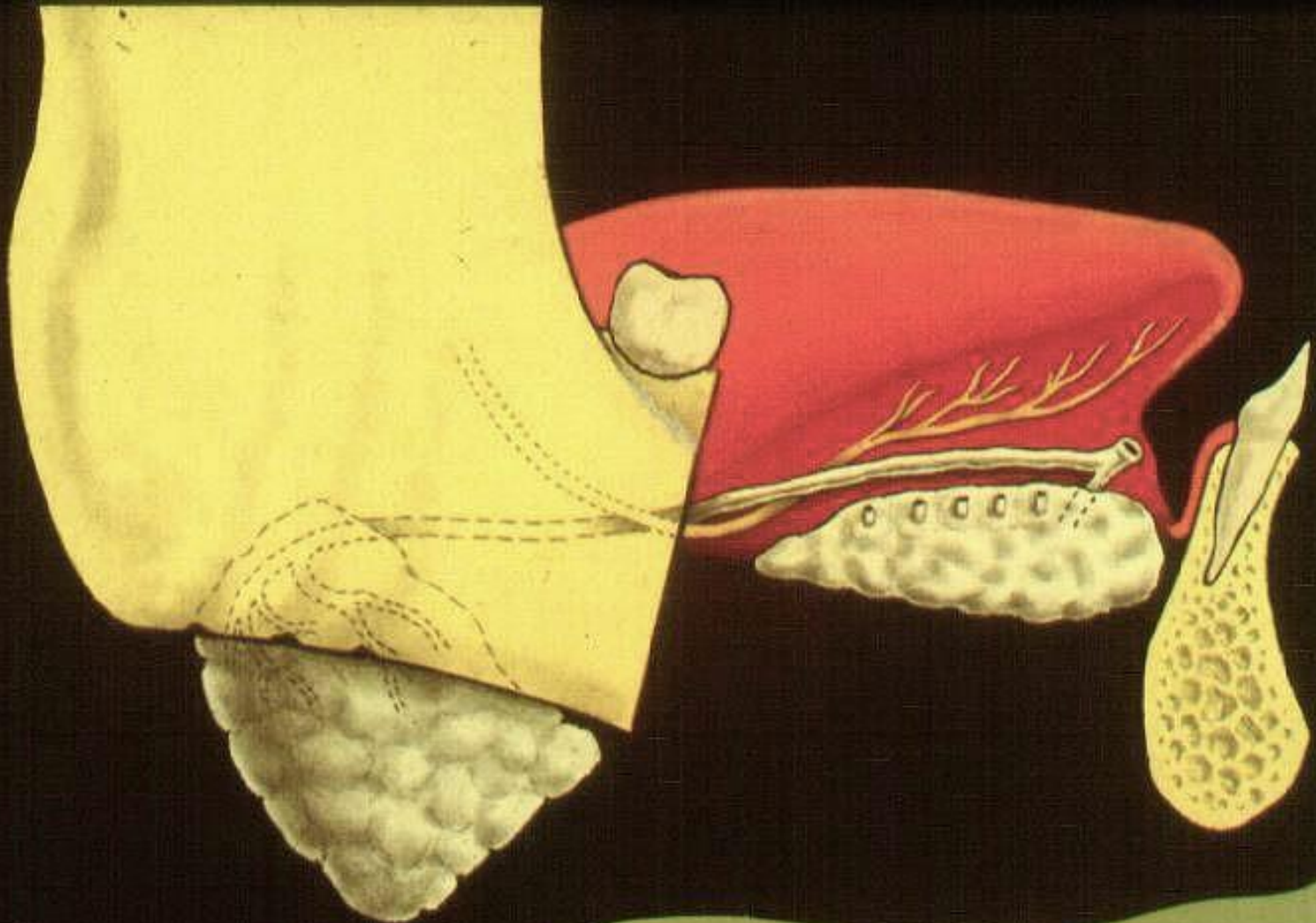




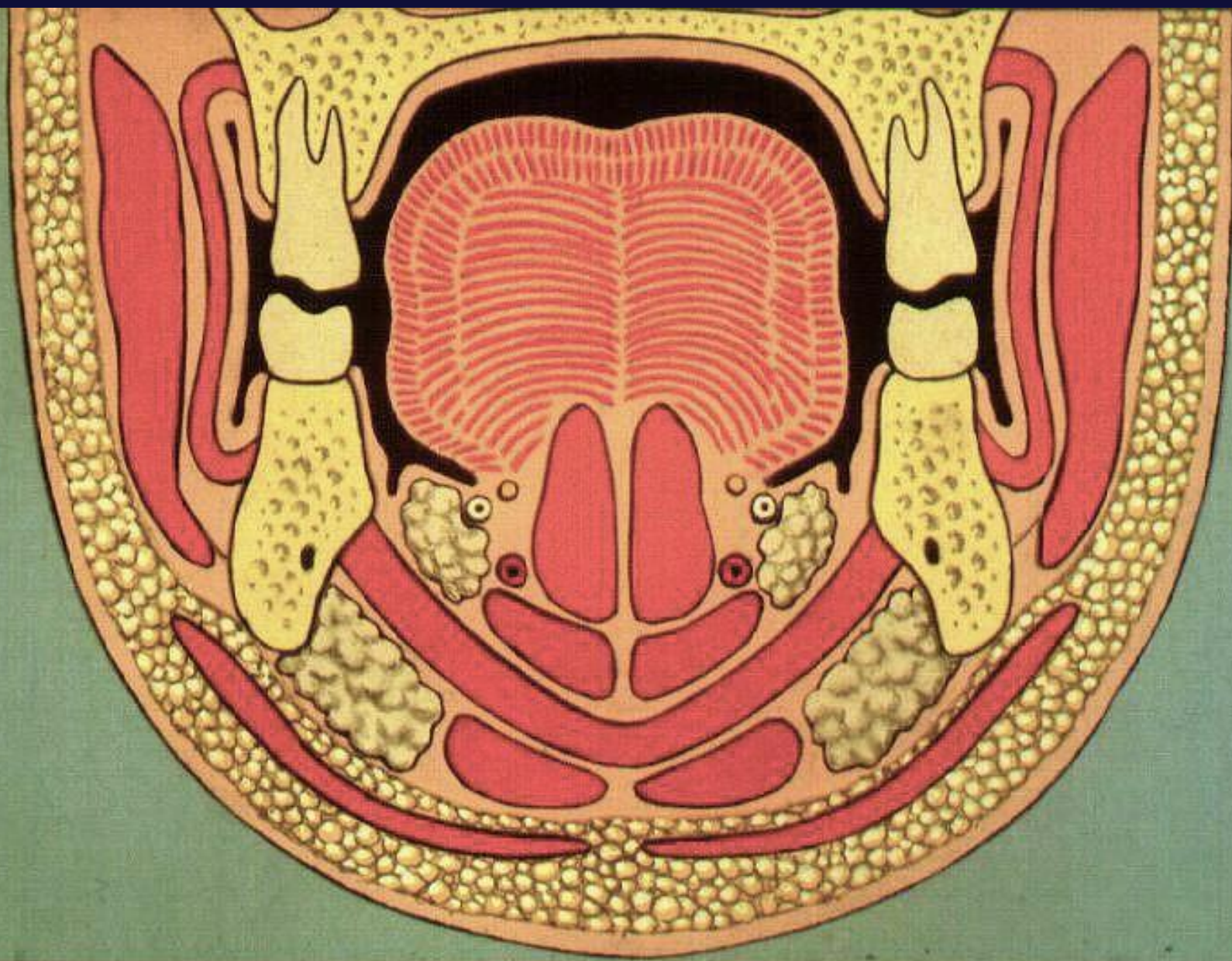




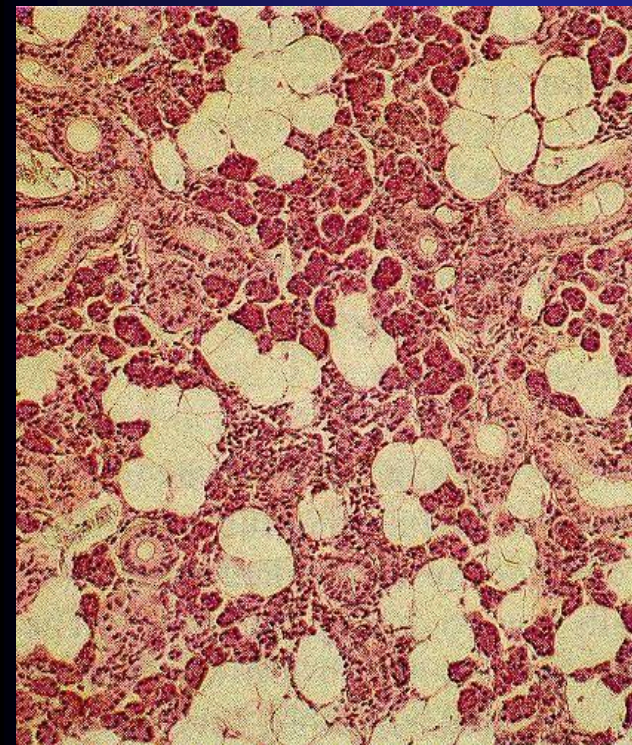




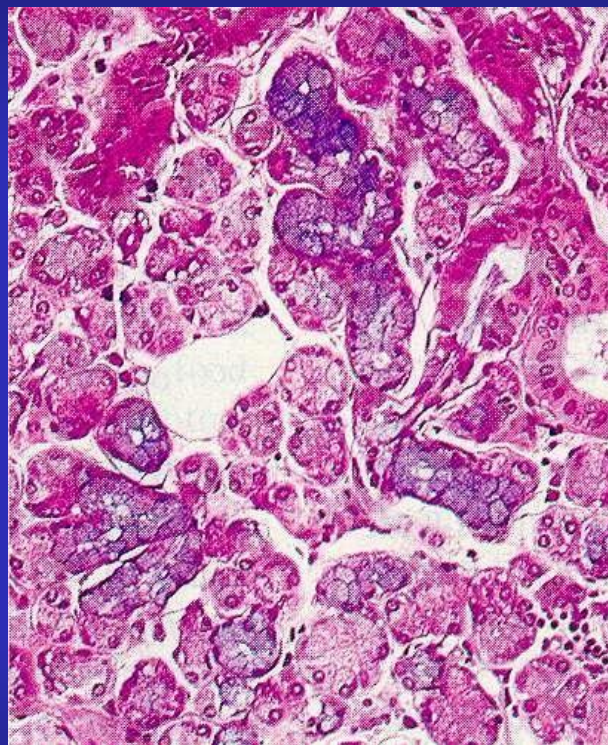




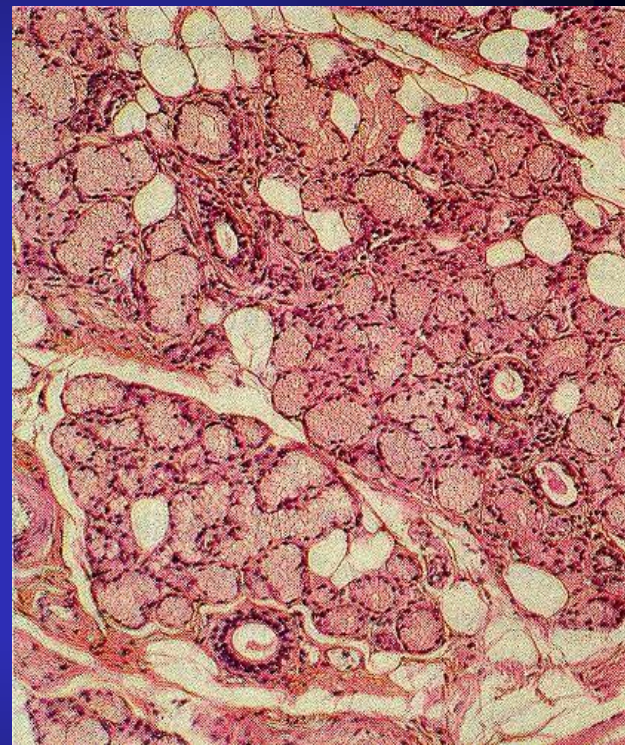




**gl. parotis**  
serosus



**gl. submandibularis**  
kevert



**gl. sublingualis**  
mucinosus

# Nyálmirigyek betegségei

**Fejlődési rendellenességek**

**Gyulladások**

**Speciális gyulladások  
(Sjögren syndroma)**

**Nyálkövesség**

**Daganatok**

**Sialosis**



# **Diagnosztikus módszerek**

**Klinikai vizsgálat**

**Röntgen, Sialográfia**

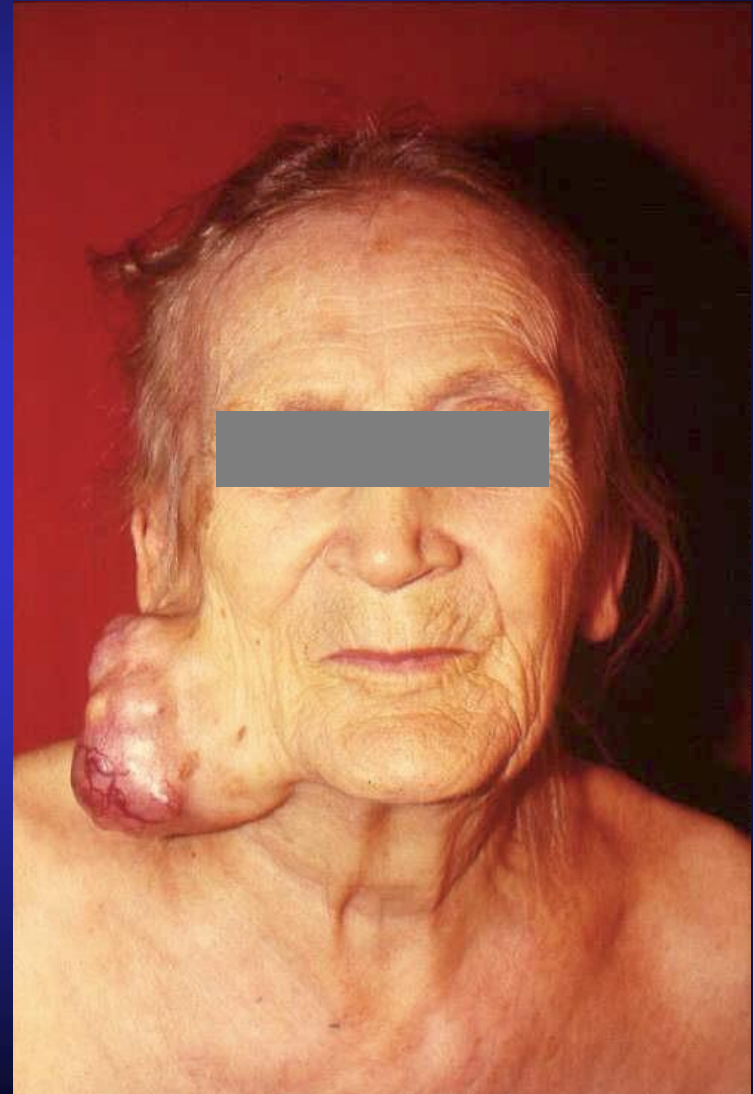
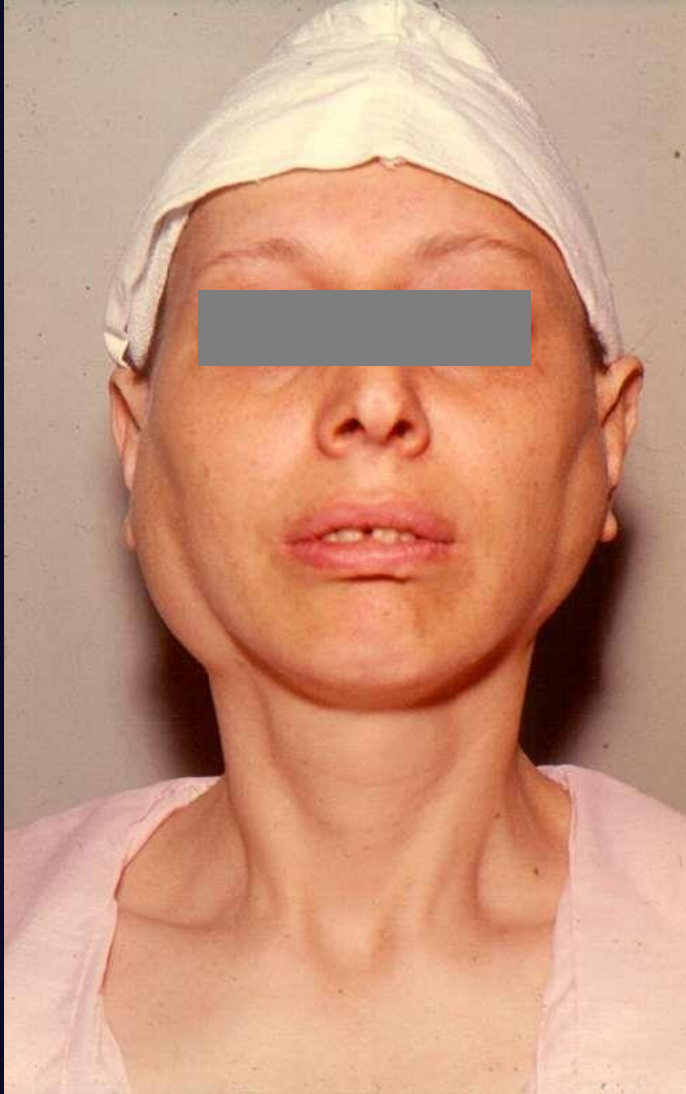
**Ultrahang**

**CT, MRI**

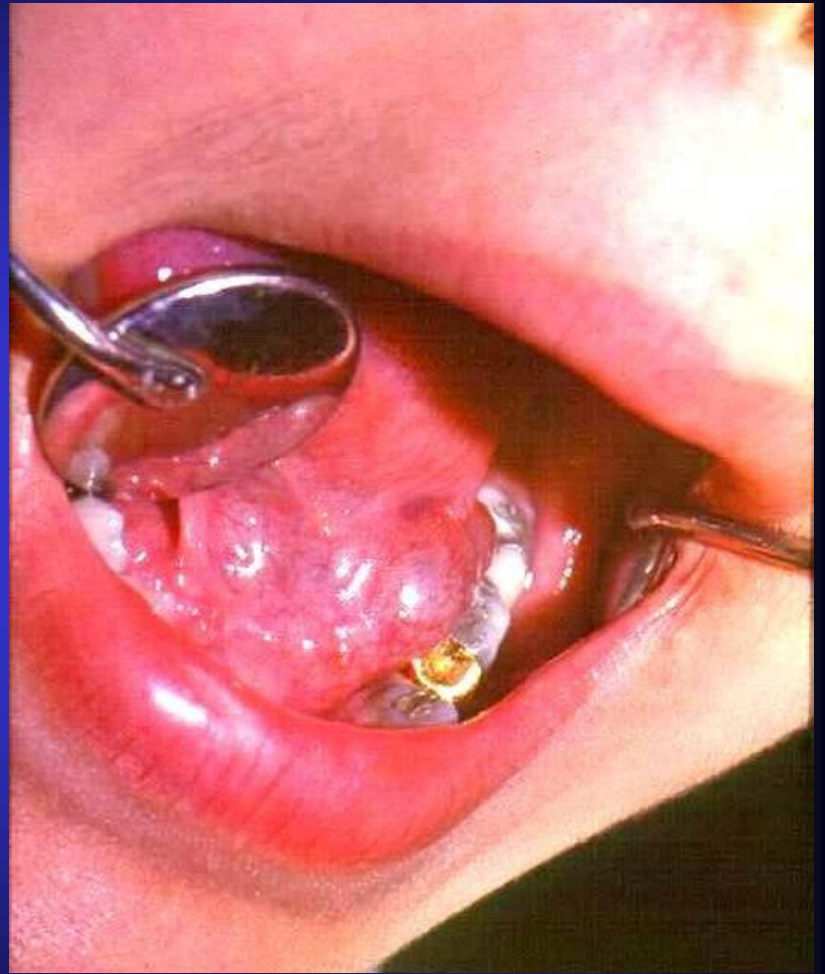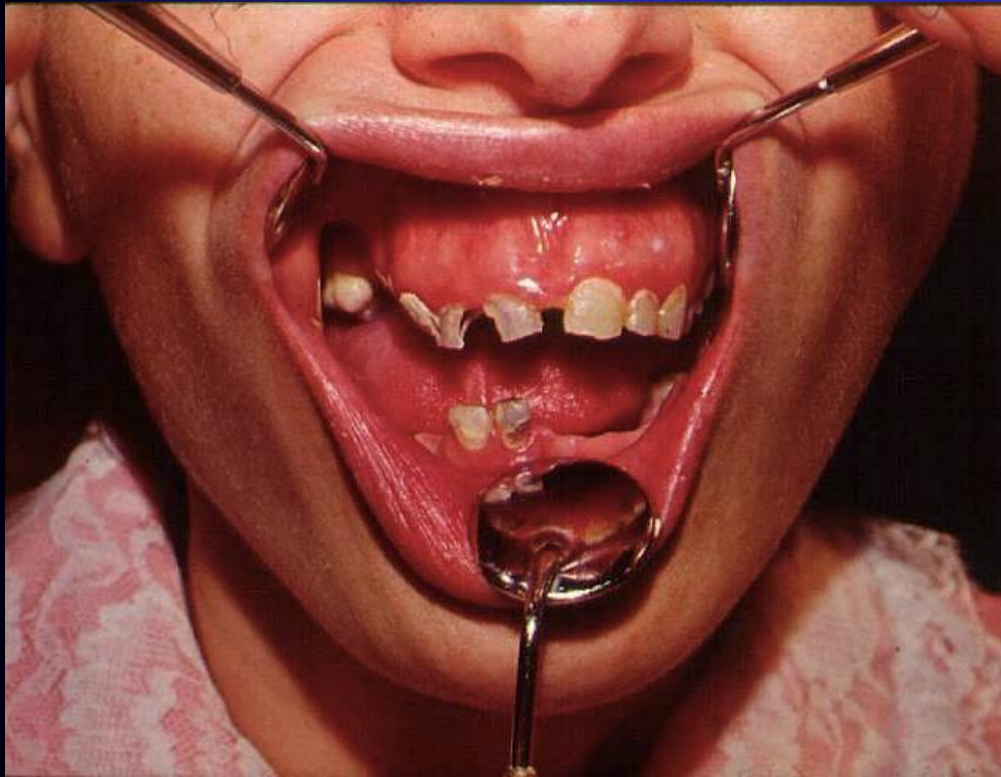**Izotóp vizsgálat**

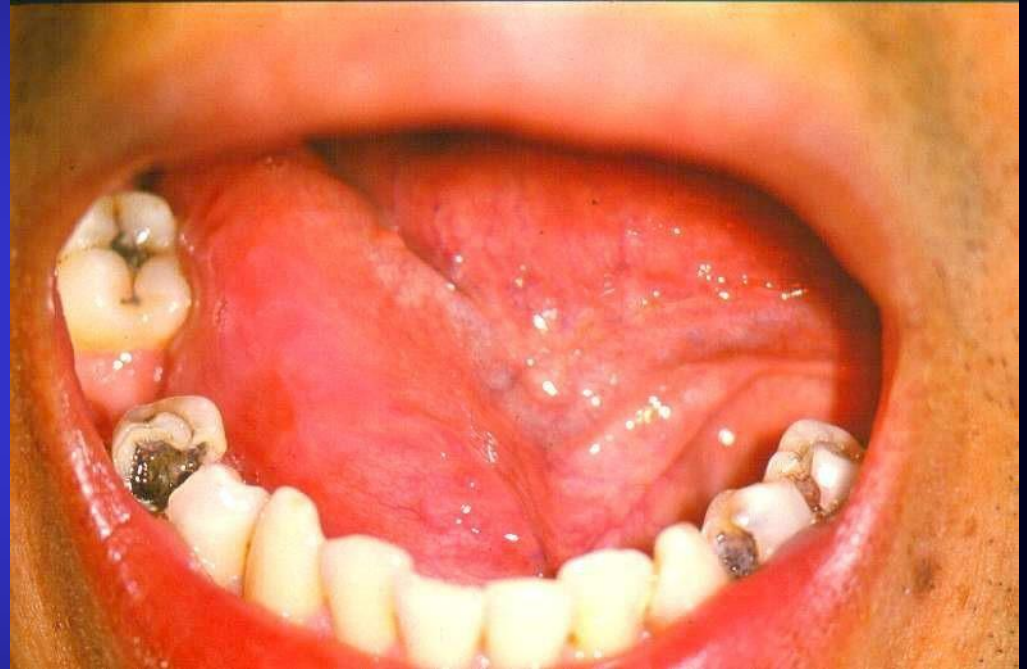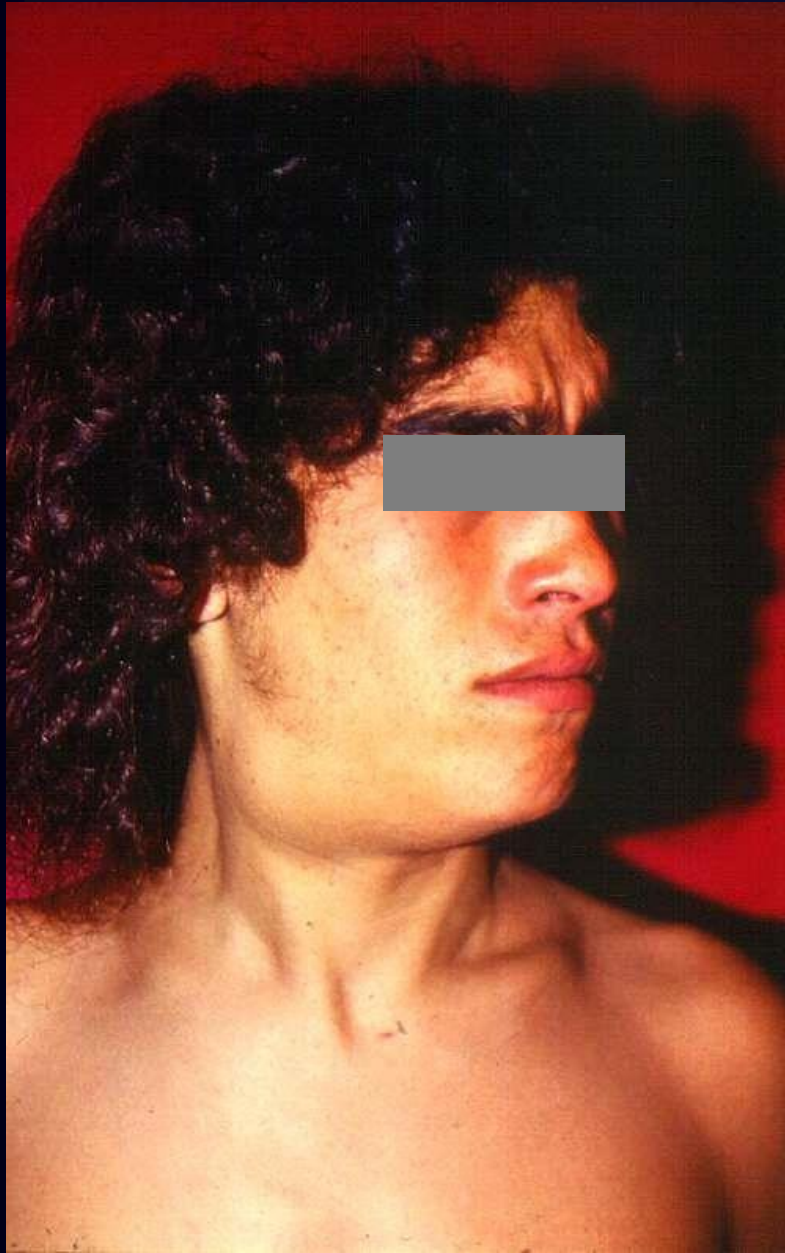**Biopszia, FNB**

# Klinikai vizsgálat





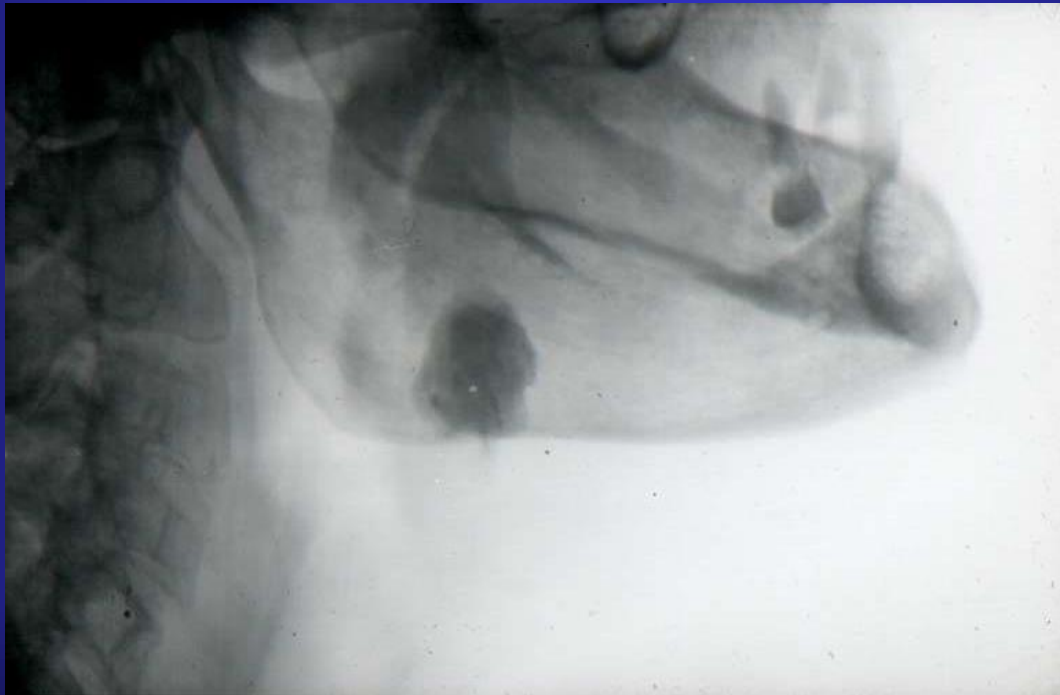


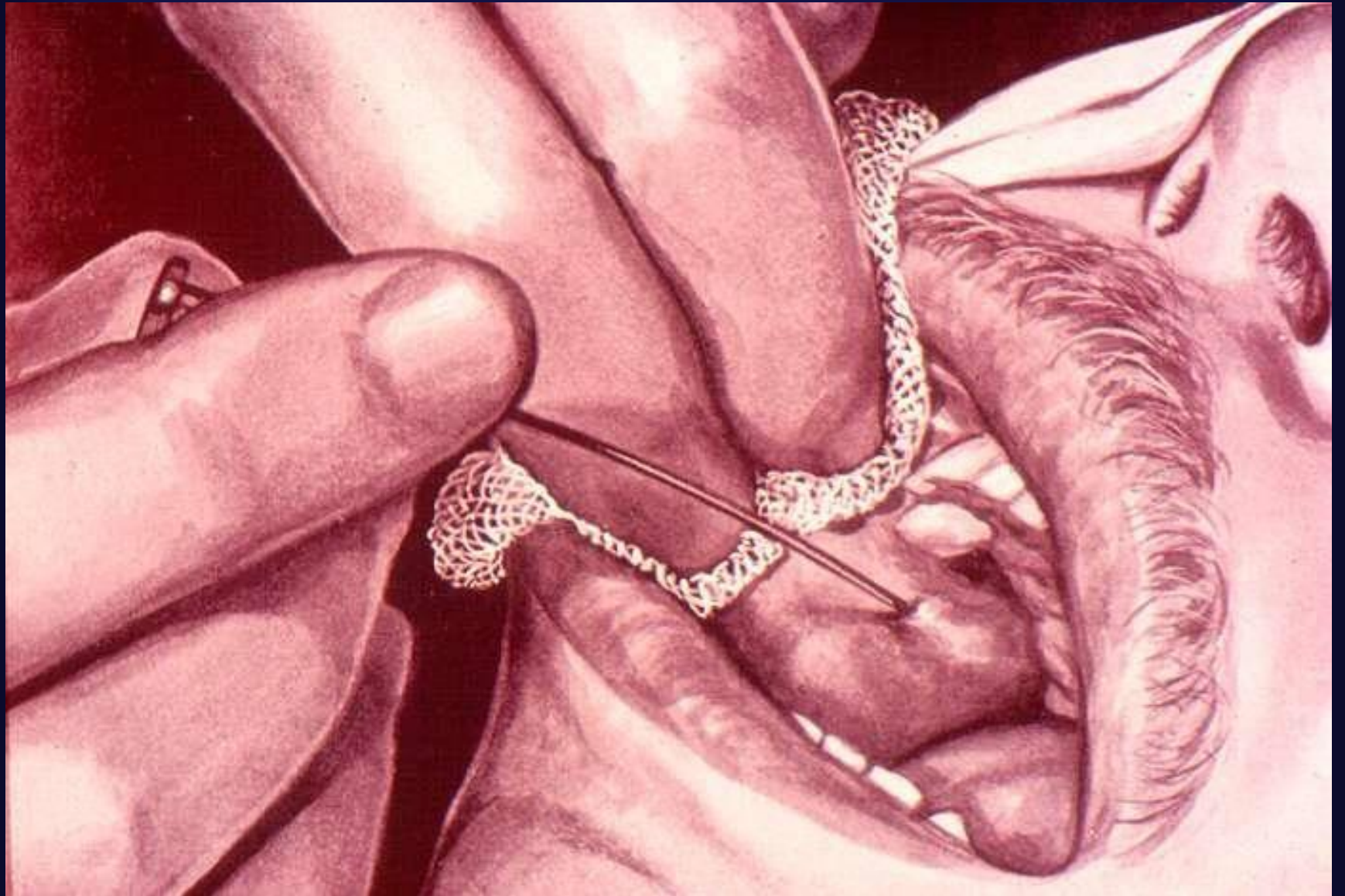


# Röntgen-diagnosztika

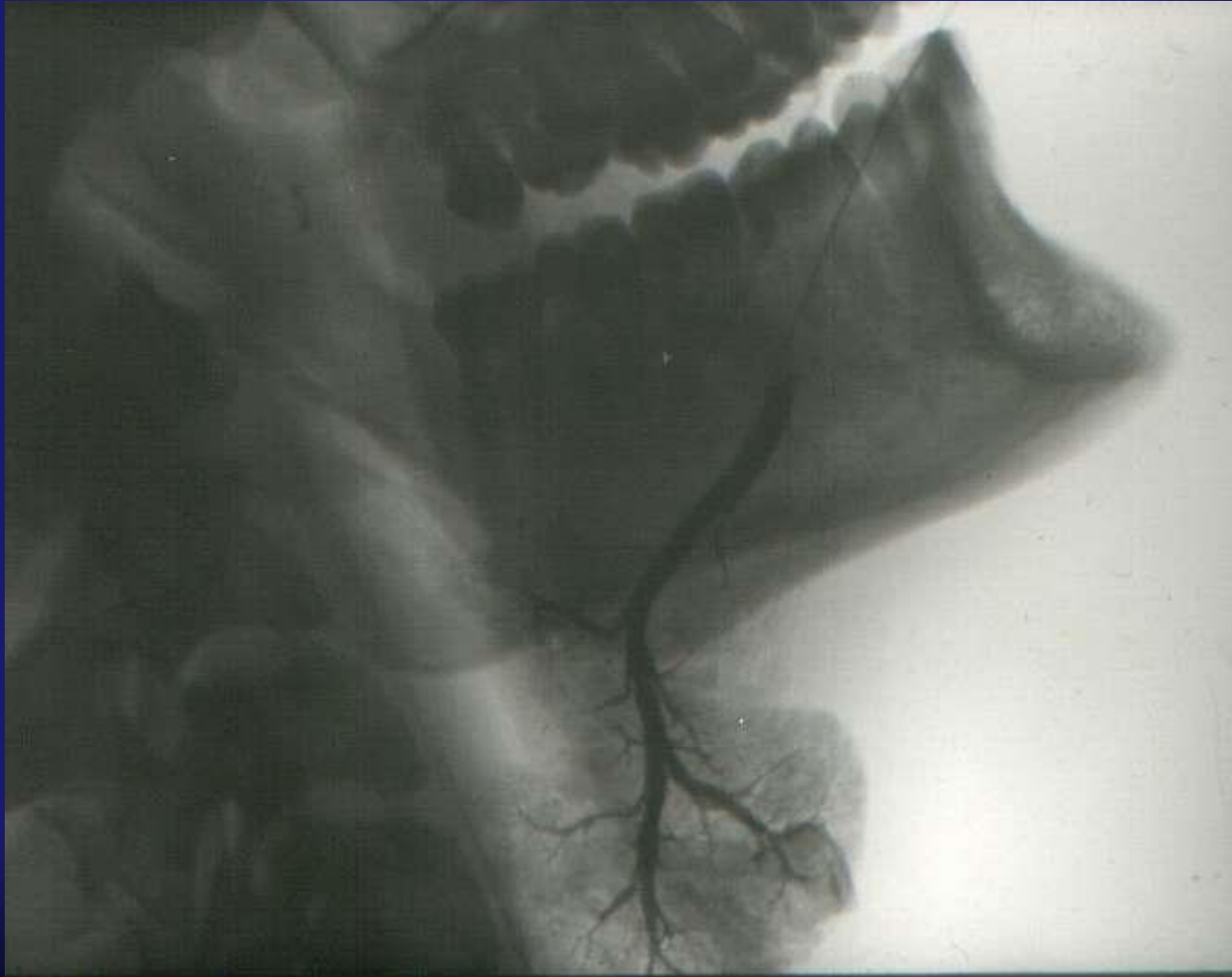
## Sialográfia

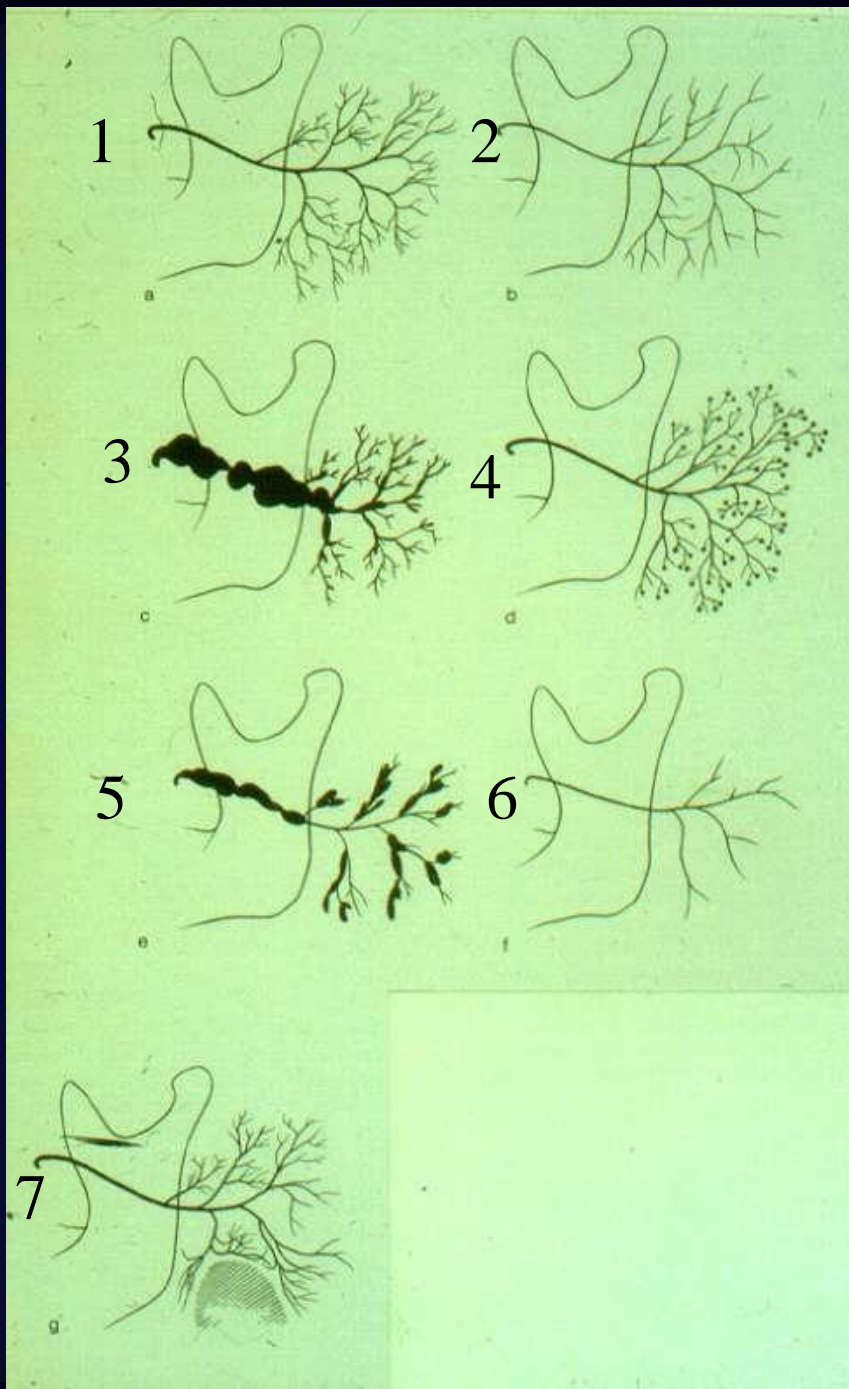






# Normal submandibularis mirigy sialográfiás képe





- 1. Normal parotis**
- 2. Akut gyulladás**
- 3. Nyálkő**
- 4. Krónikus sialadenitis**
- 5. Sjögren syndroma**
- 6. Sialosis**
- 7. Tumor**



# Izotóp vizsgálat (scintigraphy)

$^{131}\text{I}$

$^{99\text{m}}\text{Tc}$

Felezési idő

8 nap

6 óra

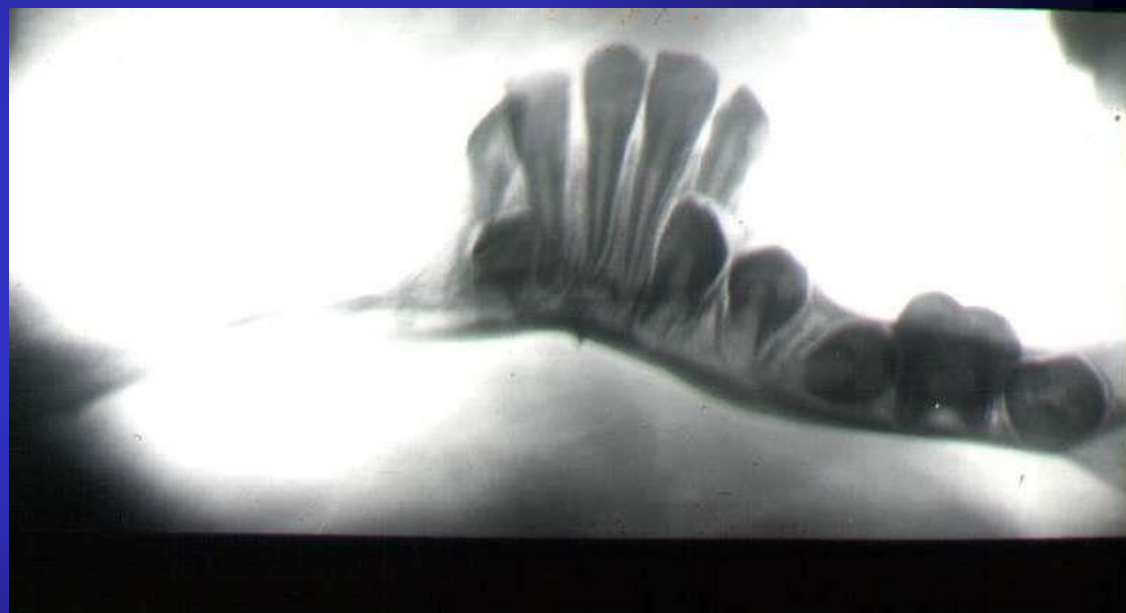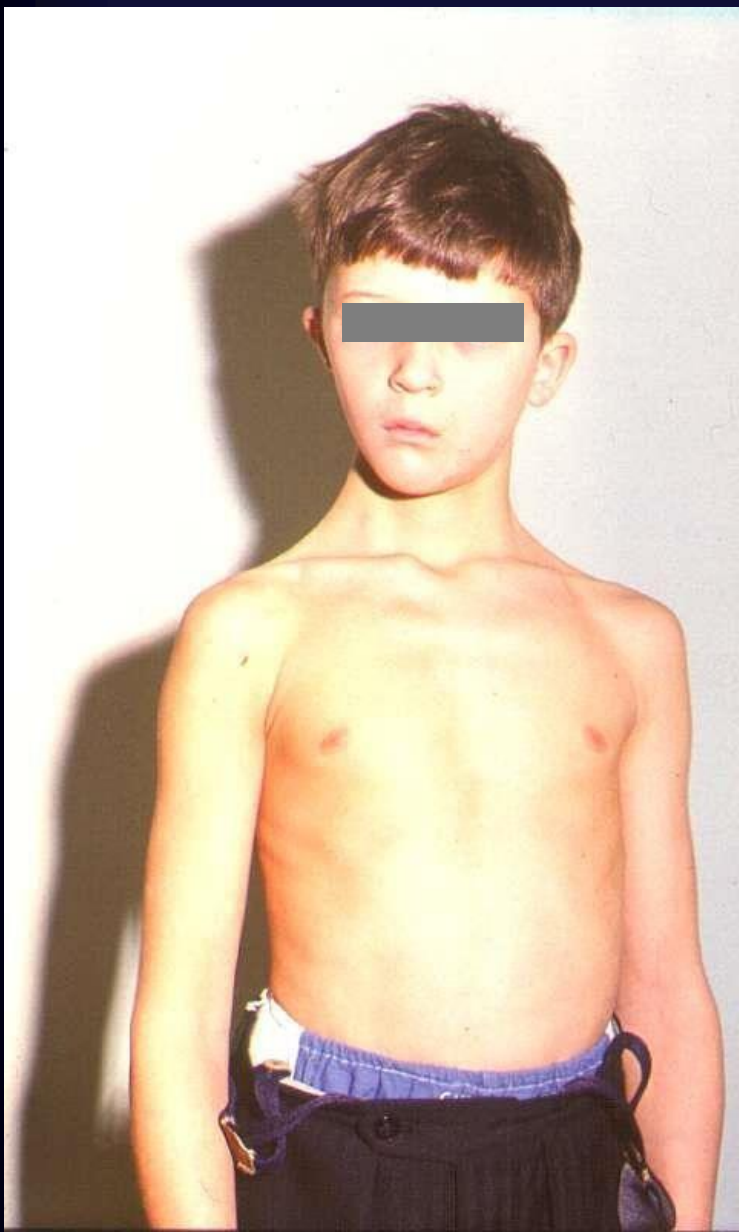# Fejlődési rendellenességek

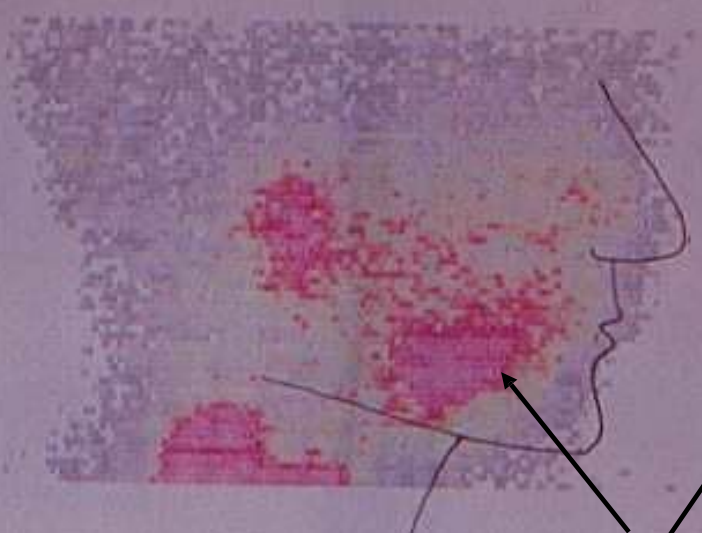

## Aplasia-hyperplasia

### Kivezetőcső rendellenességei

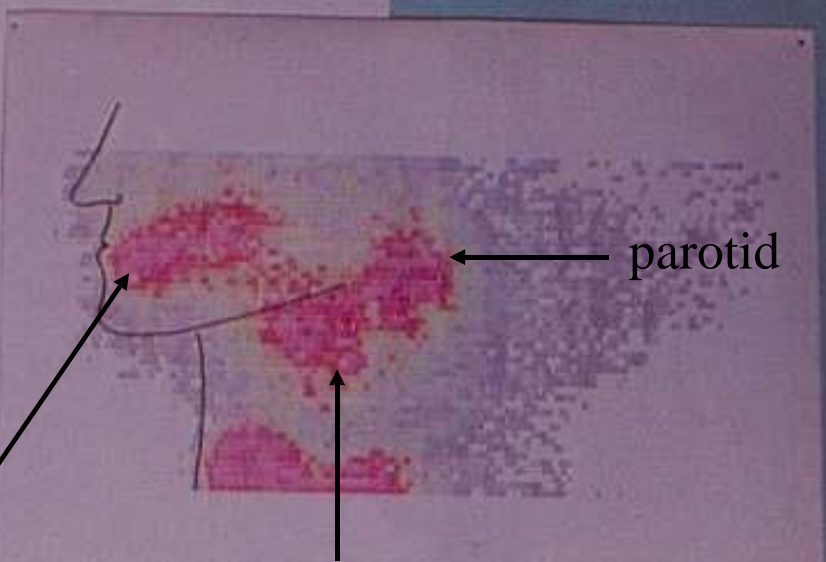


# A jobb gl. submandibularis aplasiája





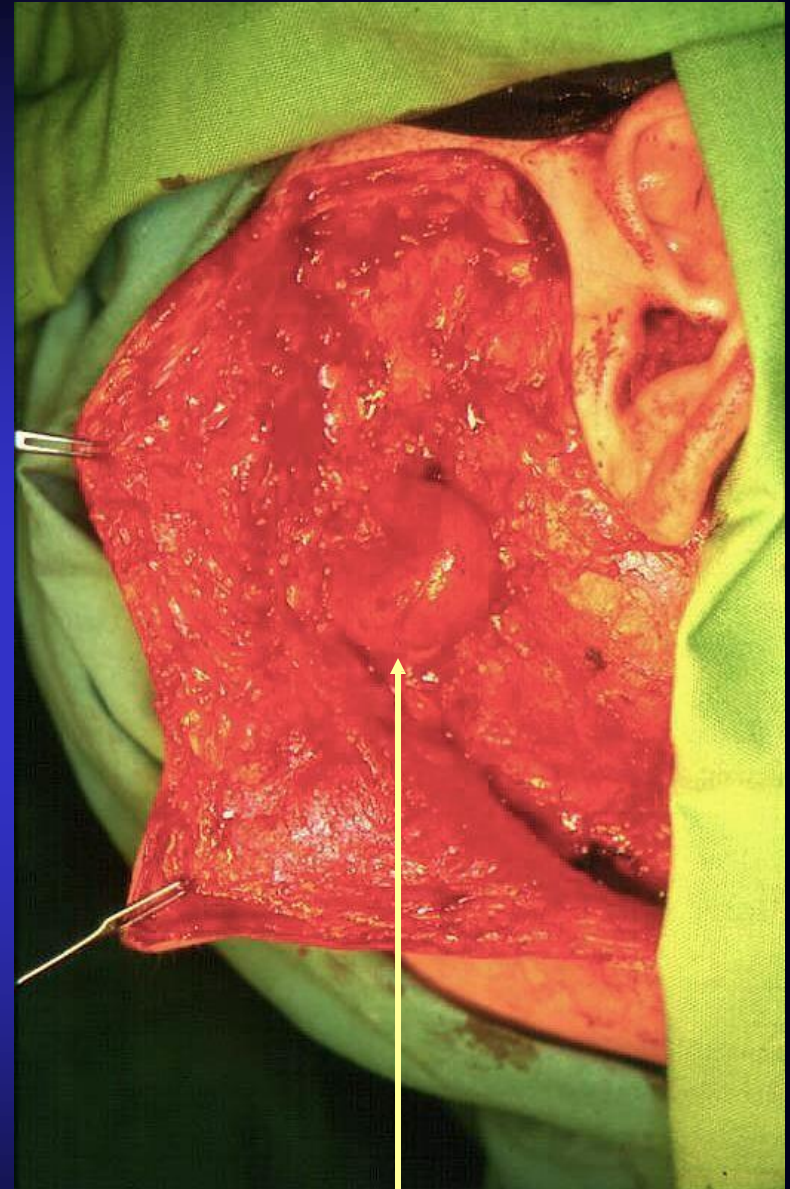
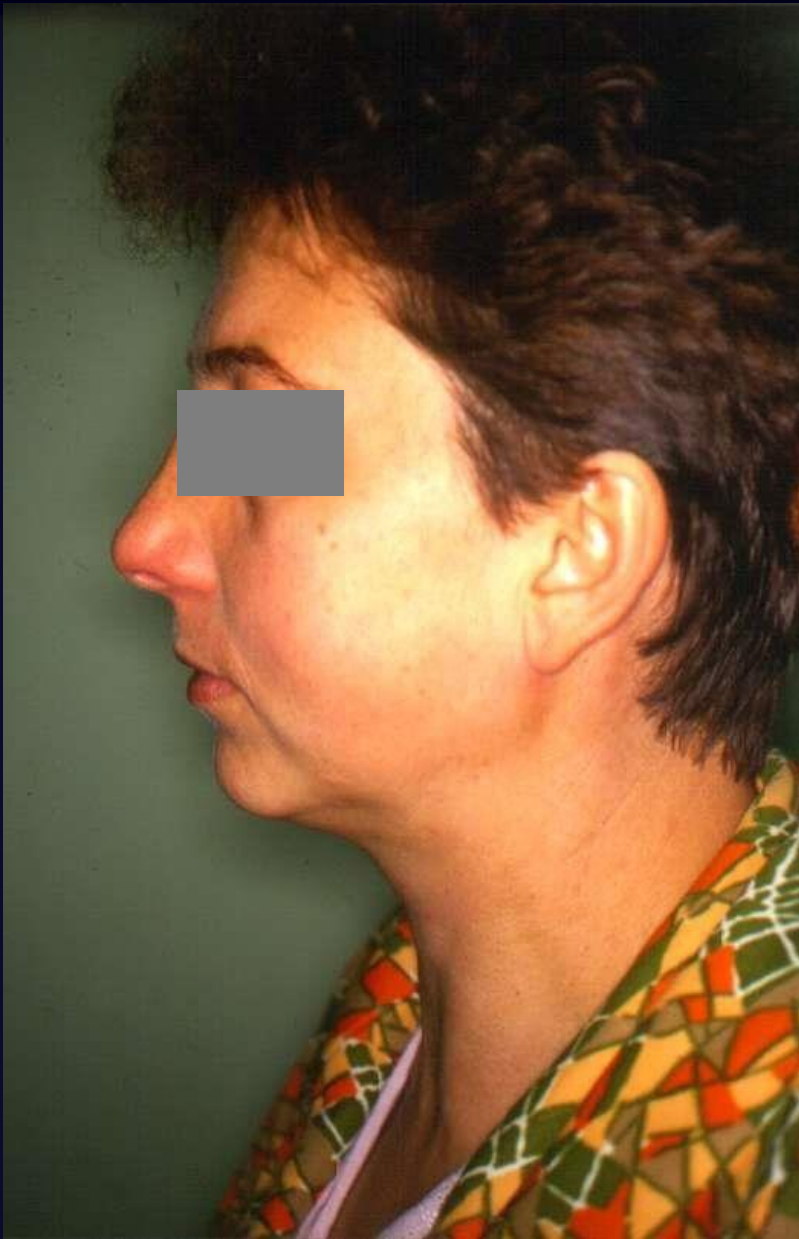minor salivary glands in the oral cavity



parotid

submandibular





**Kivezetőcső rendellenességei: „mega-Stenon” a parotisban**

# Gyulladások



## Virogen

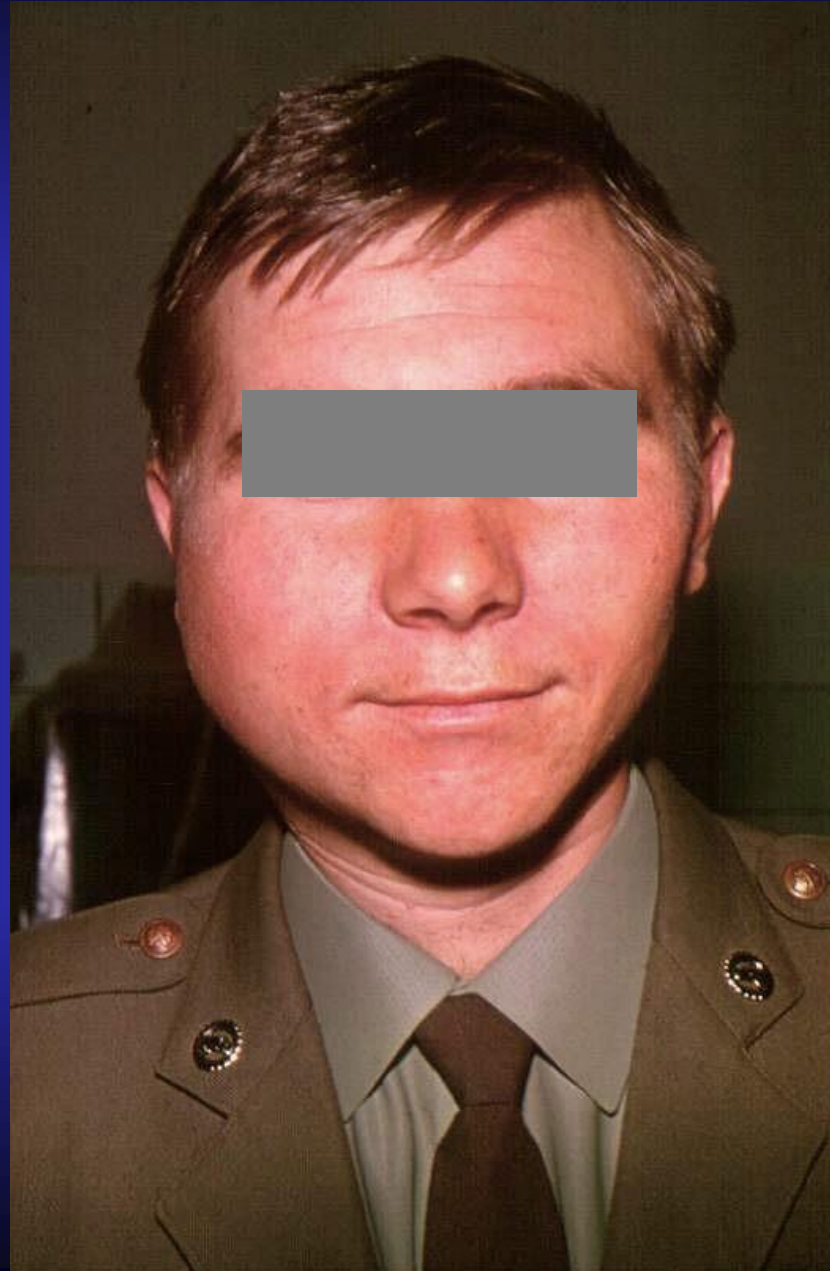Mumps  
(Parotitis epidemica)

## Bakteriogen

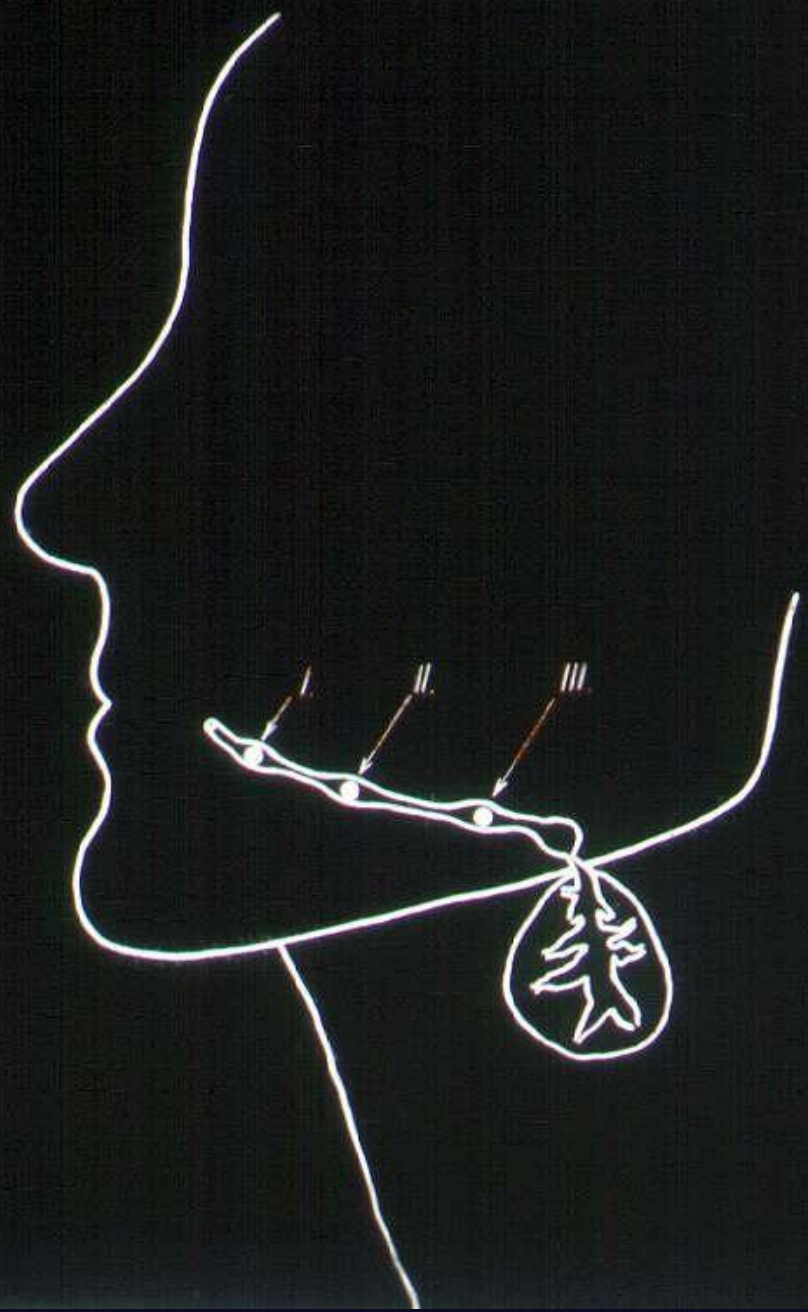
Akut  
Krónikus




# Krónikus parotitis

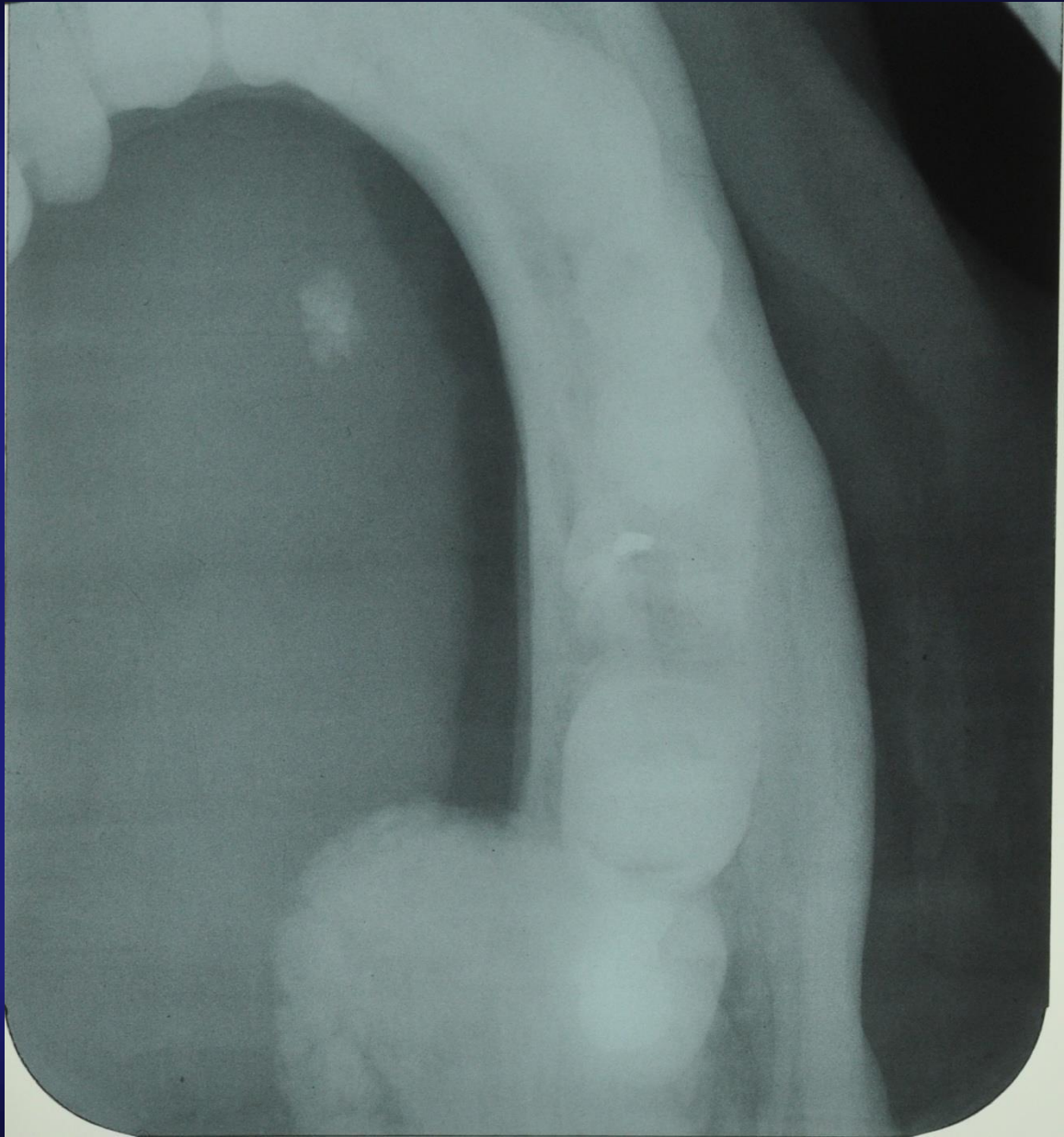


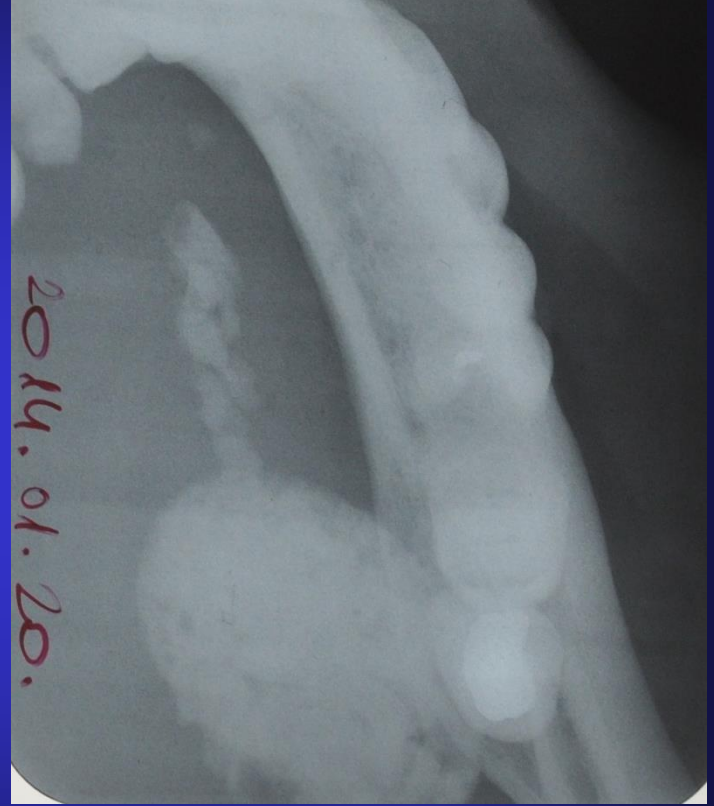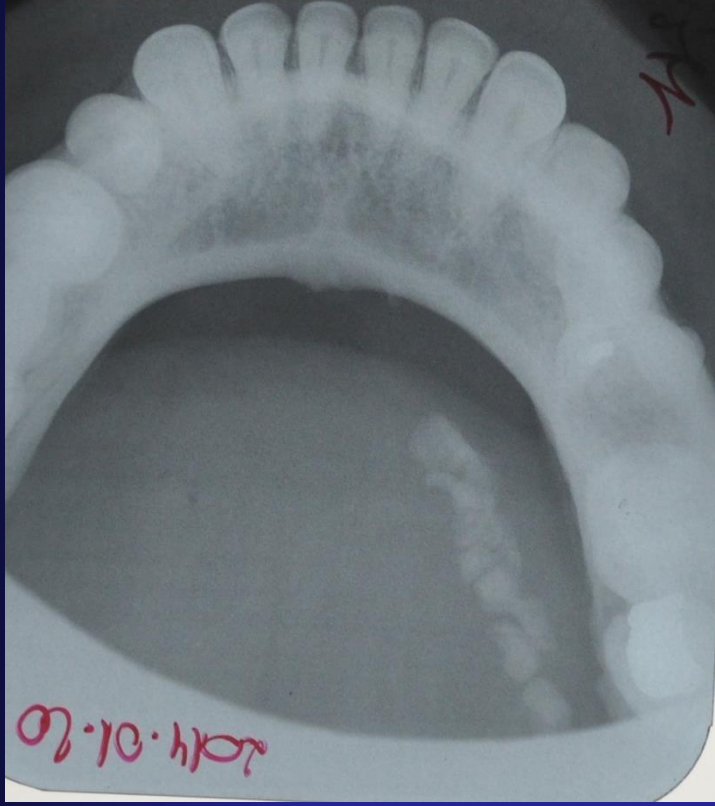**Nyálköves  
megbetegedések  
(Sialolithiasis)**



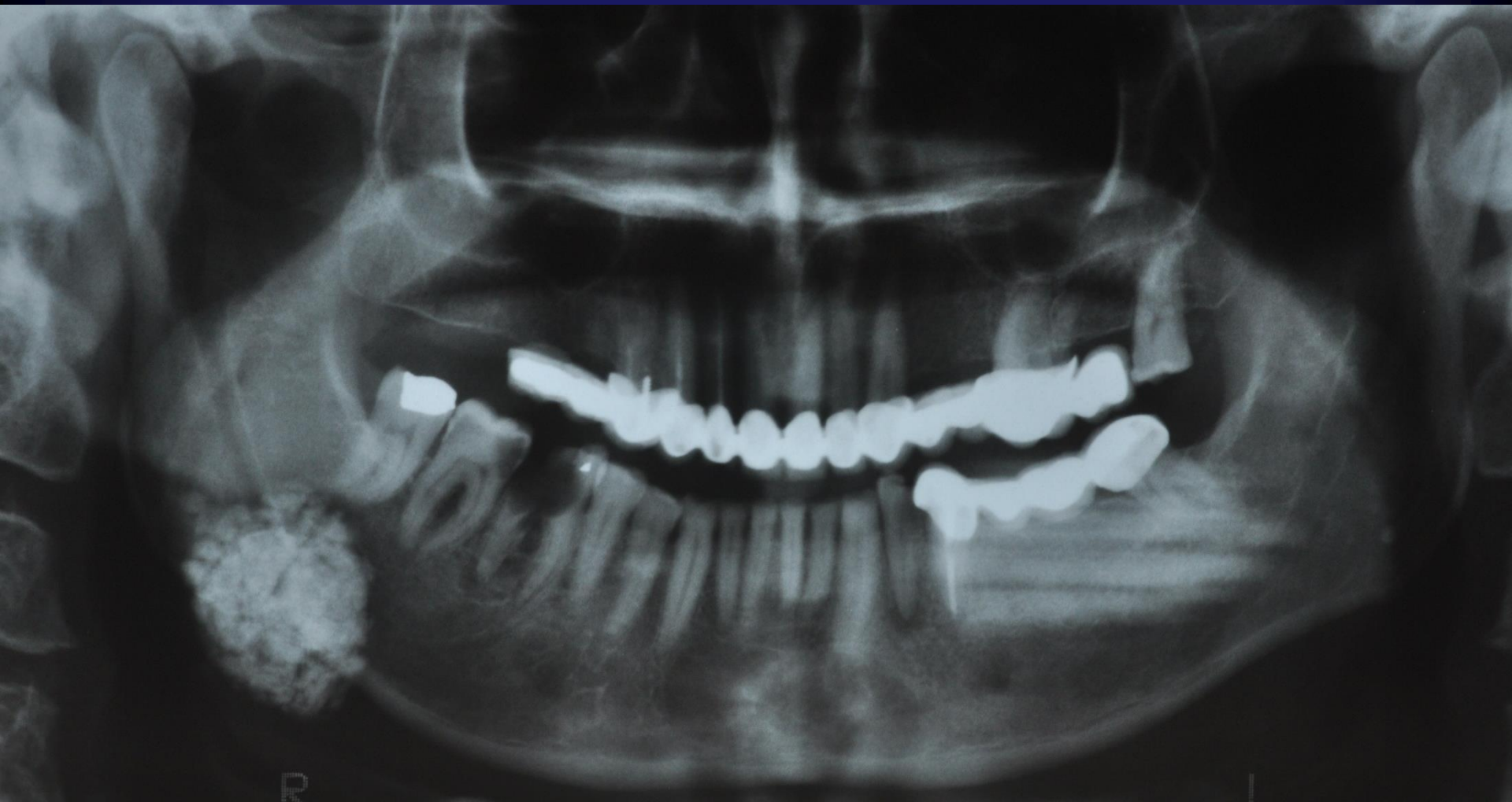


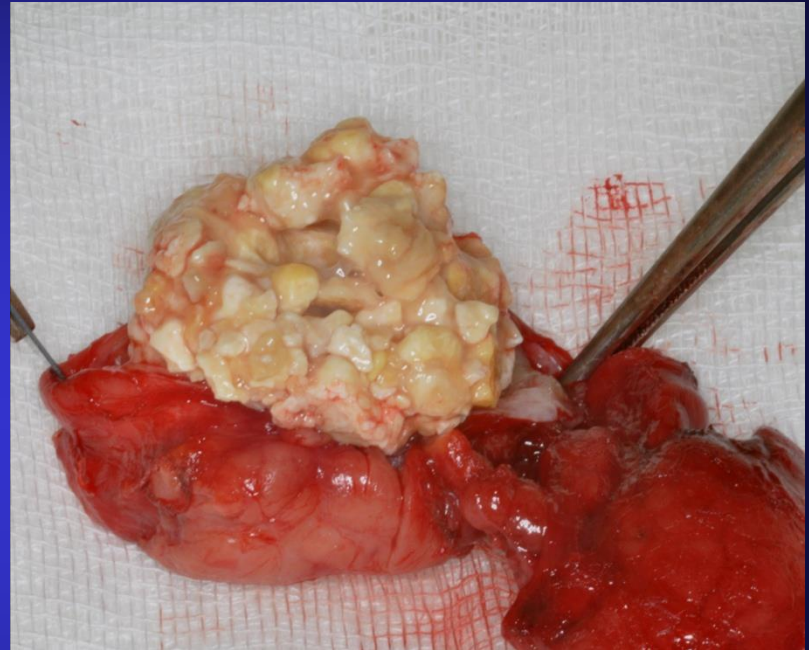
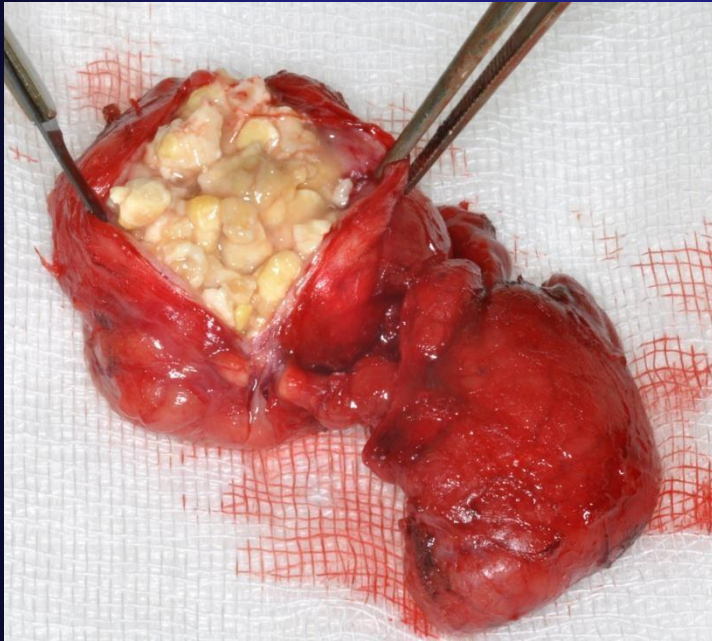










# Tumorok

**Pleomorf adenoma (vegyes tumor)**

**Warthin-tumor (cystadenolymphoma)**

**Oncocytoma**

**Cylindroma (Adenocysticus carcinoma)**

**Mucoepidermoid carcinoma**

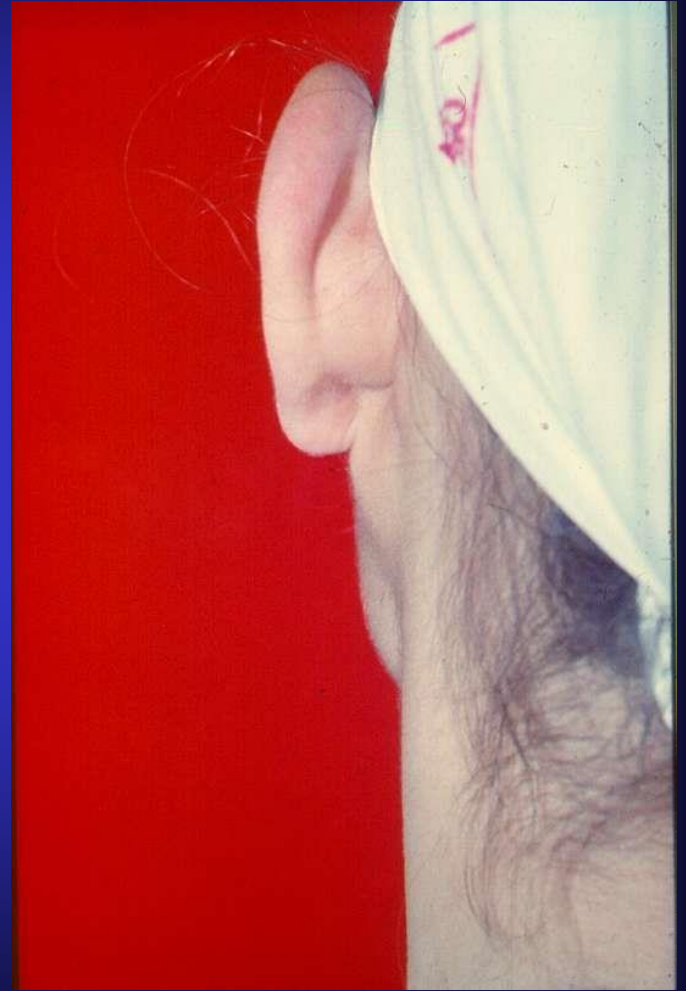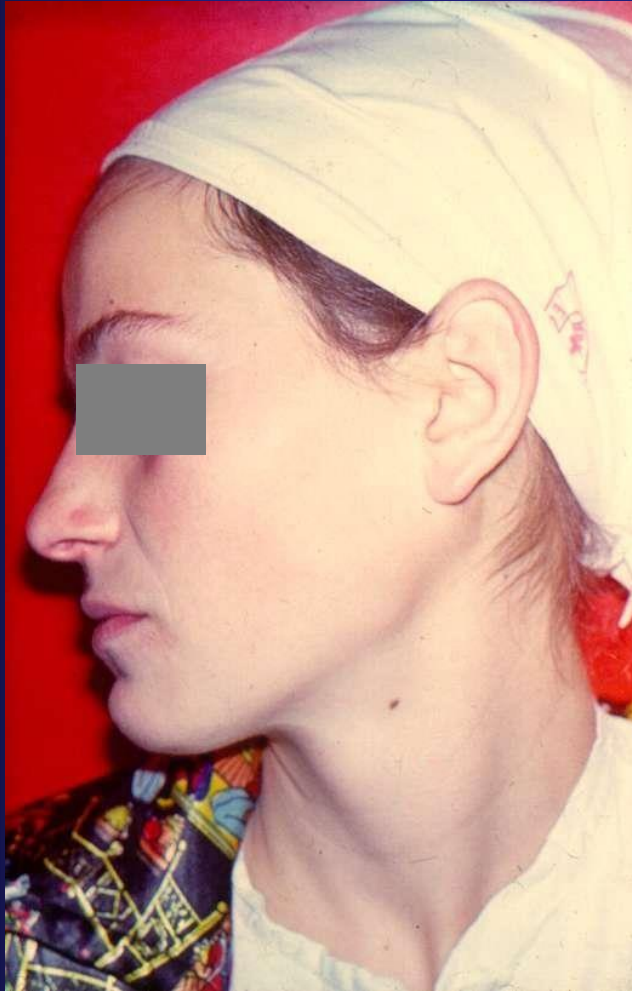**Malignus vegyes tumor**

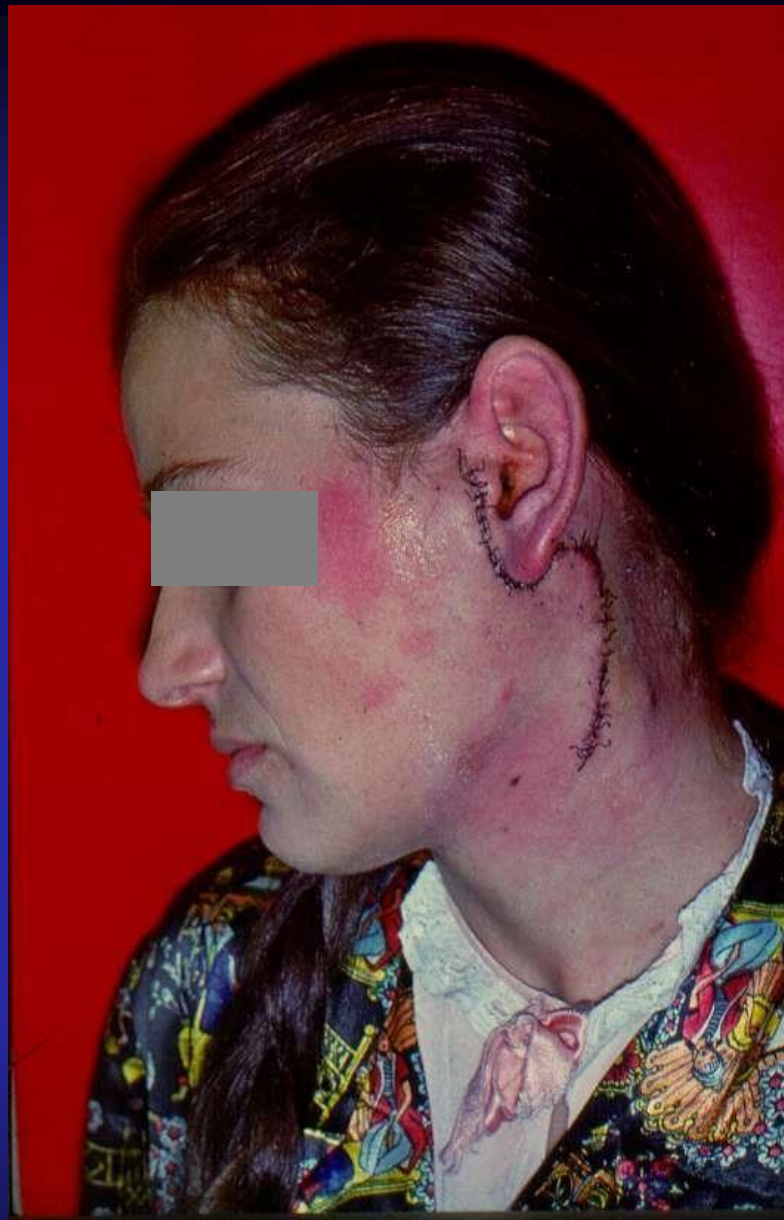**Epithelialis carcinoma**

**Adenocarcinoma**

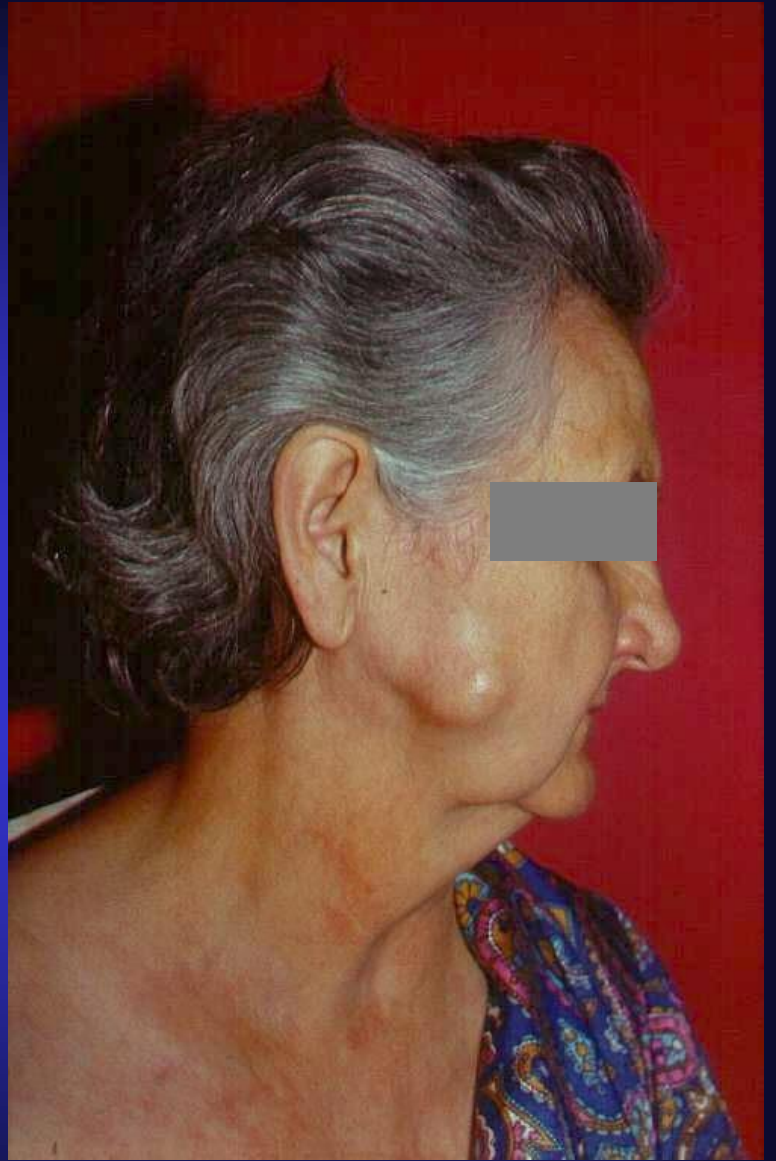
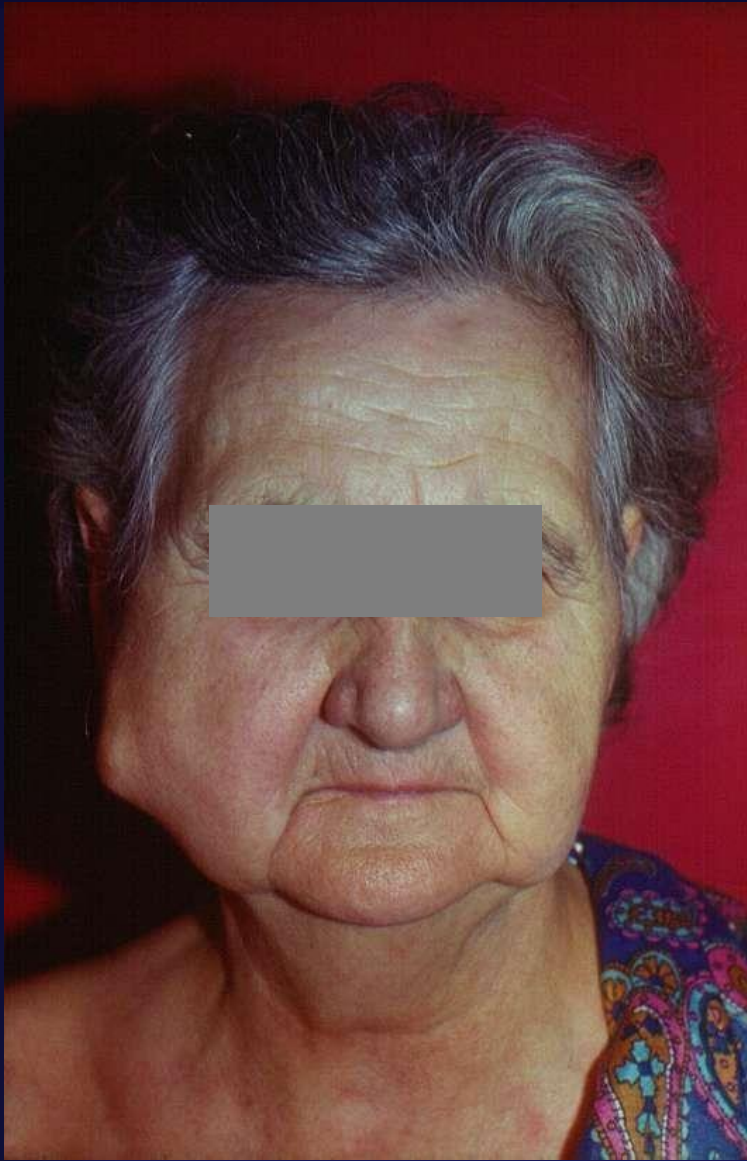
# Pleomorf adenoma

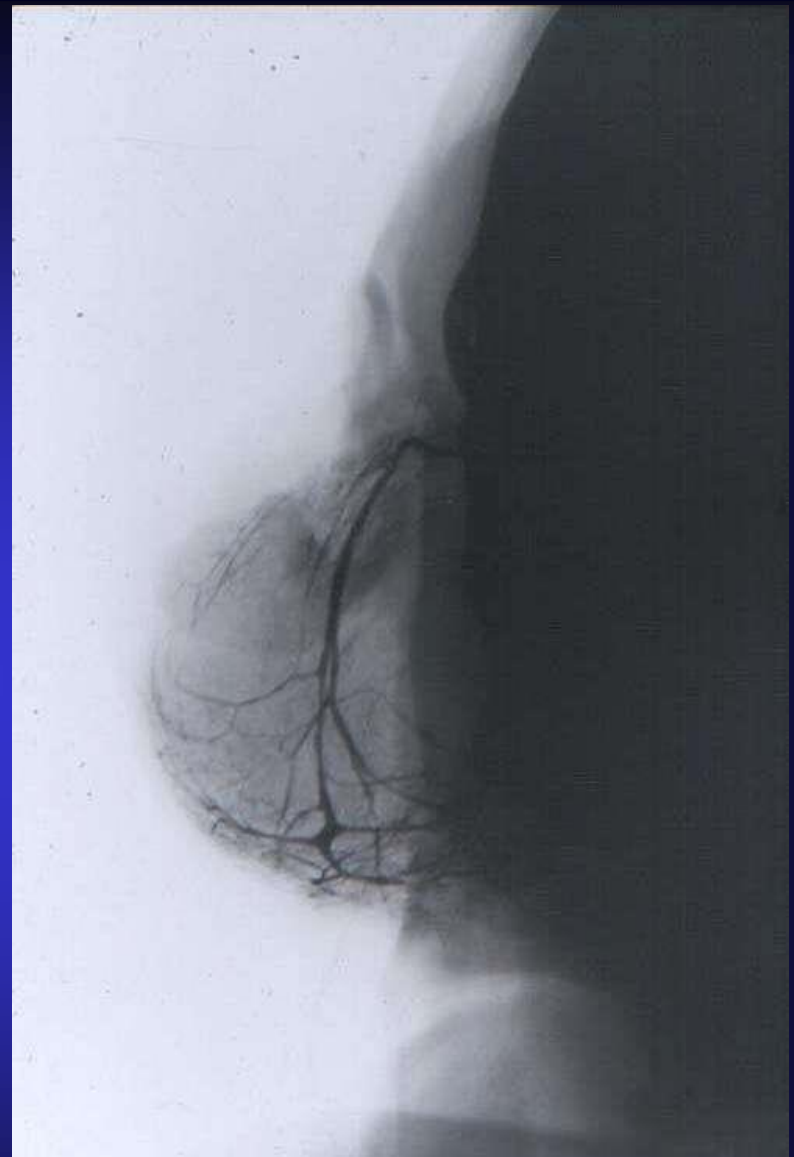
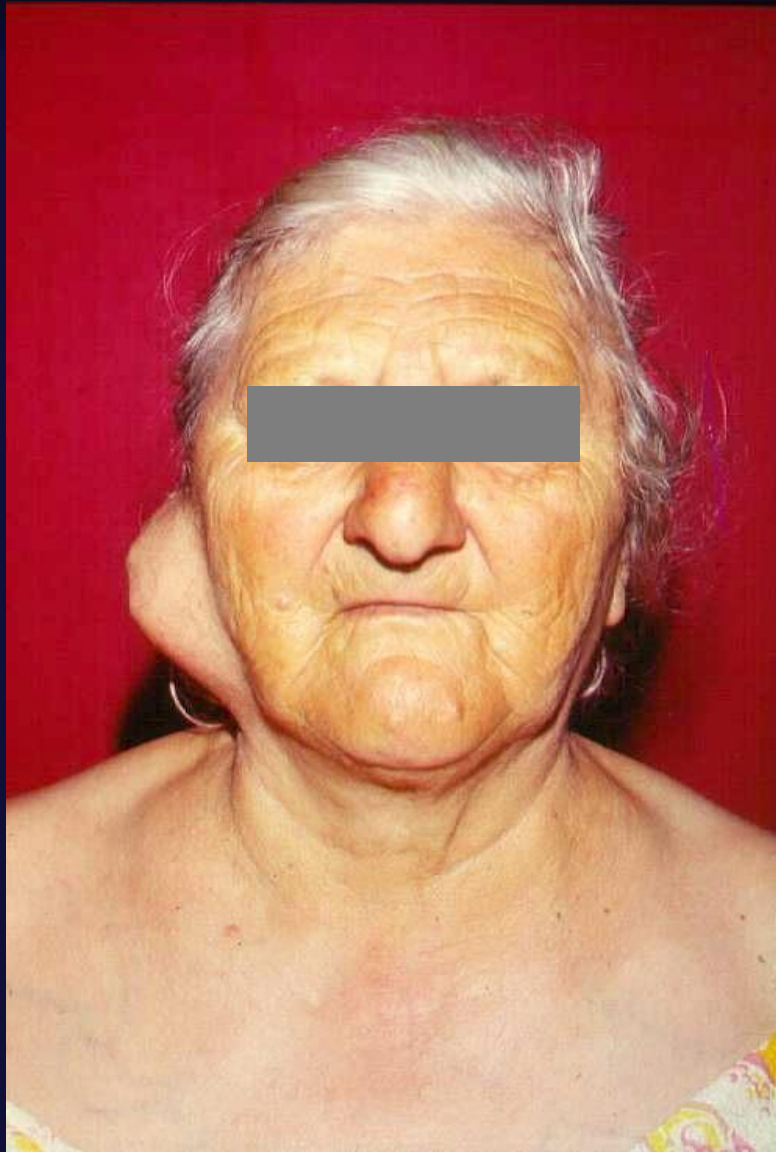



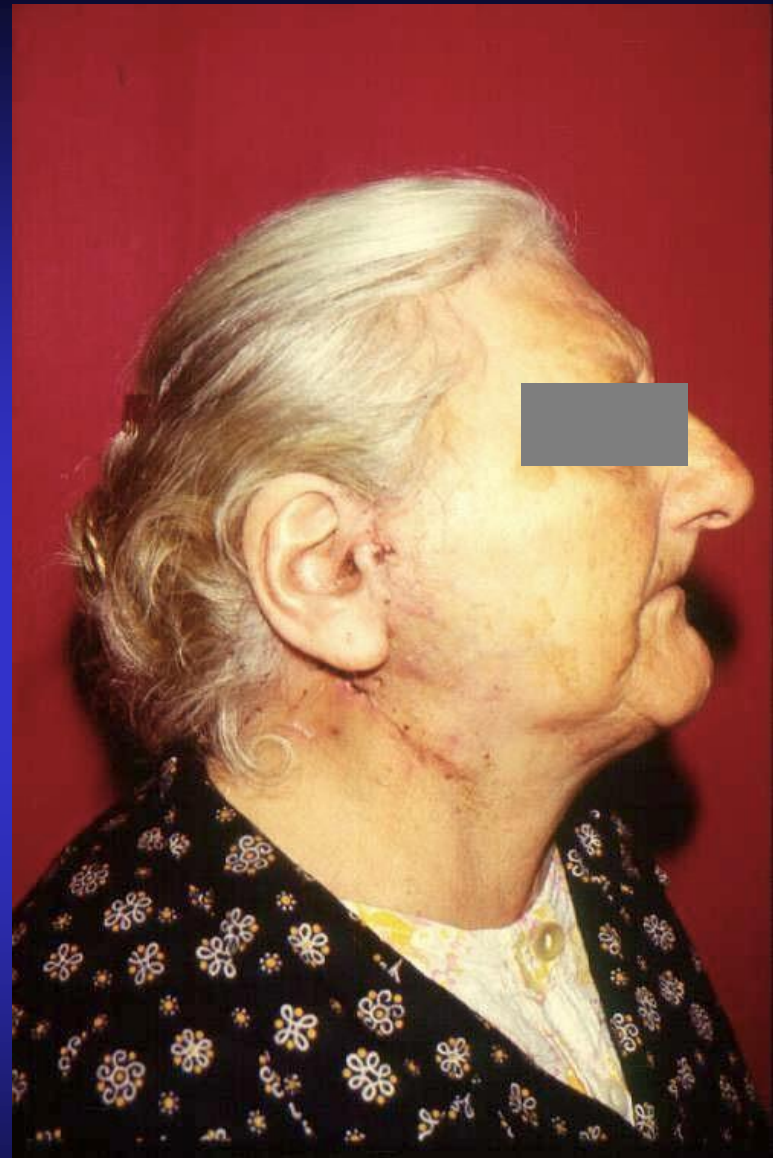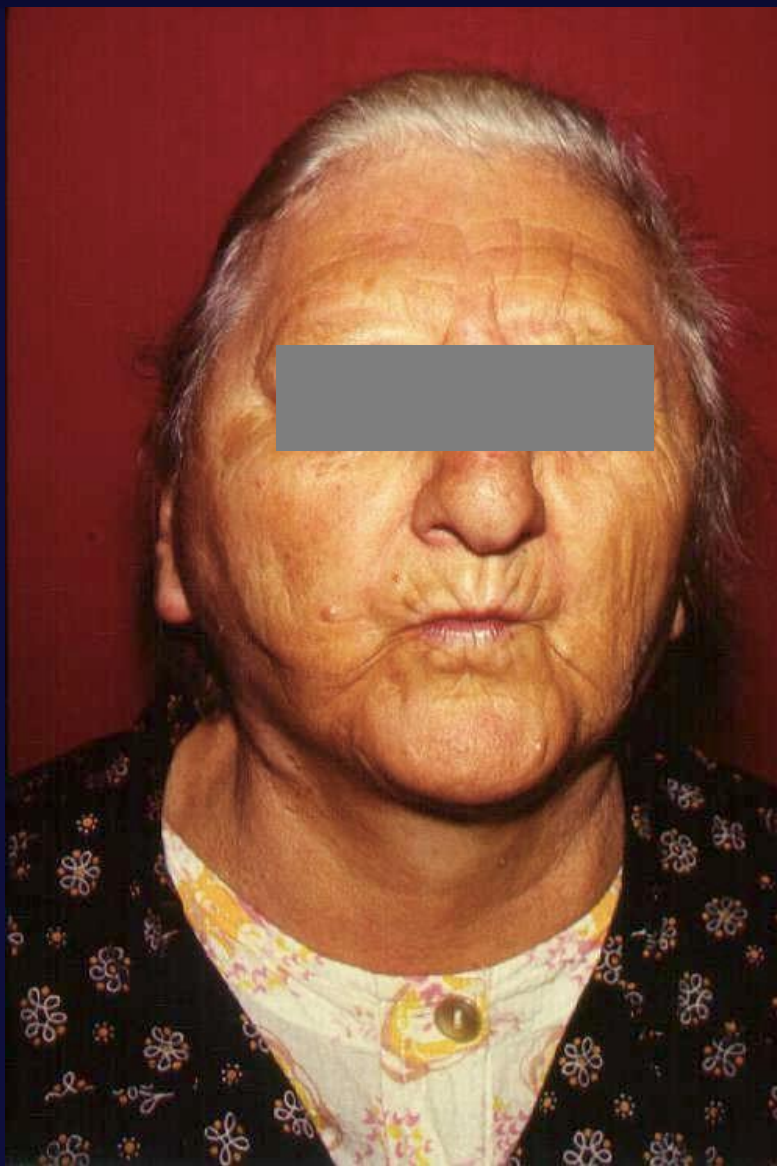**Frey syndrome ( n. auriculotemp.)**



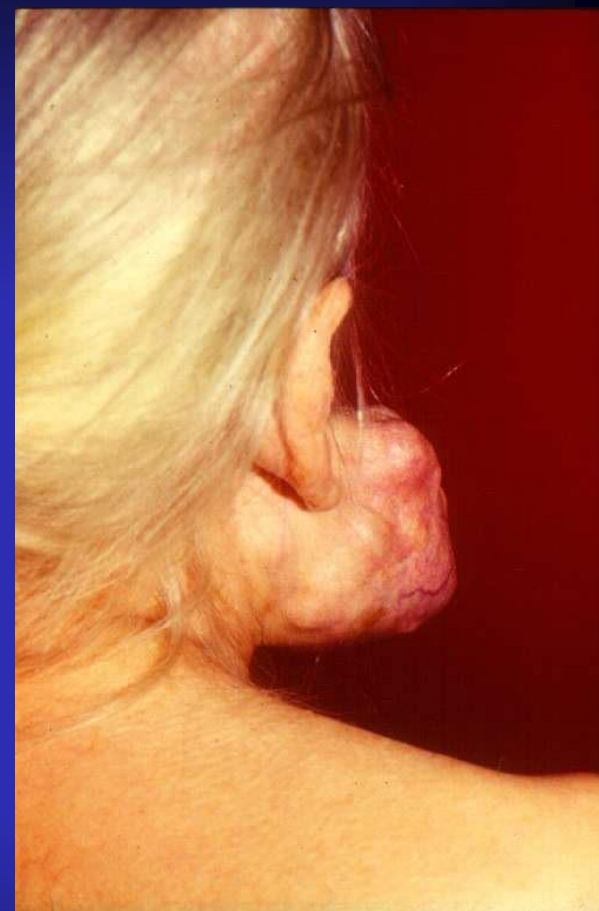
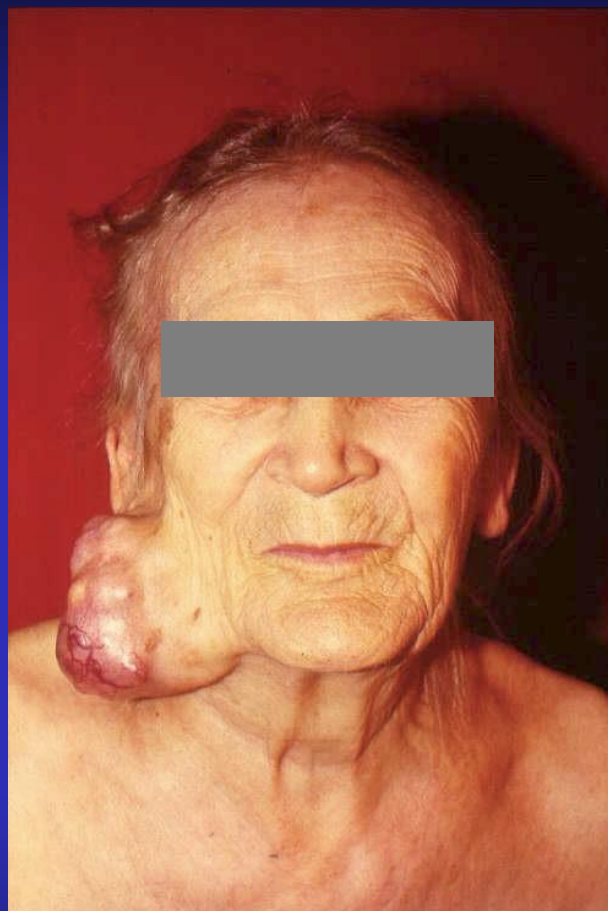
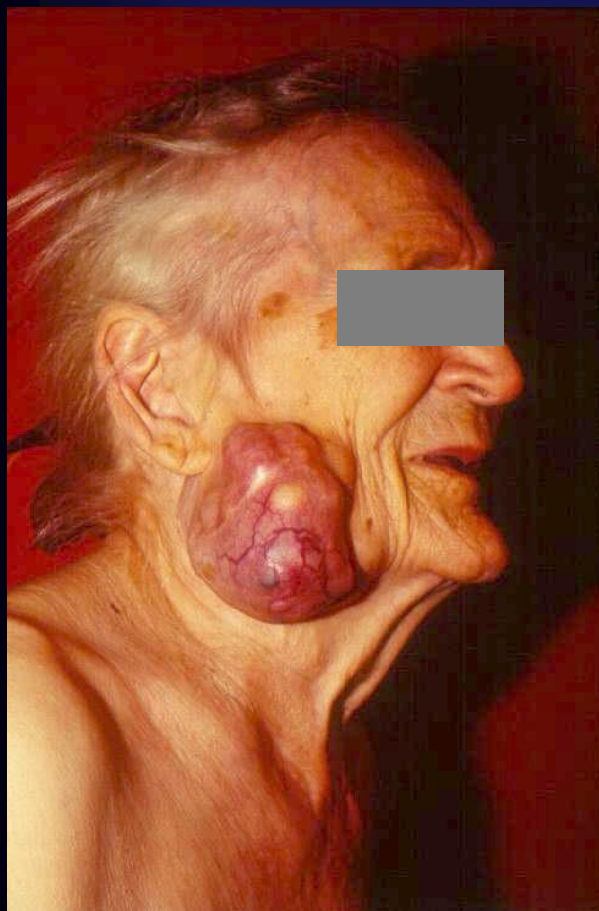

**Pleomorf adenoma**



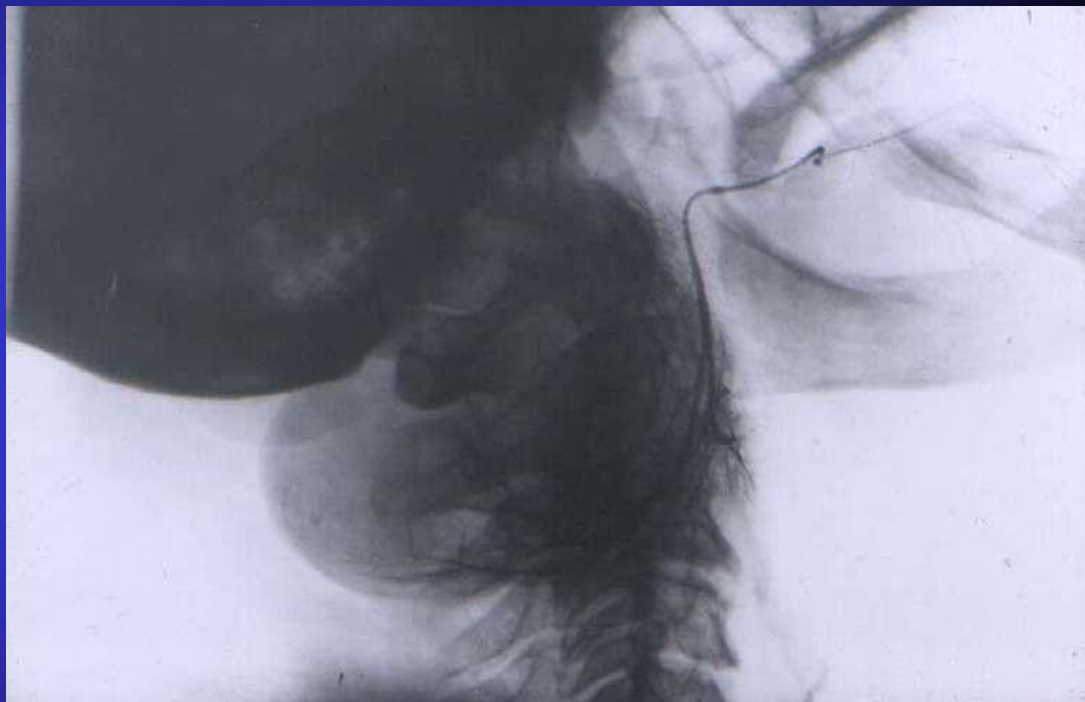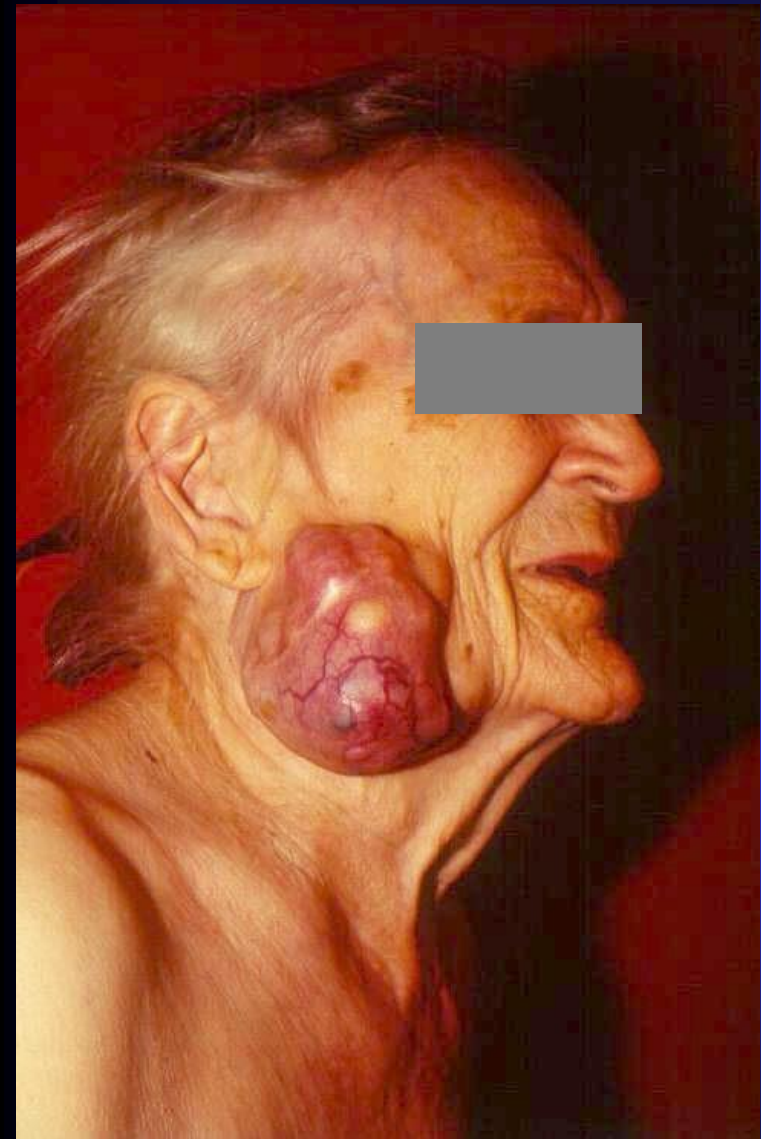**Pleomorf adenoma**  
egy héttel a műtét után

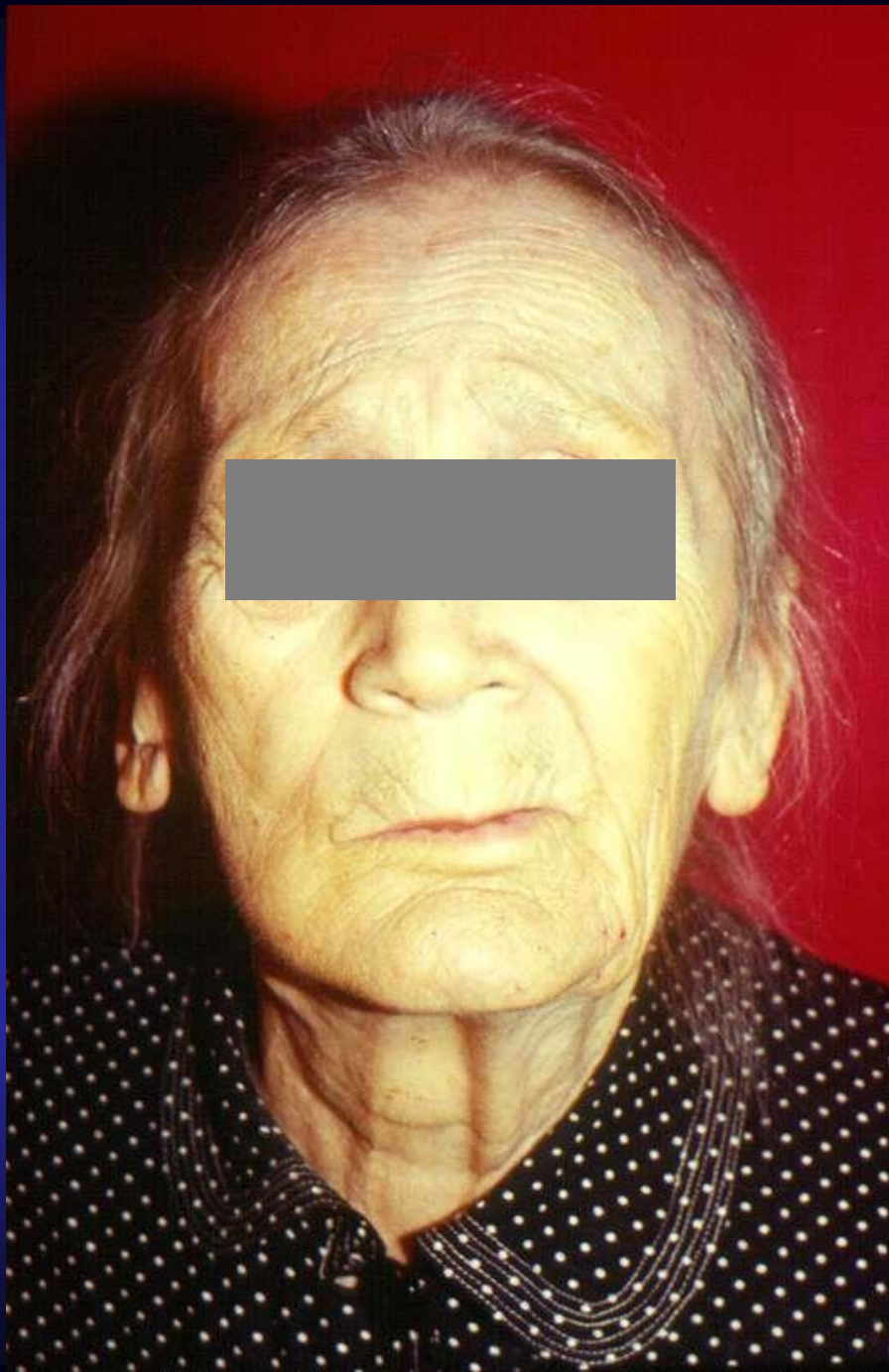

## **Pleomorfa adenoma**

92 éves nőbeteg

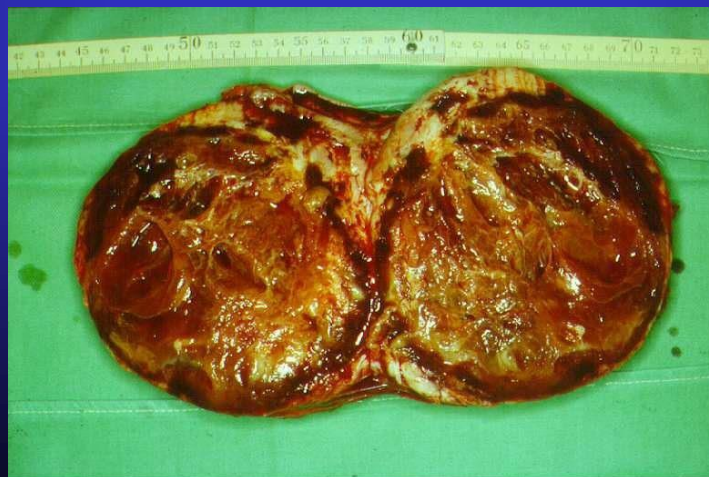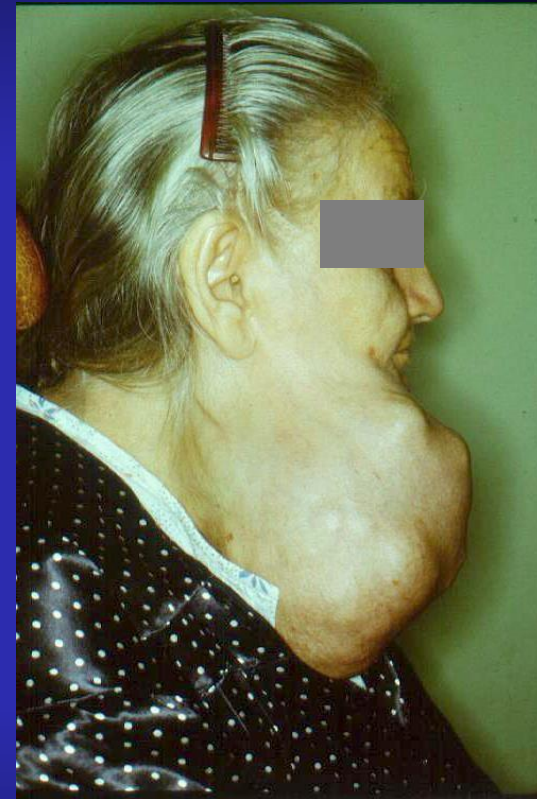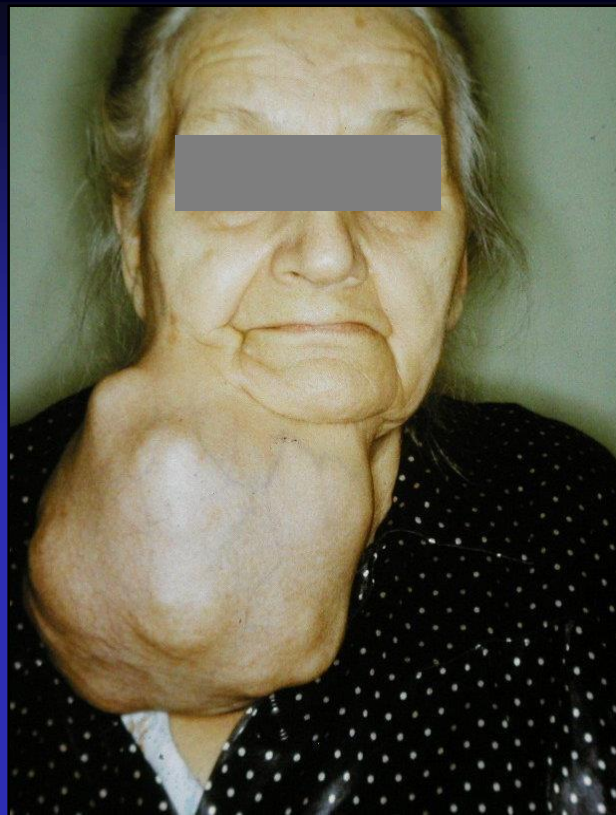


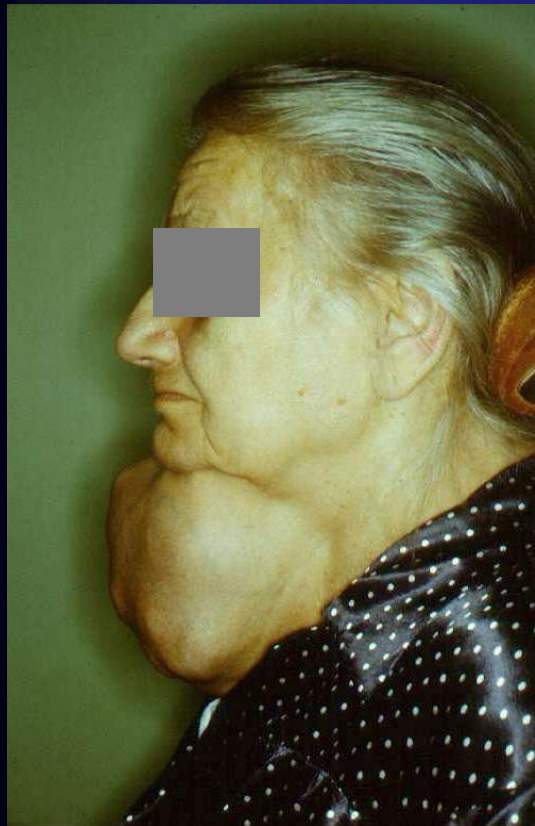




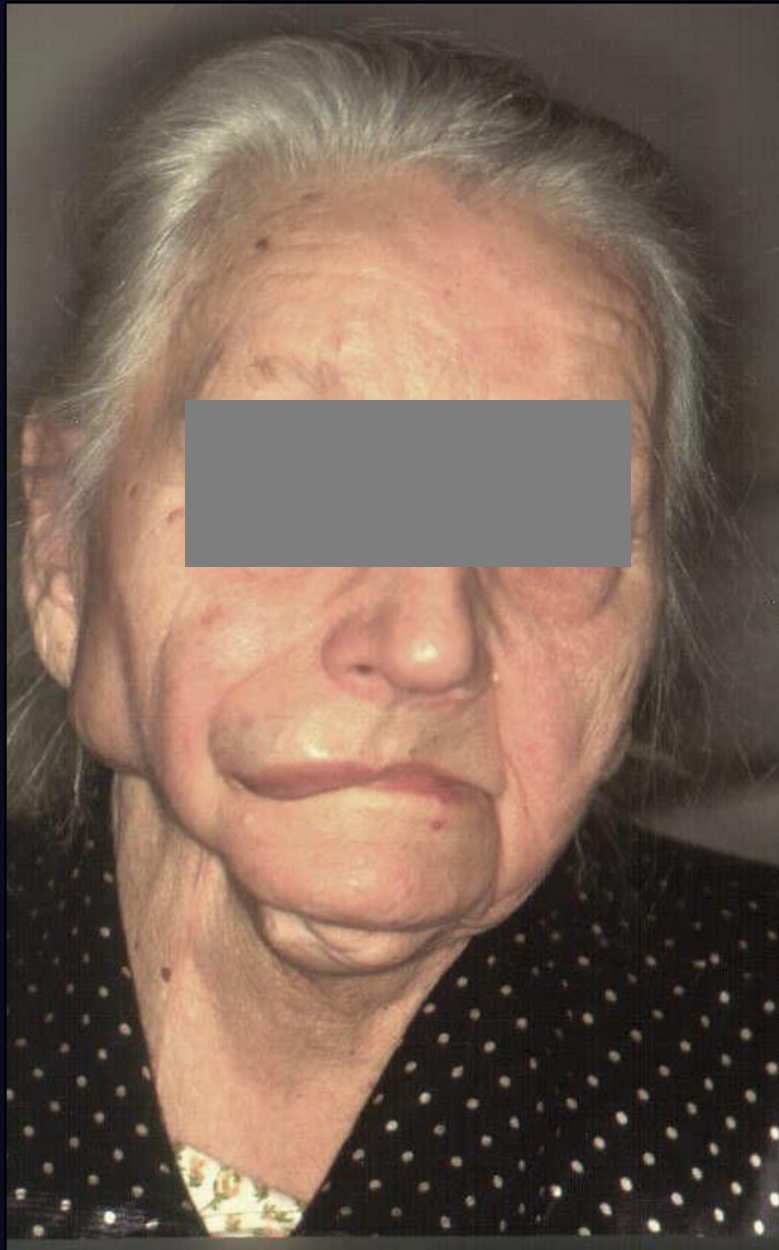
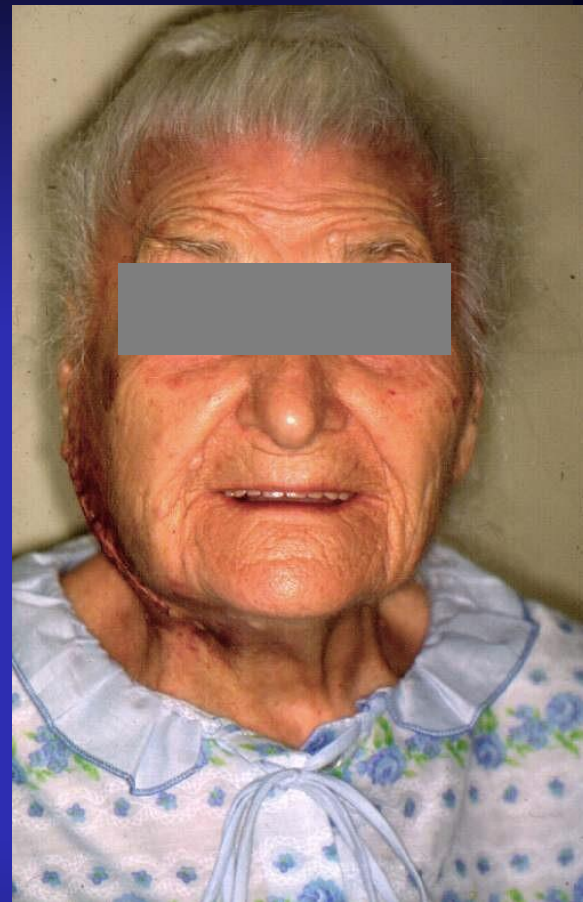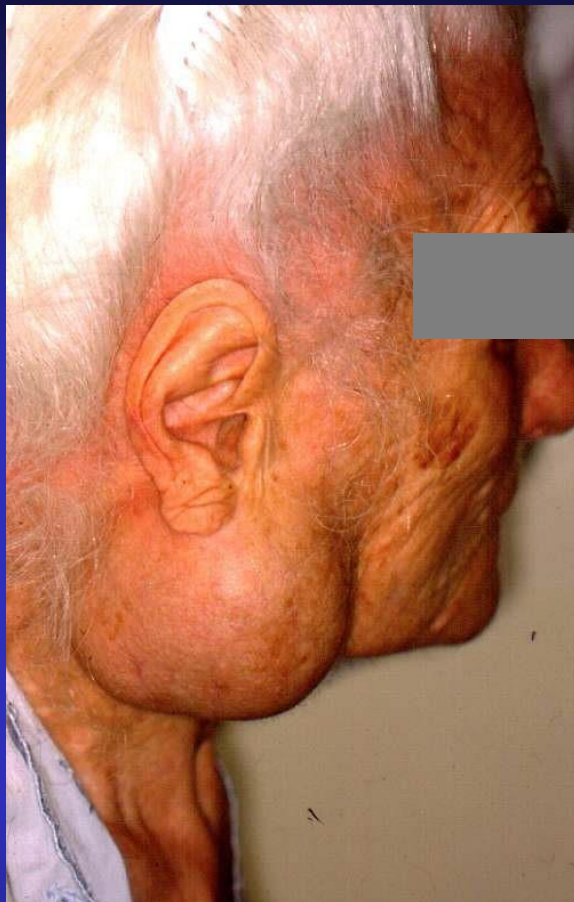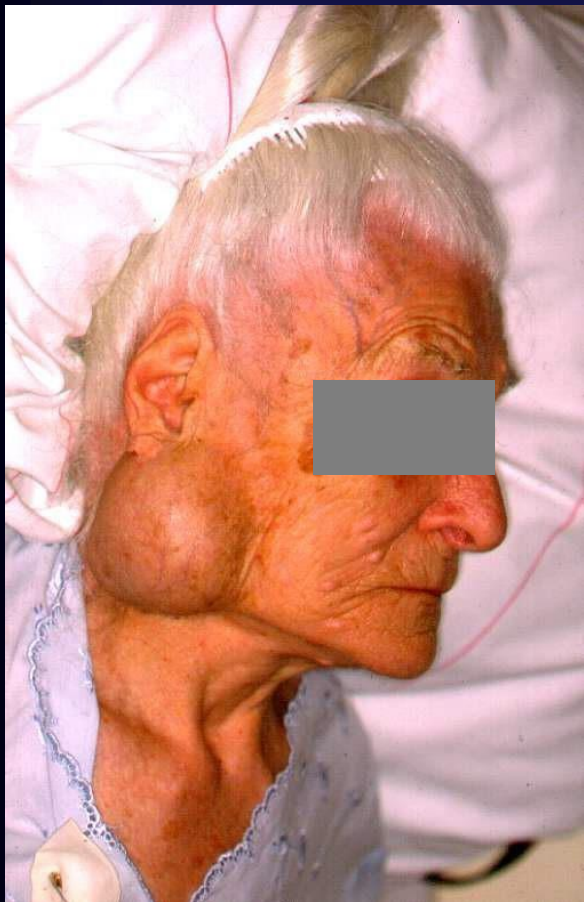# Pleomorf adenoma





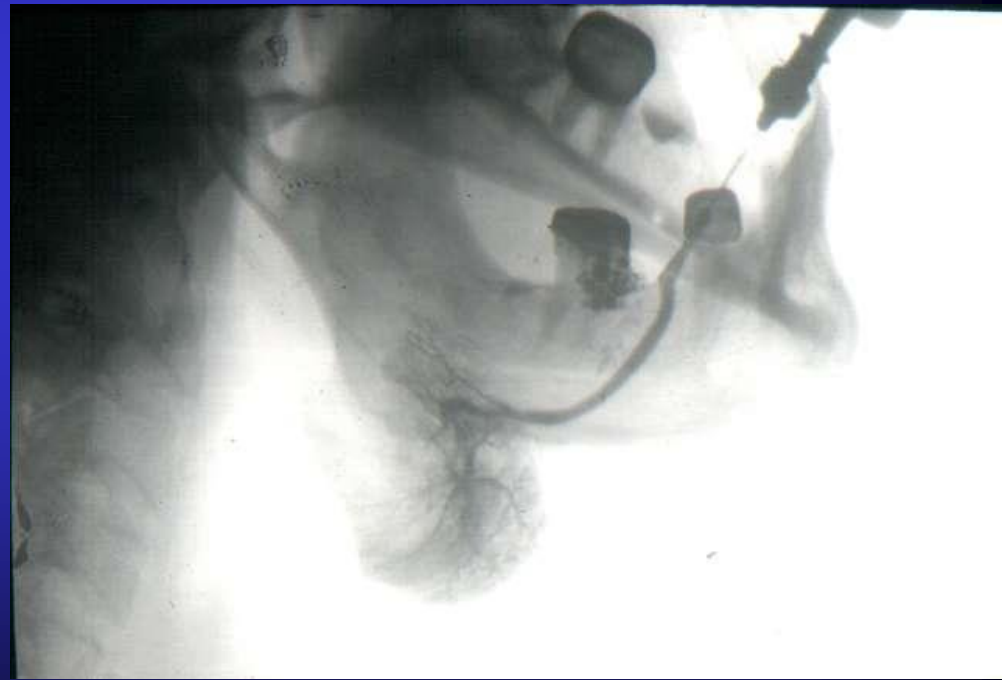
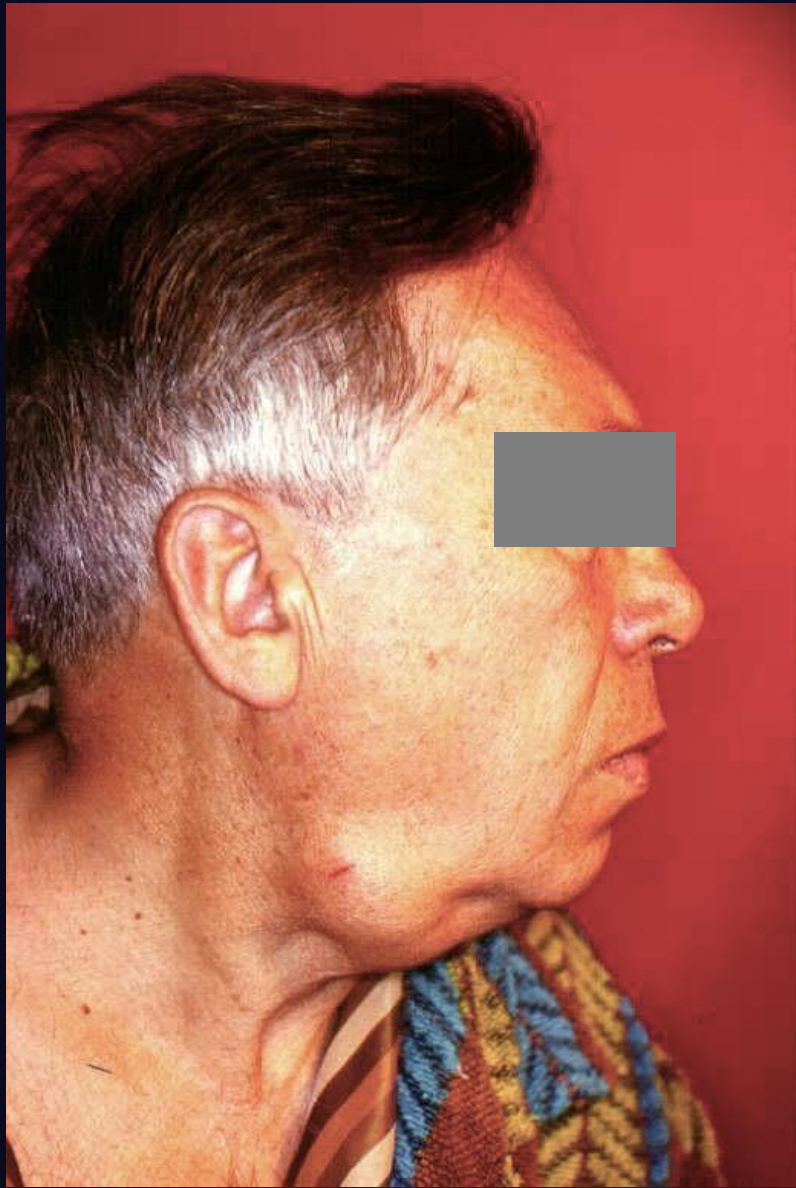
**12 évvel a műtét után,  
vegyes tumor a felső  
ajakban**



## **Vegyés tumor a parotisban**

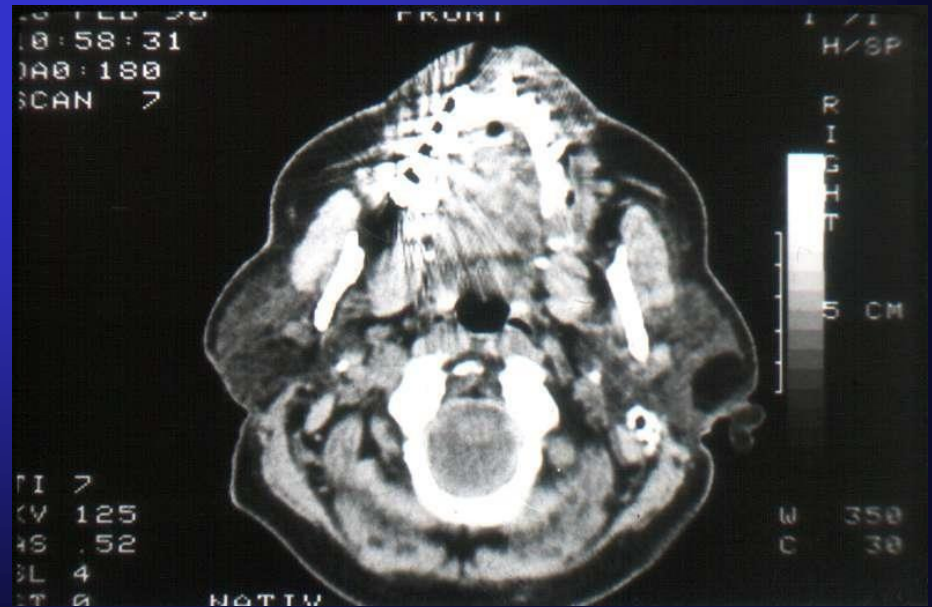
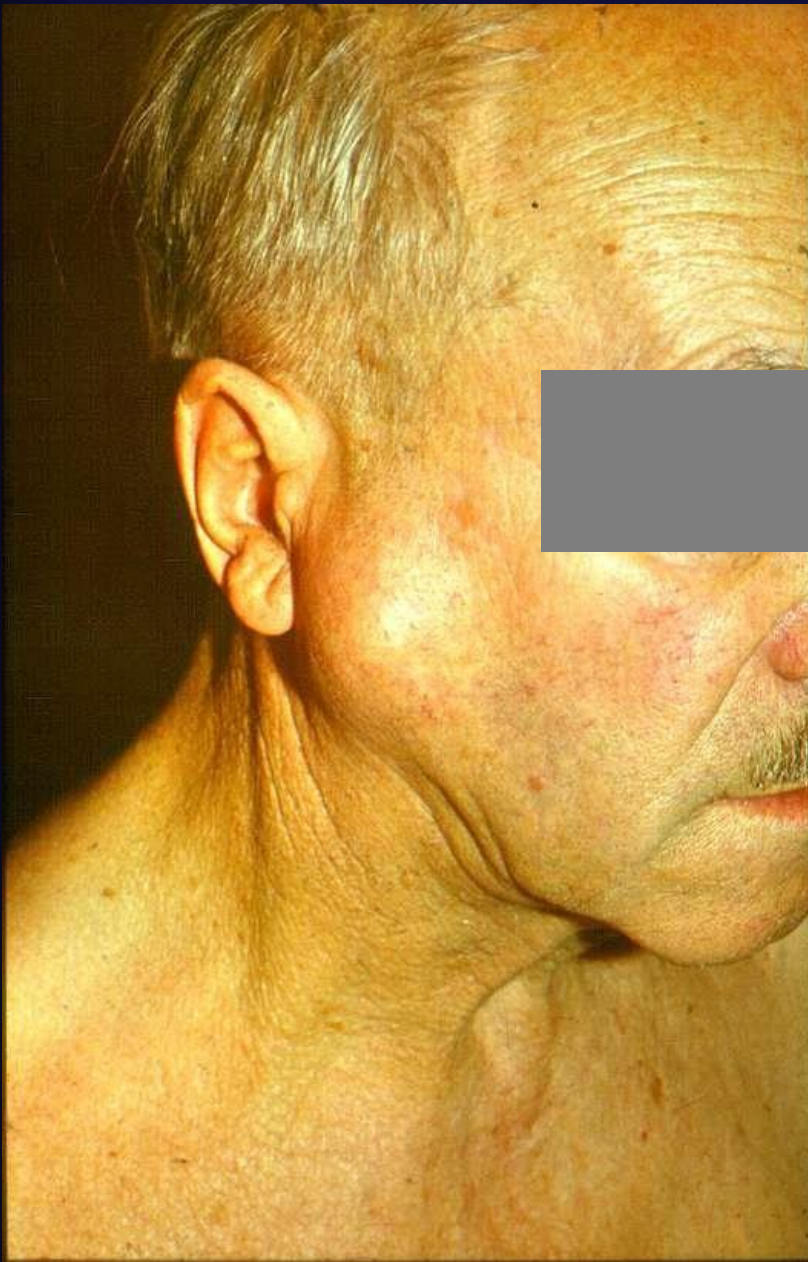102 éves nőbeteg

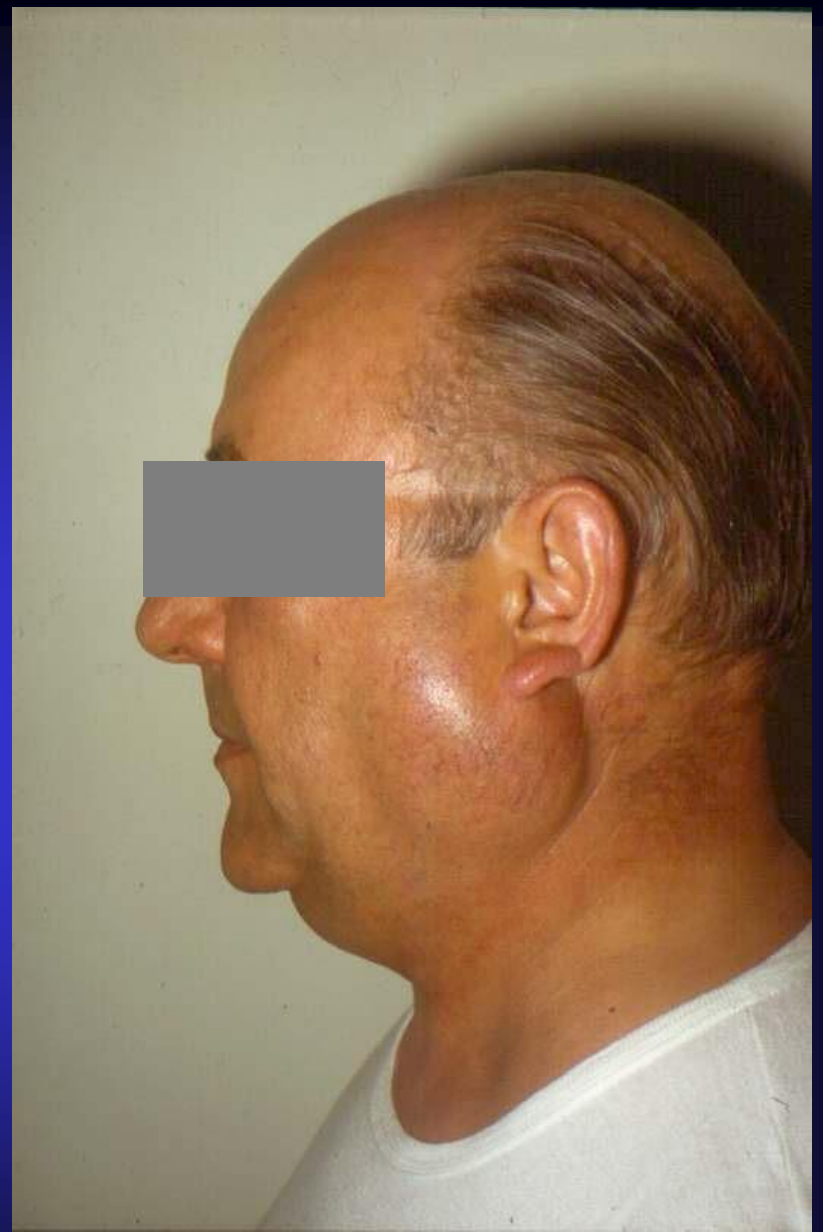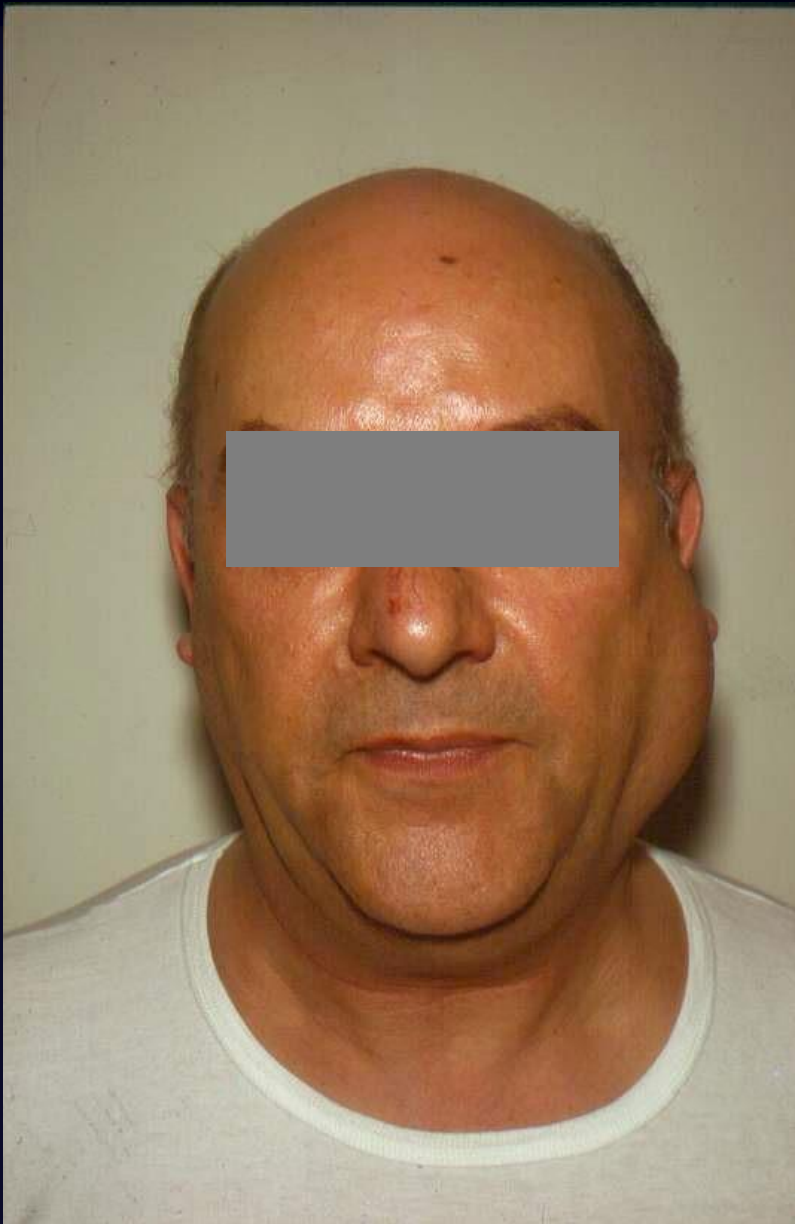


**Pleomorf adenoma a jobb submandibularis mirigyben**

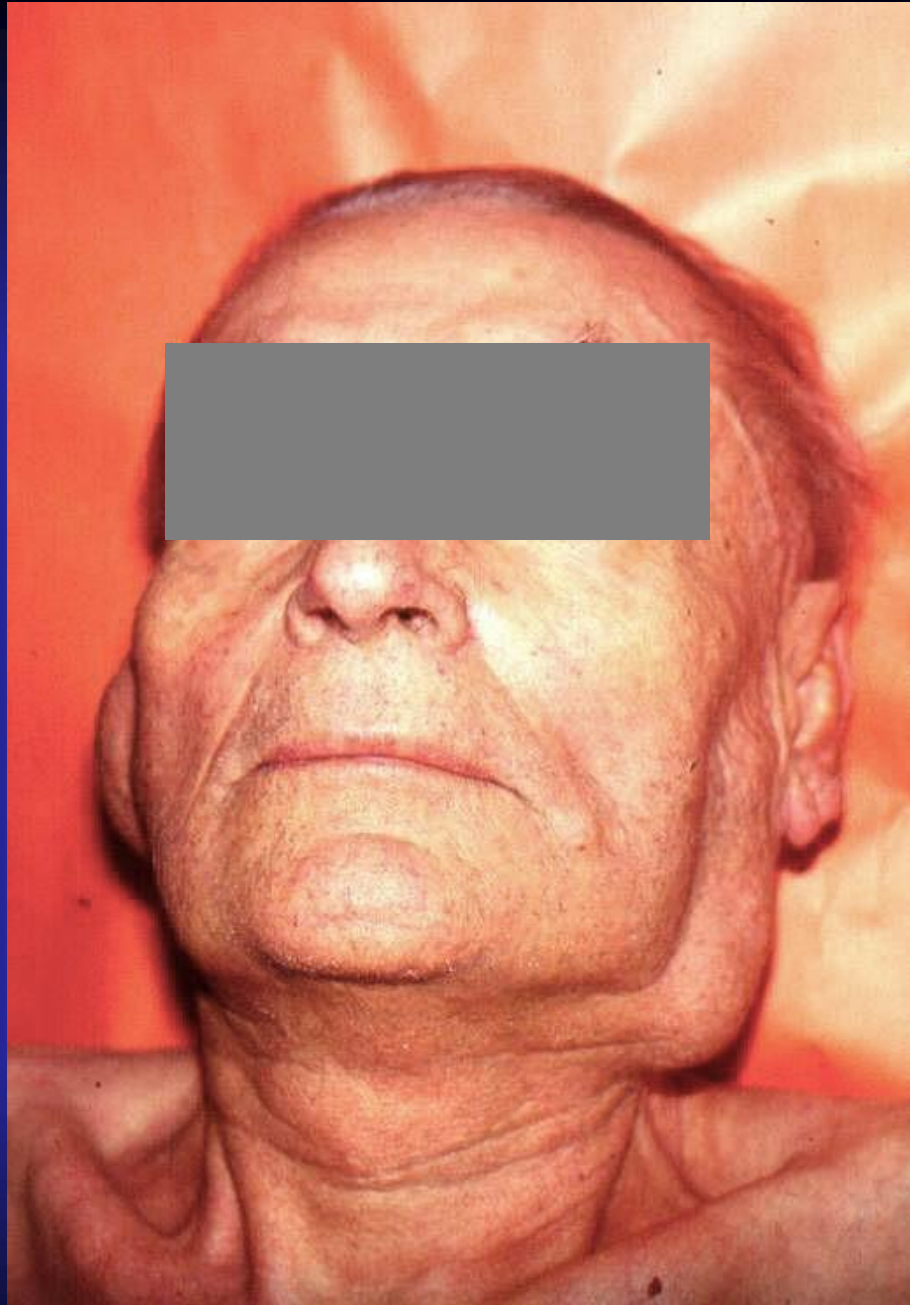

# Oncocytoma a parotisban



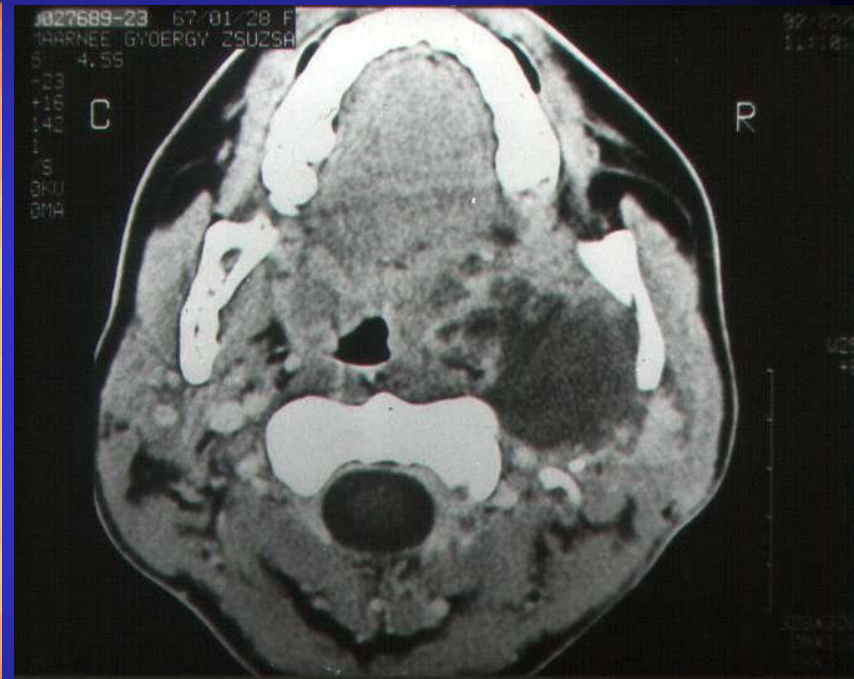
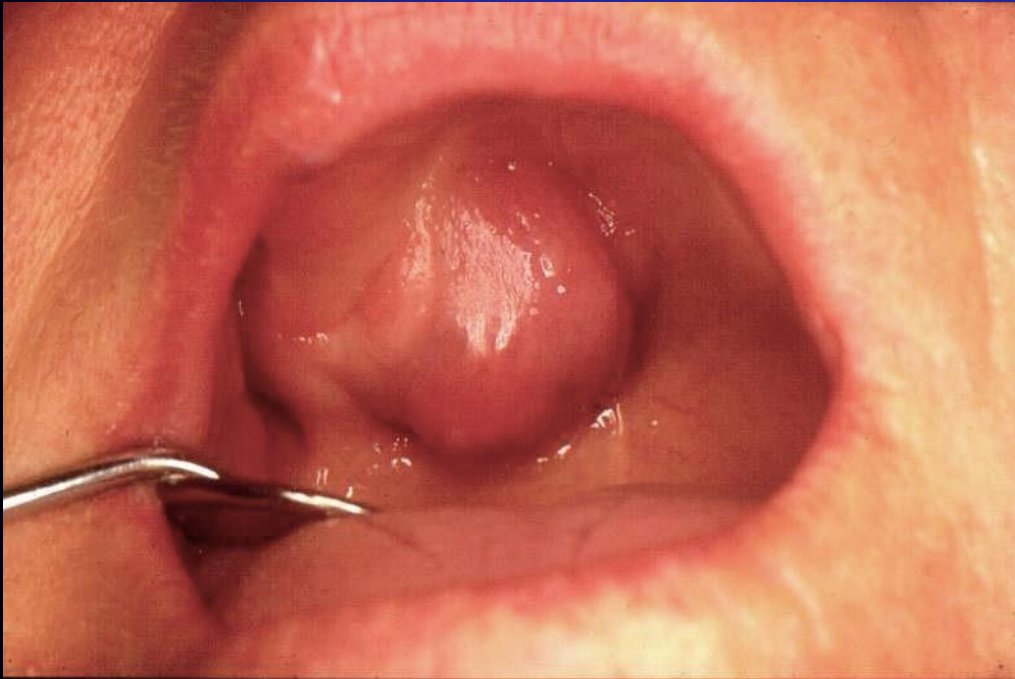


**Cystadenolymphoma (Warthin tumor) a parotisban**

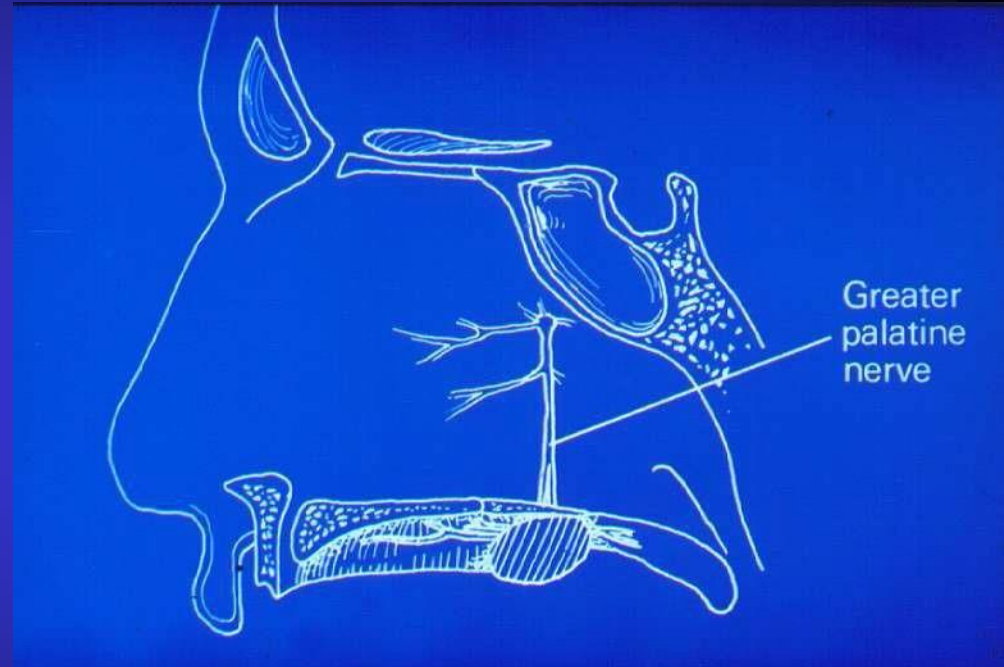
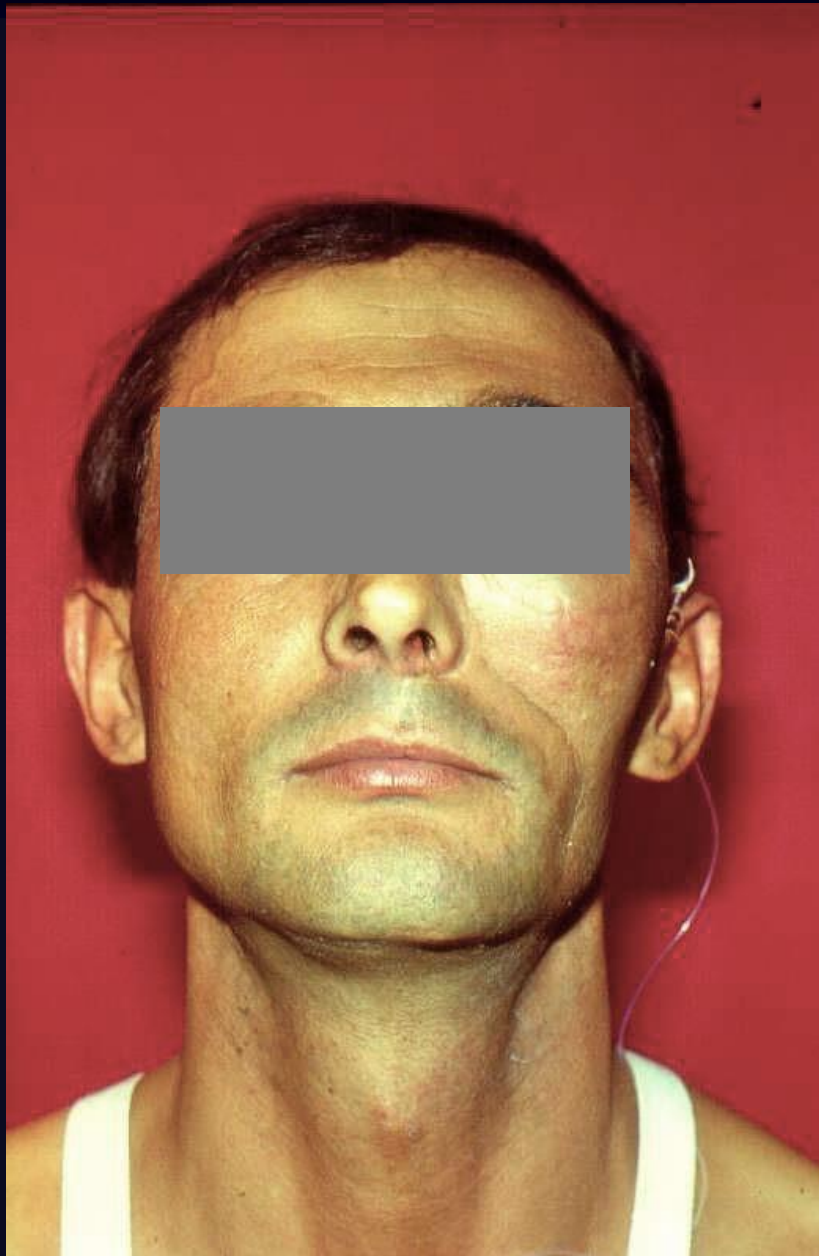

**Bilateralis oncocytoma**

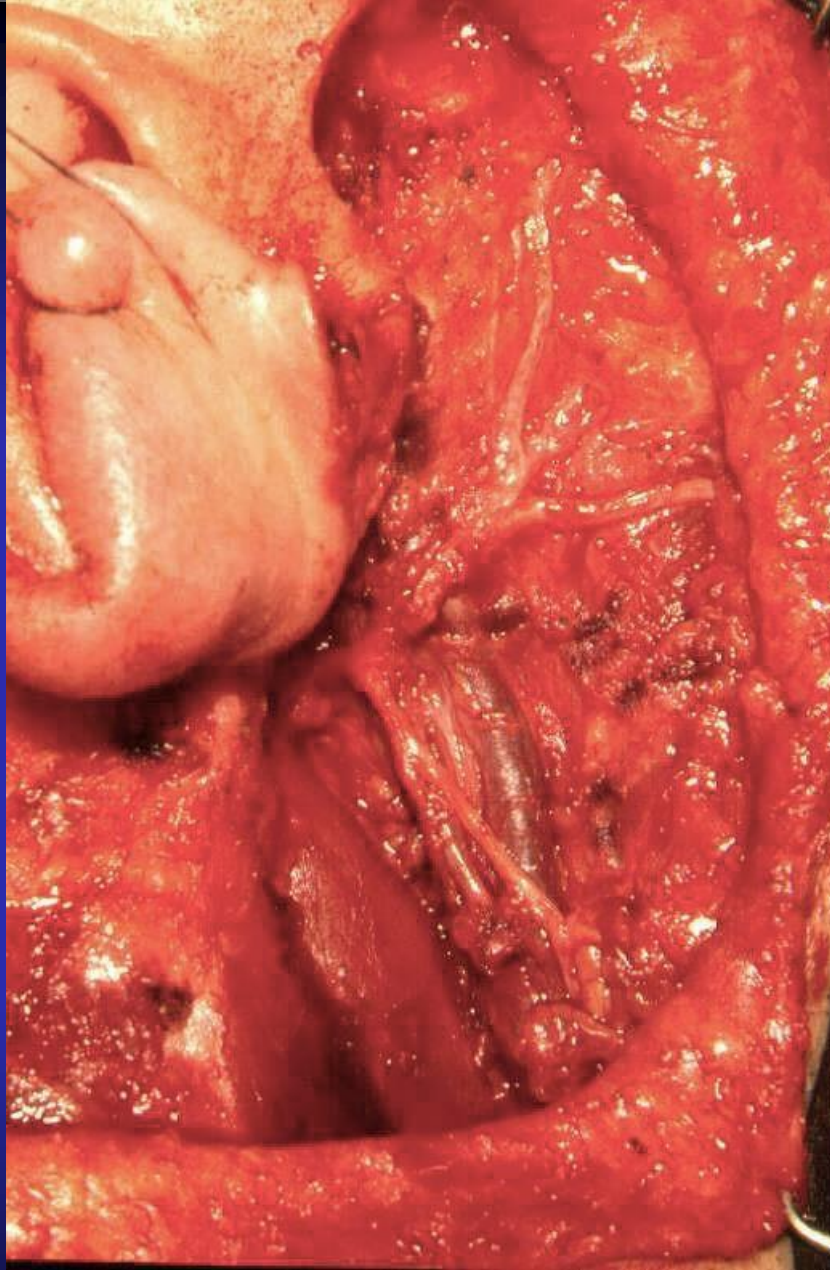




**Pleomorf adenoma a szájpadon**

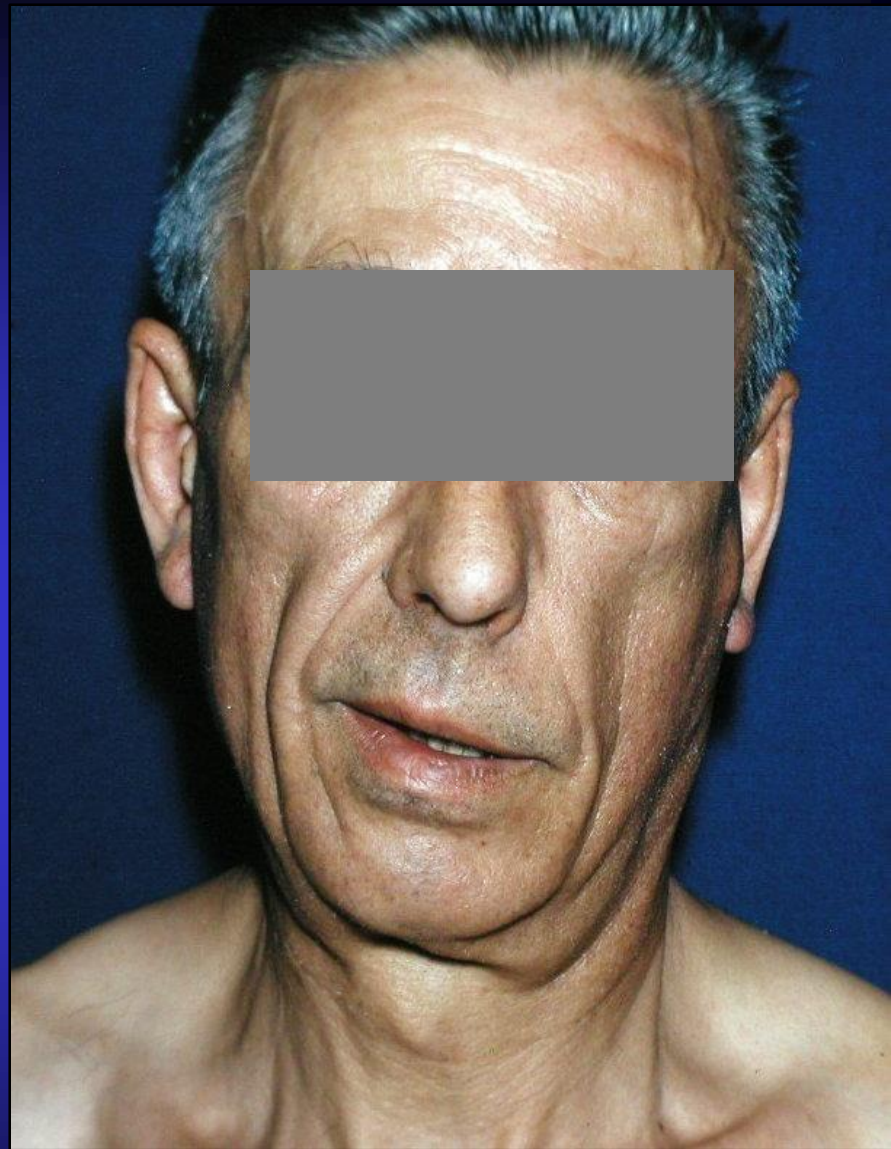
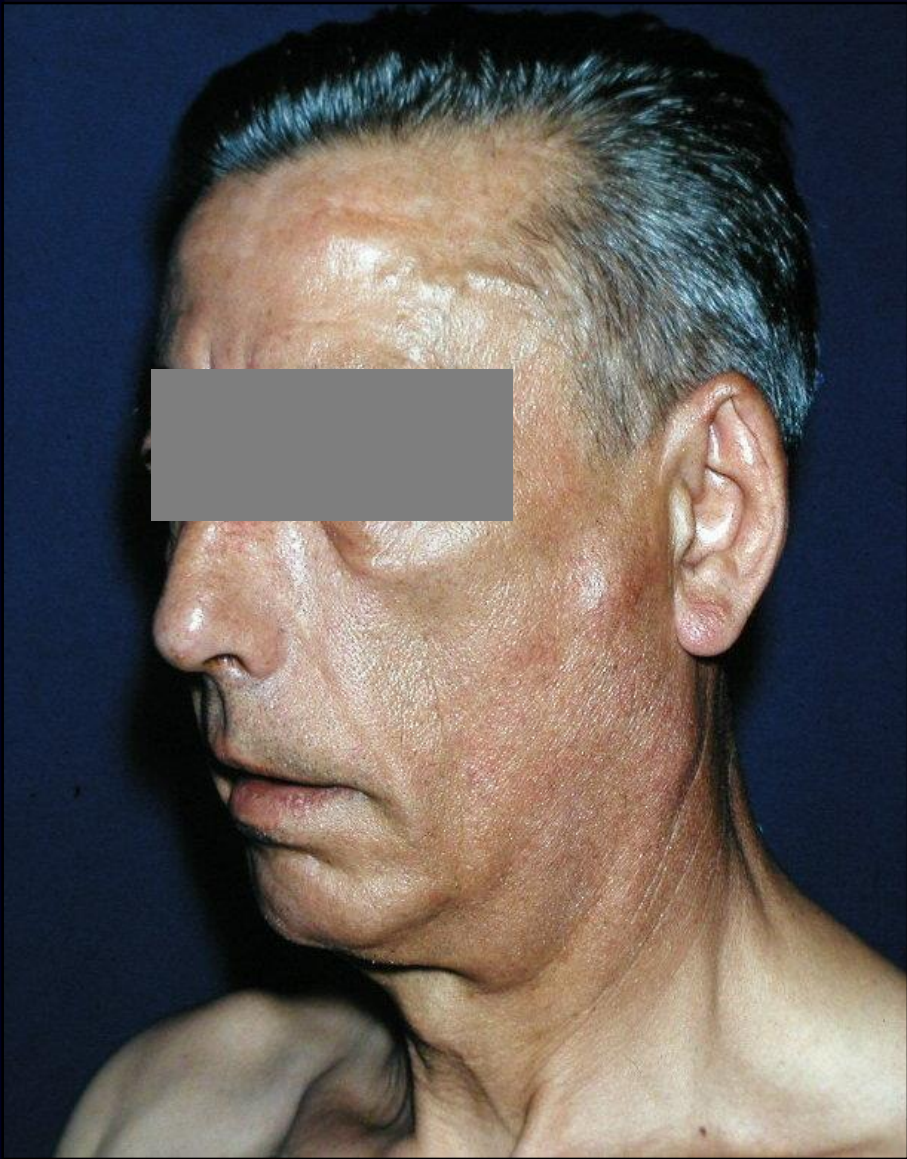

**Palatinalis cylindroma orbitális expansiója**



**Totális parotidectomia**





**Adenocarcinoma a parotisban**

# Specifikus gyulladások

# **Sjögren syndroma**

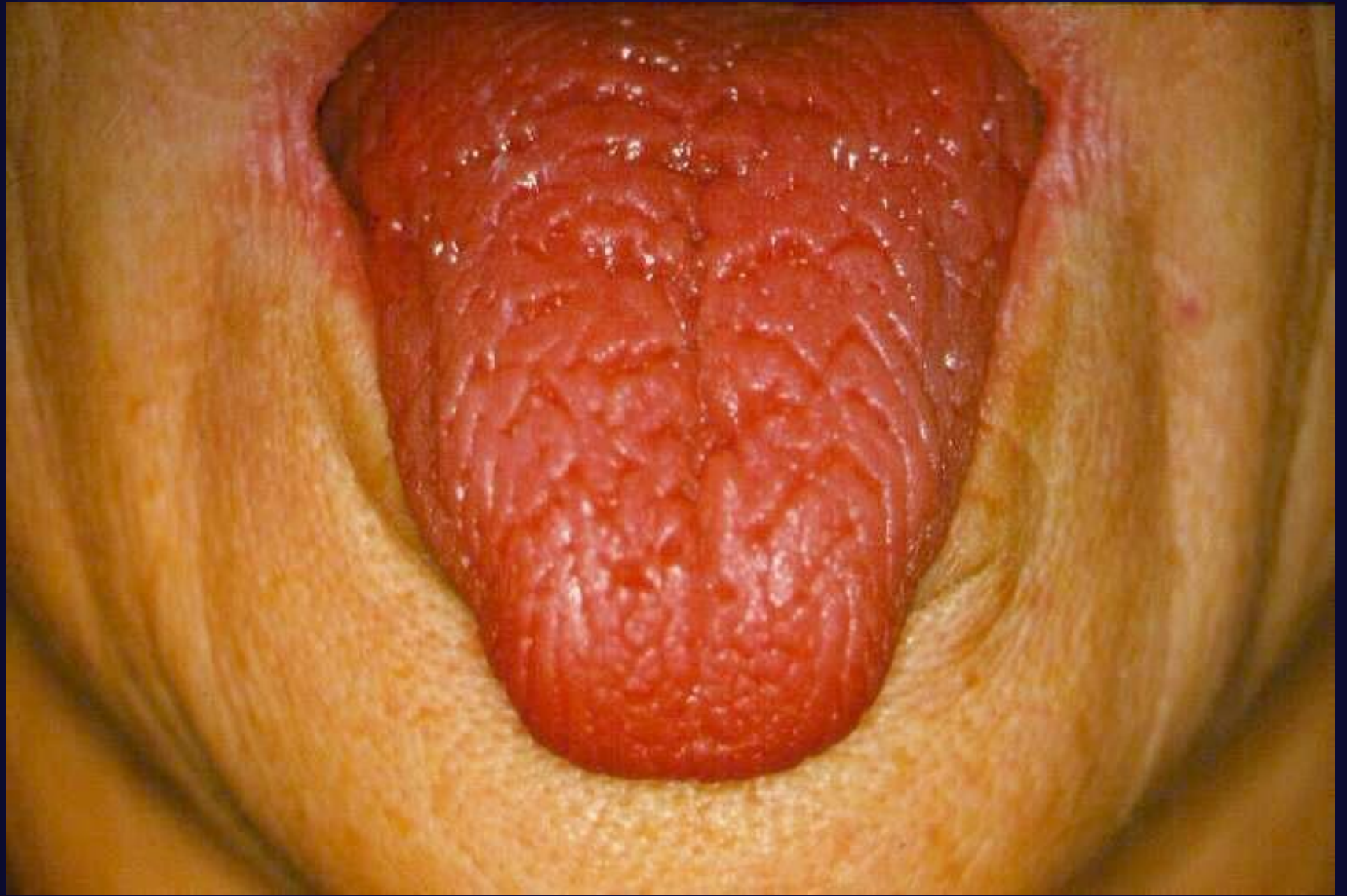**(Sicca-syndroma)**

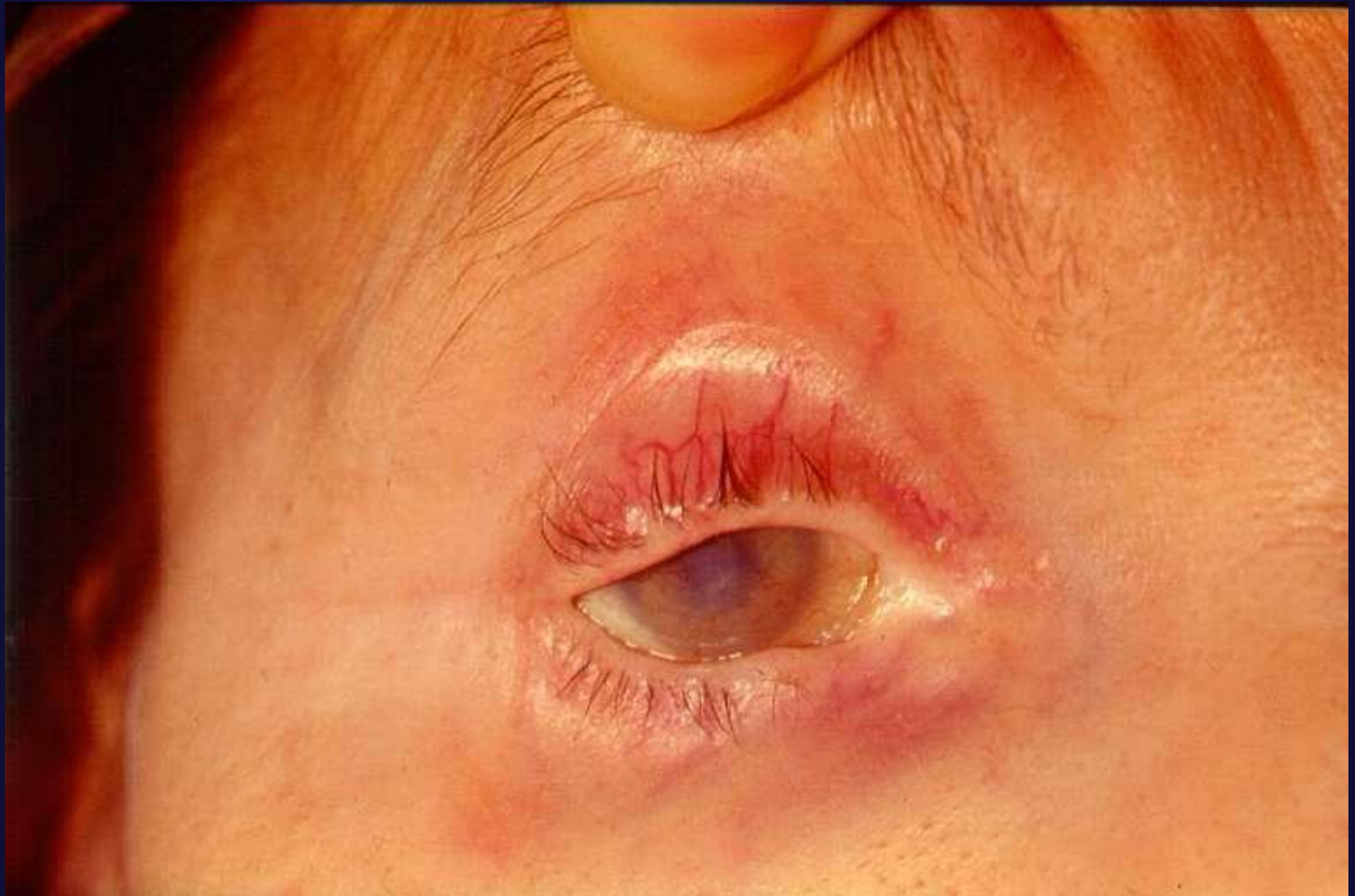**Xerostomia**

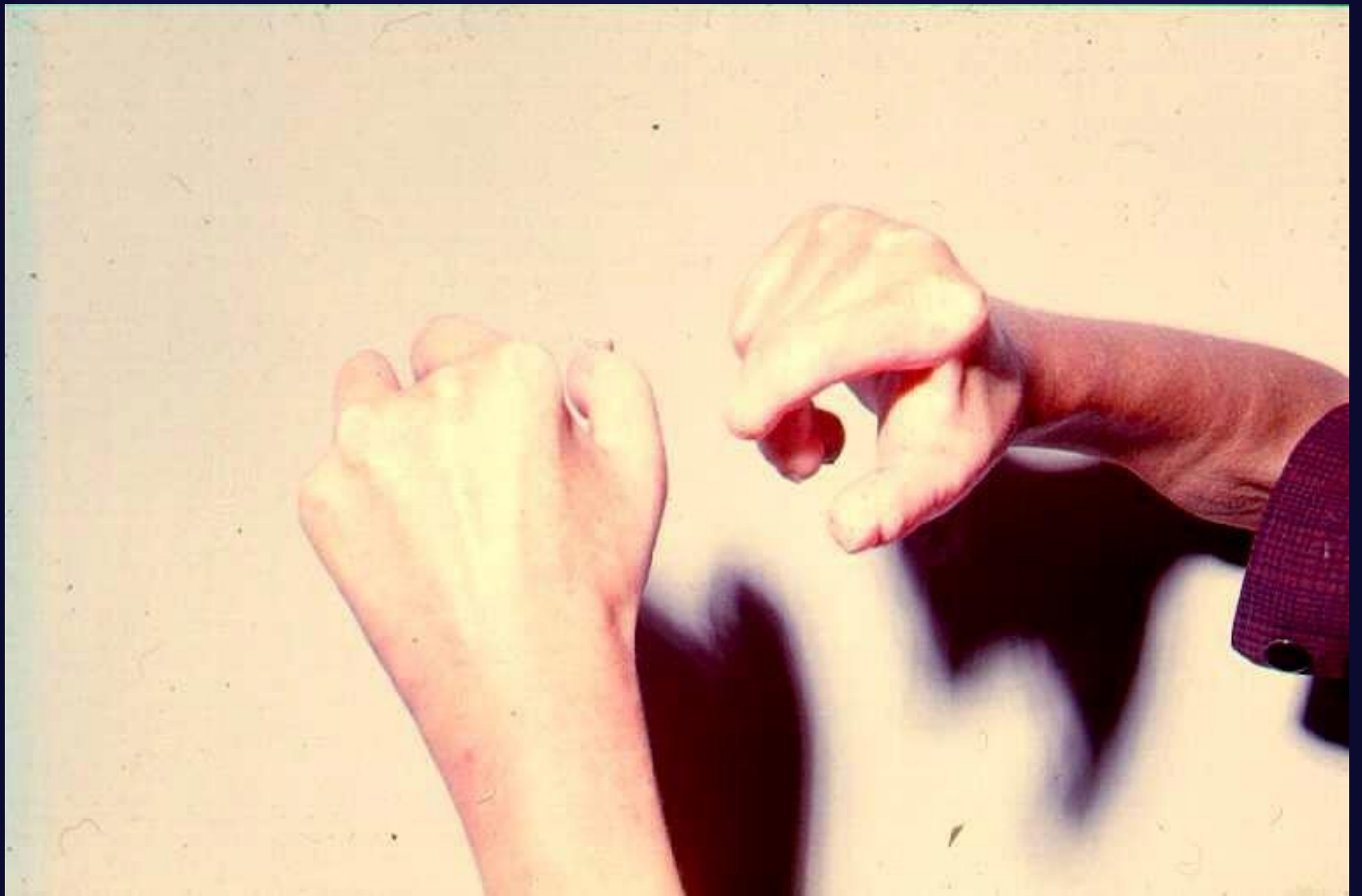**Xerophthalmia**

**Rheumatoid arthritis**

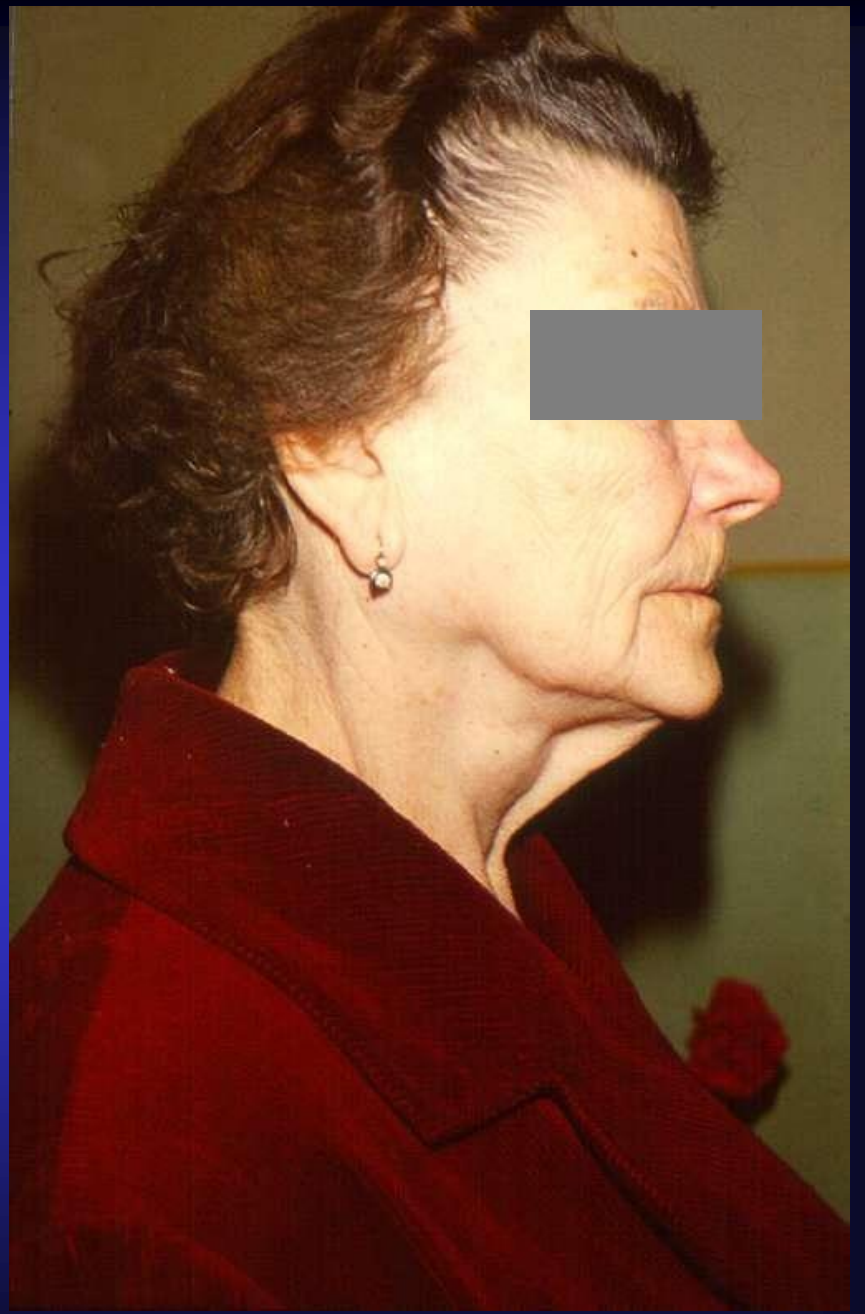
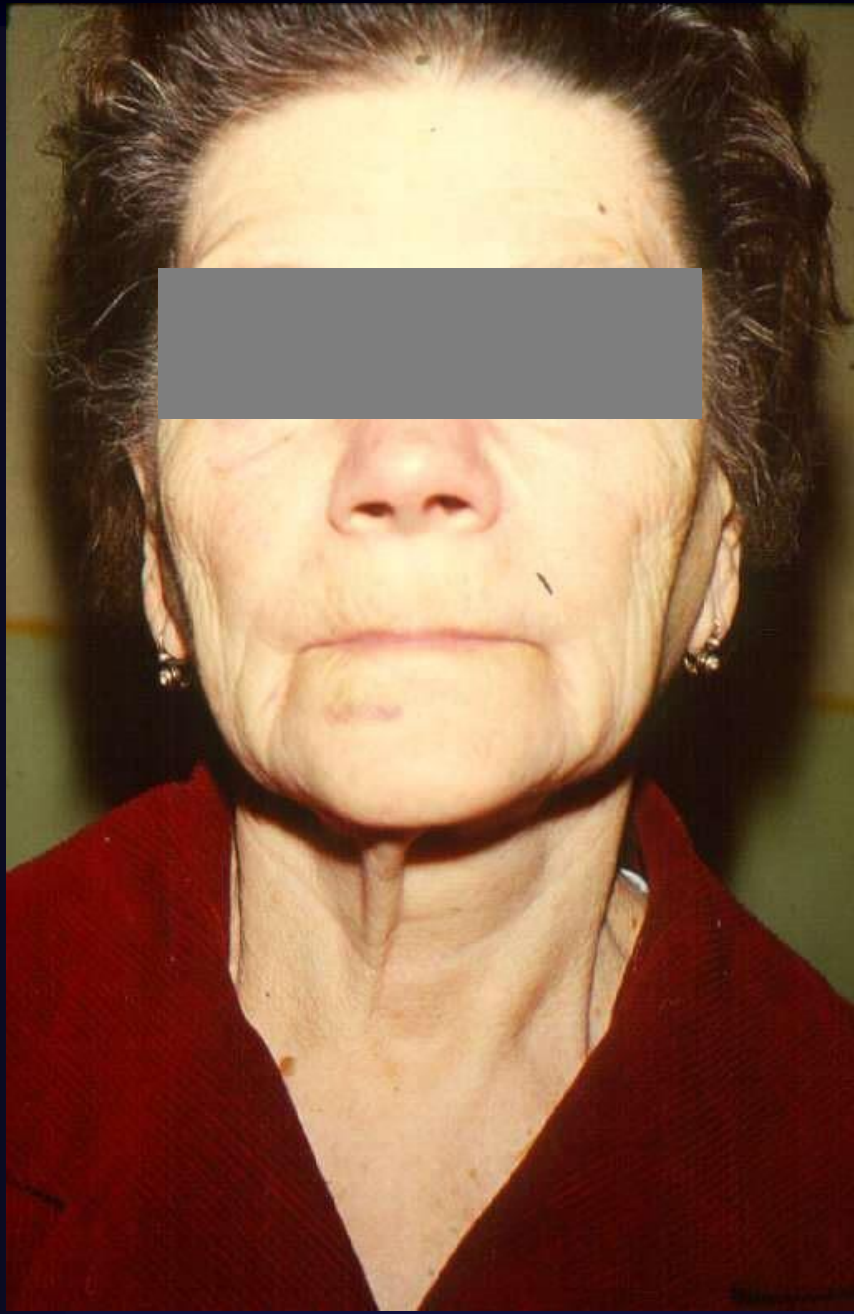


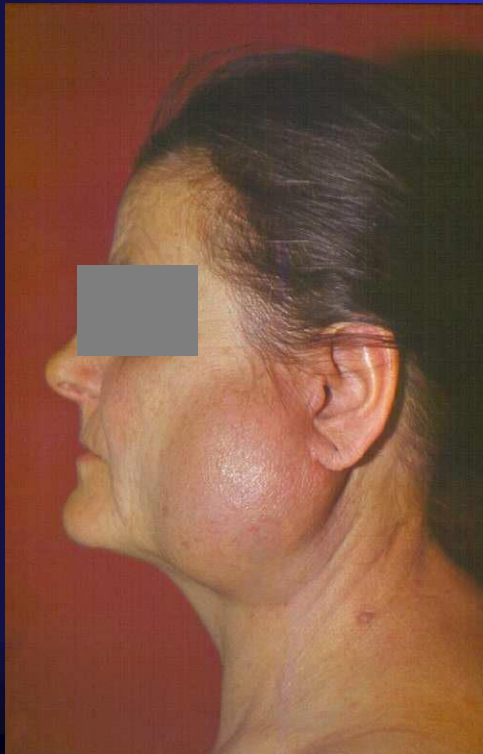
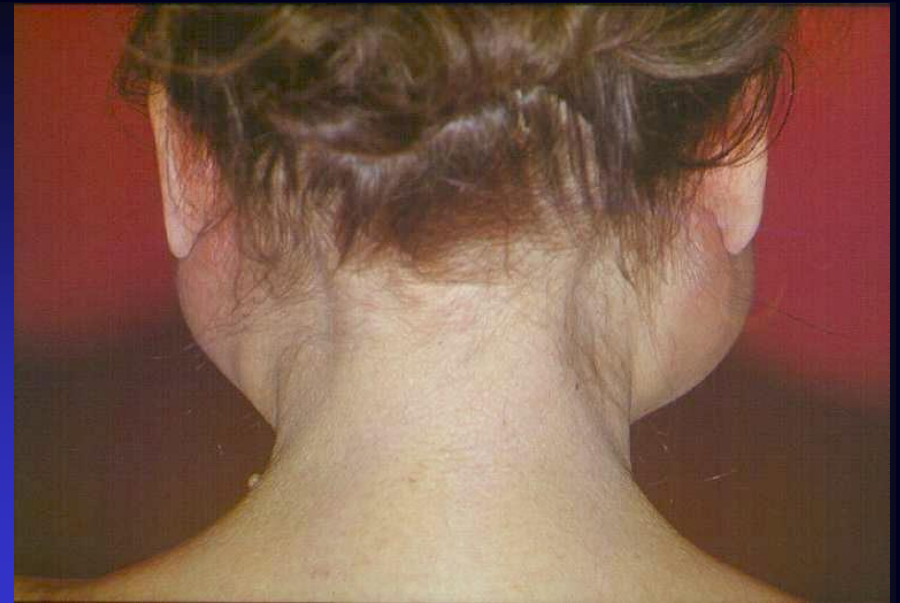
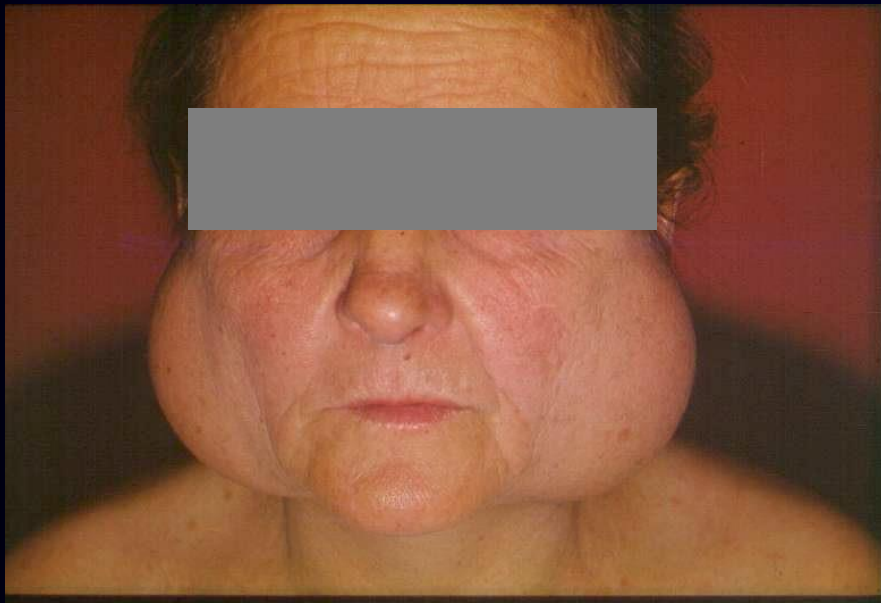

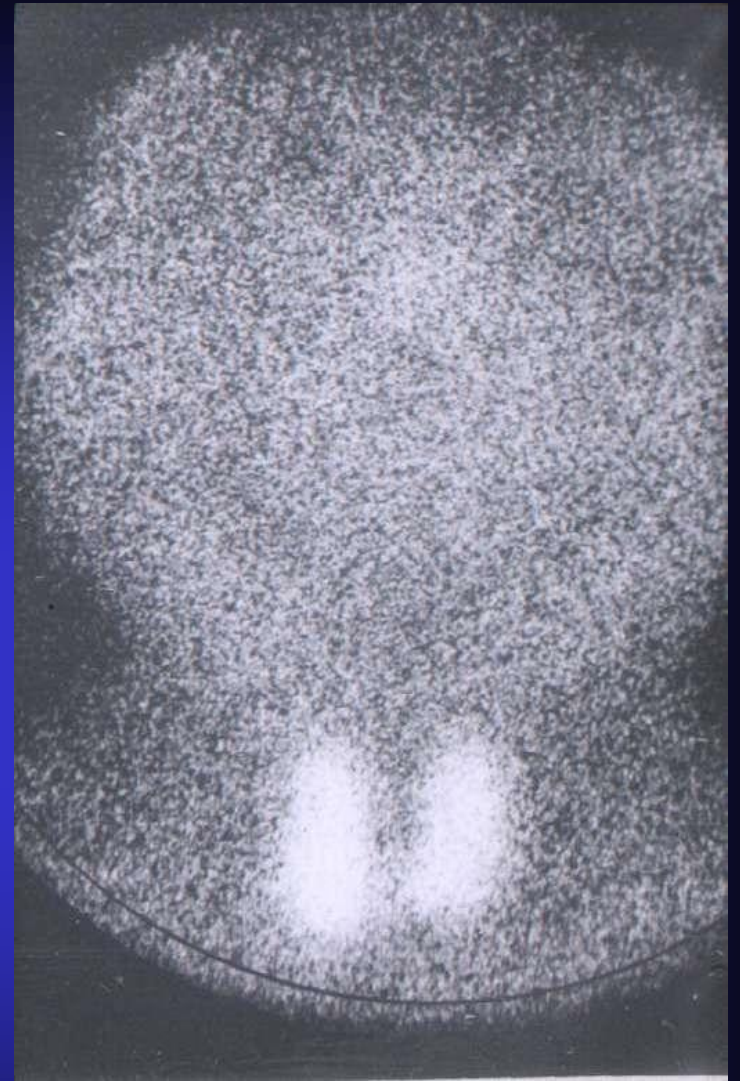





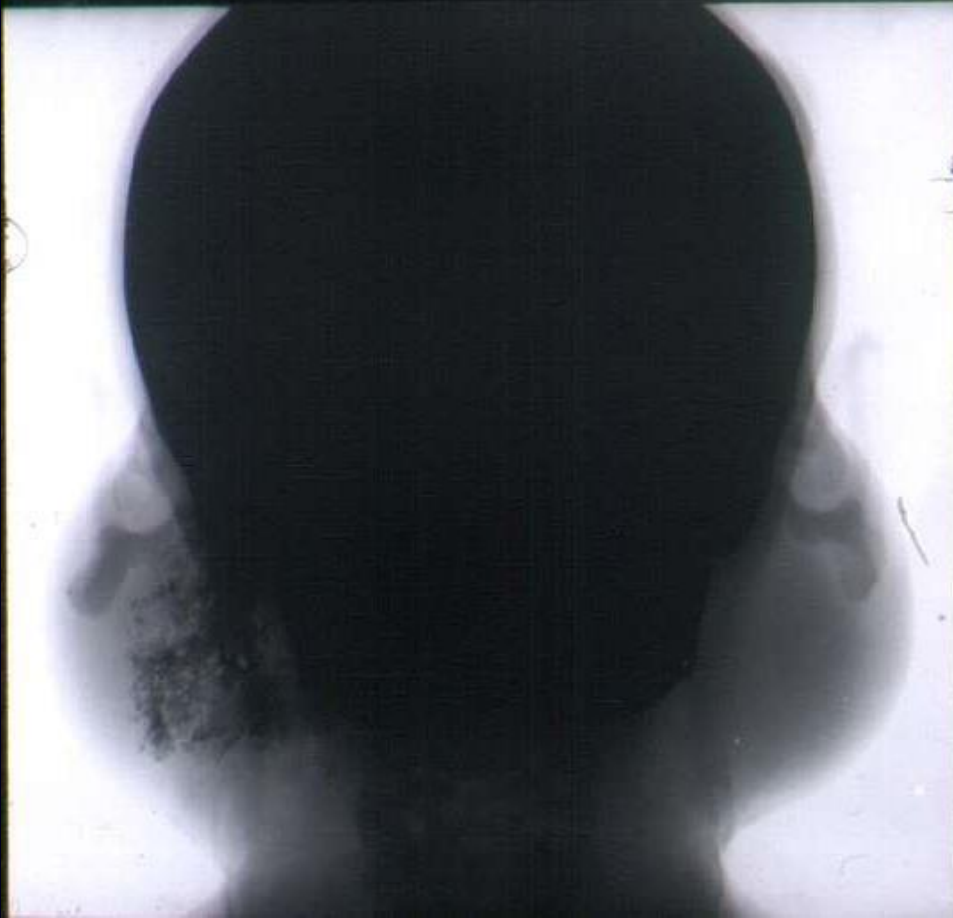
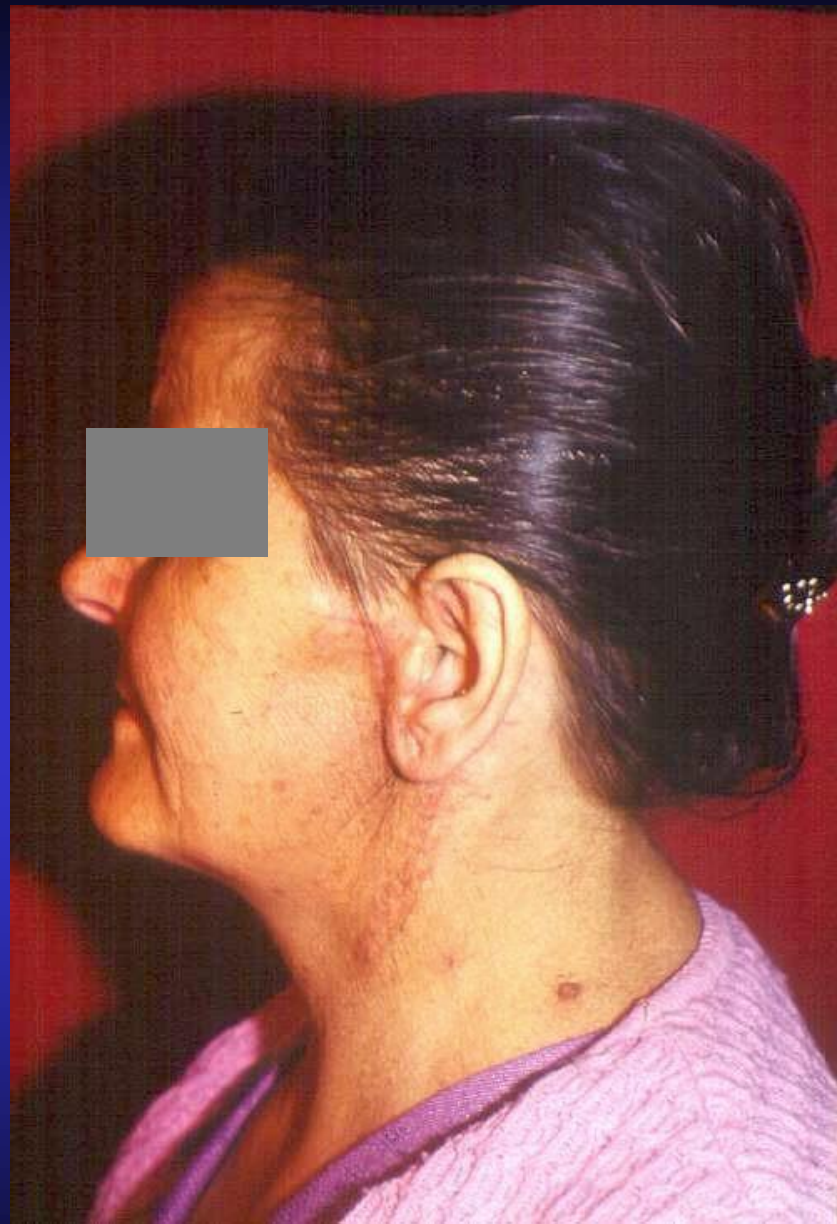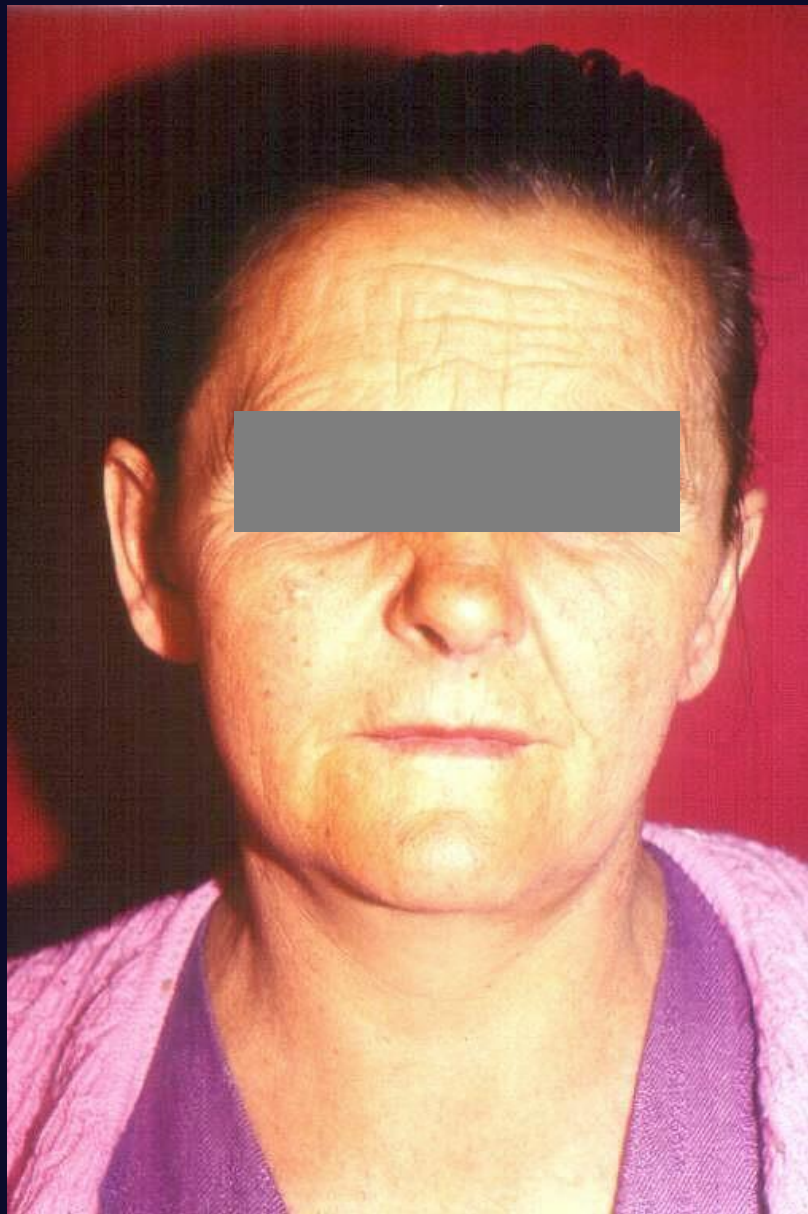**Sjögren syndroma kiterjedt  
lymphoid infiltratioval a  
nyálmirigyekben**





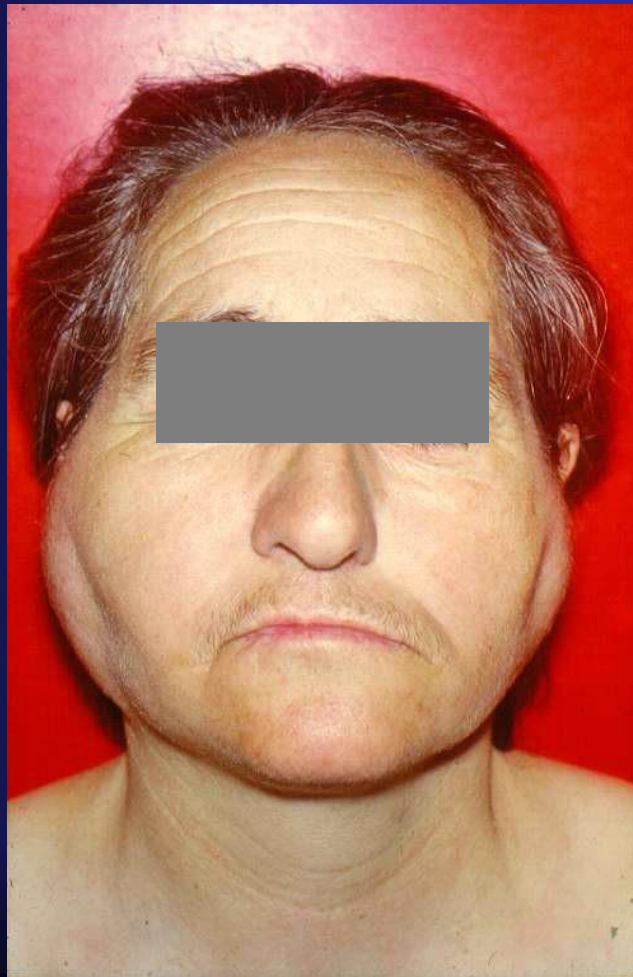**Sjögren syndroma kiterjedt lymphoid infiltrációval a nyálmirigyekben**





# **Mikulicz syndroma**

# **Heerfordt syndroma**



**Parotidomegalia**

**Facialis paresis**

**Láz**

**Uveitis**

**(virus infection)**



