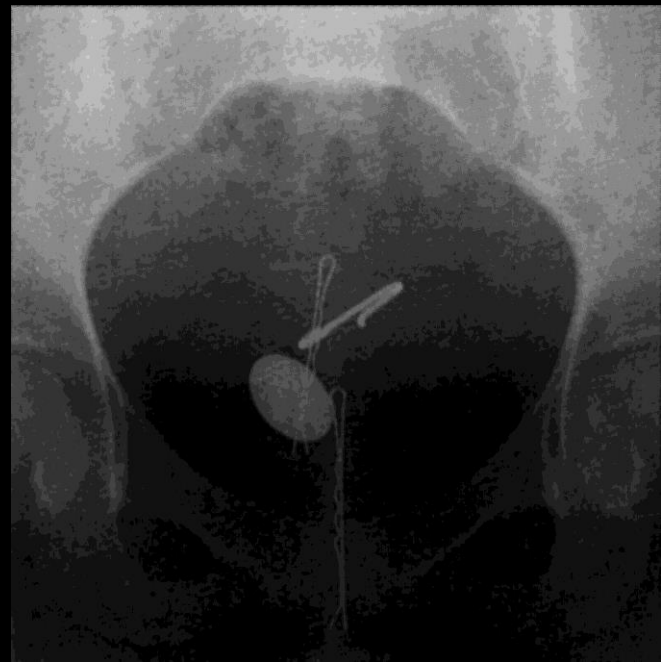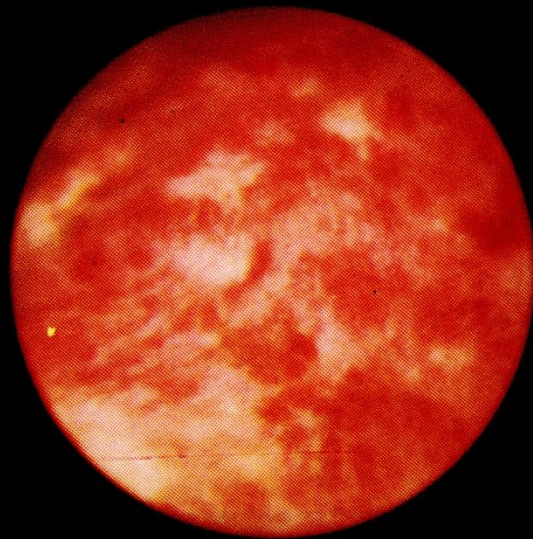
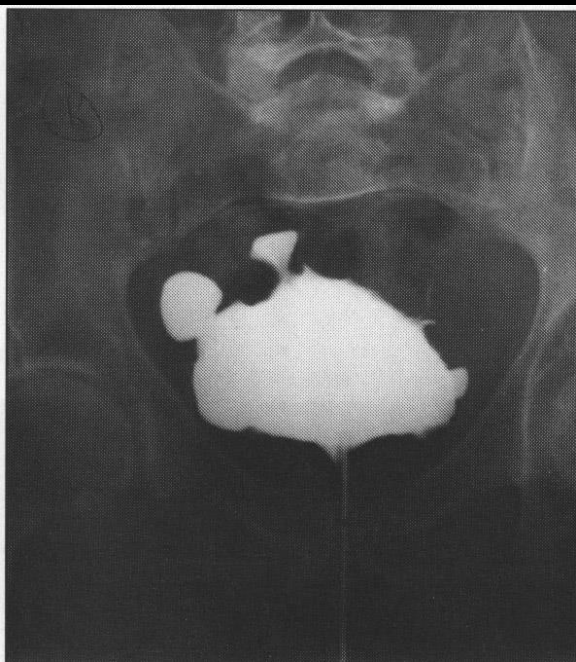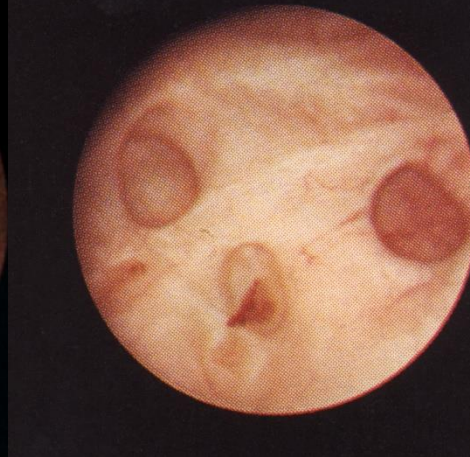
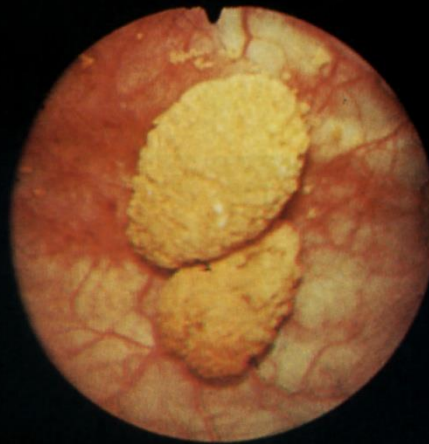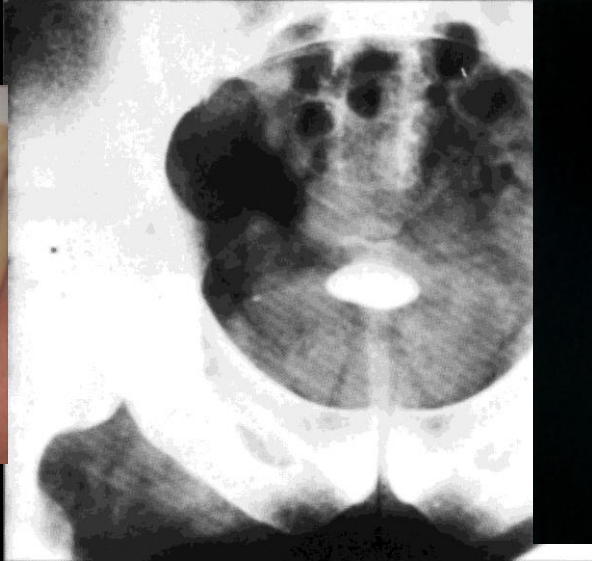
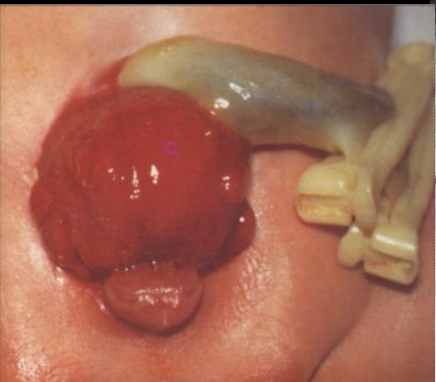


# A húgyhólyag betegségei

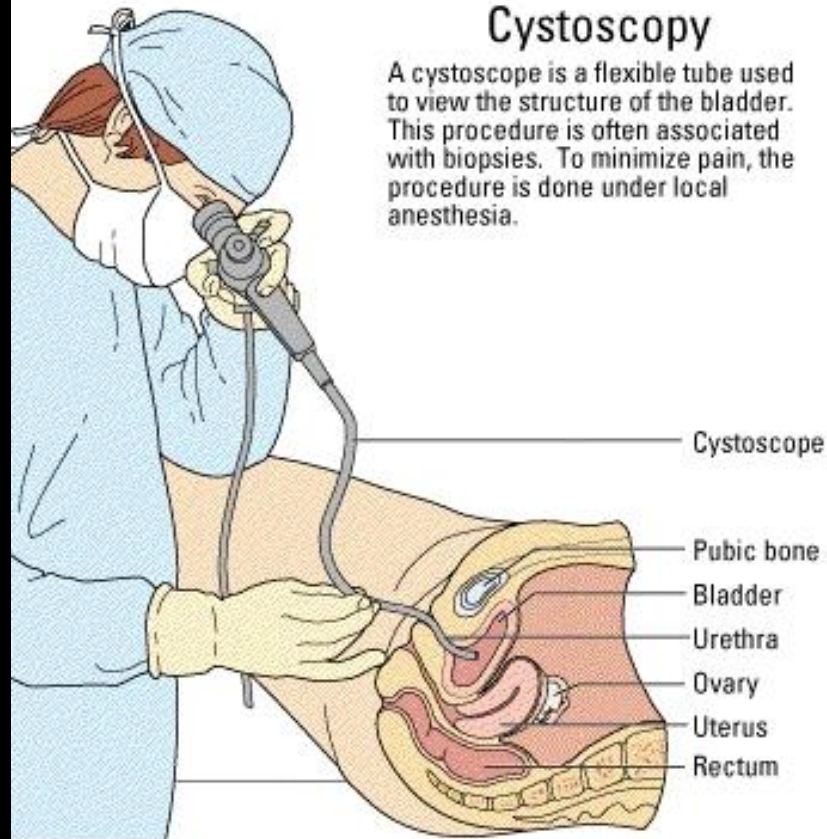


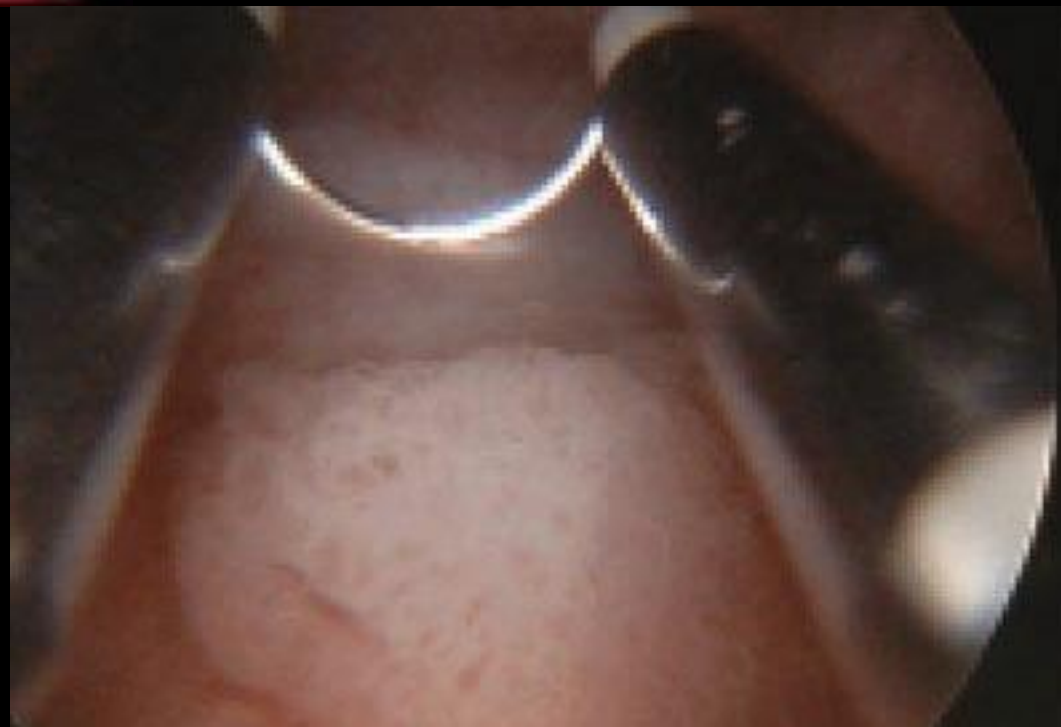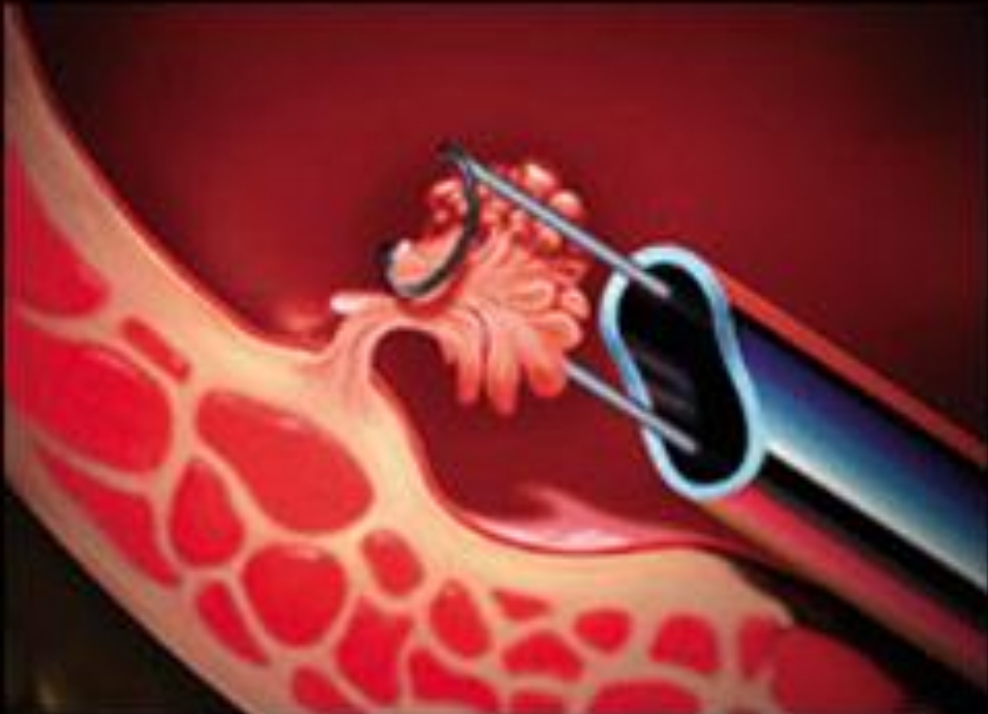
Fejlődési rendellenességek  
Gyulladások  
Kövesség  
Daganatok  
Egyéb

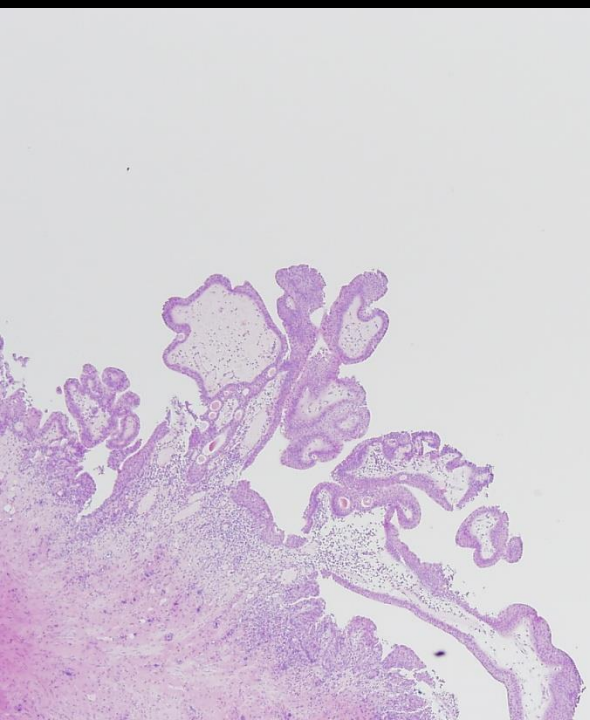
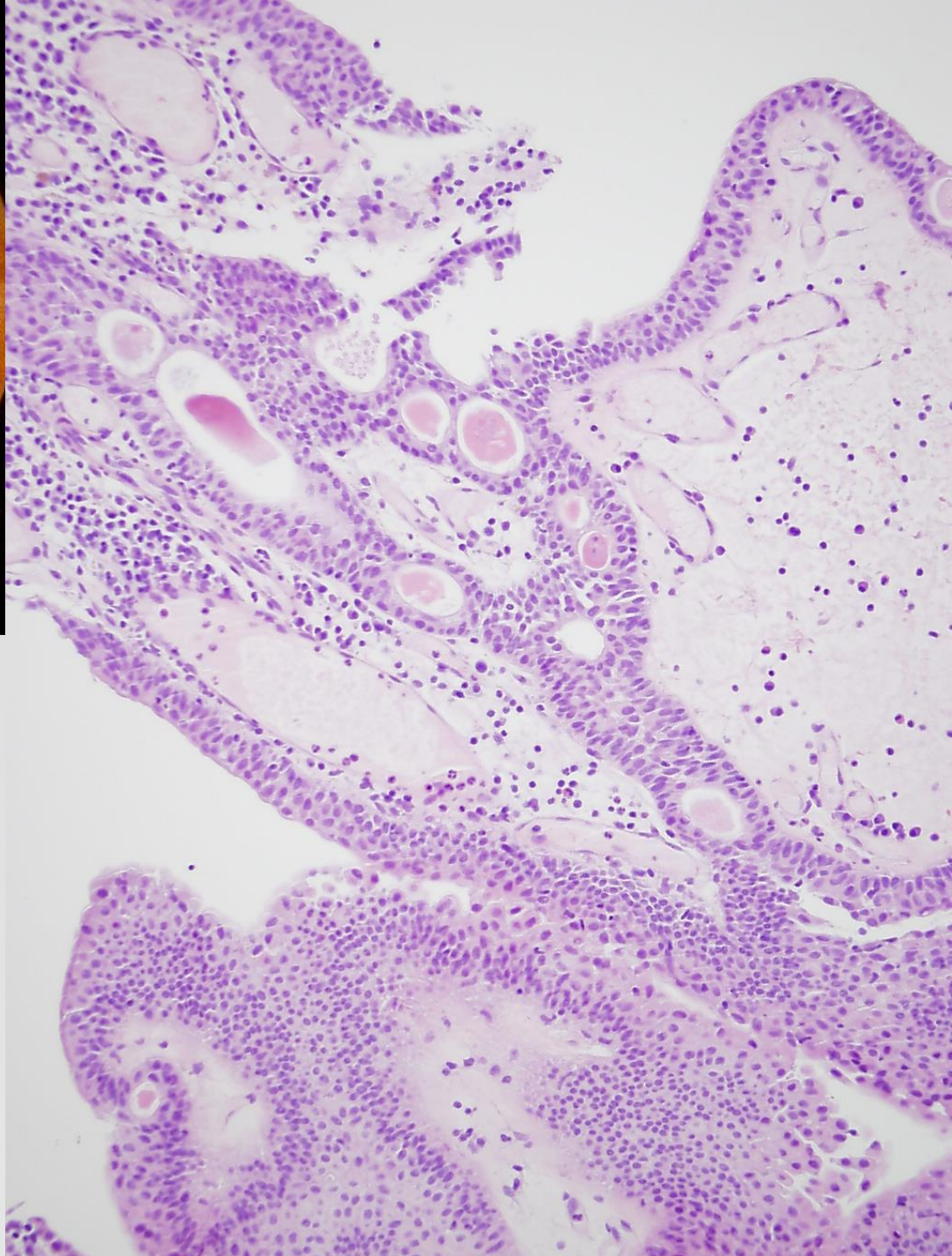
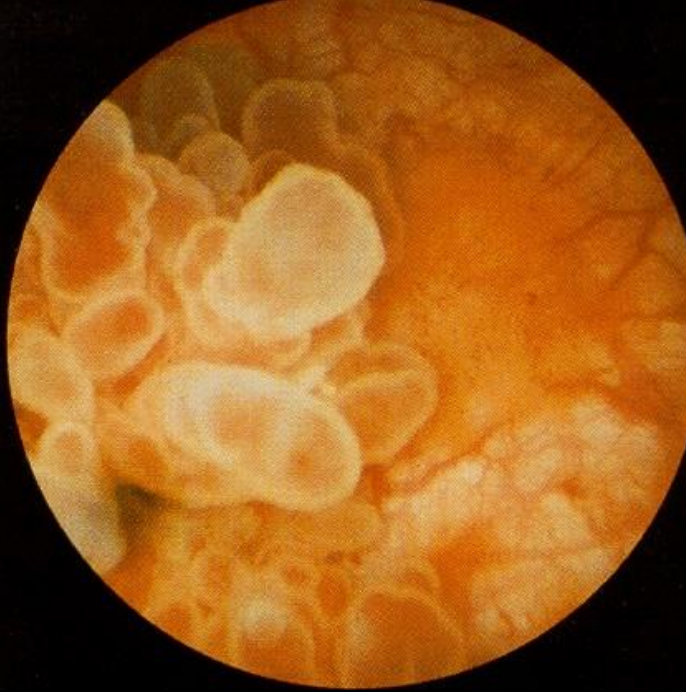

## Cystoscopy

A cystoscope is a flexible tube used to view the structure of the bladder. This procedure is often associated with biopsies. To minimize pain, the procedure is done under local anesthesia.







# Hólyagbetegségek tünetei

Fájdalom, dysuria

Gyakori vizelési inger

Haematuria

Alhasi fájdalom

Diagnosztikus lehetőségek:

Labor vizsgálat + cytológia

Tenyésztés

...gráfia

Cystoscopia

TUR

**Cystoscopia:** nyhártyán  
vörös foltok, bedomborodó  
lapos/papilláris idegenszövet,  
merev hólyagfal

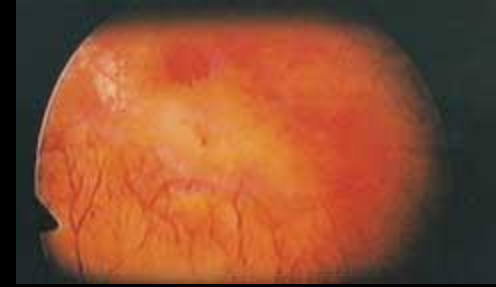# Cystititsek

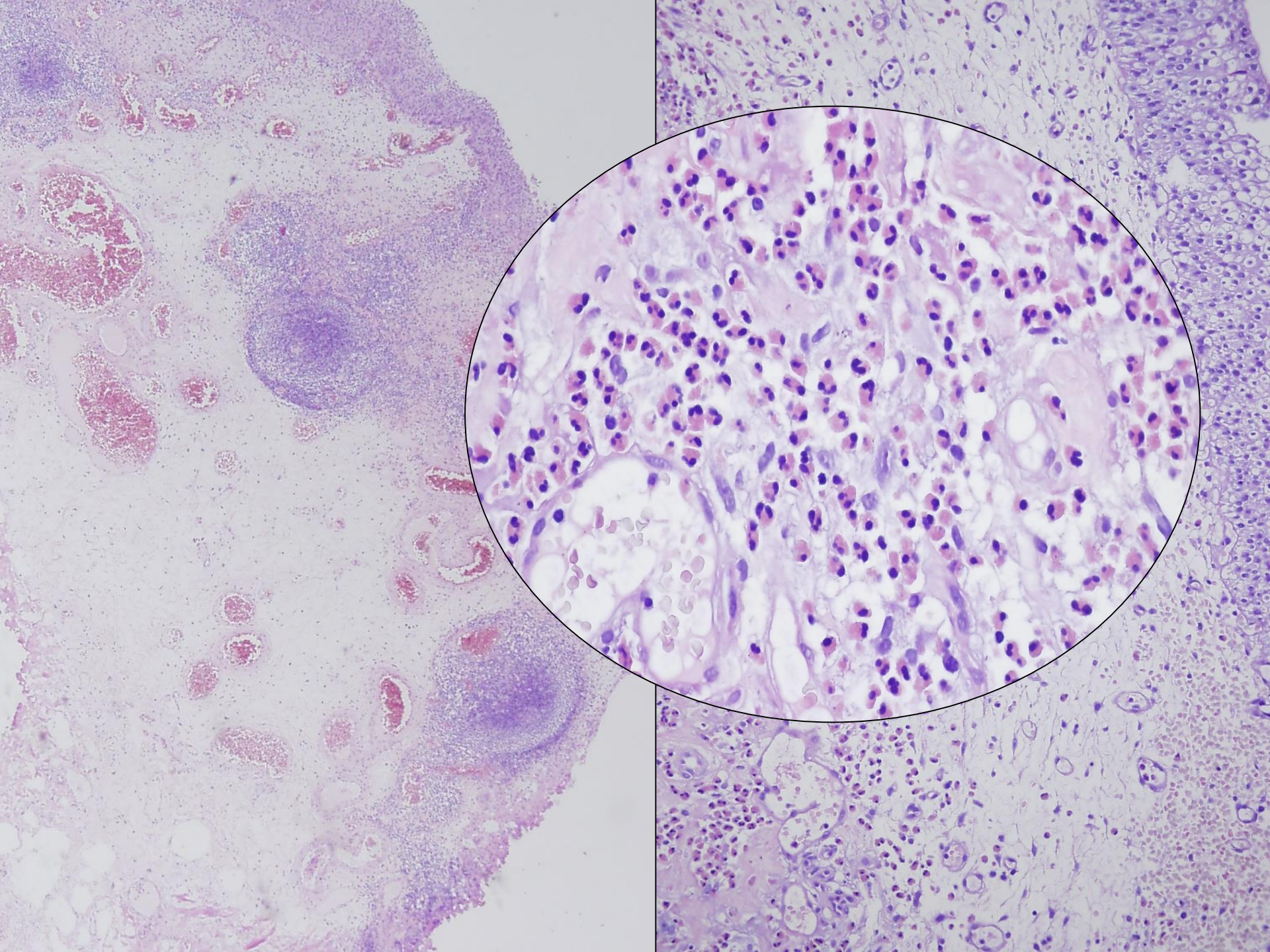
## Acut

- E. coli,
- Klebsiella,
- Proteus,
- Enterobacter,
- TBC (this)
- Candida
- Chlamydia
- Mycoplasma

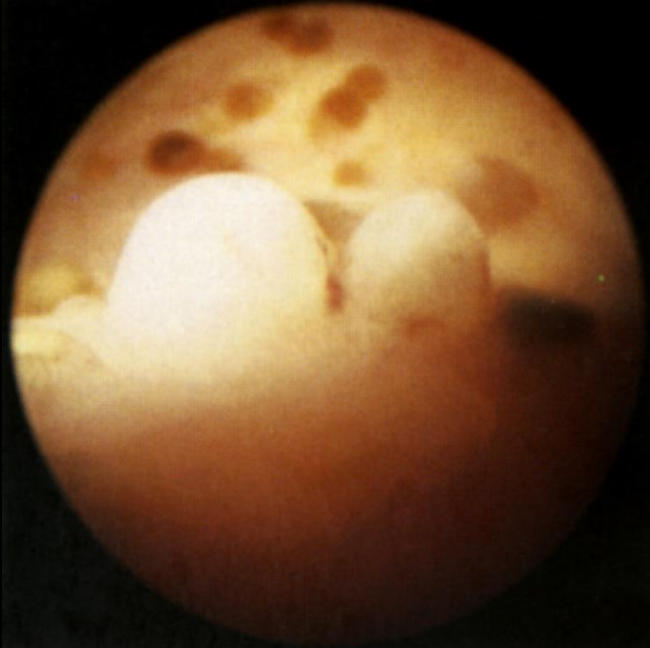## Chronicus

- Eosinophil
- Hunner  
(Interstitialis)
- Folliculáris
- Cystitis cystica
- Cystitis glanduláris
- Malakoplakia

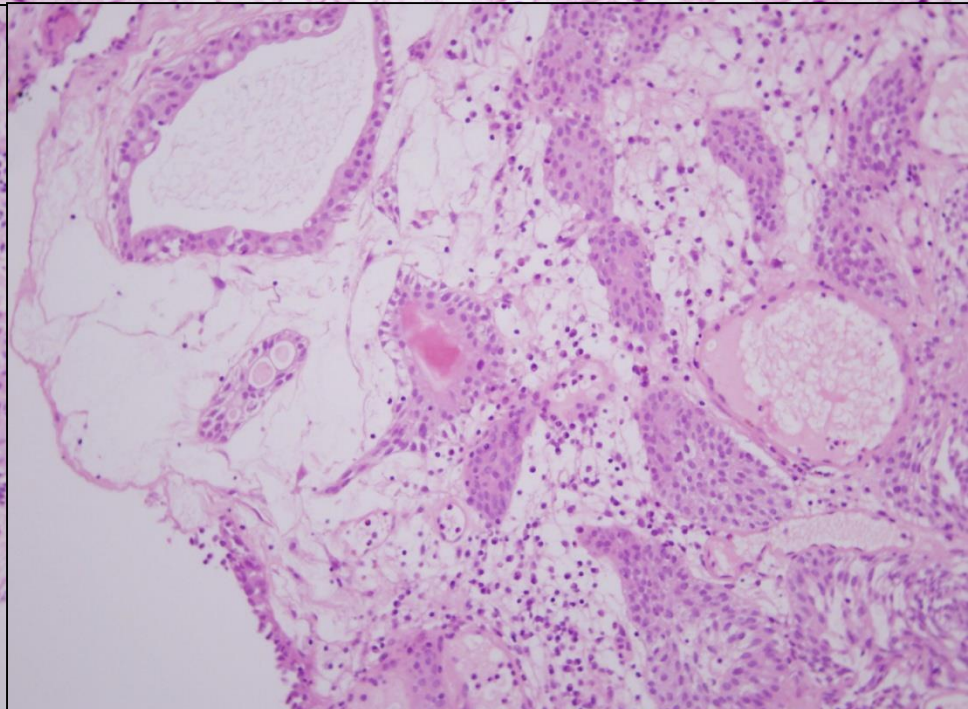
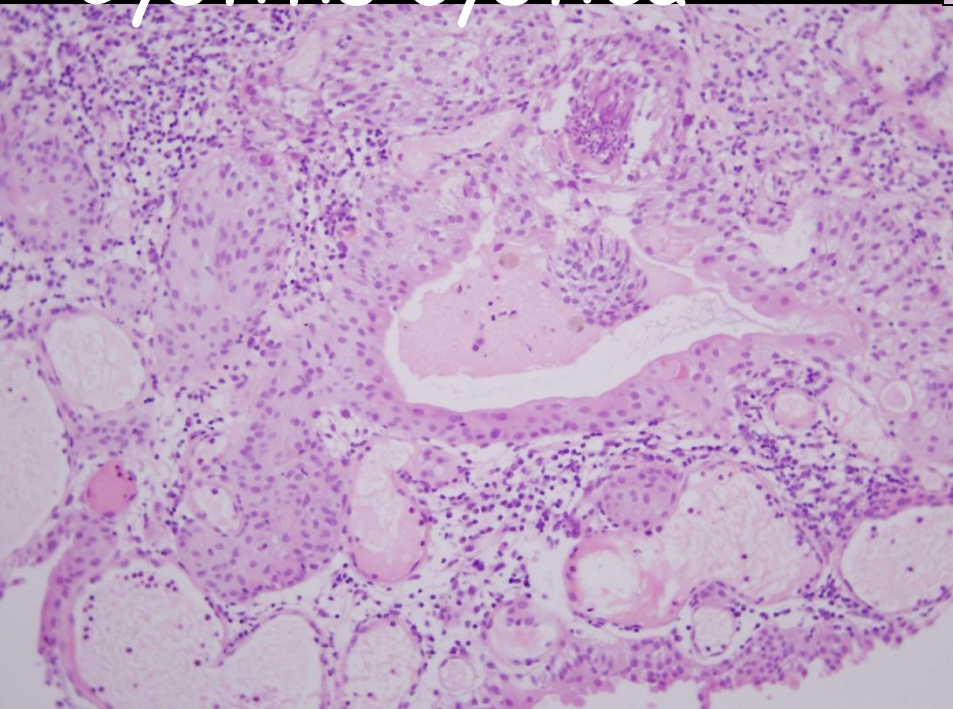
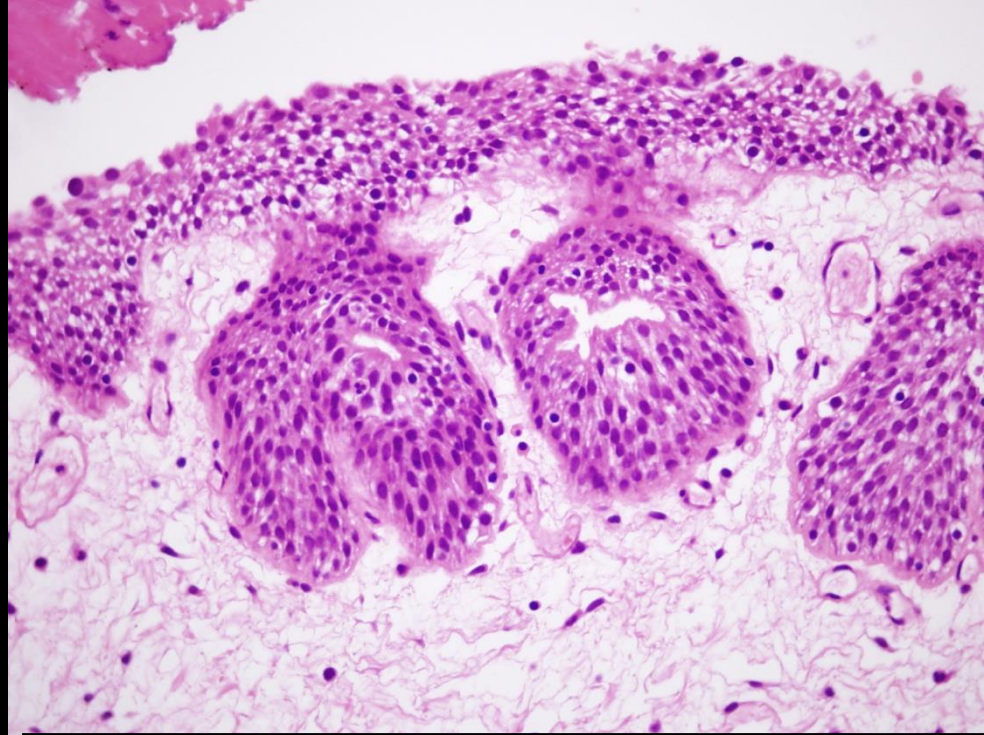


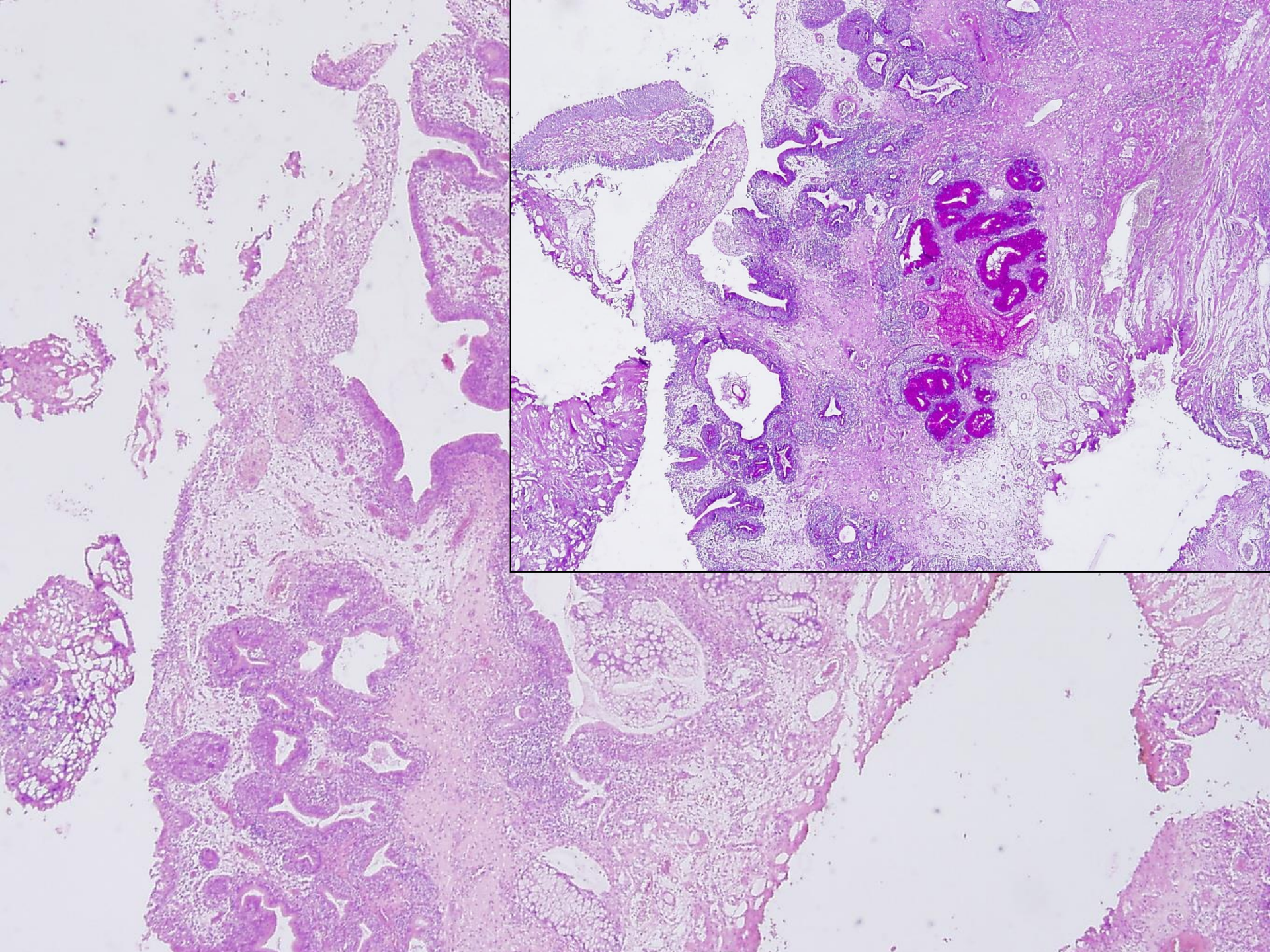


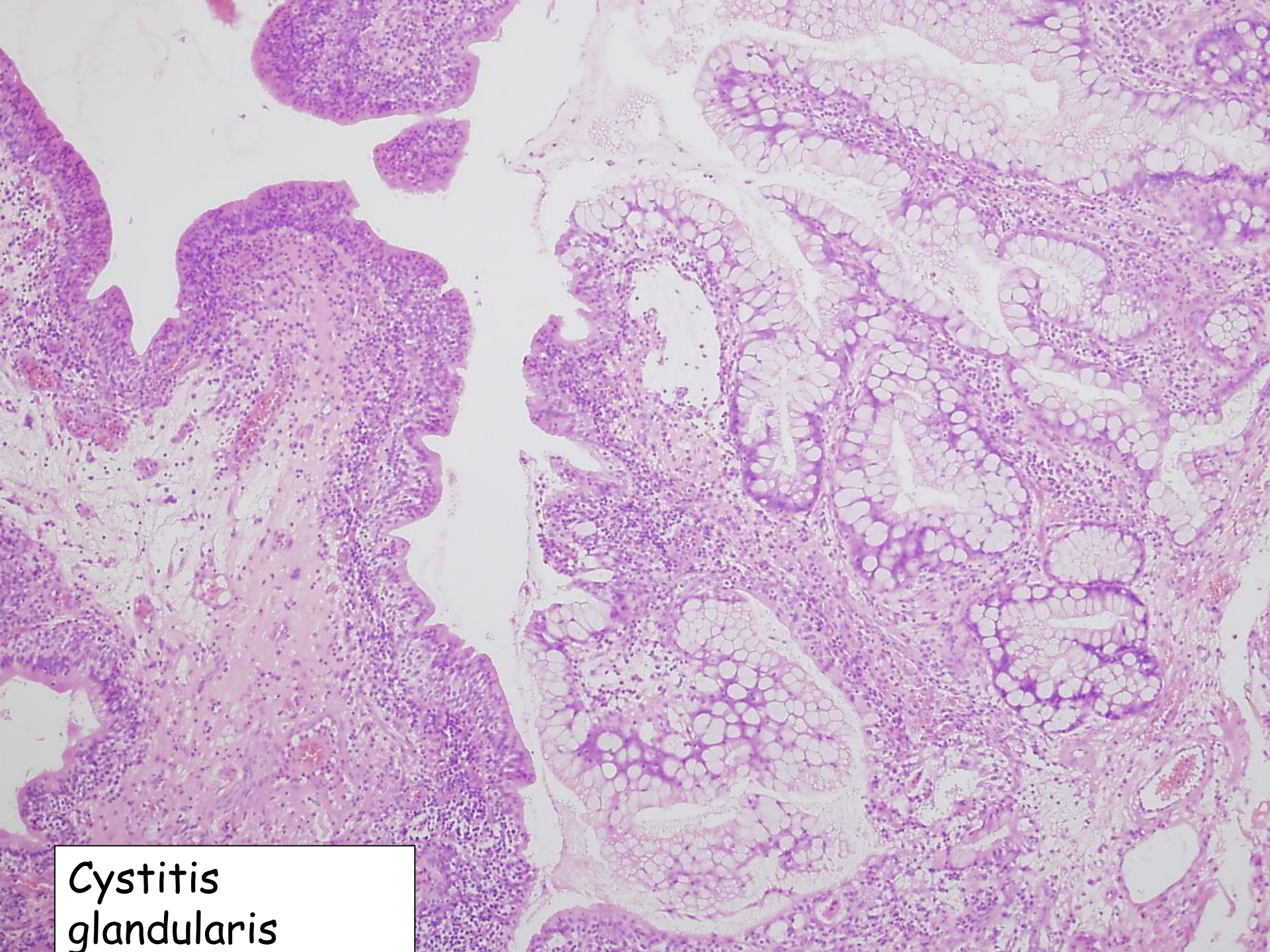




*Cystitis cystica*

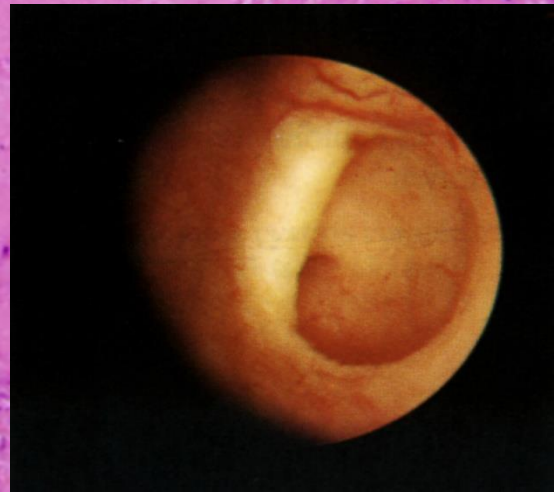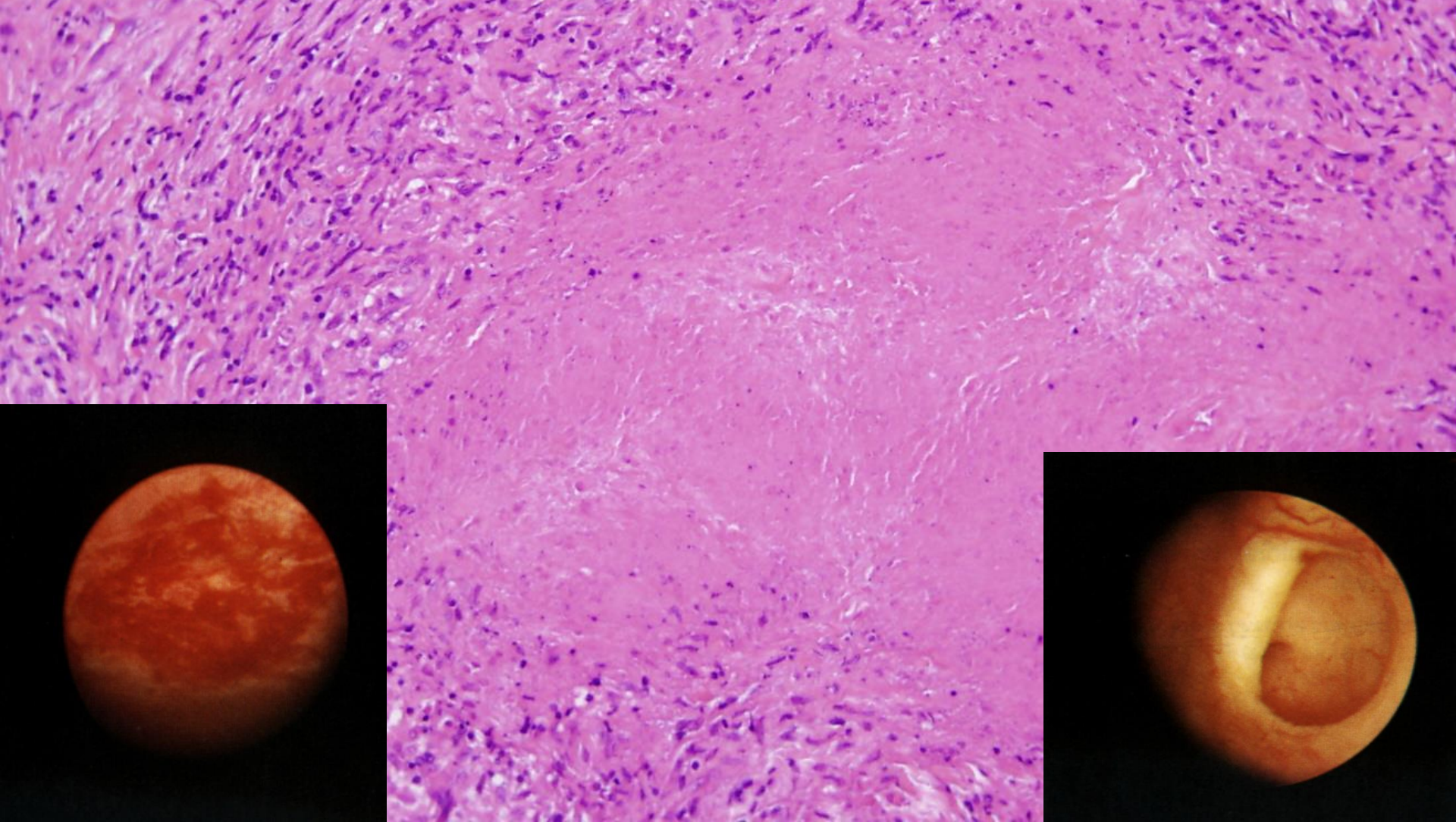
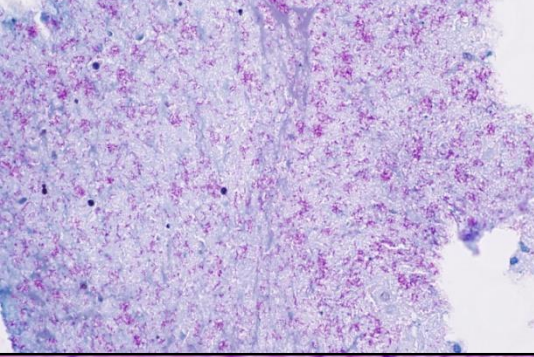






Cystitis glandularis

# Cystitis tuberculosa



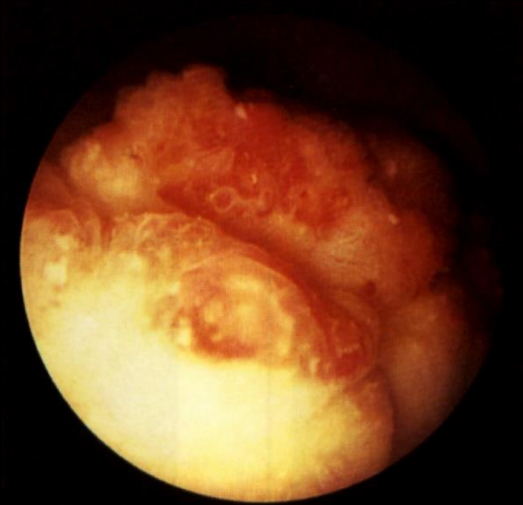# 43 éves férfi

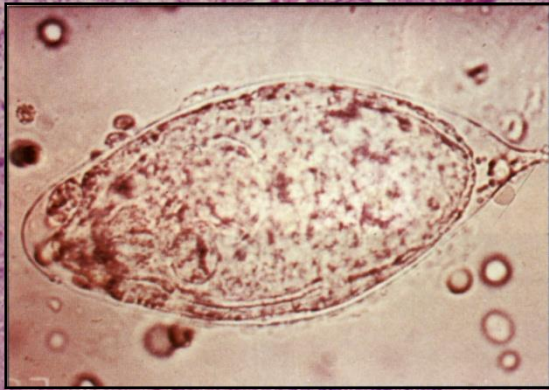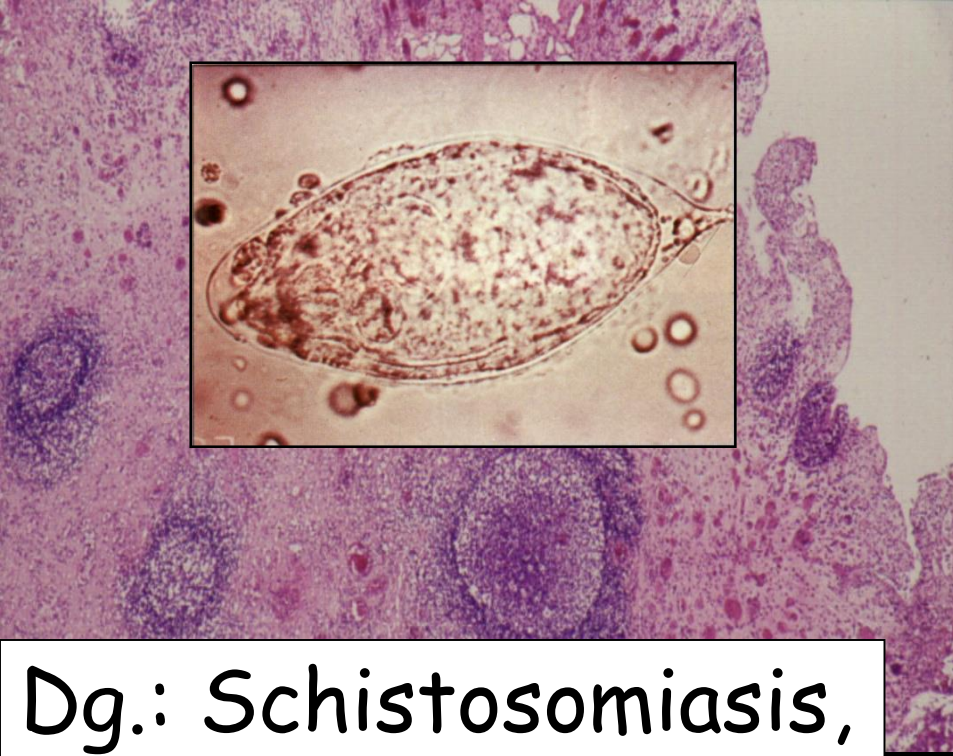
Haematuria

Cystoscoppal

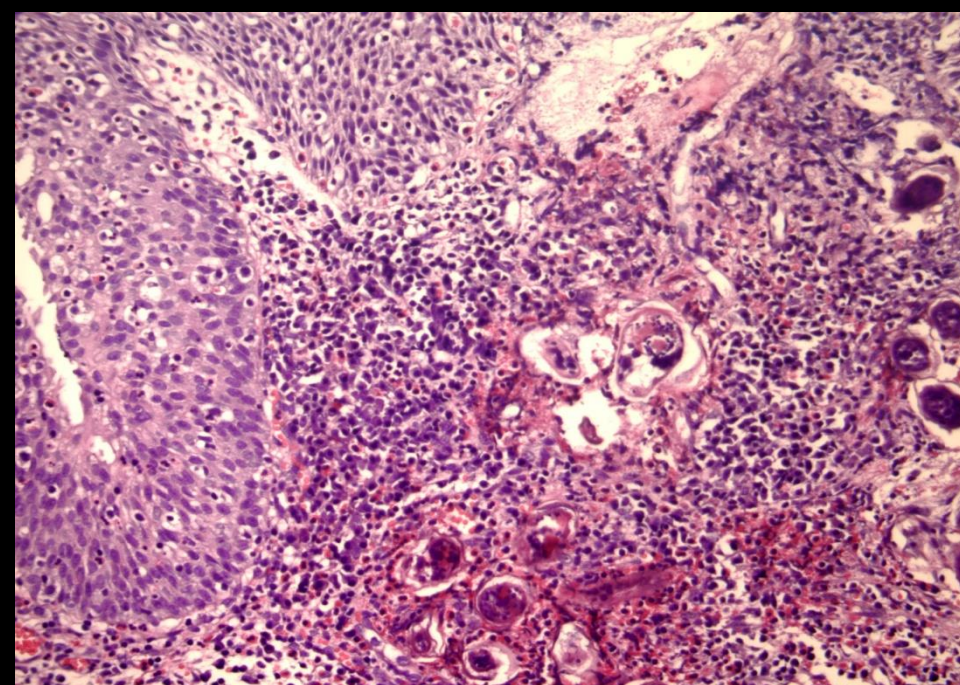
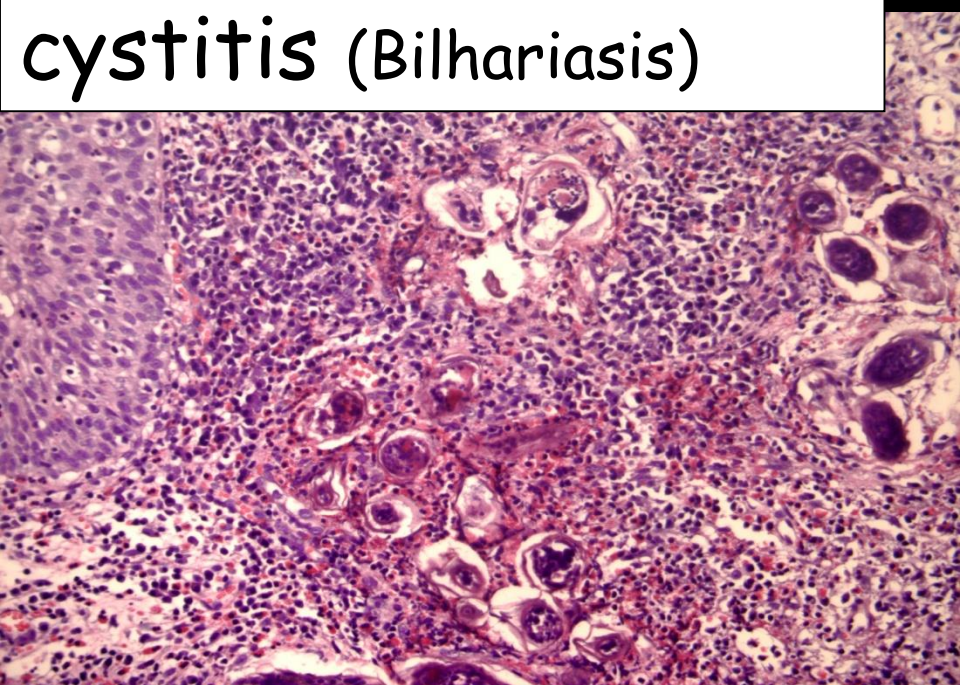
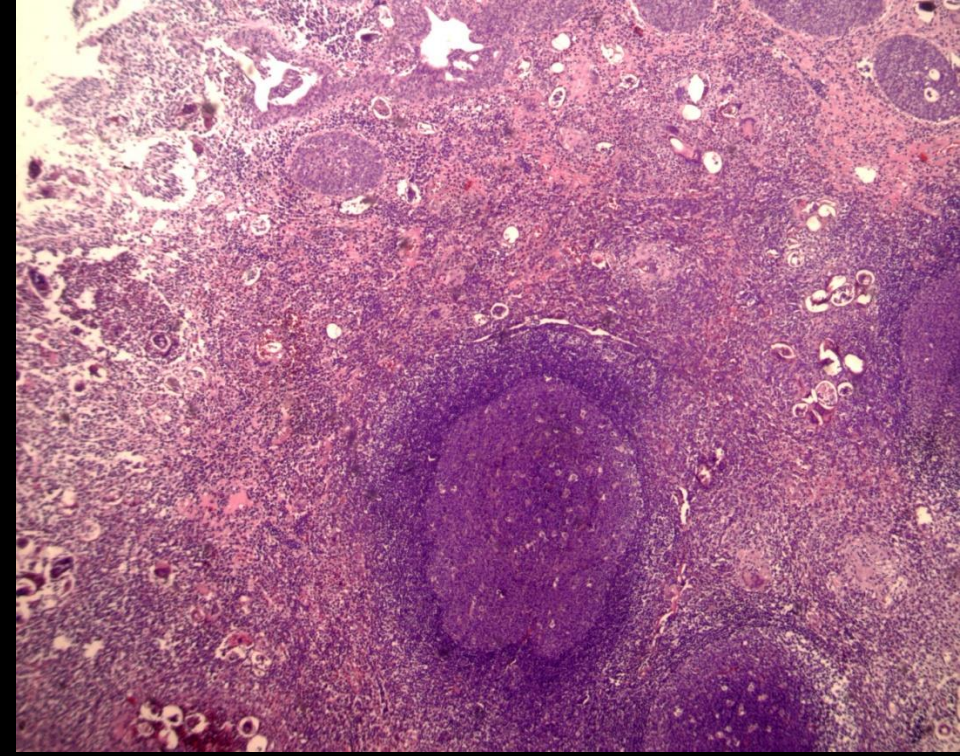
Vérzékeny, polypoid  
elváltozás .

UCC?





Dg.: Schistosomiasis,  
cystitis (Bilharziasis)

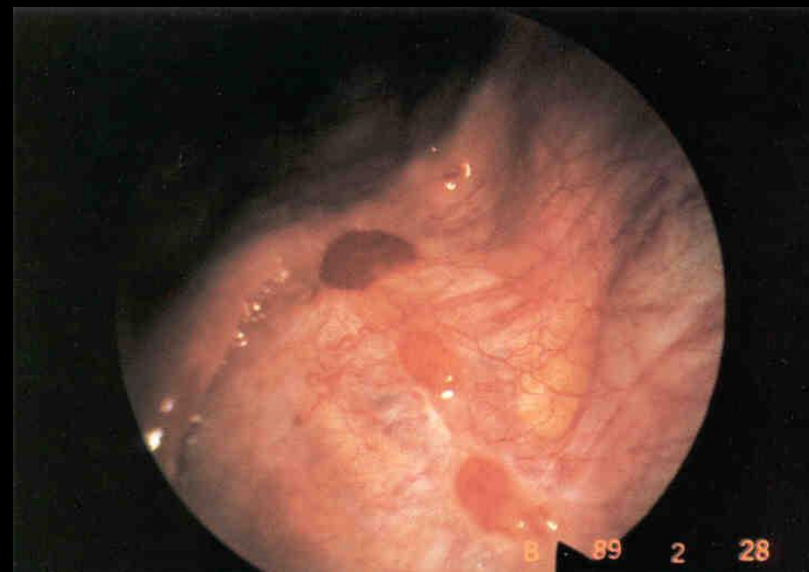
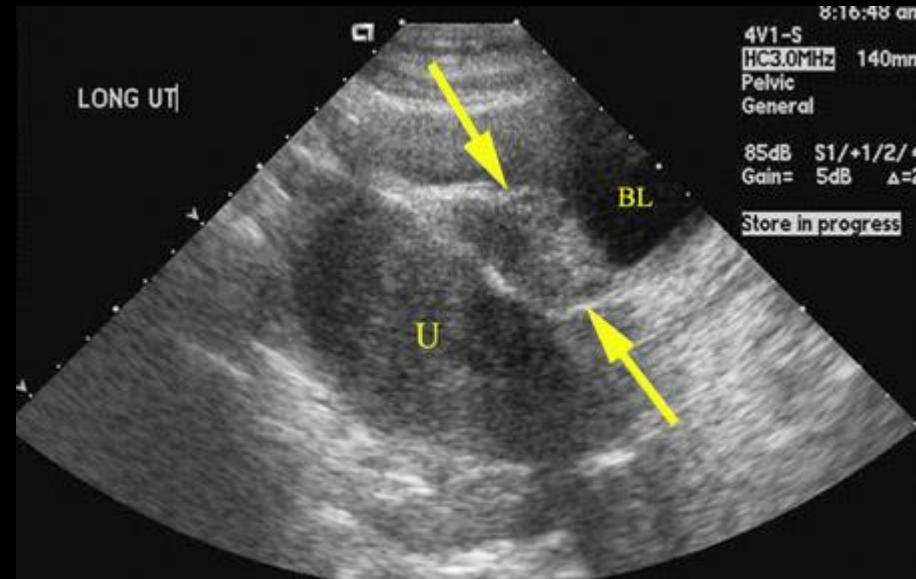


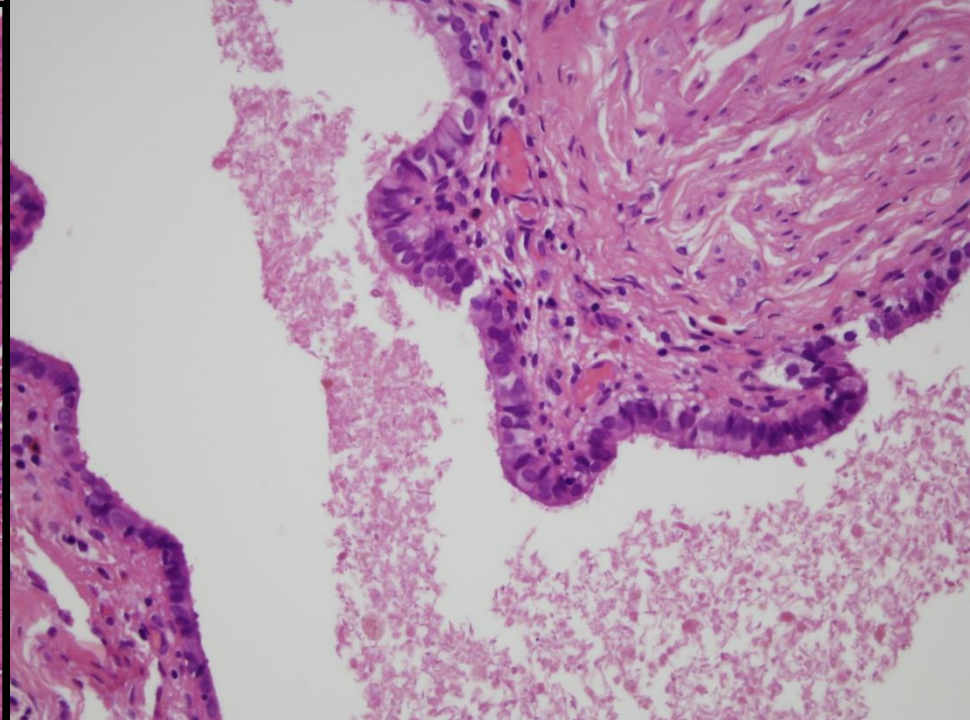
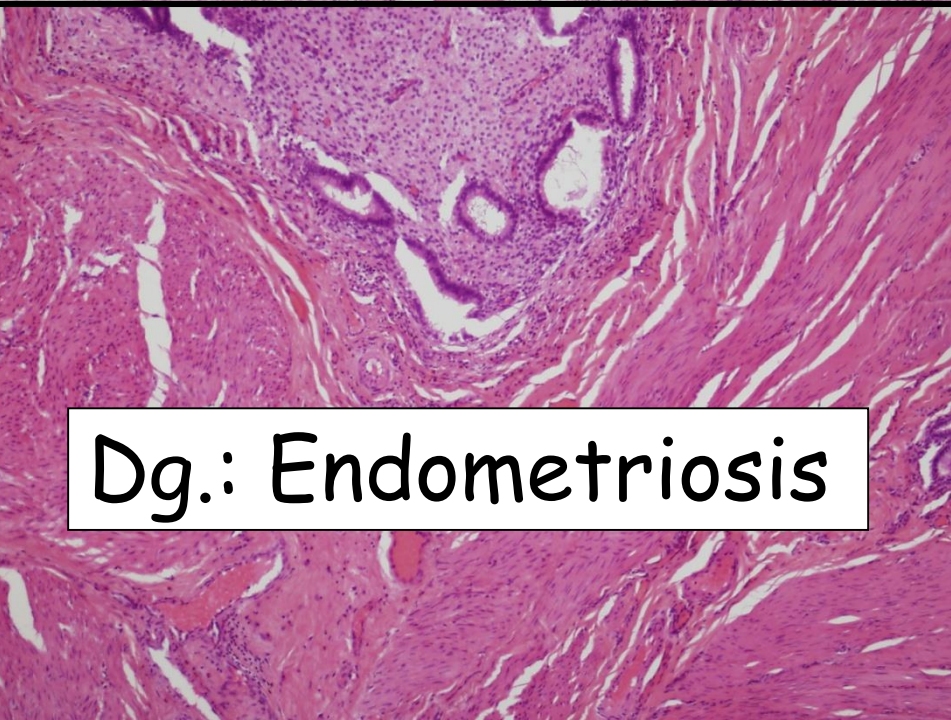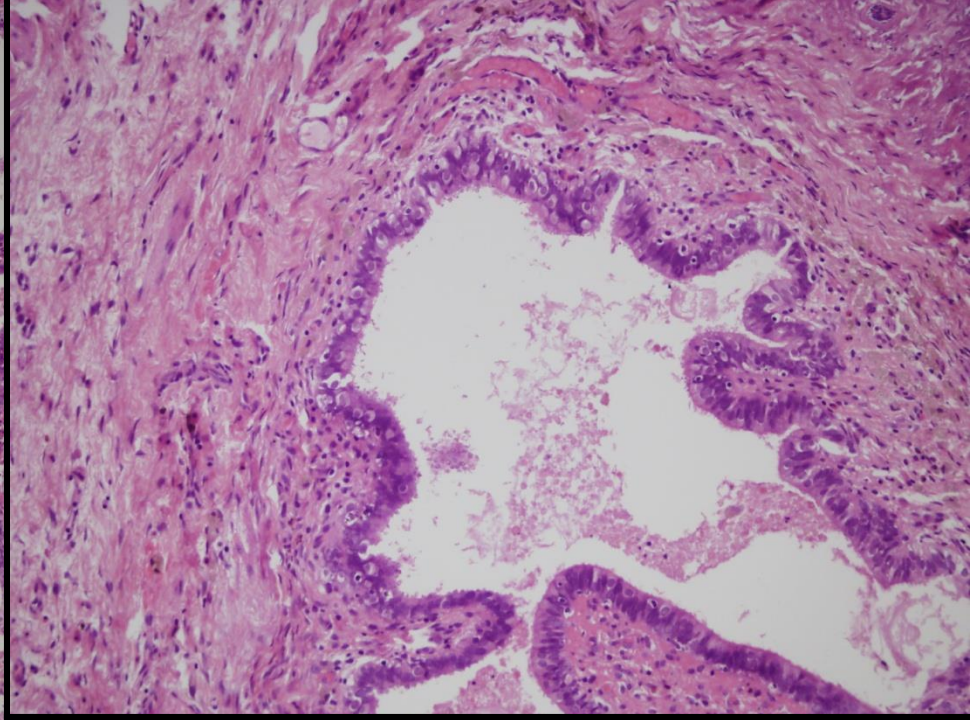
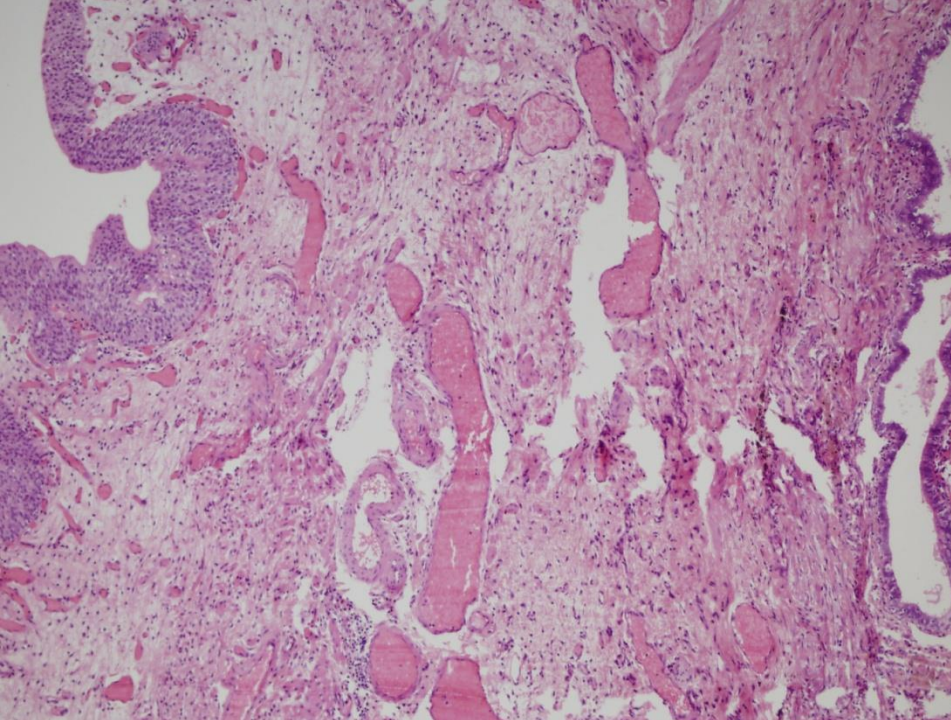
# 32 éves nő

Haematuria

Kis vörös foltok a  
hólyag  
nyálkahártyán

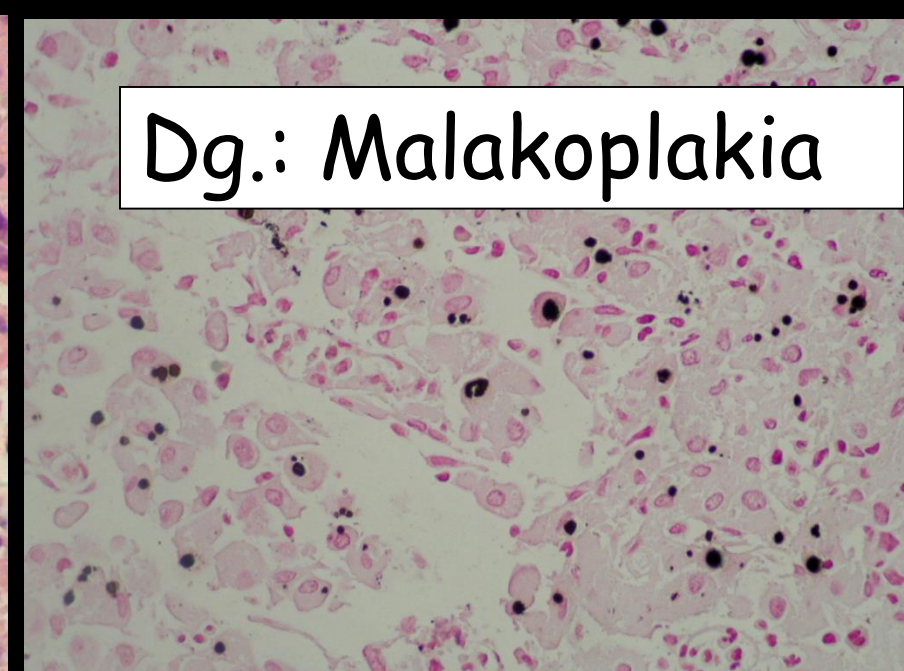
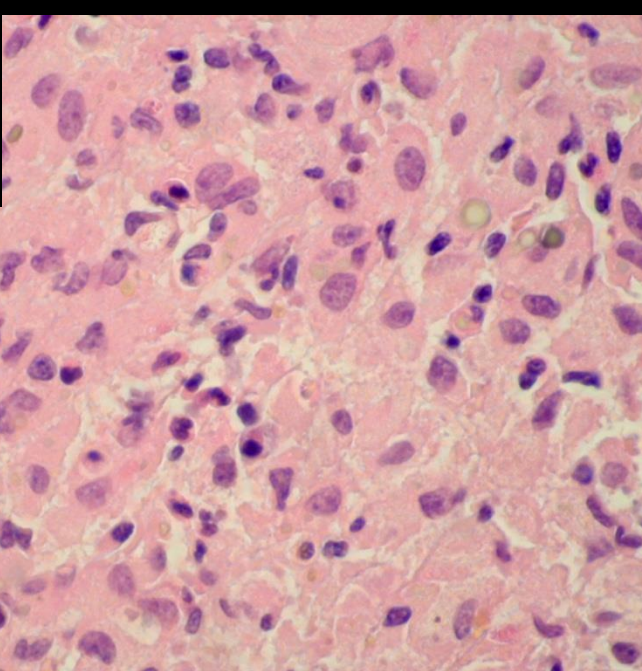
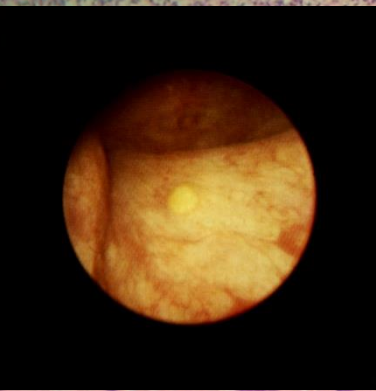
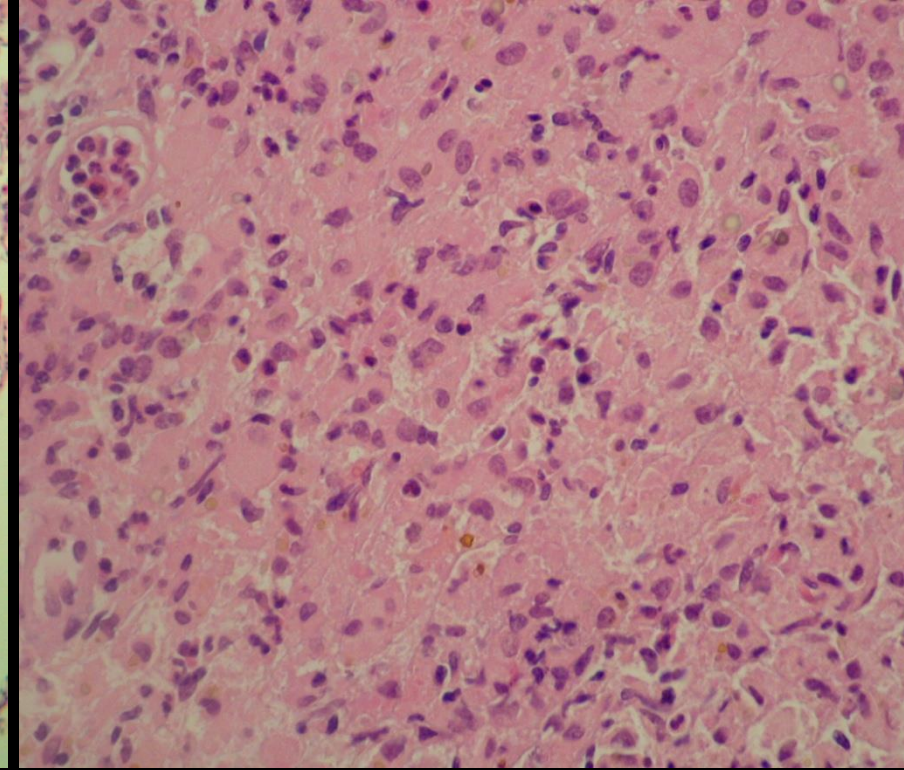
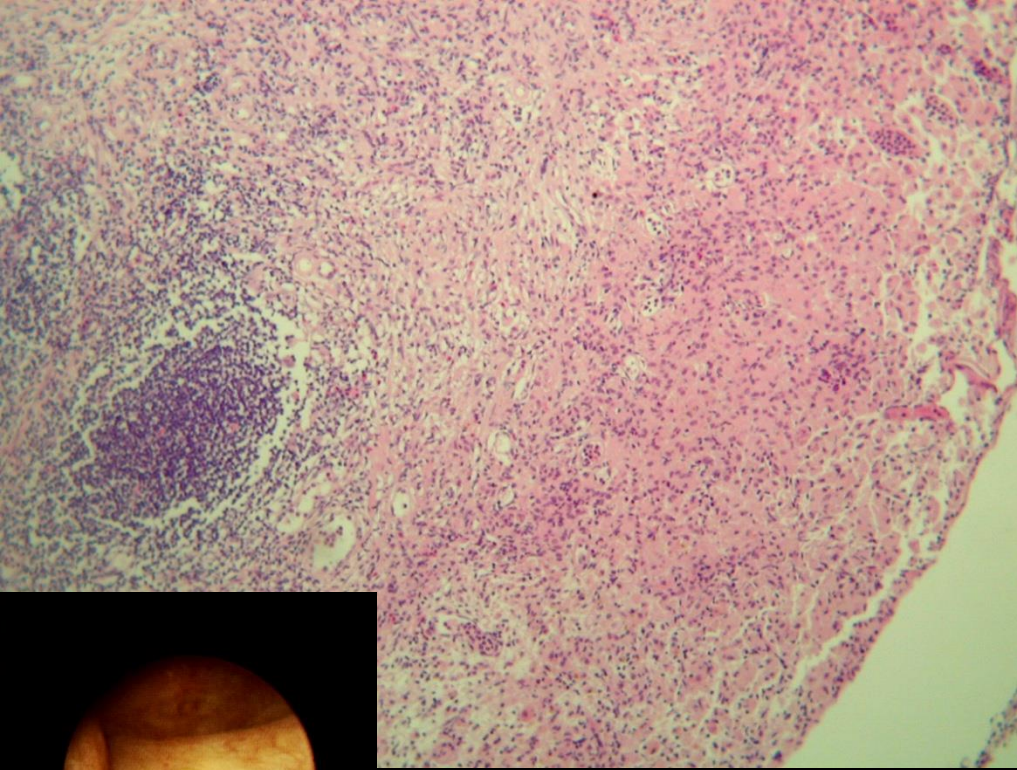
.....??





Dg.: Endometriosis





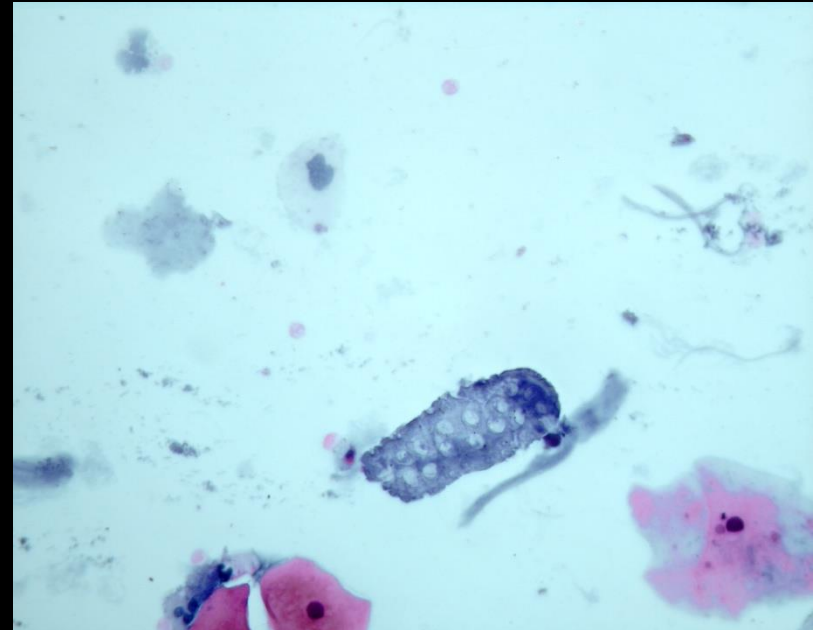Dg.: Malakoplakia

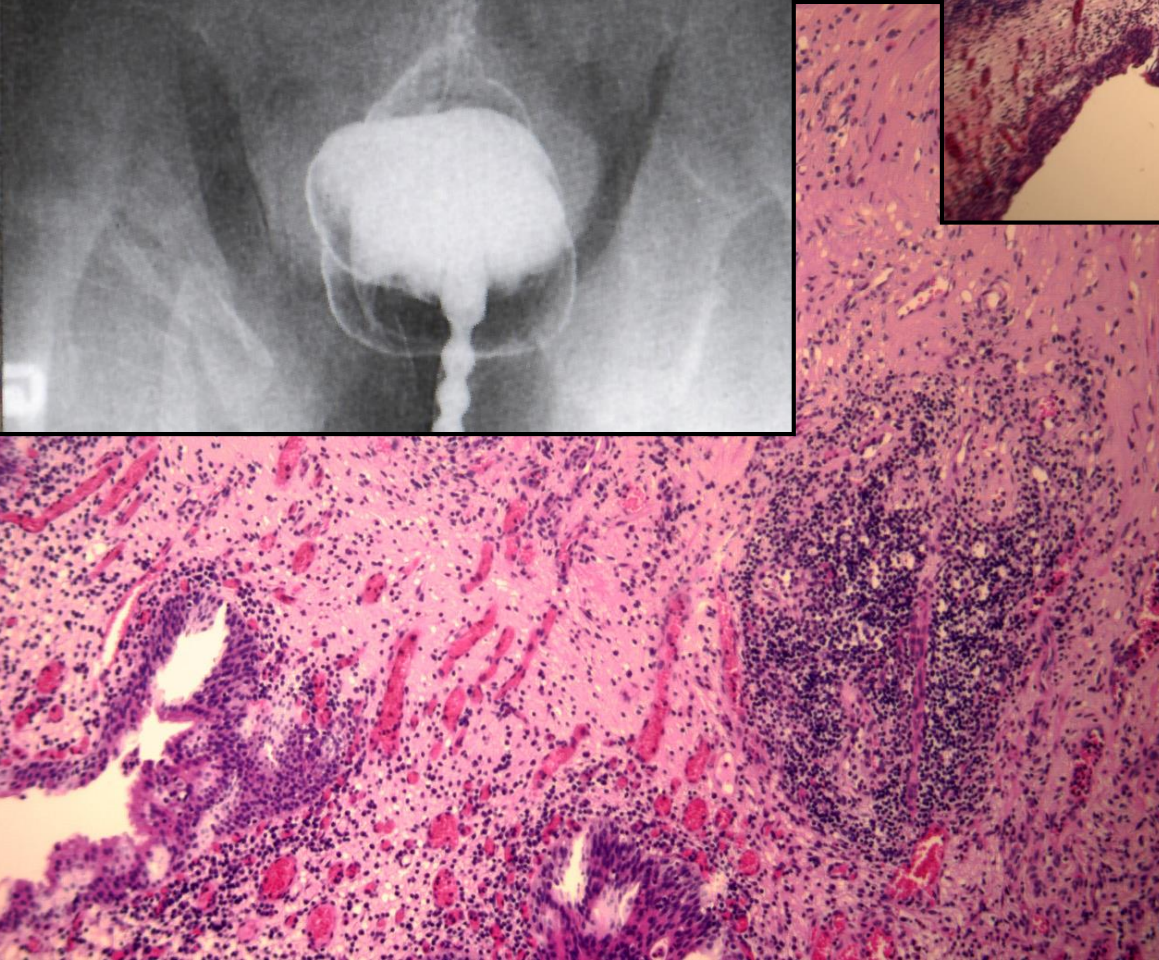
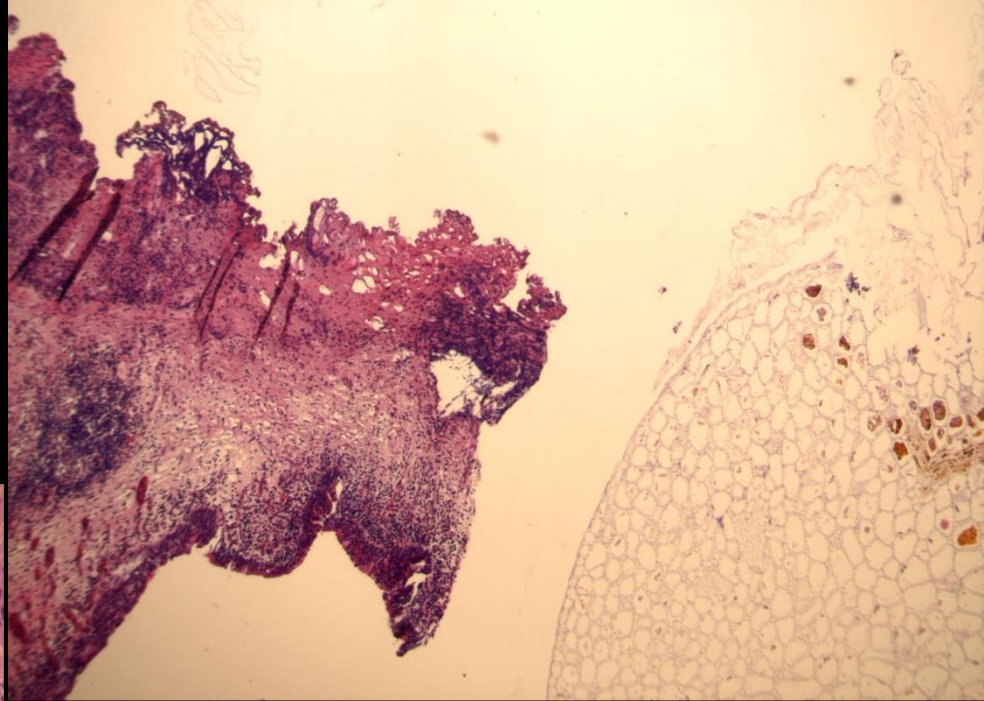
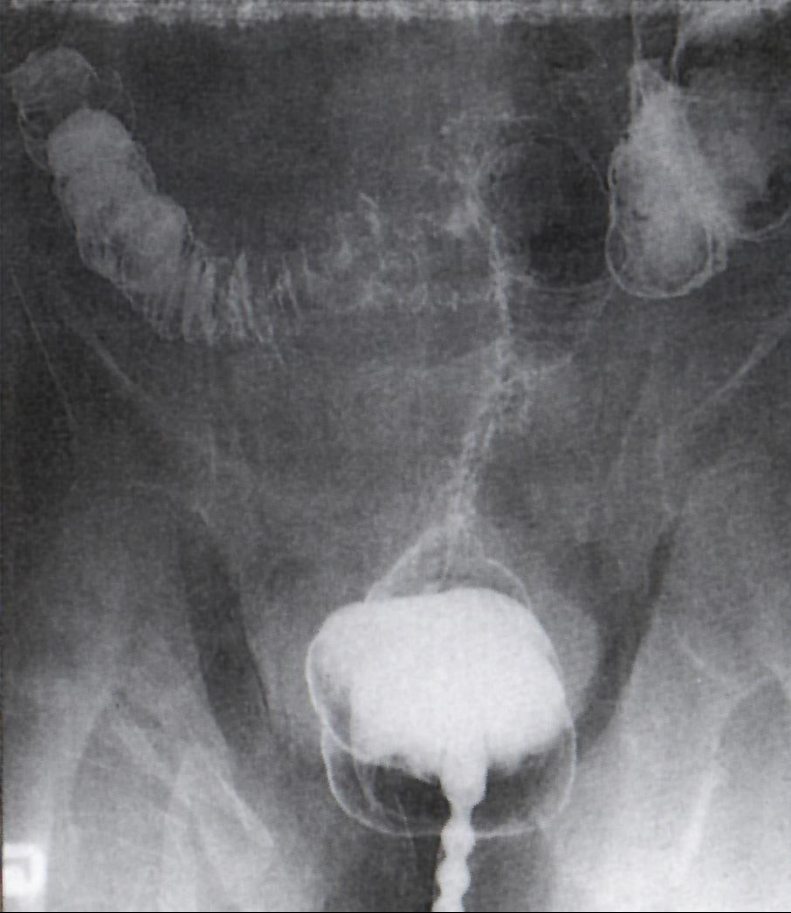# 29 éves férfi

Haematuria

Vastag, merev  
hólyagfal

Tumor?





Dg.: cystitis,  
fistula alapos  
gyanúja

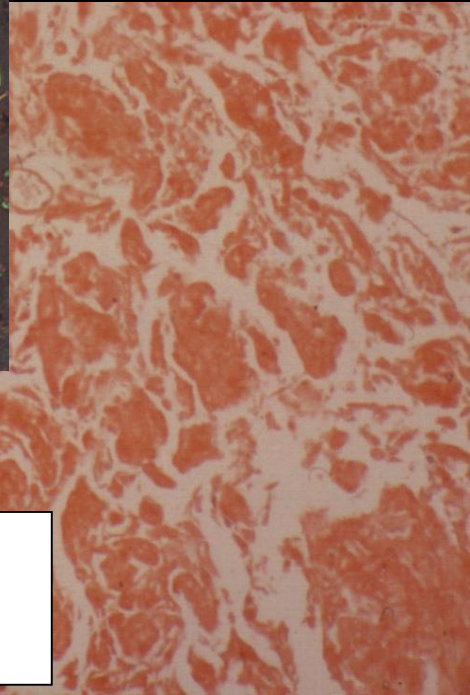
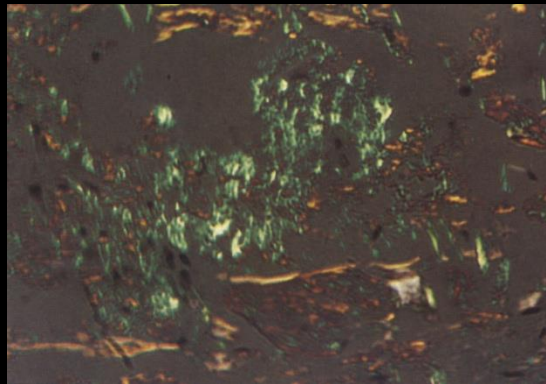
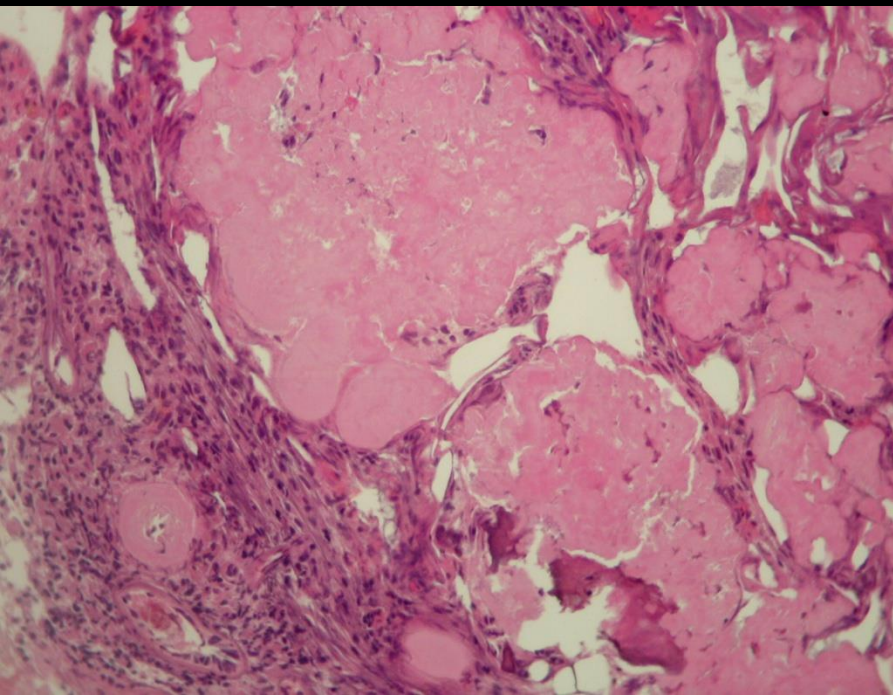
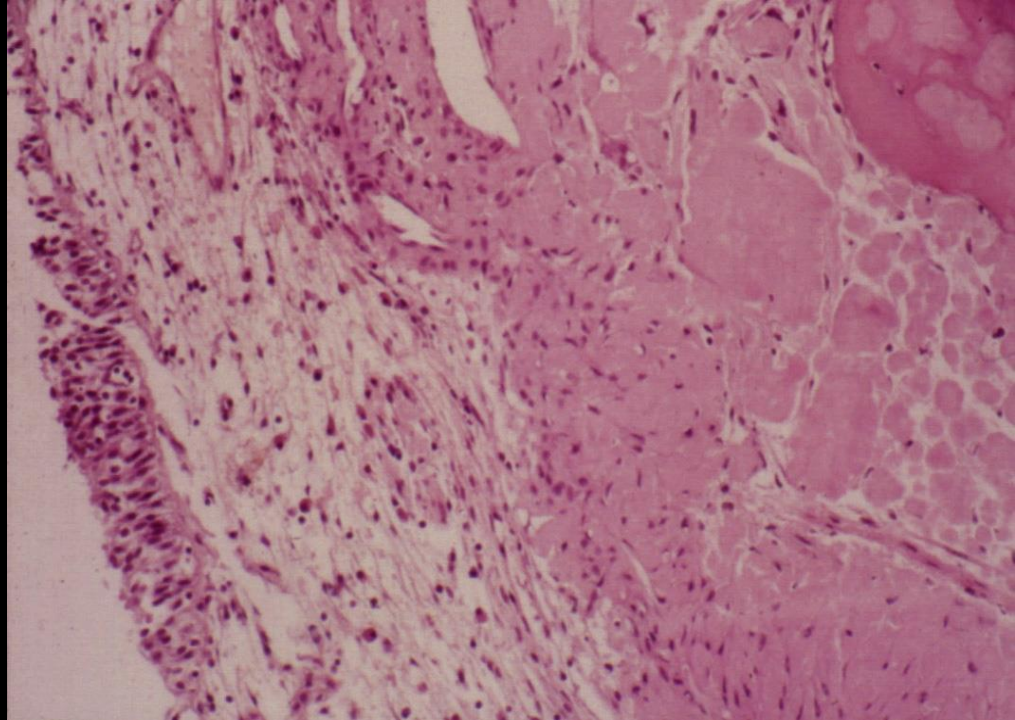
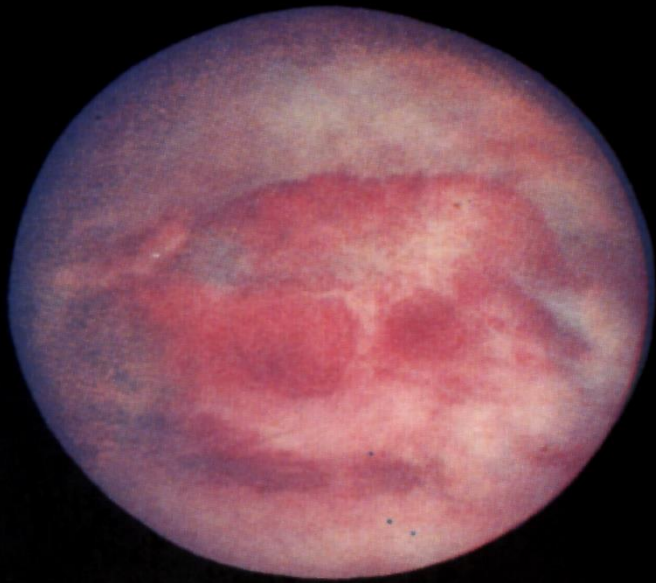
Morbus Crohn

# 43 éves nő

Dysuria miatt végzett cystoscopia

Cystoscoppal lumenbe domborodó, sima felszínű fali elváltozás

Papilloma? Papill. Cc.?



Dg.: hólyag  
amyloidosis

# Hólyagdaganatok

Benignus

Malignus

UCC (TCC)

Papilloma

Invert papilloma

- papilláris  
- CIS

Mesenchymalis

Adenoccc

Laphámcc

Sarcoma

Lymphoma

Metastaticus

„Ráterjedés”

# Hólyagdaganatok

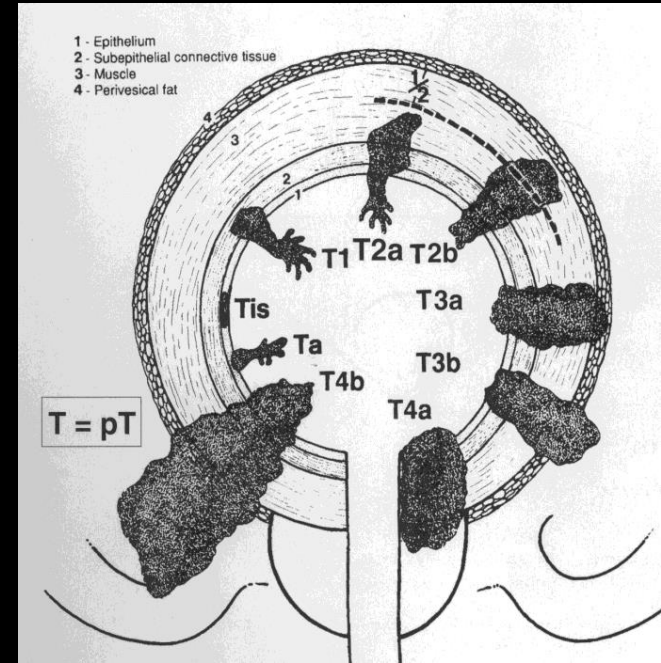
Malignus

UCC

-papilláris



- CIS



# Malignus Hólyagdaganatok - etiológia

## Dohányzás

Arylamine, 2-naphthylamine

Schistosomiasis

Analgeticumok

Cyclophosphamid

Radiatio károsodás

## *Chromosoma eltérések*

9p,9q deletio (felszínes papilláris, ritkábban lapos)

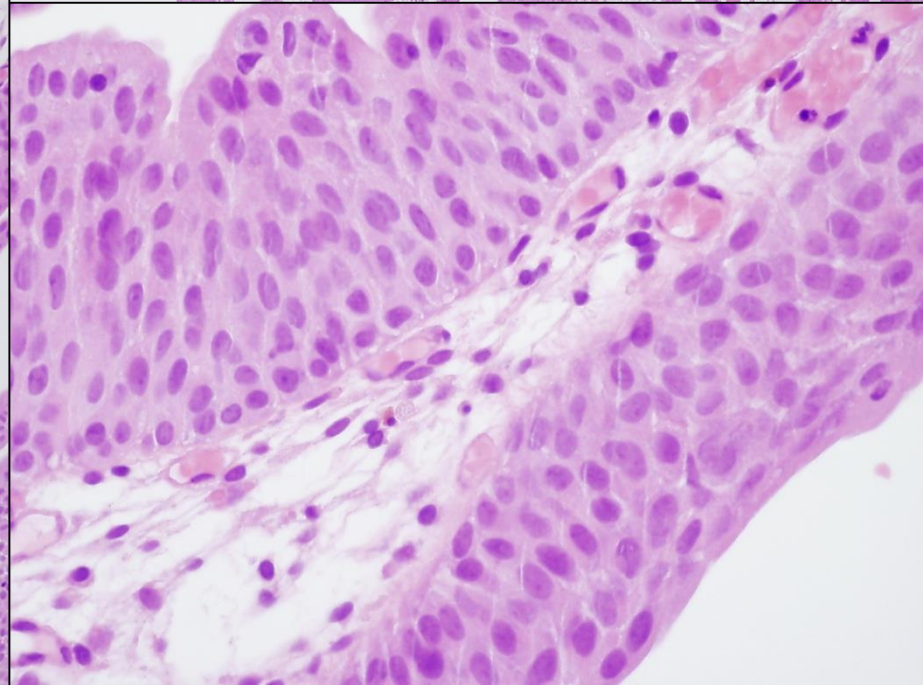
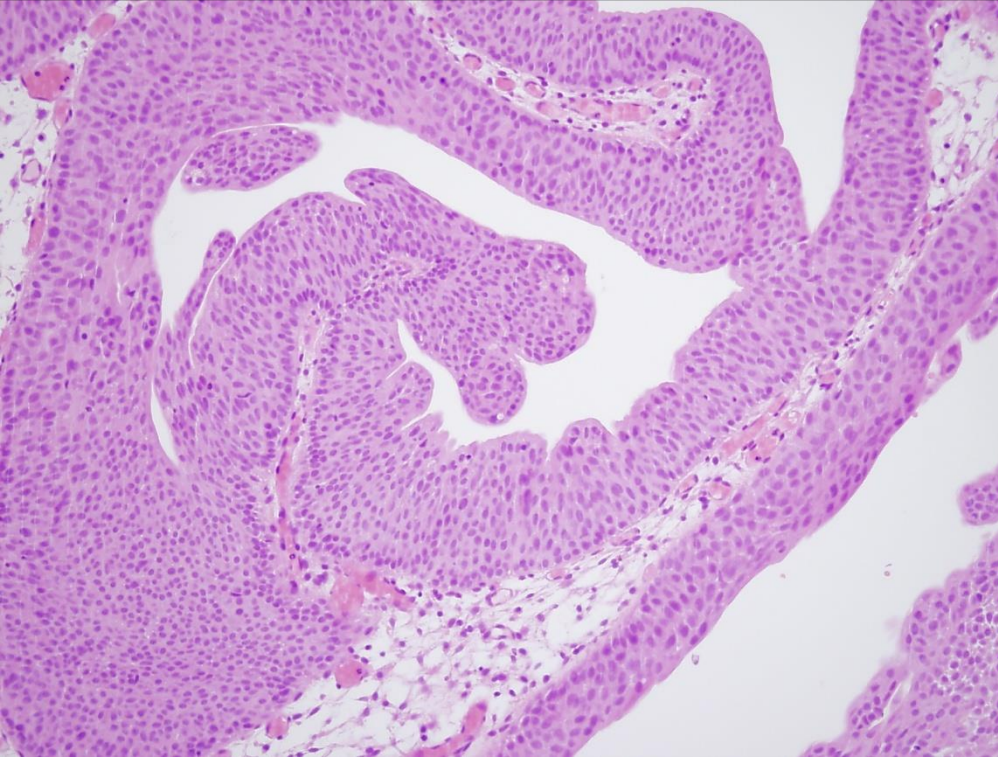
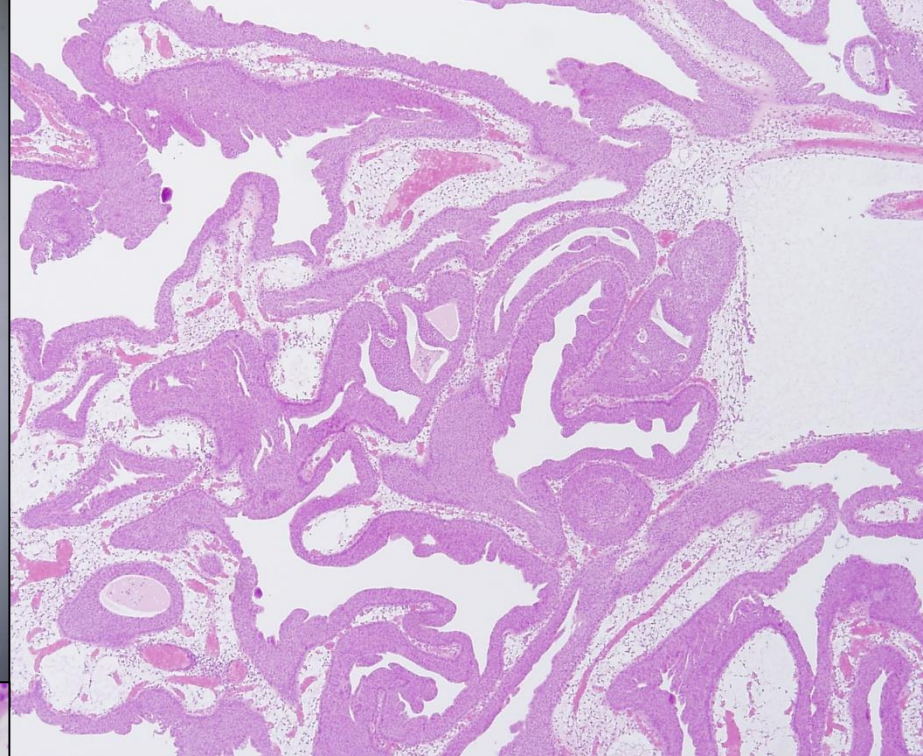
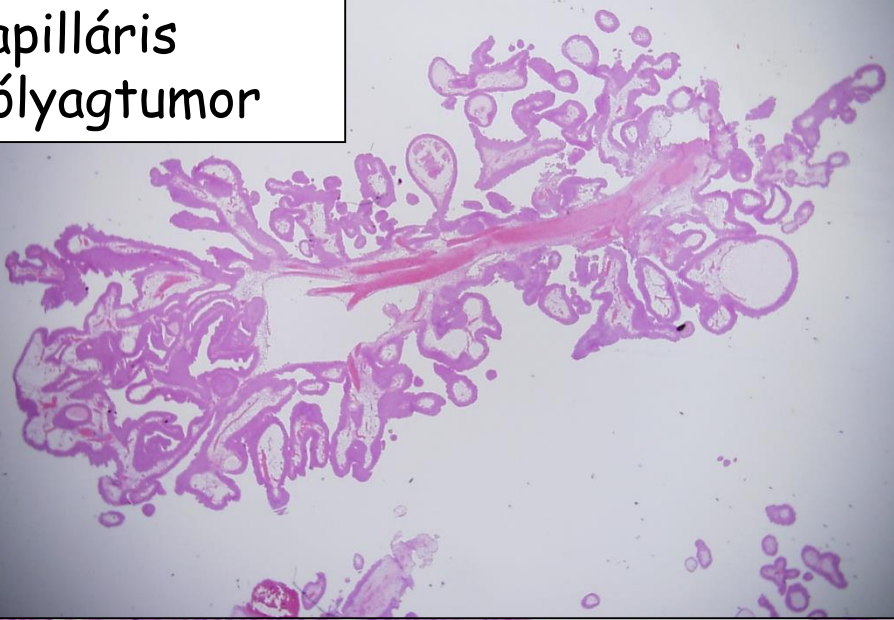
9 monosomia,

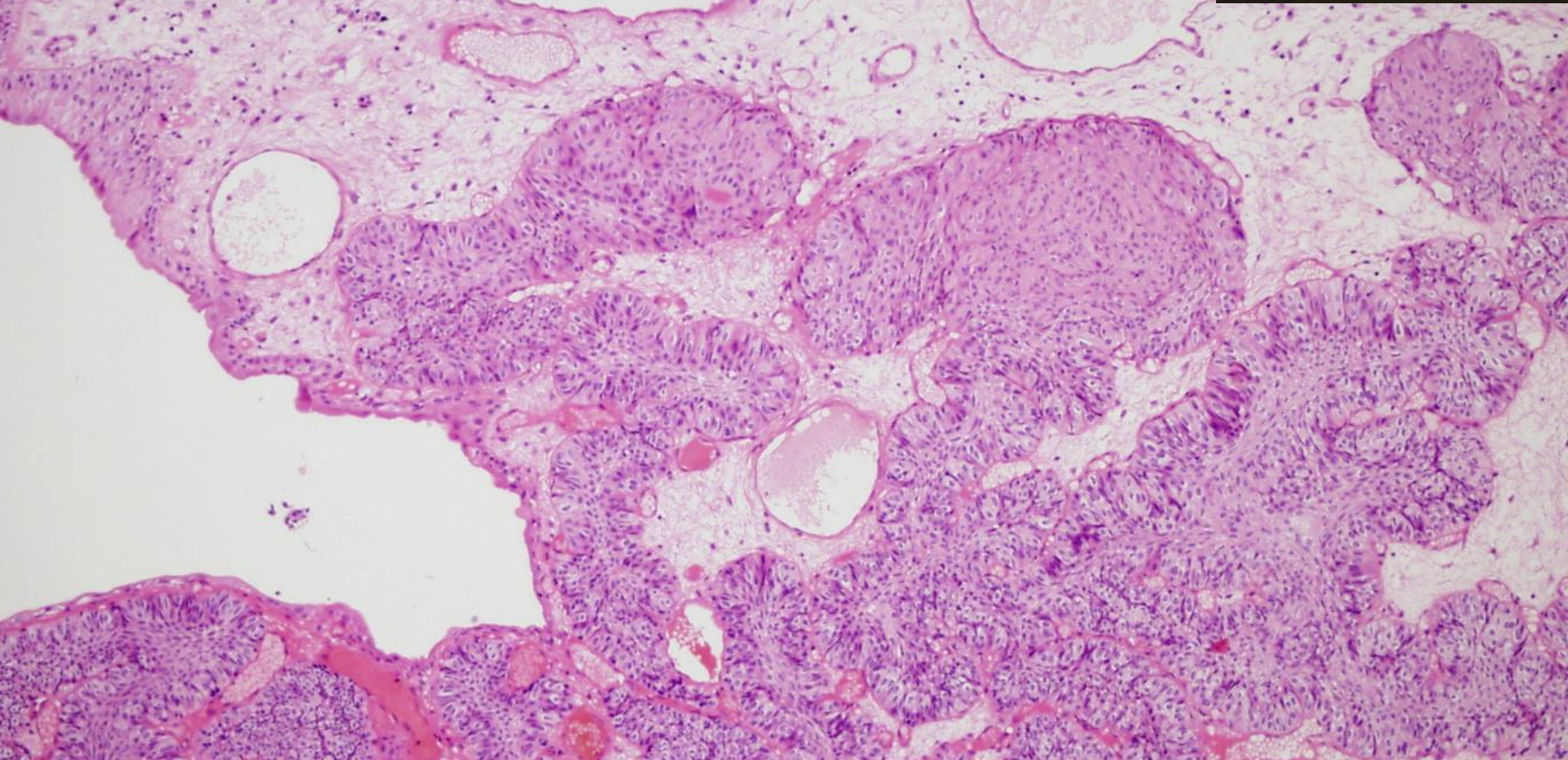
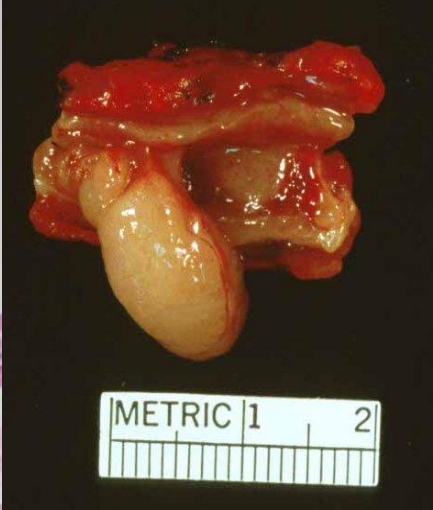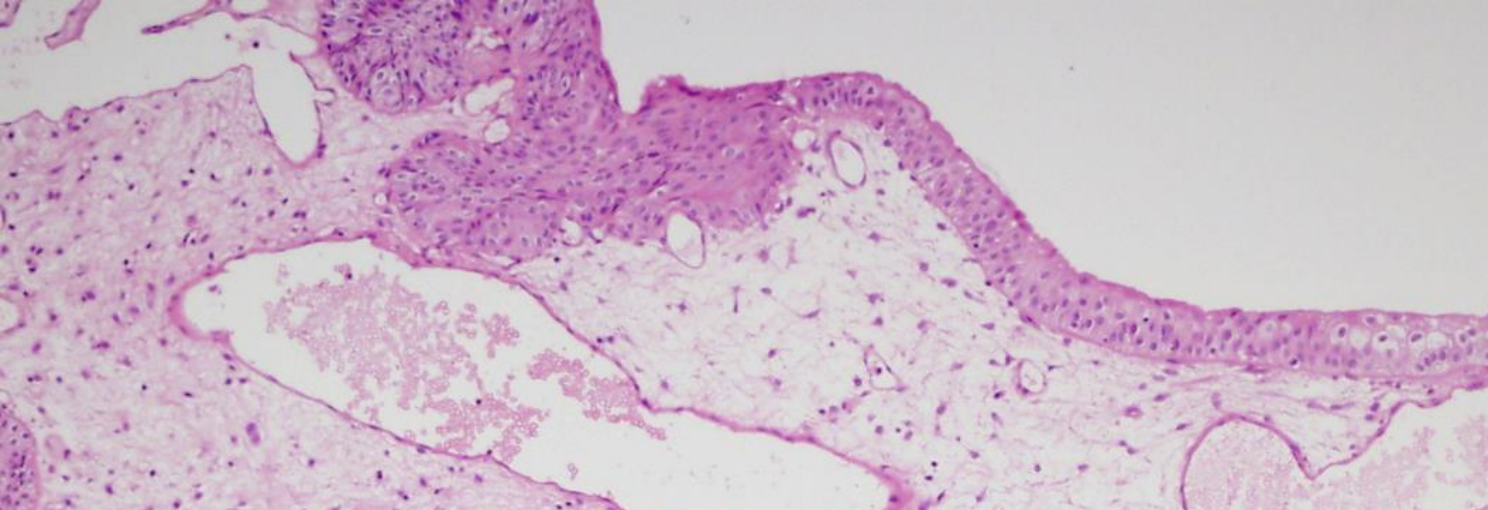
17p deletio (p53)

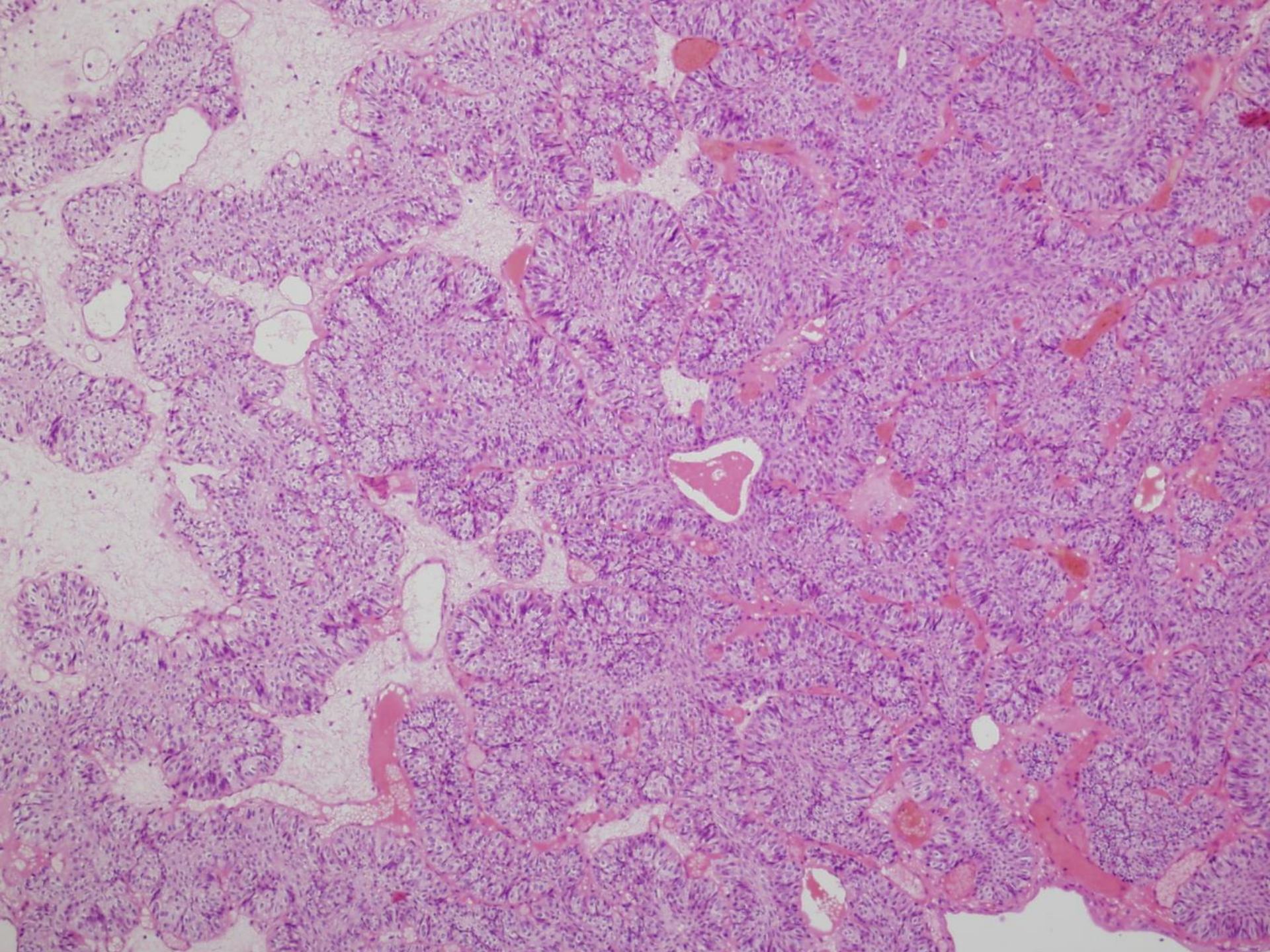
13q, 11p,14q deletio

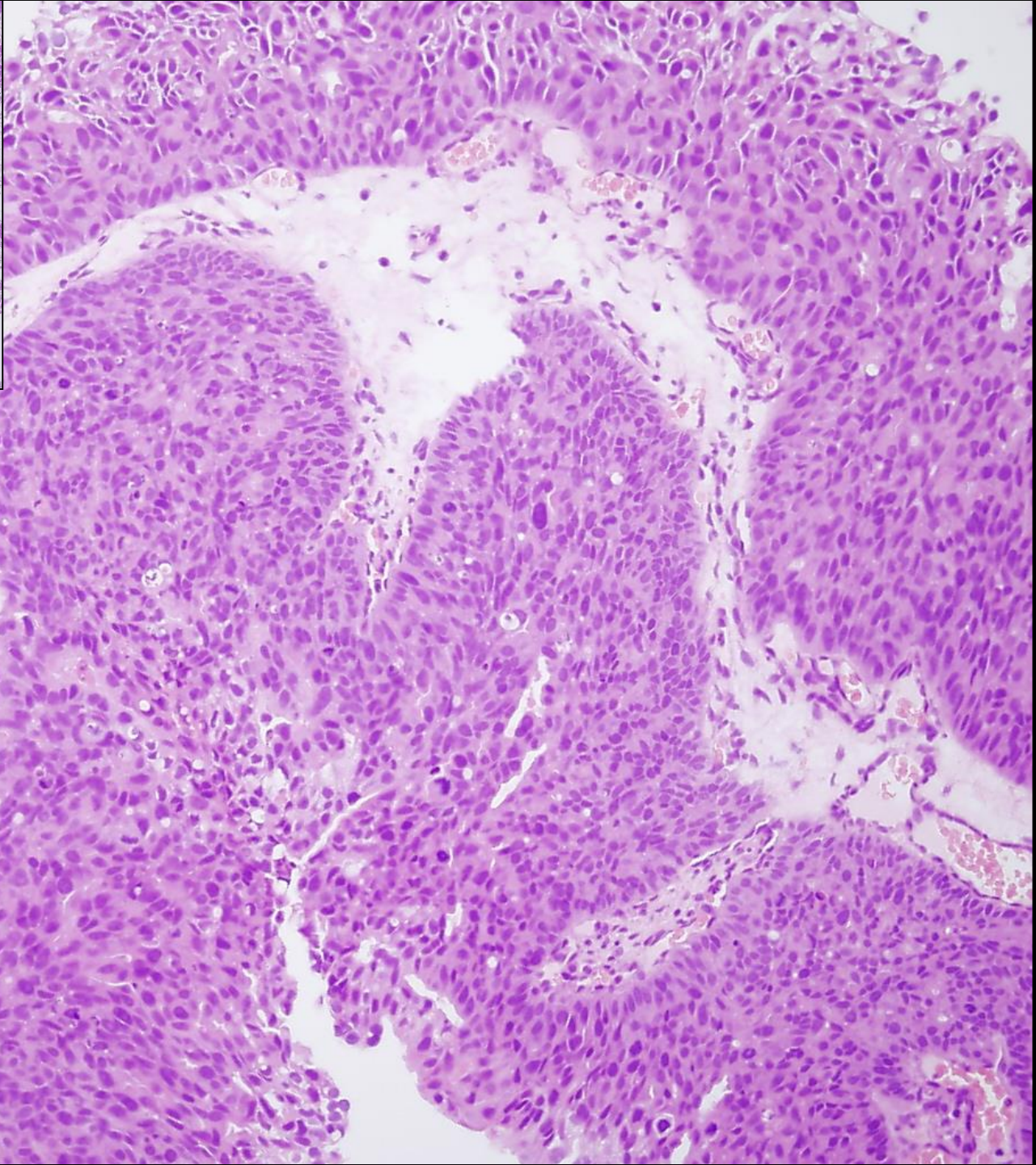
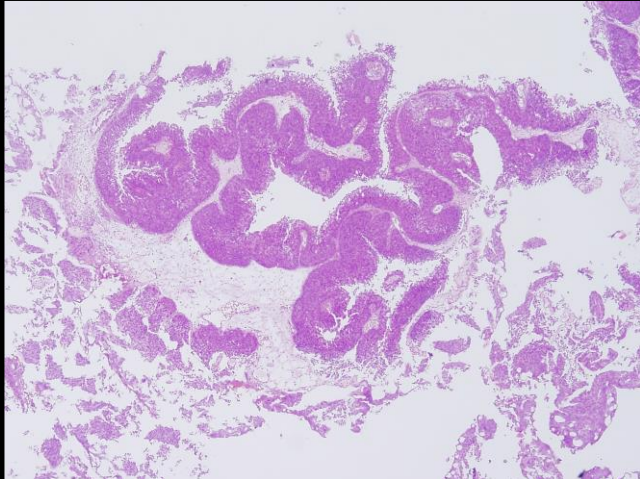


29 éves III.  
Papilláris  
hólyagtumor









Ez nem IP,  
csak a  
növekedési  
mintázata  
hasonlít!

# Papilláris tumorok- Nomenclatura, STAGE

WHO

WHO/ISUP

Papilloma → Papilloma

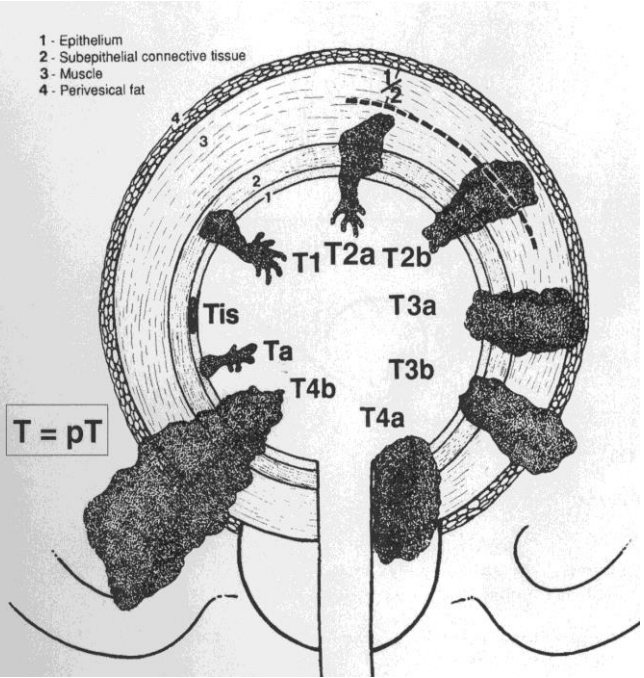
Grade I → PUNLMP

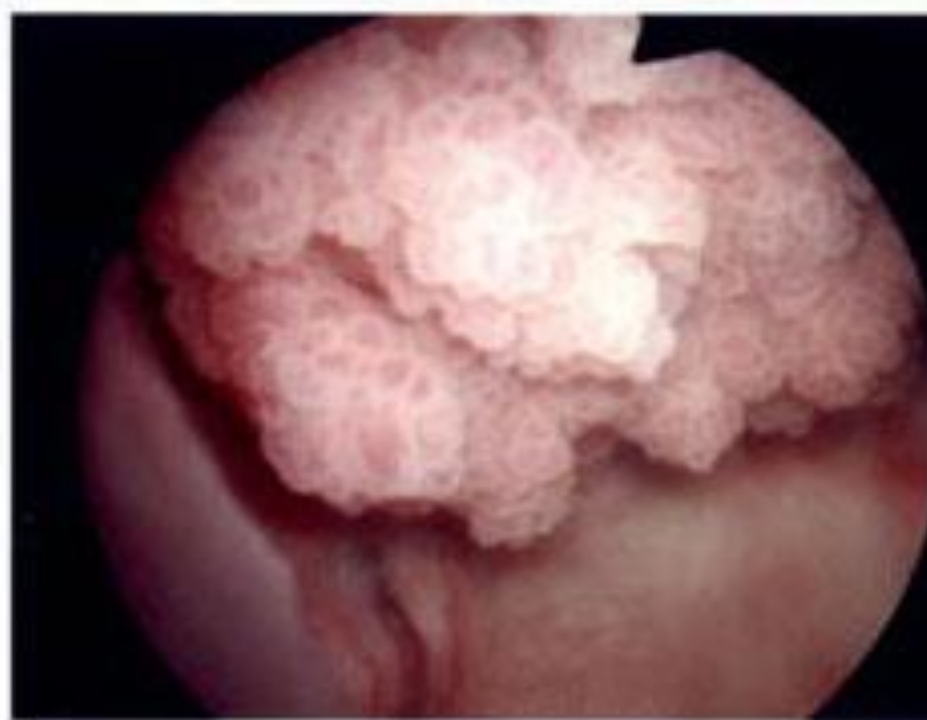
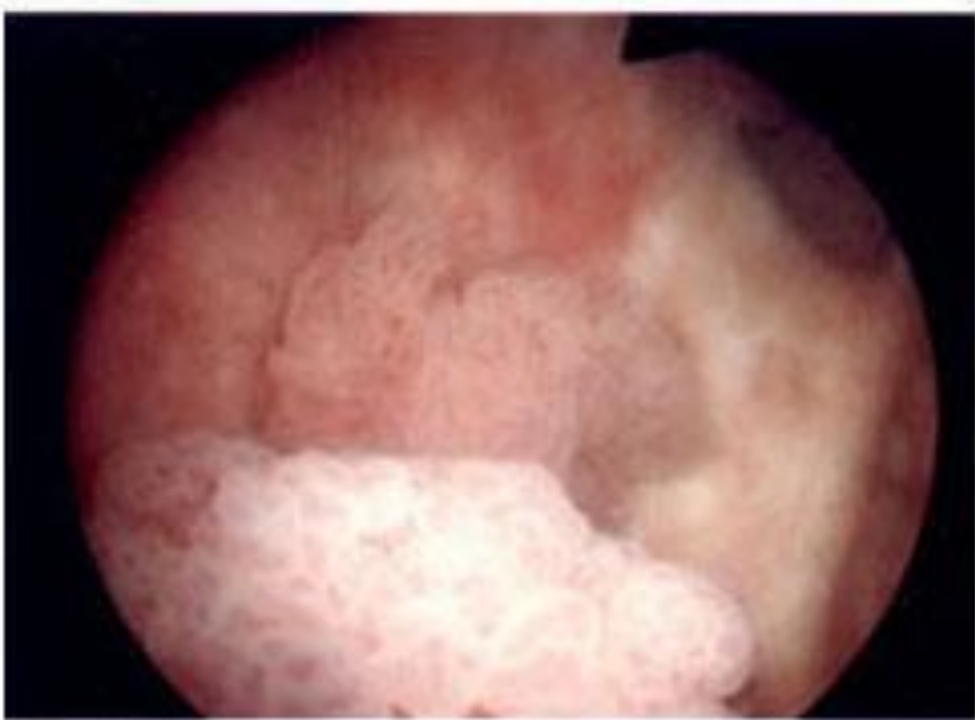
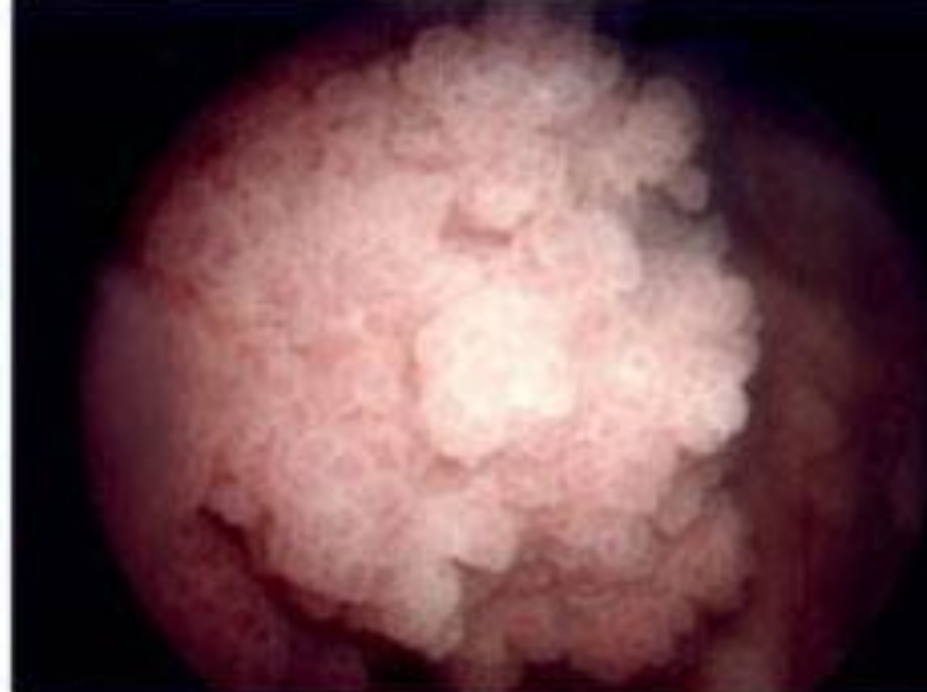
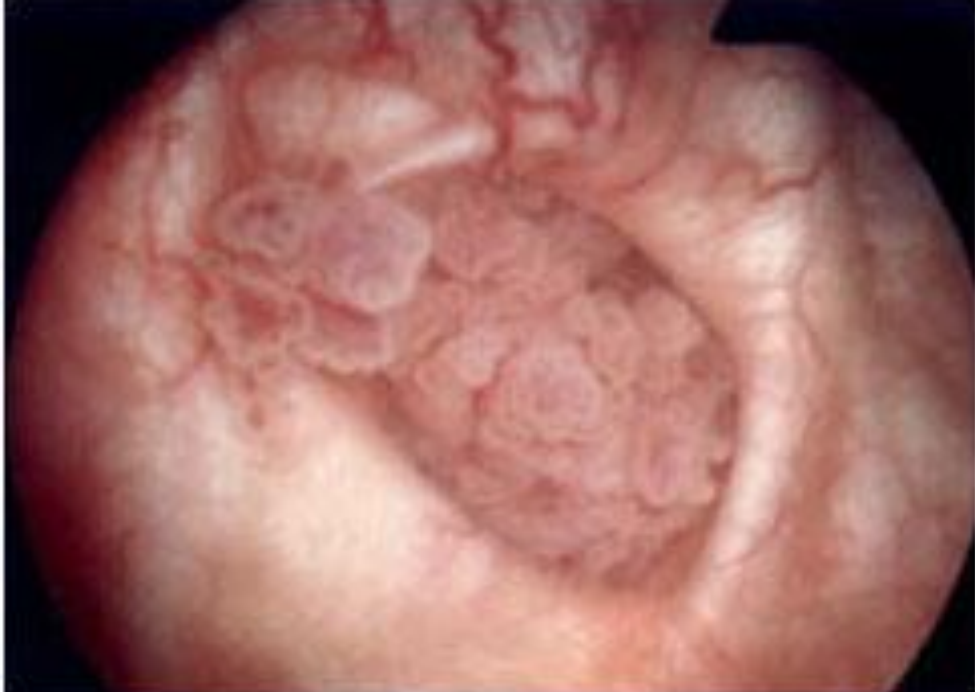Low Grade

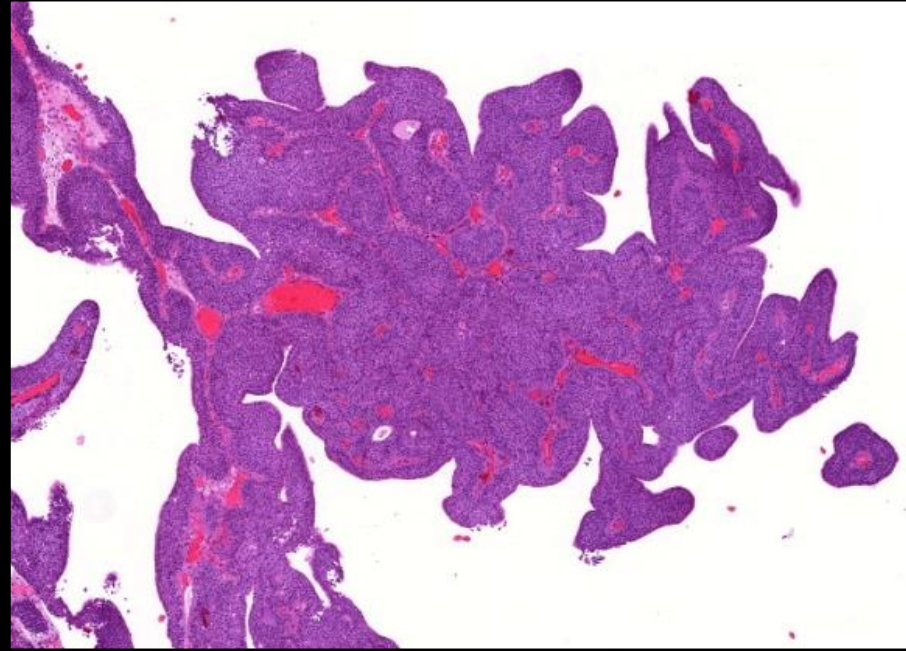
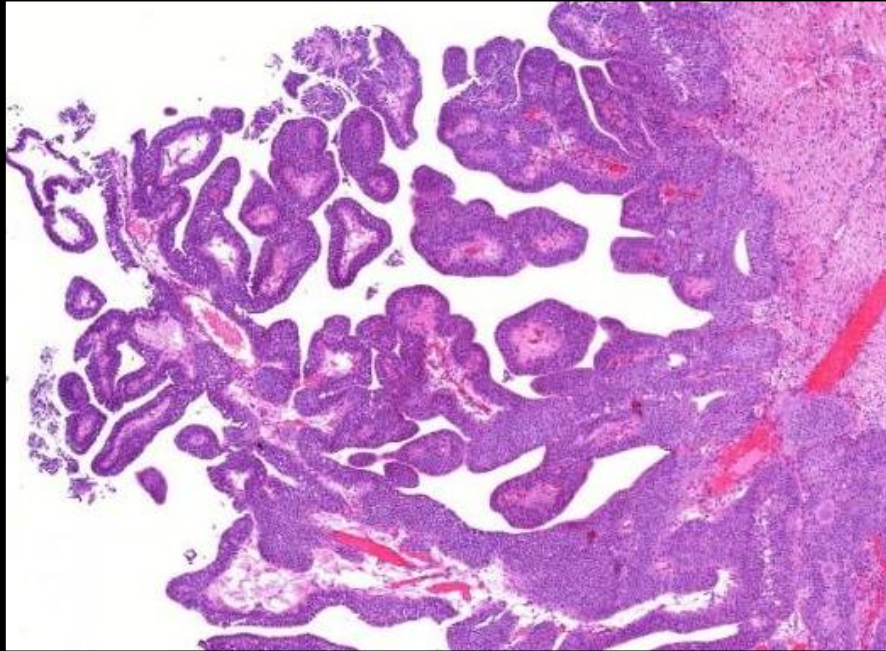
Grade II

High Grade

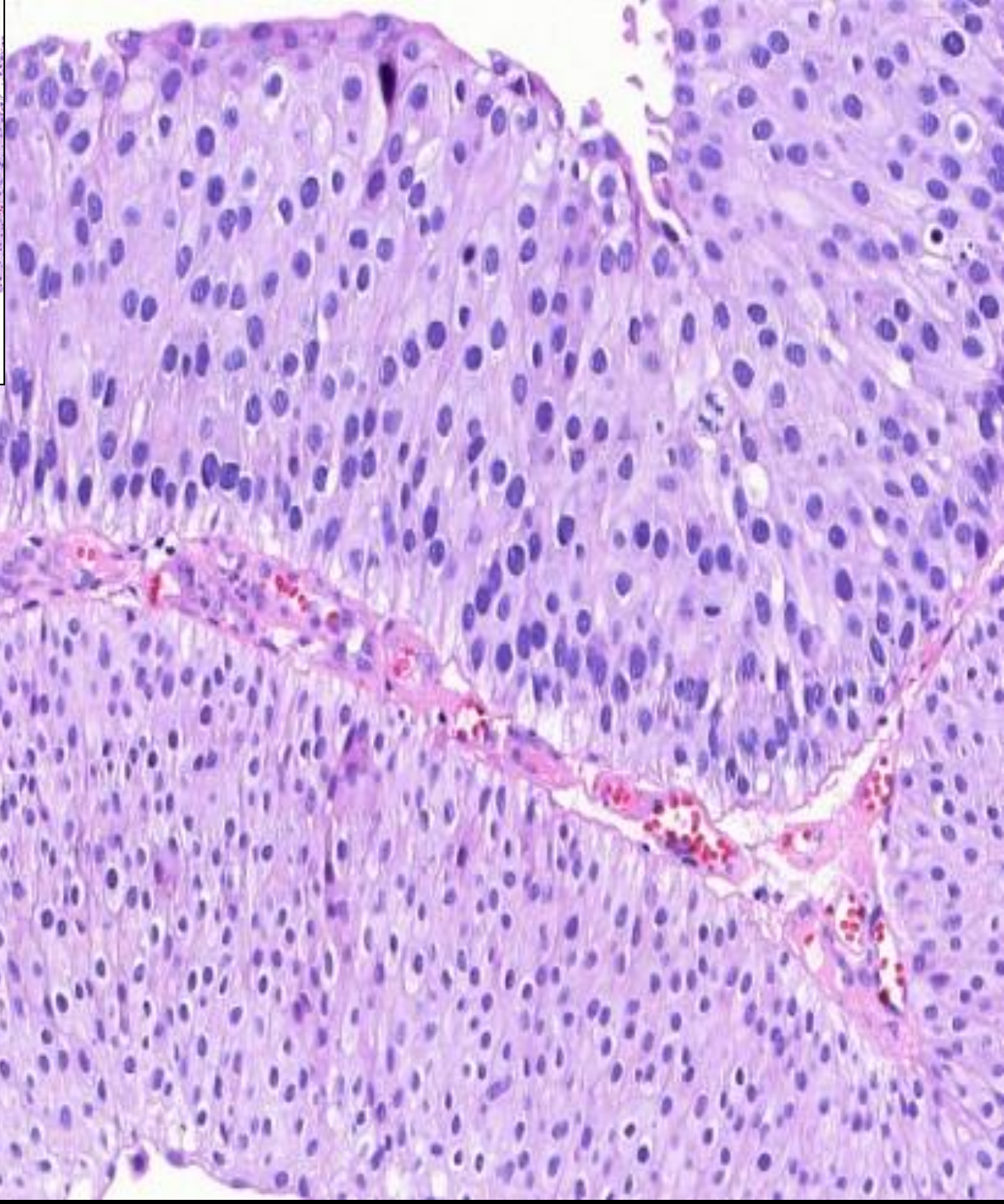
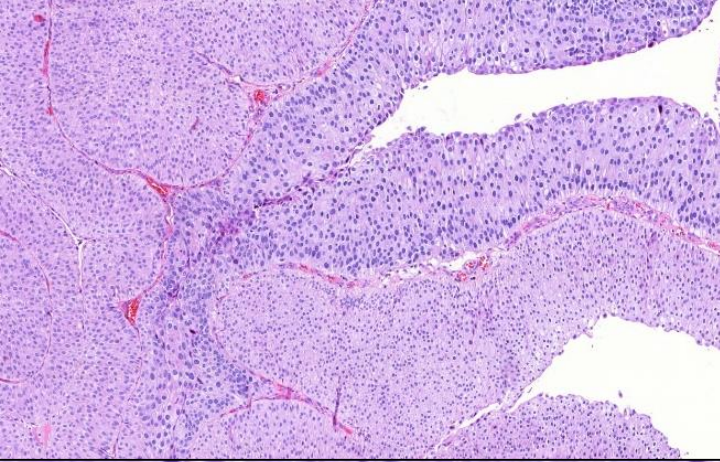
Grade III →





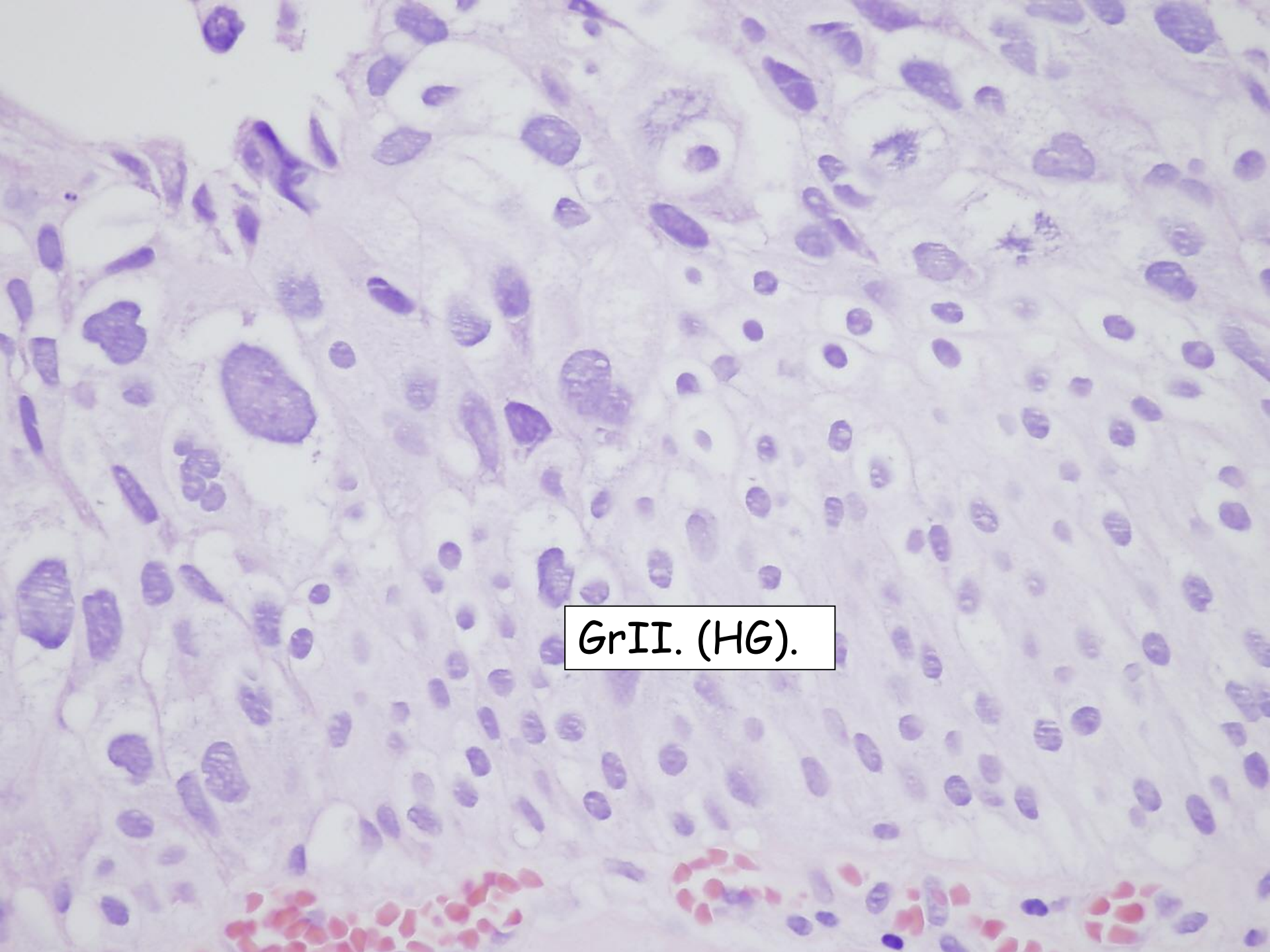


PUNLMP (GrI)



LG (GrII.)

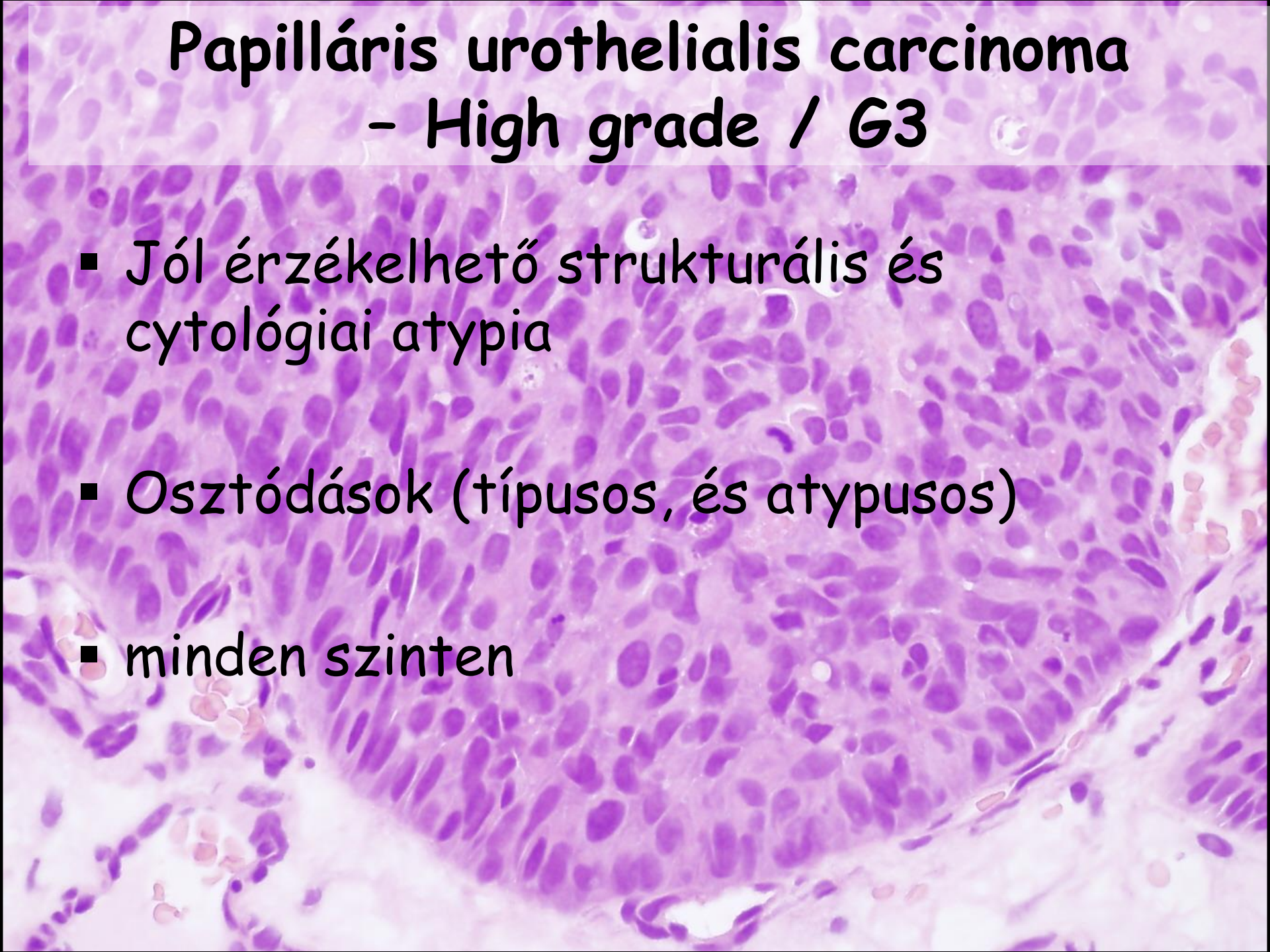




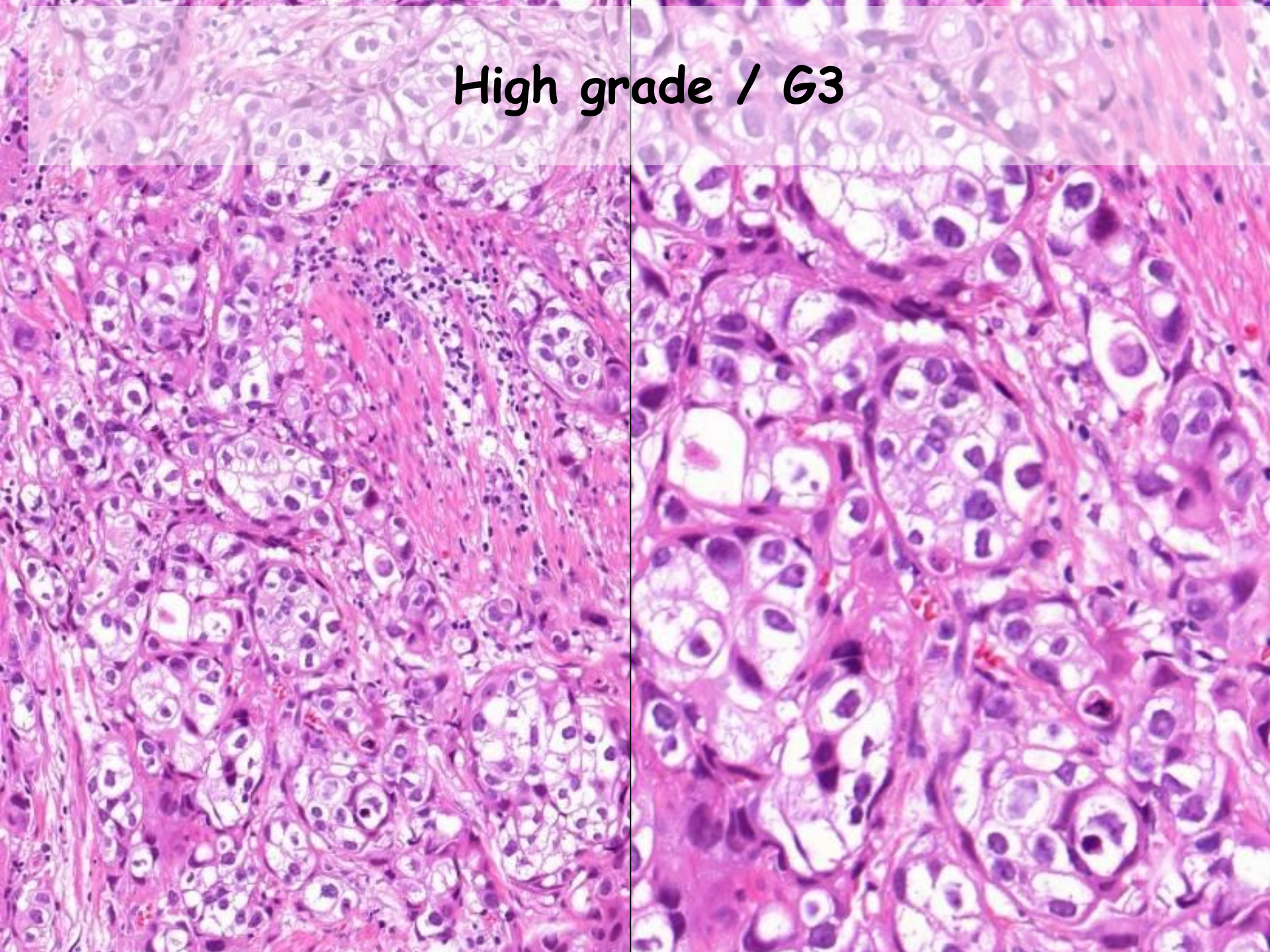
GrII. (HG).

# Papilláris urothelialis carcinoma - High grade / G3

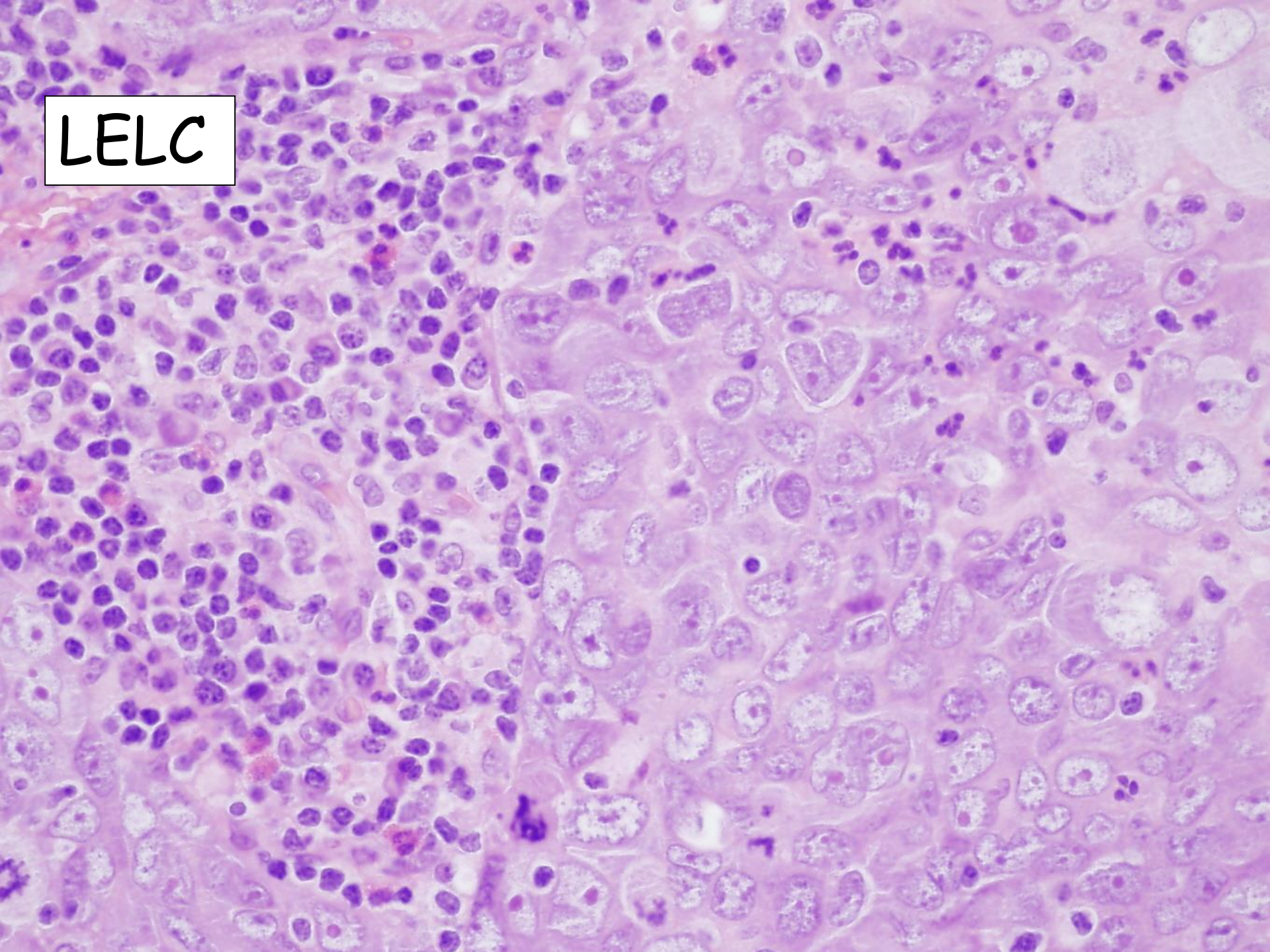
- Jól érzékelhető strukturális és cytológiai atypia
- Osztódások (típusos, és atypusos)
- minden szinten

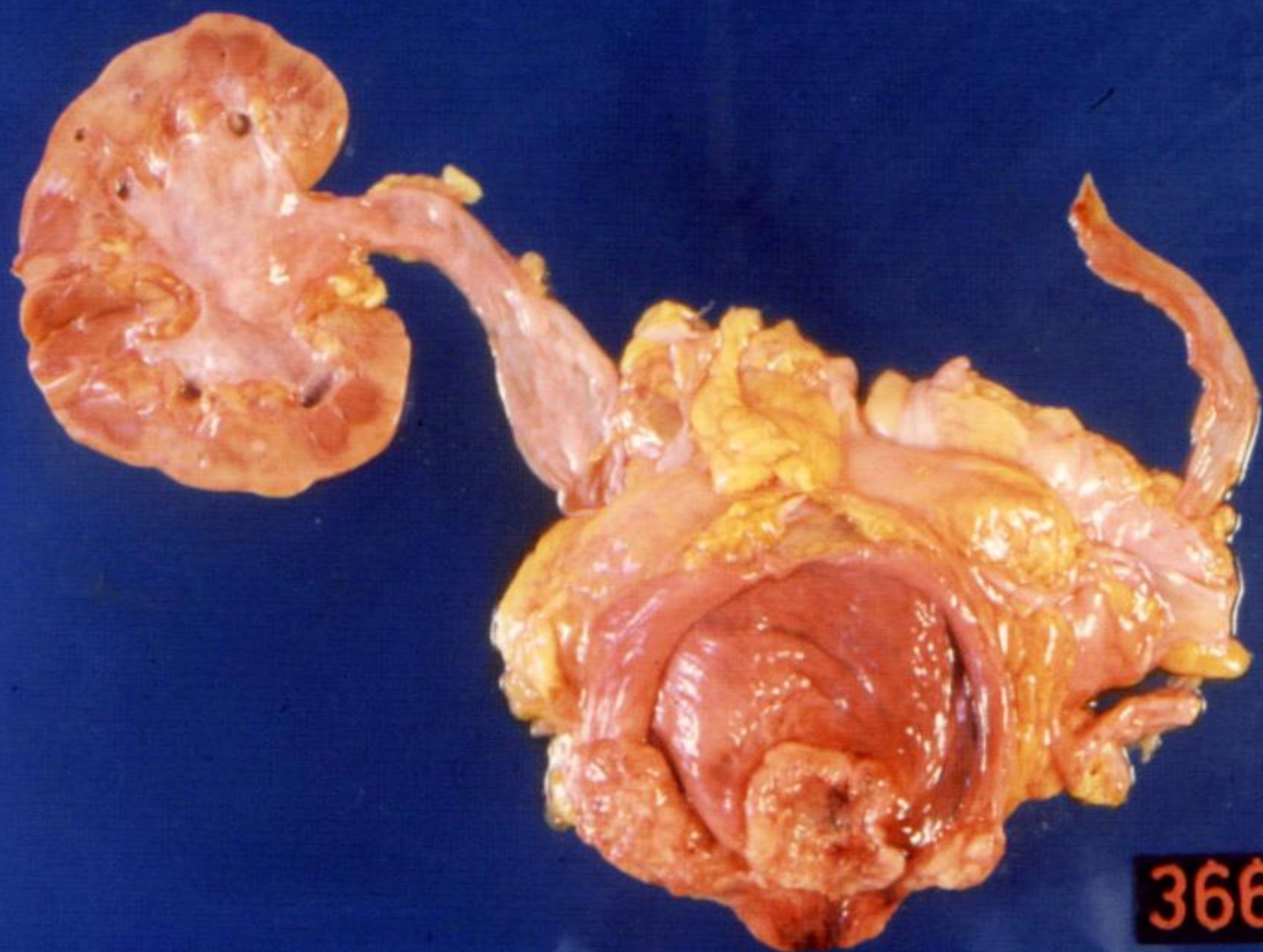


**High grade / G3**



LELC





36671

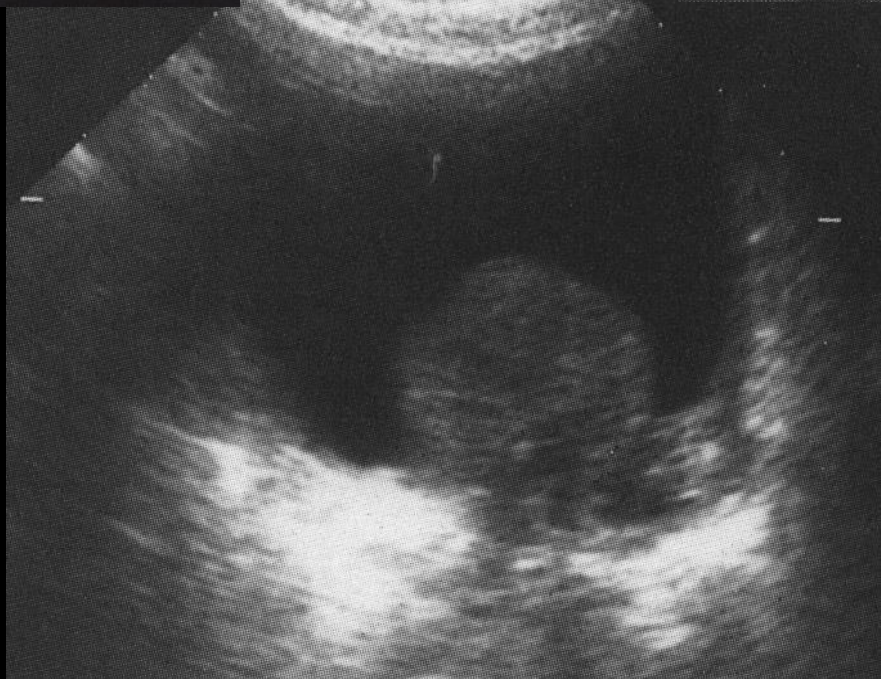
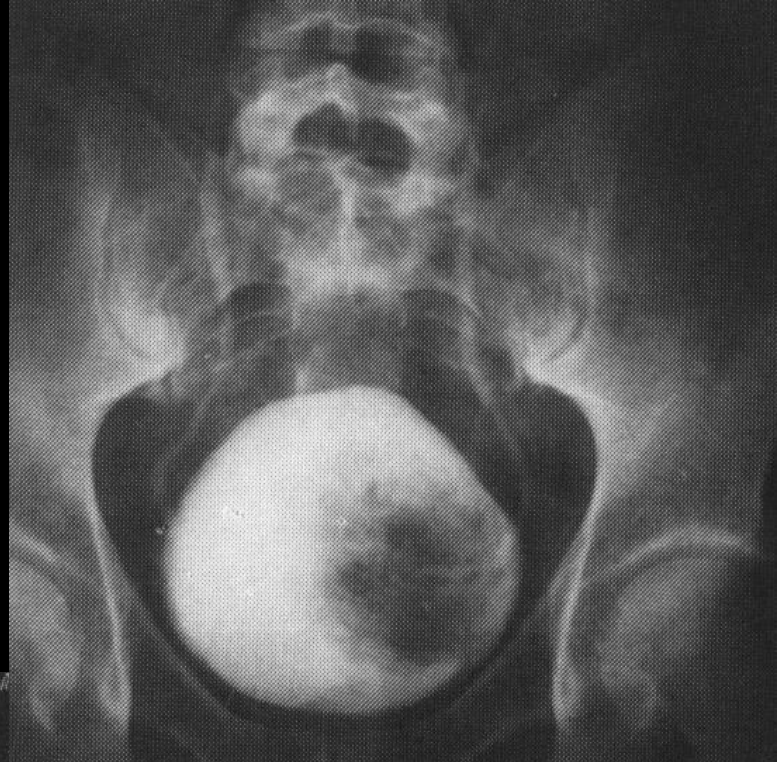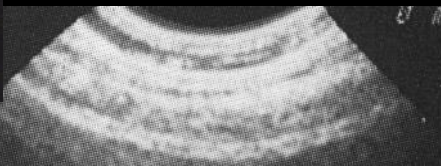
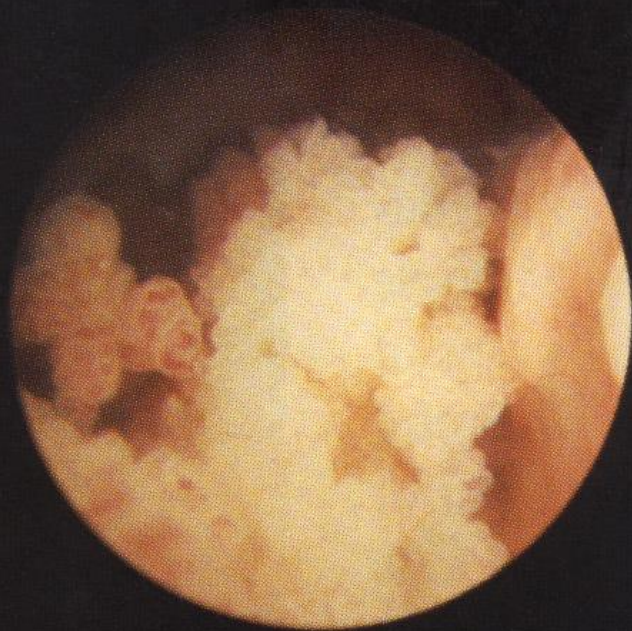
# 53 éves férfi

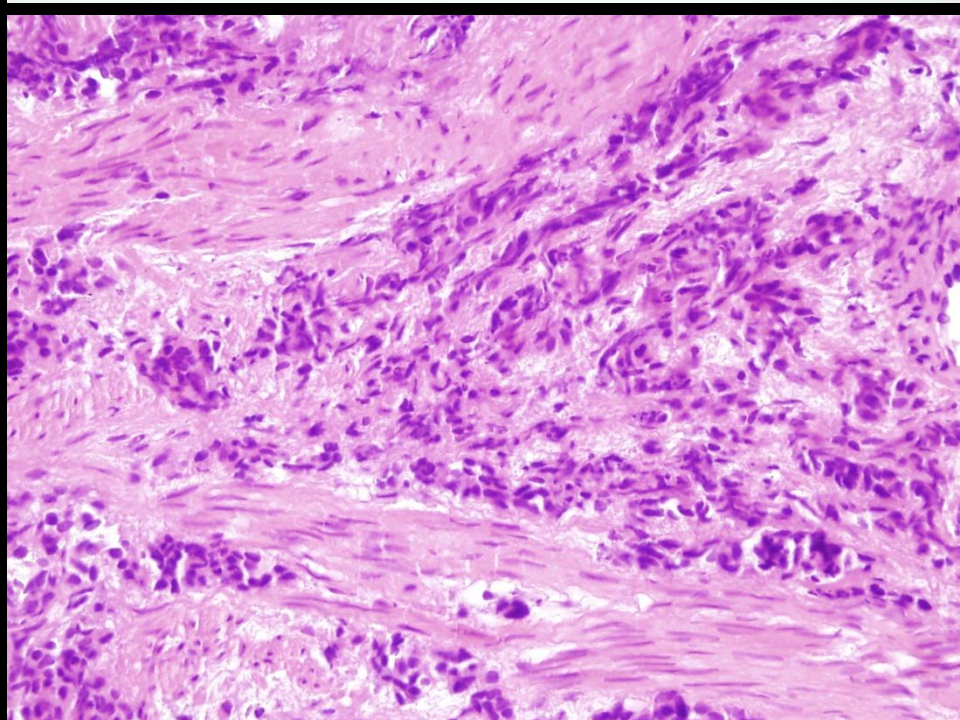
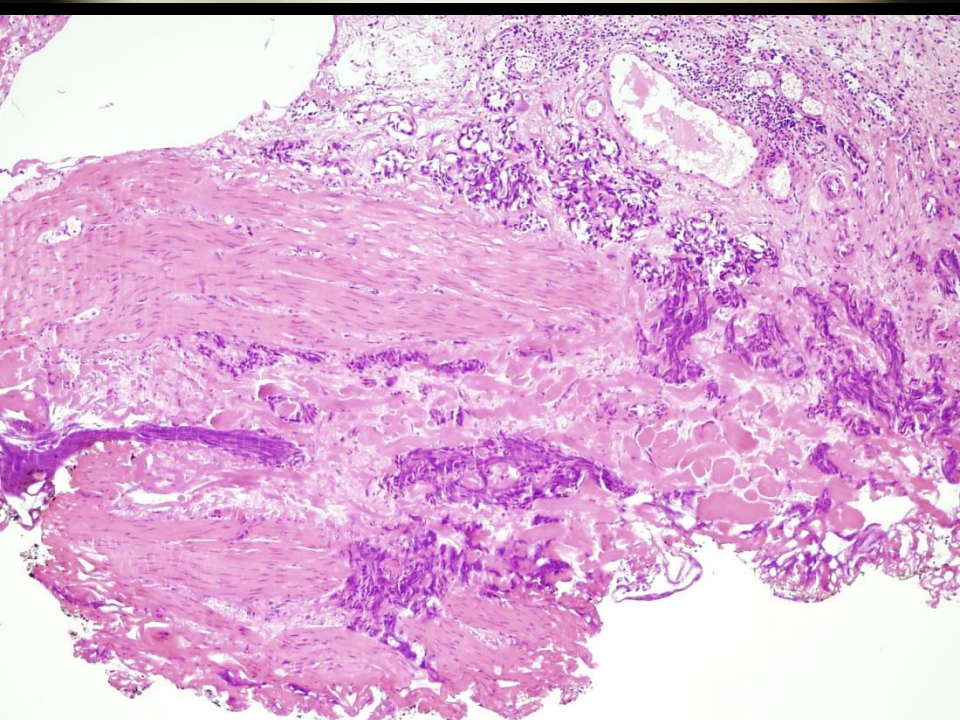
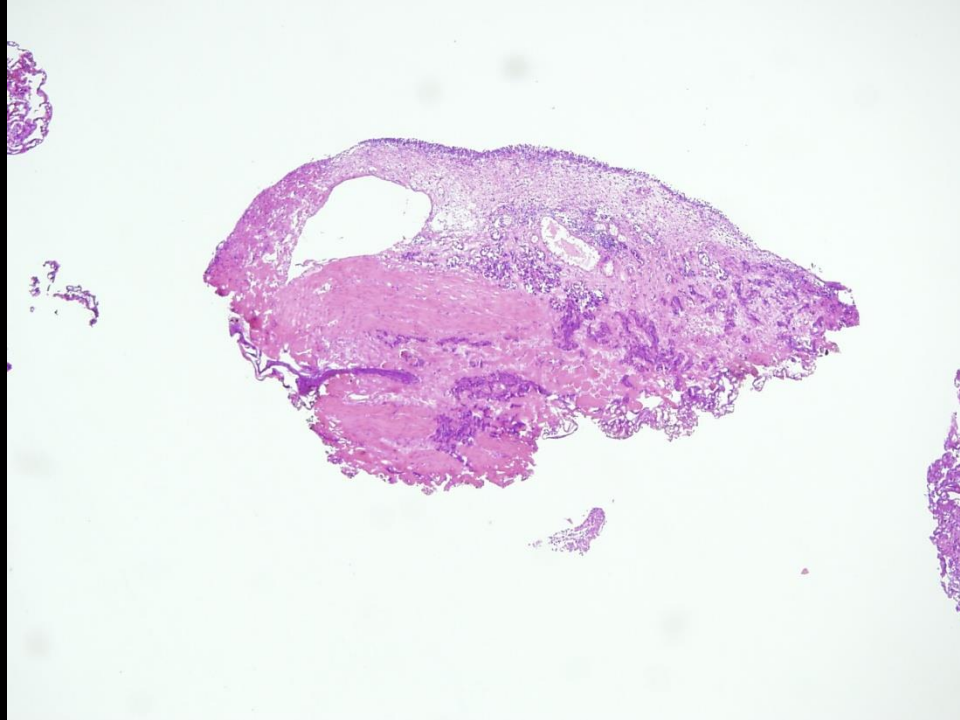
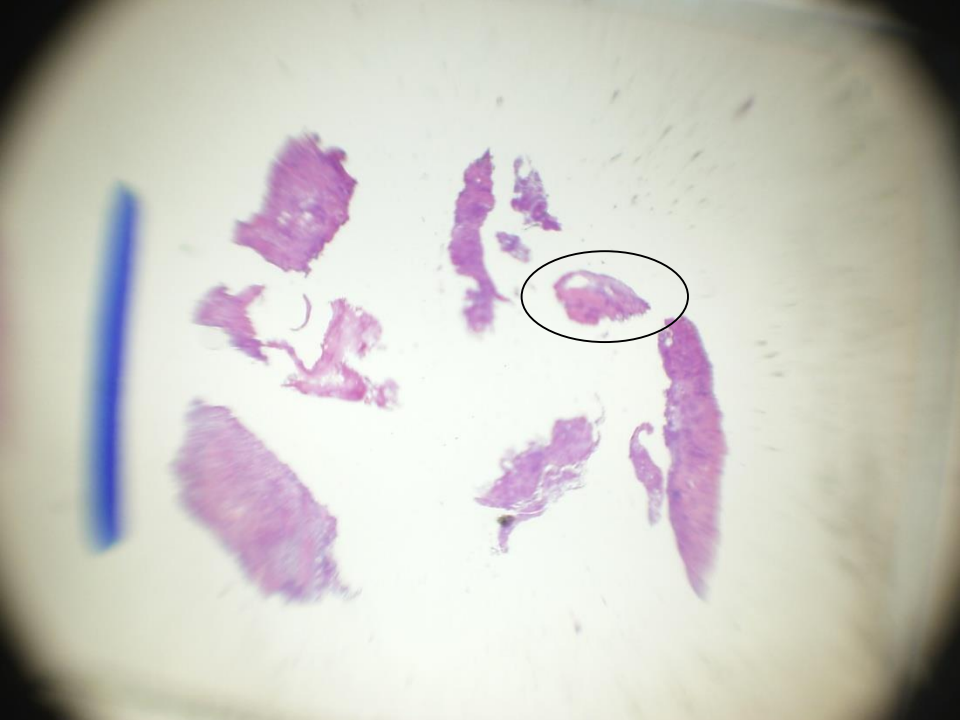
Dohányzik (!!!!!)

Haematuria miatt végzett  
vizsgálatokon

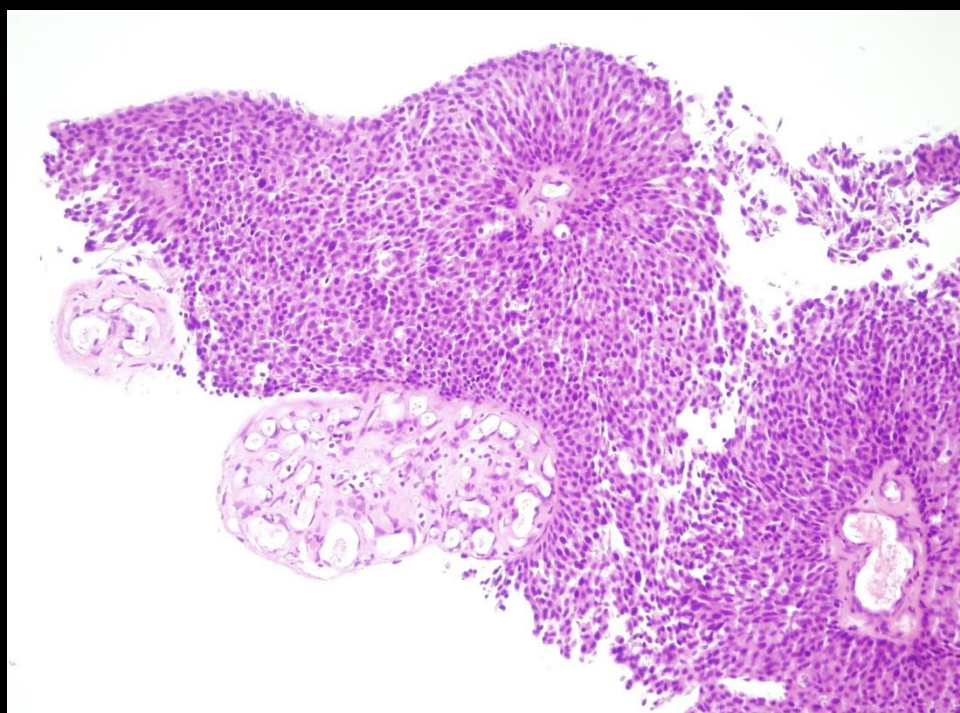
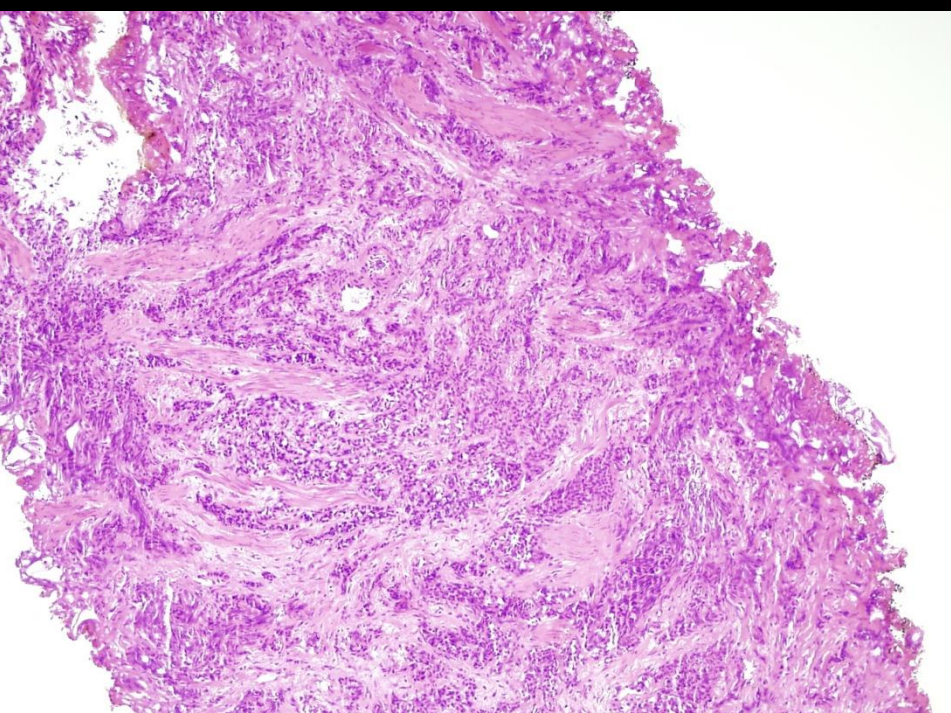
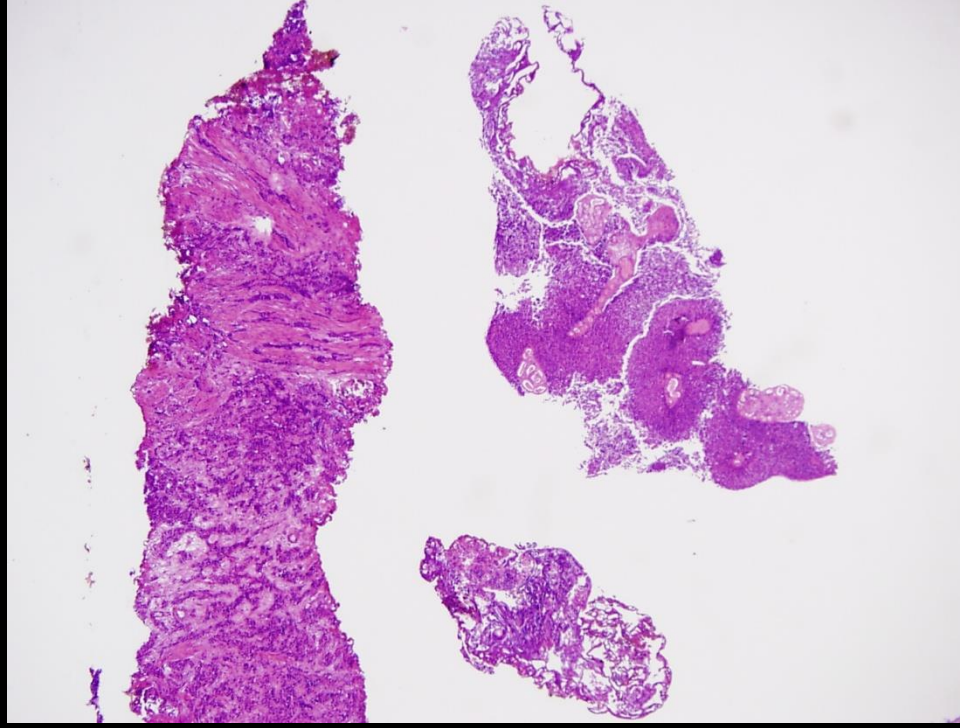
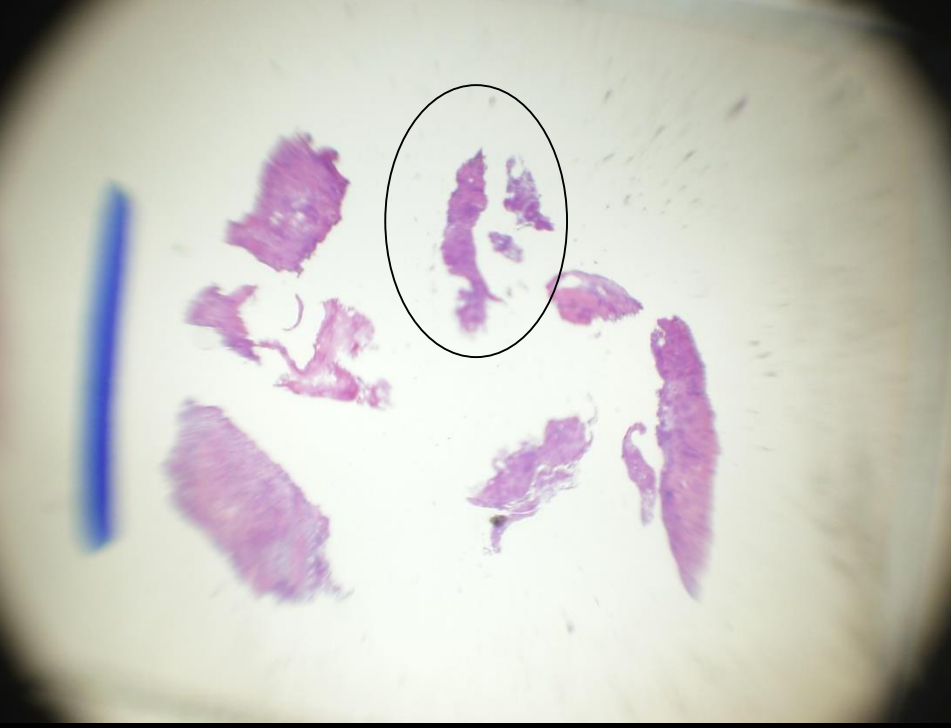
hólyagba domborodó, falat vs.  
beszűrő

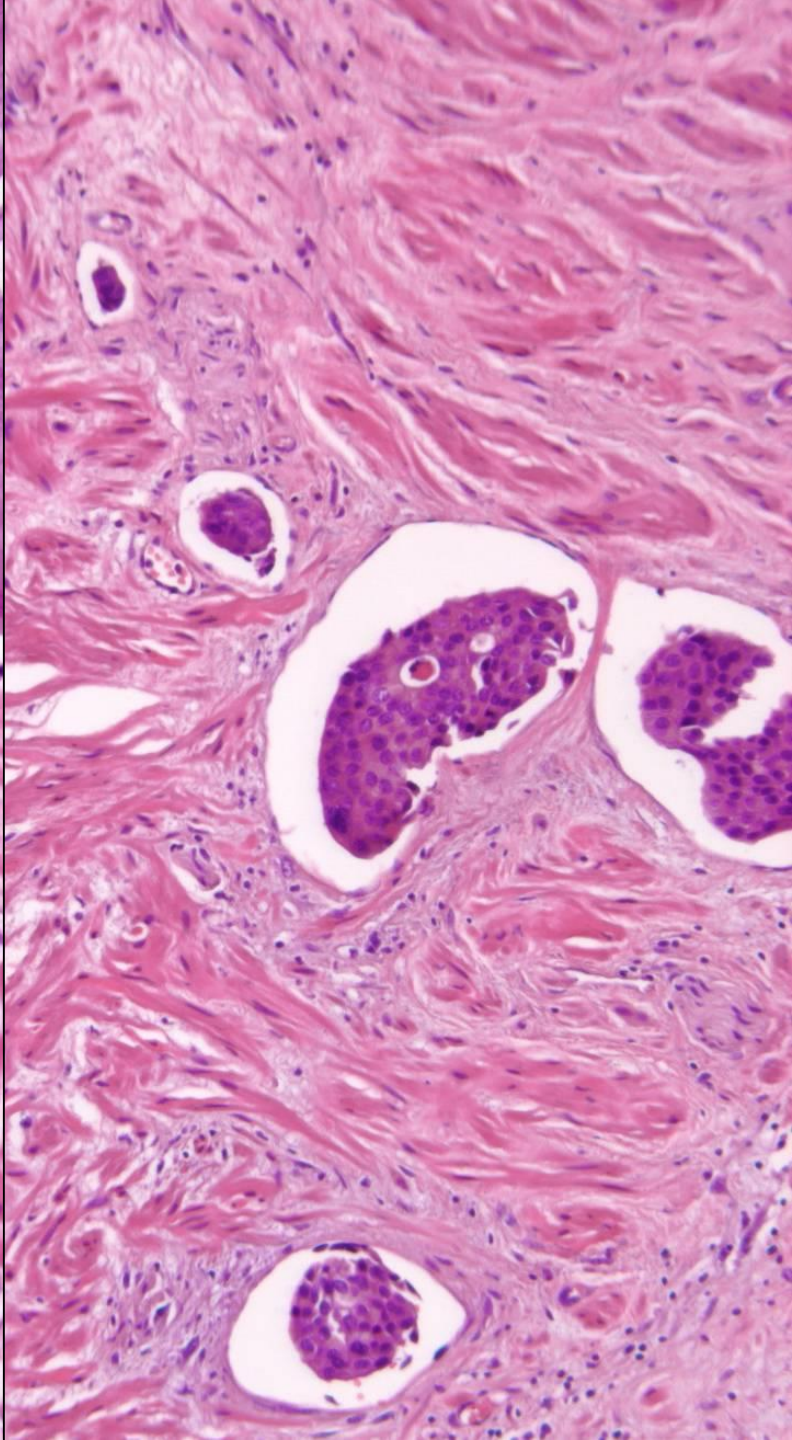
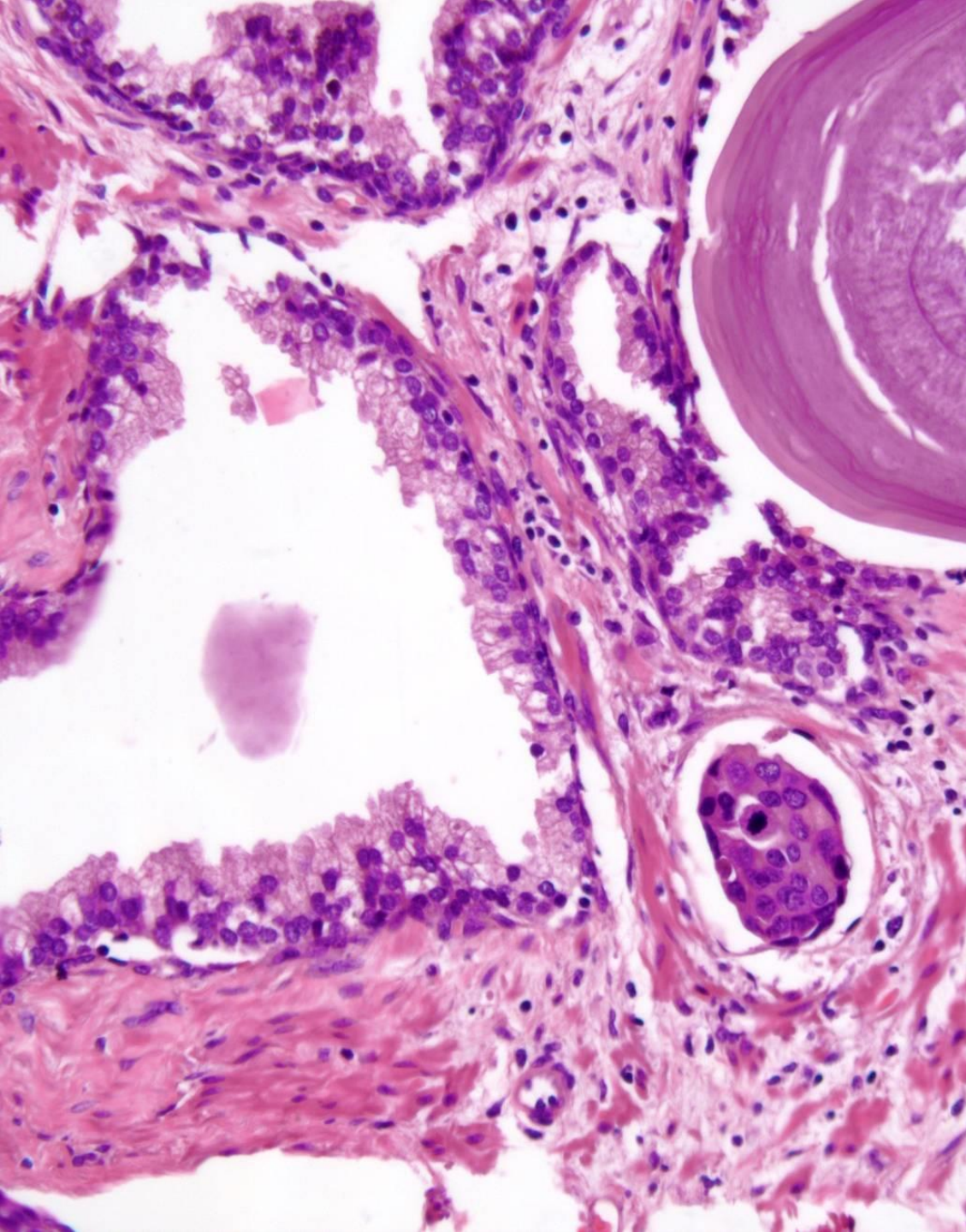
tumor

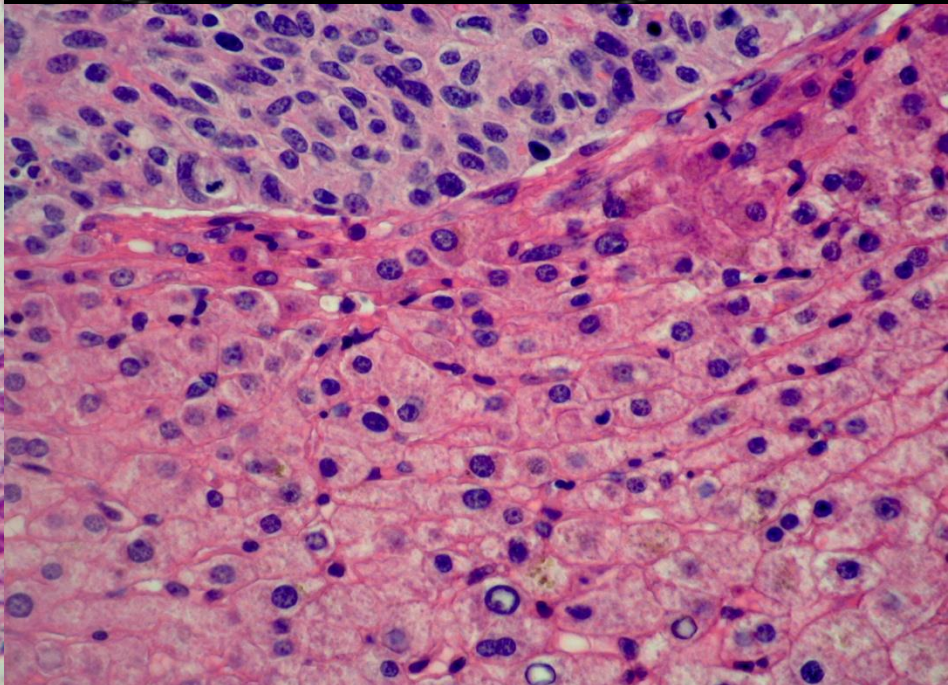
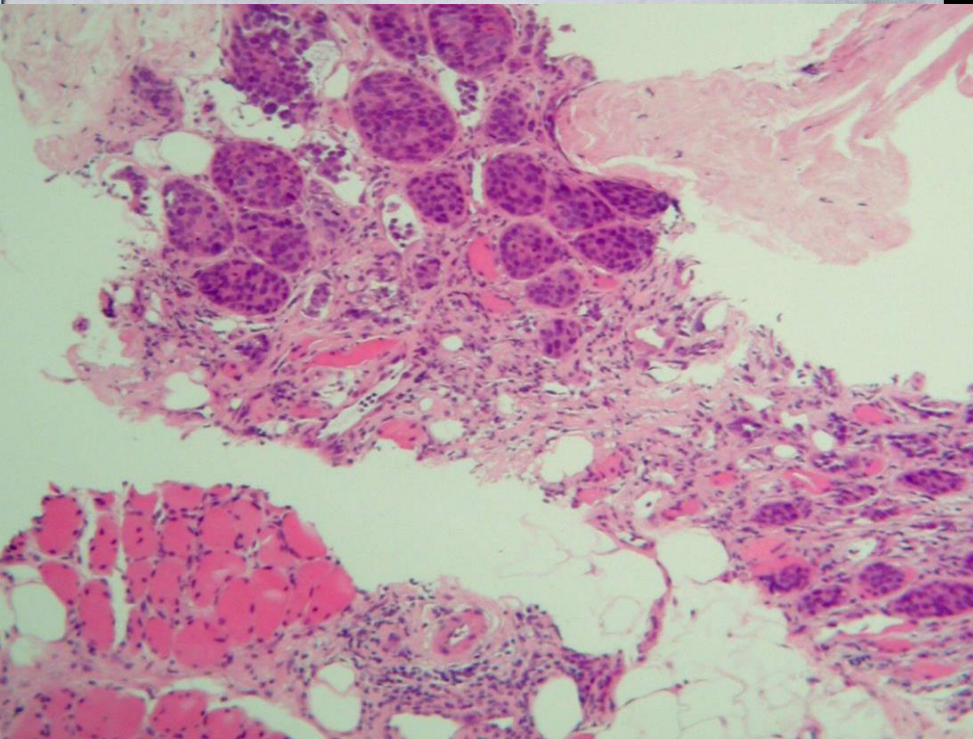
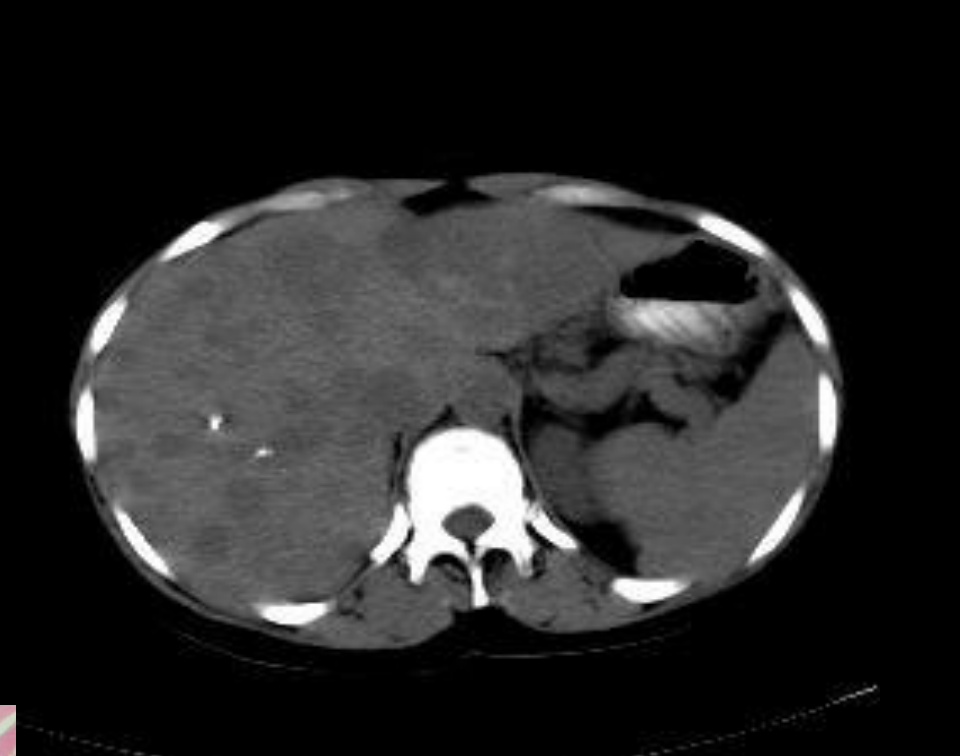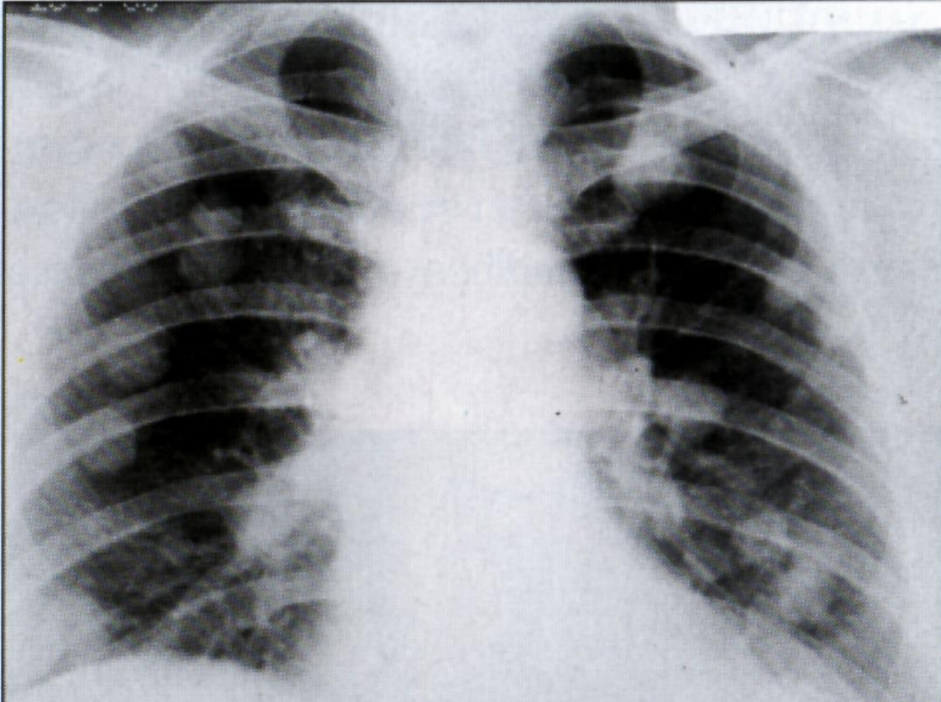






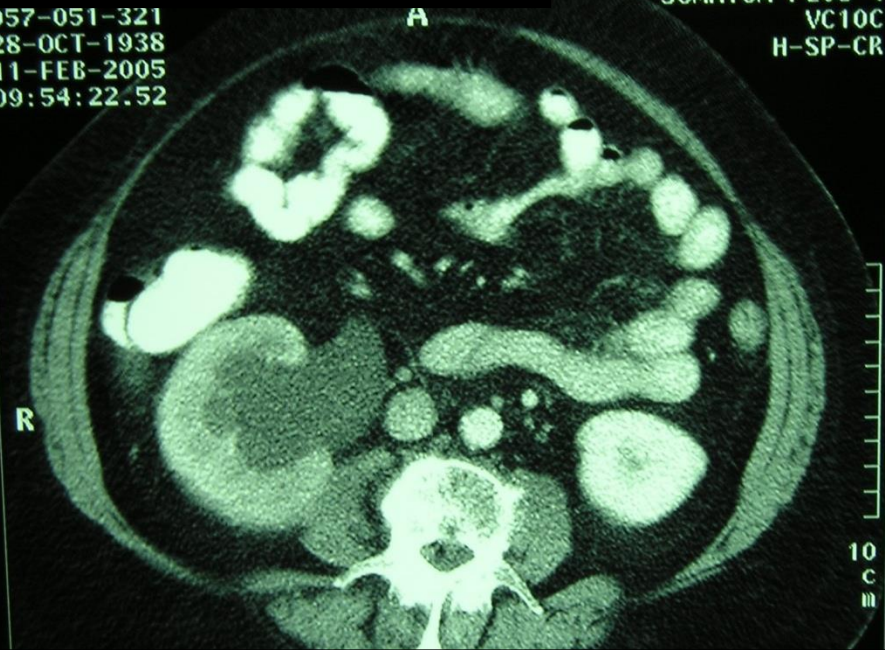




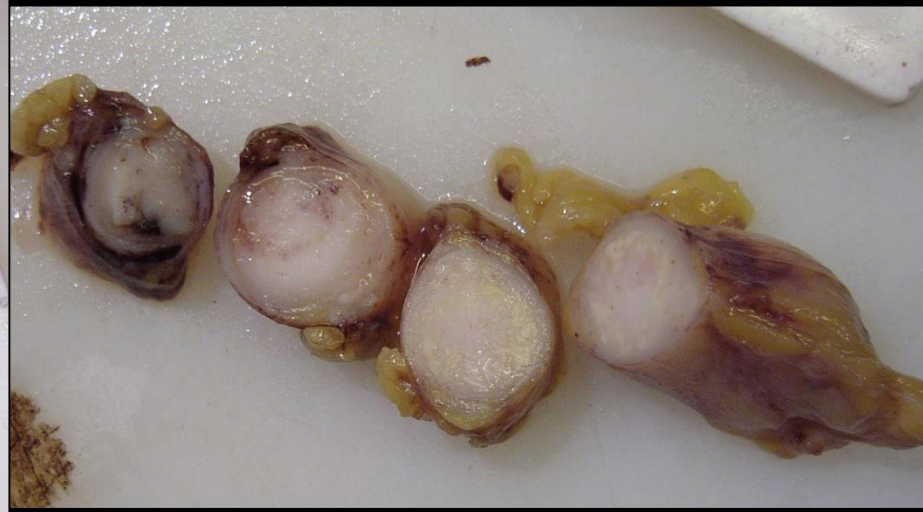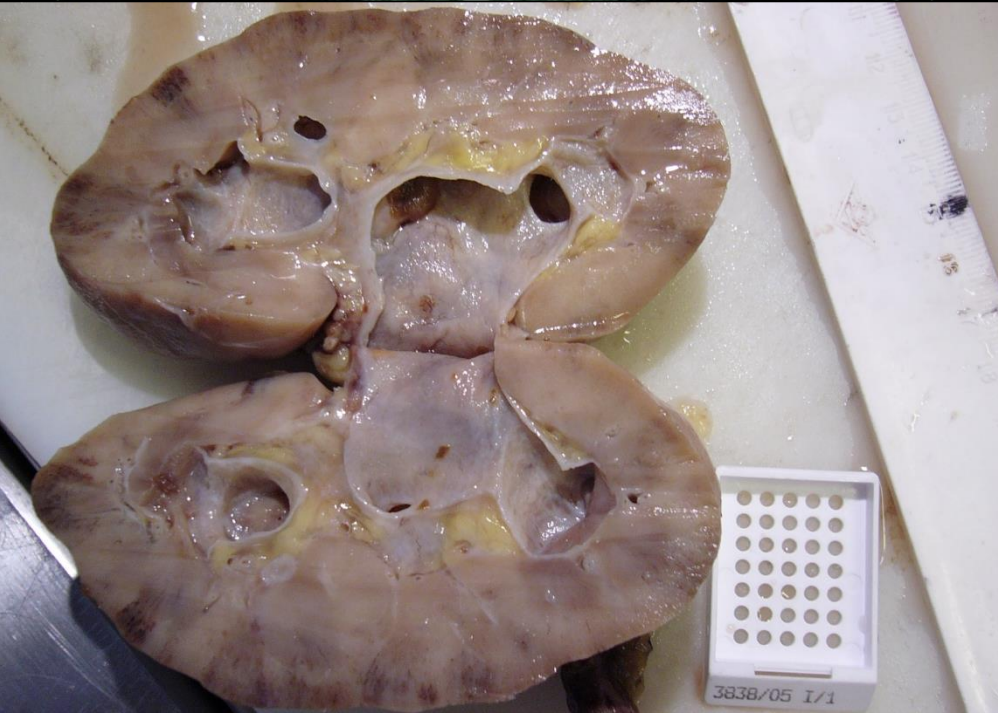


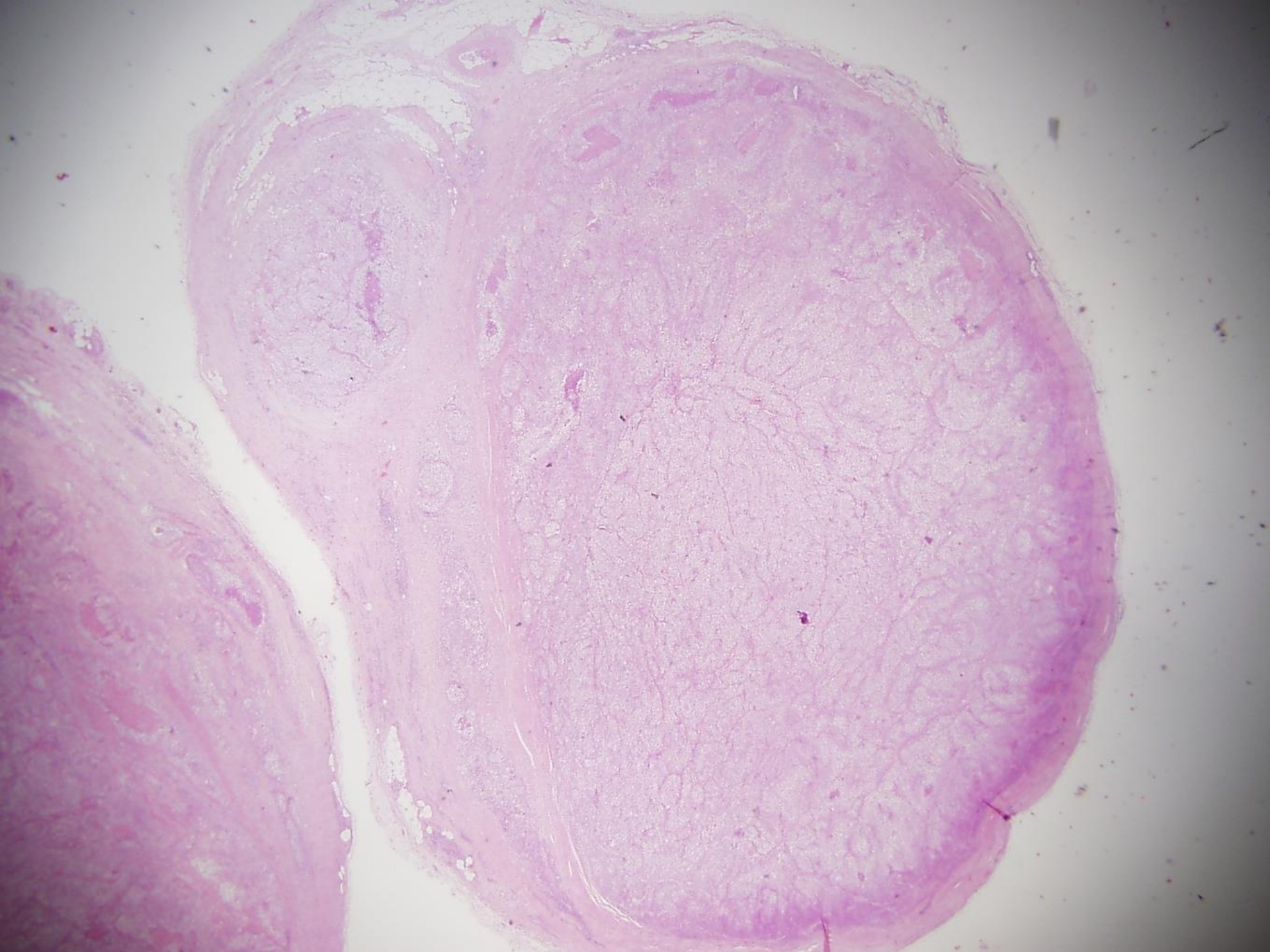
057-051-321  
28-OCT-1938  
11-FEB-2005  
09:54:22.52

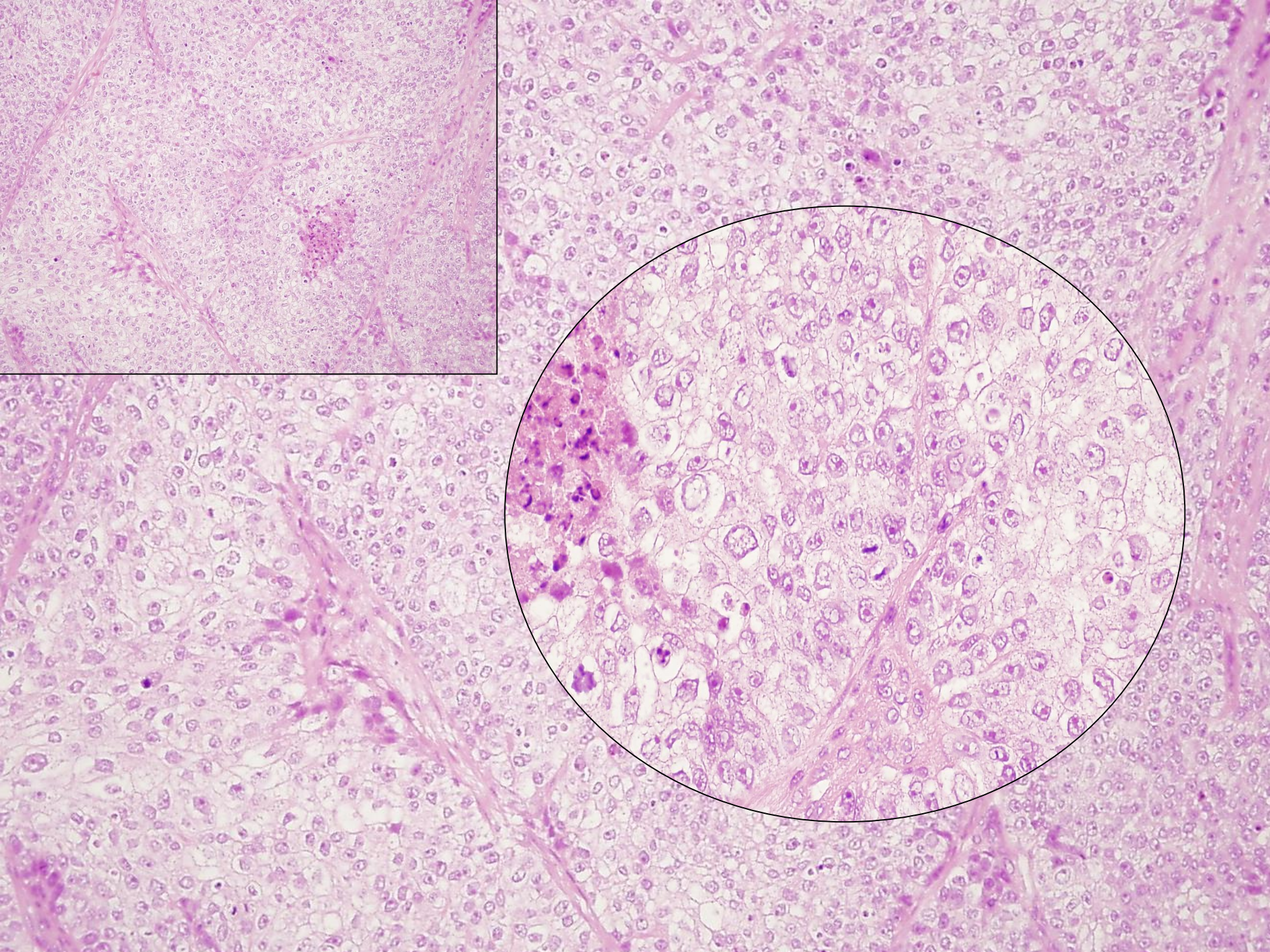
SE-AOK RAD.ONKOT.KLIN  
SOMATOM PLUS 4  
VC10C  
H-SP-CR

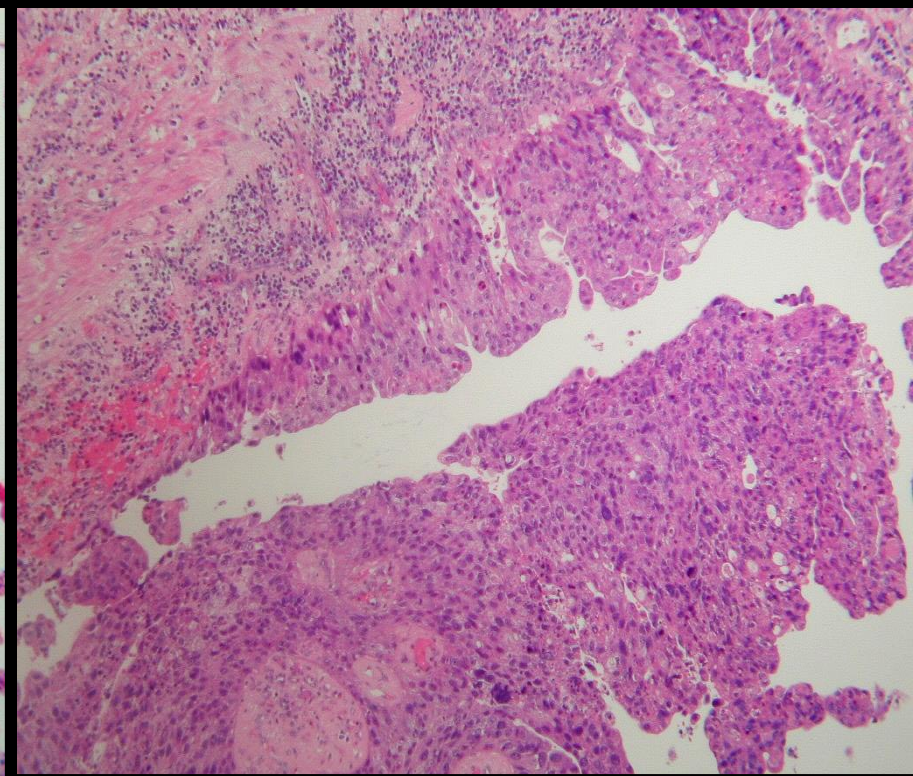
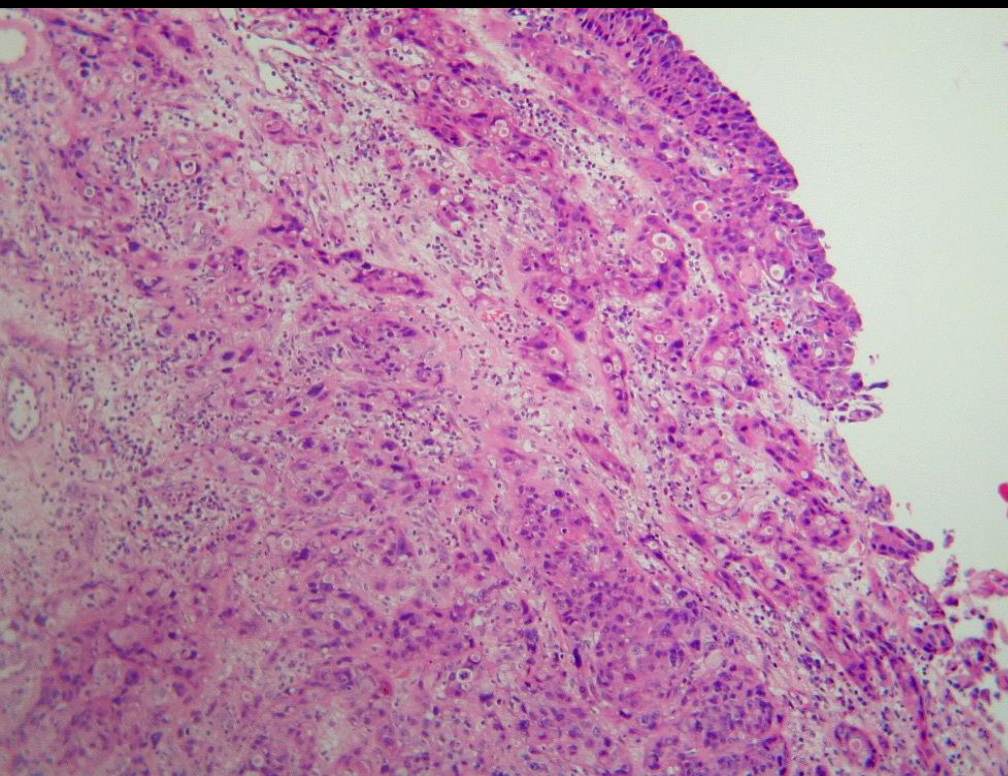
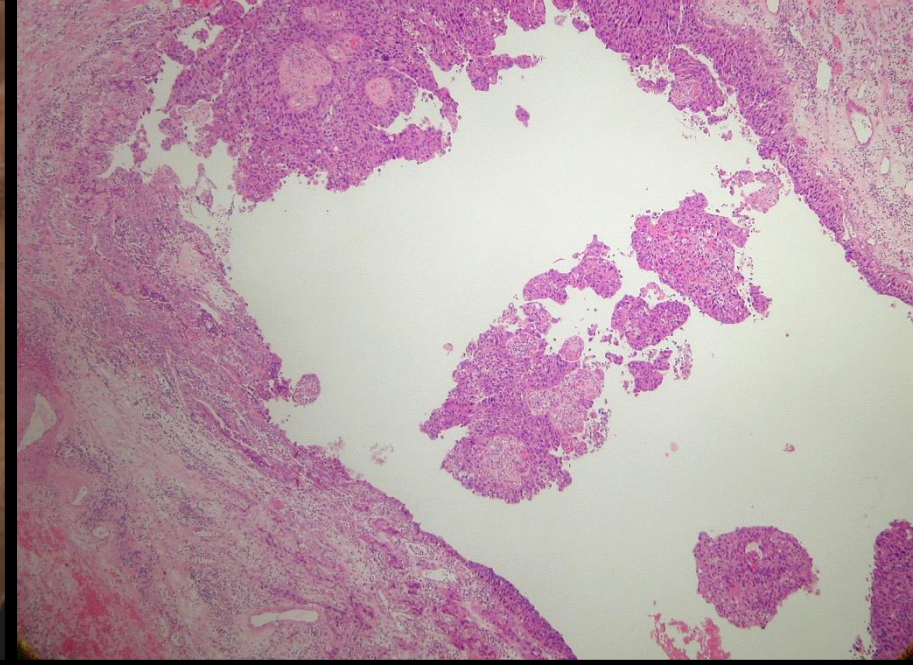
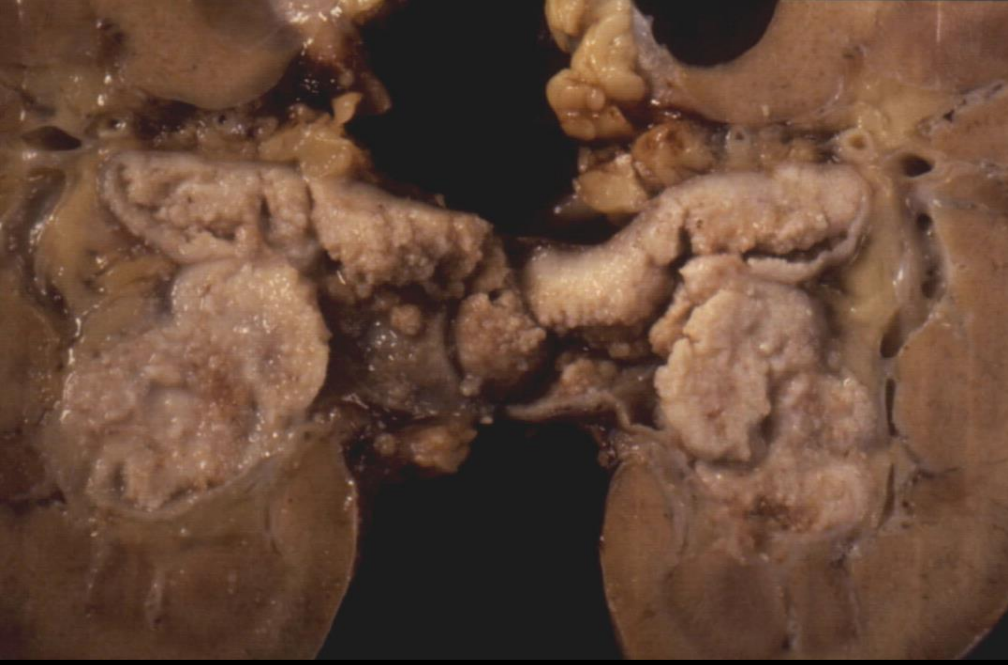

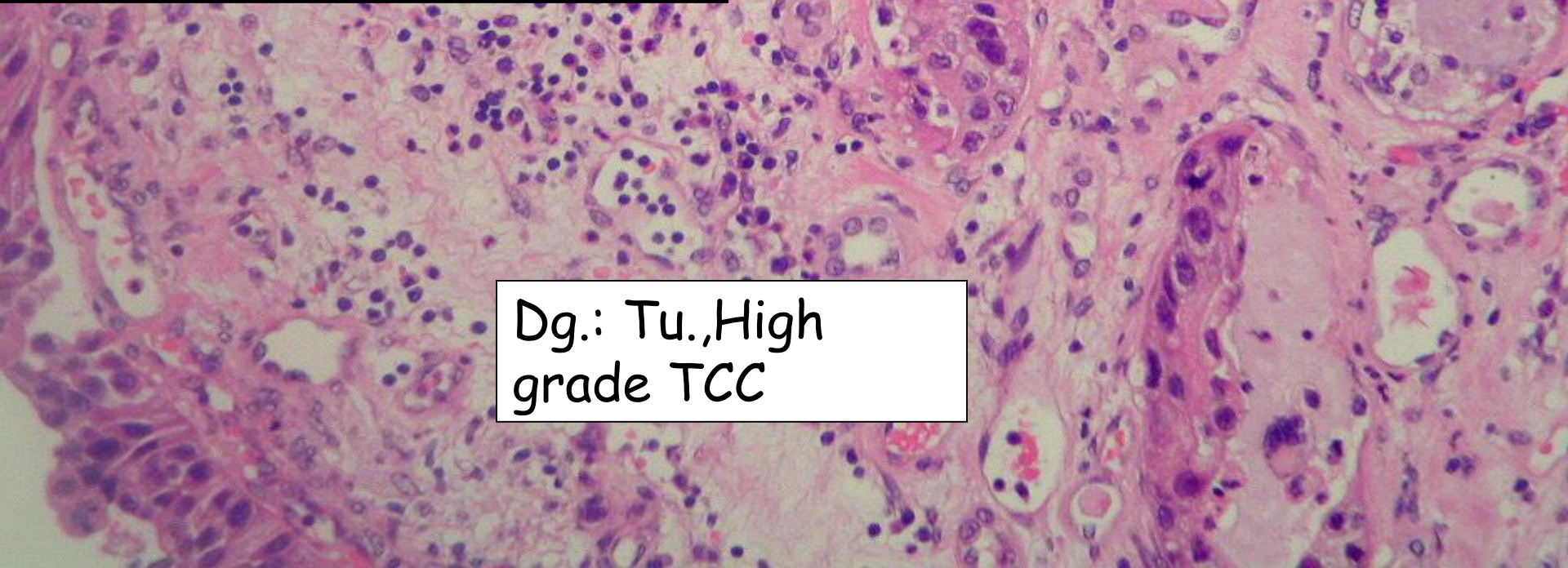
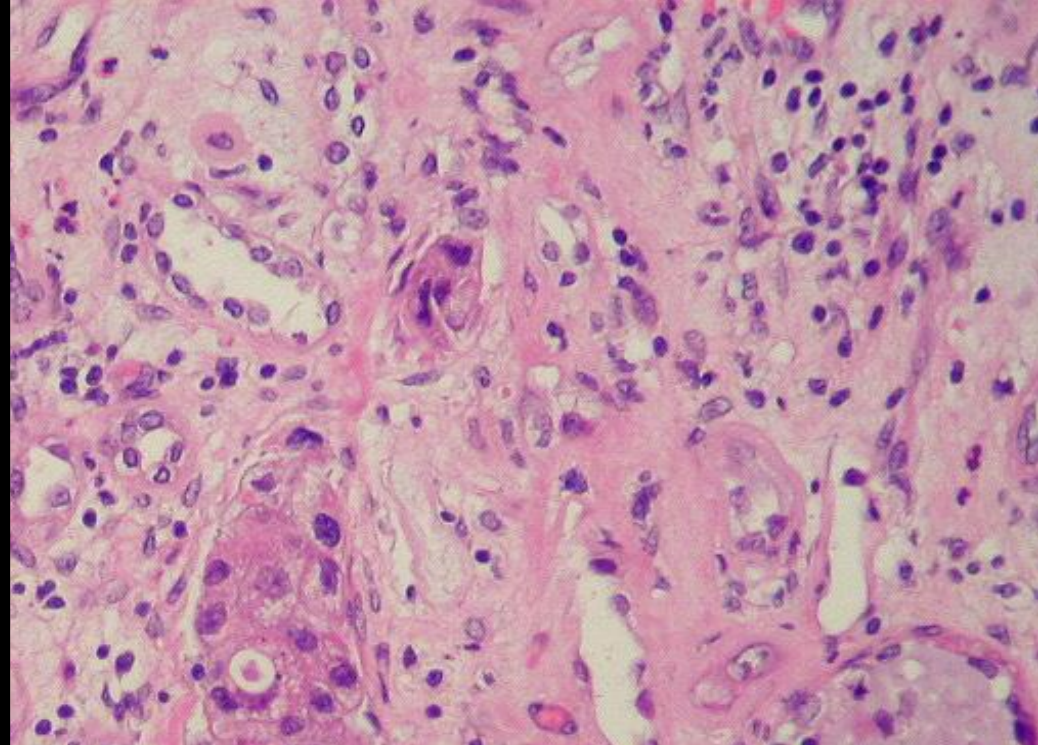
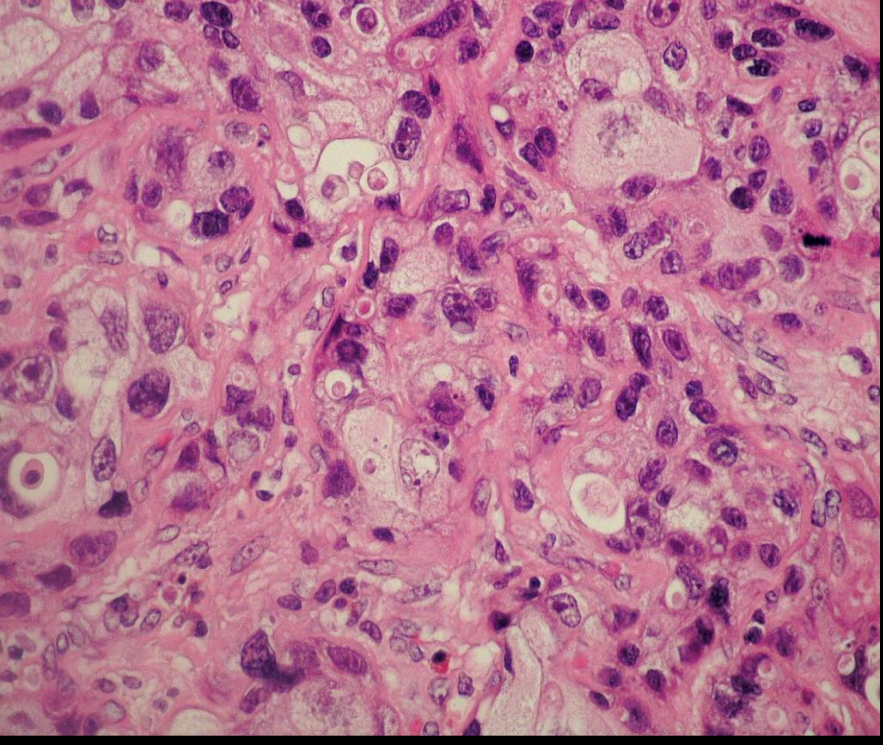
67 éves nő.  
Hydronephrosis.  
Ureter tumor  
gyanú.











Dg.: Tu., High grade TCC

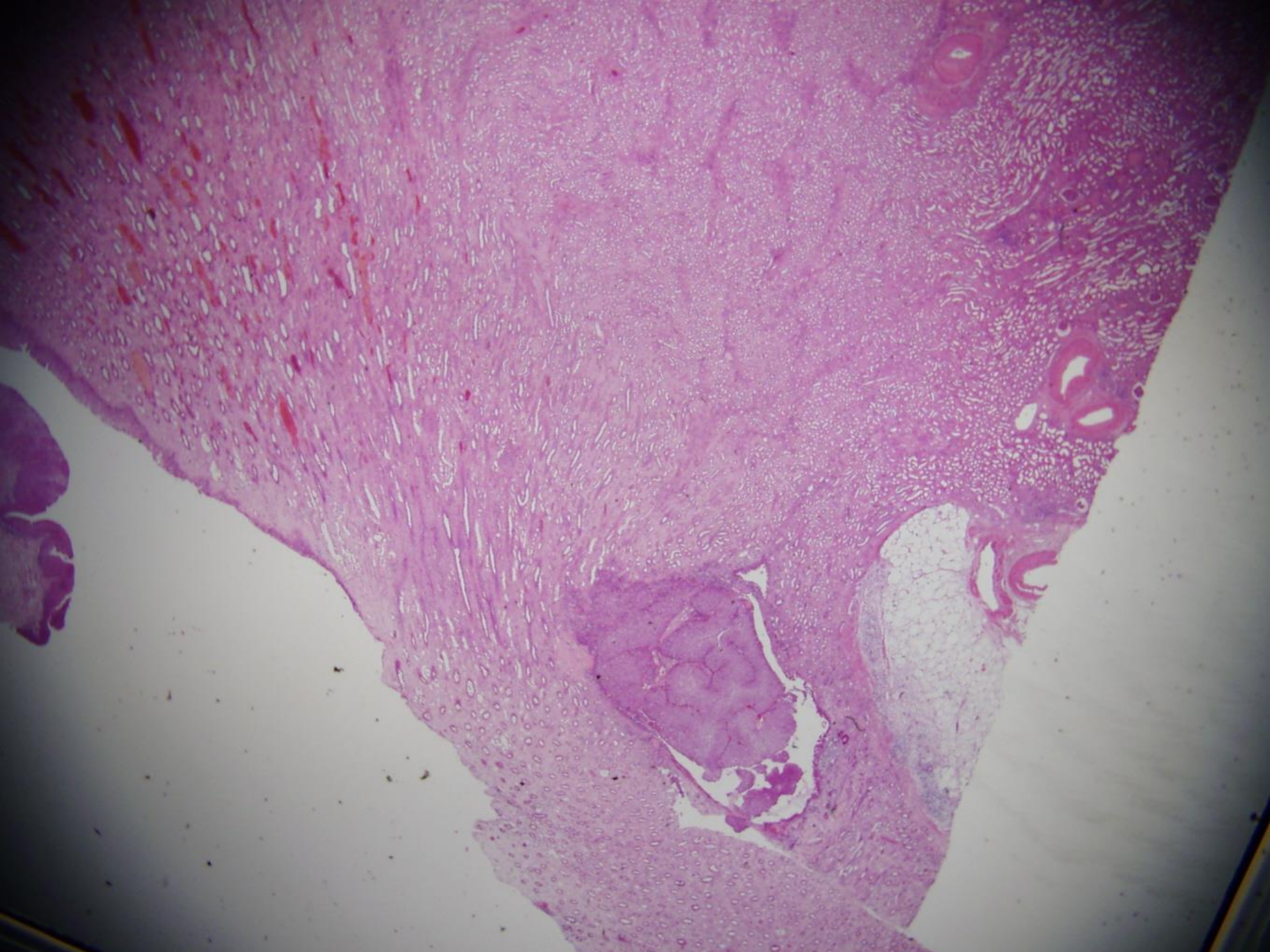


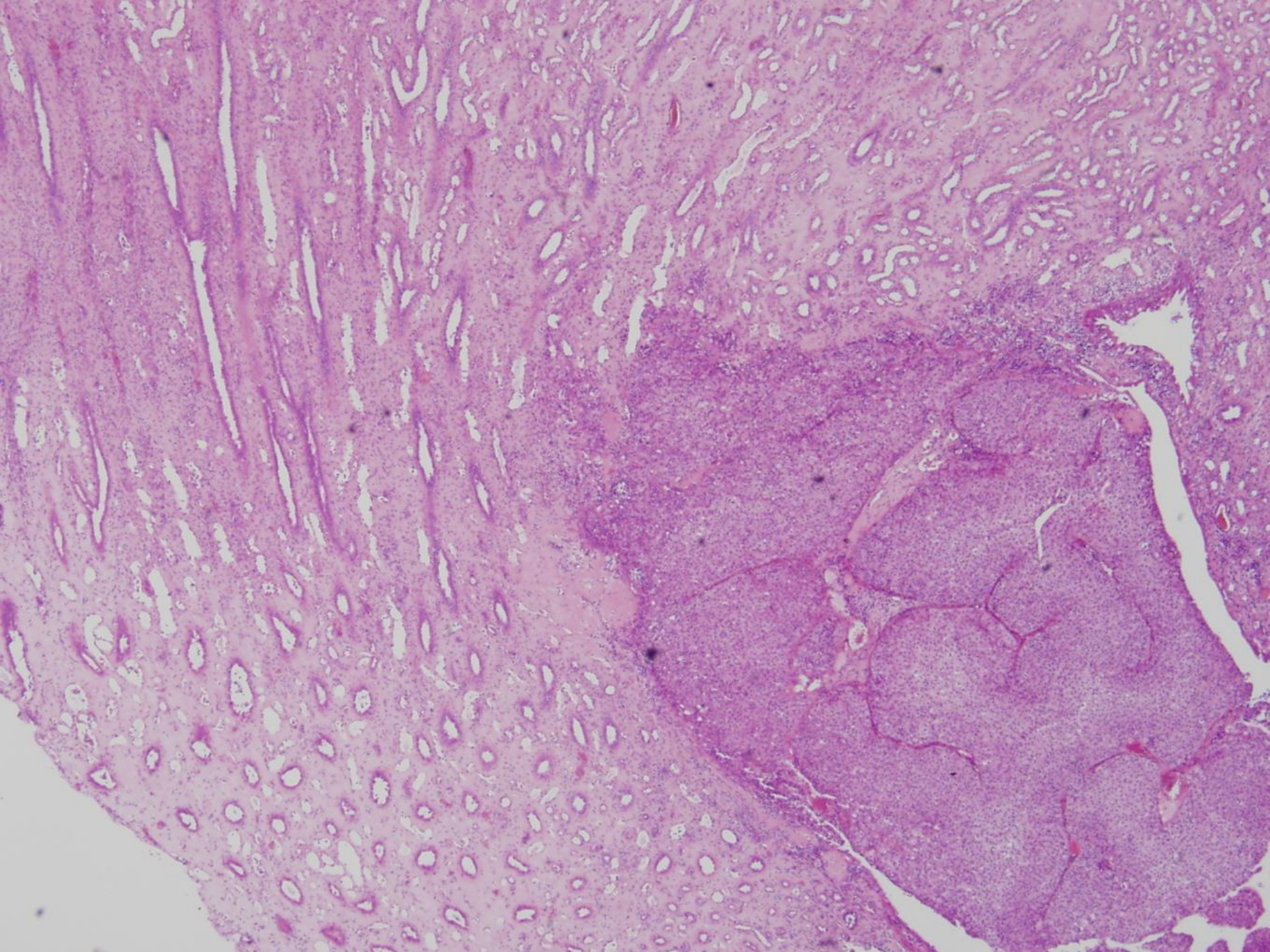
Kb. 60 éves férfi

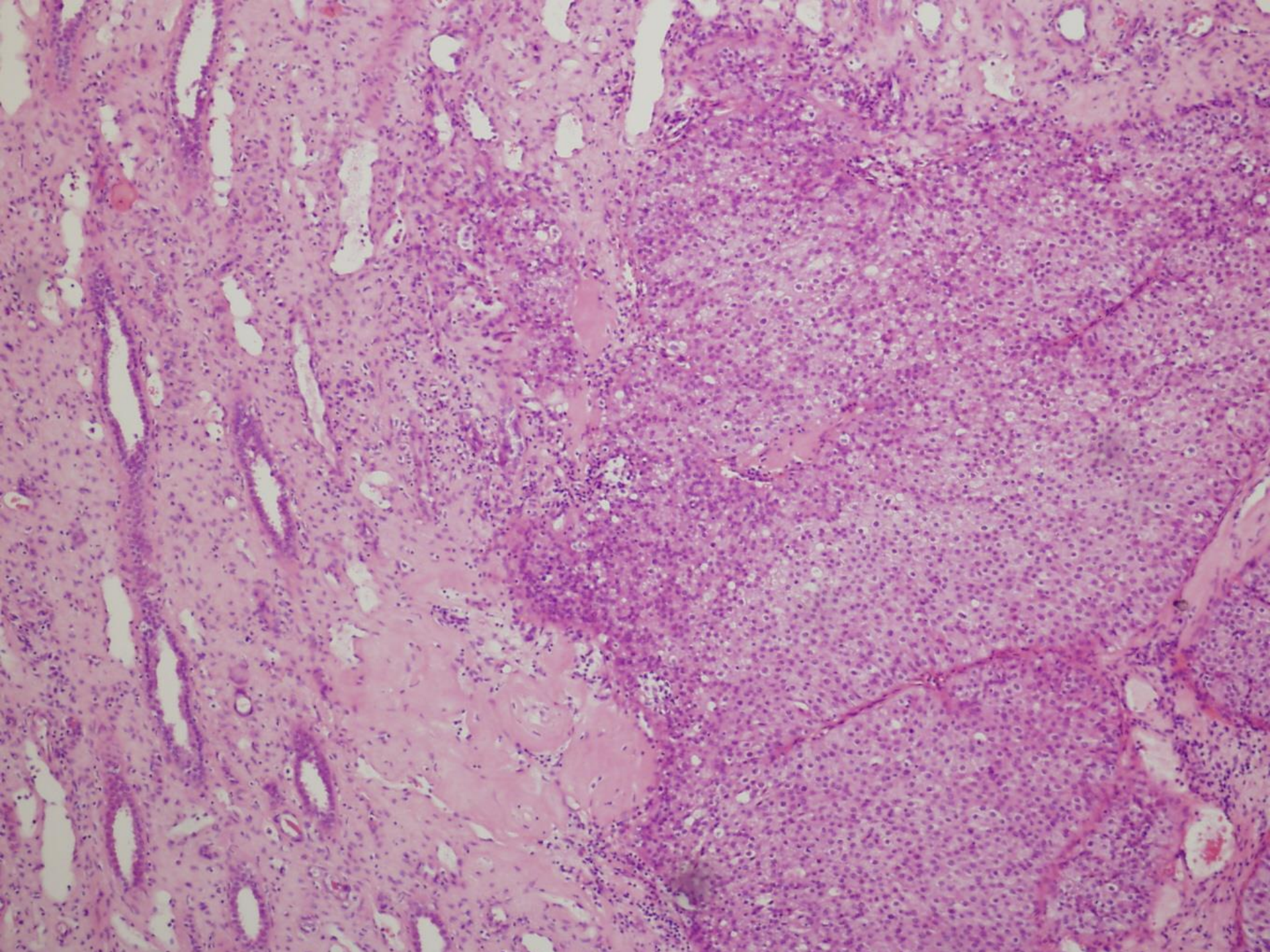
Anaemia

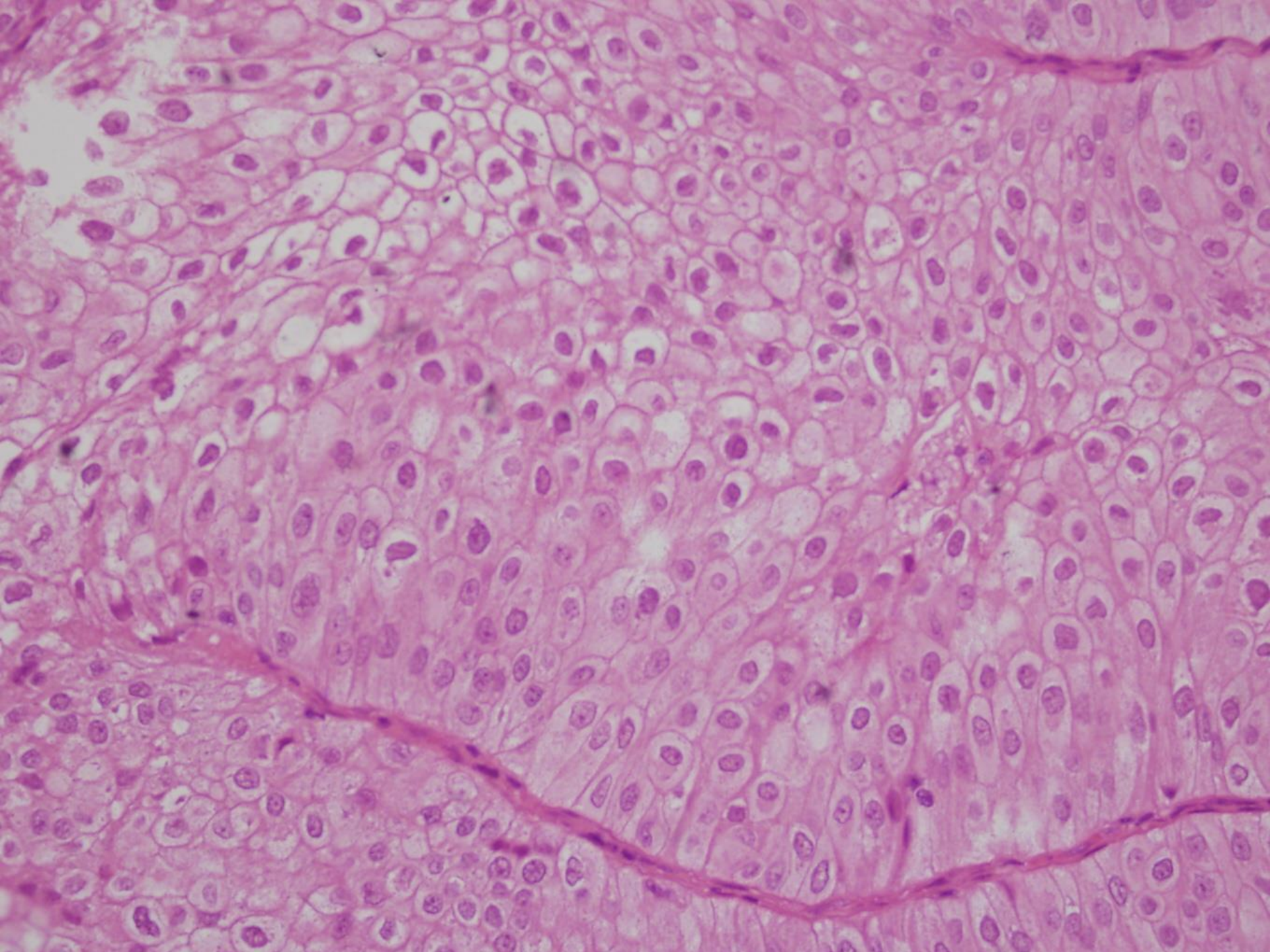
Haematuria



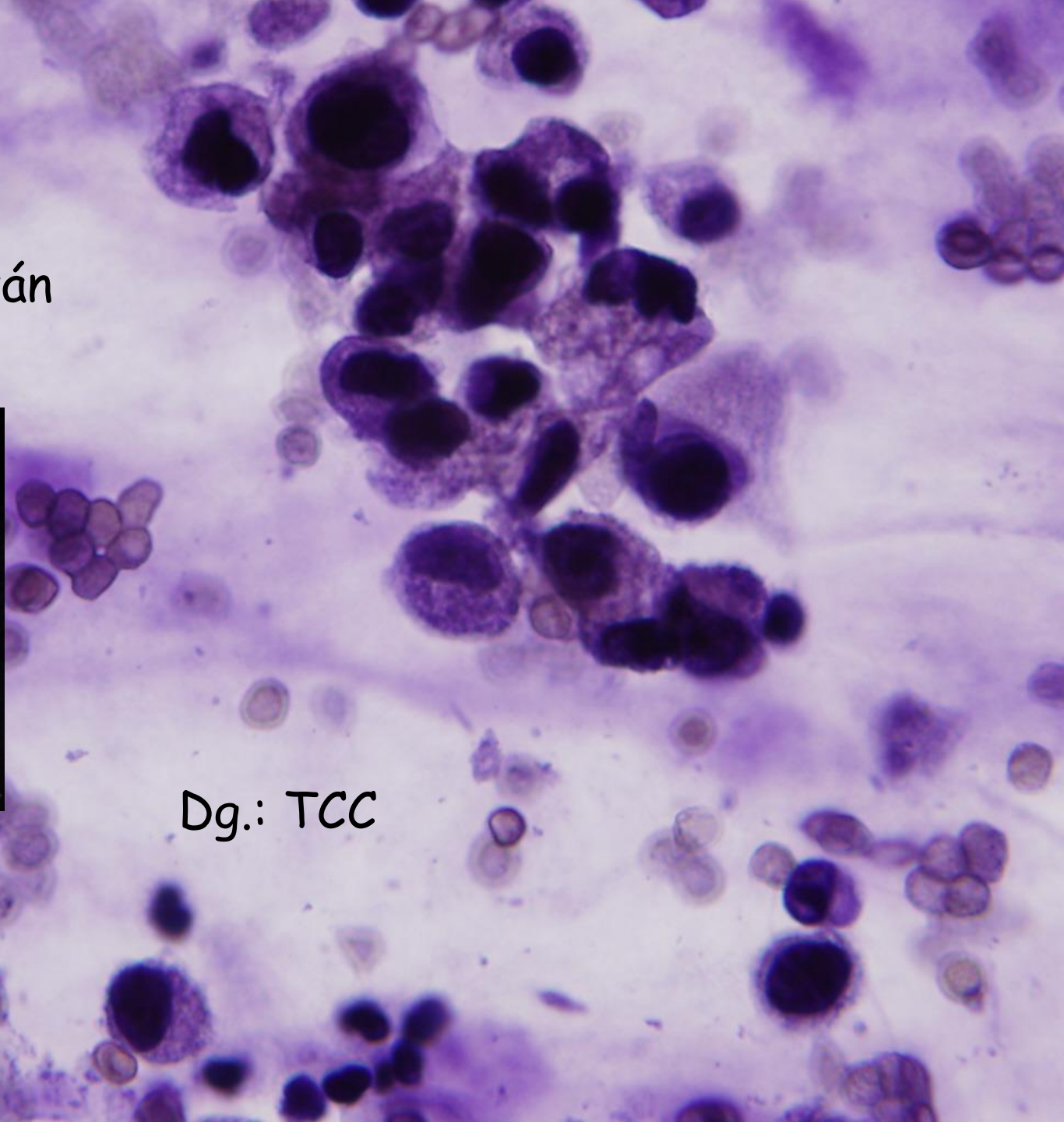
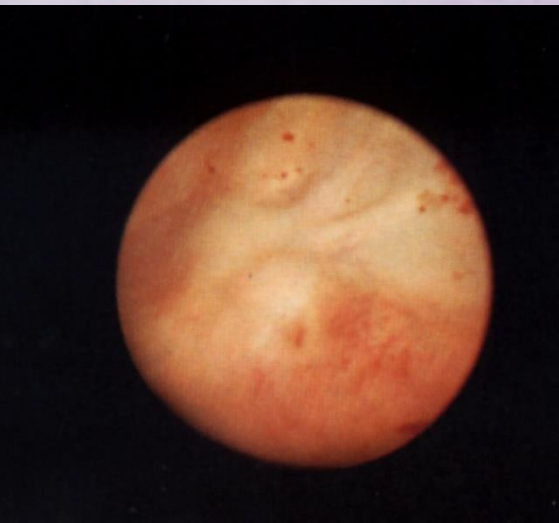



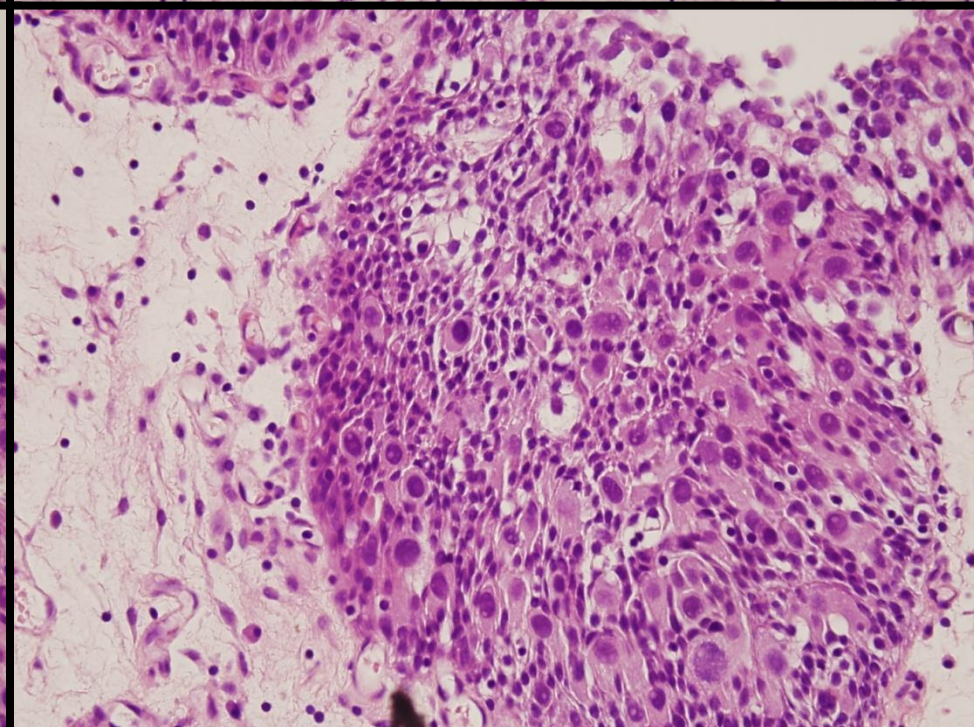
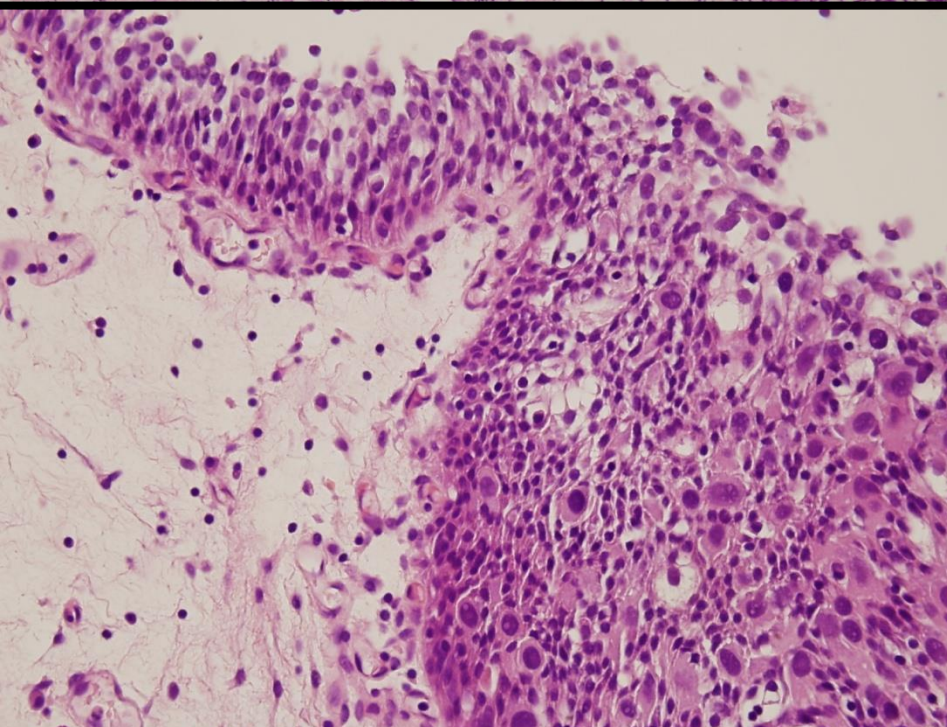
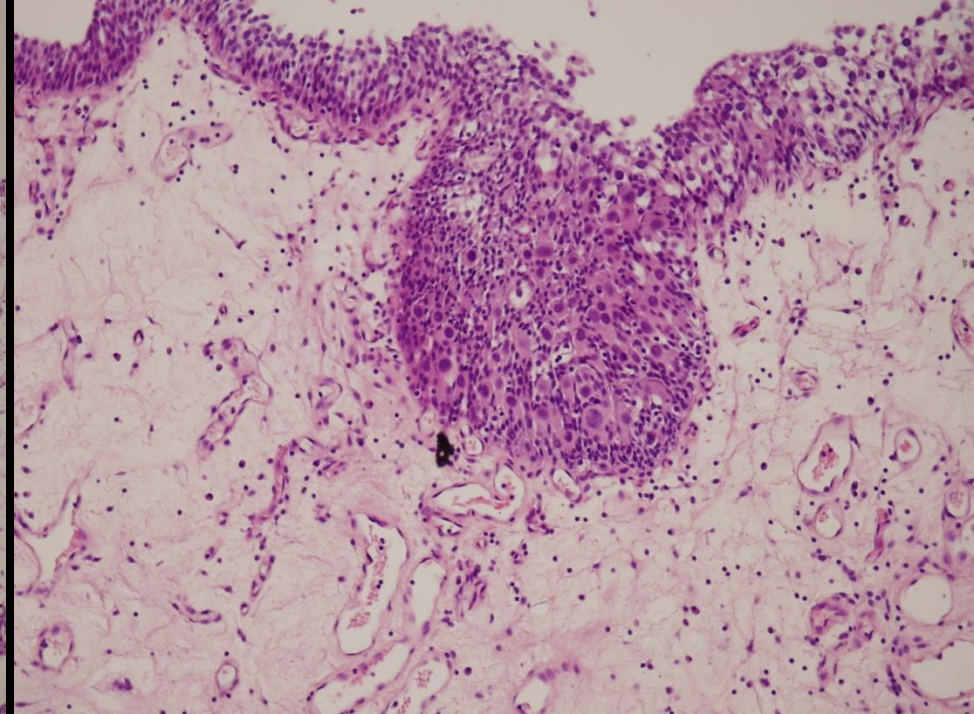
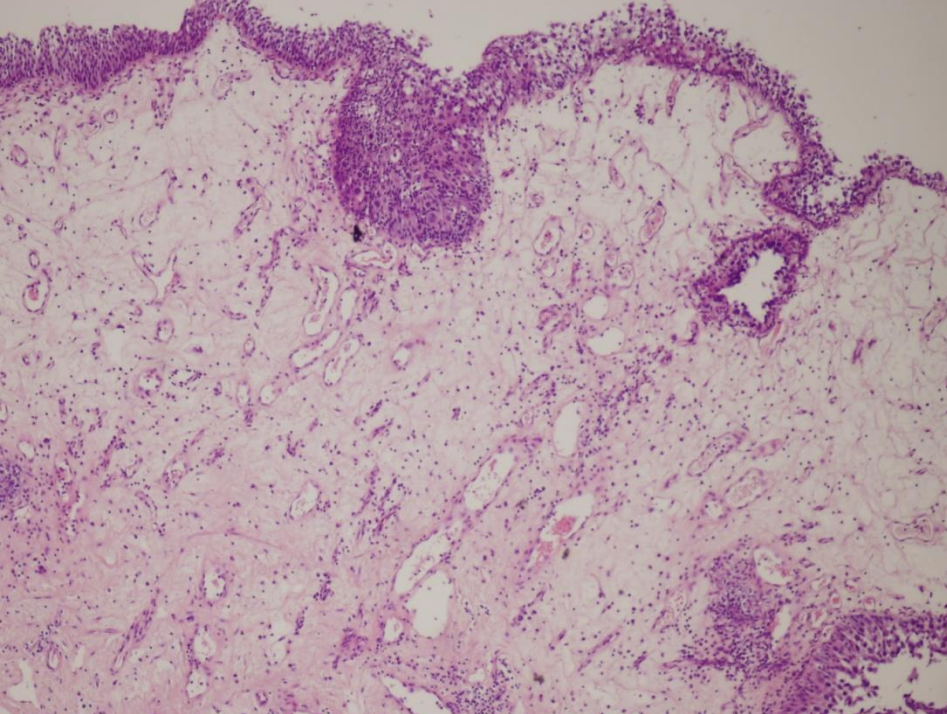


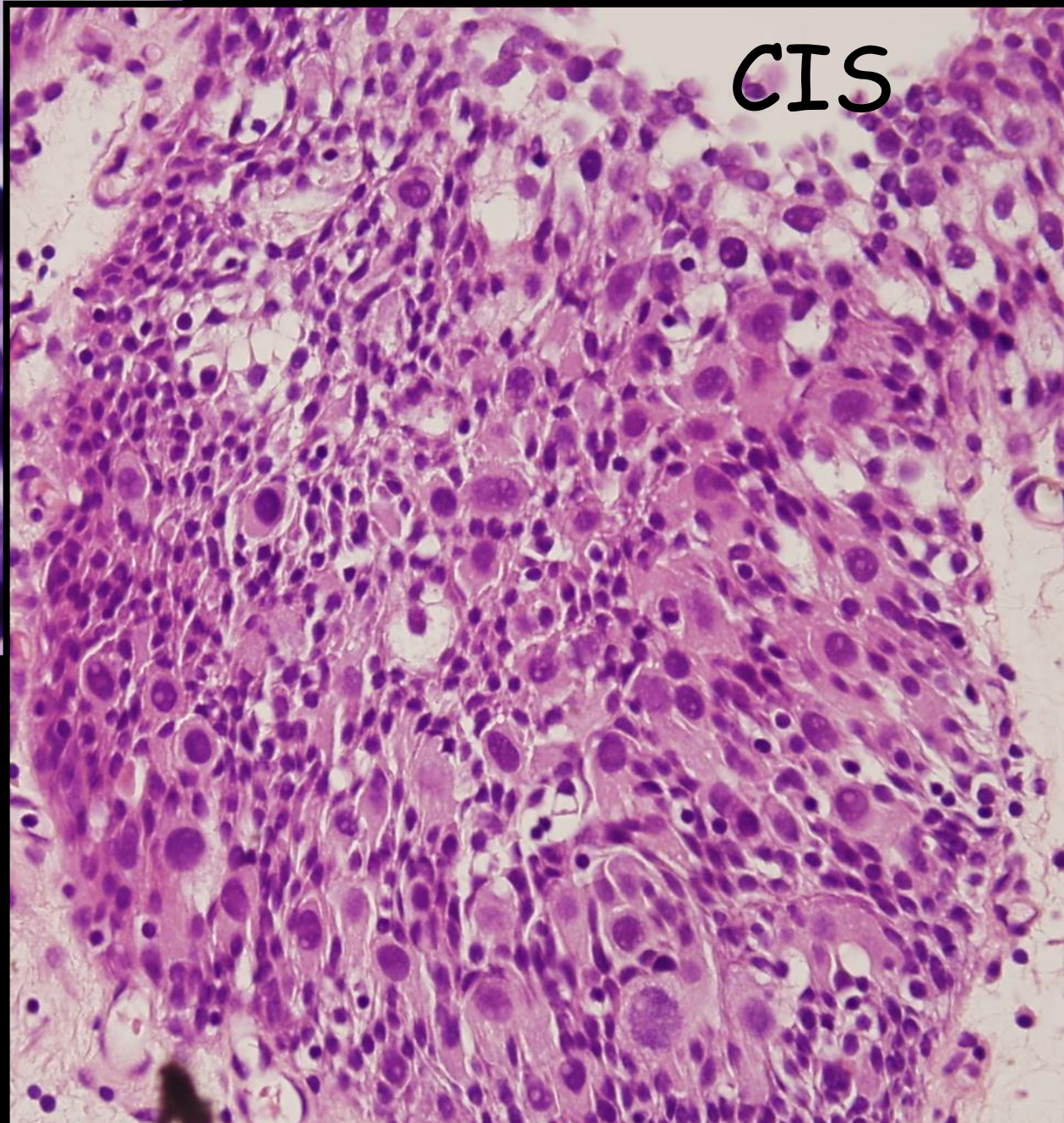
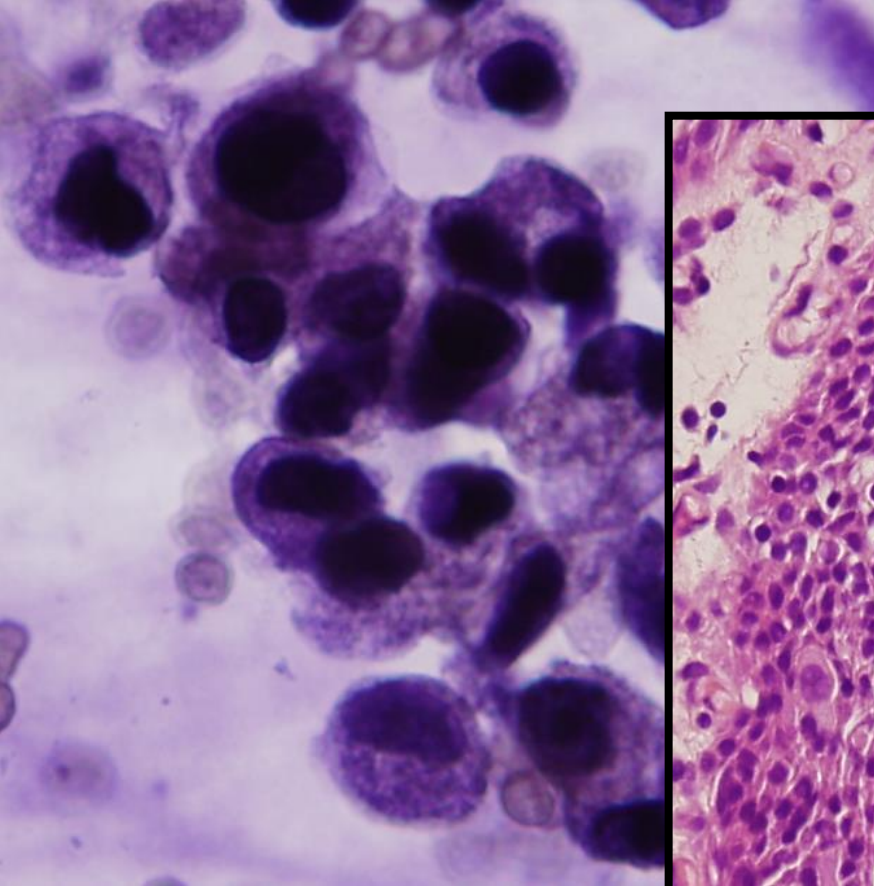


72 éves nő  
Haematuria  
Cystoscoppal a  
hólyagnyálkahártyán  
vöröses foltok.



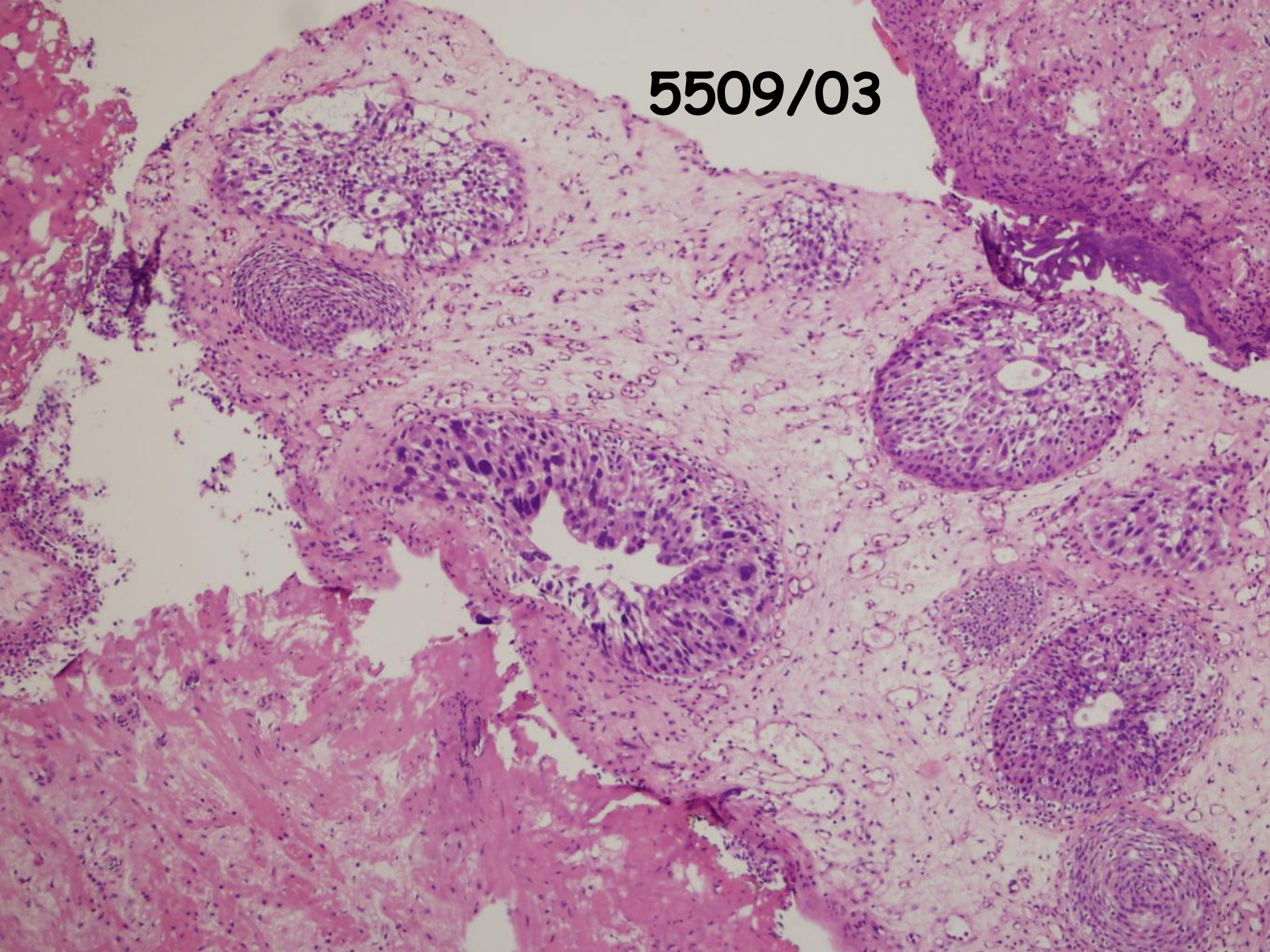
Dg.: TCC



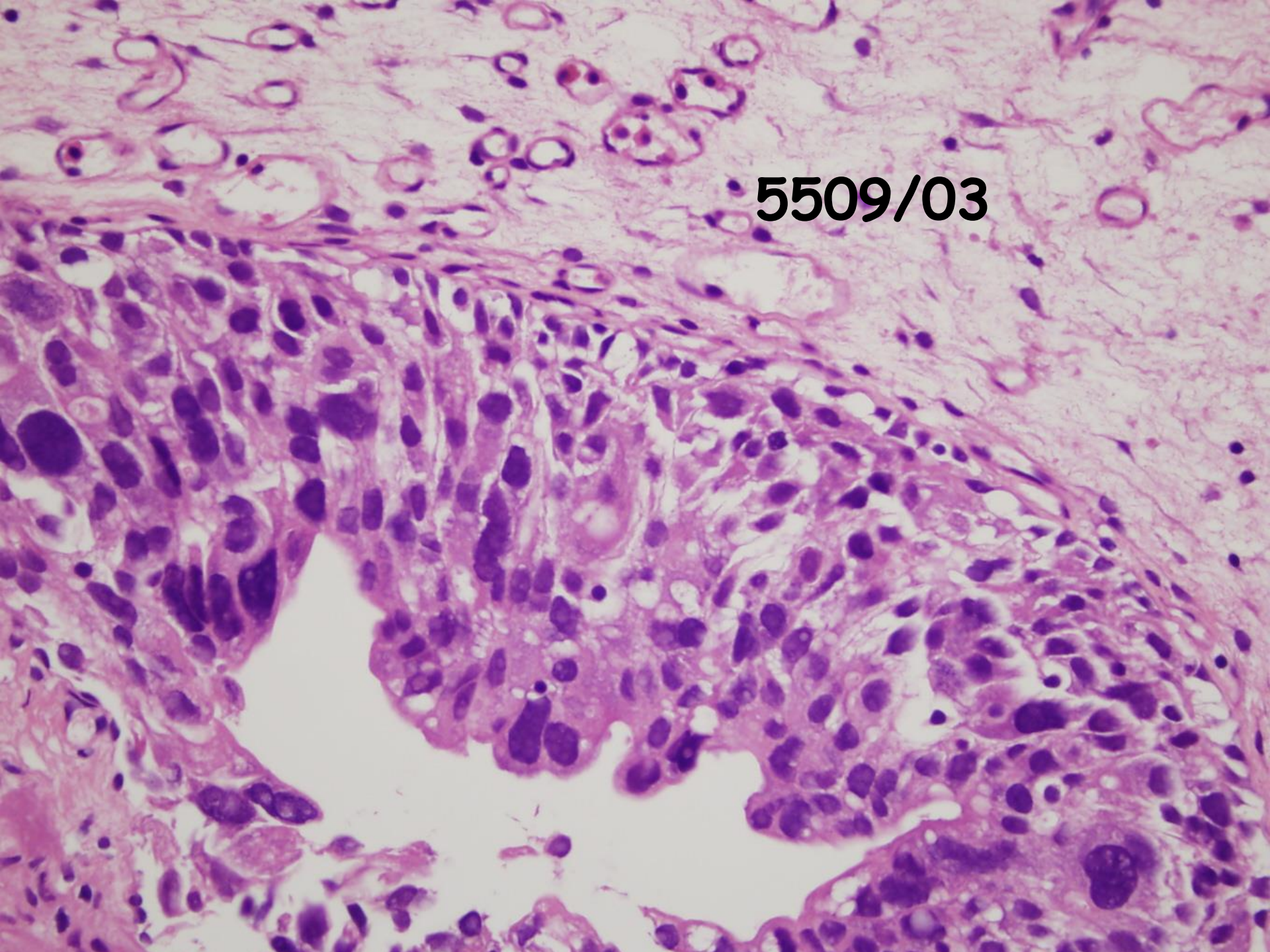




5509/03



5509/03



# CIS

Gr. III-as „lapos” tumor

Más típusú, mint a papilláris  
TCC

Prognózis sokkal rosszabb

# Hólyagdaganatok -prognózis, terápia

Papilloma, PUNLMP, LG

Ta, T1 : 98 % min. 10 év

Sebészi

Multifocalis laesiok, recidiv tumor esetén

Localis chemotherapia

CIS, HG TCC /T1


BCG instillatio

HG TCC / T2

HG TCC /T1 - BCG refracter

Cystectomy

# TCC + SQCC

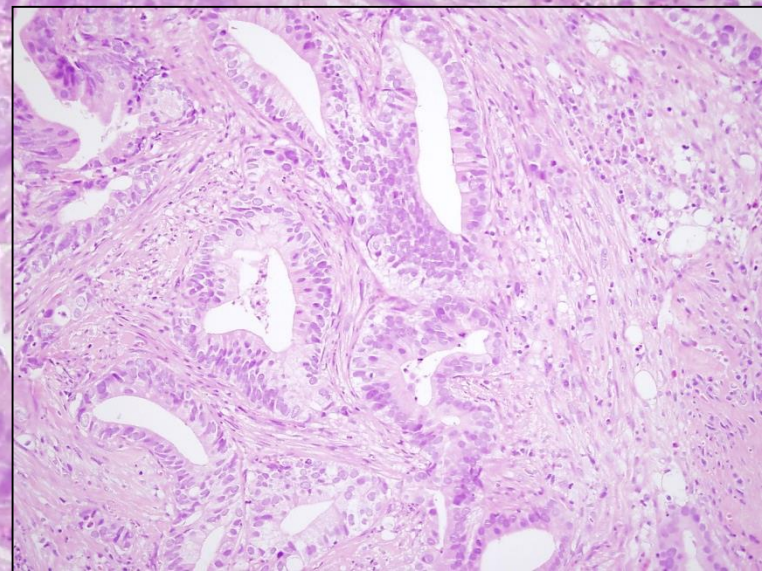
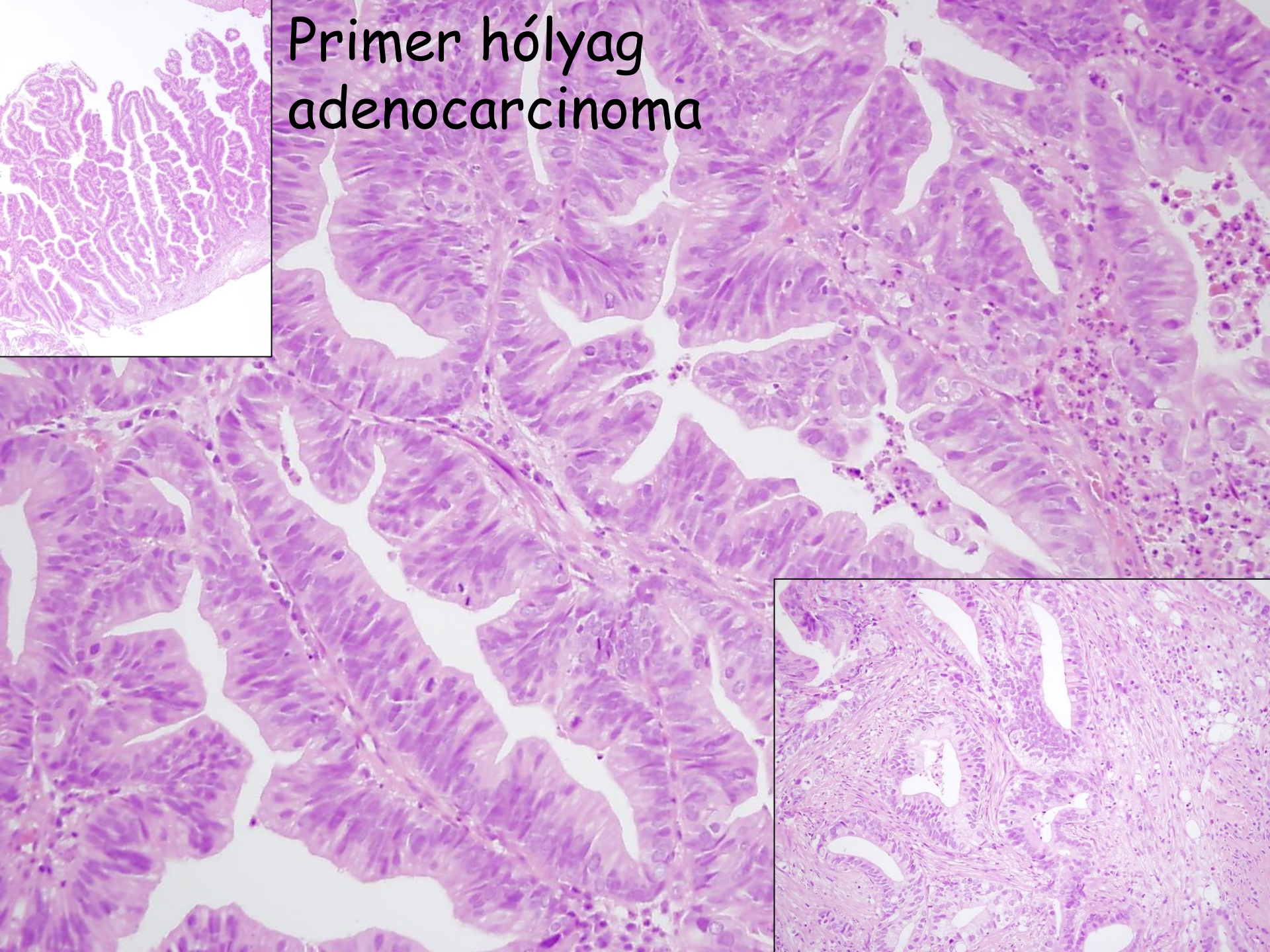
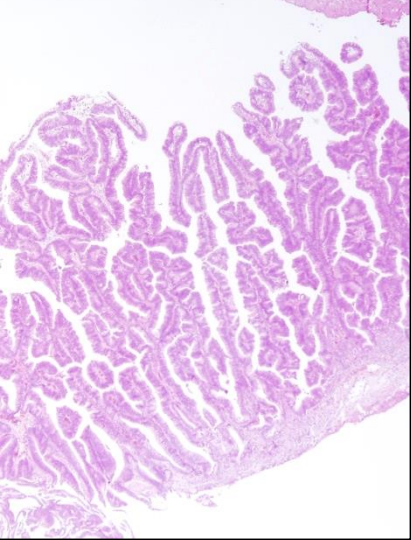


Gyakran keveredik „hagyományos” TCC-vel

Laphámmetaplasia (chr. irritáció, gyulladás, schistosoma, cyclophosphamid)

Bármilyen formában, ha SQCC komponens is van, a prognózis rosszabb

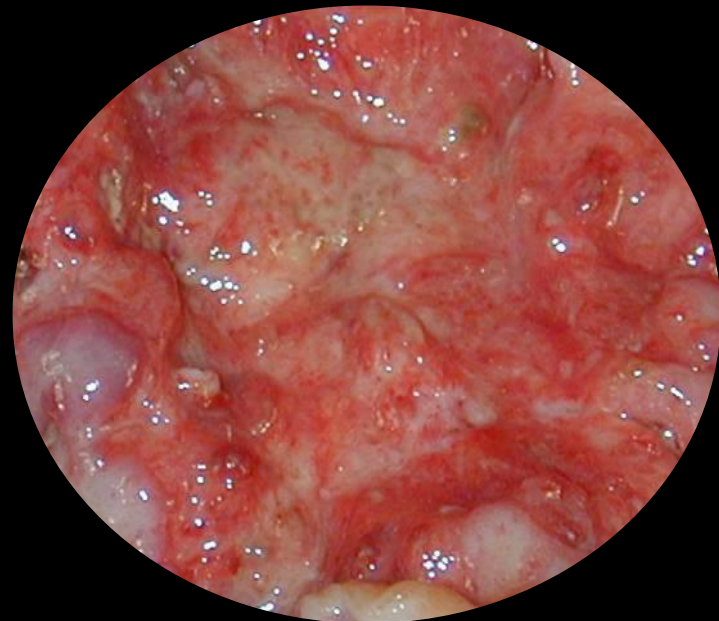# Primer hólyag adenocarcinoma

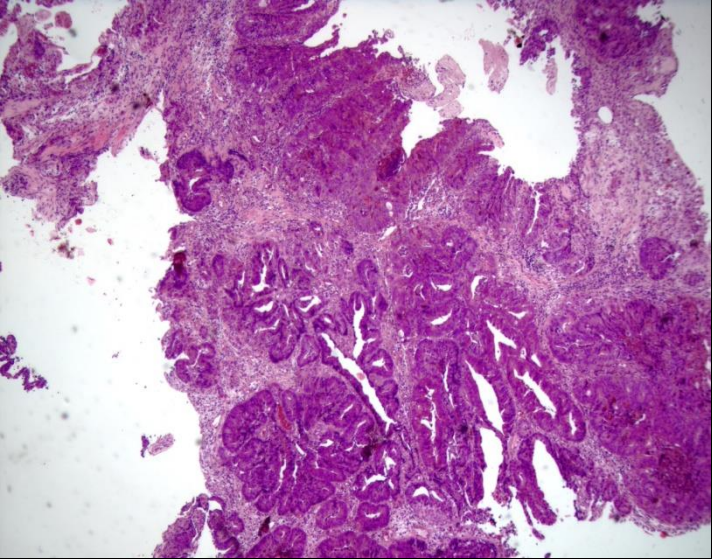


57 éves nő

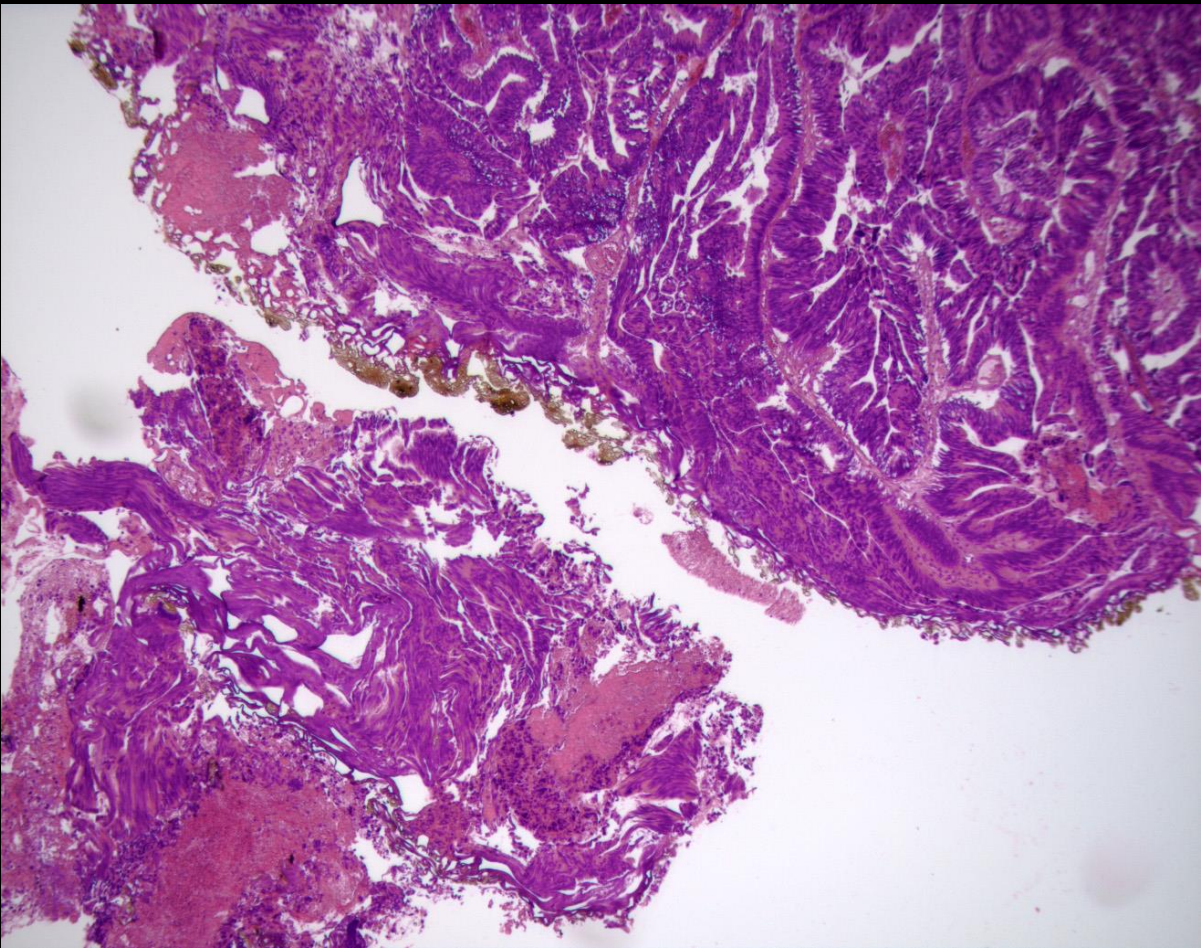
Hólyagban szélesen ülő polypoid tumor

TCC?

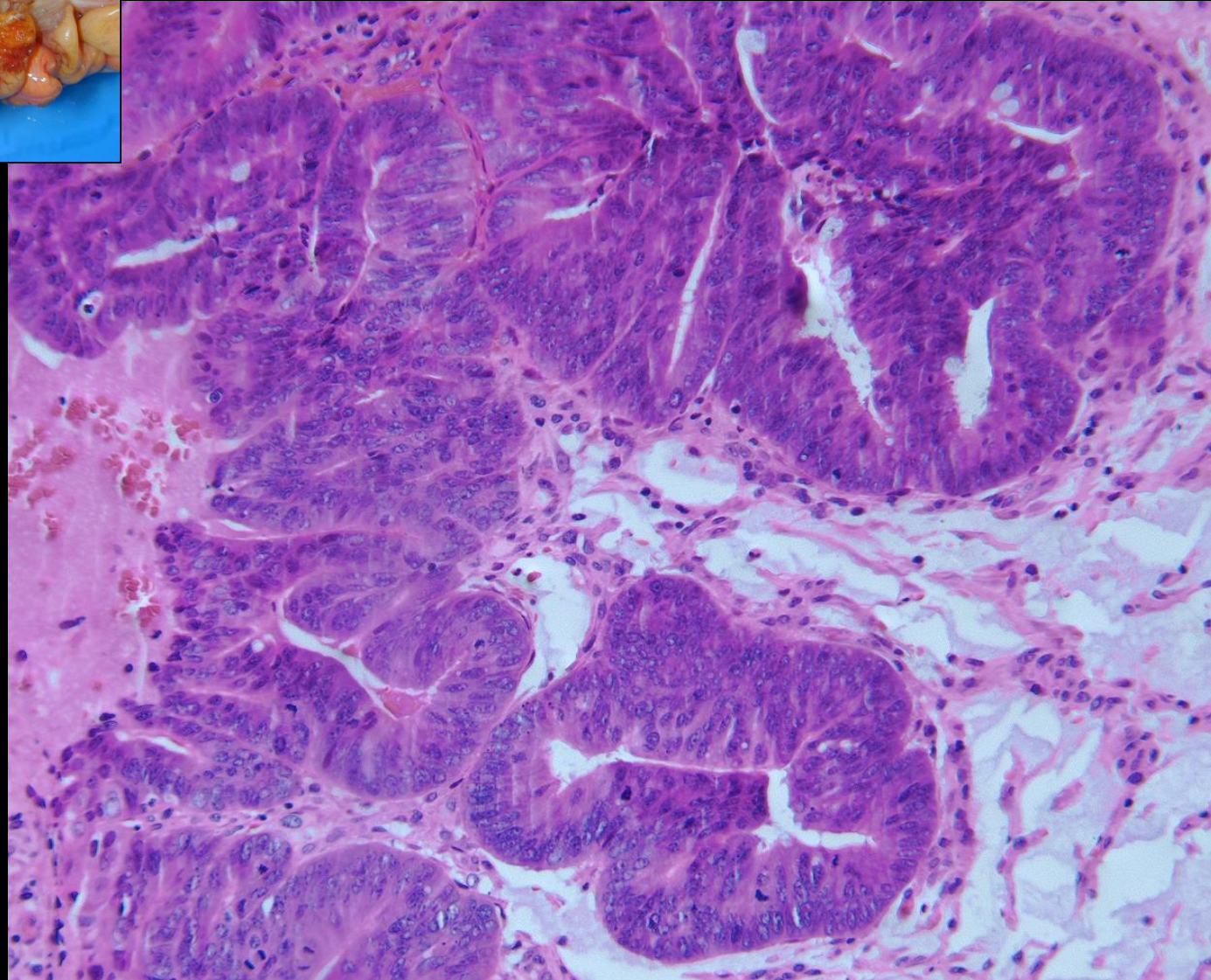
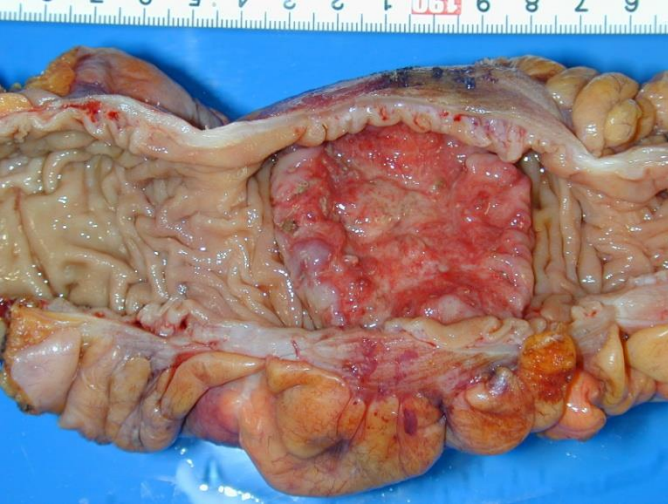




Dg.: Hólyagba  
törő adeno-  
carcinoma,  
colonoscopia  
javasolt!





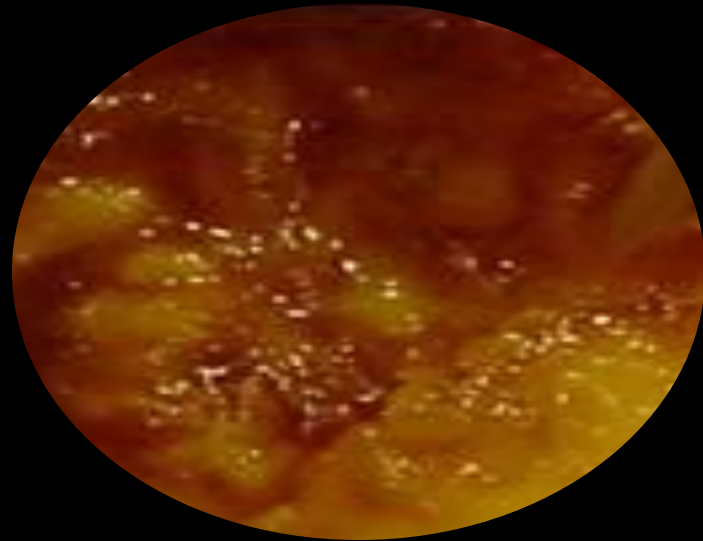


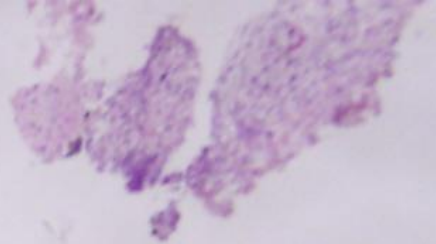
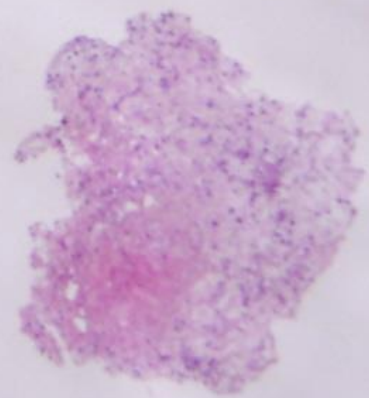
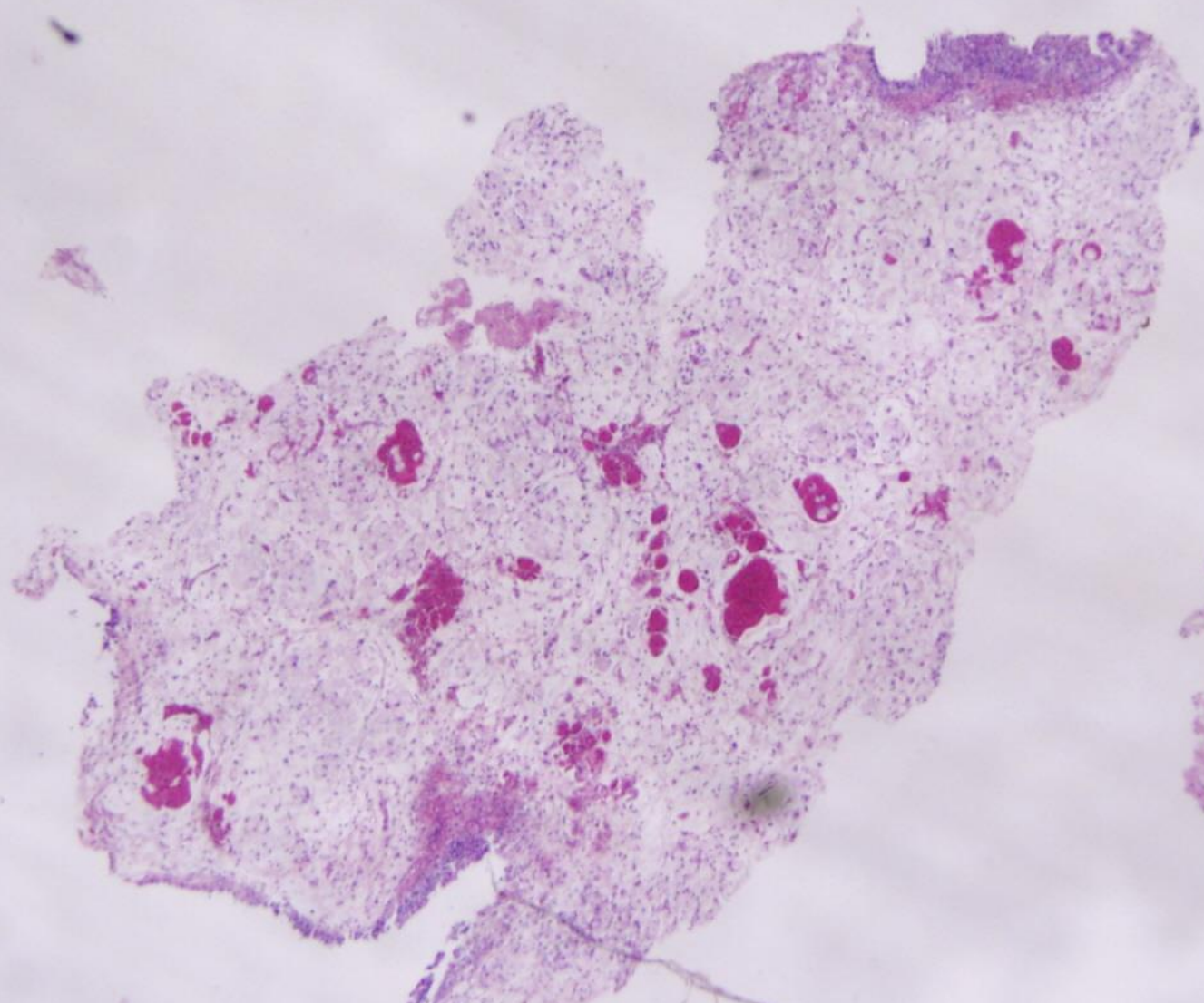
45 éves nő

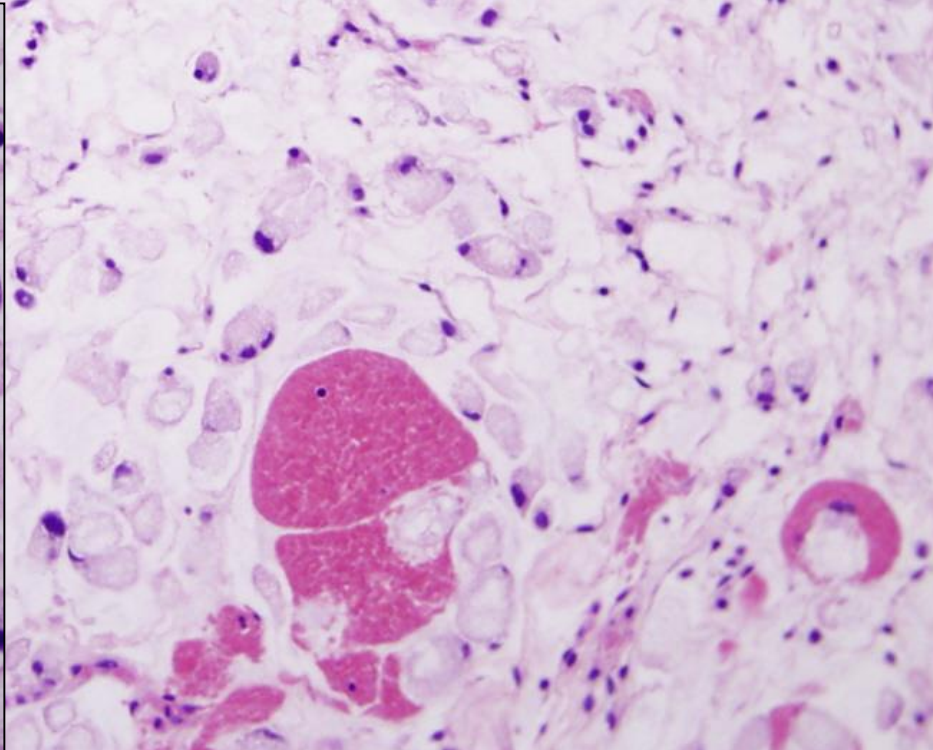
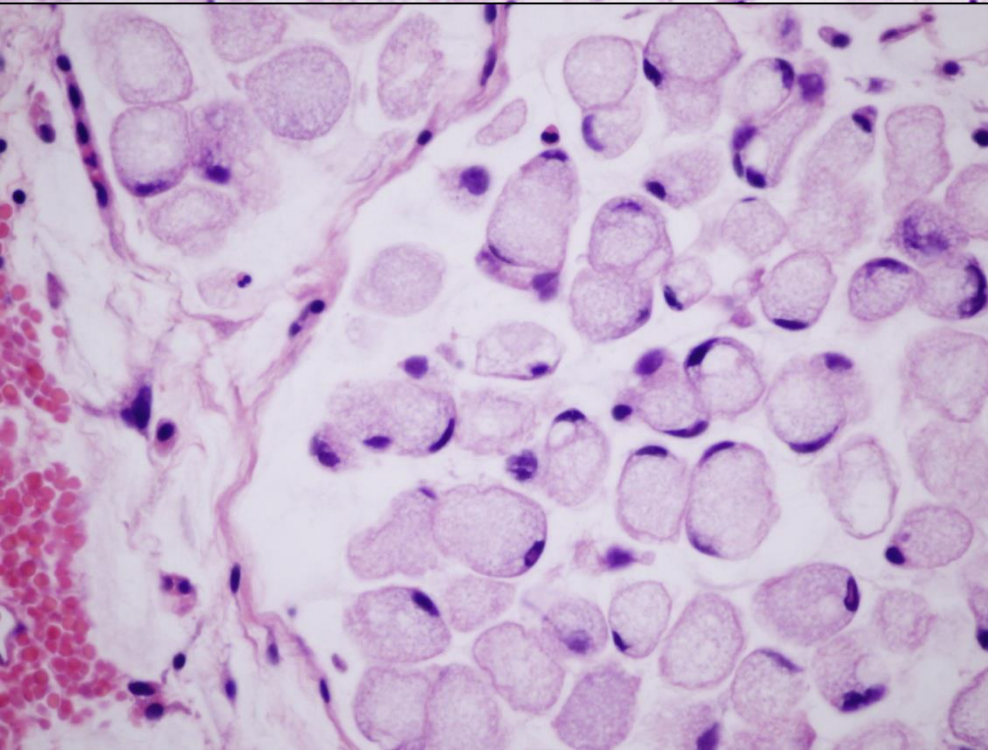
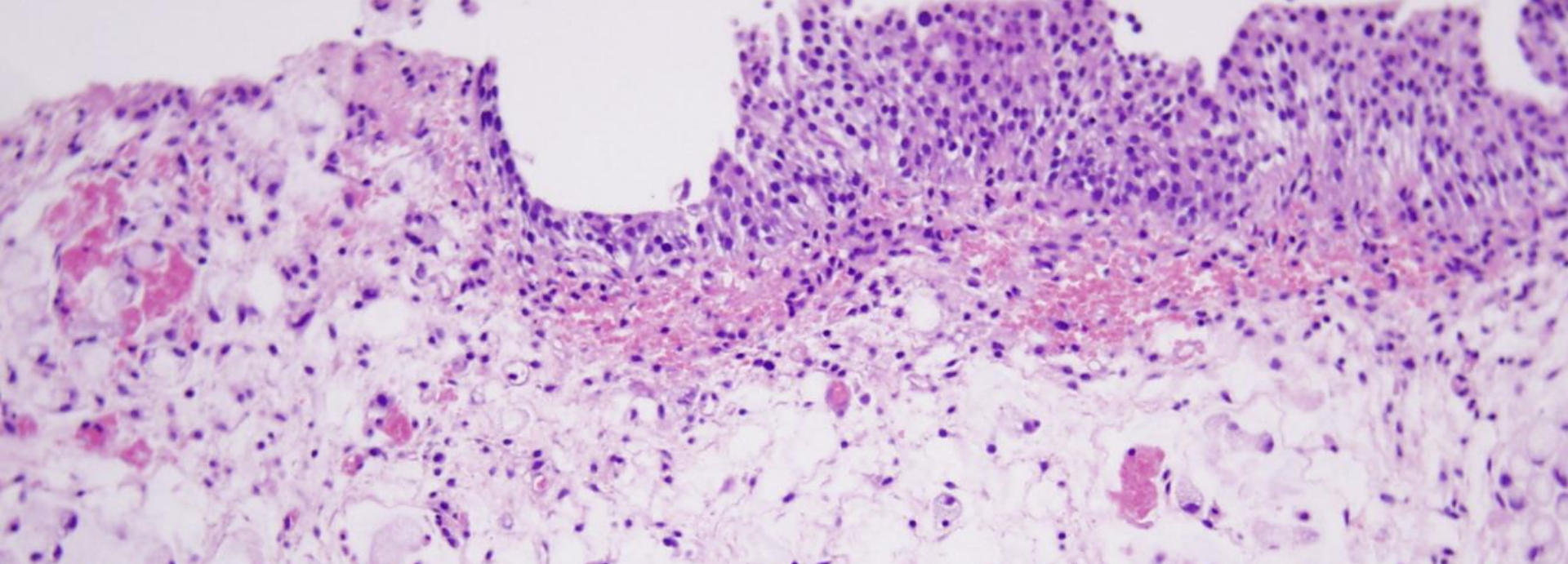
Haematuria

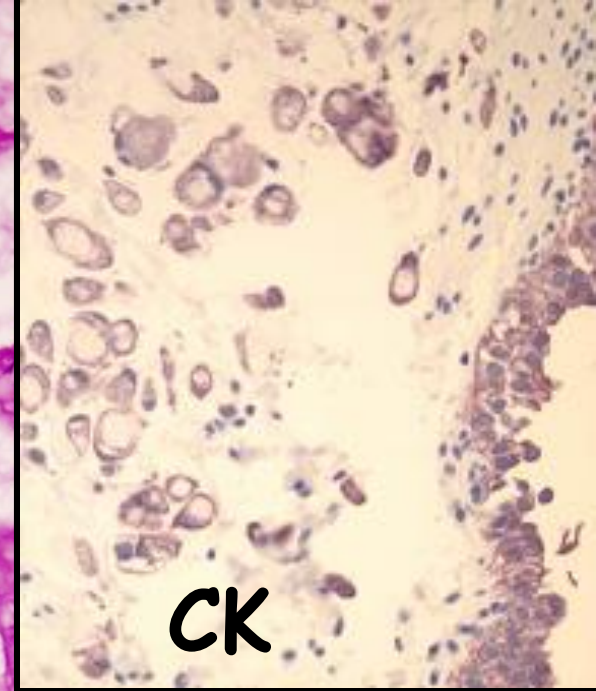
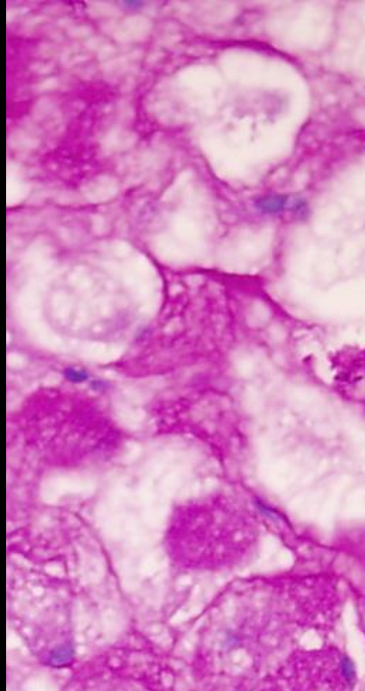
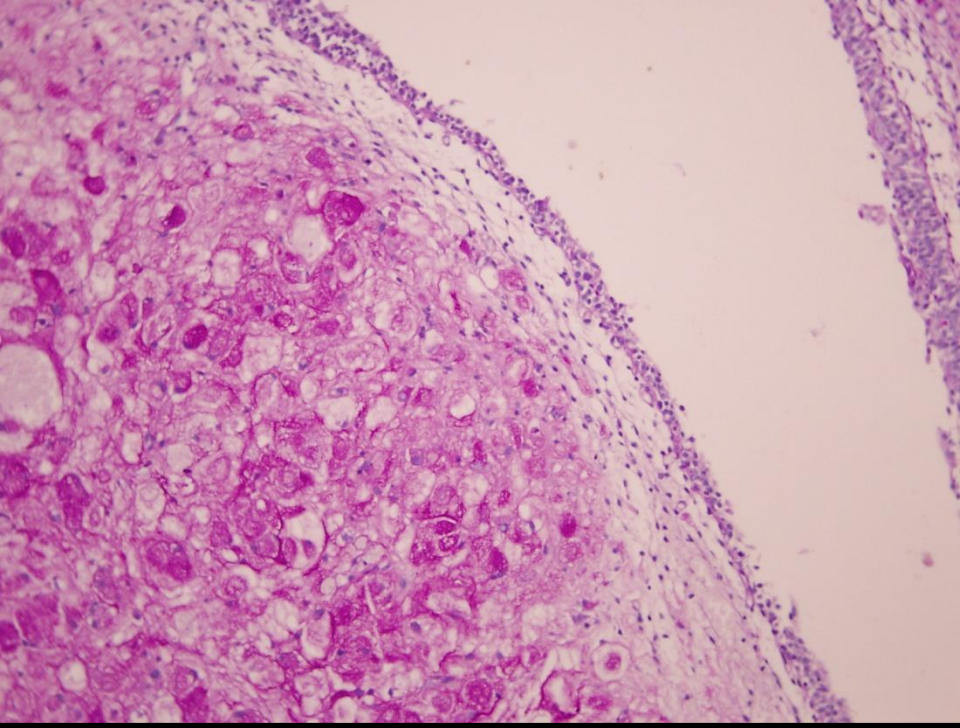
Cystoscoppal lapos , exulcerált  
elváltozás

???

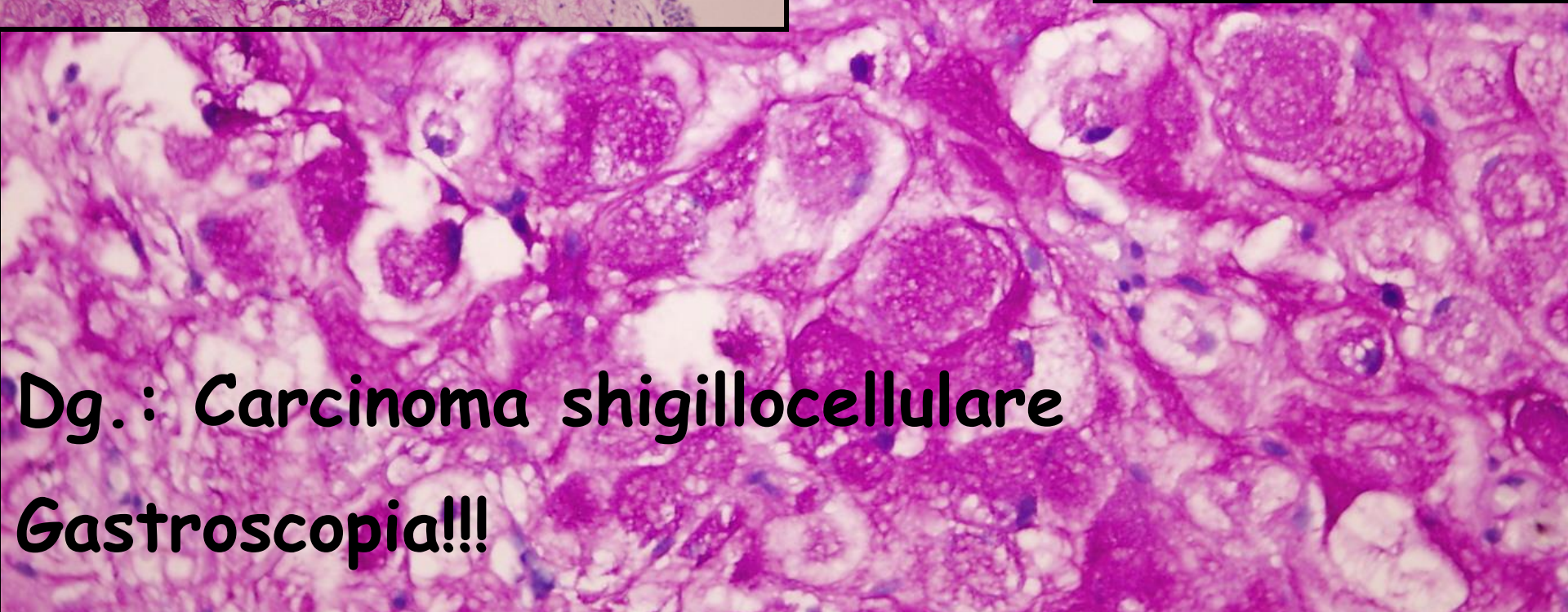




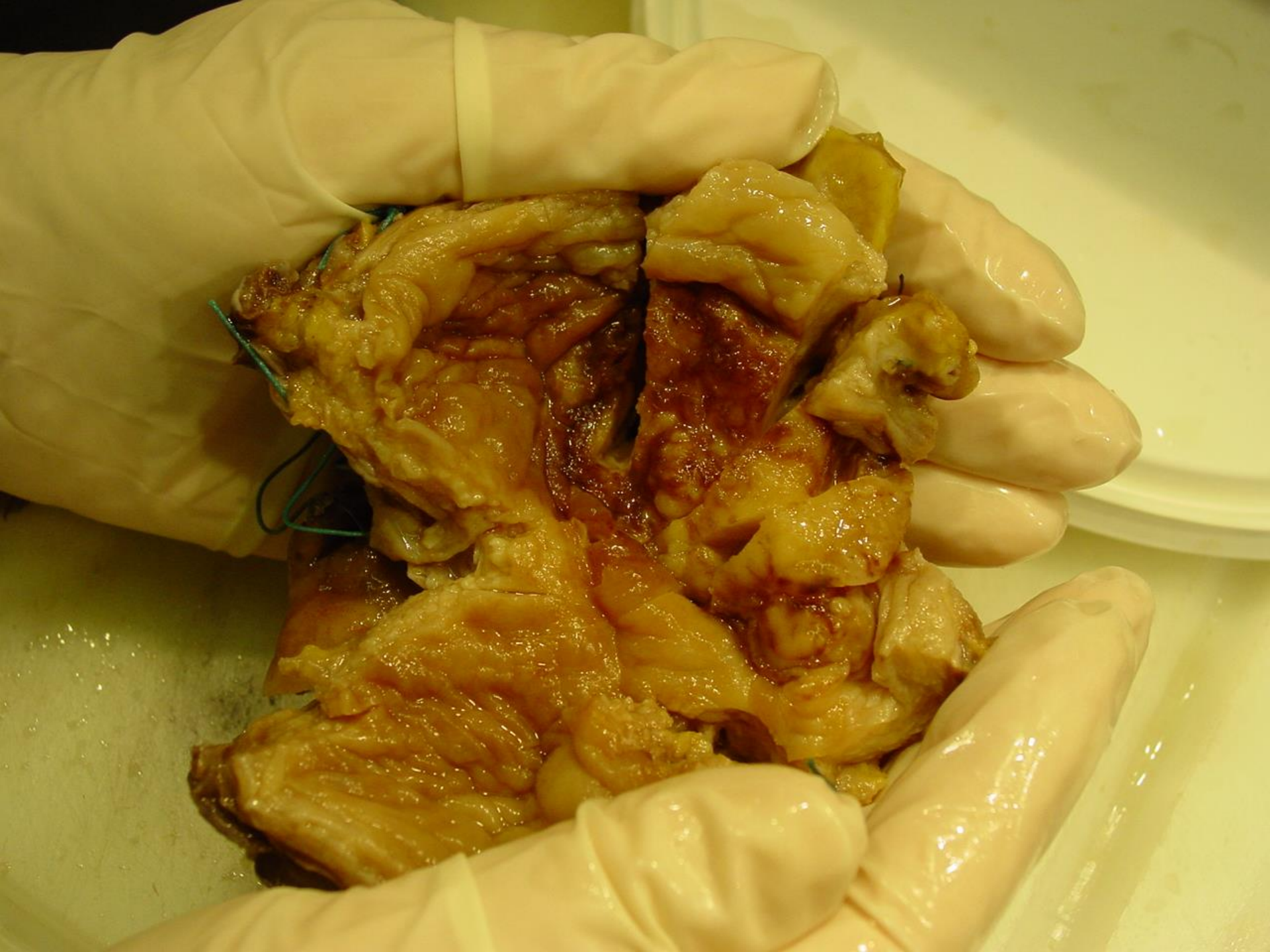

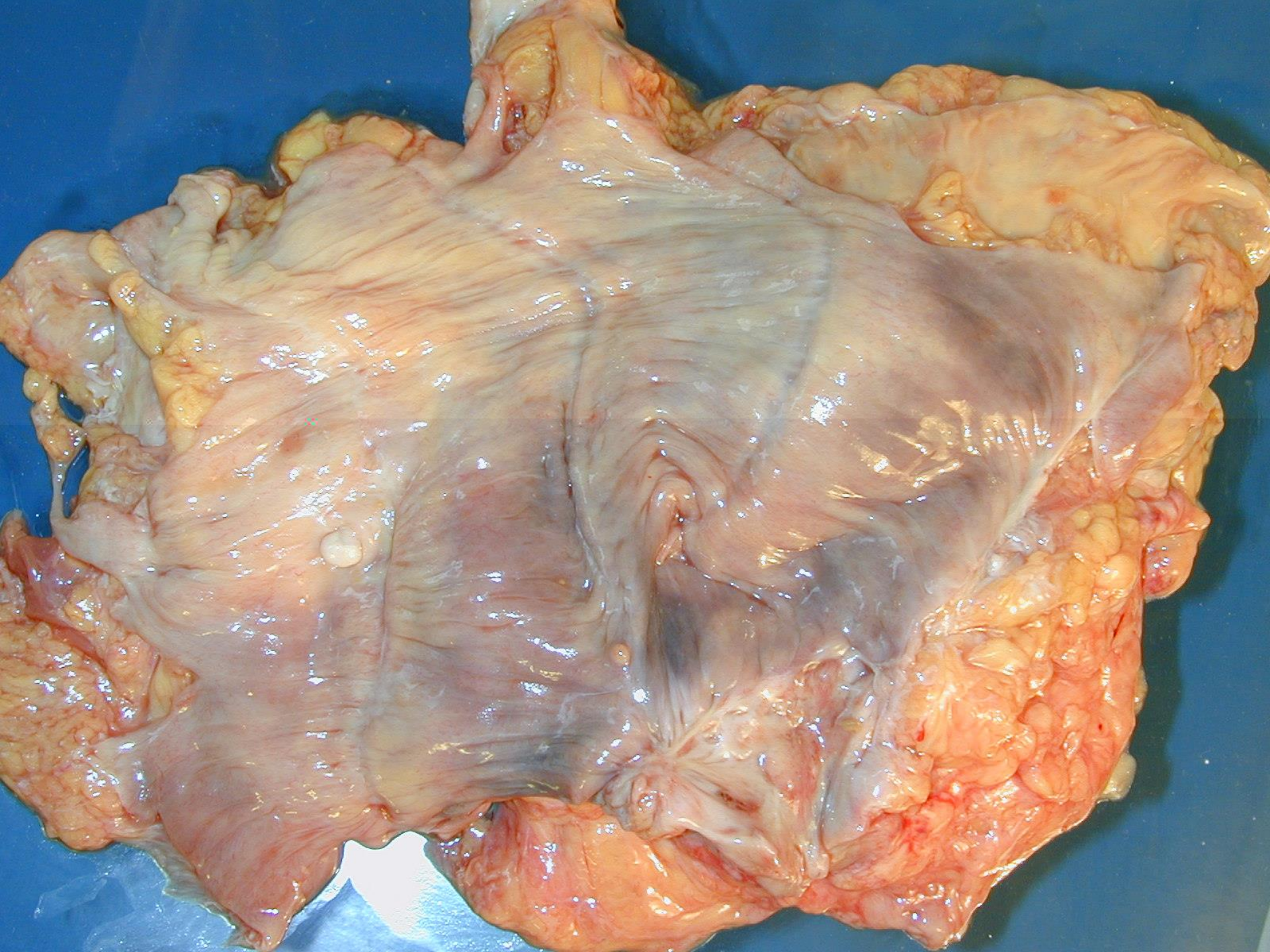


**CK**

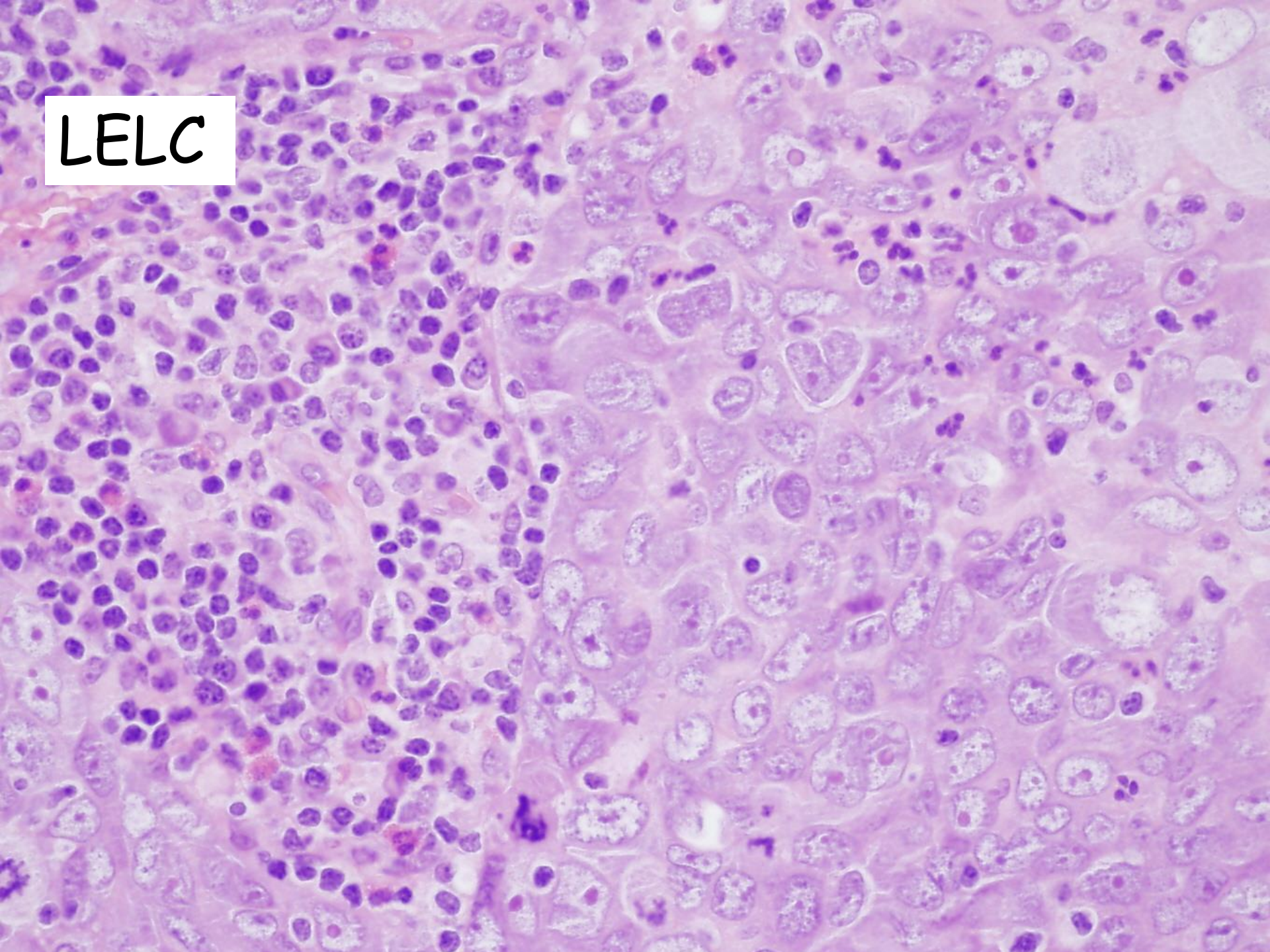


**Dg.: Carcinoma shigillocellulare**  
**Gastroscoopia!!!**





LELC



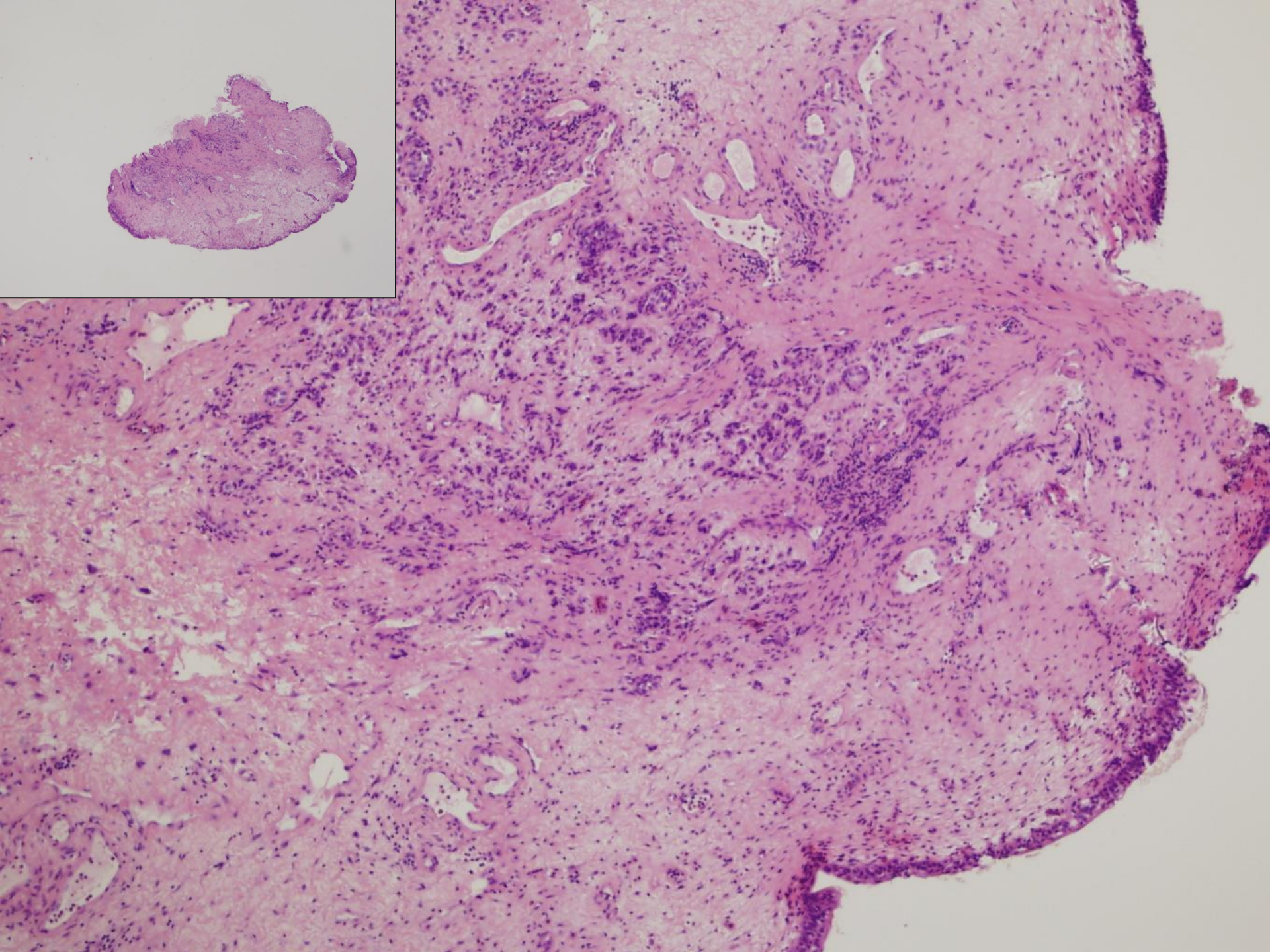


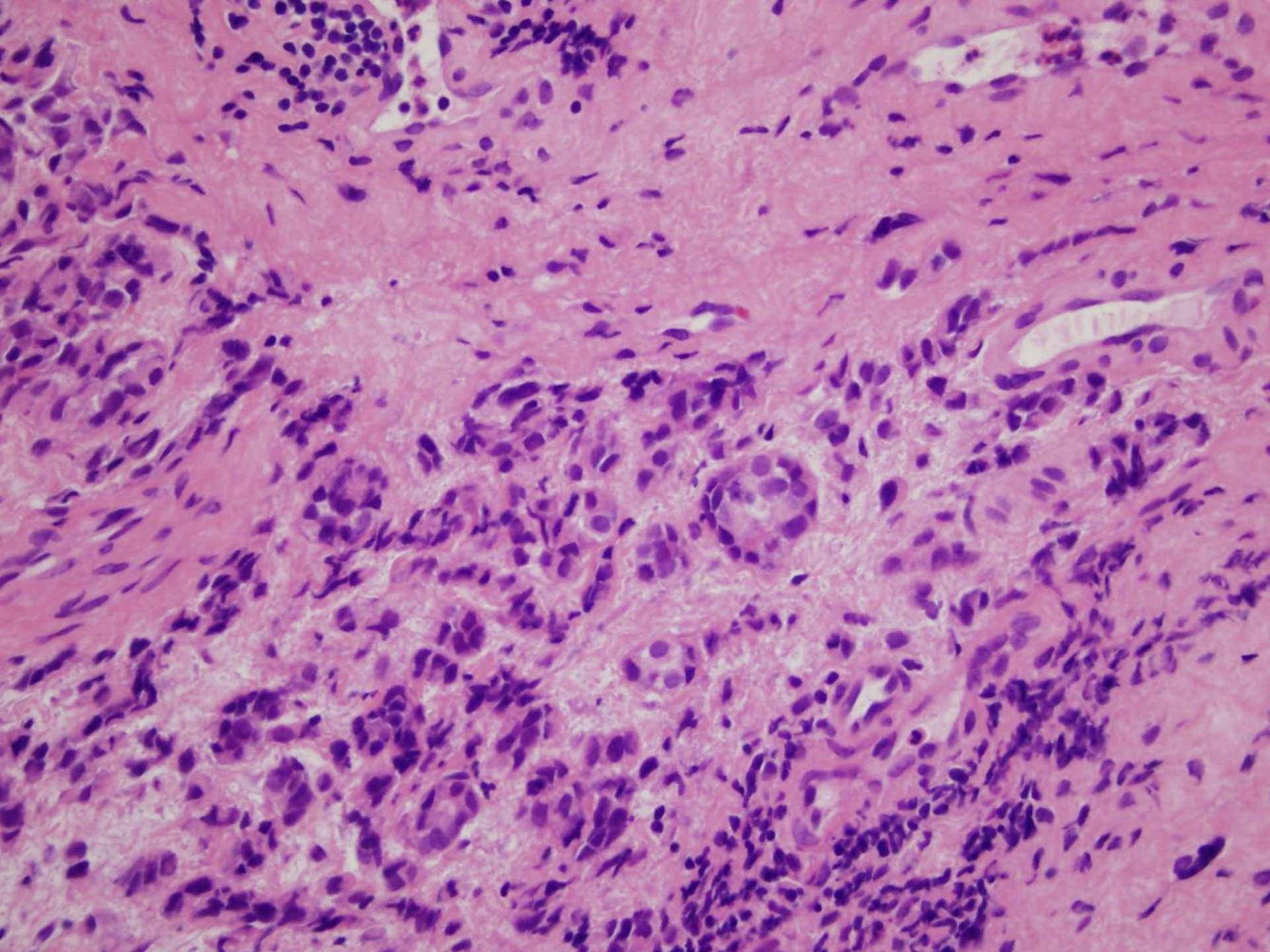
5065/03

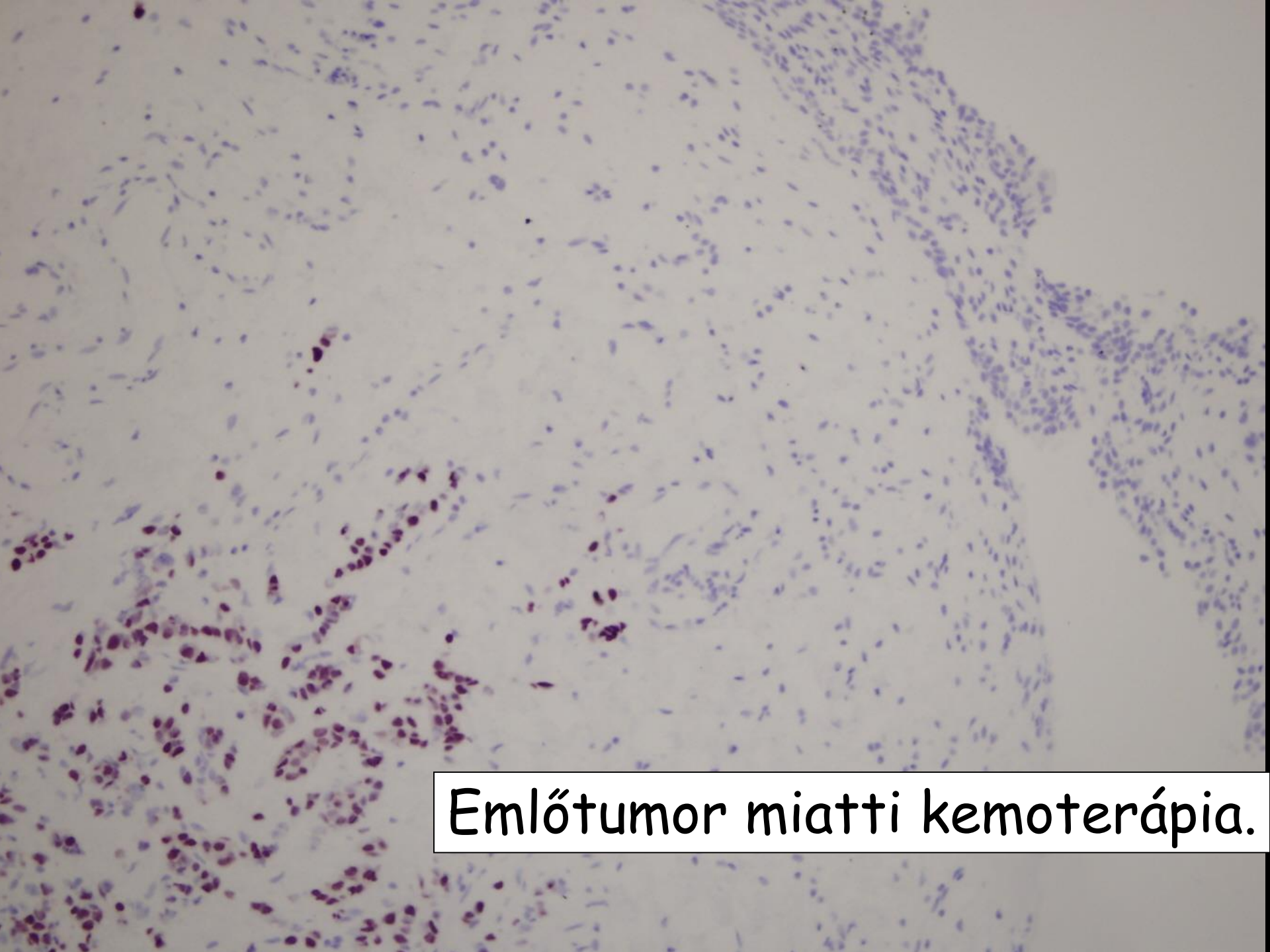
O. Jné, 63 éves

Mko-i vese üregrendszeri tágulat,  
hólyagfal vastagodás

Cystoscopia: a hátsó falon hyperaemiás  
terület

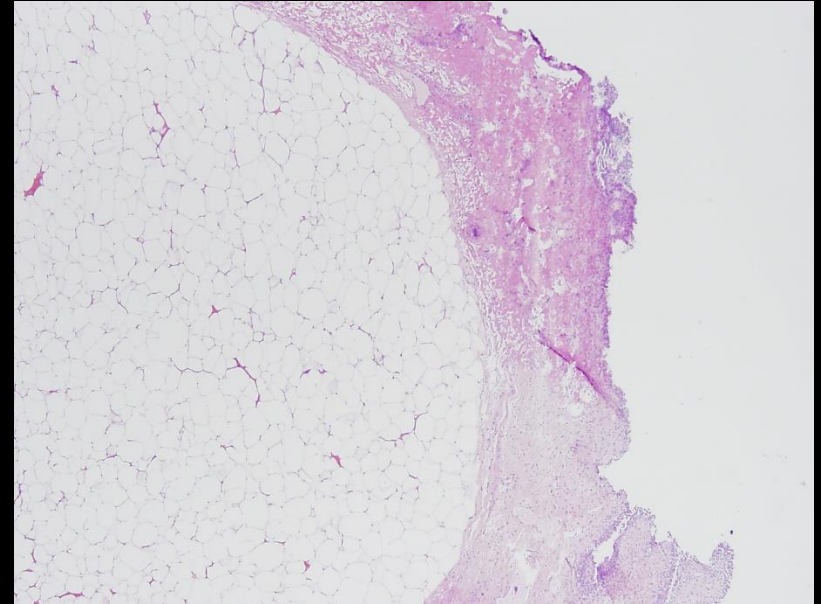
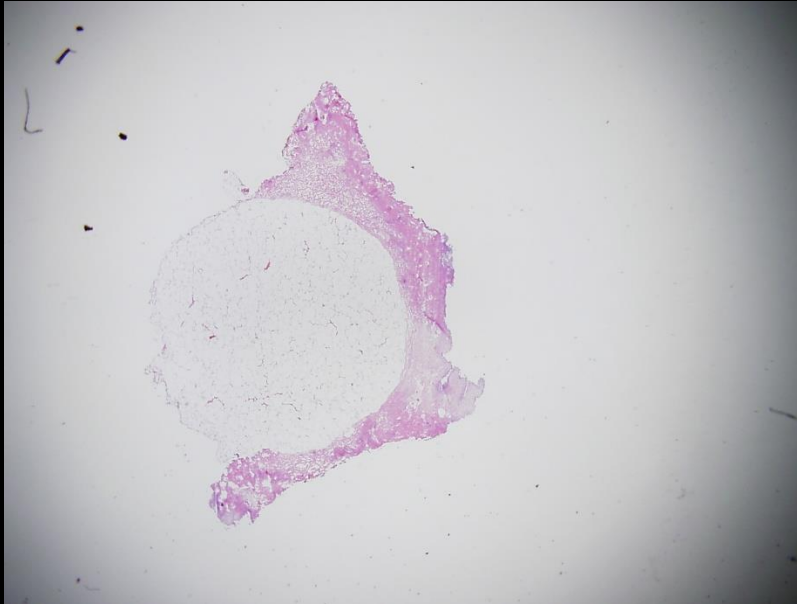






Emlőtumor miatti kemoterápia.

# Hólyagtumor. Mal?

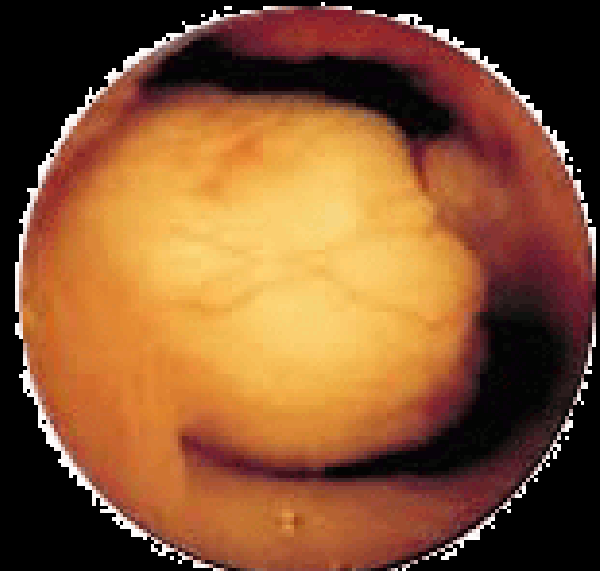
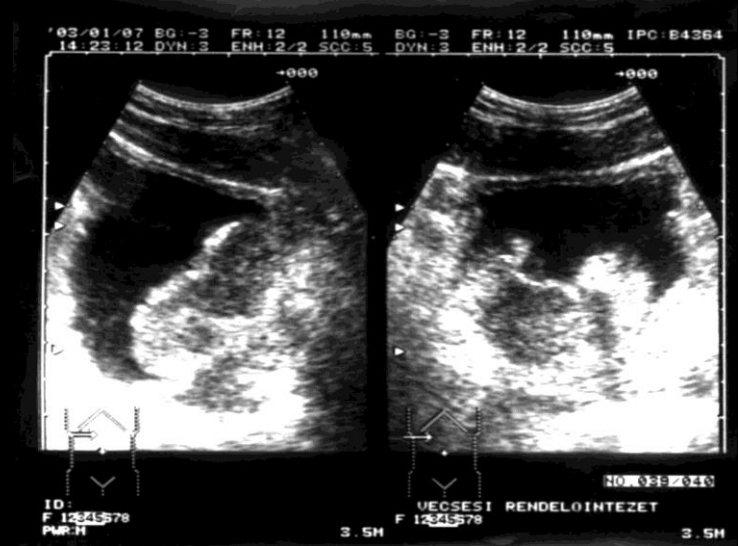
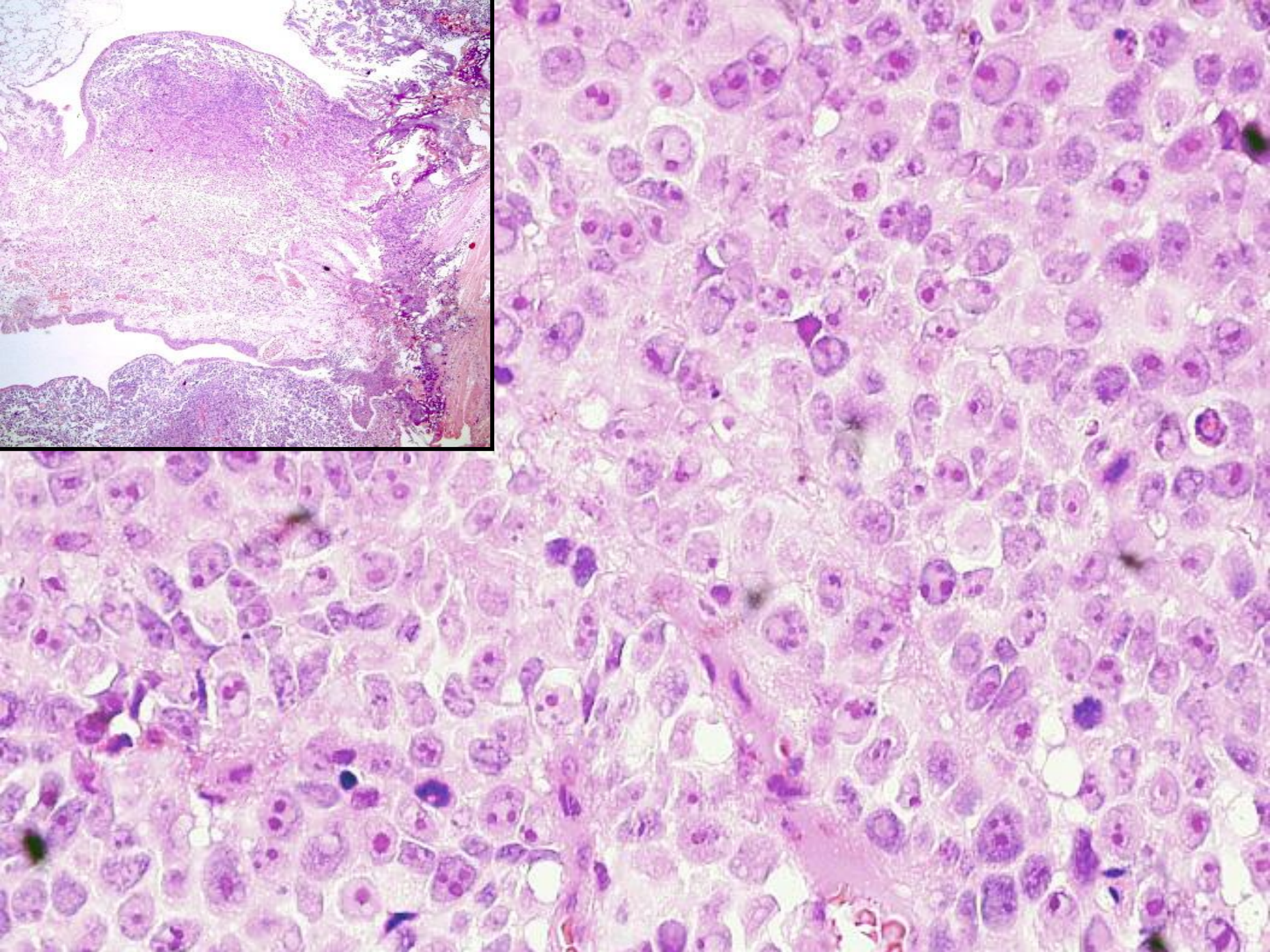
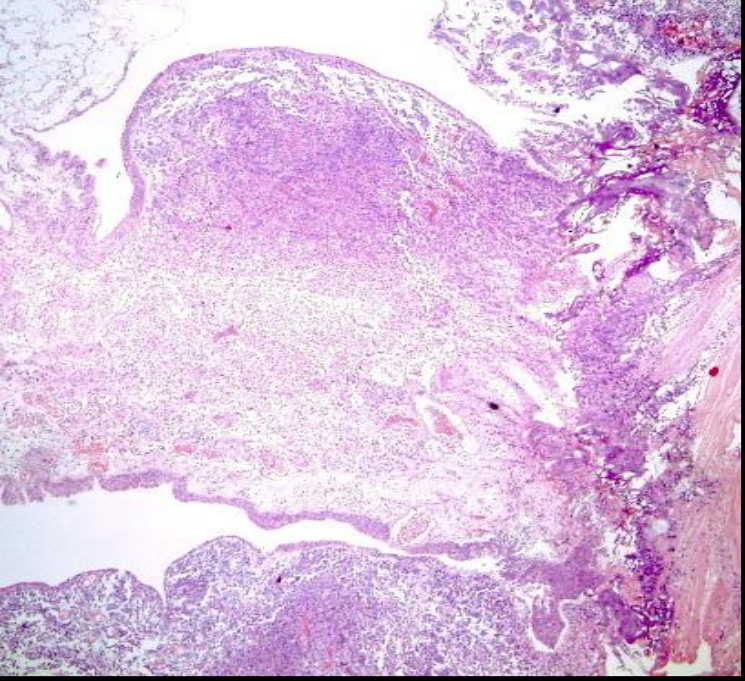
# 20 éves férfi

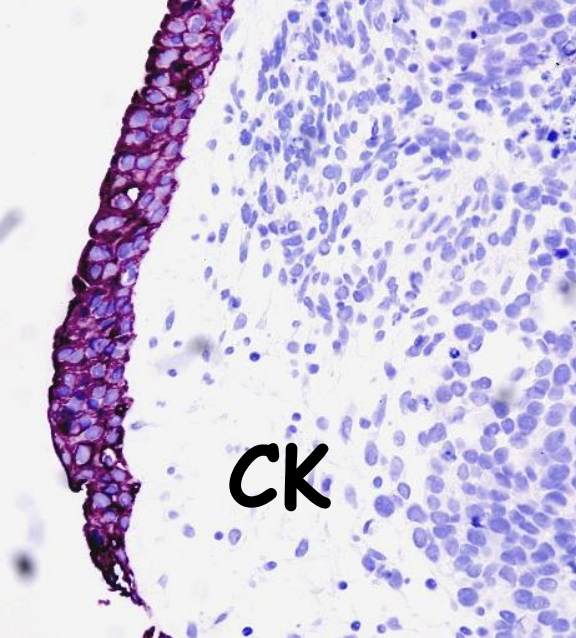
Haematuria

Hólyagba domborodó  
polypoid tumor.

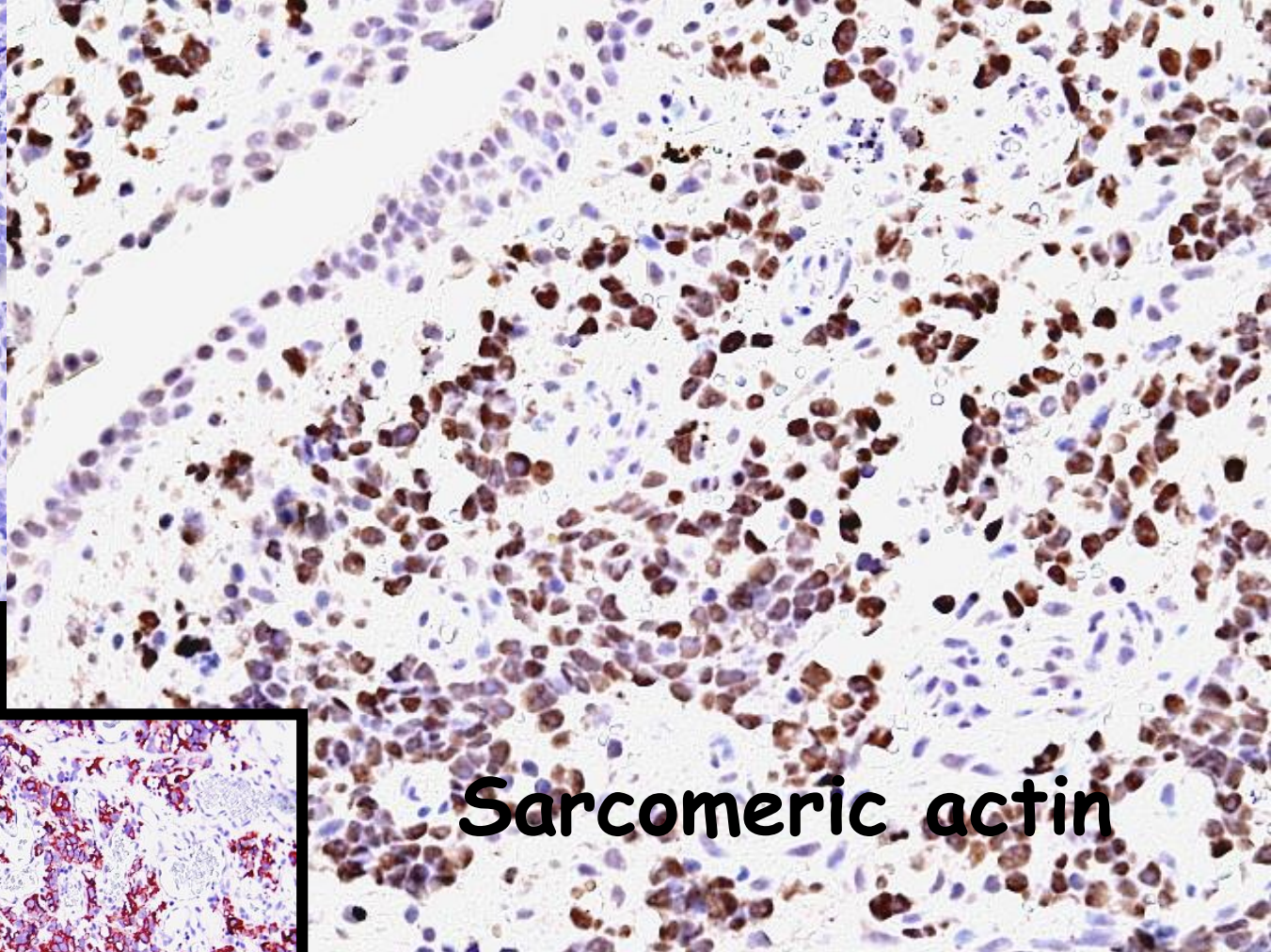
Papilloma?



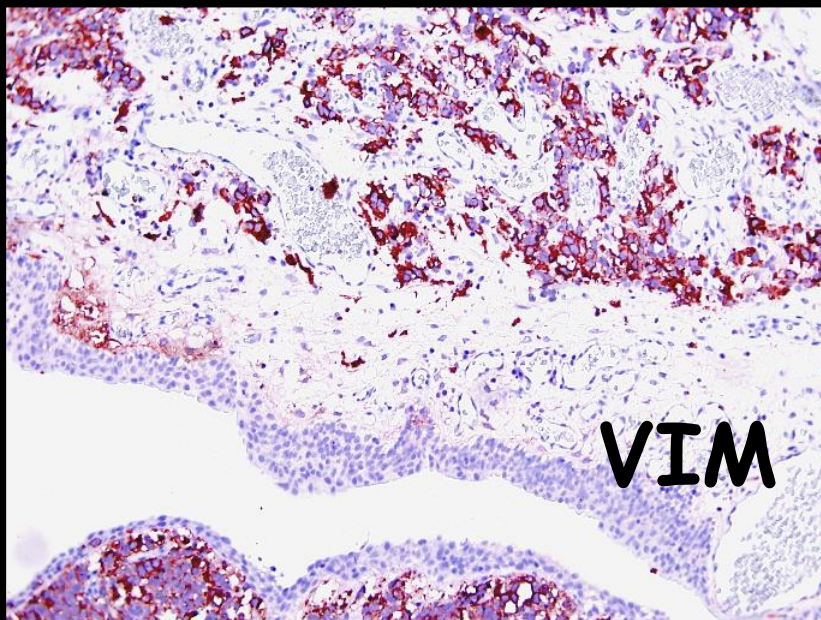




**CK**



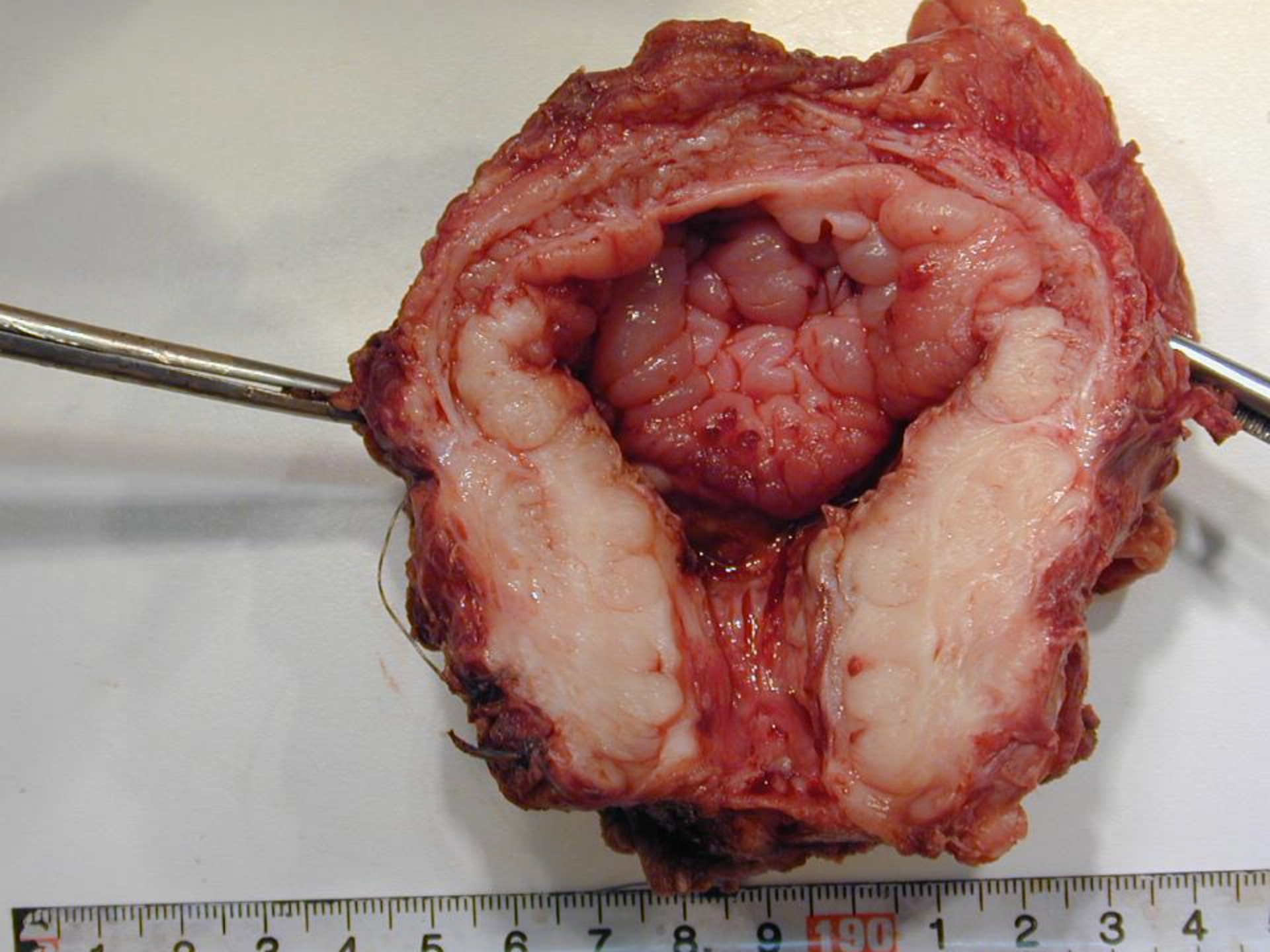
**Sarcomeric actin**



**VIM**

**Dg. :  
Rhabdomyosarcoma**



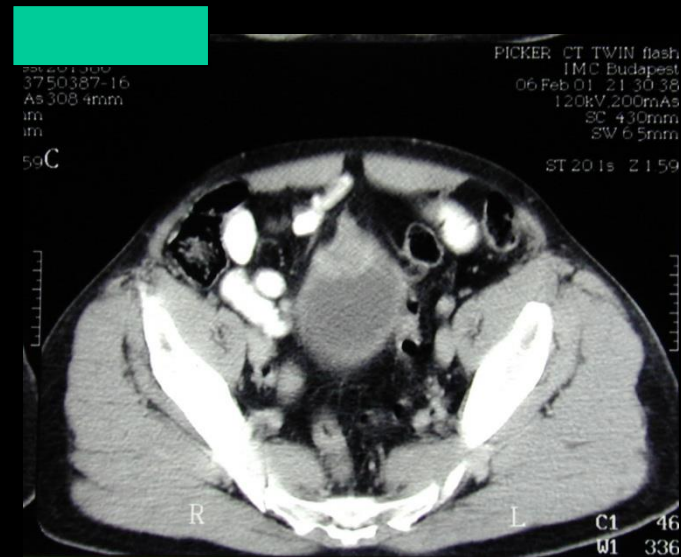


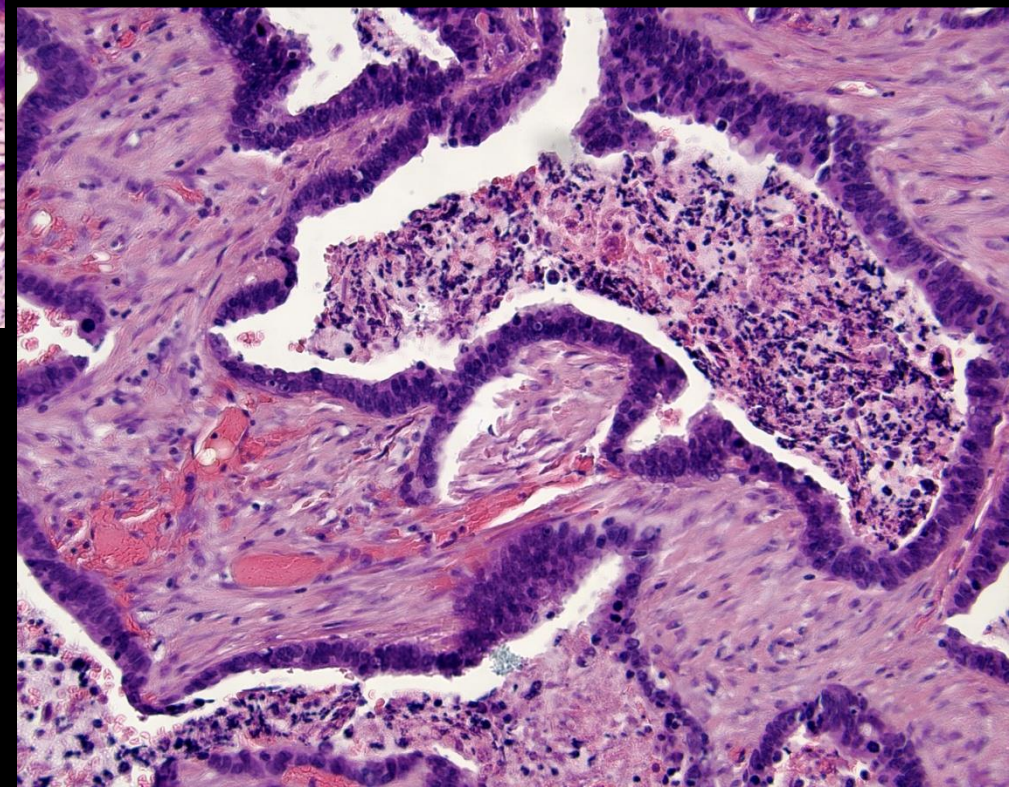
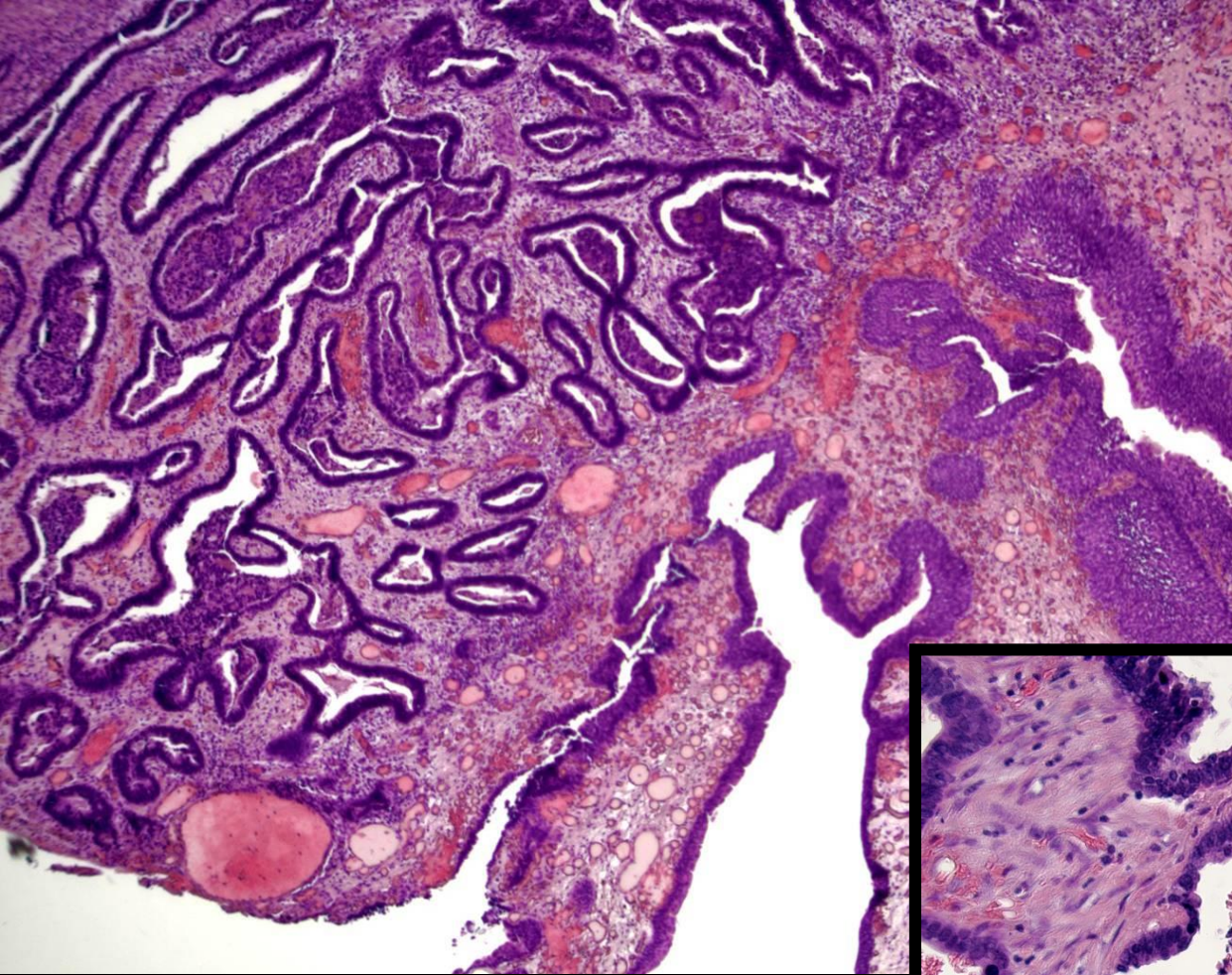
# 56 éves férfi

Hematuria

CT-n a domusban  
falvastagodás, mely a  
perivesicalis  
lágyrészekkel  
összefügg

Cystoscop: lumenbe kissé  
bedomborodó tumor





Dg. :  
adenocarcinoma  
Lehet metastasis,  
vagy urachus cc.

További kivizsgálások során primer tumort nem találtak, így végleges dg:

Urachus carcinoma

Egy év múlva kontroll CT:  
hasfalban  
inhomogén szövet:

