Gastrointestinal pathology 1.

Upper GI tract

Tumors of The Salivary Glands

Benign

- Pleomorphic adenoma (50%)
- Warthin tumor (5%)
- Oncocytoma (2%)

Malignant

- Mucoepidermoid cc (15%)
- Adenocarcinoma NOS (6%)
- Acinic cell cc (6%)
- Adenoid cystic cc (4%)
- Malignant mixed tumor (3%)
- Malignant lymphoma
- Metastatic –
  breast, lung, melanoma

Pleomorphic adenoma

- Benign
- Slow-growing, painless, mobile discrete mass
- Most common site: superficial lobe of parotis
- Well-demarcated, but might protrude into surrounding tissues → recurrs if excision is incomplete

Pleomorphic adenoma

Pleomorphic adenoma

Tumor of myoepithel-derived cells

Epithelial cells: form ducts, acini, tubules, strands and sheets

Stroma: (mesenchyme-like background) myxoid-tissue, hyalin, islands of chondroid, rarely bone

Pleomorphic adenoma

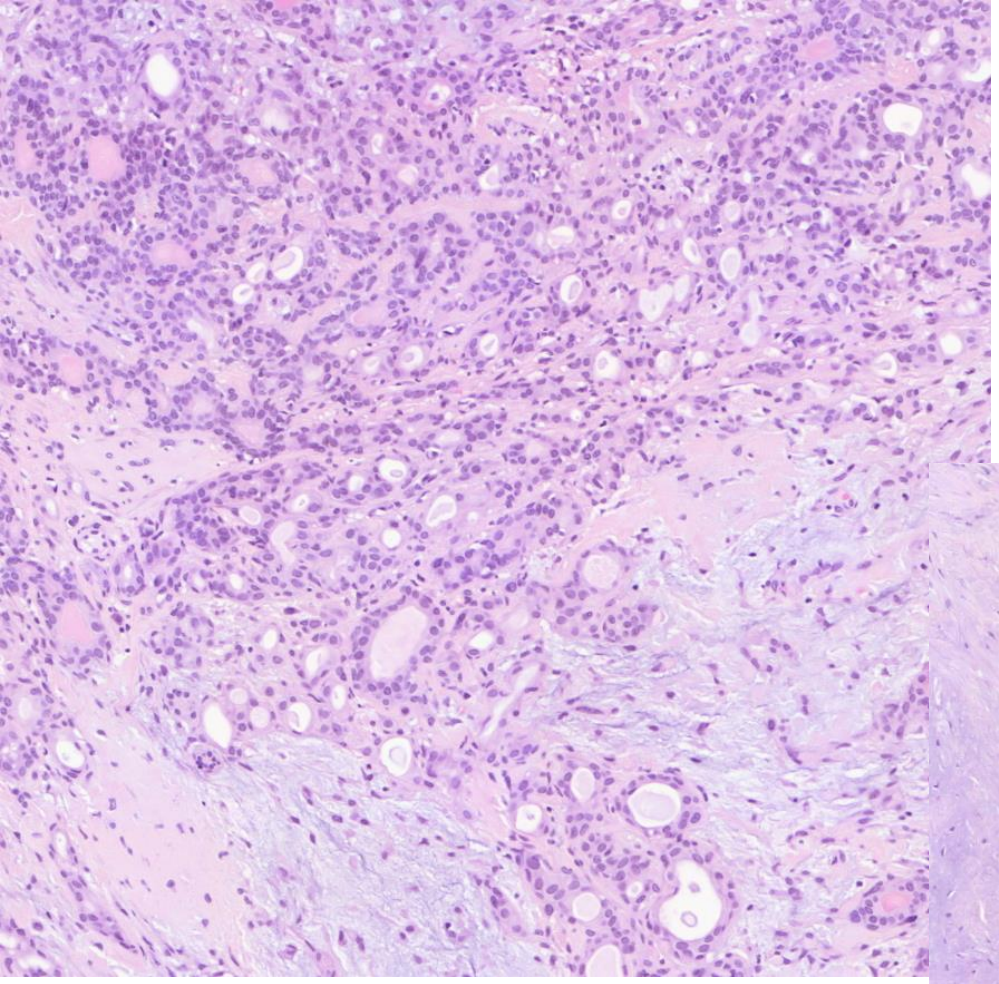

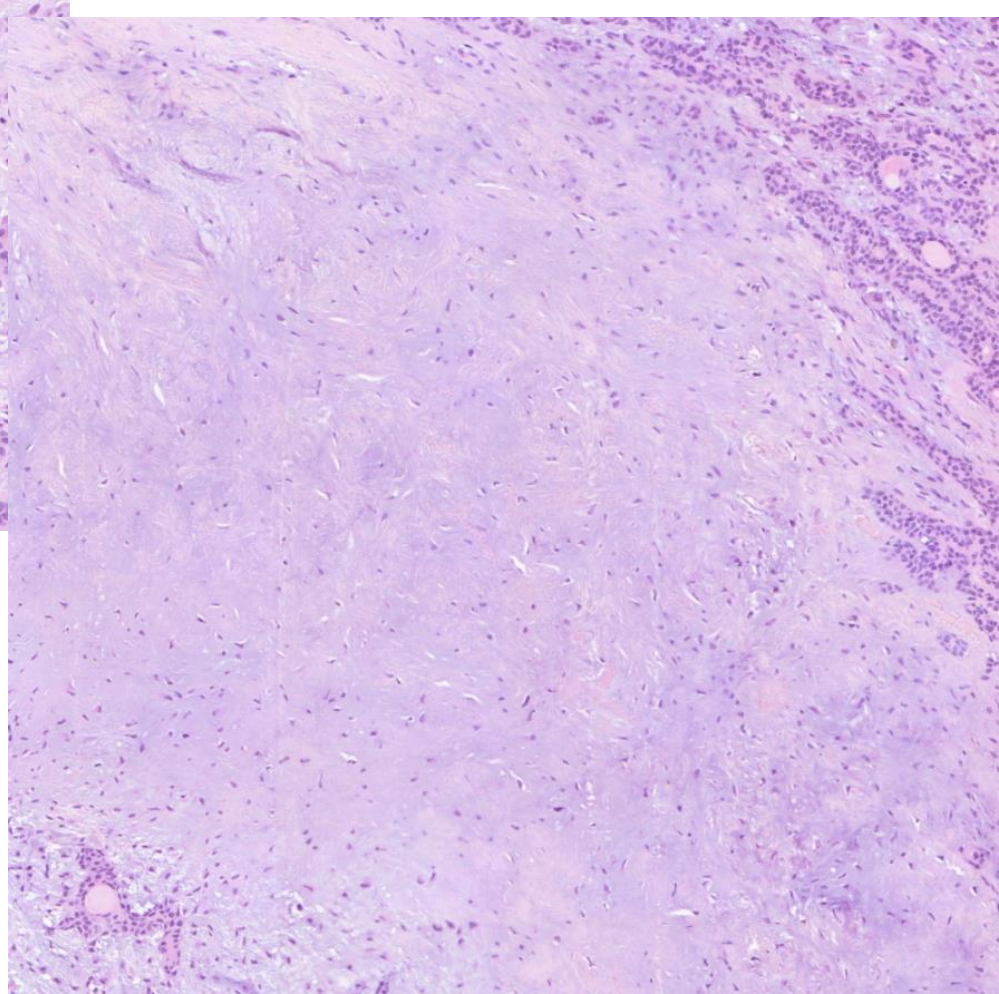

Parts of The Stomach

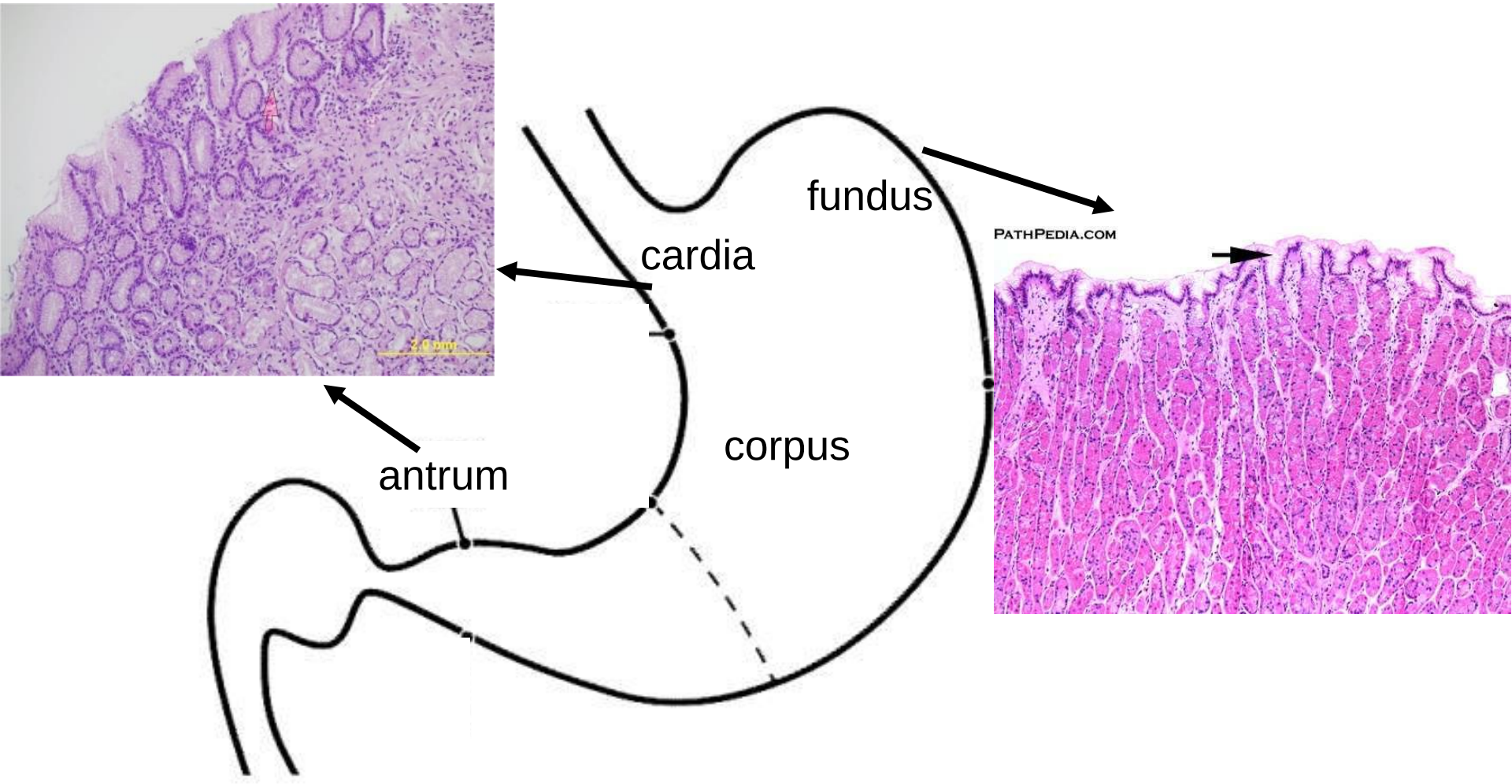

https://openi.nlm.nih.gov/detailedresult.php?img=PMC2940217_GMS-08-19-g-004&req=4

Physiological background

- Defensive Forces:
  - Surface mucus
  - Bicarbonate
  - Mucosal blood flow
  - Prostaglandin
- Damaging Forces:
  - Gastric acidity
  - Peptic enzymes

Acute gastritis

- Acute inflammation of gastric mucosa
- Usually transient
- Main cellular component: neutrophil granulocyte
- Mucosal damage: erosion (– see later) /hemorrhage may occur

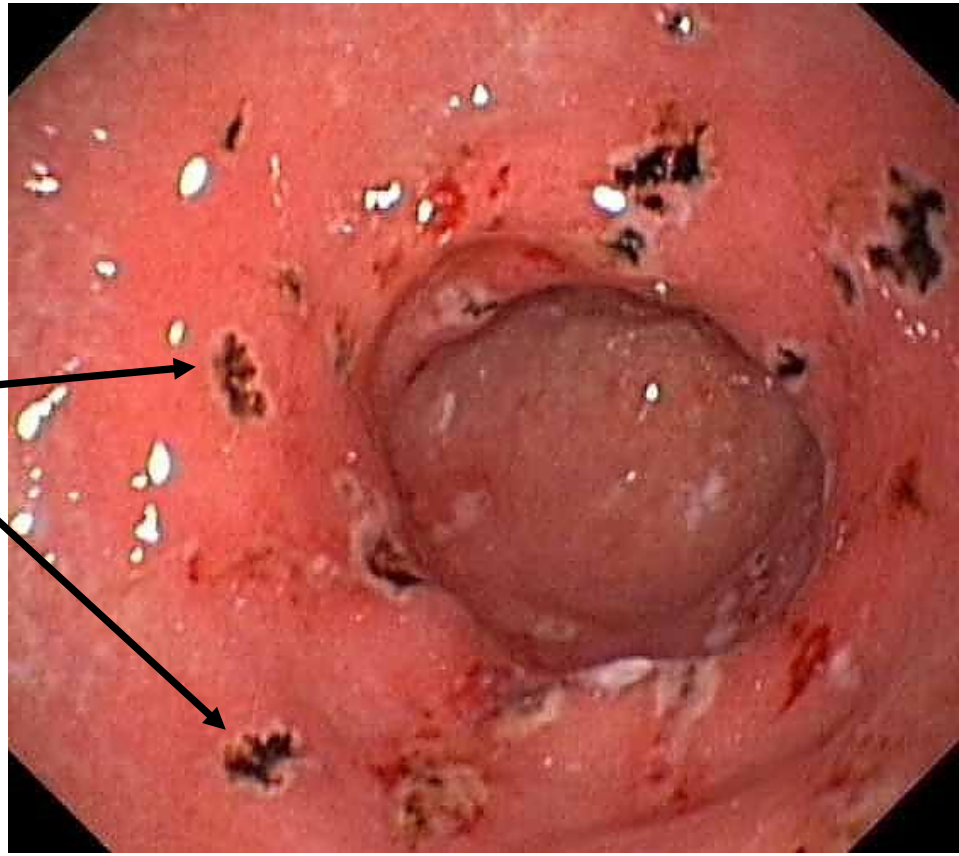

Kép forrása: Pogány Péter szakvizsga előkészítő előadása

Etiology of Acute Gastritis

- Drugs
  - NSAID, steroid, cytostatic drugs
- Alcohol, smoking, coffee
- Uraemia
- Stress
- Burning
- Heart failure
- Portal hypertension
- Ischaemia
- Infection, sepsis
- Harsh chemicals (acids, bases)
- Food
- Irradiation

Chronic gastritis

Two main features:

•Inflammatory cells (acute and chronic) infiltrate the lamina propria

•Atrophy of glandular epithel

Classification: (Sydney-classification-1991)

Type	**Non-atrophic**	**Atrophic**	**Special**
Etiology	H. pylori	• Autoimmune • Multifocal atrophic (H.pylori+dietary, environmental factors)	• Chemical (NSAID,bile reflux) • Irradiation • Granulomatous (eg: vasculitis) • Lymphocytic (immune-mediated, gluten) • Eosinophilic (allergy) • Infective (bacterium, virus)

Helicobacter pylori Associated Gastritis

- Most common type of chronic gastritis
- H. pylori: rod/spiral-shaped
- Gram-negative bacterium
- Tipically infects antrum
- Found in the mucus, on the inner surface of the epithelium

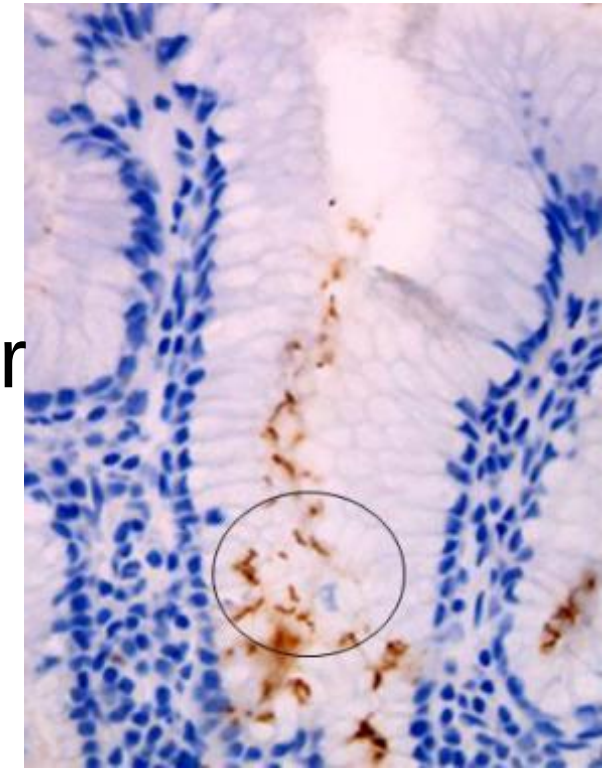

https://img.medscapestatic.com/pi/meds/ckb/90/9290tn.jpg

Chronic Gastritis (H. pylori associated)

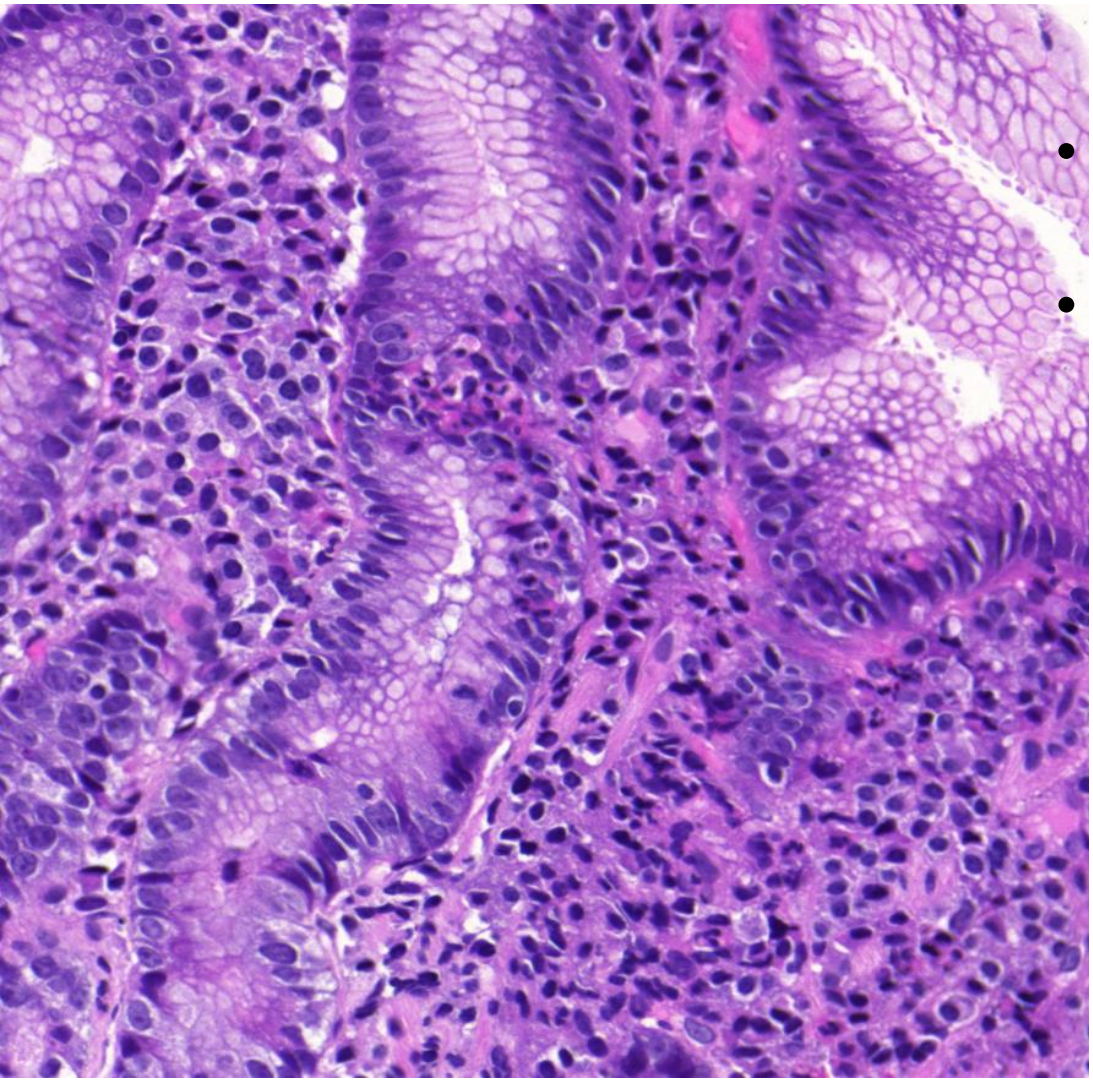

- Lymphocytes/plasma cells infiltrate the lamina propria
- Neutrophils invade glands (active chronic gastritis)

Chronic Gastritis
H. pylori associated)

HE

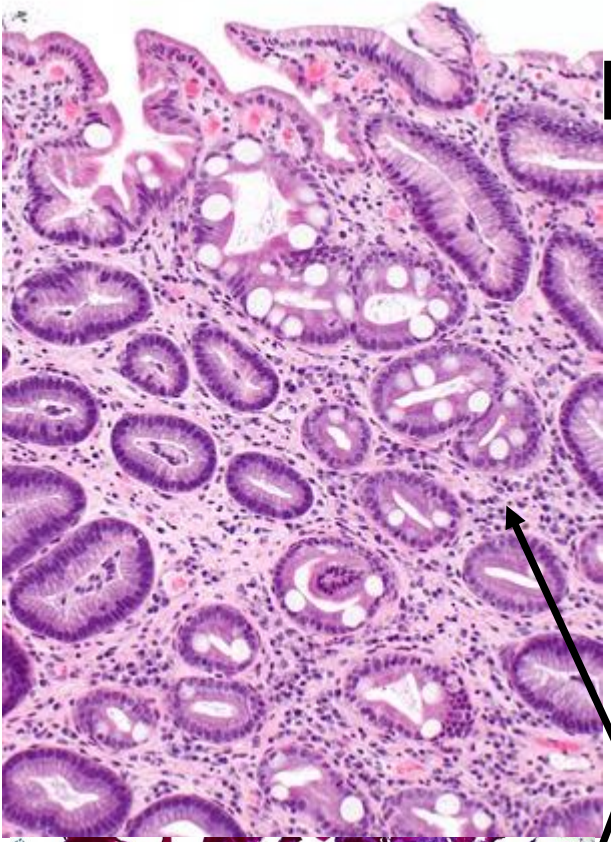

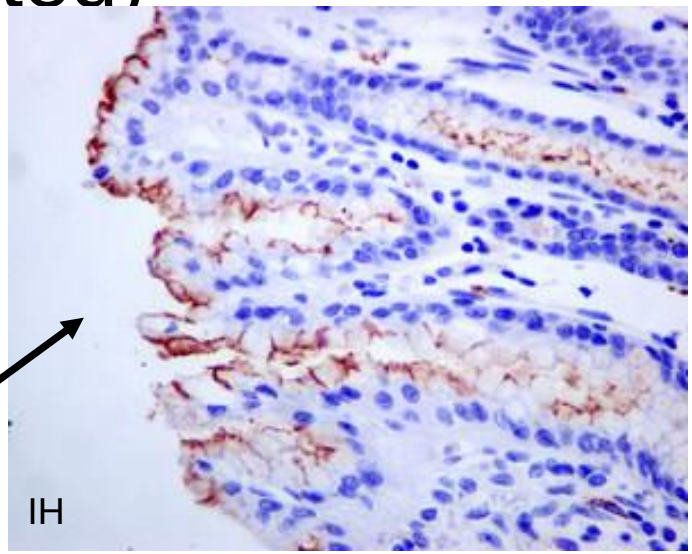

IH

- H. pylori in the mucus (Giemsa/IH)
- Intestinal metaplasia

Giemsa

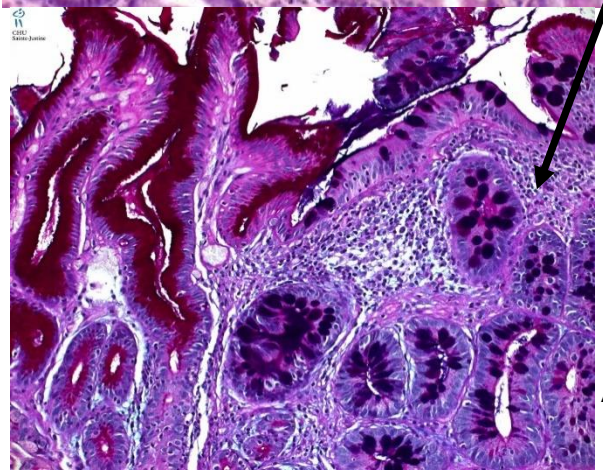

Alcian blue-PAS

https://librepathology.org/w/images/thumb/1/14/Stomach_with_intestinal_metaplasia_--_intermed_mag.jpg/300px-Stomach_with_intestinal_metaplasia_--_intermed_mag.jpg

http://a.abcam.com/ps/datasheet/images/140/ab140128/Helicobacter-pylori-Primary-antibodies-ab140128-1.jpg

Complications of Chronic Gastritis

- Peptic ulcer
- Mucosal atrophy and intestinal metaplasia
- Dysplasia → adenocarcinoma
- MALT-lymphoma (Helicobacter)

Erosion and Ulcer

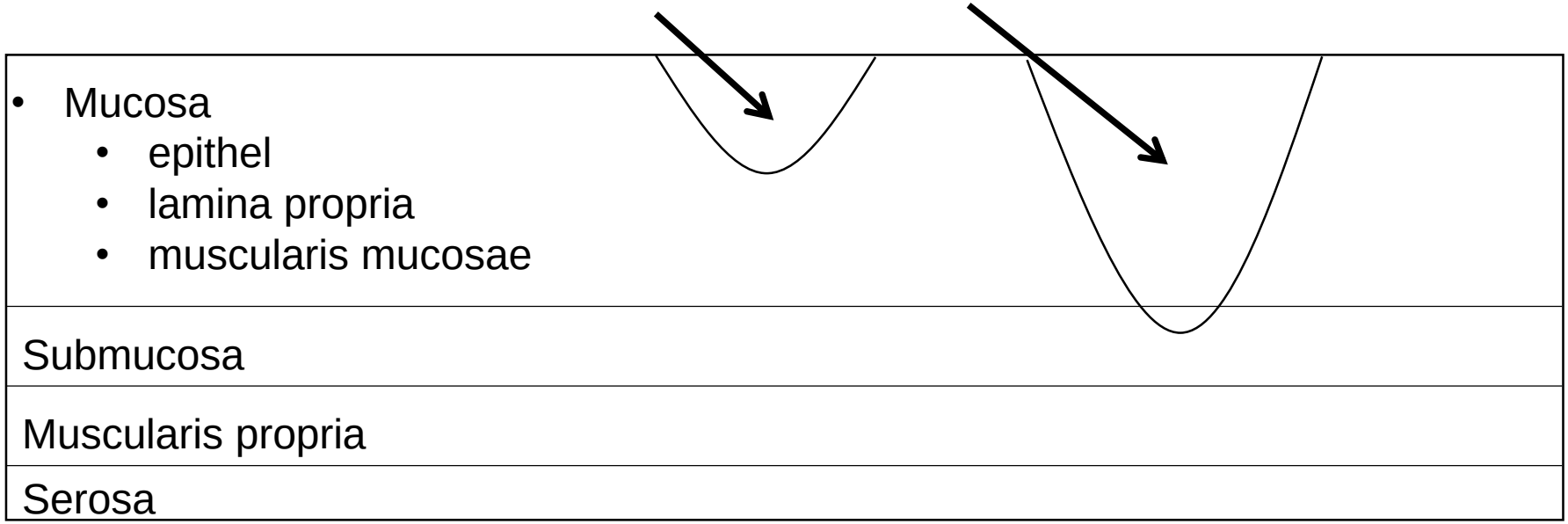

Acute erosion/ulcer

Mainly in the stomach

Causes:

- Hyperacidity
- Shock
- Stress-operation/trauma
- Cushing ulcer (CNS injury)
- Steroid ulcer
- Curling ulcer (burn)

Chronic ulcer

duodenum:stomach (antrum)
4:1

Causes:

- **H. pylori**
- NSAID
- Smoking
- Alcohol
- Hyperacidity
- Gastroduodenal reflux

Pathogenesis of Peptic Ulcer

Normal

- Damaging Forces:
  - Gastric acidity
  - Peptic enzymes

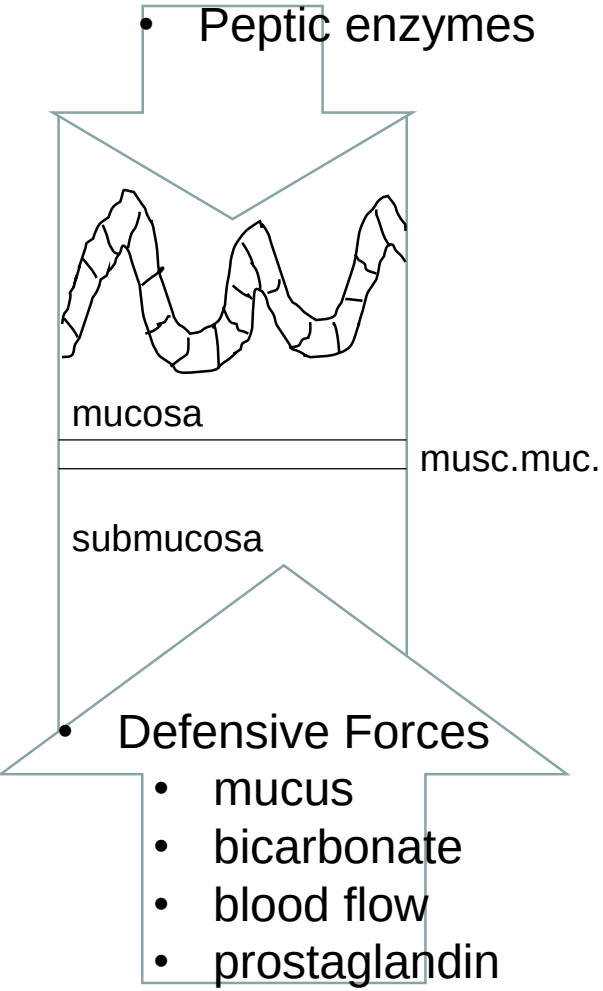

- Defensive Forces
  - mucus
  - bicarbonate
  - blood flow
  - prostaglandin

- Damaging Forces↑
  - **H. pylori**
  - NSAID
  - Smoking
  - Alcohol
  - Hyperacidity
  - Gastroduodenal reflux

- Defensive Forces↓
  Eg: ischaemia, shock

Ulcer

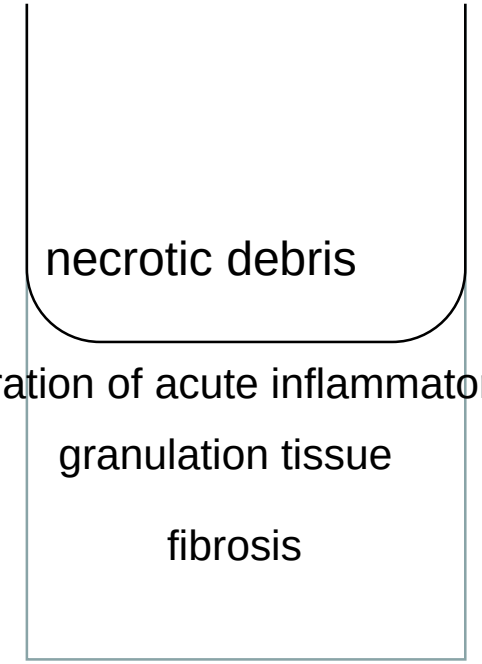

Robbins: Patológia c. könyv nyomán

Peptic Ulcer

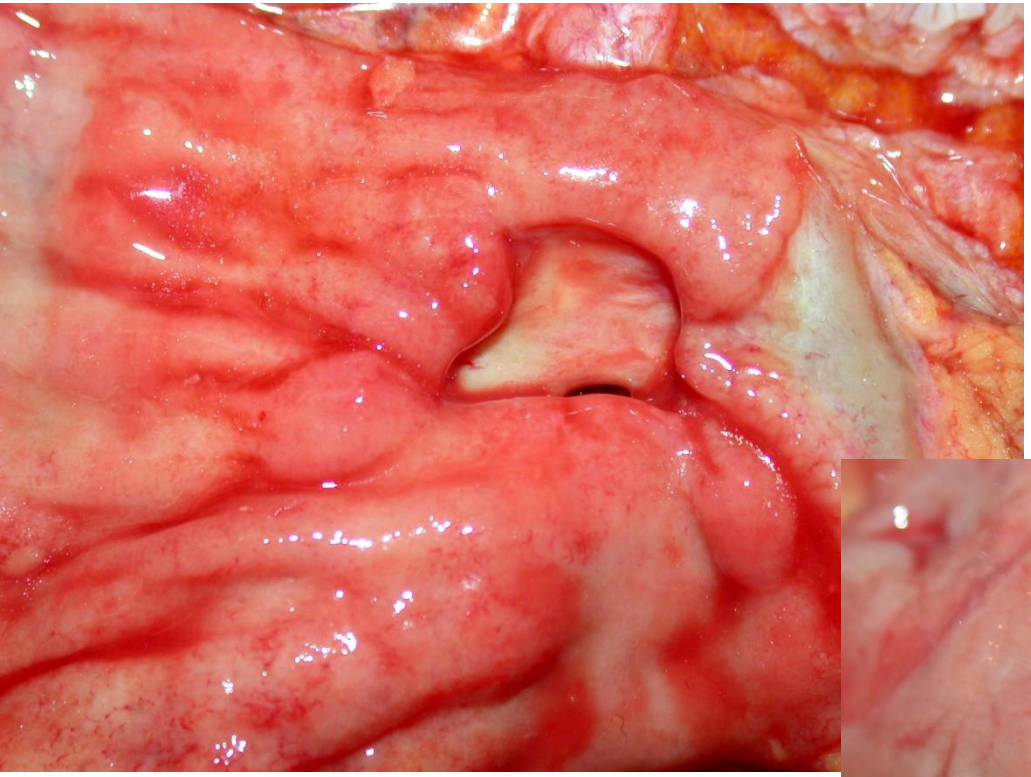

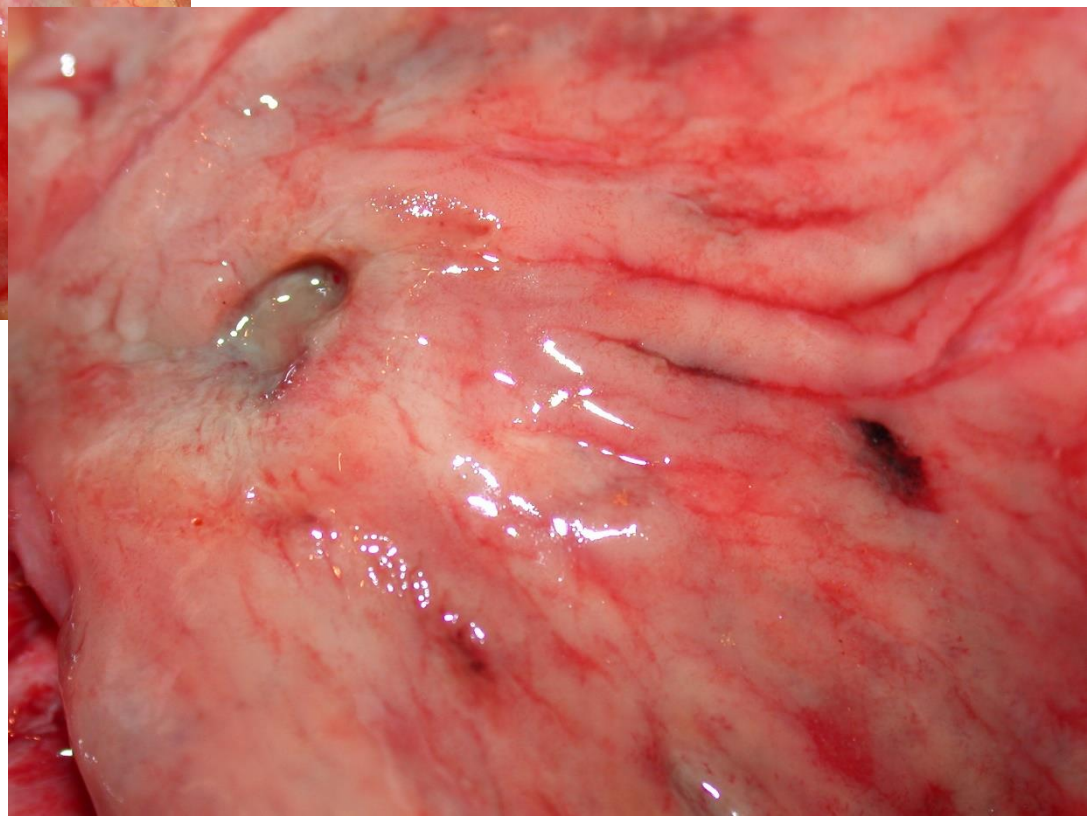

Peptic Ulcer

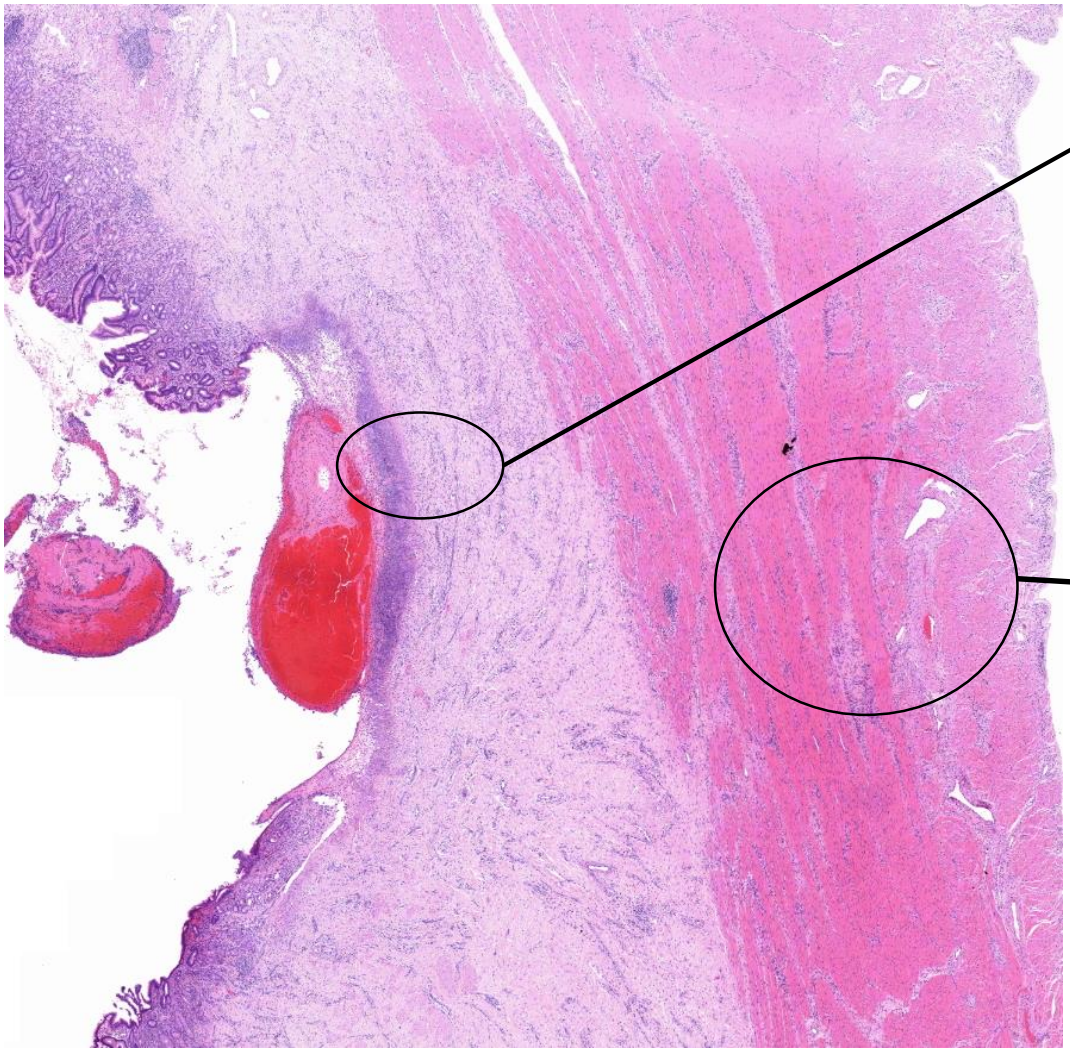

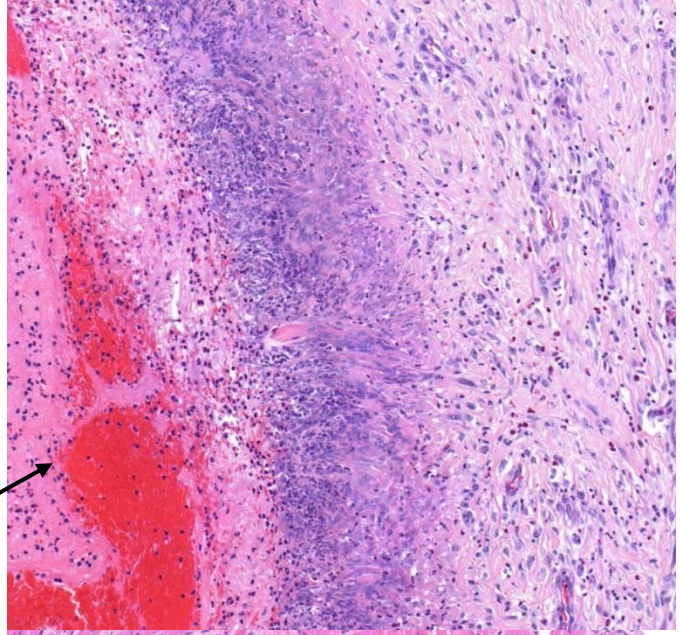

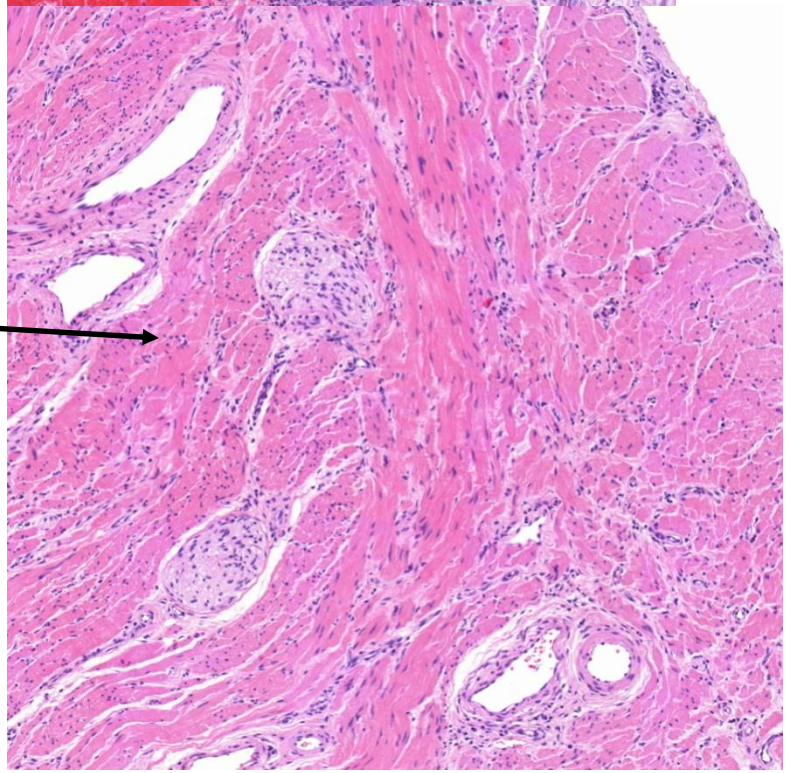

Complications

- Hemorrhage
- Perforation
- Penetration
- Scar formation (eg: stenosis of pylorus)
- Malignant transformation

Gastric Adenocarcinoma

- 90-95% of gastric tumors: adenocarcinoma
- Early symptoms = symptoms of chronic gastritis (dyspepsia, nausea)
- Late symptoms: loss of weight, anorexia, ‘meat disgust’, altered bowel habits, anaemia, hemorrage
- Survival (5 years):
  - Early gastric cancer: 90%< (T1N0M0)
  - Advanced gastric cancer: 20%>
- Prognostic factors:
  - Local invasion (pT)
  - Regional lymph node metastasis (pN)
  - Distant metastases

Types of Gastric Cancer (Lauren classification)

- Intestinal
  - Exophytic /ulcerated (heaped-up borders)
  - Glandular structures
  - Mucin production↑
  - Precursor: dysplasia/adenoma
  - HER2 amplification
- Diffuse
  - Infiltrative
  - Desmoplastic – linitis plastica
  - Discohesive cells
  - Cytoplasmic mucin vacuoles
  - No precursor
  - E-cadherin loss

Intestinal type

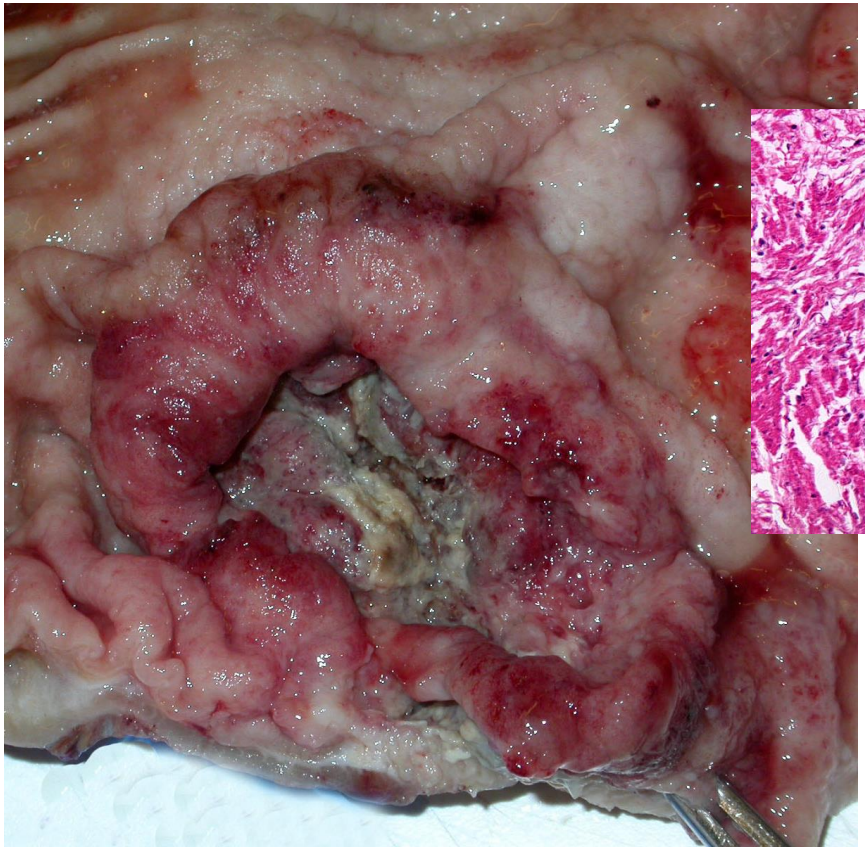

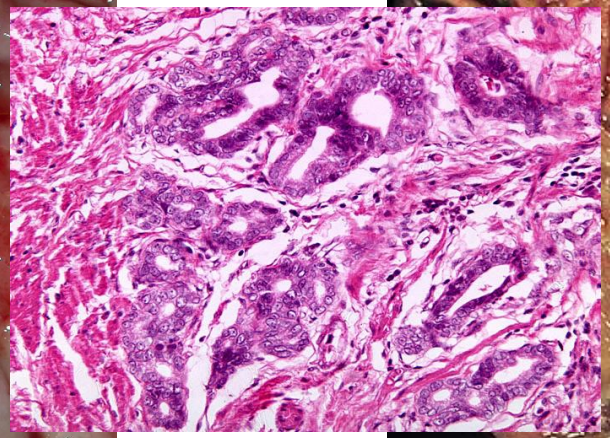

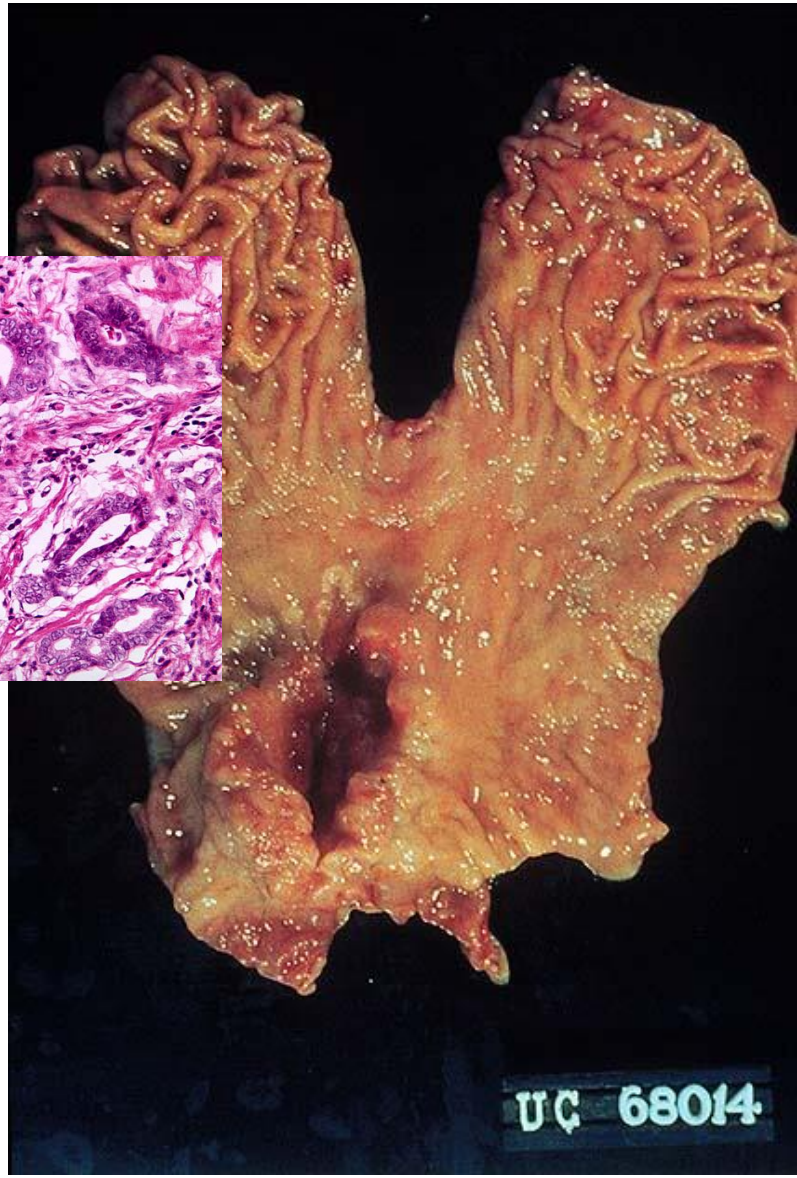

Pogány Péter szövettani gyak. diasora

Diffuse type

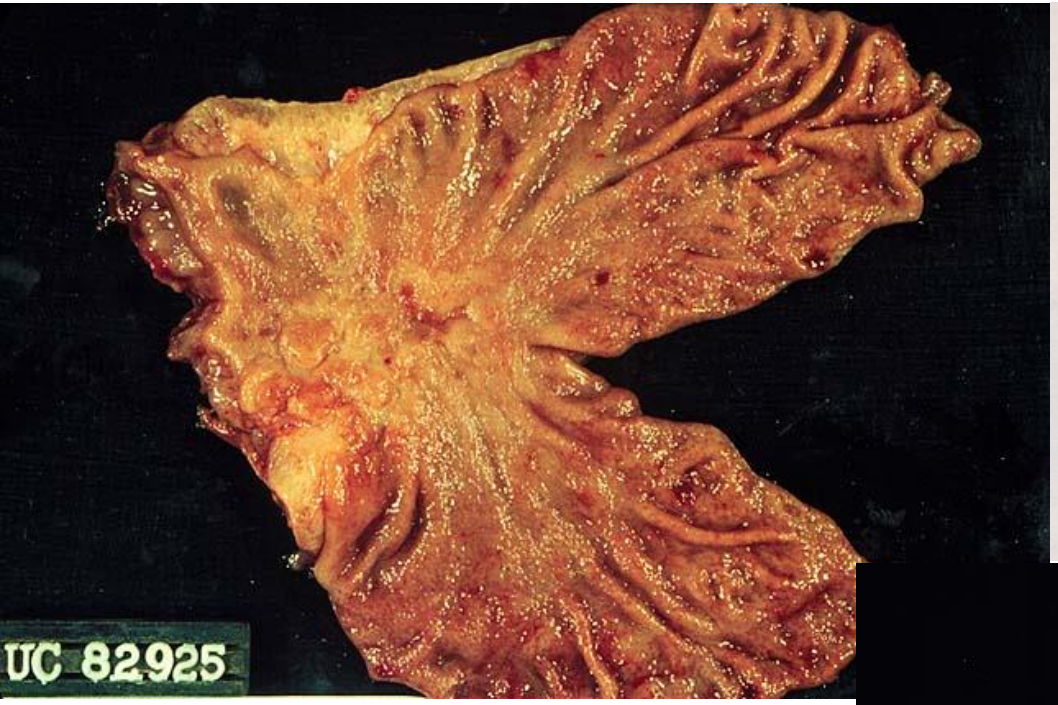

Linitis plastica

Képek forrása: Pogány Péter szövettani gyak. diasora

Diffuse type

carcinoma sigillocellulare/
signet ring cell morphology

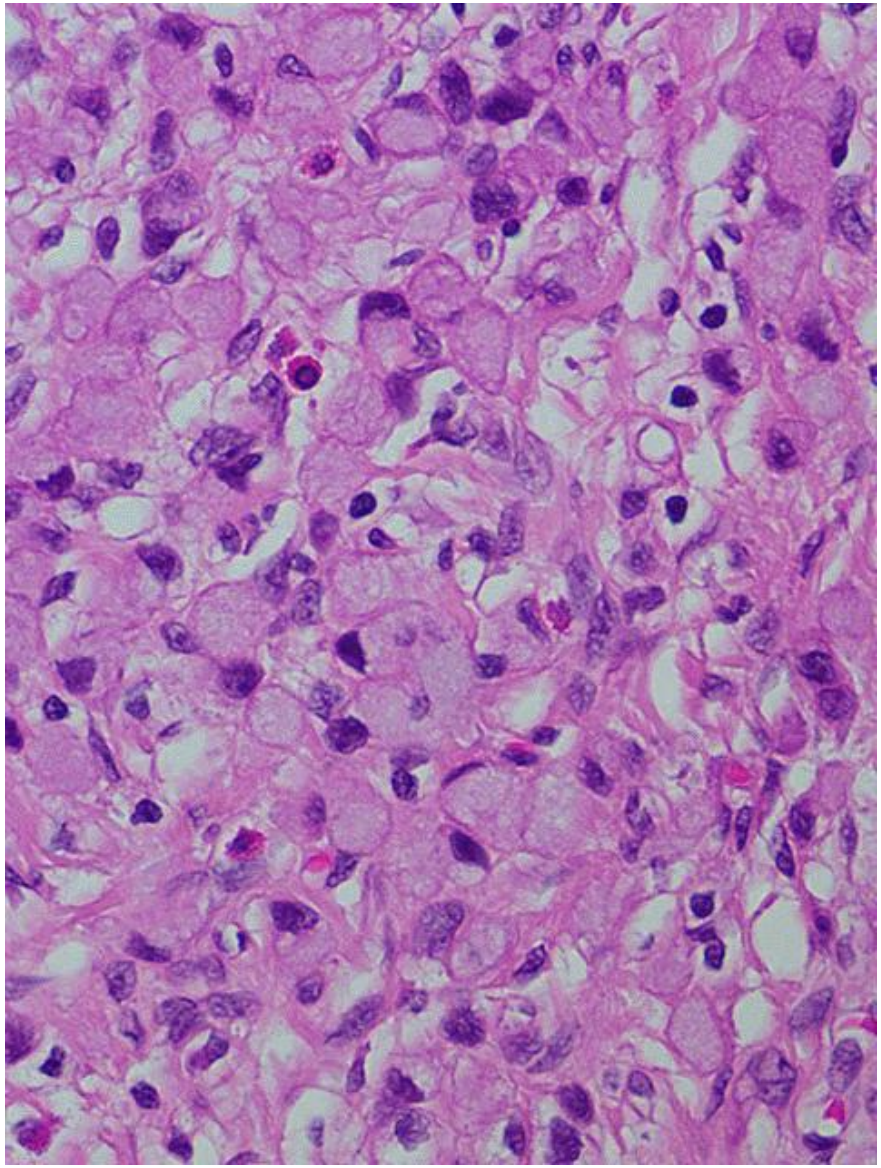

GIST
(gastrointestinalis stromal tumor)

- Most common mesenchymal tumor of the GI tract
- Arises from pacemaker cells (interstitial cells of Cajal)
- More than half of the cases are detected in the stomach
- 75-80% have KIT (CD117) mutation, 10% have PDGFR A mutation
- Peak incidence: 60 years of age
- Prognostic factors:
  - Size
  - Number of mitoses
  - Location (more aggressive if arises in the small intestine)

GIST

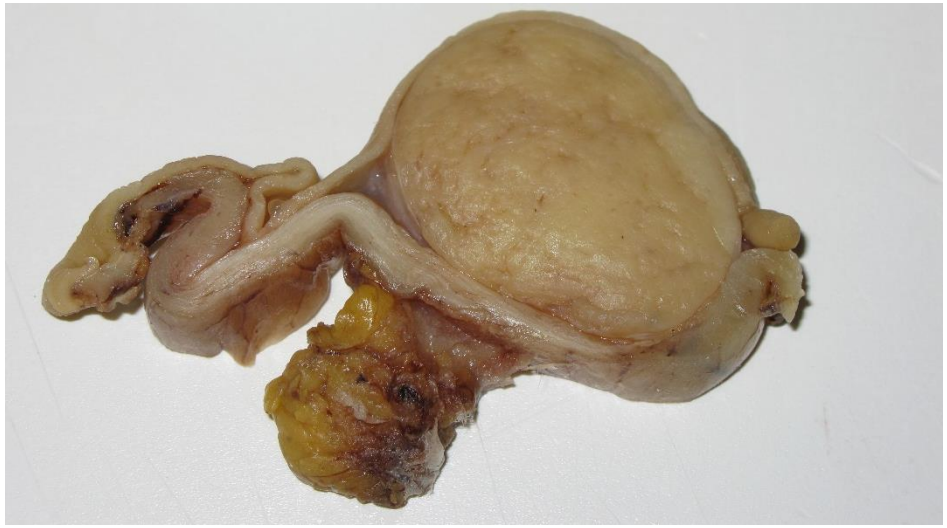

Solitary, well-circumscribed, fleshy, submucosal mass, might be subserosal or intramural.
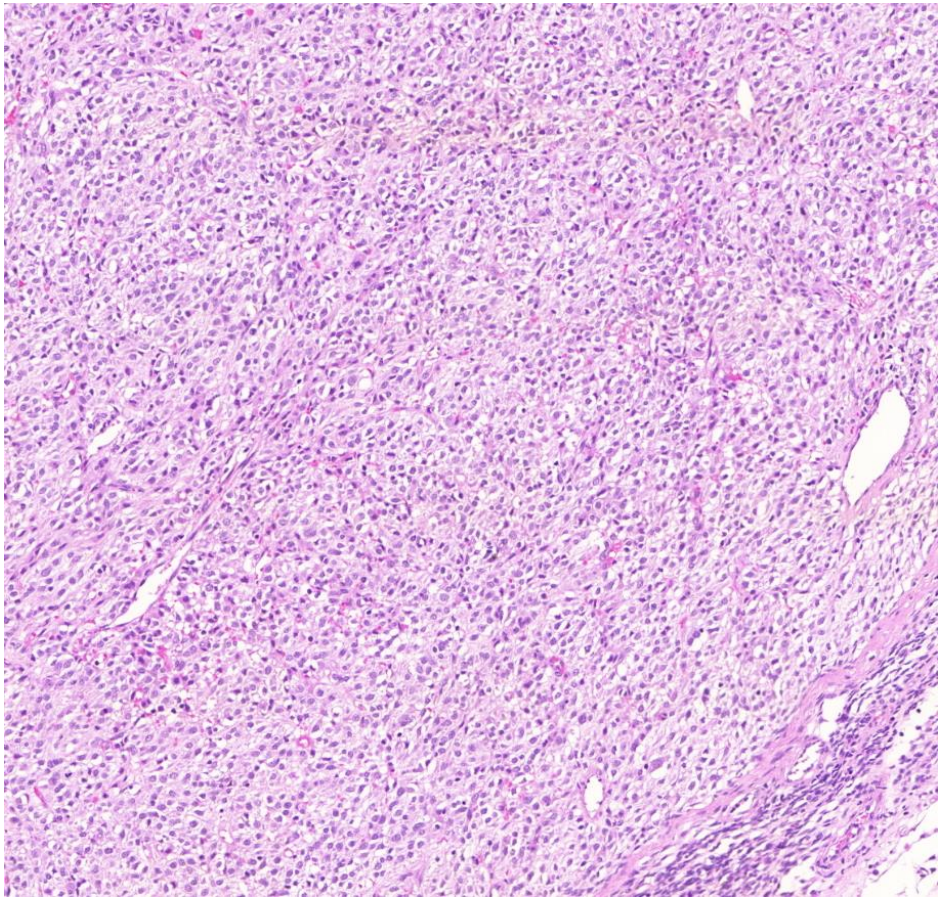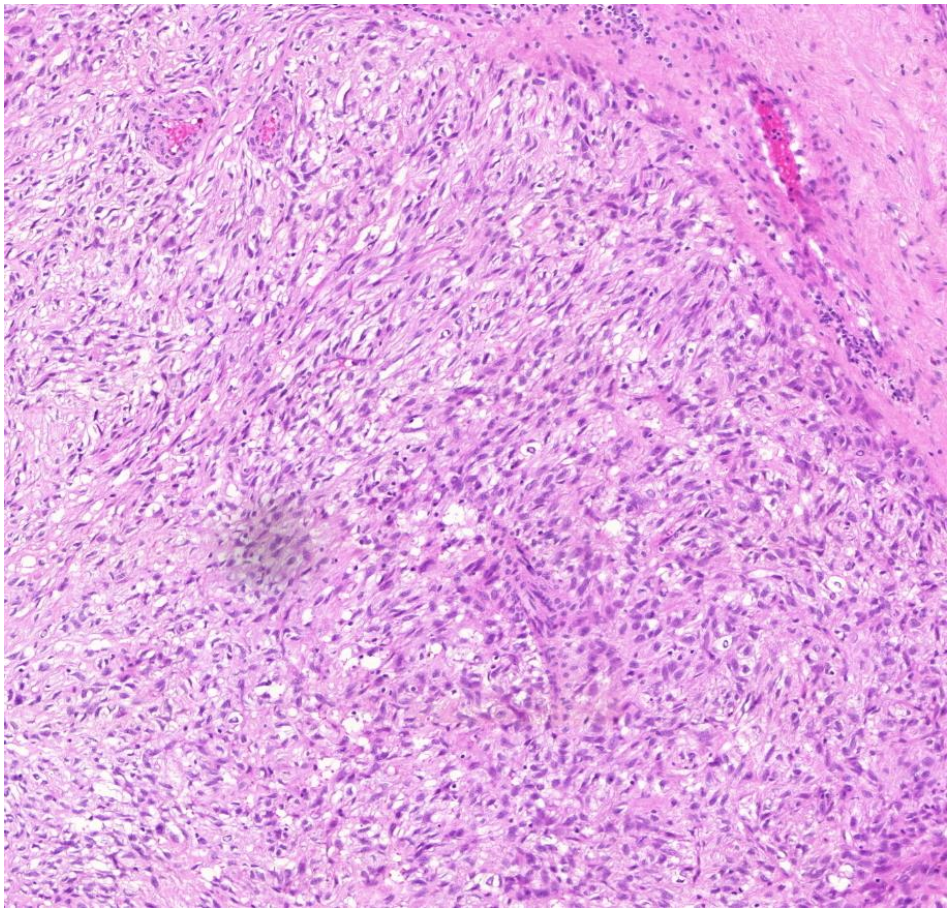
GIST