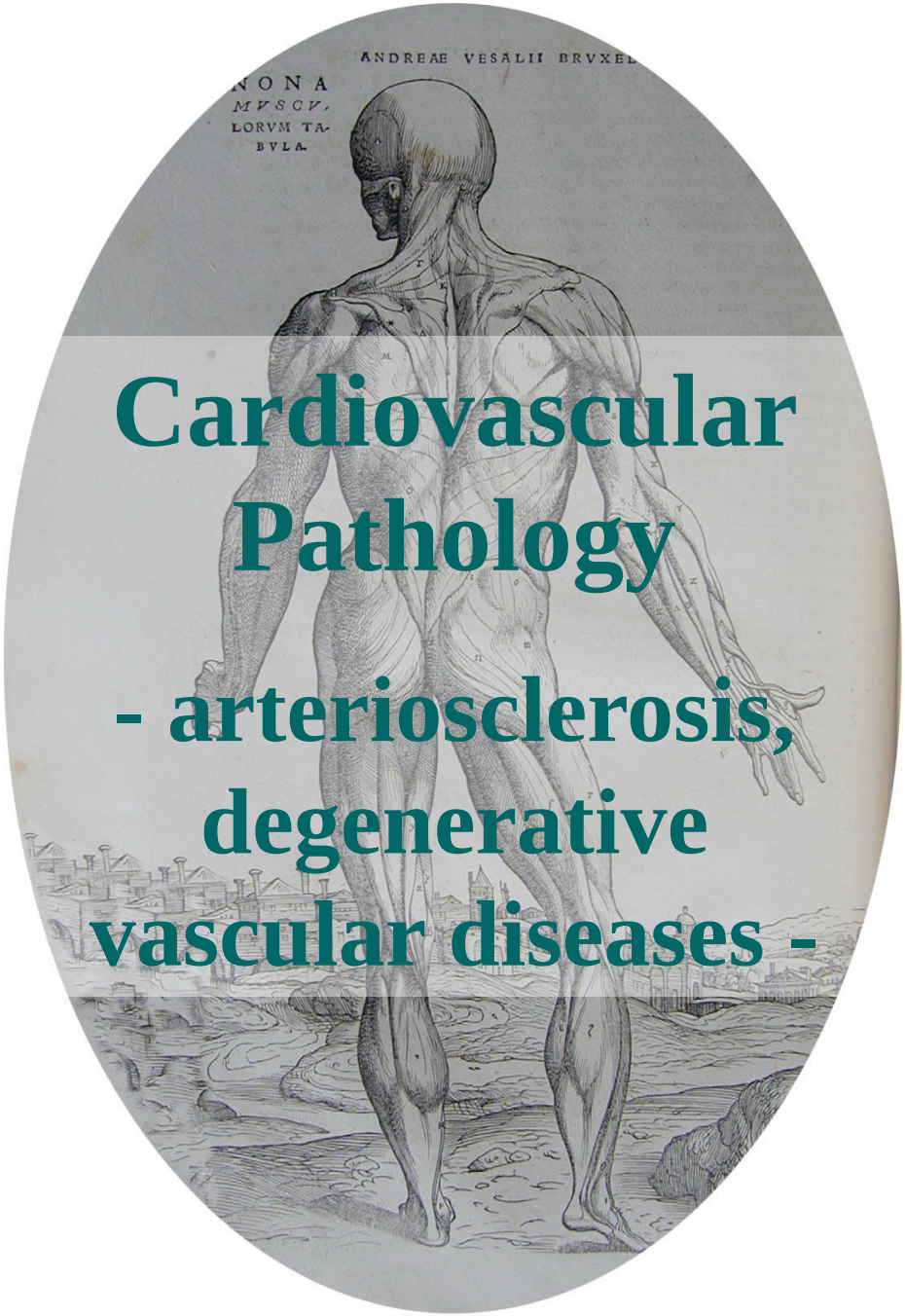

Cardiovascular Pathology

- arteriosclerosis, degenerative vascular diseases -

Semmelweis University
2nd Department of Pathology

2017/2018 – Autumn Semester

Tibor Glasz MD PhD

Degenerative vascular diseases

- Arteriosclerosis – *collective term for altered mechanic-structural vascular wall characteristics (stiffening/hardening or softening)*
  - Atherosclerosis – *mural change of elastic and middle sized to large muscular arteries*
  - Arteriolosclerosis – *mural change of small muscular arteries and arteioles*
  - Medial sclerosis of Mönckeberg – *mural change with special characteristics*
- Vascular changes in diabetes mellitus
- Aneurysms
- Dissection of vascular wall layers

Atherosclerosis

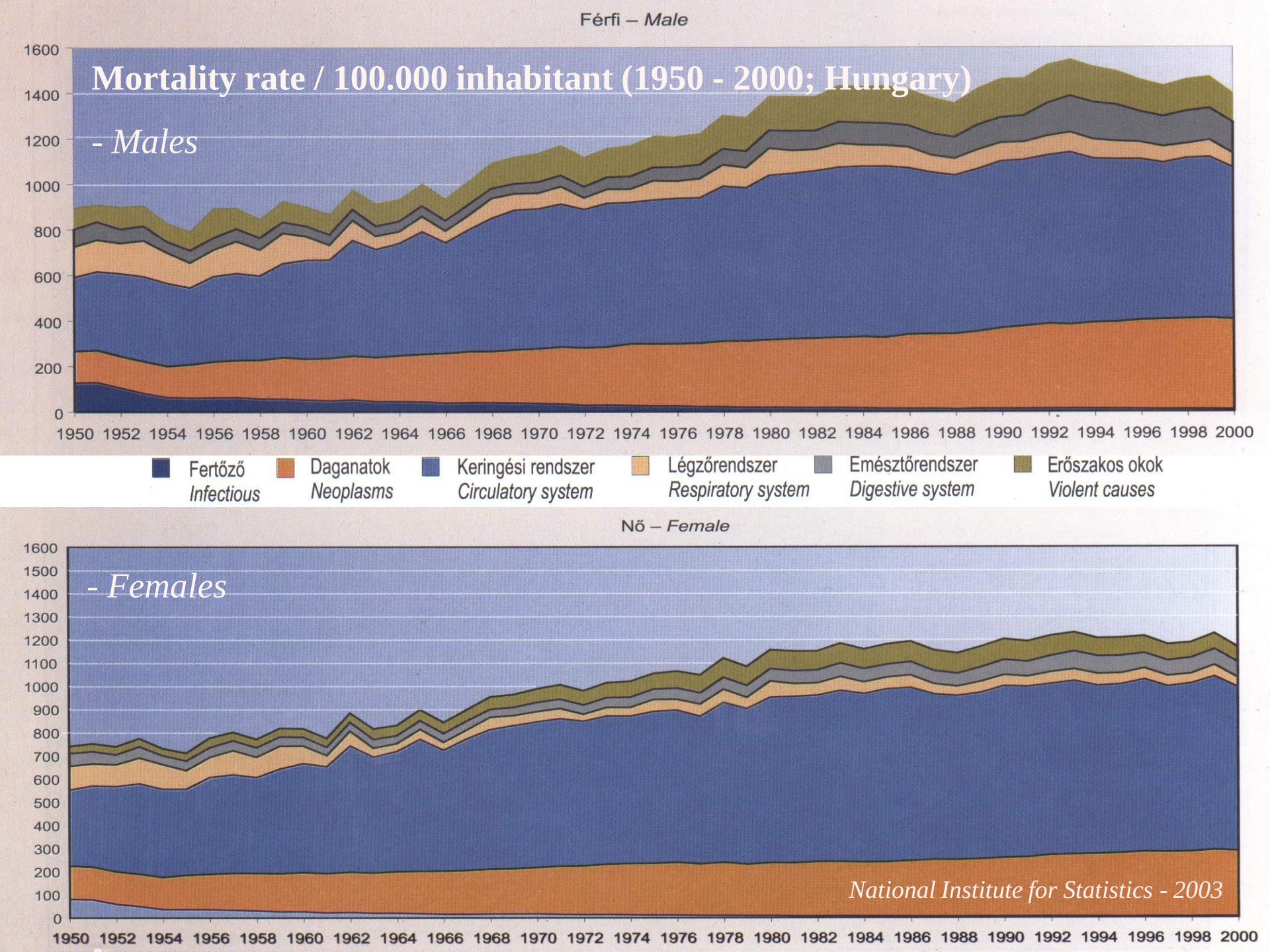
Férfi – Male
Mortality rate / 100.000 inhabitant (1950 - 2000; Hungary)
- Males
1600
1400
1200
1000
800
600
400
200
0
1950 1952 1954 1956 1958 1960 1962 1964 1966 1968 1970 1972 1974 1976 1978 1980 1982 1984 1986 1988 1990 1992 1994 1996 1998 2000
Fertőző
Infectious
Daganatok
Neoplasms
Keringési rendszer
Circulatory system
Légzőrendszer
Respiratory system
Emésztőrendszer
Digestive system
Erőszakos okok
Violent causes
Nő – Female
- Females
1600
1500
1400
1300
1200
1100
1000
900
800
700
600
500
400
300
200
100
0
1950 1952 1954 1956 1958 1960 1962 1964 1966 1968 1970 1972 1974 1976 1978 1980 1982 1984 1986 1988 1990 1992 1994 1996 1998 2000
National Institute for Statistics - 2003

Number of deaths in mortality groups (2000; Hungary)

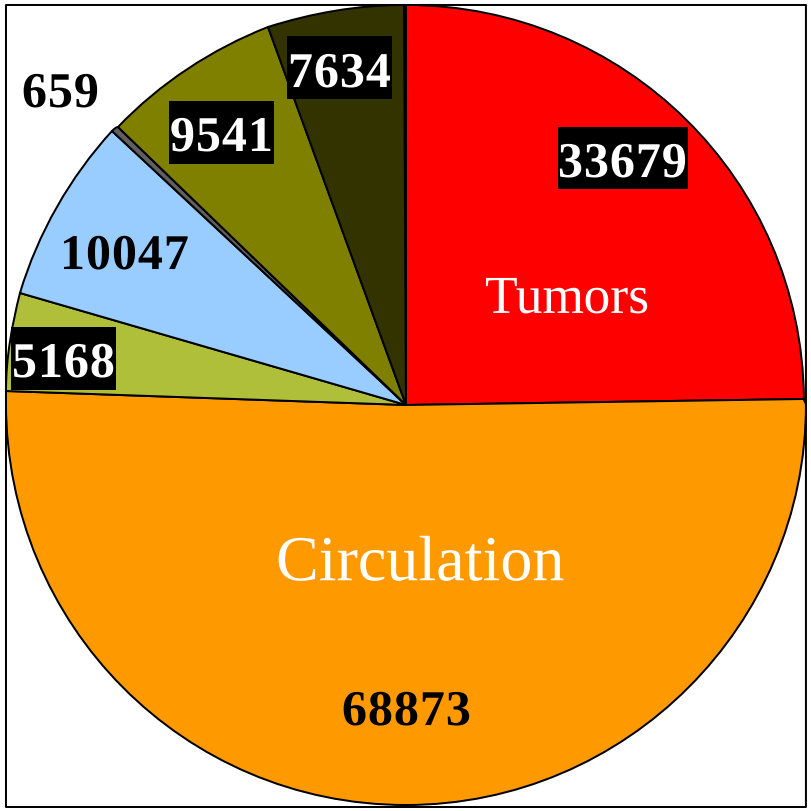

Division of cardiovascular death cases (2000; Hungary)

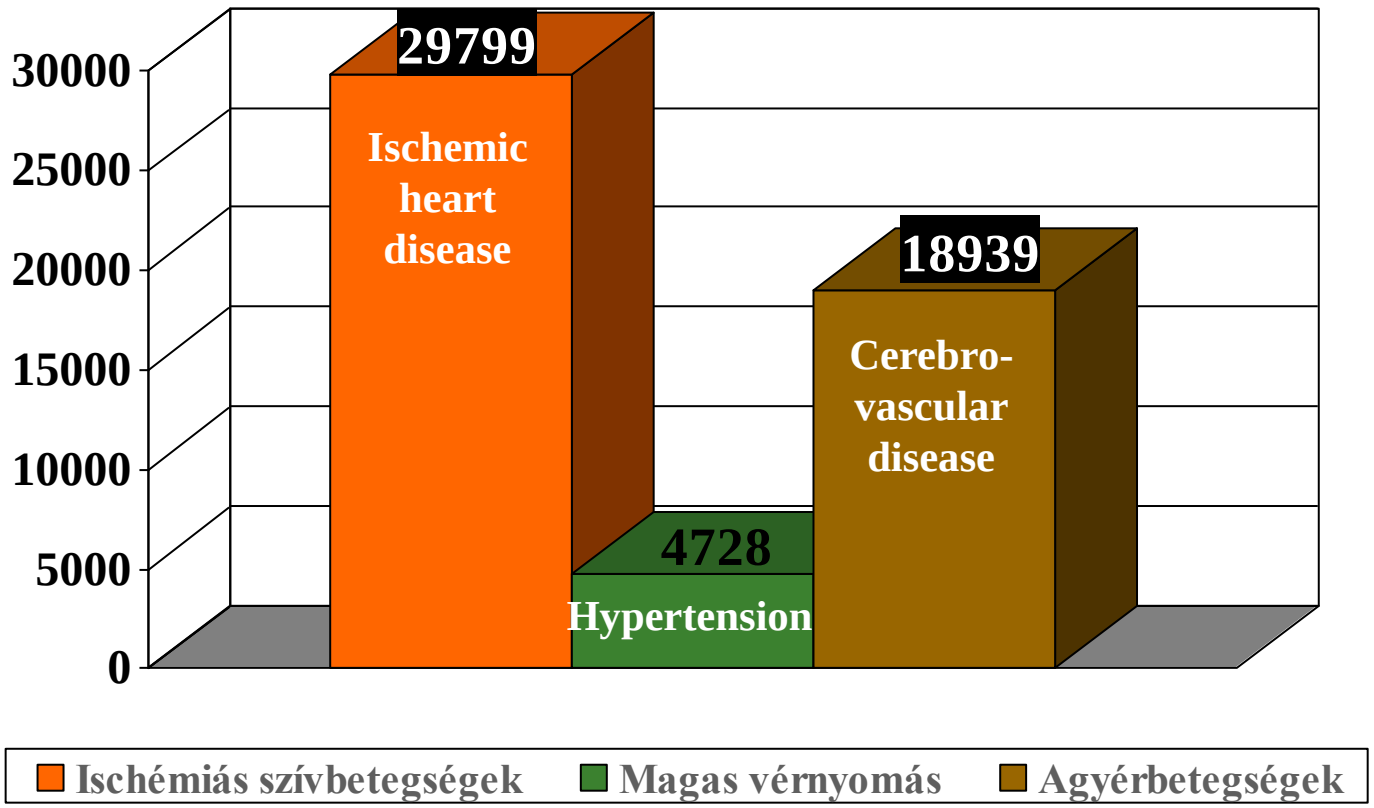

National Institute for Statistics - 2003

Atherosclerosis is cause of death

in

50%

of the cases on the western hemisphere.

Atherosclerosis in the young

Enos WF et al.: Coronary disease among United States soldiers killed in action in Korea: preliminary report. JAMA **1953**, 152: 1090-1093.

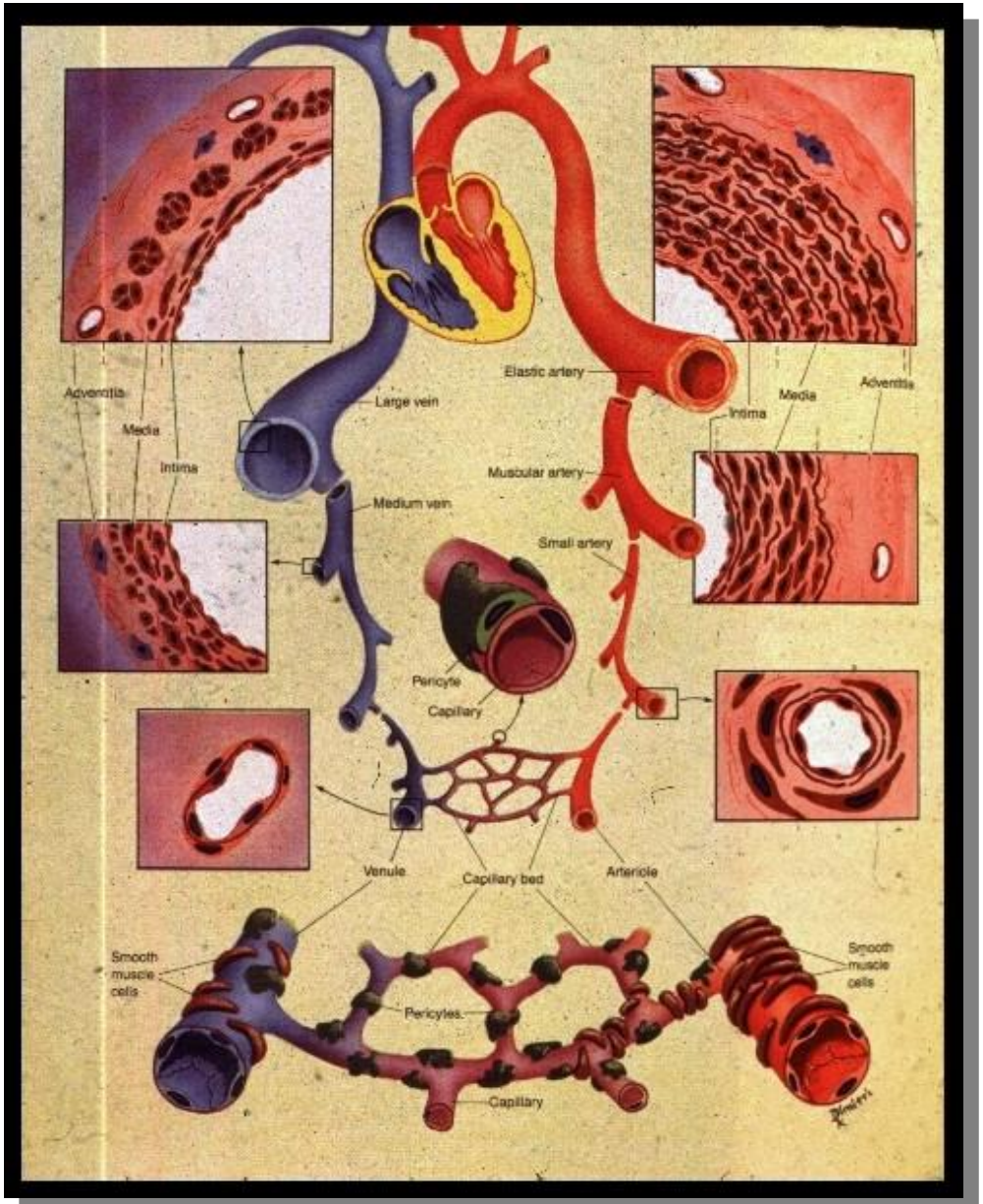
Adventitia
Media
Intima
Large vein
Elastic artery
Intima
Media
Adventitia
Muscular artery
Medium vein
Small artery
Pericyte
Capillary
Venule
Capillary bed
Arteriole
Smooth muscle cells
Pericytes
Capillary
Smooth muscle cells

Lipid metabolism

	MAJOR LIPIDS	MAJOR APOPROTEIN(S)
Chylomicron 80–500 nm	80–95% TG (dietary)	C proteins, AI, AII, B48
VLDL 30–80 nm	45–65% TG (endogenous) 25% cholesterol	C proteins, B48, E
IDL 30 nm	45% cholesterol	B100, E
LDL 15–25 nm	70% cholesterol	B100
HDL 5–12 nm	<25% cholesterol	AI, AII

Lipid metabolism

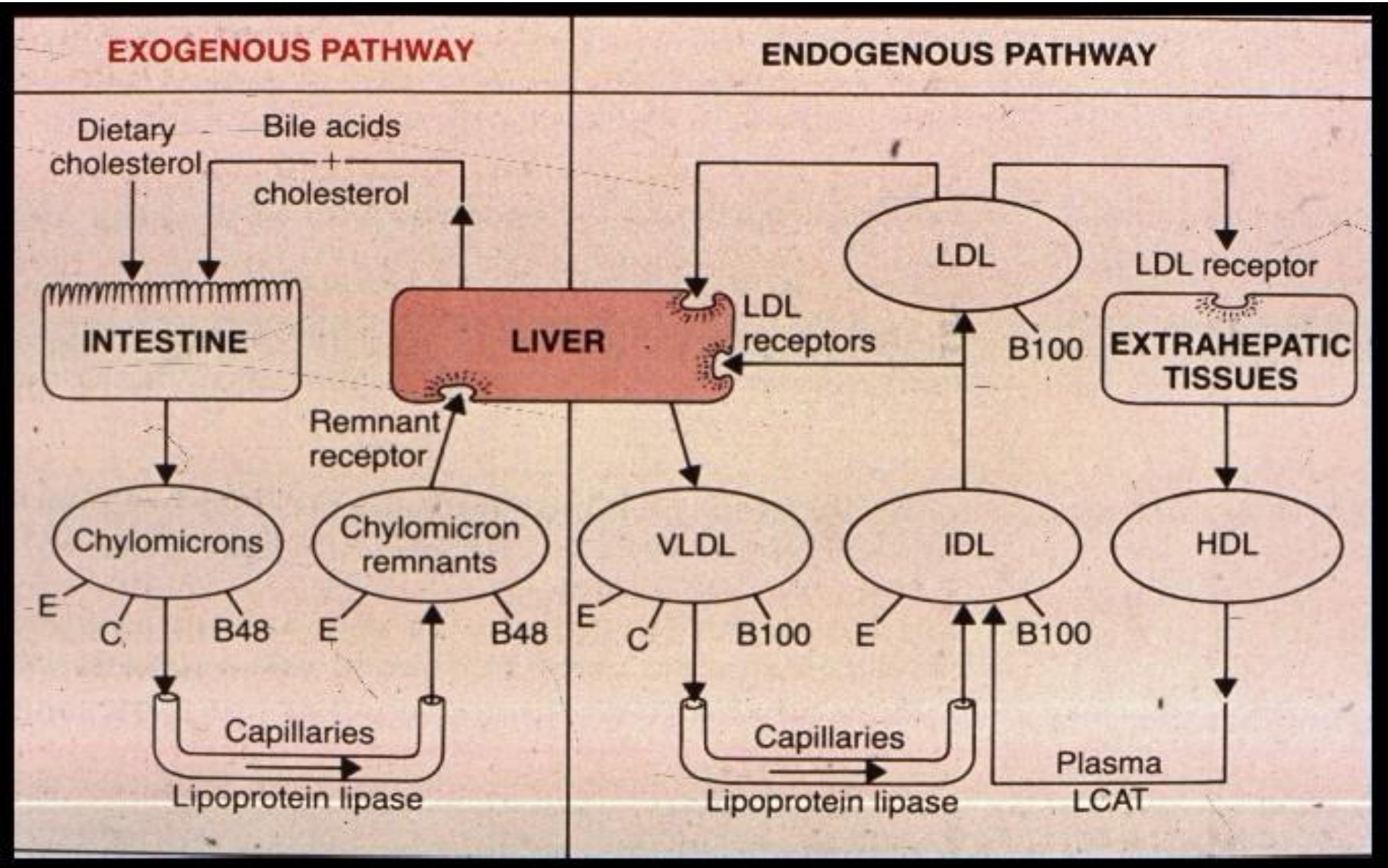

Functions of the intact endothelium

- Provision of a non-adherent, non-thrombogenic vascular inner surface
- Regulation of
  - vascular wall permeability
  - fibrinolytic and coagulation characteristics of the vascular wall
  - adhesion of leukocytes and thrombocytes (so-called homing)
  - lipid oxydation
- Production of so-called chemoattractants
- Proliferation stimulus for vascular smooth muscle cells
- Production of extracellular matrix components
- Metabolic activity (e.g. LDL-oxydation)
- Maintenance of elasticity (vessel tonus through NO, PGI_2, Endothelin, Angiotensin II, TXA_2) and structure (e.g. basal membrane) of vessels
- Effectuation of inflammatory and immunologic reactions

Functions of monocytes/macrophages

- A cell type of central importance in atherogenesis
- Participation in lipid metabolism
  - oxydation
  - ingestion of extracellular lipid substances with formation of foamy cells
- Production of extraordinarily many kinds of cytokines and growth factores
  - growth stimulants: GM-CSF, M-CSF, HB-EGF, IGF-I, VEGF, bFGF, TGFα, PDGF, IL-2
  - growth antagonists: IL-1, TNFα, TGFß
  - chemoattractants: MCP-1, oxLDL
- Antigen presentation for T-cells
- 'Scavanger' function to eliminate harmful substances

Functions of smooth muscle cells

- Two different phenotypes: (a) contractile, (b) synthetic
- The contractile phenotype
  - rich in myofilaments
  - lipid uptake and excretion in equilibrium: no lipid accumulation, no foamy cells
- The synthetic phenotype
  - rich in rough endoplasmatic reticulum (RER)
  - on cytokine stimulation (PDGF, bFGF, TGFß) production of extracellular matrix components and expression of LDL- and ‘scavanger’ receptors >>
  - >> disbalanced lipid-uptake and -excretion: lipid accumulation and formation of foamy cells
- Migration from the media into the intima

Theories on atherogenesis

- The «response to injury» theory
- The lipid theory
- The theory of monoclonal growth
- The thrombogenic theory
- The infection-inflammation / autoimmnune theory

The «response to injury» theory

- *In short*: Atherogenesis is a **stereotype counterreaction** of the vascular wall to **harmful effects of any kind** resulting in a typical vessel wall change: the **atherosclerotic plaque**.

- *Definition:* Arteriosclerotic **plaque** is a **degenerative** type **circumscribed** vessel wall **thickening** characterised by intramural **lipid**-rich substance **accumulation** and **fibrous tissue production** in proportions varying from plaque to plaque. Initially, plaque formation is confined to the gradually thickening intima, yet not changing the original wall structure; later the plaque extends from the intima over to the media to wash away, replaces these layers to result in fundamental **remodelling** of the vascular wall. *Main consequences*: **loss of** original vascular (a) **morphologic** composition, (b) **elasticity** (wind-pipe function – hardening or softening), (c) **patency** (altered hemodynamics).

- Harmful effects may be
  - cellbiologic
  - geometric
  - microanatomic *('progression-prone' vs. 'progression-resistant' locations)*
  - mechanic-hemodynamic
  - microenvironmental

- Backgrounds may be
  - genetic constitution of the body
  - chemical constitution of blood components

Hemodynamic factors of plaque formation

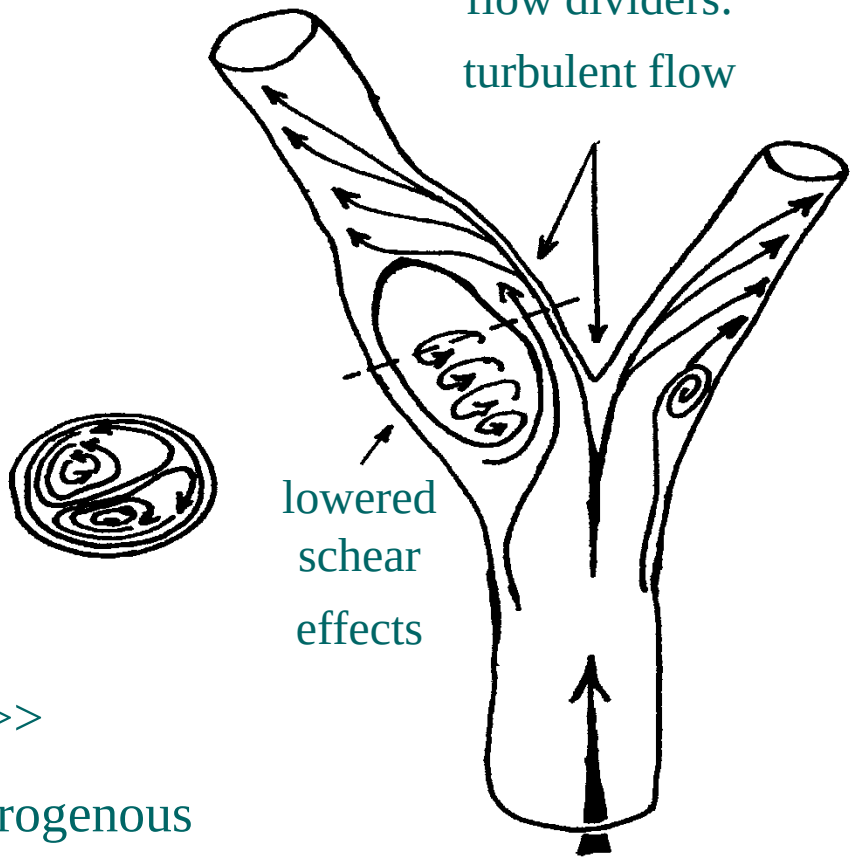

turbulent flow >>

slow passage of blood particles >>

lengthened activity time for atherogenous agents on a given vessel segment

Simple autopsy experience:
Atherosclerosis accentuated around vessel branchings

The «response to injury» theory

- *Central pathogenic event*: focal endothelial activation and readjustment of its reactivity and metabolism is the initiative step for atherogenesis and plaque formation.

- Endothelial stimulation
  - modification of the lipid metabolism (production of oxLDL!)
  - excretion of biologically active molecules (chemoattractants, mitogenes, growth regulators, NO, adhesion molecules, thrombogenic factors)

- According to this theory…
  - endothelial stimulation >>
  - adhesion and intimal gathering of circulating cellular elements: leukocytes, thrombocytes, monocytes, T-lymphocytes
  - enhanced endothelial permeability: intimal gathering of lipid substances >>
  - infiltration of medial smooth muscle cells into the intima across the internal elastic membrane and proliferation of intimal muscle cells >> phenotypic change from contractile to synthetic >> production of extracellular matrix components (esp. collagene)
  - monocytes turn to macrophages + synthetic smooth muscle cells: intake of excess extracellular lipides >> foamy cell formation

- Plaque stability is defined by plaque components: dimensions of the plaque's lipid core, proteolytic enzyme activity of cellular plaque elements, calcification

Factors in relation with endothelial damage/activation

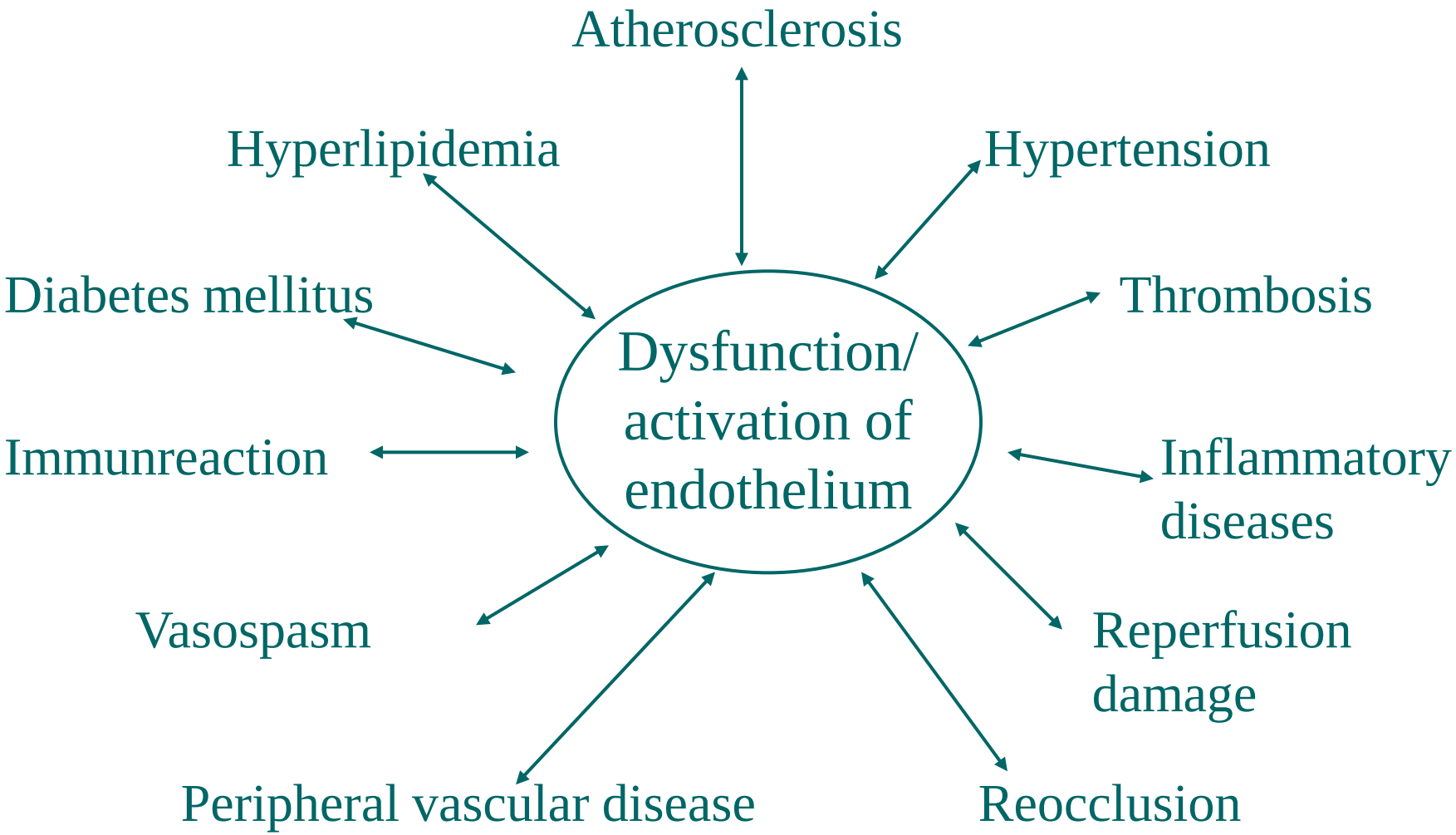

Heme-mediated cytotoxicity: an example of oxidative stress to the endothelium

- A recently proposed, **ubiquitous** mechanism of **endothelial damage**
- **Leakage of hemoglobin** from red blood cells and oxidation within the plasma >> production of ferri- or methemoglobin >> heme release from its proteins
- **Free heme and heme iron are toxic** to endothelium – both can catalyze free radical reactions and so e.g. potentiate cytotoxicity by activated polymorpho-nuclear leukocytes (PMN) (amplification of cellular damage arising from activated oxygen) >> in particular, the endothelial lining is at greatest risk of exposure to free heme and heme iron
- Mechanism of cellular damage: the highly hydrophobic **heme** can easily enter and **cross cell membranes** >> readily and spontaneous penetration of endo-thelial cells by heme >> liberation of heme iron, an especially **active catalyst of oxidation** of cell membrane constituents and LDL particles passing through the endothelium >> production of oxLDL >> **direct cytotoxicity and oxidative stress** particularly to vascular endothelium
- Mechanisms of defence: (a) **hemopexin** – a serum protein present at remarkably high concentrations in plasma, binding heme with extraordinary avidity, (b) **hap-toglobin, albumin** – plasma proteins with heme binding activity, (c) intracellu-lar mechanism – **heme oxygenase-1** (HO-1) and **ferritin**: cleavage of the porphyrin ring of heme by HO-1 releasing free redox active iron, the latter being effective-ly sequestered by the antioxidant iron storing protein, ferritin

Participants in atherogenesis

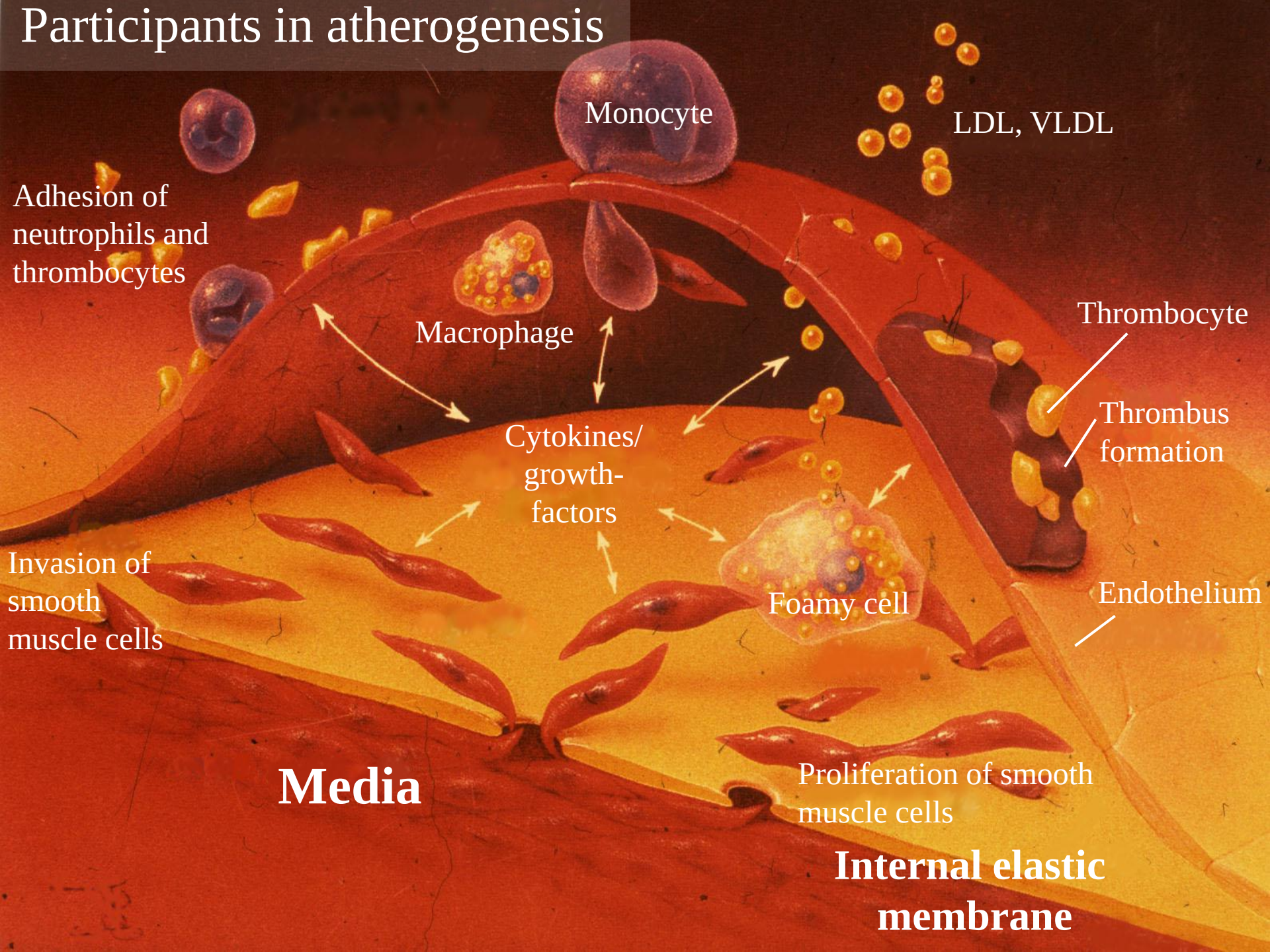

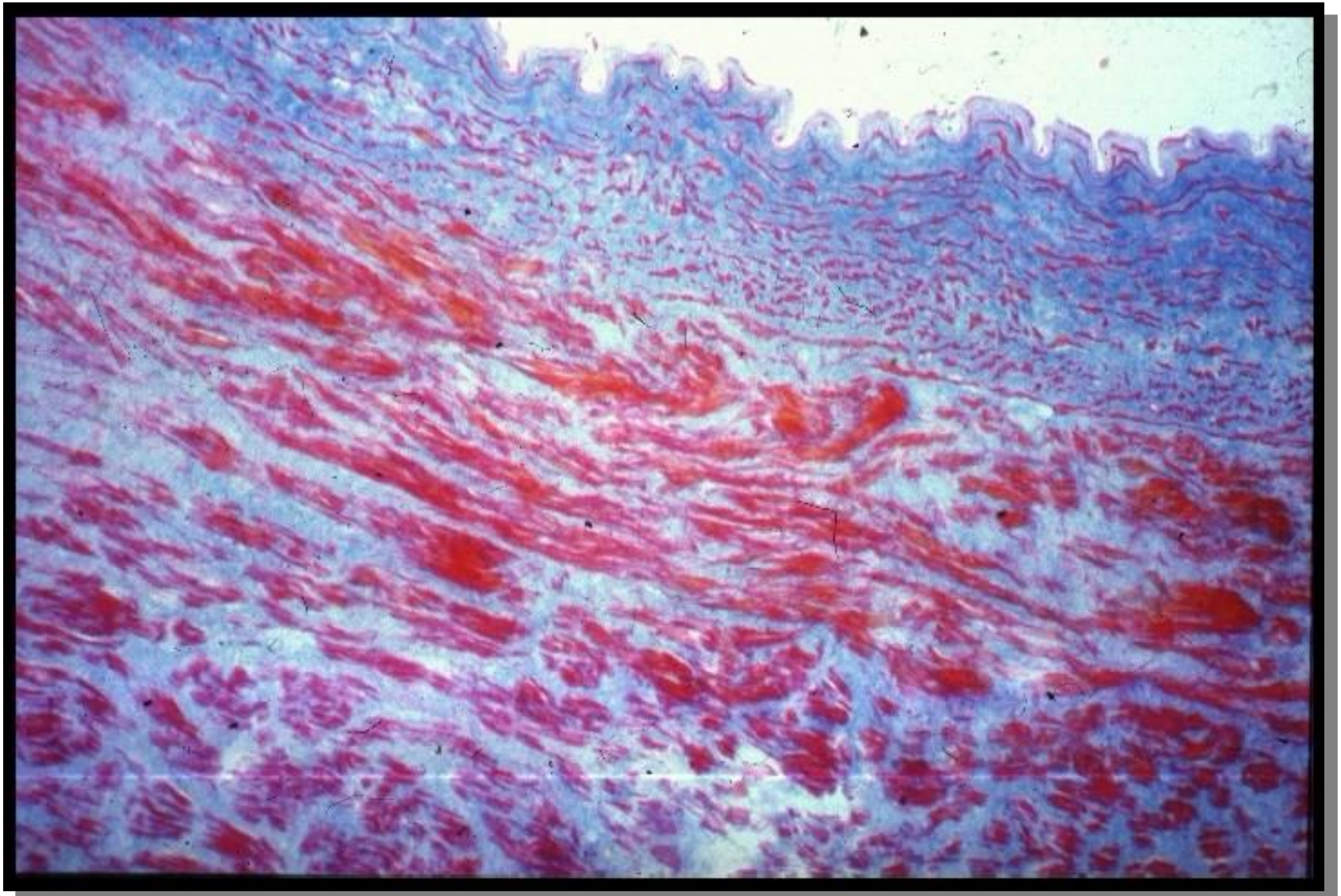

The lipid theory

- *Central pathogenic event*: Insudation of lipid substances into mural structures of the vessels.
- Epidemiologic, clinico-pathologic analyses
  - correlation of body weight with atherosclerosis
  - LDL,VLDL ↑, and HDL ↓: enhanced risk for plaque formation
- Animal experiments (atherogenic diet)
- Inherited derangements of lipid metabolism
  - partial or complete loss of receptors; genetic damage
  - familiar hyperlipidemia

The lipid theory

- According to this theory…
  - Lipid insudation into the intima >>
  - LDL-receptors of monocytes/macrophages infiltrating into the intima become after a time oversaturated >> aspecific, so-called ‘scavanger’-receptors will be involved in the lipid uptake >> lipid ingestion exceeds metabolic capacities of the cell >> foamy cell formation
  - Appearance of macroscopic fatty streaks
  - Production of oxLDL >> endothelial stimulation by oxydative stress >> adhesion molecules and adherence of more monocytes

Genetic background of hyperlipoproteinemias

Lipoprotein types	Lipid types	Genetic damage	Atherogenity
LDL	Cholesterol	Mutation of the LDL-receptorgene	+++
LDL & VLDL	Cholesterol & Triglicerides	Mutation of the LDL-receptorgene	+++
VLDL	Triglicerides	Mutation of the lipoproteinlipase-gene	+
VLDL & Chylomicron	Triglicerides & Cholesterol	Mutation of the apoprotein- or lipoproteingene	+

The theory of monoclonal growth

- According to this theory…
  - Proliferation of smooth muscle cells should be monoclonal, similar to tumors – this theory was never proven

The thrombogenic theory

- According to this theory…
  - Mural (not necessarily occlusive) thrombosis >> further gathering of circulating cellular elements >> organisation of thrombus >> plaque formation
  - According to present understanding, thrombosis is rather a complication than an initial step of atherogenesis

Commonly acknowledged risk factors of arteriosclerosis and their effects

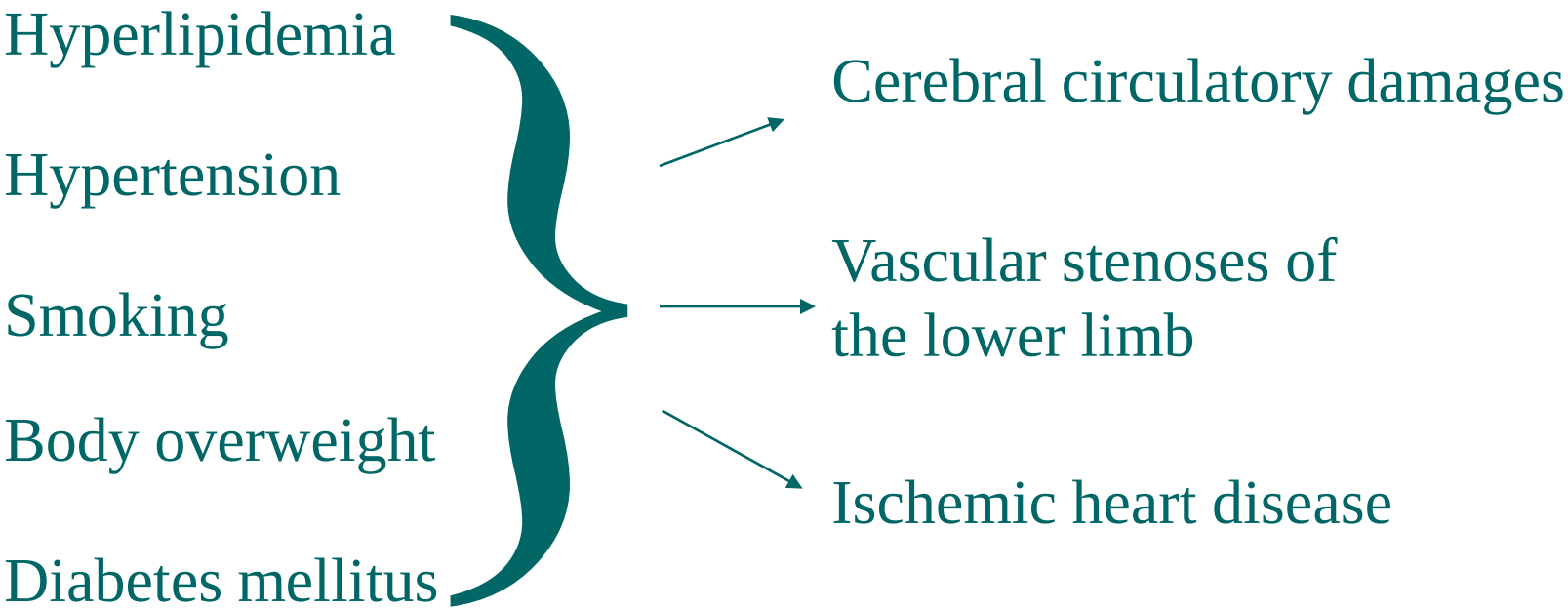

Atherogenesis:
conventional and ‘new’ risk factors

- *Conventional risk factors*
  - hypercholesterinemia
  - hypertension
  - diabetes mellitus, smoking
  - sex, age
  - hyperhomocysteinemia
  - inherited factors, genetic factors

in < 50% of the patients

- *„New” risk factors*
  - infectious agents
  - immune reaction
  - inflammation

Theory of infection: possible role of microbes in atherogenesis

Probable agents

Chlamydia pneumoniae
Helicobacter pylori
CMV
Herpes simplex virus
Mycoplasma pneumoniae

Newly proposed

Hepatitis A virus

Intracellular pathogenes

proinflammatory
procoagulant
proatherogenic
} activity

<>

humoral and cellular reactions

<>

autoimmunity (discovery of the so-called anti-cholesterol antibodies /ACHA/)

Chlamydia Genus

C. trachomatis (1907)
C. psittaci
C. pneumoniae (1989)
C. pecorum (1992)

Characteristics: - highly specialized, Gram-negative bacterium;
- obligatory intracellular energy parasite

Chlamydia pneumoniae: a factor in atherogenesis?

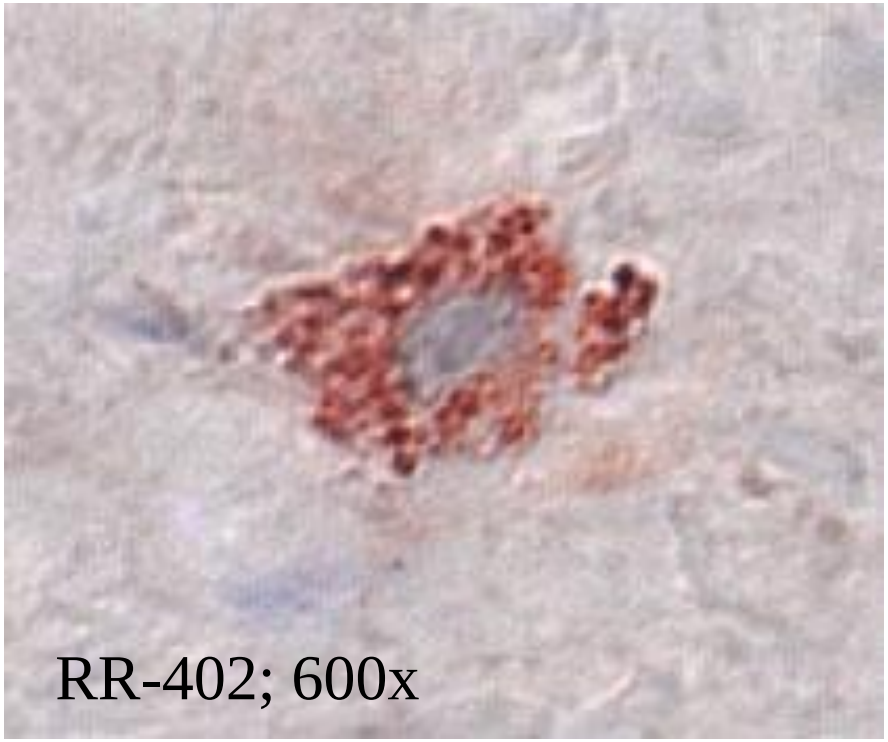

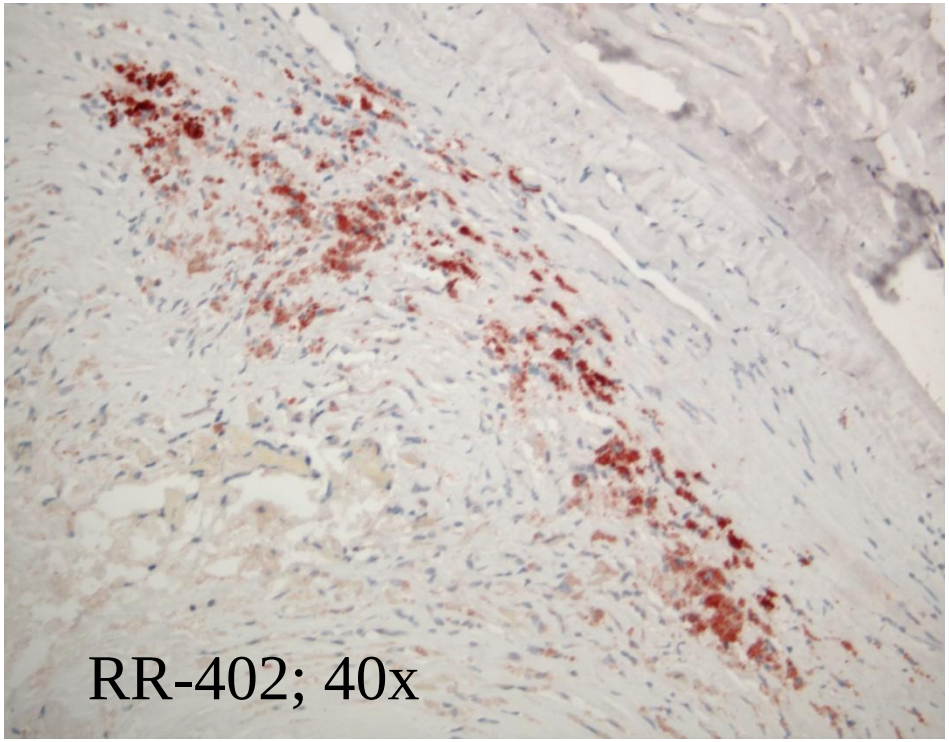

Demonstration of the agent in atherosclerotic plaques
by immunhistochemical reaction

Effect of important risk factors upon arteriosclerosis

Hyperlipidemia	Hypertension	Smoking	The pathologic reaction	The morphologic alteration
+	+	+	endothelial dysfunction	none
++	-	-	lipid deposition	fatty streaks
+	+	-	proliferation of smooth muscle cells, fibrosis	atheromatous plaque
++	+	-	plaque rupture, and thrombosis	complicated plaque

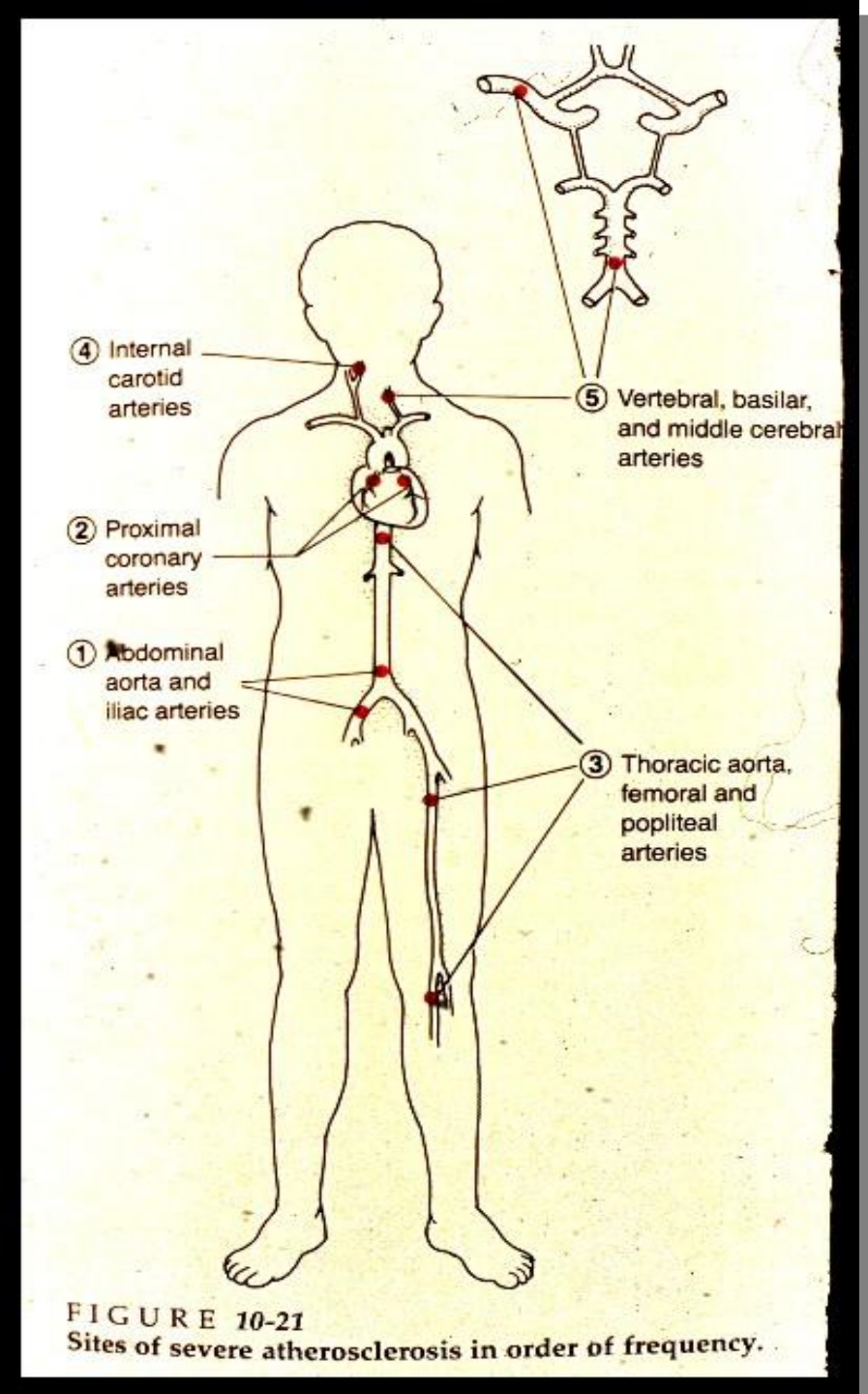

FIGURE 10-21
Sites of severe atherosclerosis in order of frequency.

Frequency of arteriosclerotic changes according to topographic sites

Thoracic aorta in healthy conditions

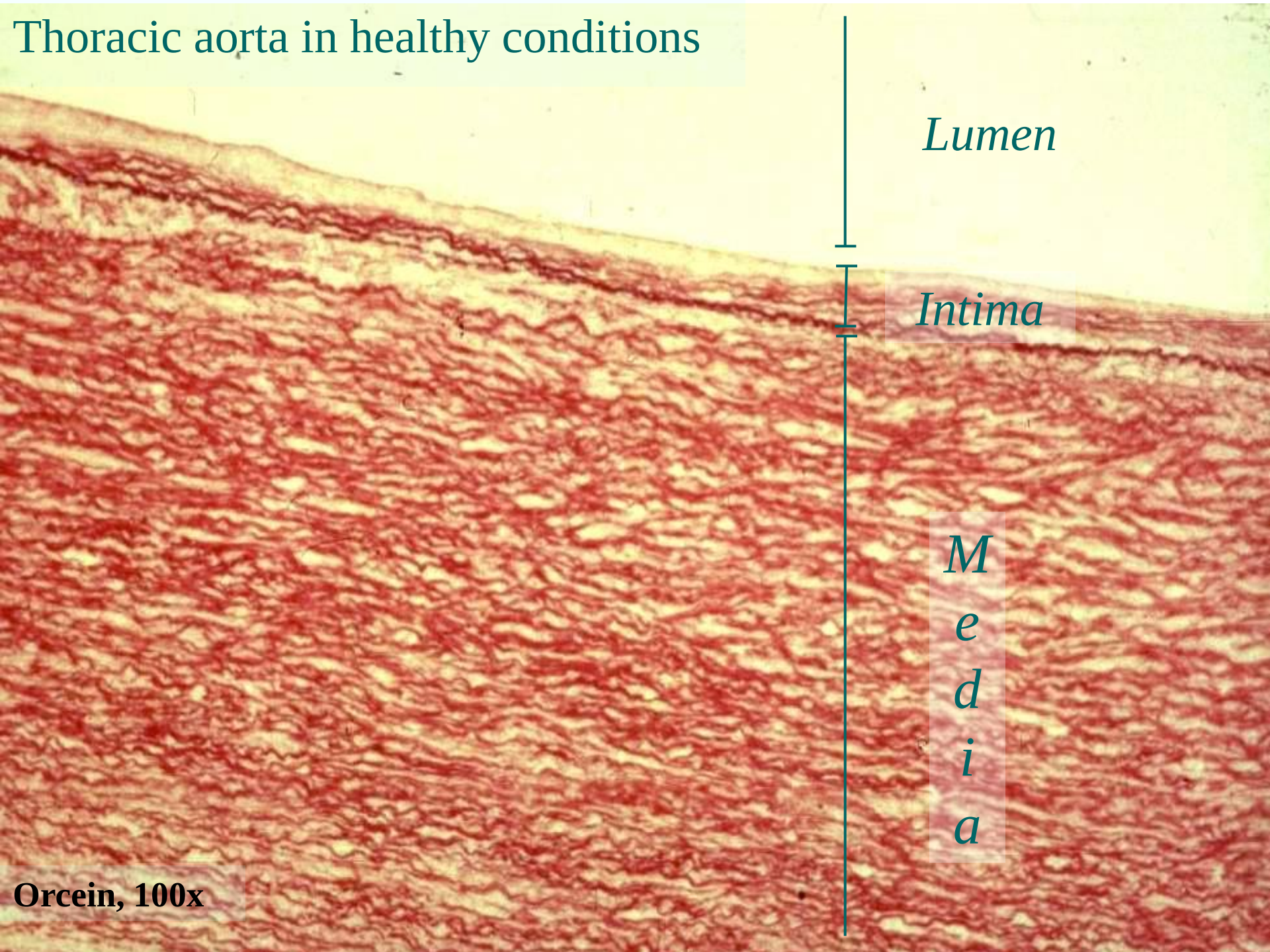

Orcein, 100x

Intact intimal inner surface of the aorta as seen on scanning electron microscopy

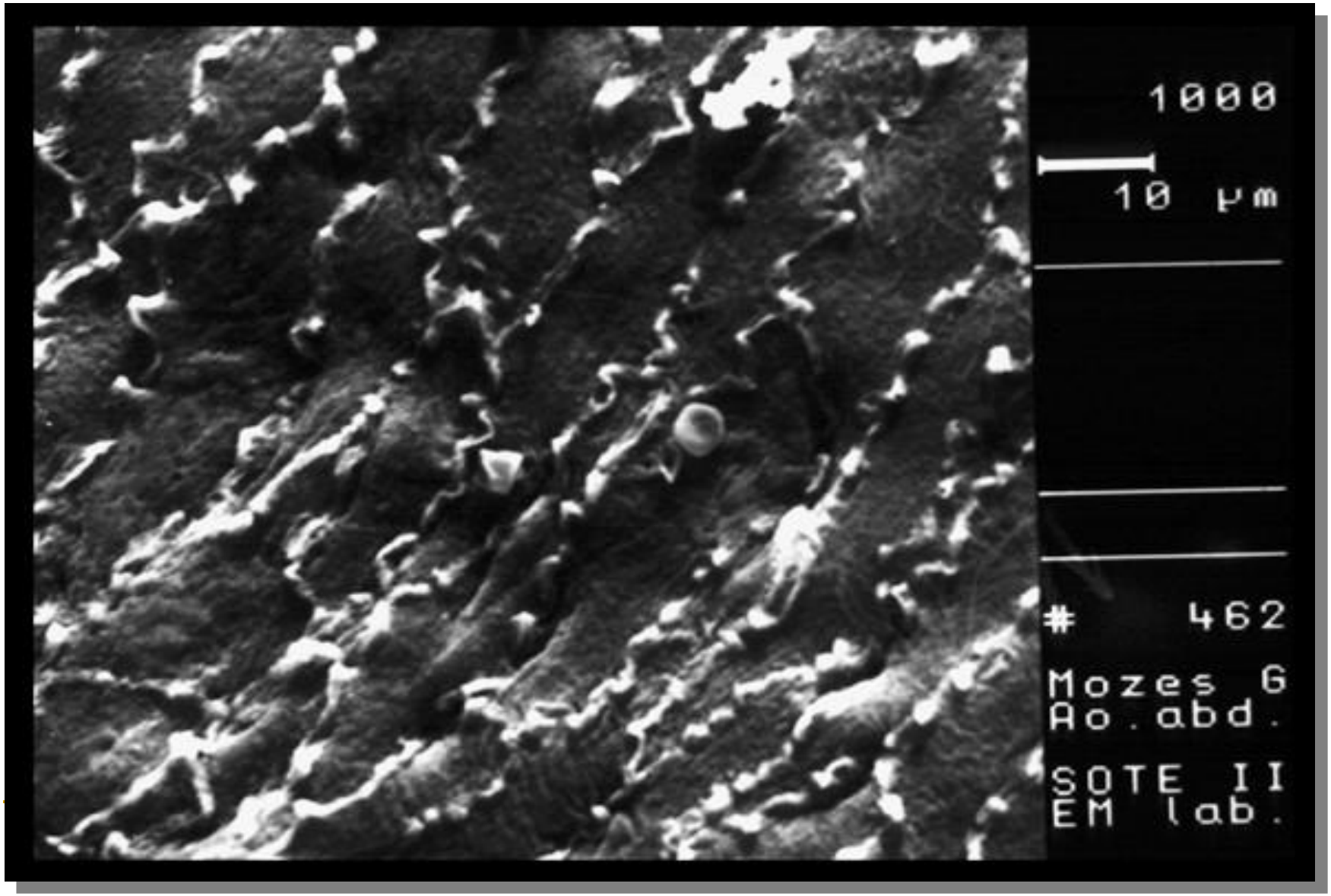

Morphologic forms of atherosclerosis

Early atherosclerosis: minimal plaque, nearly normal conditions (picrosyrius; 50x)

Stages of plaque formation

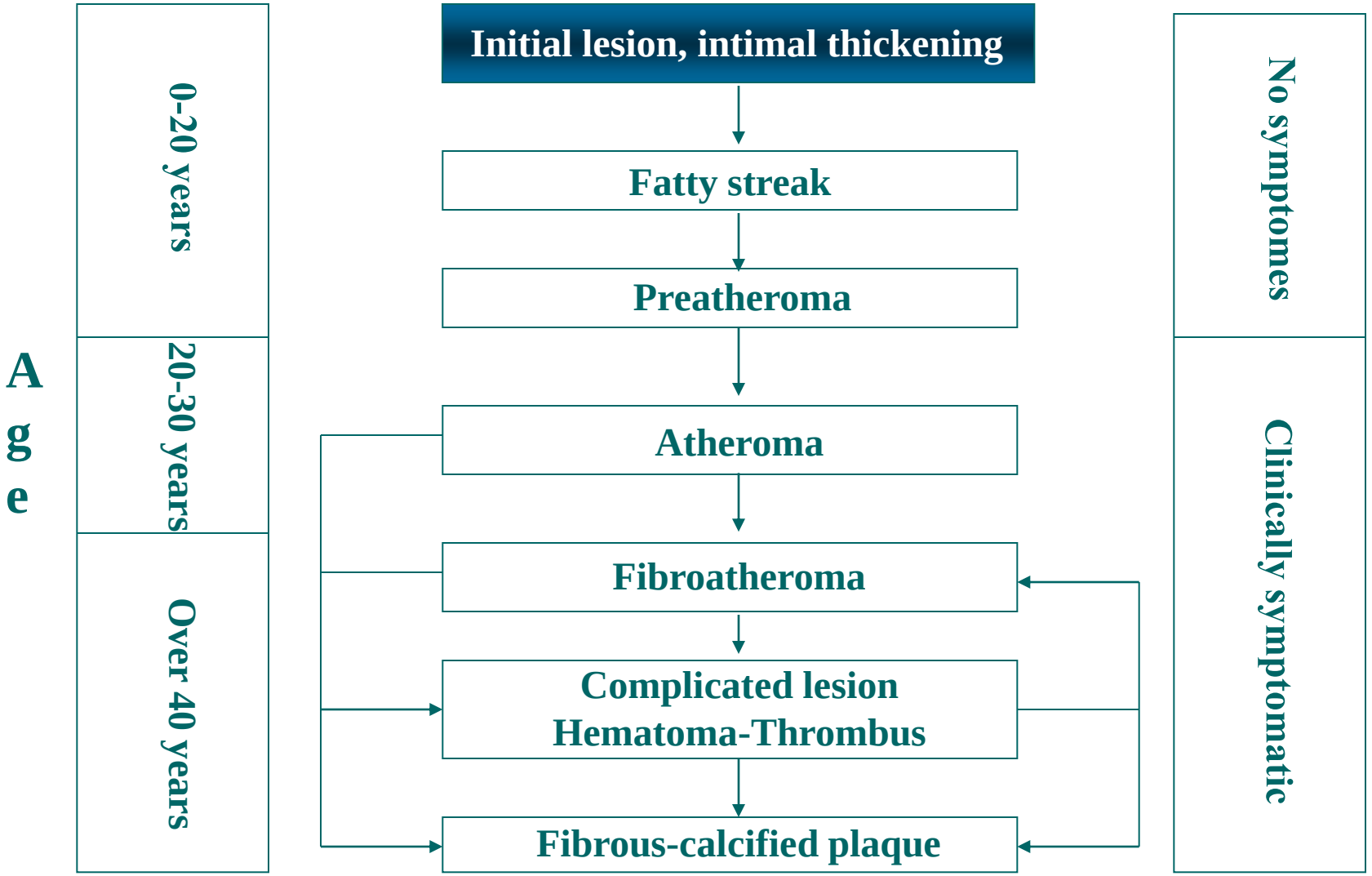

Morphologic forms of atherosclerosis

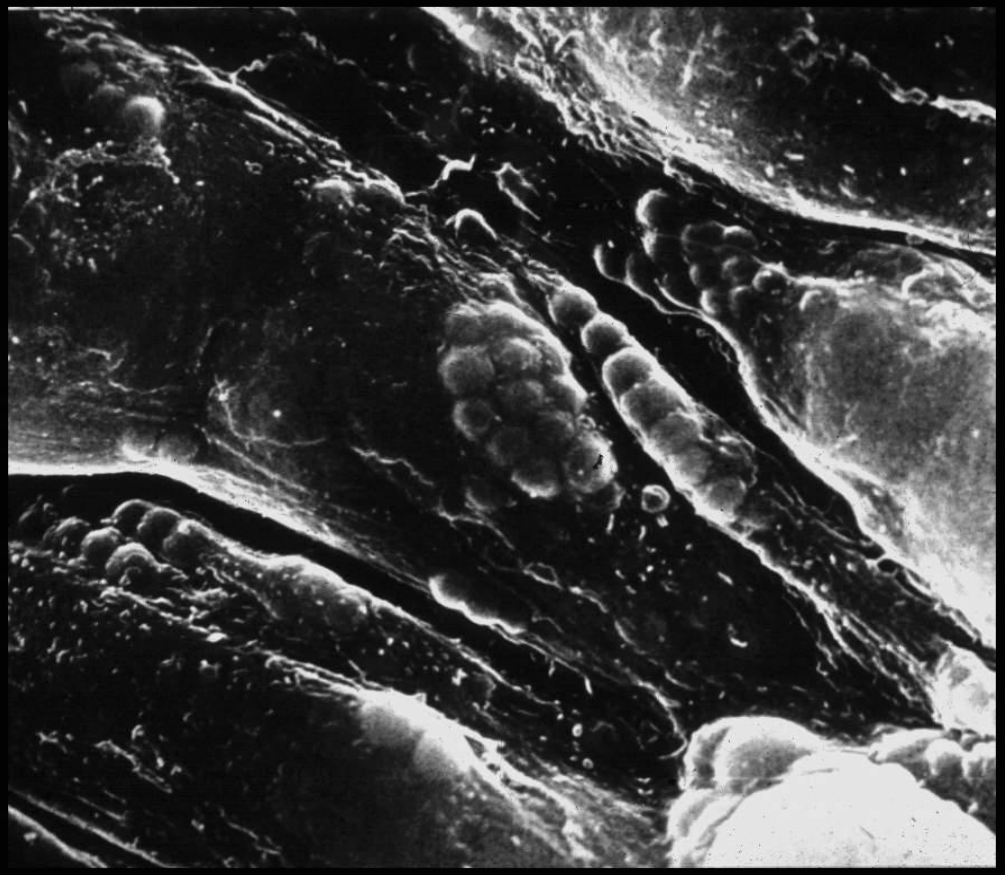

Early atherosclerotic lesion, AHA-Type I.:
intracellular lipid accumulation (scanning-EM; 3000x)

Morphologic forms of atherosclerosis

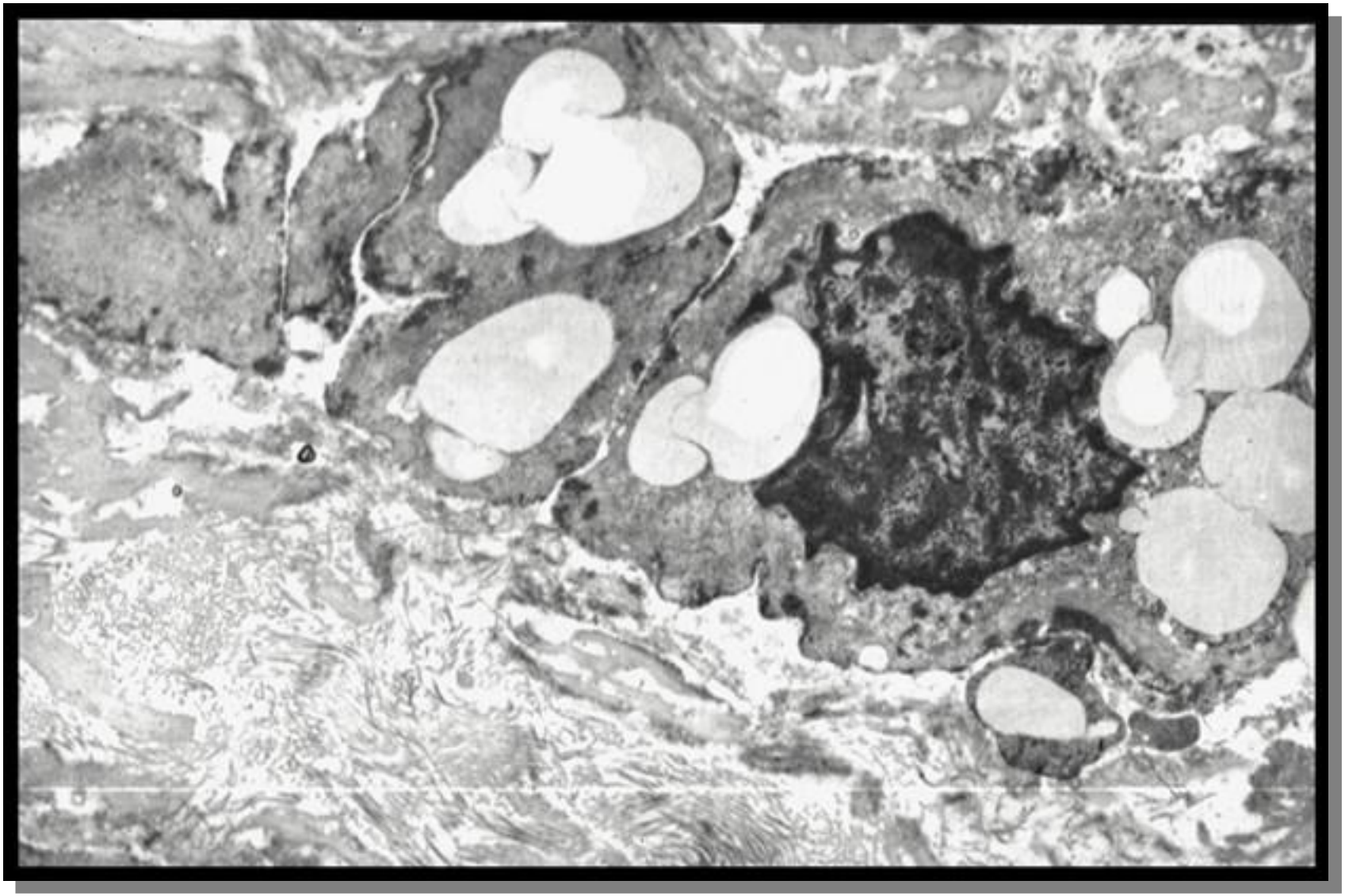

Early atherosclerotic lesion, AHA-Type I.:
intracellular lipid accumulation (transmission-EM; 4000x)

Stages of plaque formation

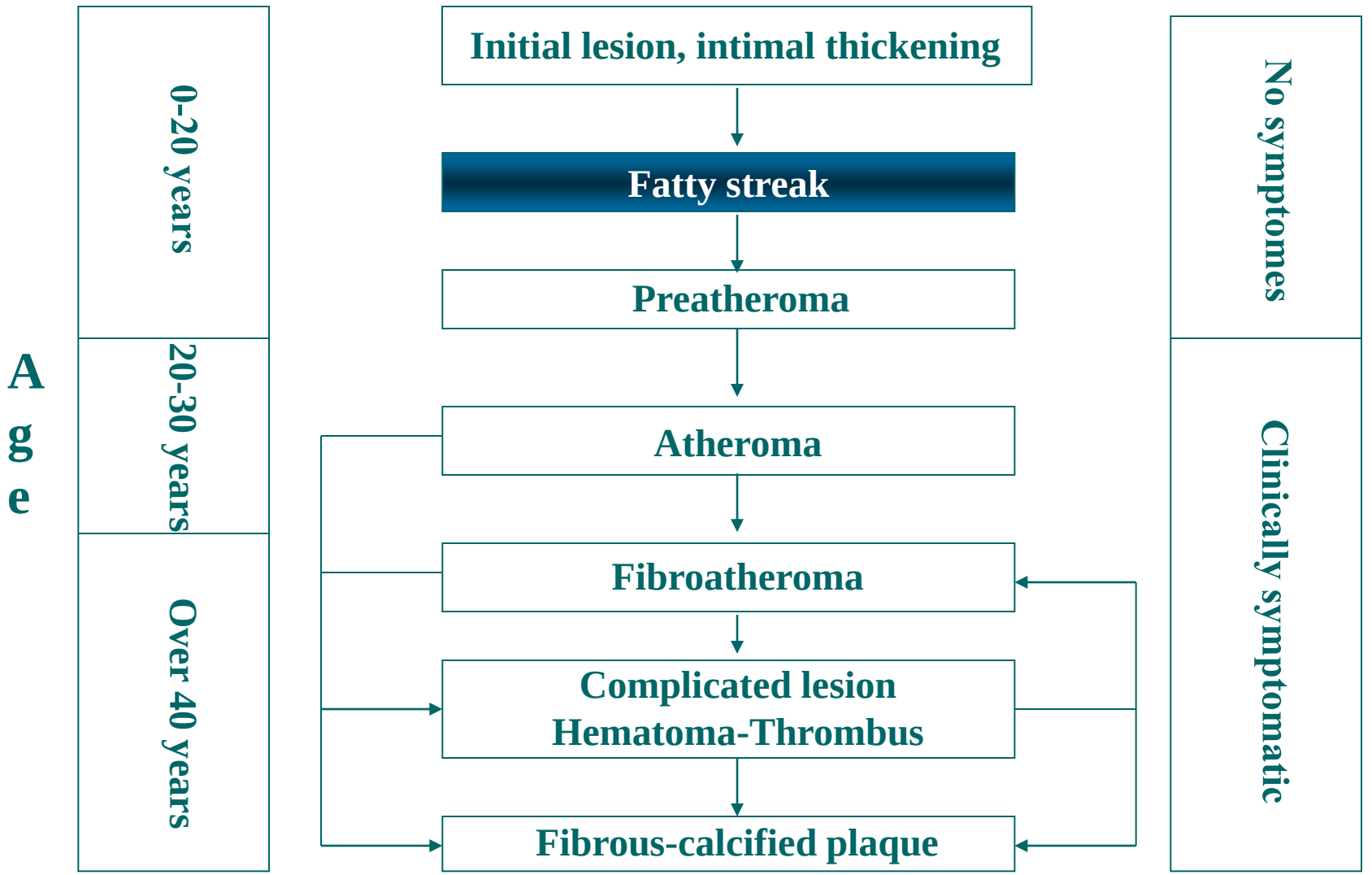

Morphologic forms of atherosclerosis

Early atherosclerotic lesion, AHA-Type II.:
fatty streaks – macroscopic appearance

Morphologic forms of atherosclerosis



Early atherosclerotic lesion, AHA-Type II.:
fatty streak (H&E; 100x)

Stages of plaque formation

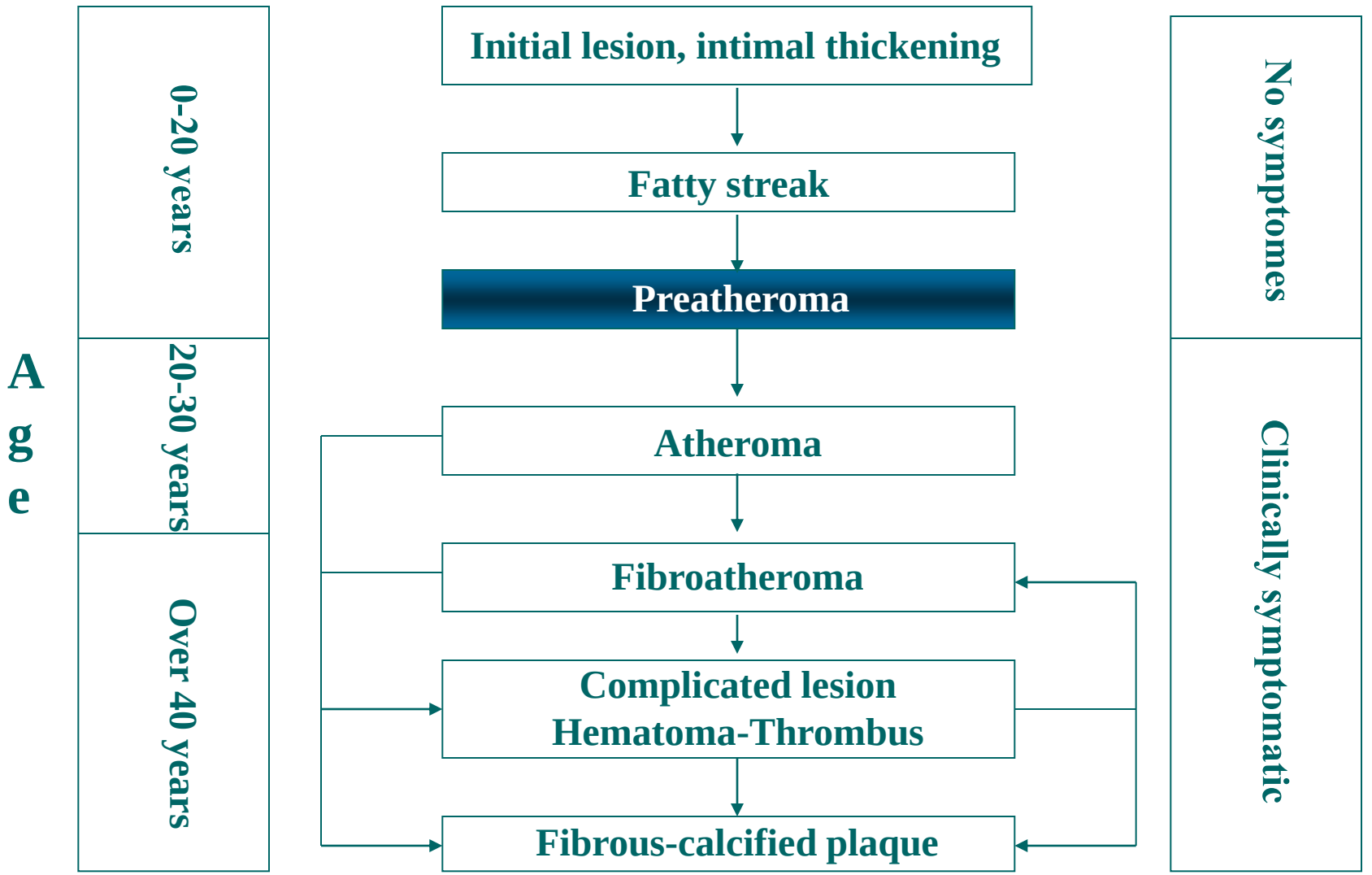

Morphologic forms of atherosclerosis

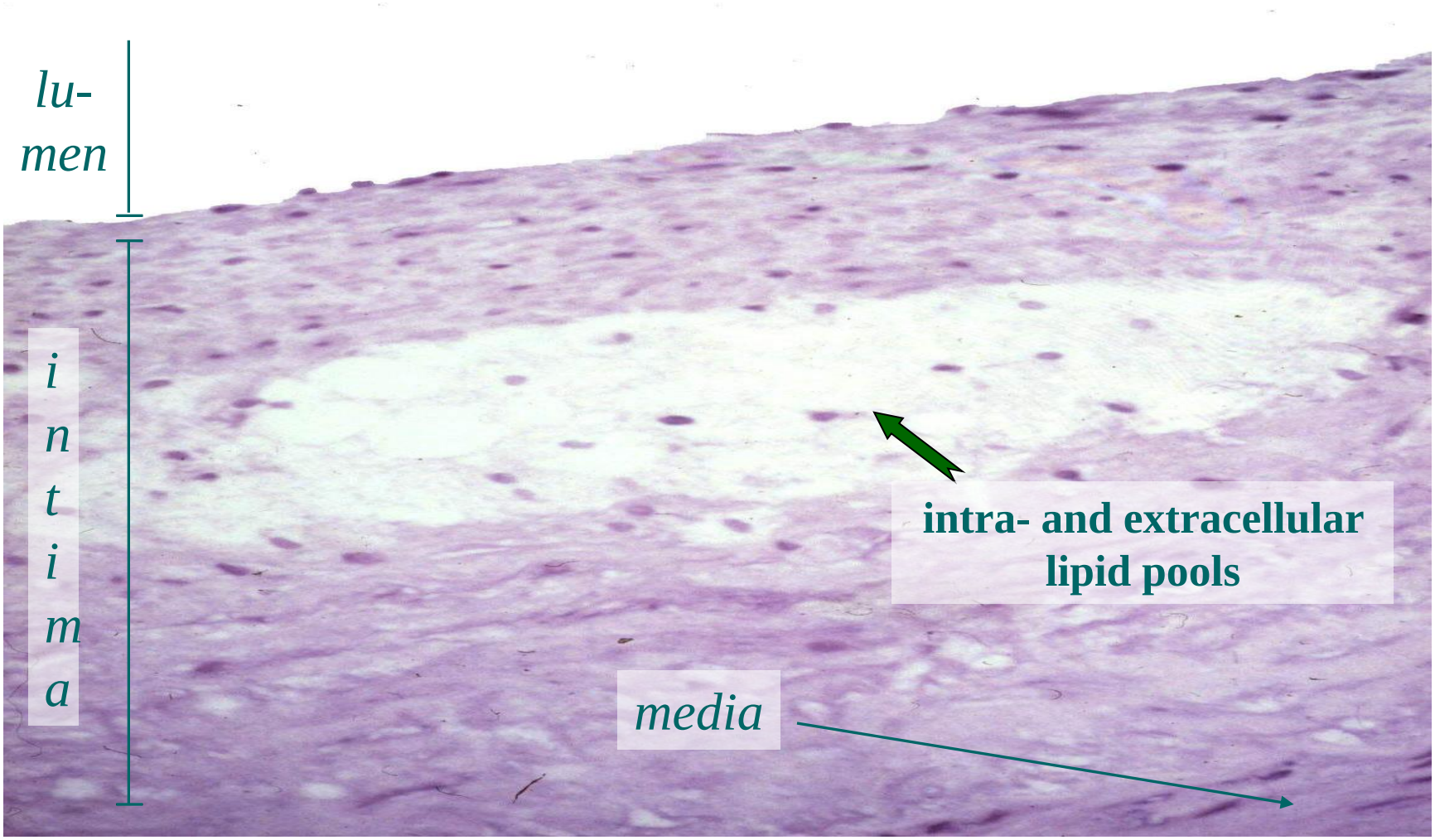

Intermediate atherosclerotic lesion, AHA-Type III.:
preatheroma (toluidine blue; 100x)

Stages of plaque formation

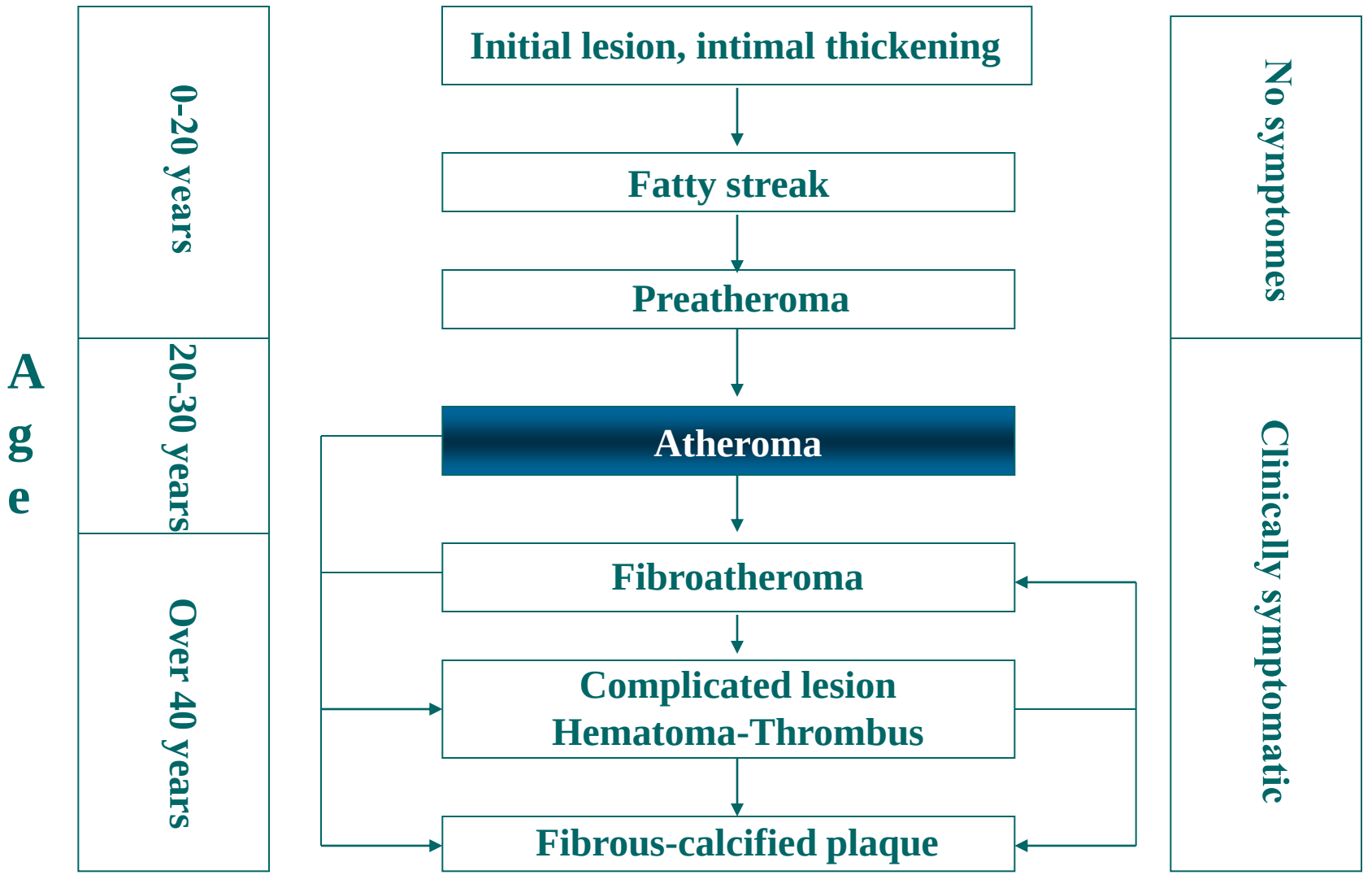

Morphologic forms of atherosclerosis

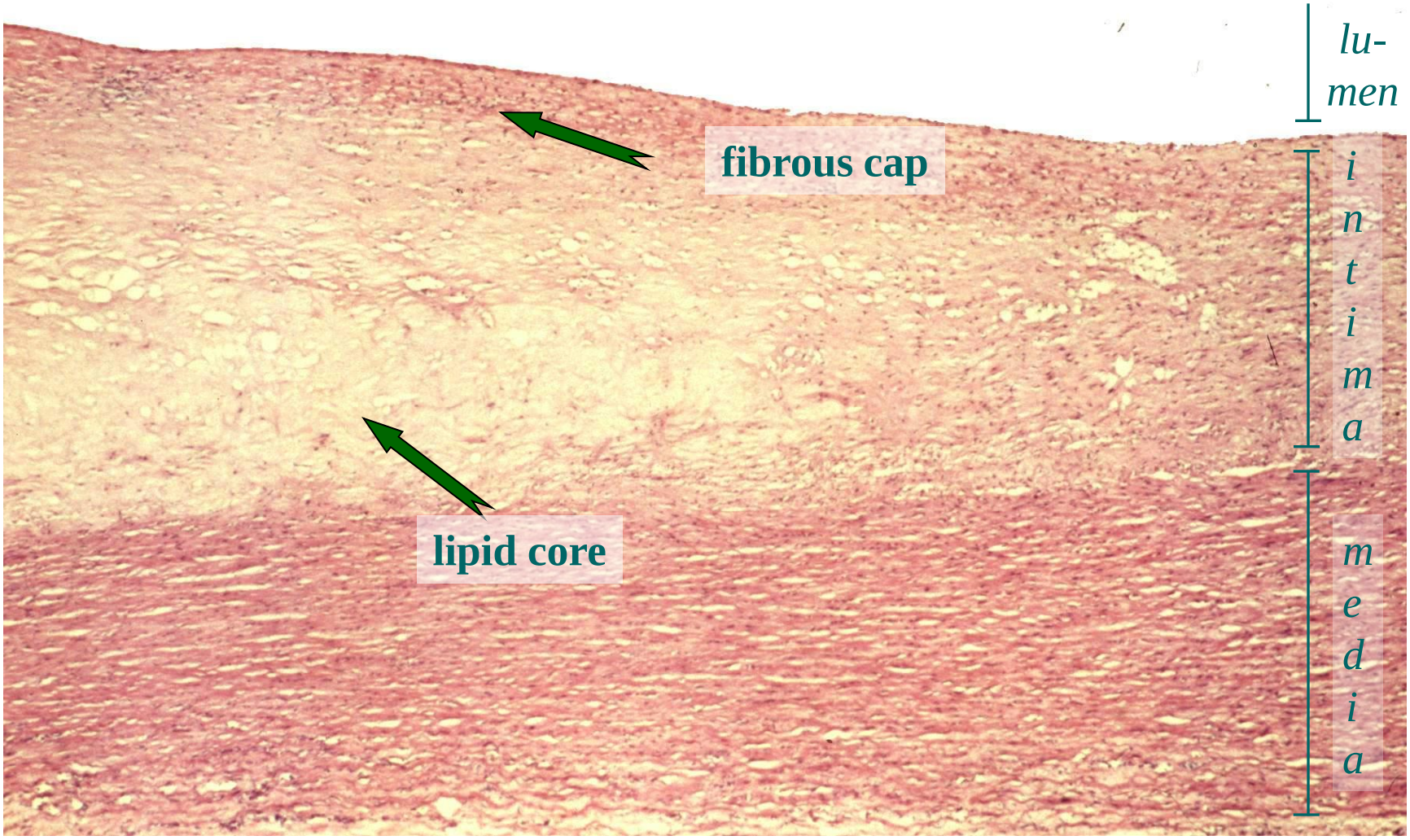

Advanced atherosclerotic lesion, AHA-Type IV.:
Atheroma (H&E; 100x)

Morphologic forms of atherosclerosis

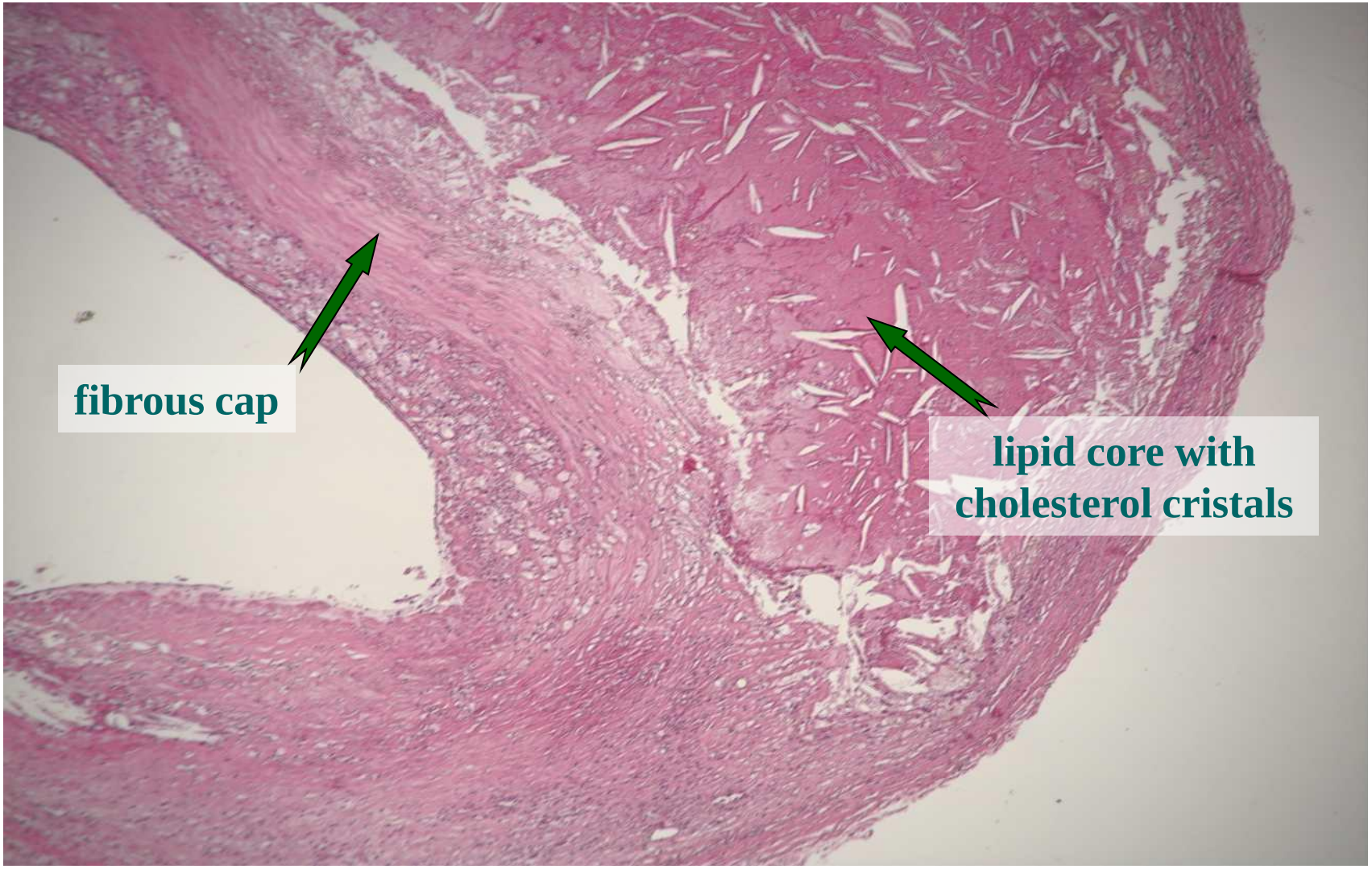

Advanced atherosclerotic lesion, AHA-Type IV.:
Atheroma (H&E; 50x)

Stages of plaque formation

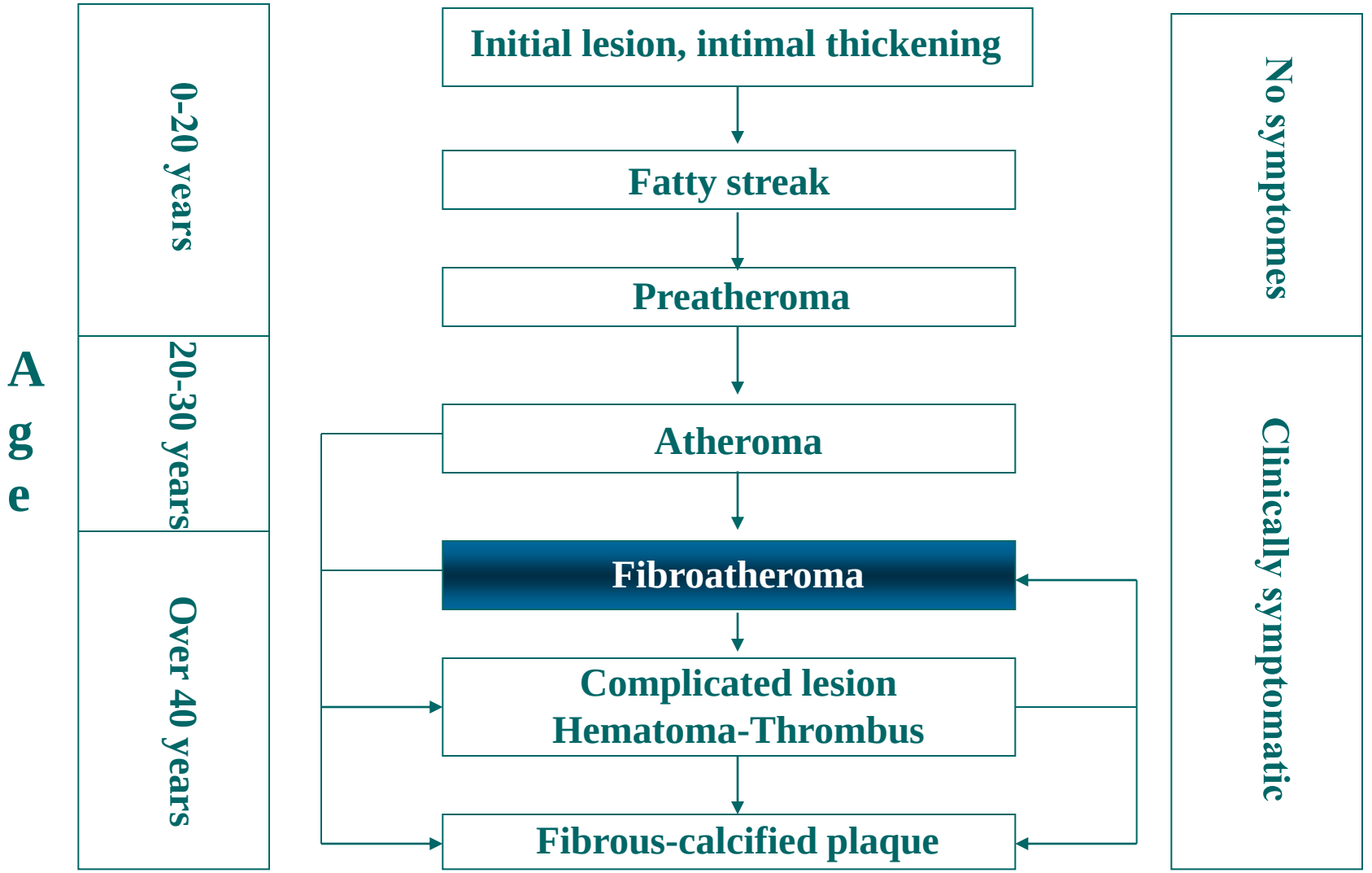

Morphologic forms of atherosclerosis

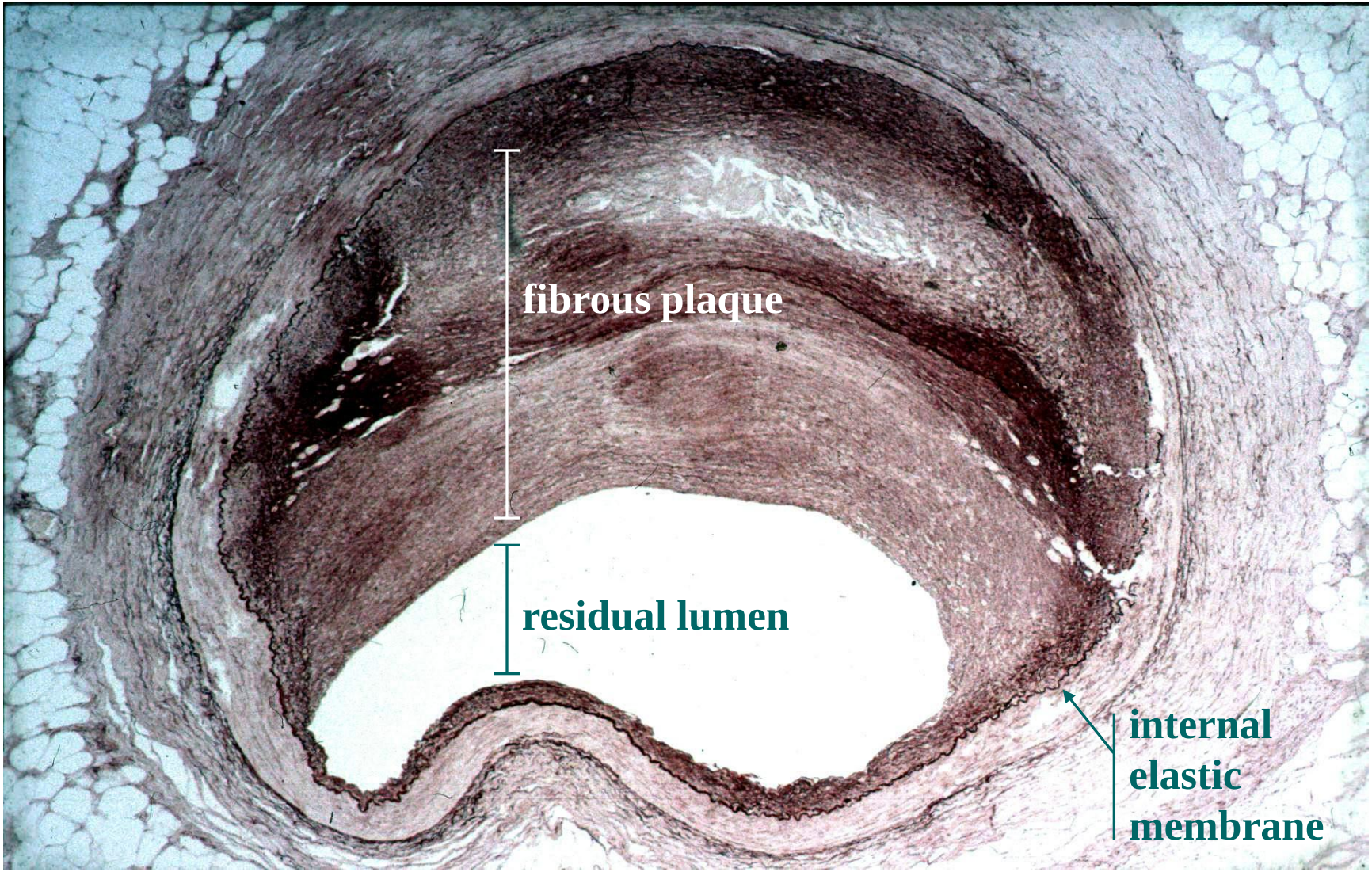

Advanced atherosclerotic lesion, AHA-Type V.:
Fibroatheroma (Orcein; 50x)

Morphologic forms of atherosclerosis

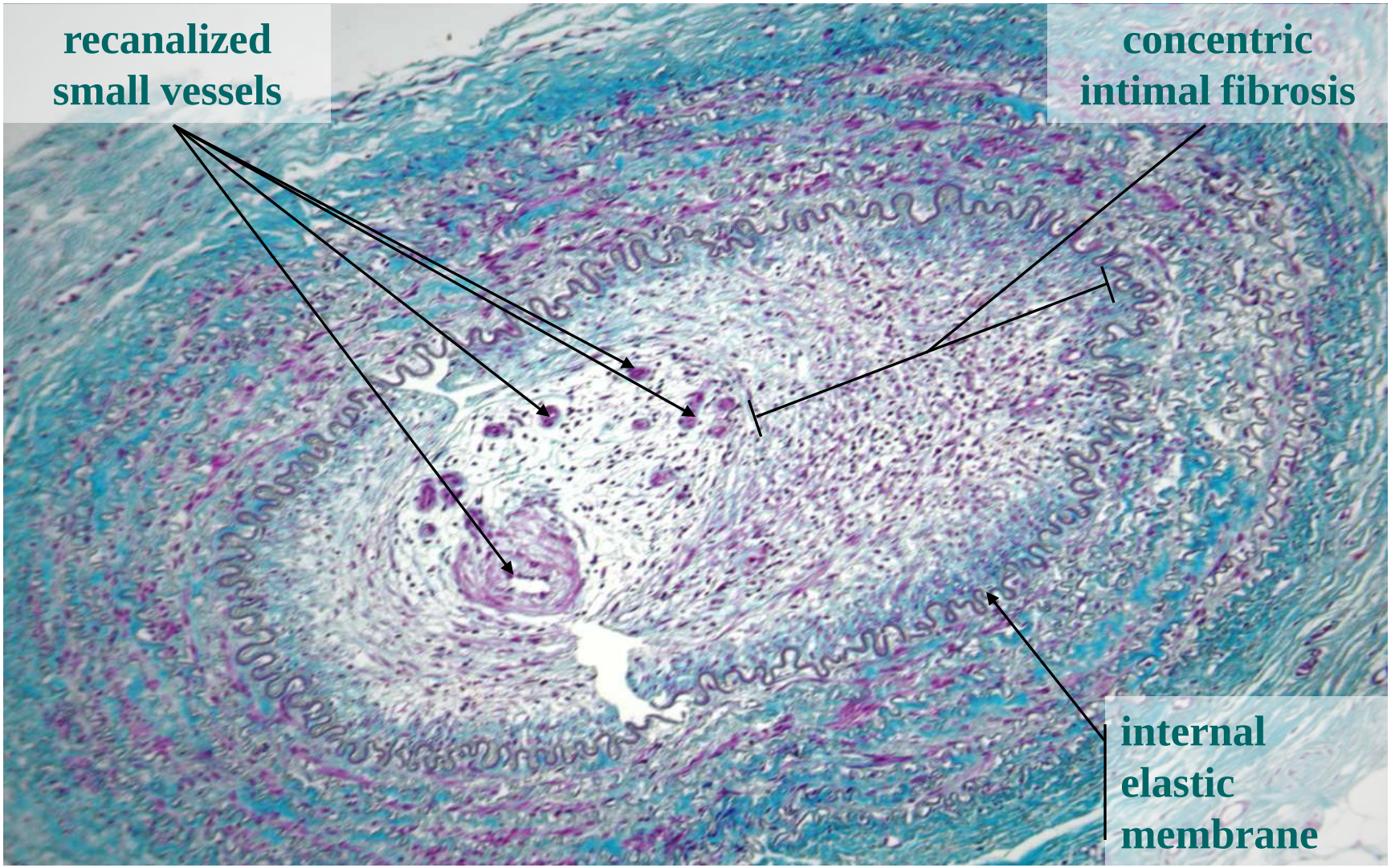

Fibrotic occlusion with recanalizing small vessels
apparently following intimal proliferation and obliterating thrombosis (Azan; 50x)

Stages of plaque formation

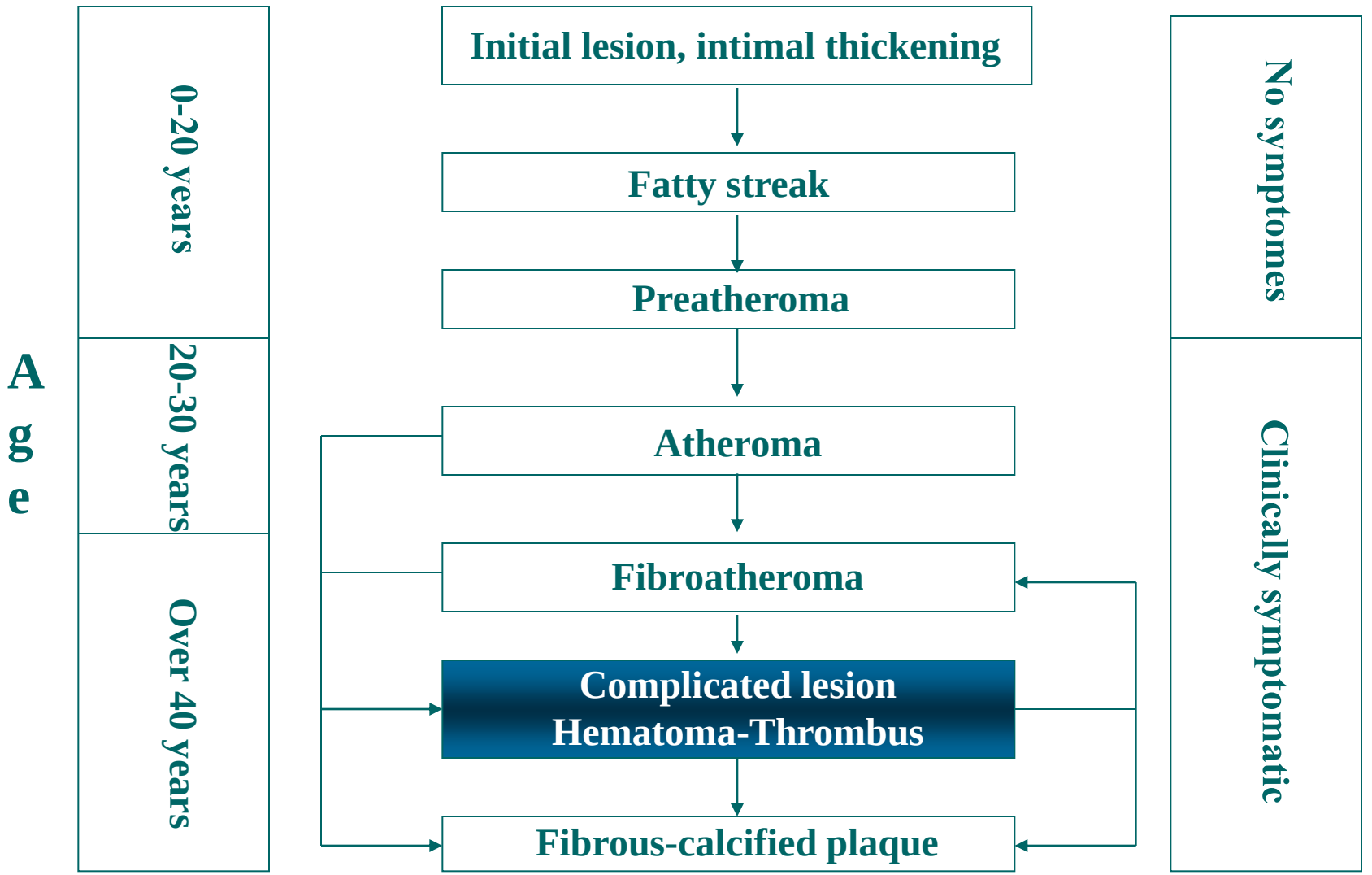

Morphologic forms of atherosclerosis

Severe atherosclerosis of the abdominal aorta with development of an aneurysm

Morphologic forms of atherosclerosis

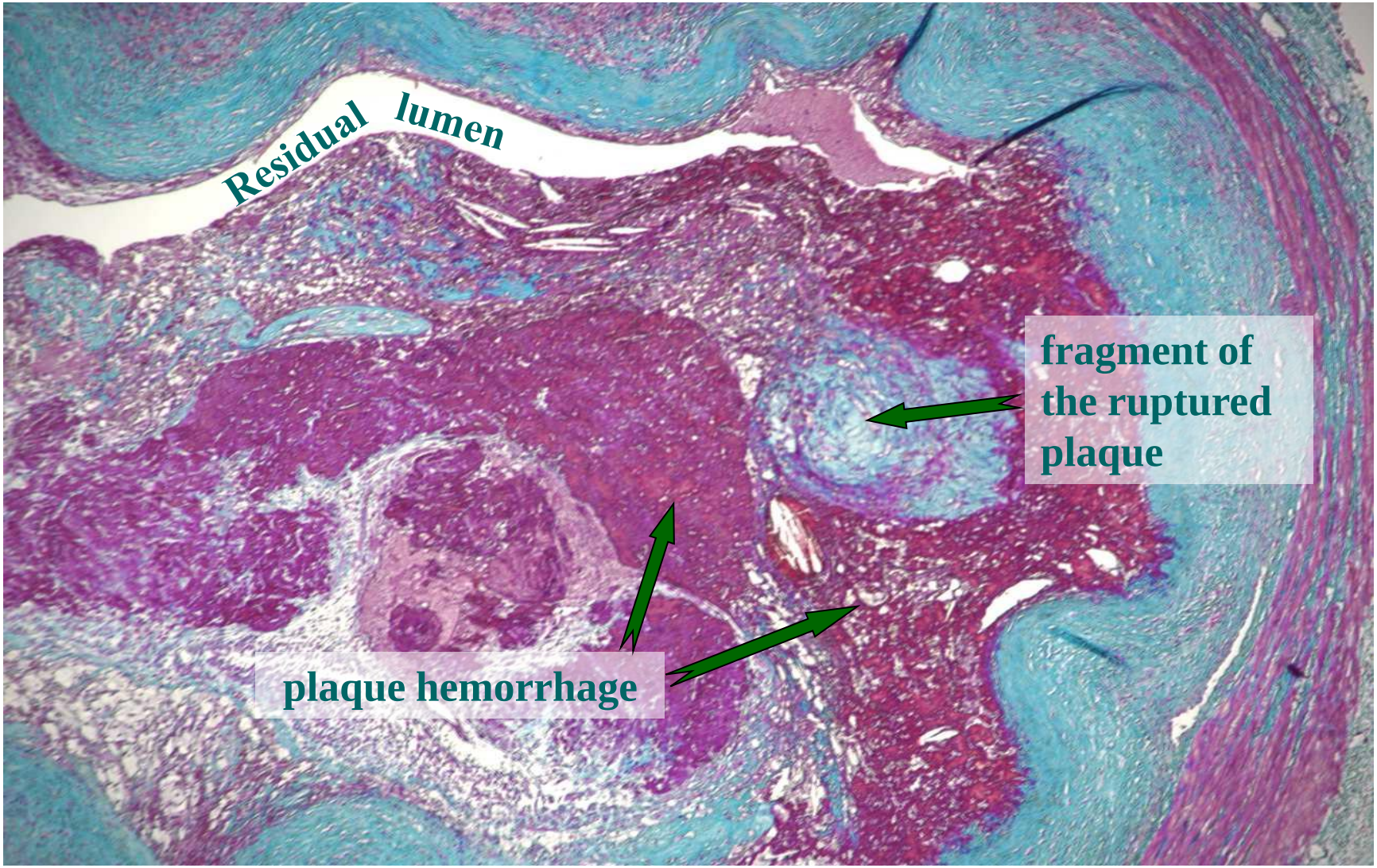

Advanced atherosclerotic lesion, AHA-Type VI.:
complicated plaque (Azan; 50x)

Stages of plaque formation

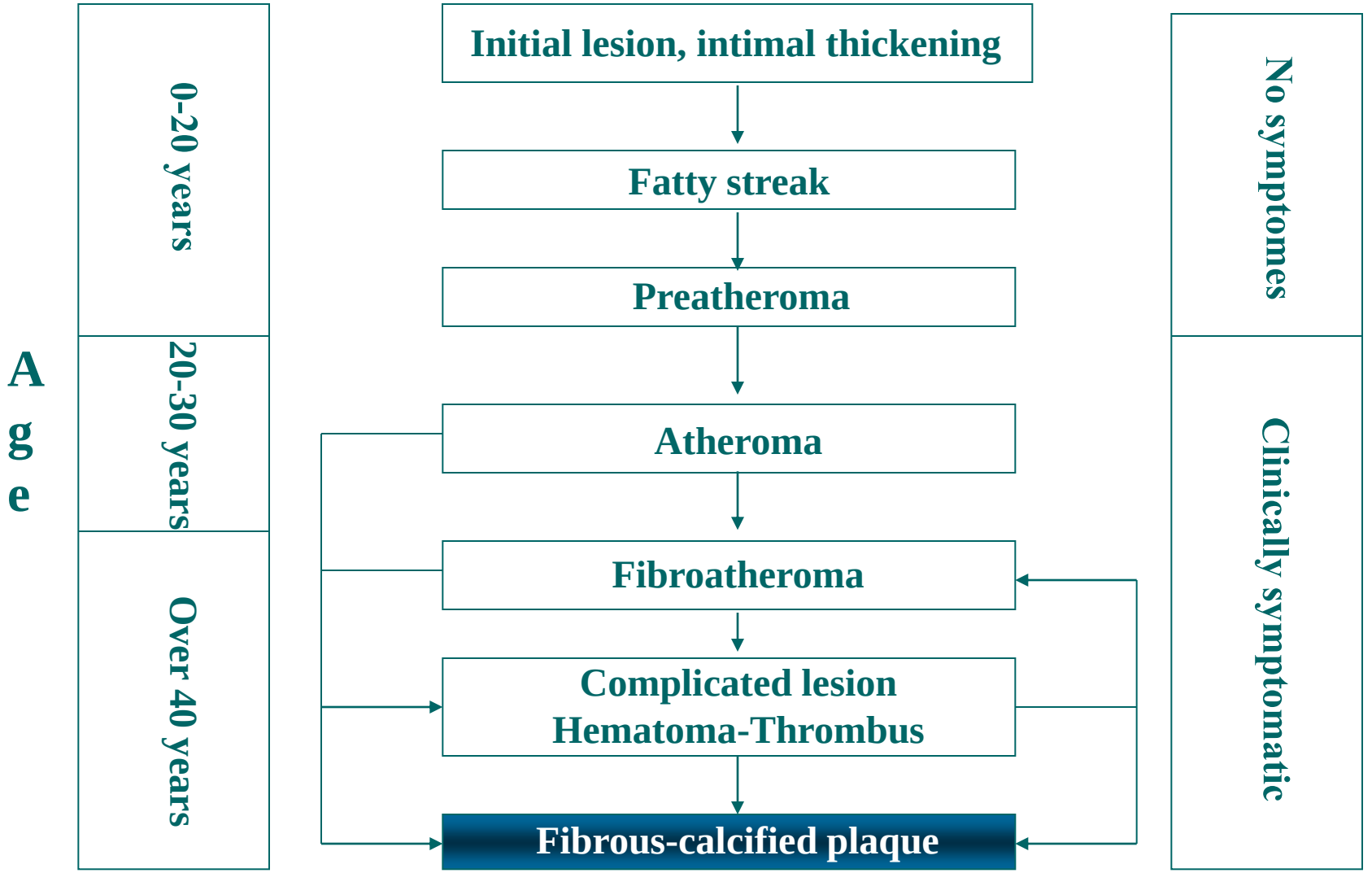

Morphologic forms of atherosclerosis

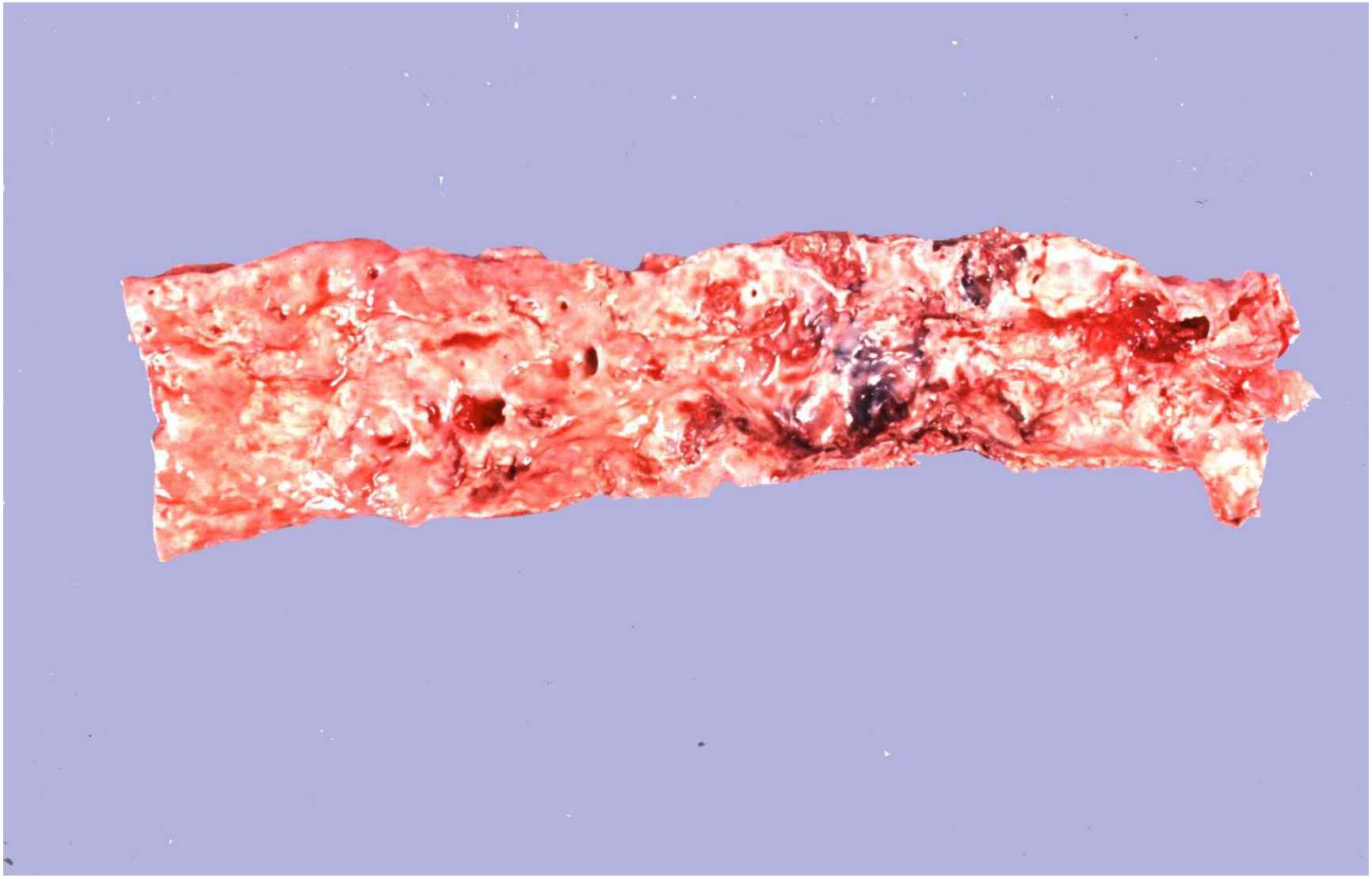

Severe atherosclerosis of the abdominal aorta: calcified-hemorrhagic plaques

Stages of atherosclerosis

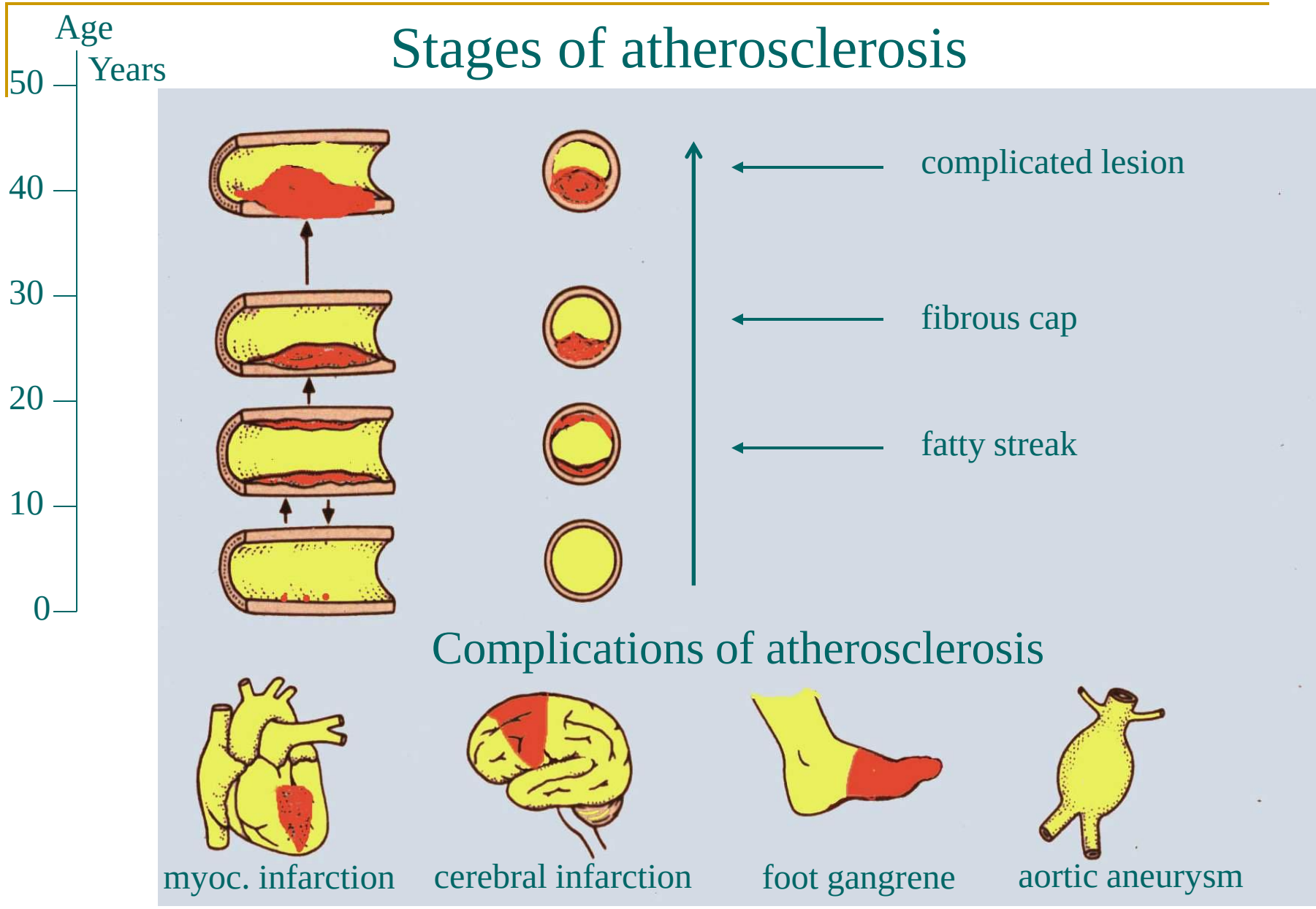

Reserve capacity of organs against atherosclerosis

- ischemic reserve capacity of tissues in developping slowly hypoxia
- anastomoses between supplying vessels
- formation of otherwise unimportant collateral vascular connections
- compensational vessel dilatation of Glagov
- shrinkage of fatty plaques (by e.g. serious loss of body weight)

Plaque formation: compensational vessel dilation

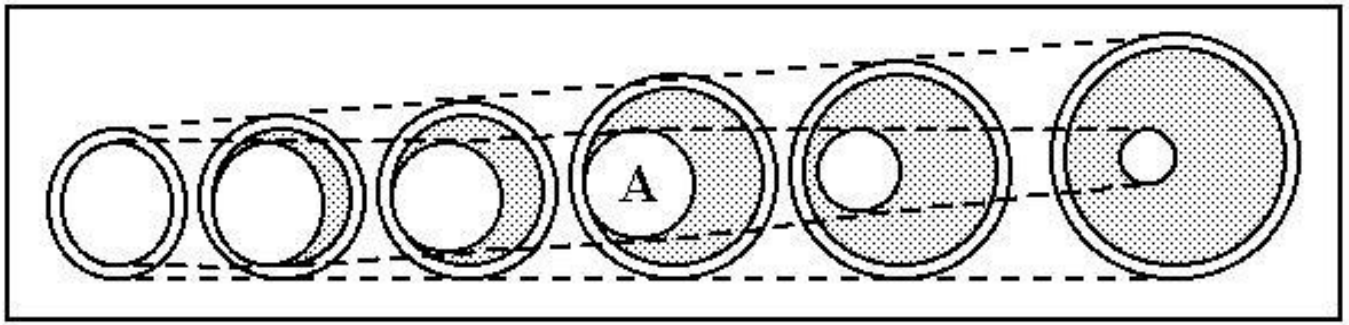

(Glagov et al., 1995)

Clinical appearances of atherosclerosis

- Noises of flow at the stenotic segments on auscultation (e.g. carotid art. stenosis)
- Weak pulse
- Ischemic pain
  - Angina pectoris
  - Abdominal angina (typically 10-15 minutes after a meal)
    - mesenteral thrombosis >> bowel infarction
  - *Claudicatio intermittens* (pain in the lower extremities on walking)
    - foot gangrene
  - Ischemic colitis
- Functional derangement of the affected organs (as by myocardial infarction)
  - Development of an ischemic heart disease, cerebral circulatory defeciencies
    - myocardial / cerebral infarction
  - Ischemic colitis
  - Renovascular atherosclerosis >> secondary hypertension
  - Leriche-syndrome (aorto-iliac stenosis with impotence)

Complications of atherosclerosis

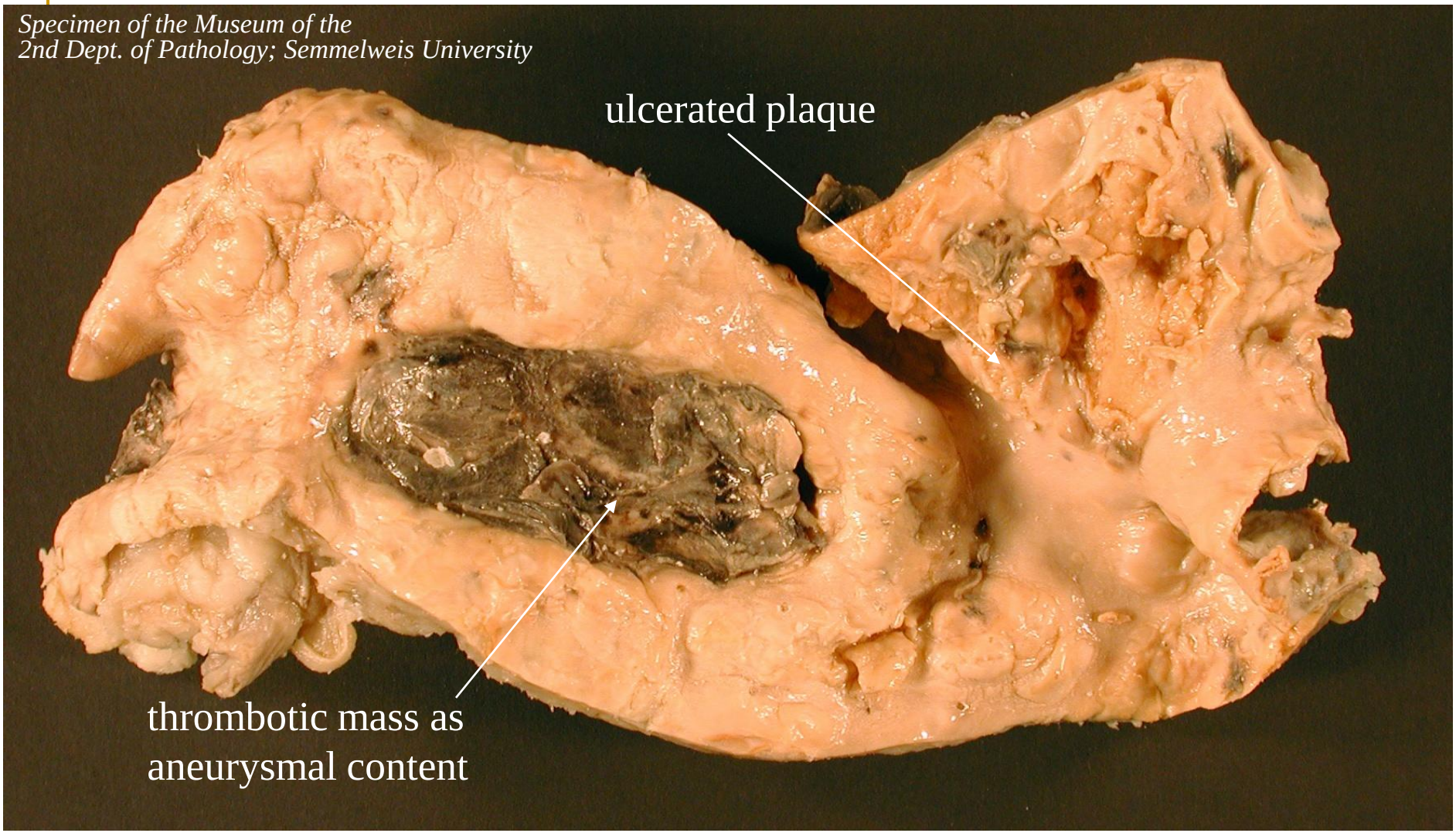

Severe atherosclerosis of the abdominal aorta

Complications of atherosclerosis

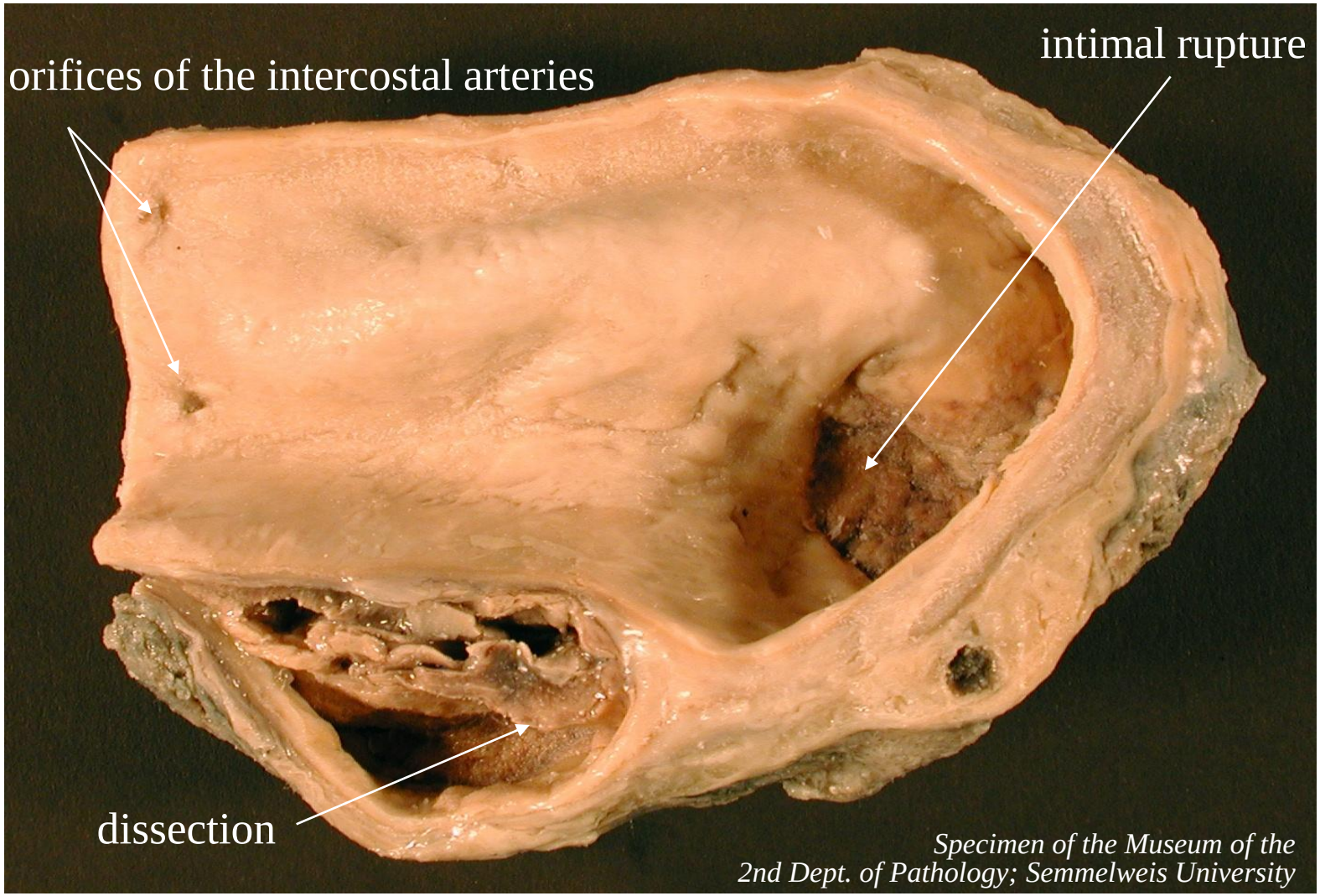

Intimal rupture of the aortic arch with
dissection in the descending aorta

Arteriolosclerosis and hypertension

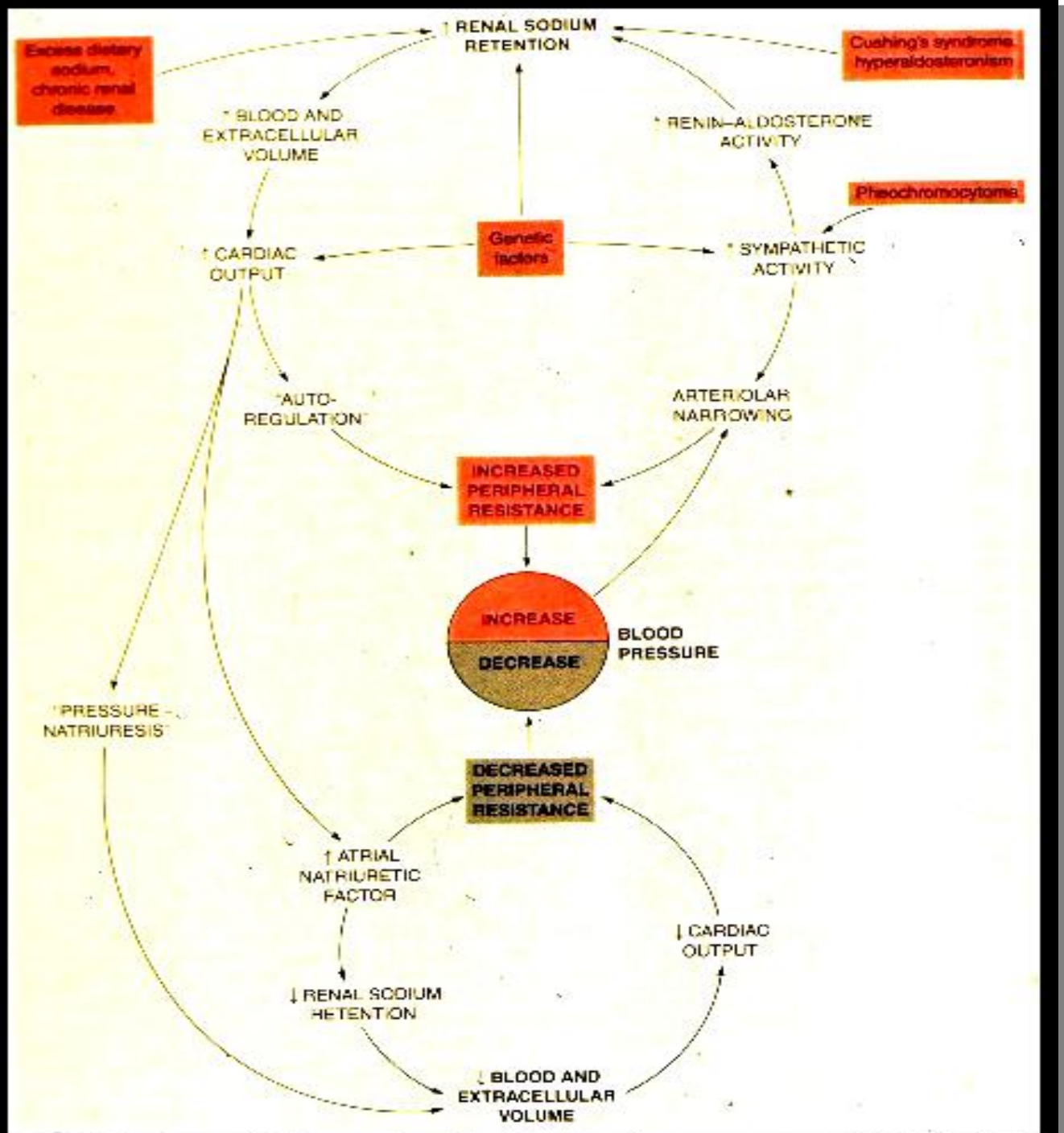

Regulation of the systemic blood pressure

Formes of hypertension

- Primary /essential/ - cause unknown (90-95% of the cases)
- Secondary (a definite disease in the background – 5%)
- Benign – development slow over the years (95%)
- Malignant – development accelerated, blood pressure elevation is drastic (5%)
- Definition by WHO: systemic blood pressure above 140/90 Hgmm over a longer period

Primary hypertension

- initially: a volume hypertension; later: a resistence hypertension

- Pathogenesis
  - preponderance of the sympathetic activity
  - activation of the renin-angiotensin-system
  - disbalance of vasopressants and vasodilators of the endothelium

Development of the essential hypertension

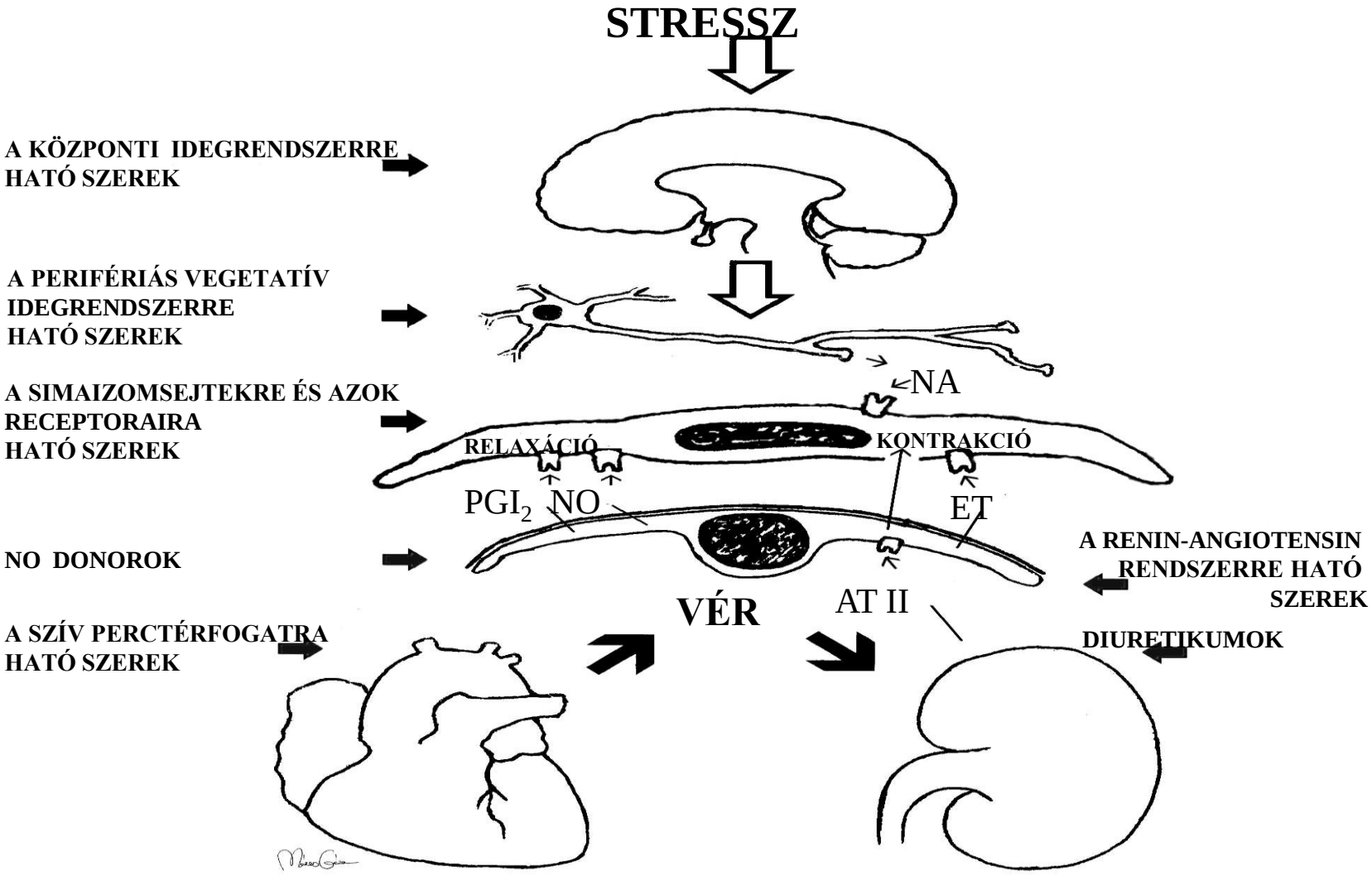

Secondary hypertension

- Renoparenchymal hypertension (glomerulonephritides, pyelonephritides >> decreased filtration >> activation of the renin-angiotensin-system)
- Renovascular hypertension
- Aortic coarctation (hypertension of body parts above the stenosis)
- Endocrine hypertension (pheochromocytoma, Cushing's syndrome, Conn's syndrome)

Nephrosclerosis

1
2
1
3
1μ

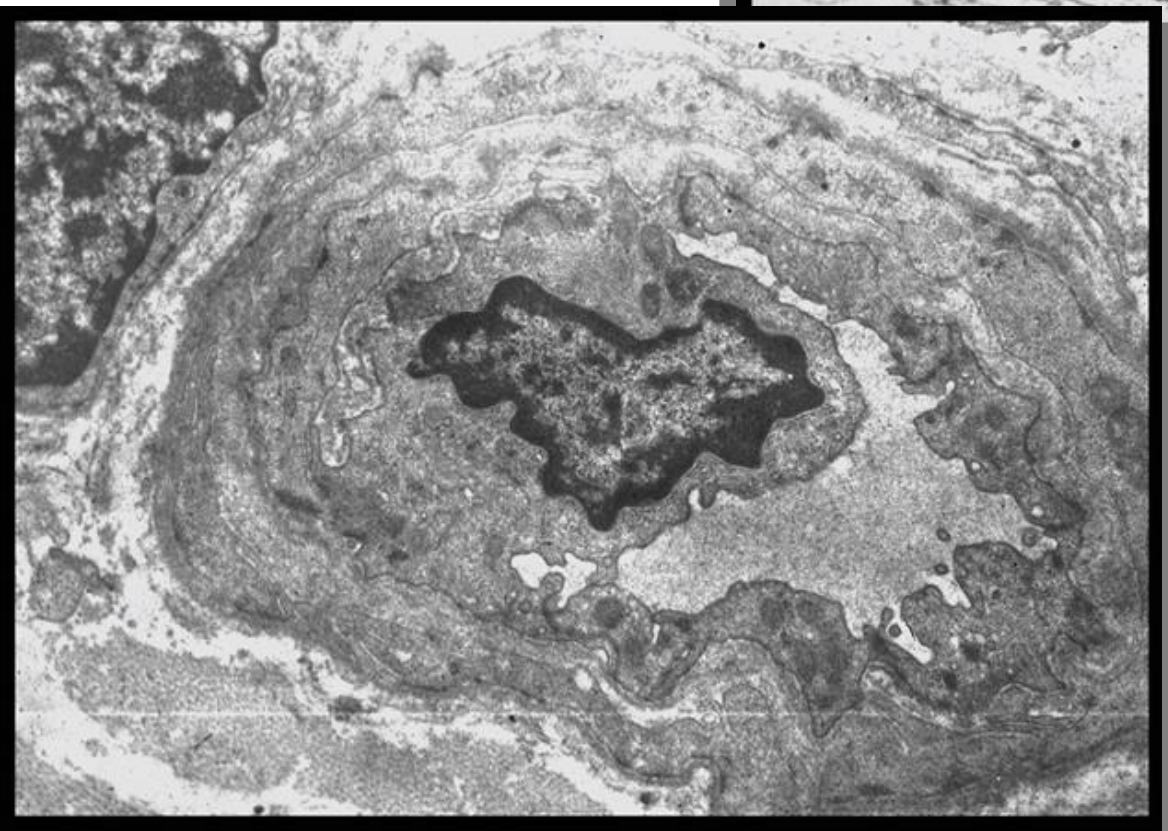

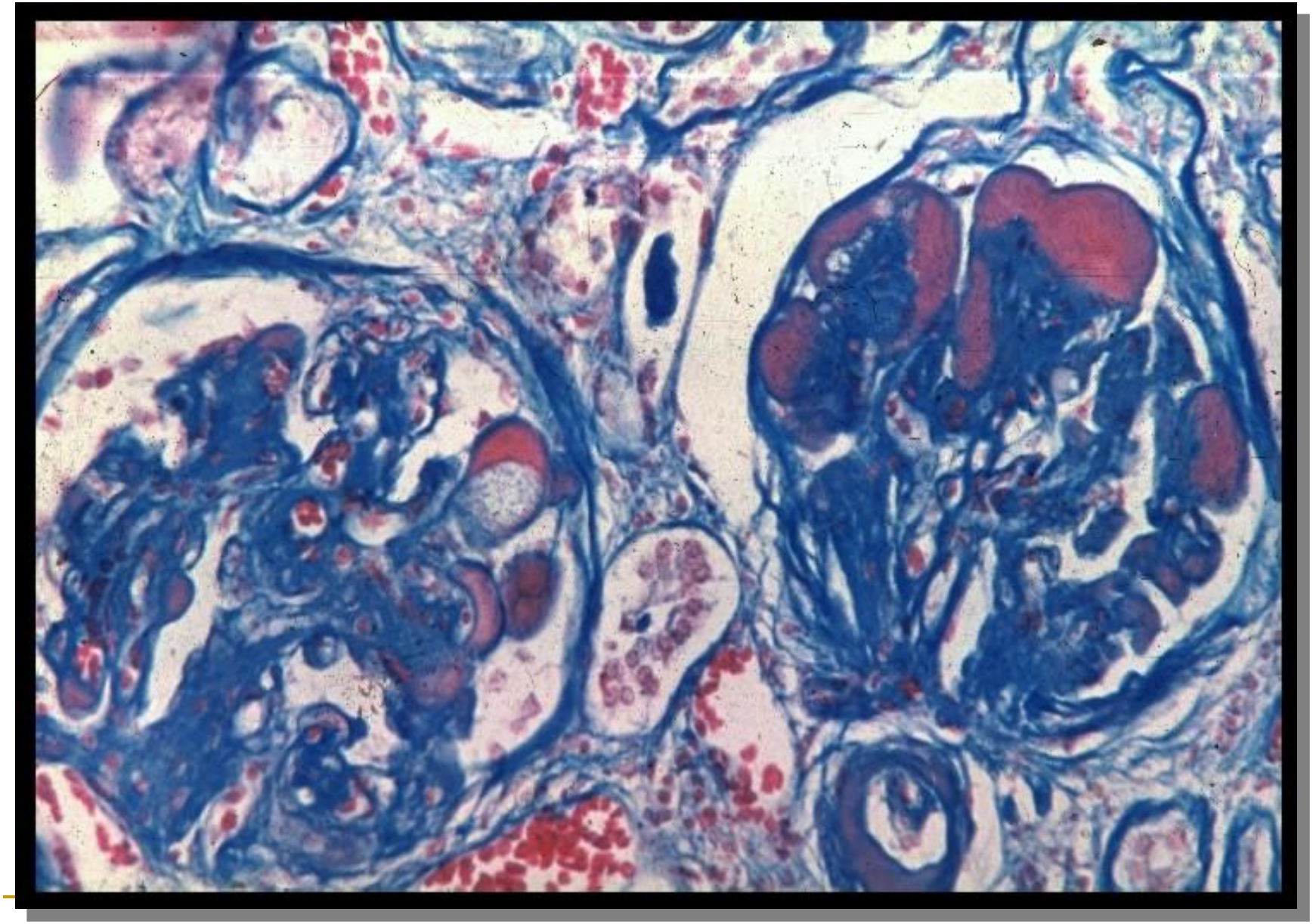

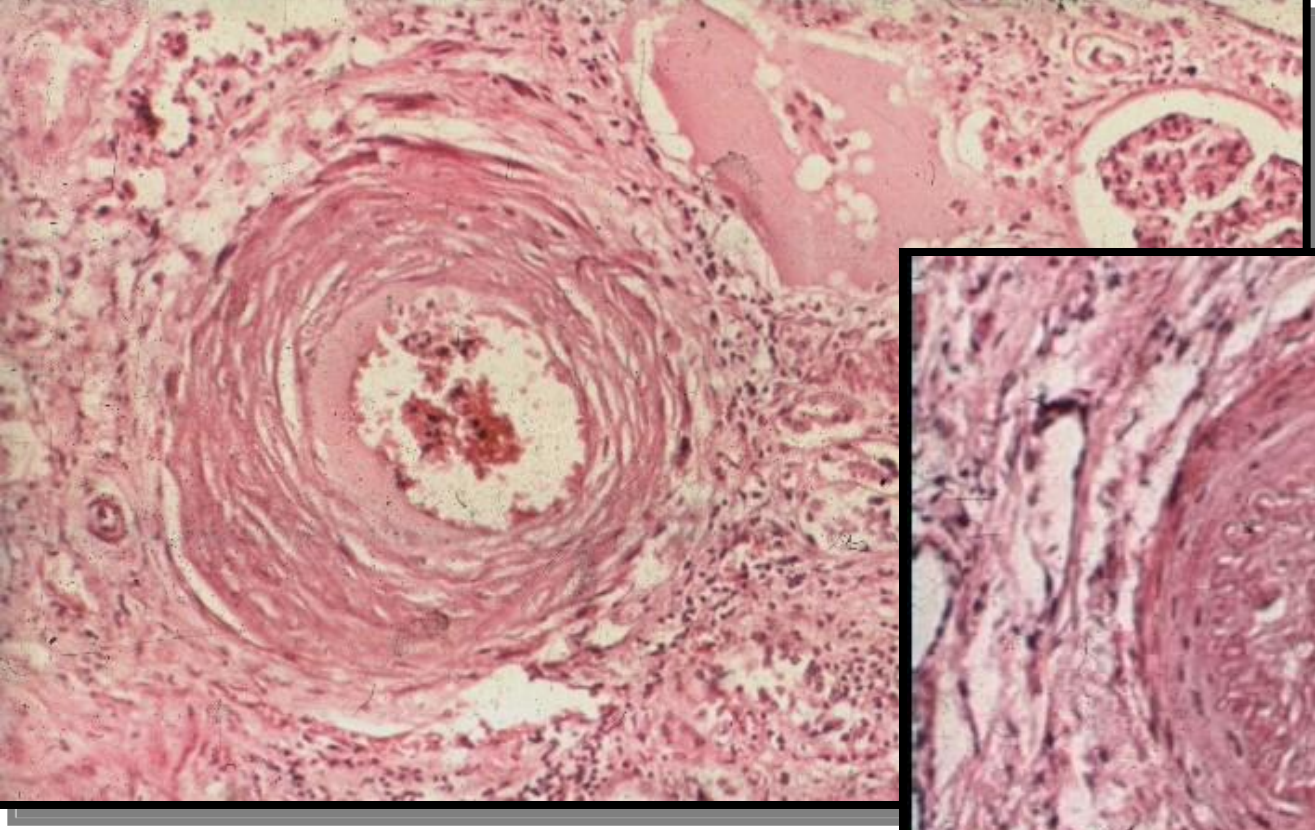

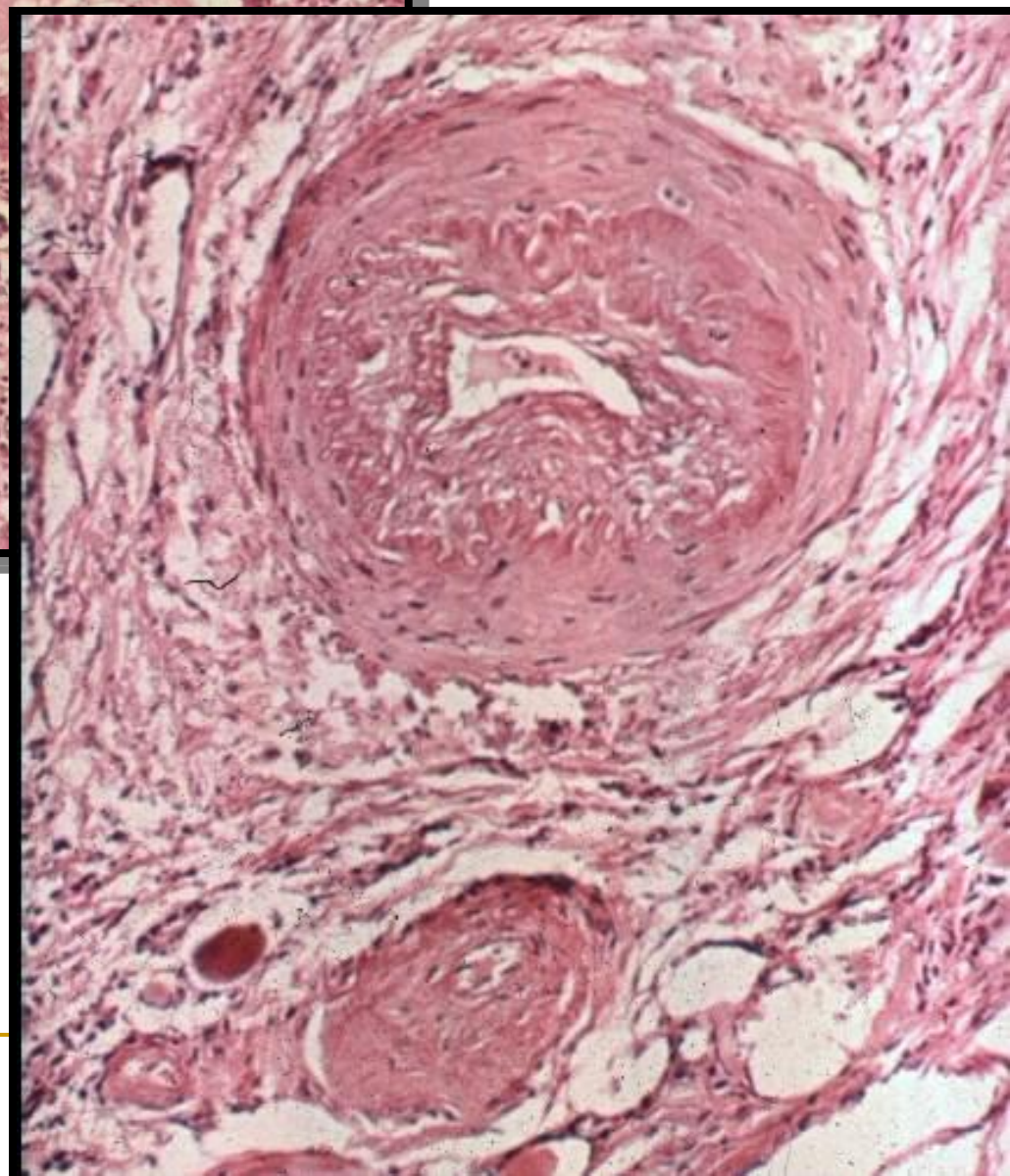

Lamellar elastosis

Mönckeberg's mediasclerosis

- Affected are middle sized arteries of the lower extremities
- Diffuse or focal calcification of the media
- Especially in patients over 50 years of age with diabetes mellitus
- Etiology and pathogenesis unknown
- Radiologically demonstrable

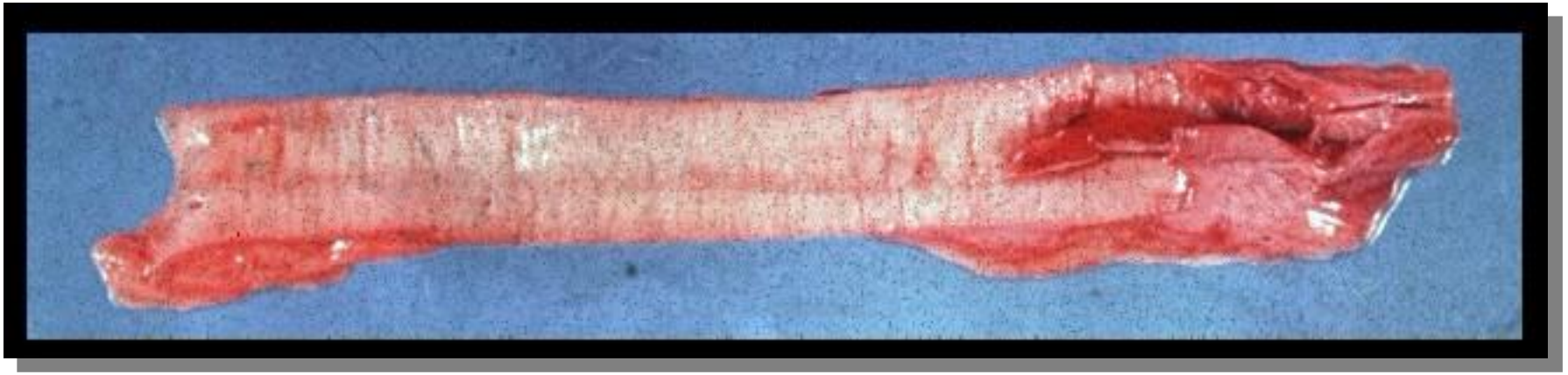

Mönckeberg's mediasclerosis

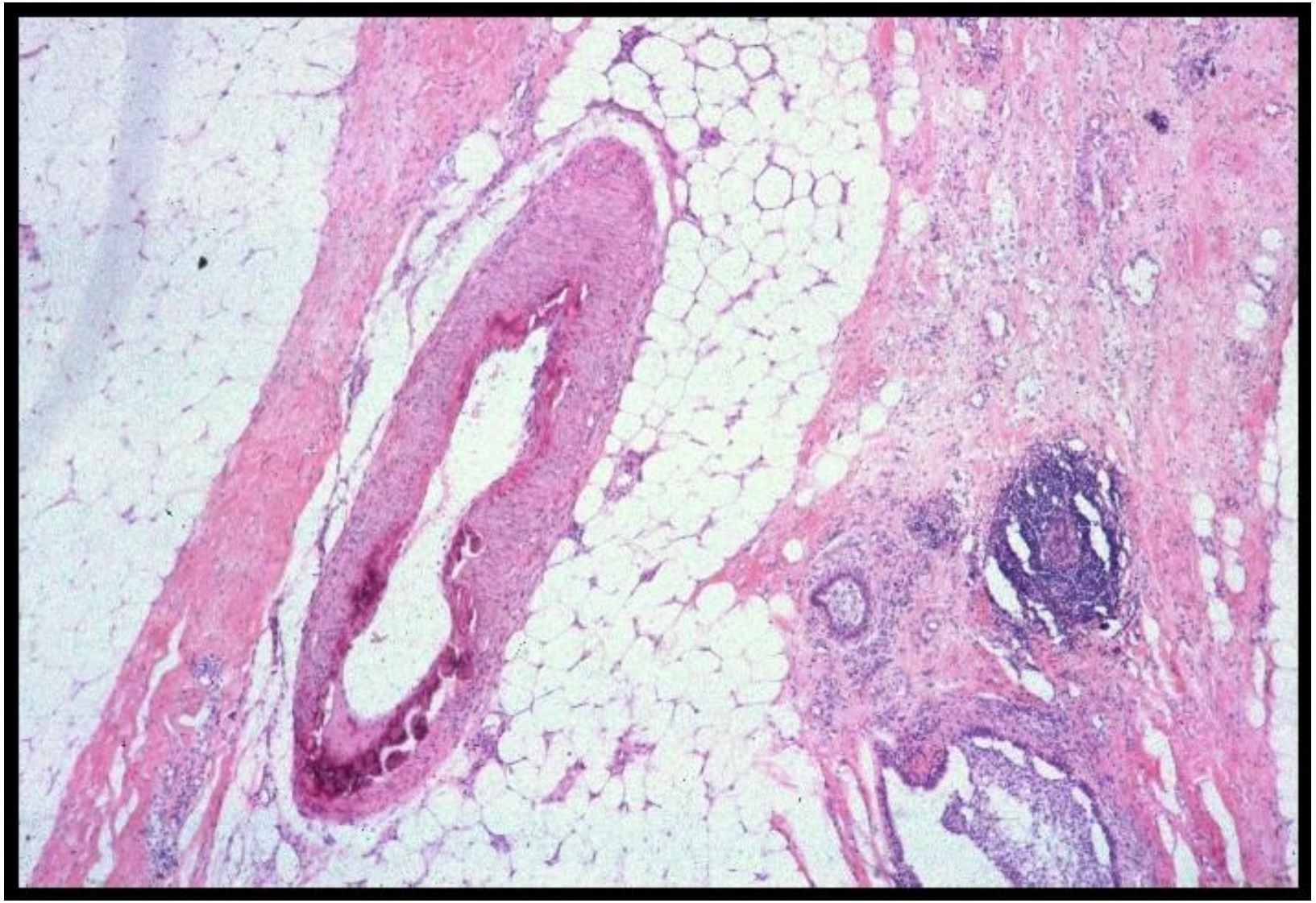

Aneurysms – Vessel dissections

Aneurysms

Definitions:

- *aneurysm*: a circumscribed lumen dilatation that exceeds generally 150% of the original lumen.
- *ectasy*: diffuse dilatation of a vessel.

causes:

- degeneration of mural structures by atherosclerosis (atheroma)
- infection of vascular wall structures (*aneurysma mycoticum/infectivum*)
- aneurysm formation in tertiary syphilis – ascending aorta
- constitutional weekness of the vascular wall (so-called berry-aneurysms)
- trauma

Aneurysms

- Localisations -

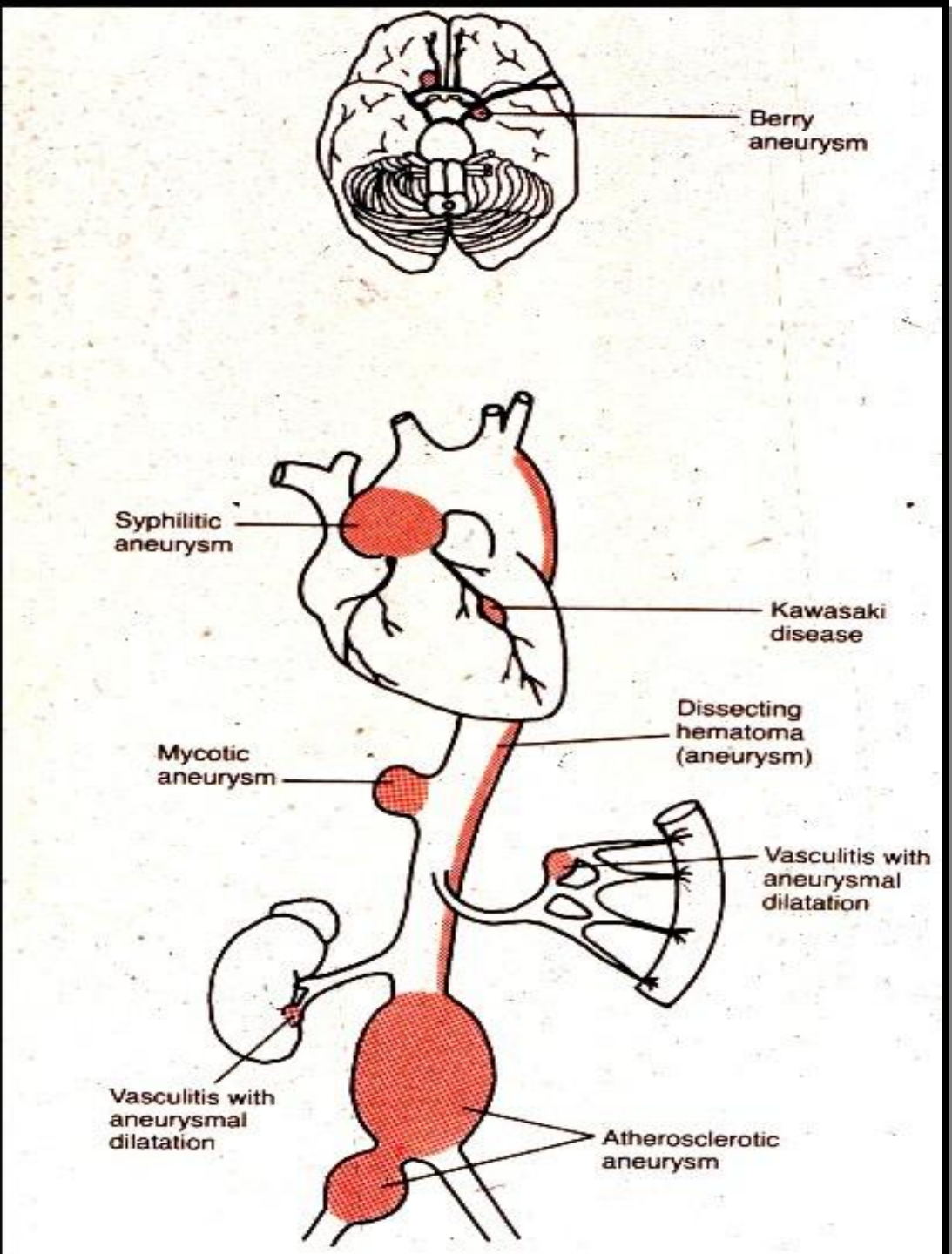

Aneurysms

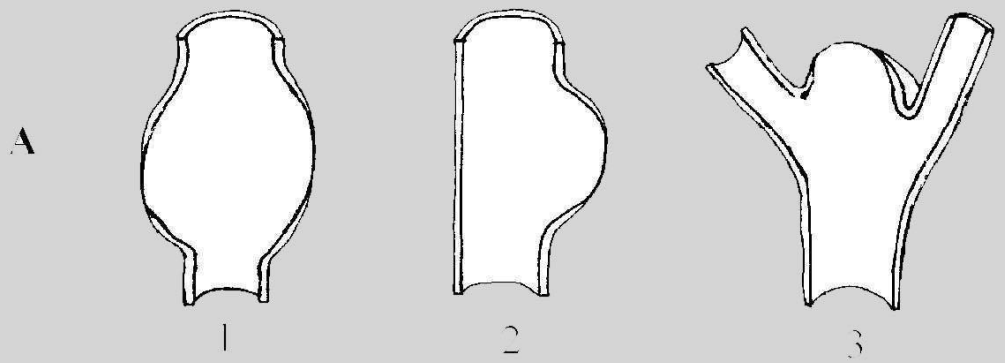

Real aneurysms



Aneurysm mimics

A1 = fusiform; A2 =saccular, A3 = berry-aneurysm,
B = pseudoaneurysm *(indeed: a perivascular hematoma)*,
C = dissecting aneurysm *(indeed: dissection of the vessel wall layers)*

Aneurysms

morphology

- aneurysma verum *(real aneurysm)* – vascular wall structures are detectable in the aneurysmal wall. Forms: (a) fusiform and (b) saccular (special form: berry-aneurysm of cranial arteries)
- aneurysma spurium *(fake aneurysm)* – e.g. posttraumatically, after catheterization. The perivascular hematoma looks from the outside as if it was a real aneurysm.

complications:

- rupture (the larger the aneurysm, the higher the risk)
- usuration (pressure-linked atrophy or erosion) of neighbouring body parts (e.g. vertebrae)
- thrombosis
- embolisation

⑩ *Museum of Pathology;*
2nd Dept. of Pathology; Semmelweis University

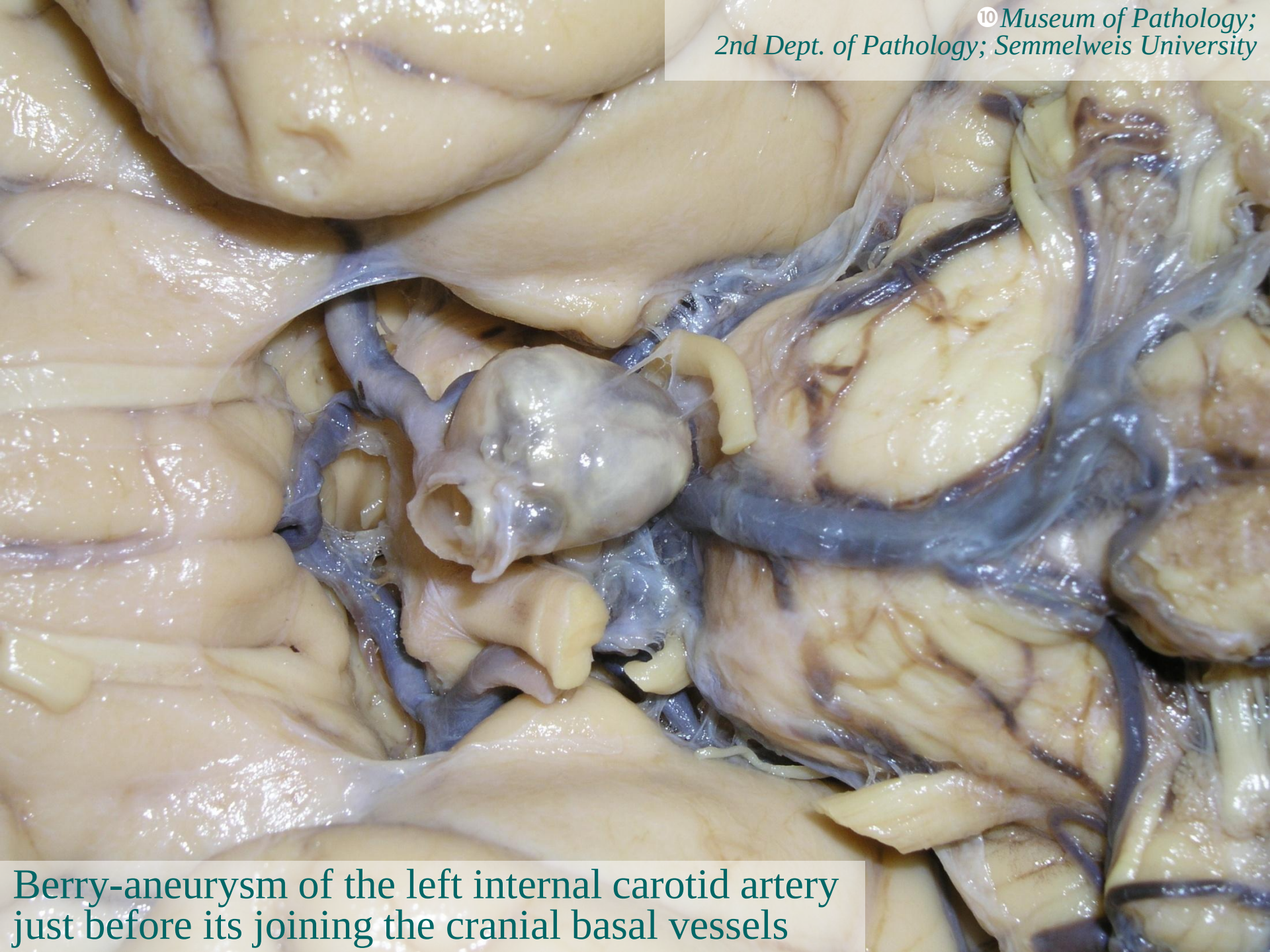

Berry-aneurysm of the left internal carotid artery just before its joining the cranial basal vessels

Saccular aneurysm of the aortic arch

Museum of Pathology;
2nd Dept. of Pathology; Semmelweis University

Museum of Pathology;
2nd Dept. of Pathology; Semmelweis University

Fusiform aneurysm of the descending thoracic aorta

Huge chronic aneurysm of the postero-apical two-third of the left ventricular wall

Museum of Pathology;
2nd Dept. of Pathology; Semmelweis University

Chronic aneurysm of the postero-lateral
left ventricular wall with thrombosis
Museum of Pathology;
2nd Dept. of Pathology; Semmelweis University

Dissection

Definition:

a longitudinally expanding detachment of vascular wall layers resulting in the formation of a secondary (false) lumen that runs parallel to the original one.

pathogenesis: wall layers' detachment is possible through

- constitutional weekness (Marfan's syndrome: weekness of the elastic fibers and deposition of mucoid substances: *cystic medial degeneration of Erdheim-Gsell*)
- atherosclerosis (atheromatous intimal plaques with intimal rupture and distally from here detachment of the degenerated wall layers under the pulsating blood stream. A second, more distal intimal tear may lead to reunification of the two blood ways, or else, an adventitial tear to perivascular hemorrhage.)
- hypertension

Dissection

- complications:
  - infarction of the supplied organ
  - rupture with hematoma of the neighbouring regions (retroperitoneal hematoma; hemascos; hematopleura; hemopericardium) >> exsanguination

- clinical apperance of the aortic dissection:
  - typical age: 40-60th years of life. With Marfan's syndrome yet in youth possible.
  - on palpation: a pulsating abdominal mass
  - complaint: sudden, anihilating, knife-stabbing-like thoracal/abdominal pain >> sometimes followed by an acute abdomen syndrome
  - the more dangerous type of the aortal dissections is the proximal form (Typ A, or DeBakey I. and II.)
  - somewhat less dangerous is the distal type (Typ B./DeBakey III.)
  - early diagnosis may offer the chance of a successful operative intervention (vascular prosthesis)

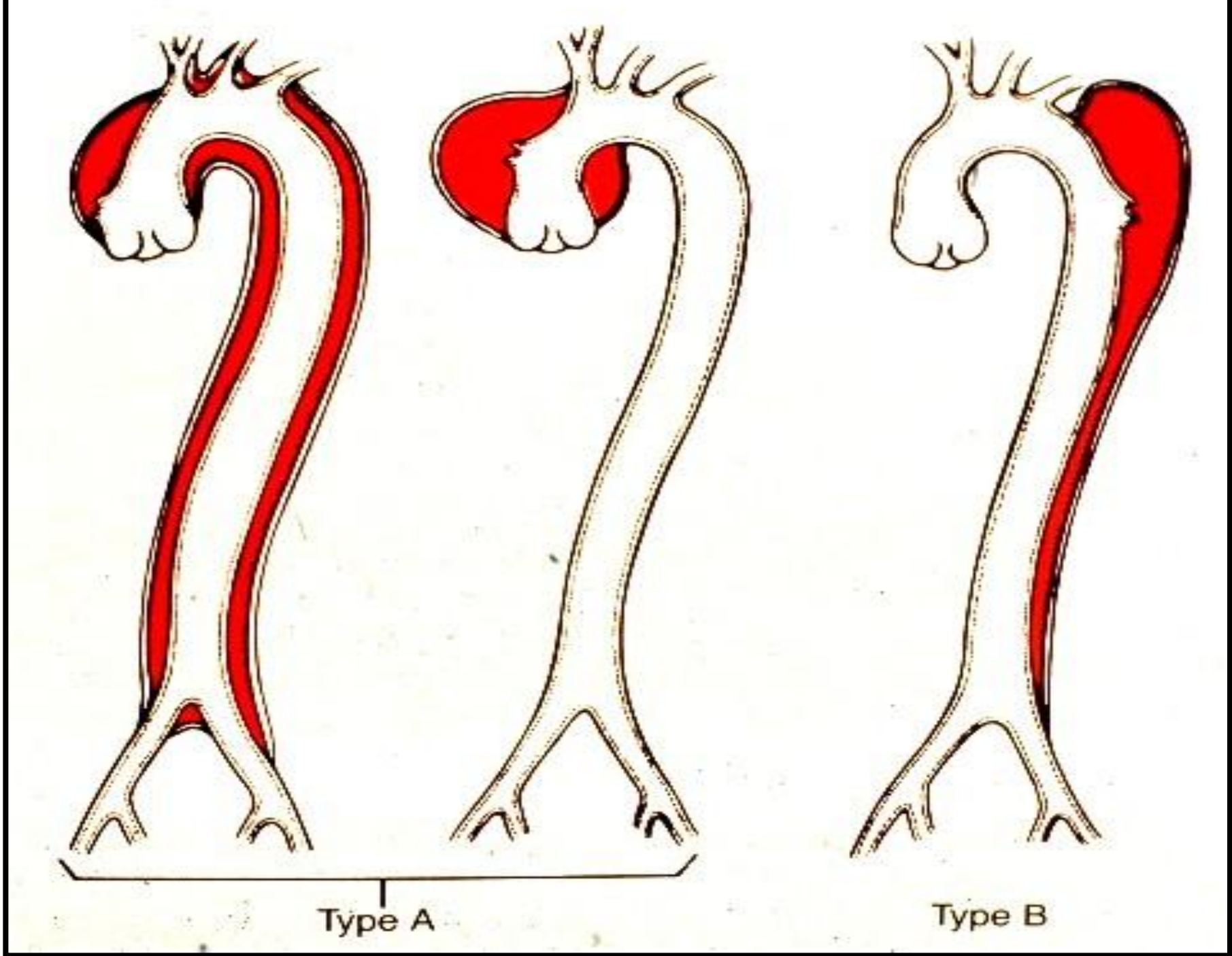
Type A
Type B

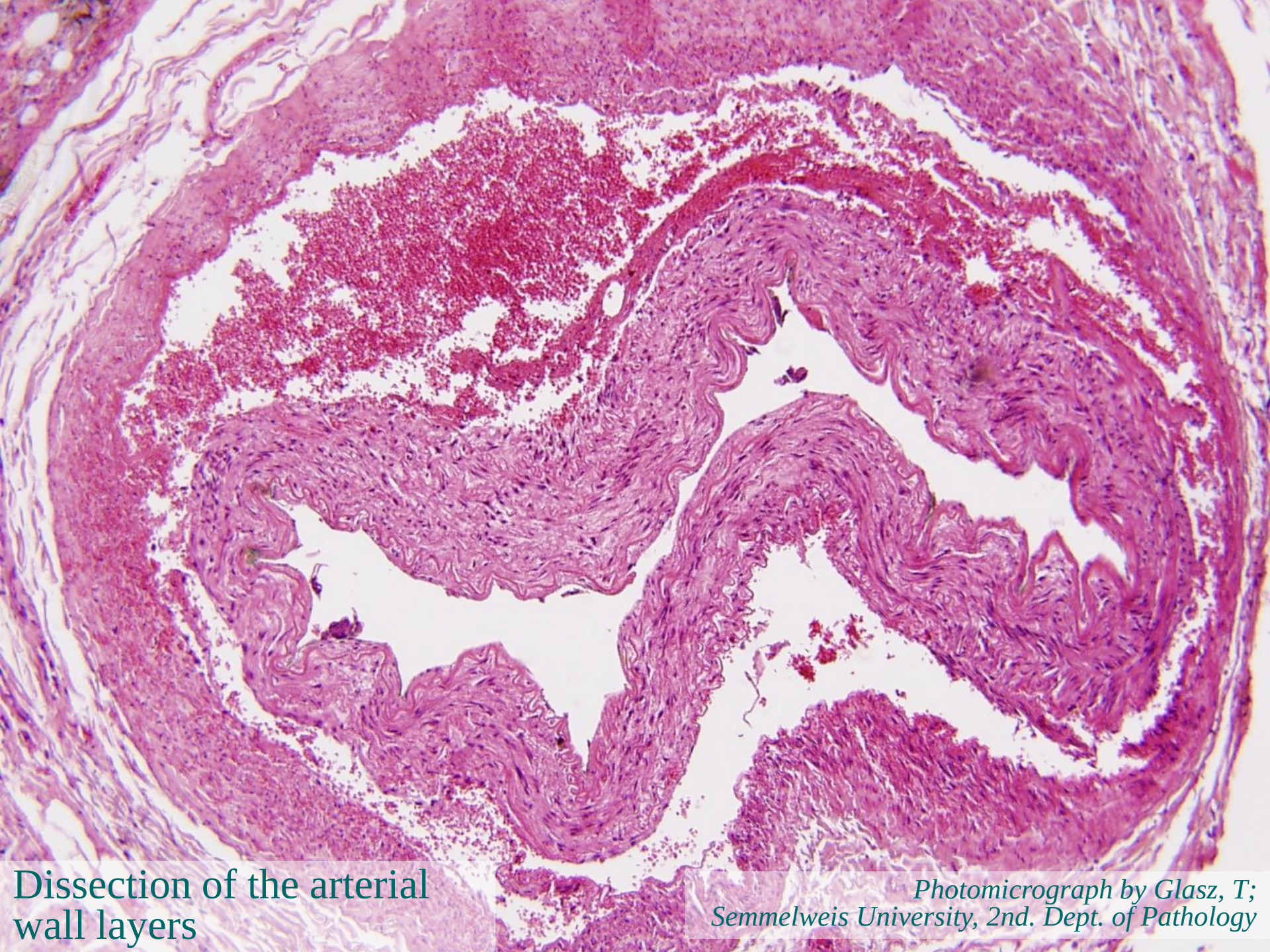

Dissection of the arterial wall layers

Photomicrograph by Glasz, T; Semmelweis University, 2nd. Dept. of Pathology

Vasculitides

Vasculitides of the large vessels

Giant cell arteritis (temporal arteritis)

- over the 50th year of life; generally in females; affected are the aorta, its large branches, the extracranial branches of the carotid artery (like the temporal artery)
- cause unknown (immunpathogenesis against wall structures is possible)
- morphology: a segmental granulomatous panarteritis with giant cells and elastic fiber fragmentation; later mural fibrosis
- clinically painful thickening of the vessels; pain in the facial and mandibular region; fever; weekness; muscular pain in the neck and the shoulders; on involvement of the ophtalmic artery visual complaints or even blindness may occur

Vasculitides of the large vessels

Takayashu-Arteritis

- in females under 40 years;
- affected are the aorta and its elastic large branches: the classical topography is the aortic arch
- morphology: histologically an initial sign is the inflammation of the vasa vasorum; followed by a non-segmental, granulomatous panarteritis with giant cells upon long segments of the affected vessel; later mural fibrosis; wall thickening at the branchings-off of the side vessels of the aortic arch causing vascular stenosis and weekness of the pulse in the arm (*pulseless disease*)
- clinically in the early stage general chronic inflammatory symptomes (fever, weekness, weight loss); in later stage symptomes of the vessel stenoses (ophtalmologic, neurologic alterations)

Vasculitides of the middle sized vessels

Polyarteritis nodosa

- affected are the visceral main vessels and their primary side branches (the mesenteric, lienal, renal, hepatic, coronary, etc. arteries)
- all organs may be affected (other than the lungs)
- alterations of varying ages appear synchronously in several arteries: a segmental, nodular, necrotizing panarteritis
- initially fibrinoid necrosis of wall structures, later fibrosis; the necrotic damaged segments dilate aneurysmatically: macroscopically a pearl chain like aspect; later vascular thrombosis
- peak of prevalence in young adults
- clinically fever, abdominal and muscular pains (often with melena); later occlusive symptomes: infarctions of various organs (a very ‘colourful’ clinical picture) >> on affection of the kidneys: hypertension
- immunsuppressive therapy (corticosteroids) gives remission up to 90% of the cases

Vasculitides of the middle sized vessels

Kawasaki-Arteritis

- develops in children younger than 5 years of age in the asiatic continent
- affected are the visceral, most frequently the coronary arteries: a segmental, necrotizing panarteritis >> myocardial infarction
- exact cause unknown (suspected is an immunpathogenesis with malfunction of T-cells and macrophages)
- in case cutaneous purpures, mucosal inflammations, enlargement of lymphatic nodules also occur: muco-cutaneous lymphnode syndrome

Morbus Buerger *(thrombangitis obliterans)*

- affects severely smoking males under 40 years in the small to middle sized muscular arteries of the (primarily lower) extremities
- smoking plays a probable role: hypersensitivity against tobacco
- a segmental panarteritis with thrombosis; later intimal fibrosis, organization of thrombi, recanalisation
- pain in resting position refers to affection of the neighbouring nerves
- smoking abstinence brings spectacular amelioration

Vasculitides of the small vessels

Schönlein-Henoch's Purpure

- IgA-deposition in small vessels
- begins with infection of the upper respiratory tract around the 5th year of life
- clinically: fever, joint pains, cutaneous purpures, melena, hematuria, IgA-nephropathy
- generally a spontanous healing follows

Wegener's Granulomatosis

- necrotizing, granulomatous inflammation of the upper & lower respiratory organs
- furthermore, all over the body, focal, necrotizing vasculitides of small vessels + glomerulonephritis possible
- begins around the 40th year of age; without therapy leads to death within a year
- clinically: two-sided, necrotizing pneumonitis; chronic sinusitis; nasopharyngeal ulcerations; renal damage
- immunsuppressors may successfully be applied

Churg-Strauß Syndrom

- eosinophylic, granulomatous, respiratory inflammation with necrotizing small vessel vasculitis + asthma bronchiale

Pathology of the veins

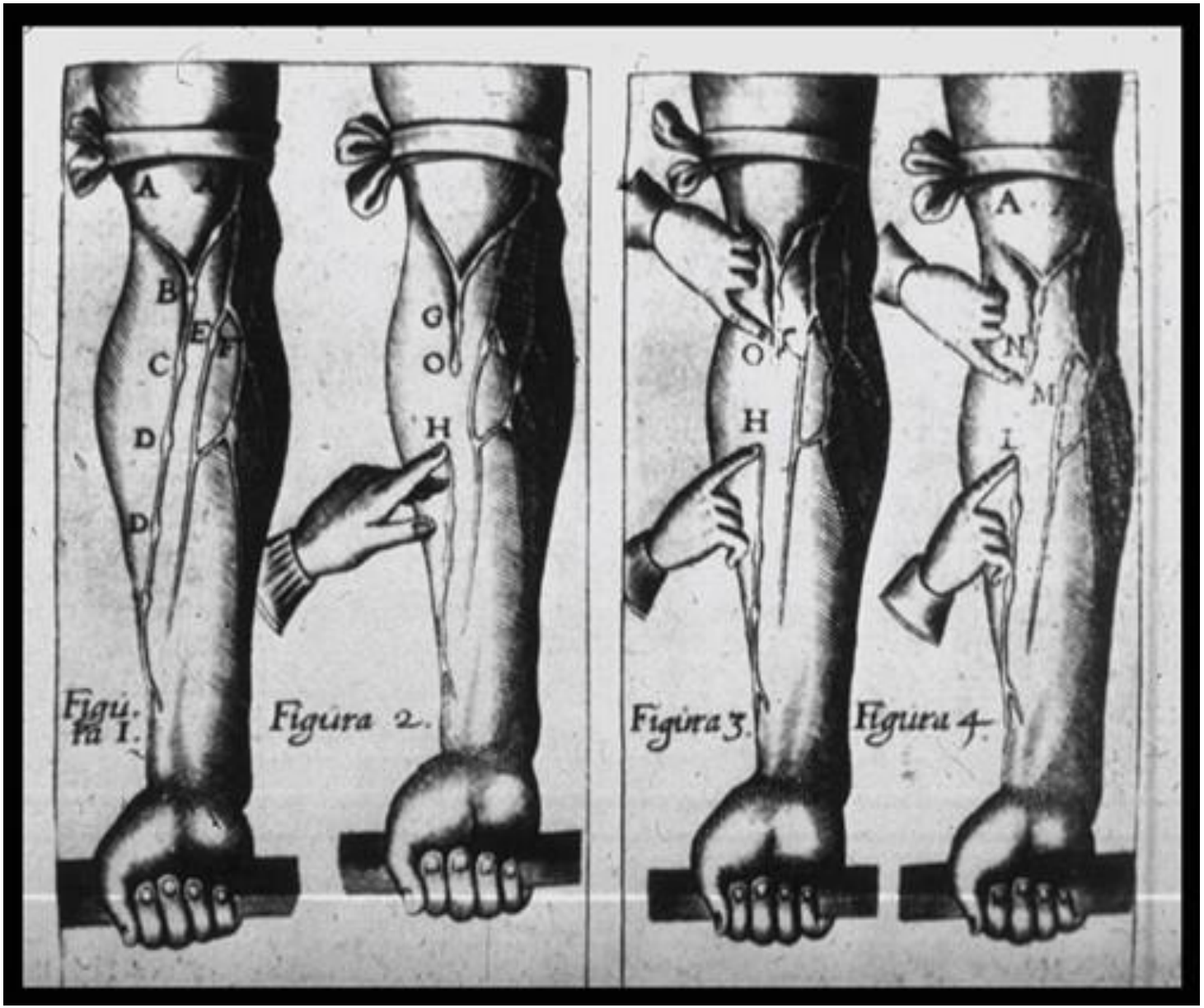

Demonstration of the venous valves and their function
(XVII. century by Harvey after his master Fabrizio d'Aquapendente)

Varicosity

dilation of the veins in the lower extremities

insufficiency of venous valves >> chronic venous insufficiency

primary varices (hormonal, working, etc. conditions)

secondary varices (e.g. after thrombosis of the lower limb veins)

phlebosclerosis (by recurring phlebitides, drog abusers)

Thrombosis of the deep veins

lower limb veins, periprostatic-periuteral plexus

clinically: swelling, pains

collaps of the nearby capillaries: paleness of the limb (*phlegmasia alba dolens*)

affection of the collateral veins: decrease of venous drainage of the whole limb (*phlegmasia coerulea dolens*)

consequencies: propagation; rethrombosis; thrombembolism; organisation of thrombi, postthrombotic syndrome, *ulcus cruris venosum*

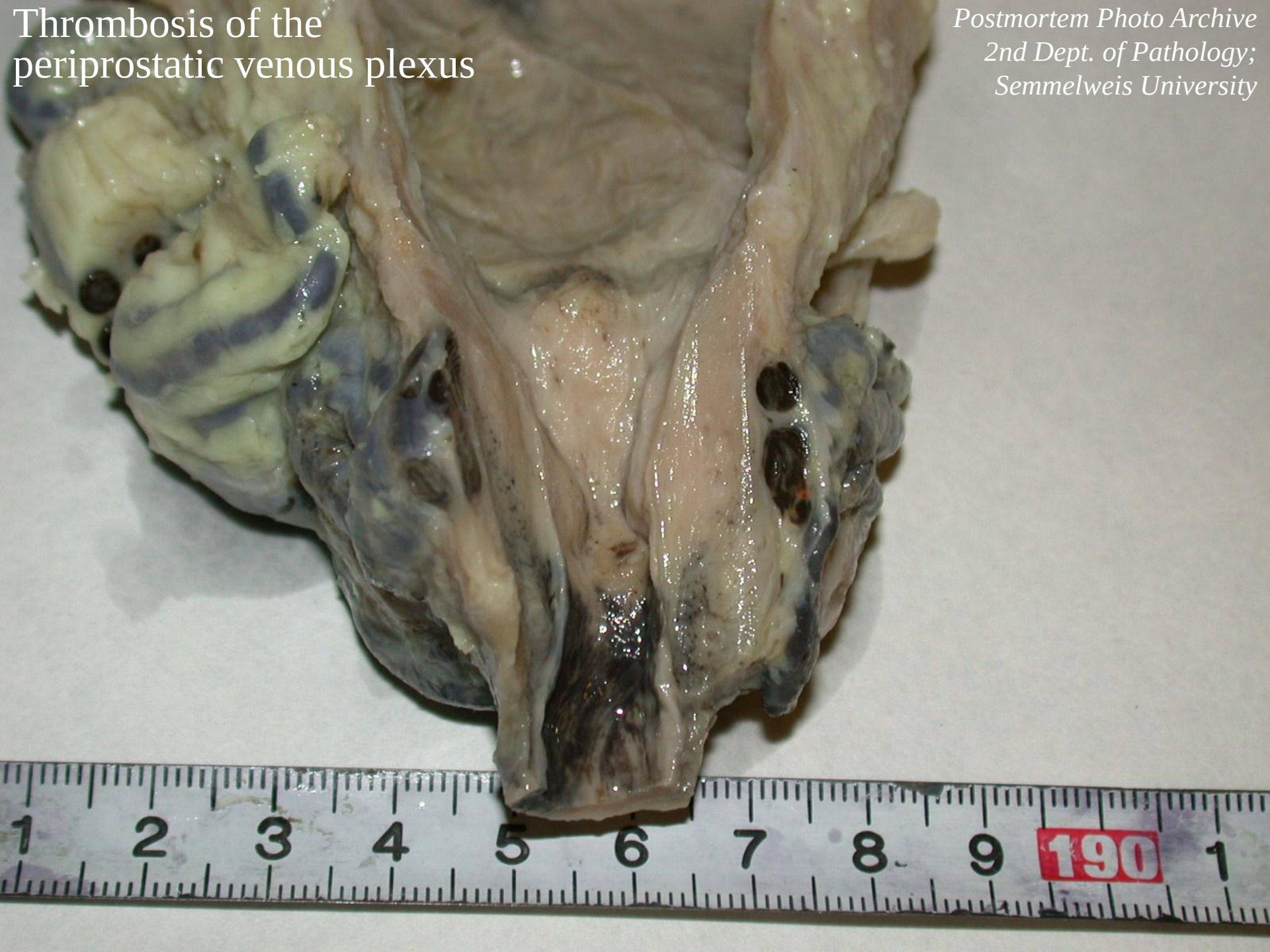
Thrombosis of the
periprostatic venous plexus
Postmortem Photo Archive
2nd Dept. of Pathology;
Semmelweis University
1
2
3
4
5
6
7
8
9
190
1

Postmortem Photo Archive of the 2nd Dept. of Pathology;
Semmelweis University

Thrombosis of the
periprostatic venous plexus

Museum of Pathology;
2nd Dept. of Pathology; Semmelweis University

Pylethrombosis: blood clotting in the portal vein

Paradox embolism: an embolus just in the phase of transition from the right to the left circulation through the opening of a patent foramen ovale

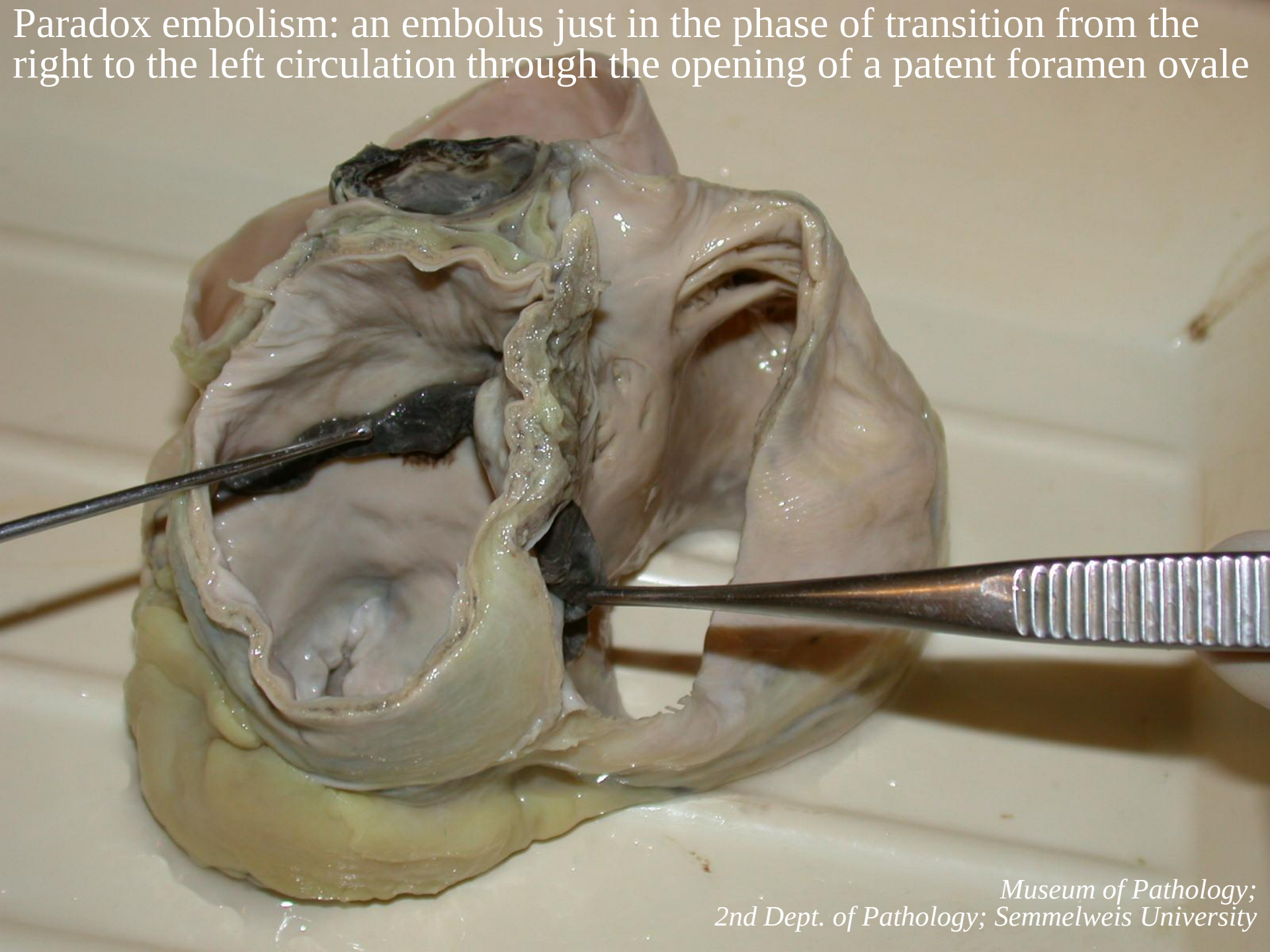

Museum of Pathology;
2nd Dept. of Pathology; Semmelweis University

Esophageal varices.
Note rough inner surface over meandering submucosal veins with a mucosal rupture

Museum of Pathology;
2nd Dept. of Pathology; Semmelweis University

Esophageal varices on cut surface

Museum of Pathology;
2nd Dept. of Pathology; Semmelweis University