



*250 years of EXCELLENCE
in medical education,
research & innovation
and healthcare*

Diseases of endocardium, myocardium, pericardium

Attila Fintha

1st Department of Pathology and Experimental
Cancer Research

09.12.2019

Topics

Endocardial and valvular diseases

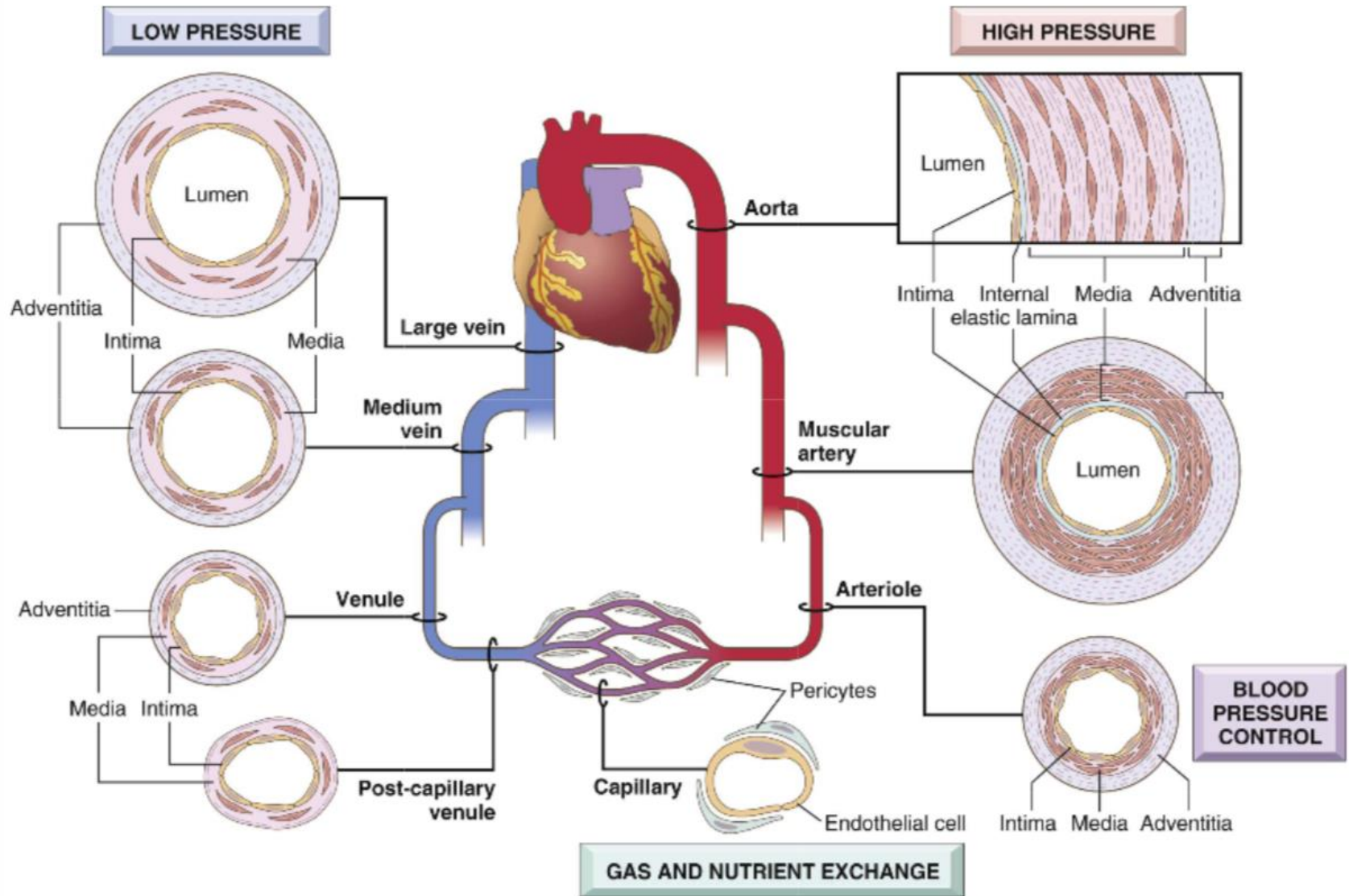
Cardiomyopathies

Myocarditis

Pericarditis

Cardiac tumors





Robbins and Cotran Pathologic Basis of Disease



Endocardial and valvular diseases

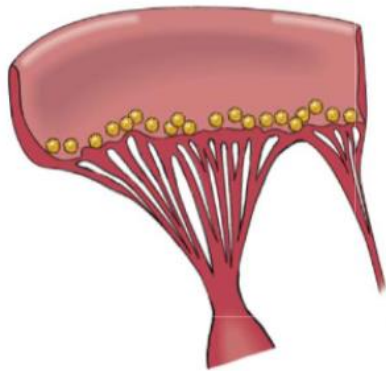


Valvular function

Stenosis

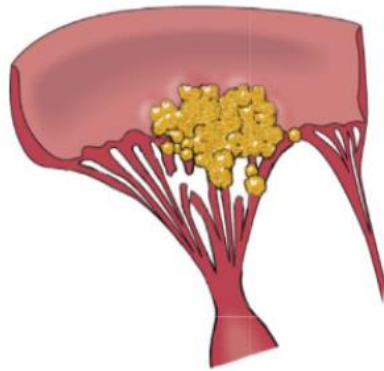
Insufficiency





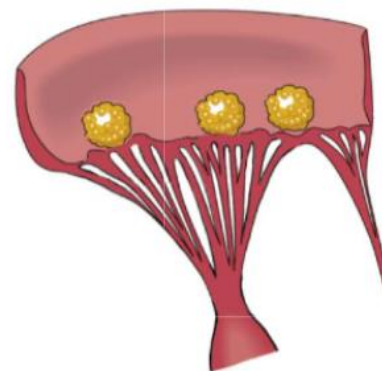
RHD

„Verrucosus”



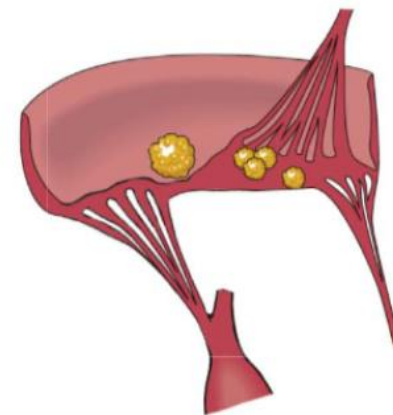
IE

Vegetation



NBTE

„Marantic”

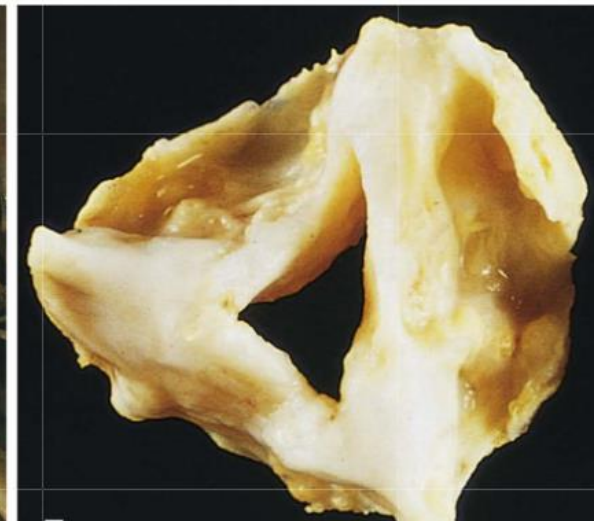
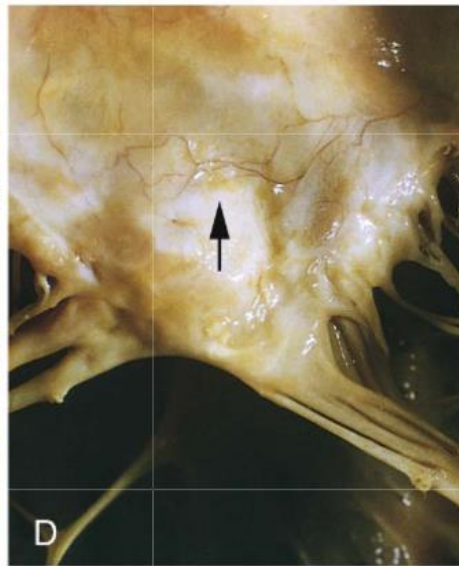
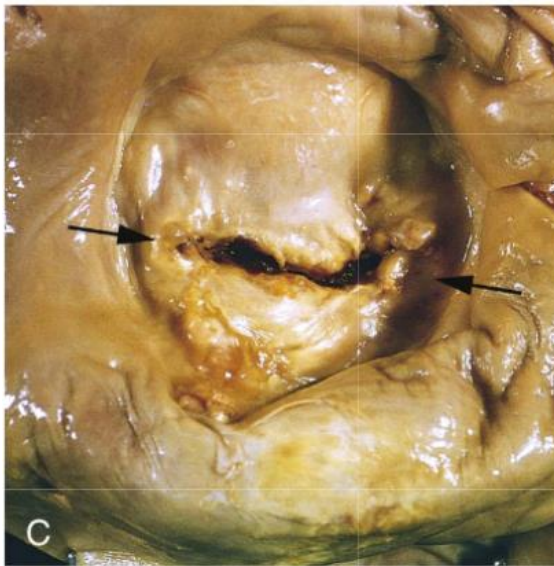
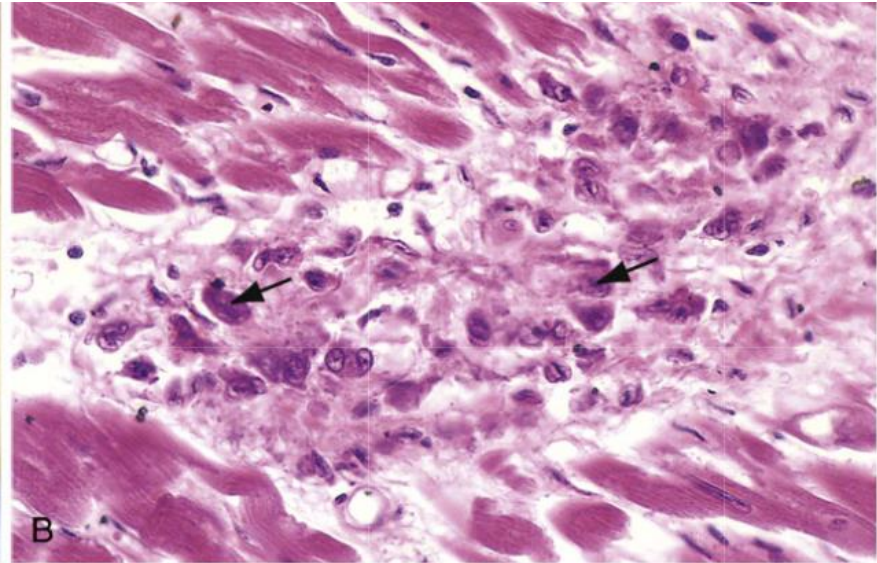
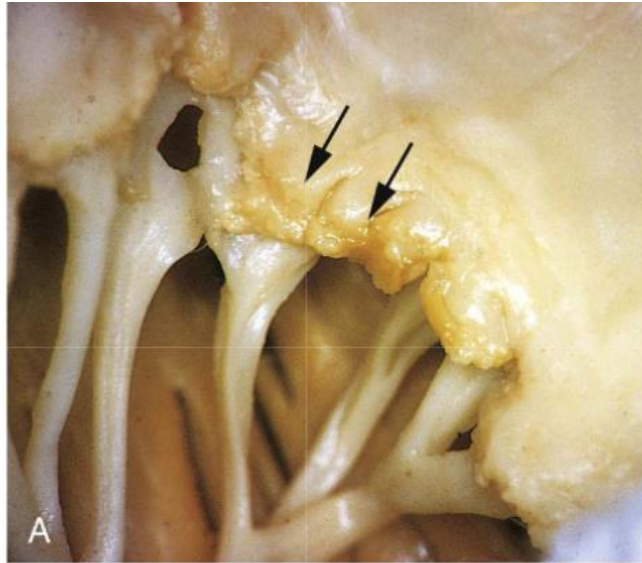


LSE

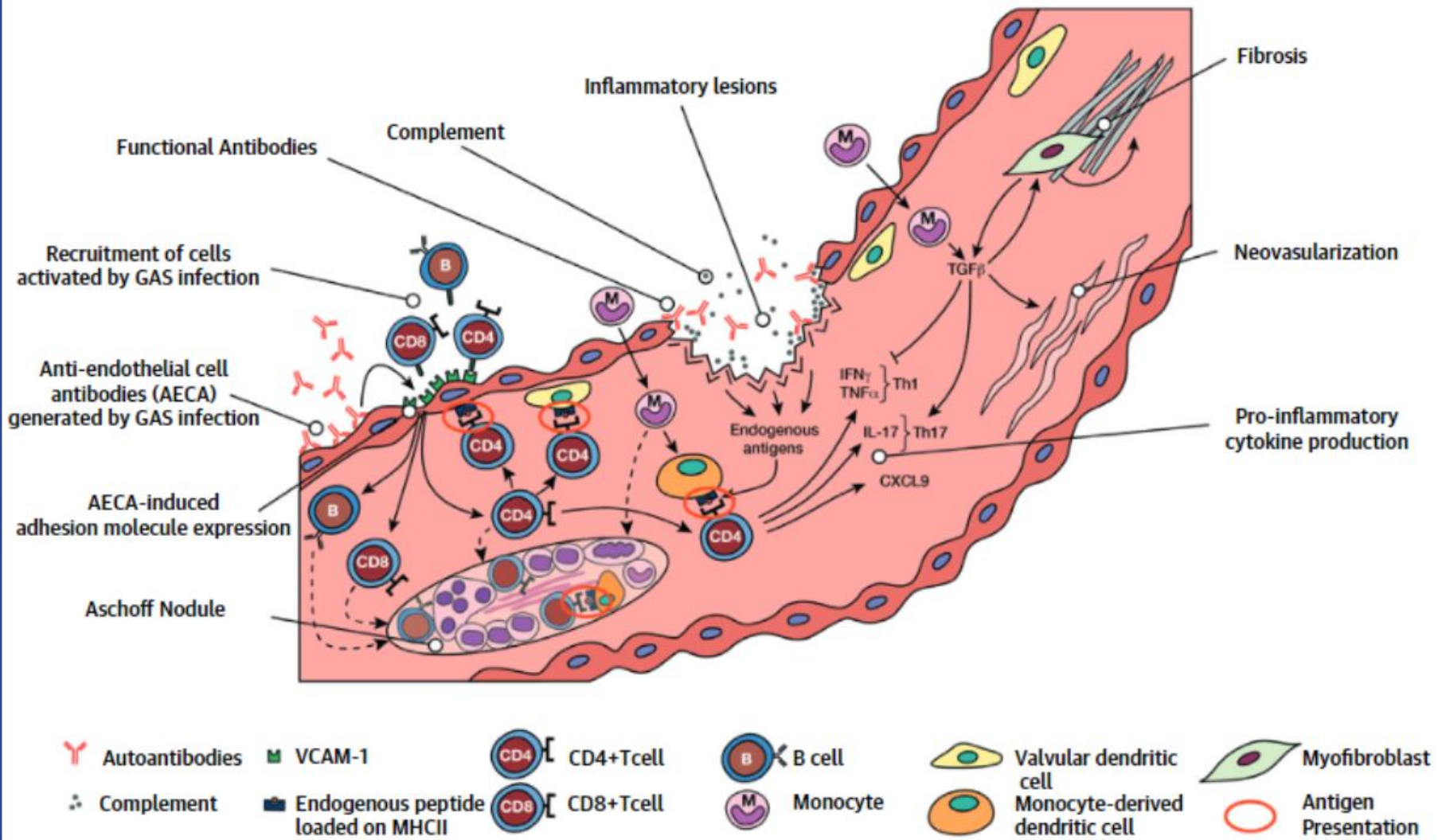
Robbins and Cotran Pathologic Basis of Disease



Rheumatic fever



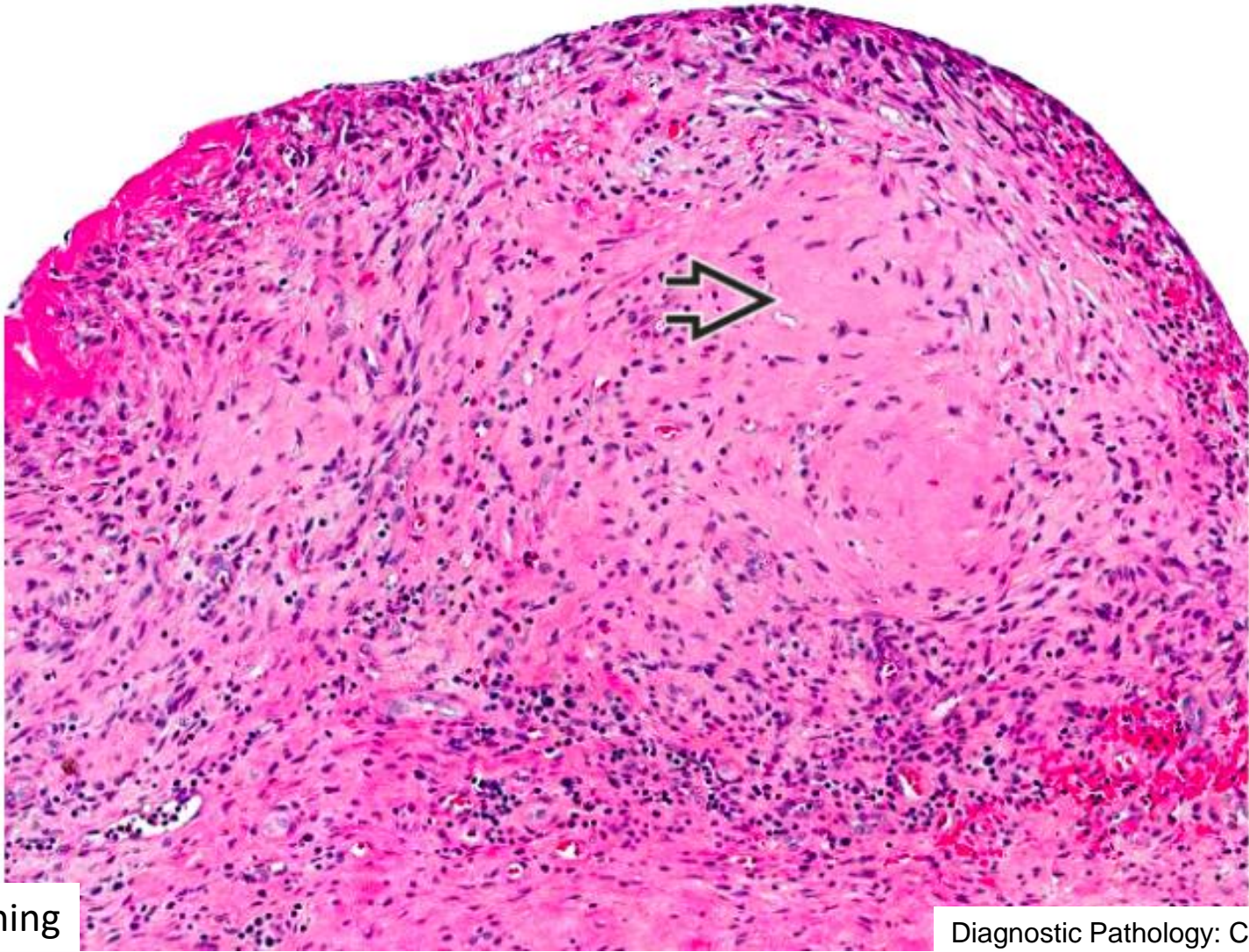
Robbins and Cotran Pathologic Basis of Disease



JACC VOL. 72, NO. 12, 2018:1397–1416



Rheumatic fever

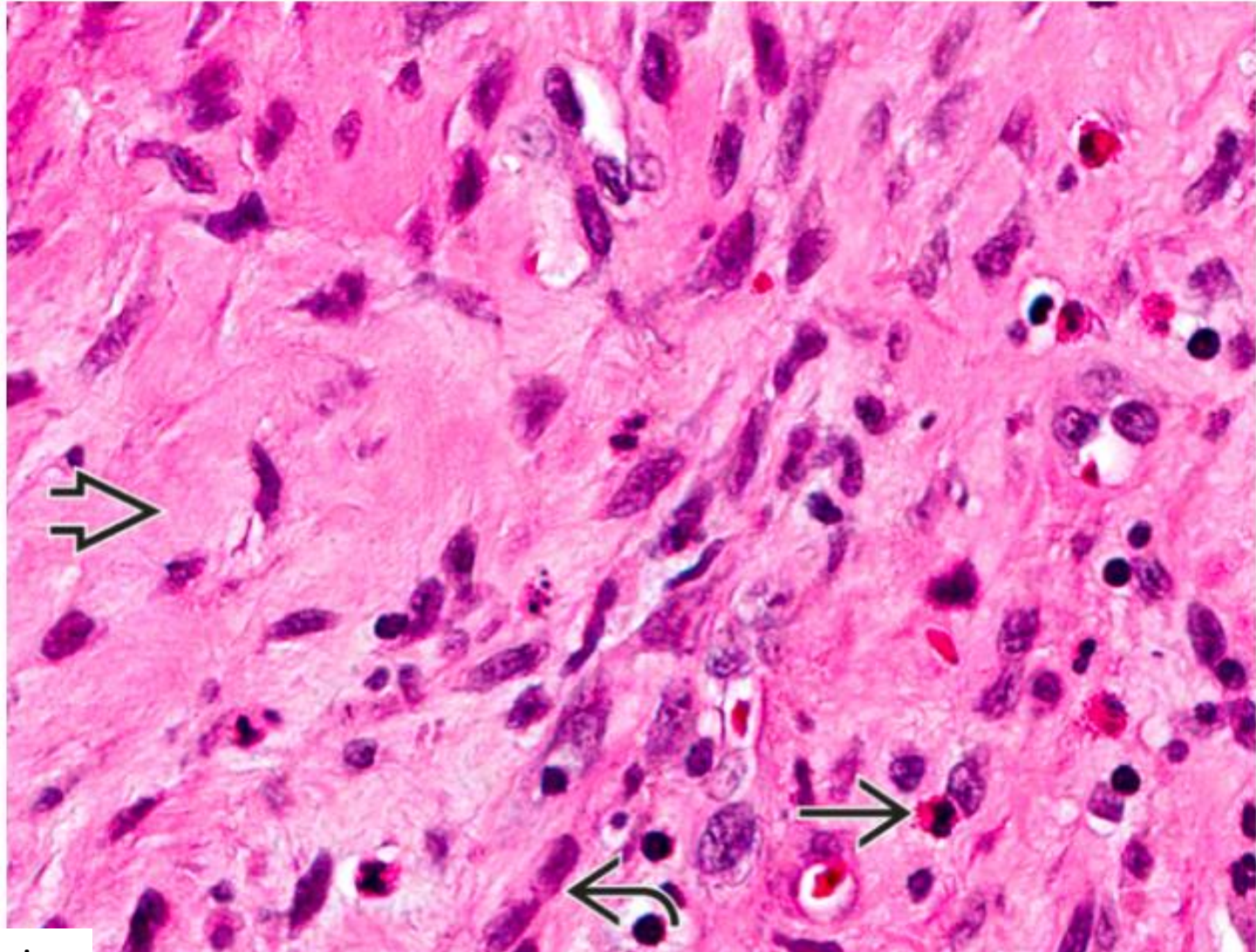


HE staining

Diagnostic Pathology: Cardiovascular



Rheumatic fever



HE staining

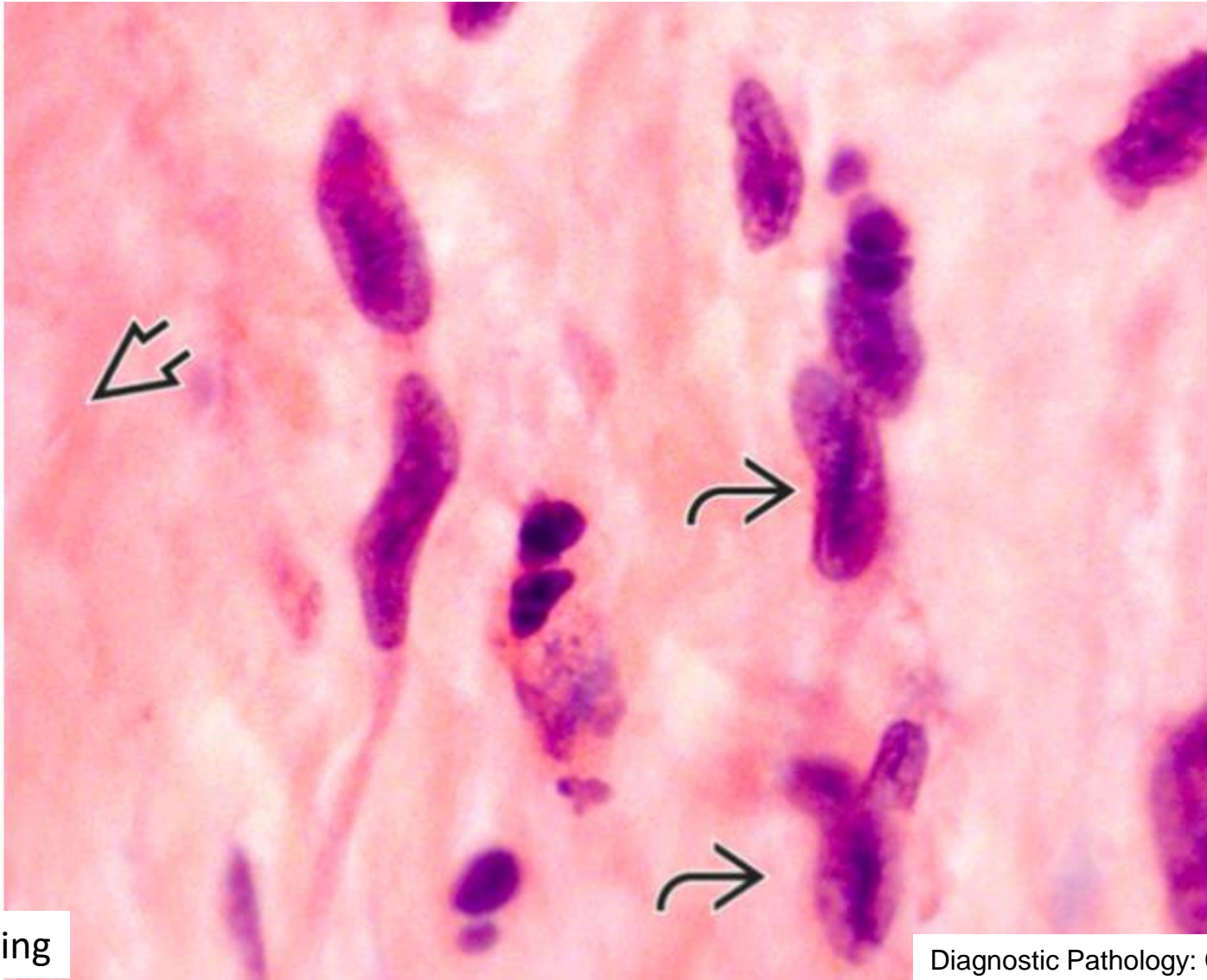
Diagnostic Pathology: Cardiovascular



Semmelweis University
<http://semmelweis.hu>

Attila Fintha MD PhD

Rheumatic fever

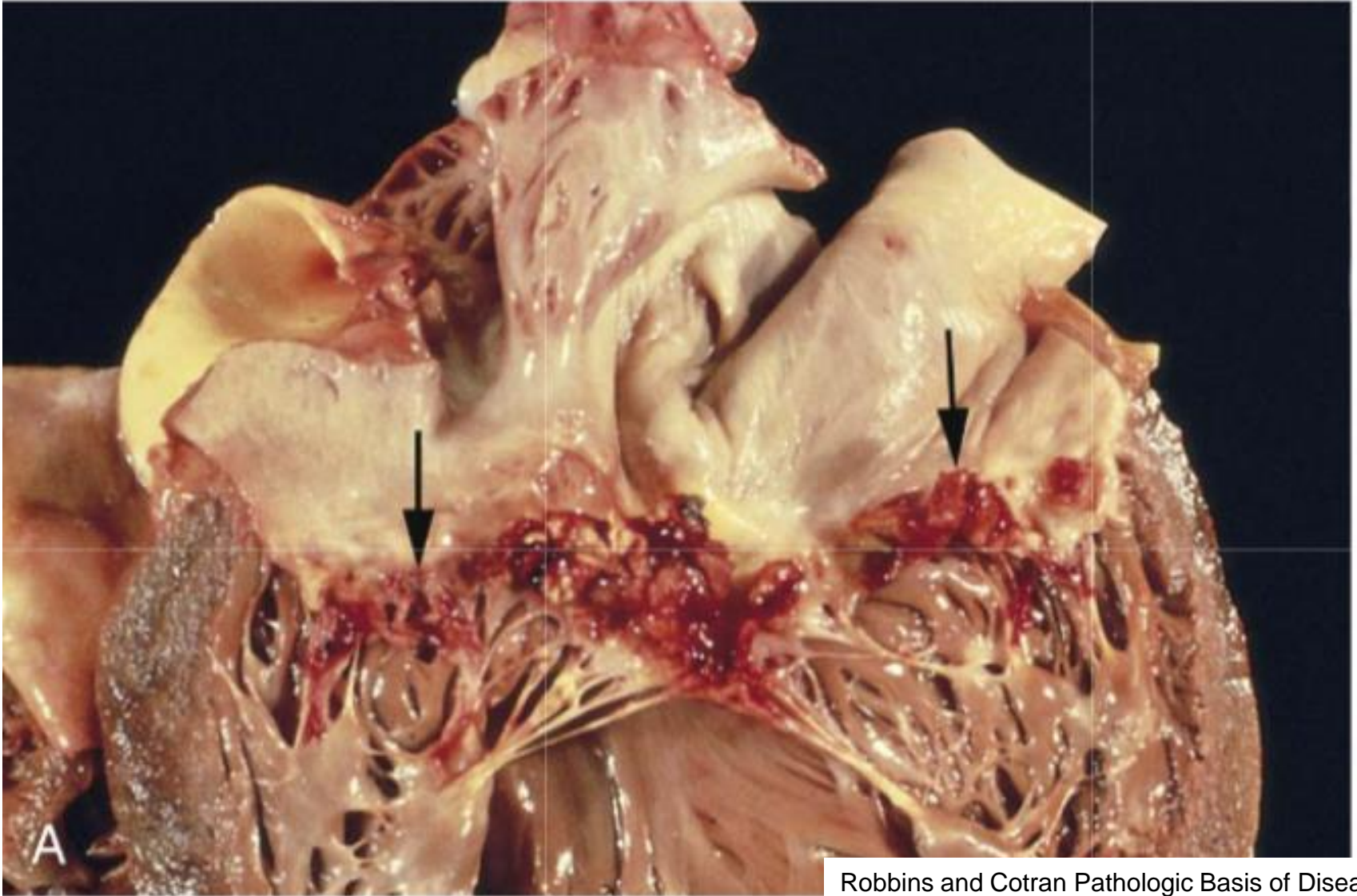


HE staining

Diagnostic Pathology: Cardiovascular

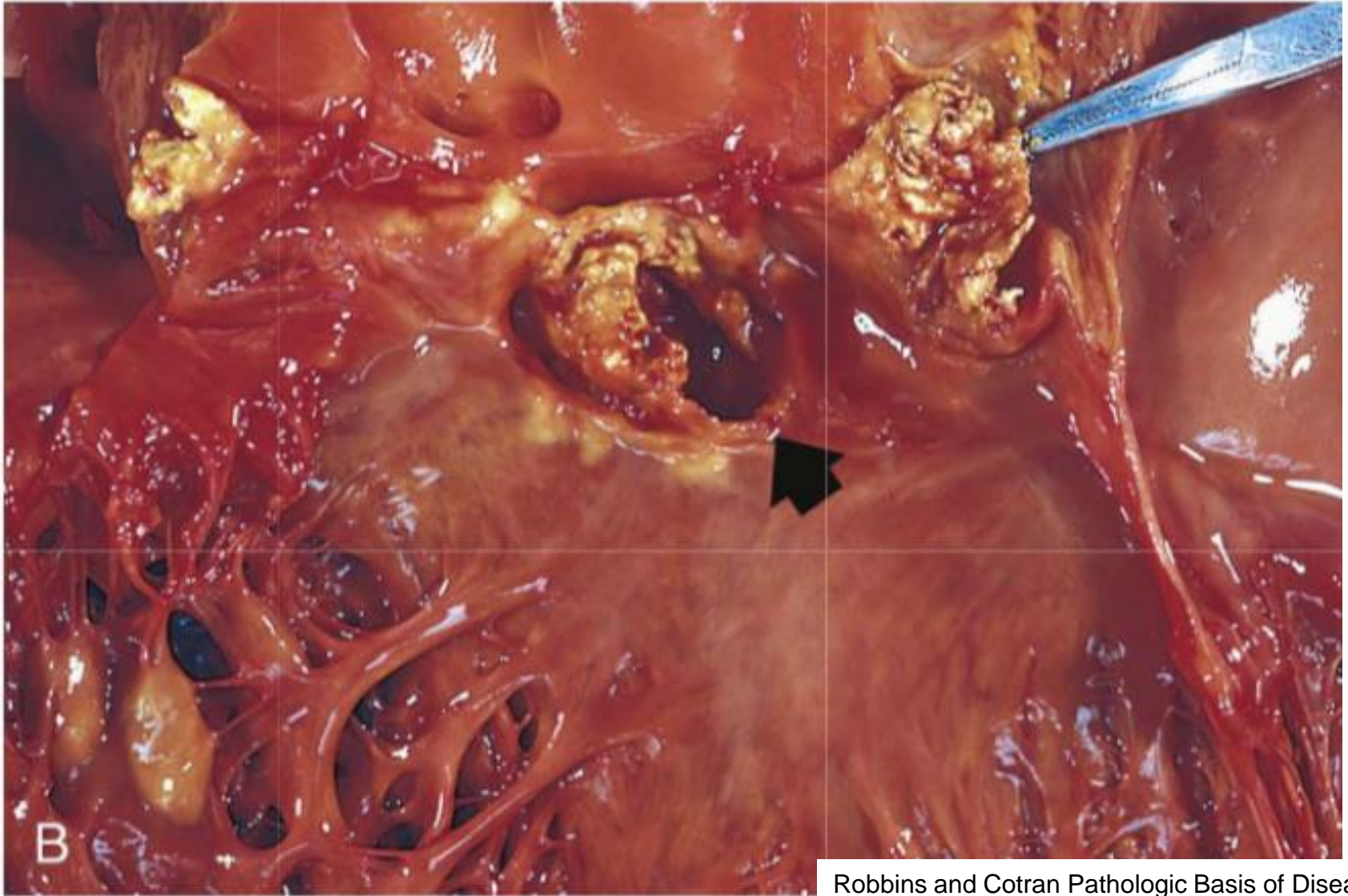


Infective endocarditis

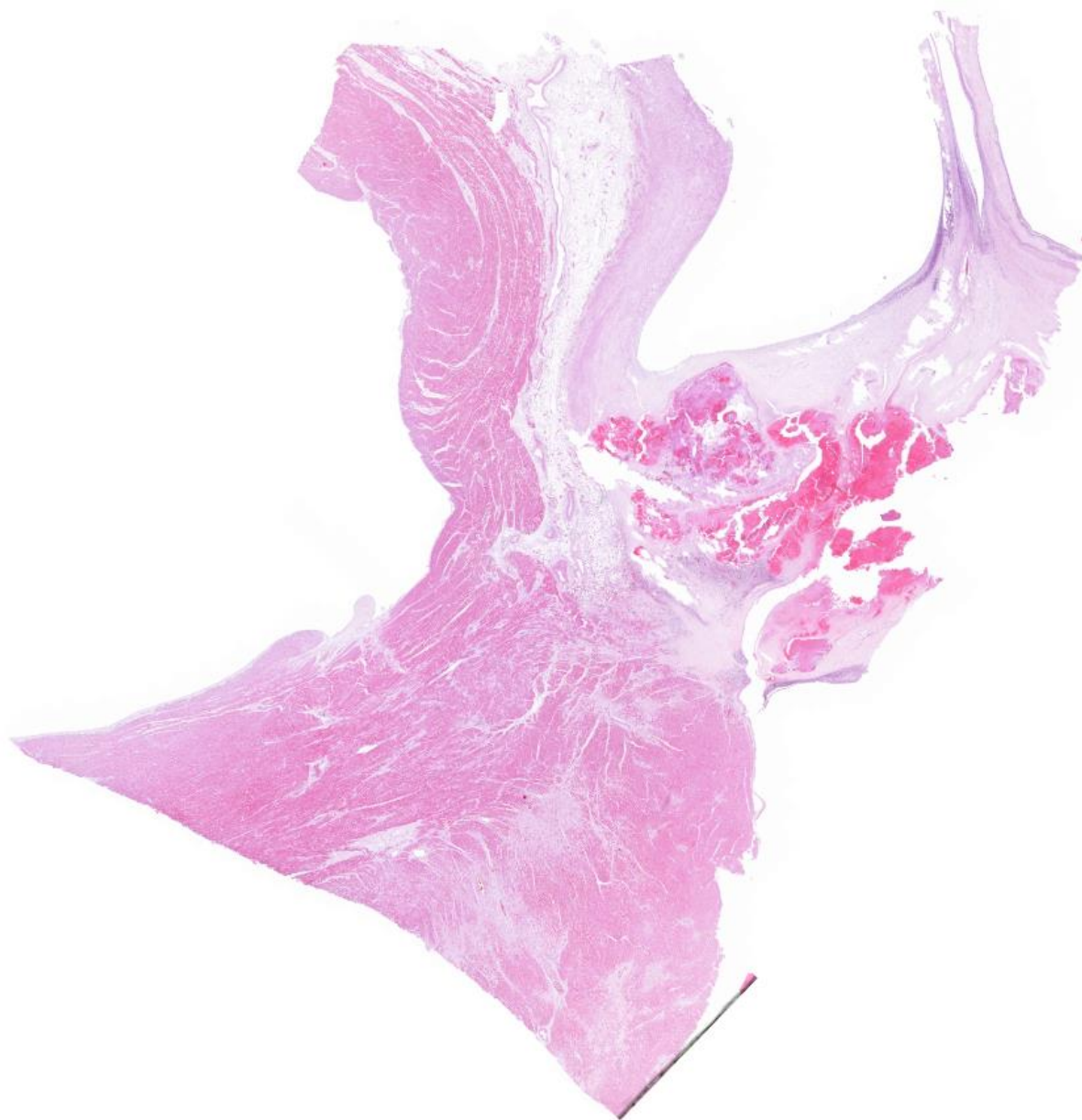


Robbins and Cotran Pathologic Basis of Disease

Infective endocarditis



Robbins and Cotran Pathologic Basis of Disease



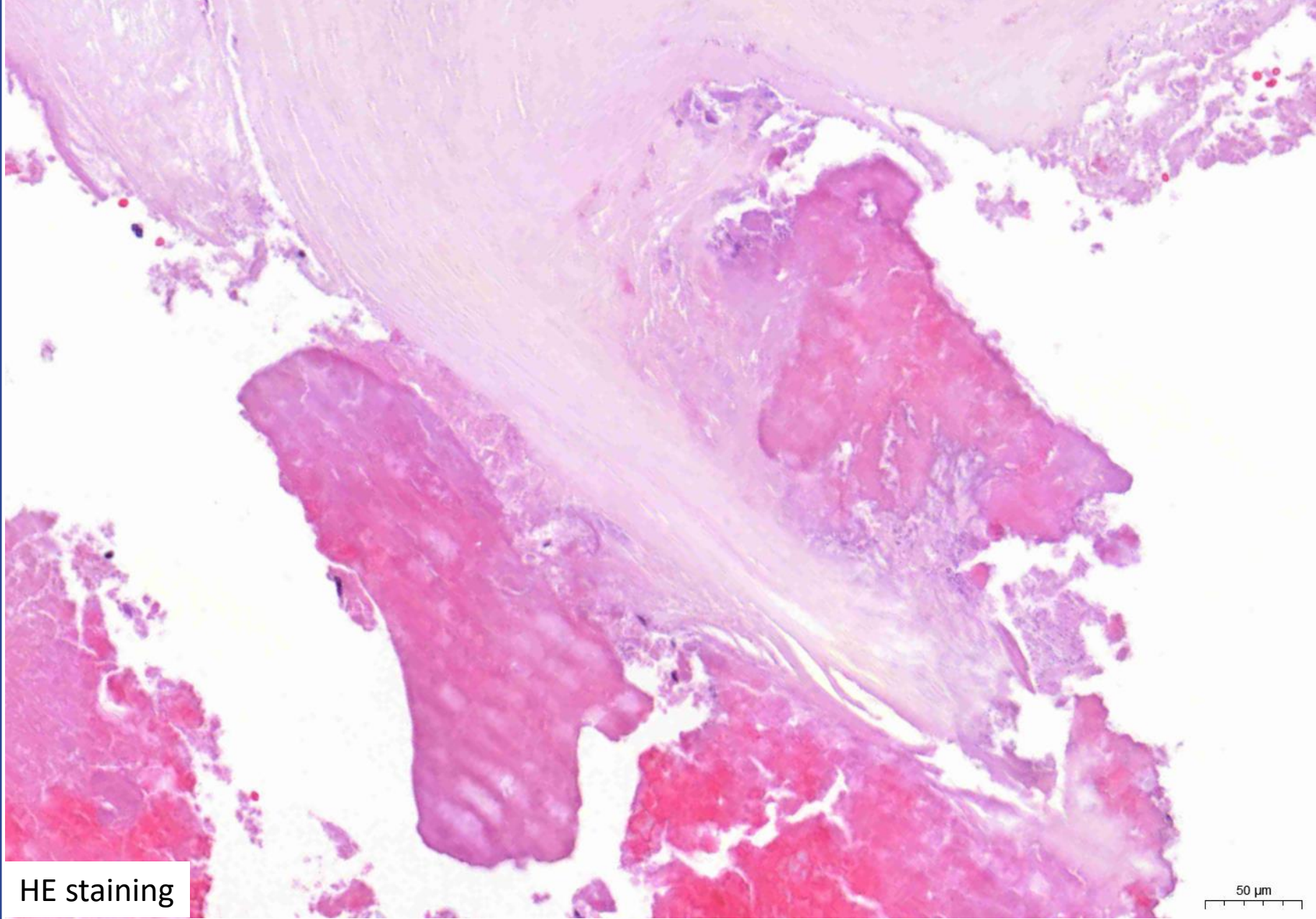
HE staining

5000 μm



Semmelweis University
<http://semmelweis.hu>

Attila Fintha MD PhD



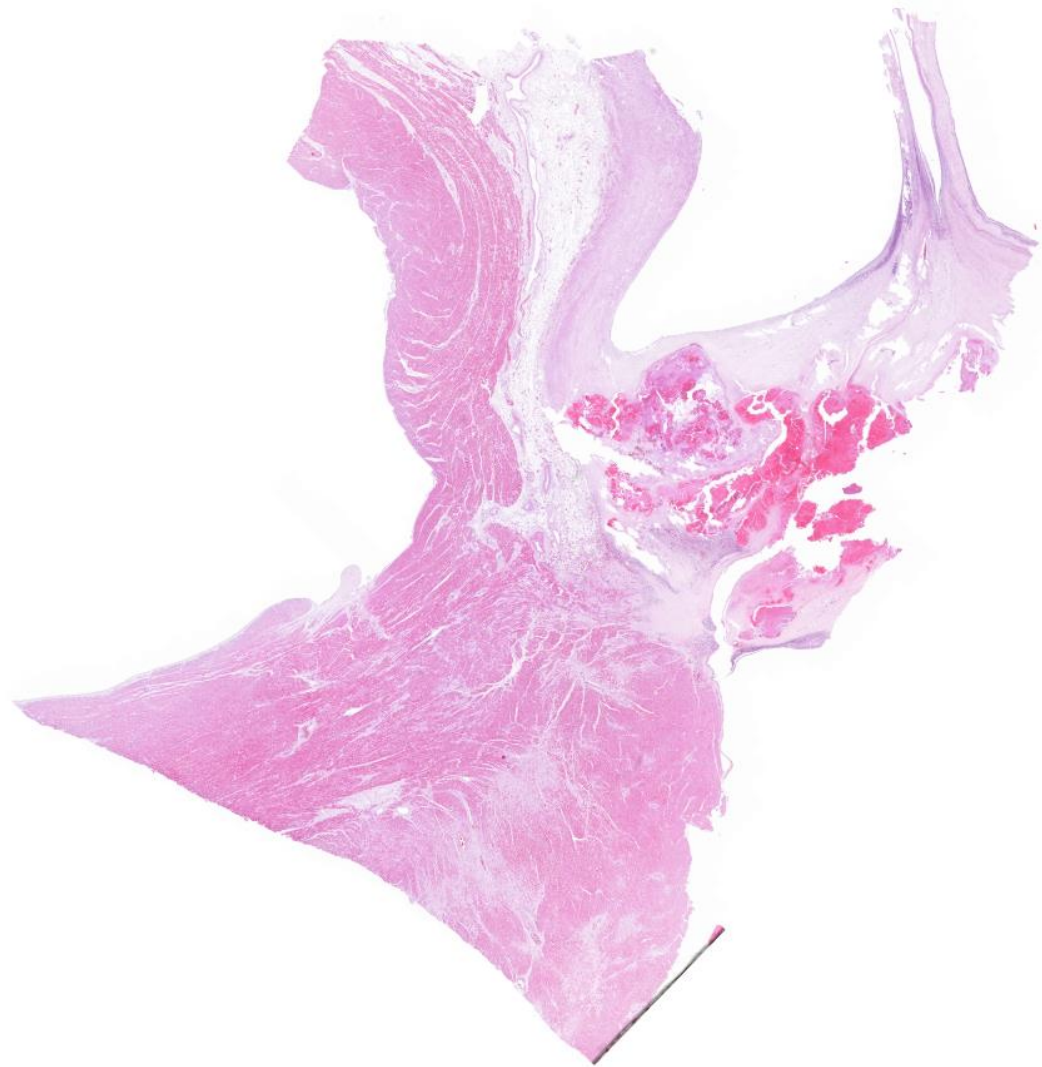
HE staining

50 μm



Semmelweis University
<http://semmelweis.hu>

Attila Fintha MD PhD



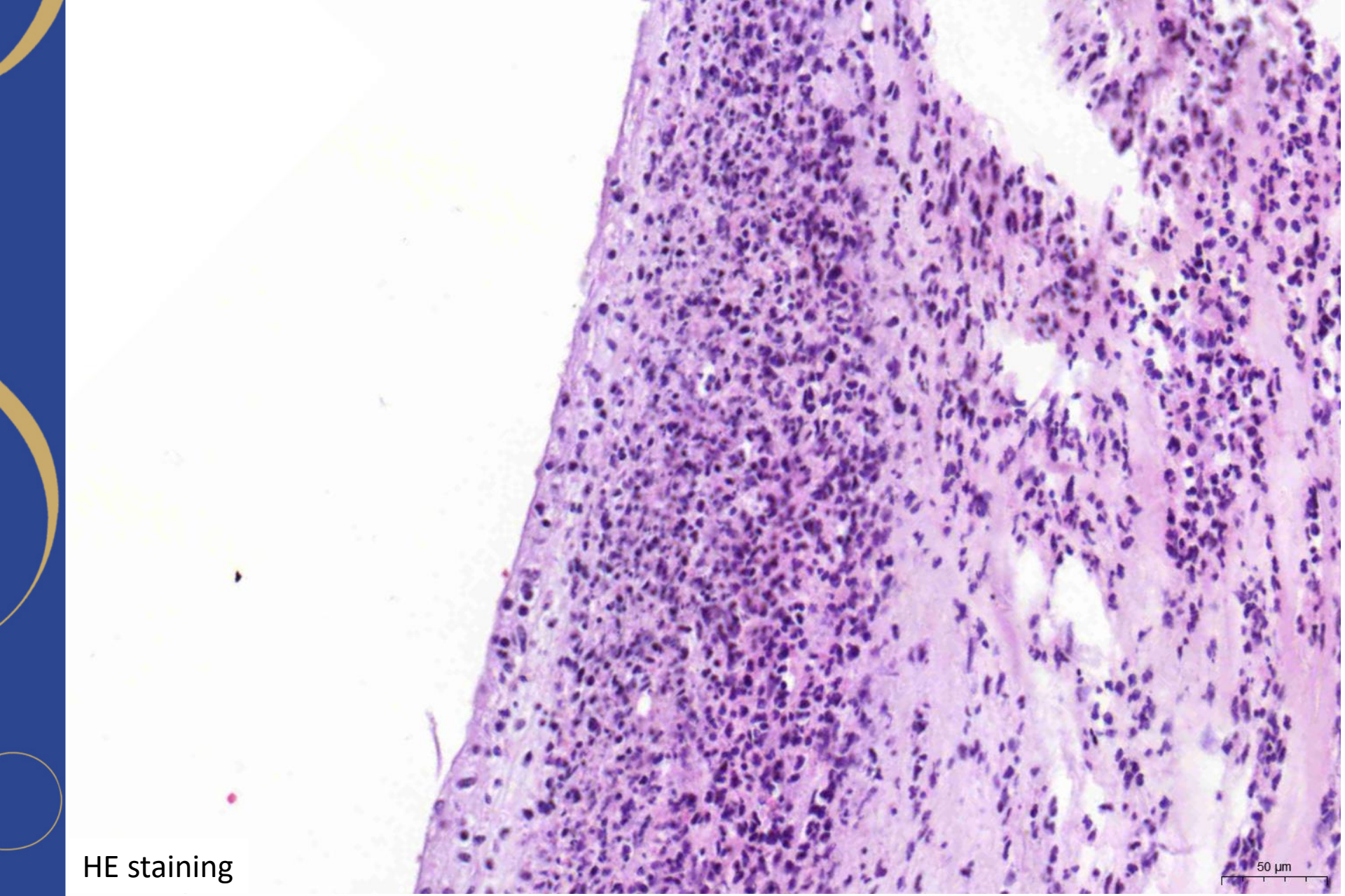
HE staining

5000 μm



Semmelweis University
<http://semmelweis.hu>

Attila Fintha MD PhD



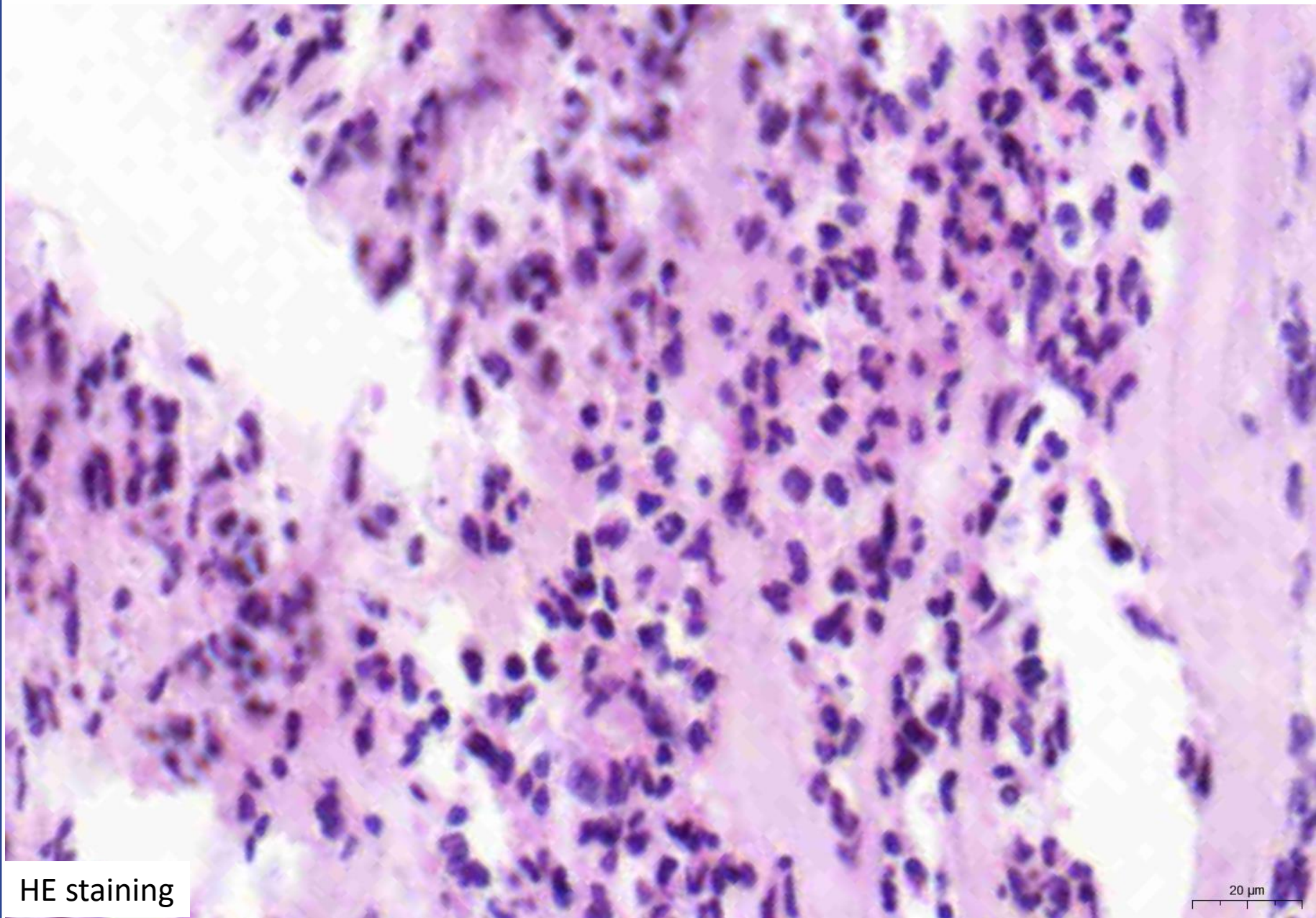
HE staining

50 μm



Semmelweis University
<http://semmelweis.hu>

Attila Fintha MD PhD



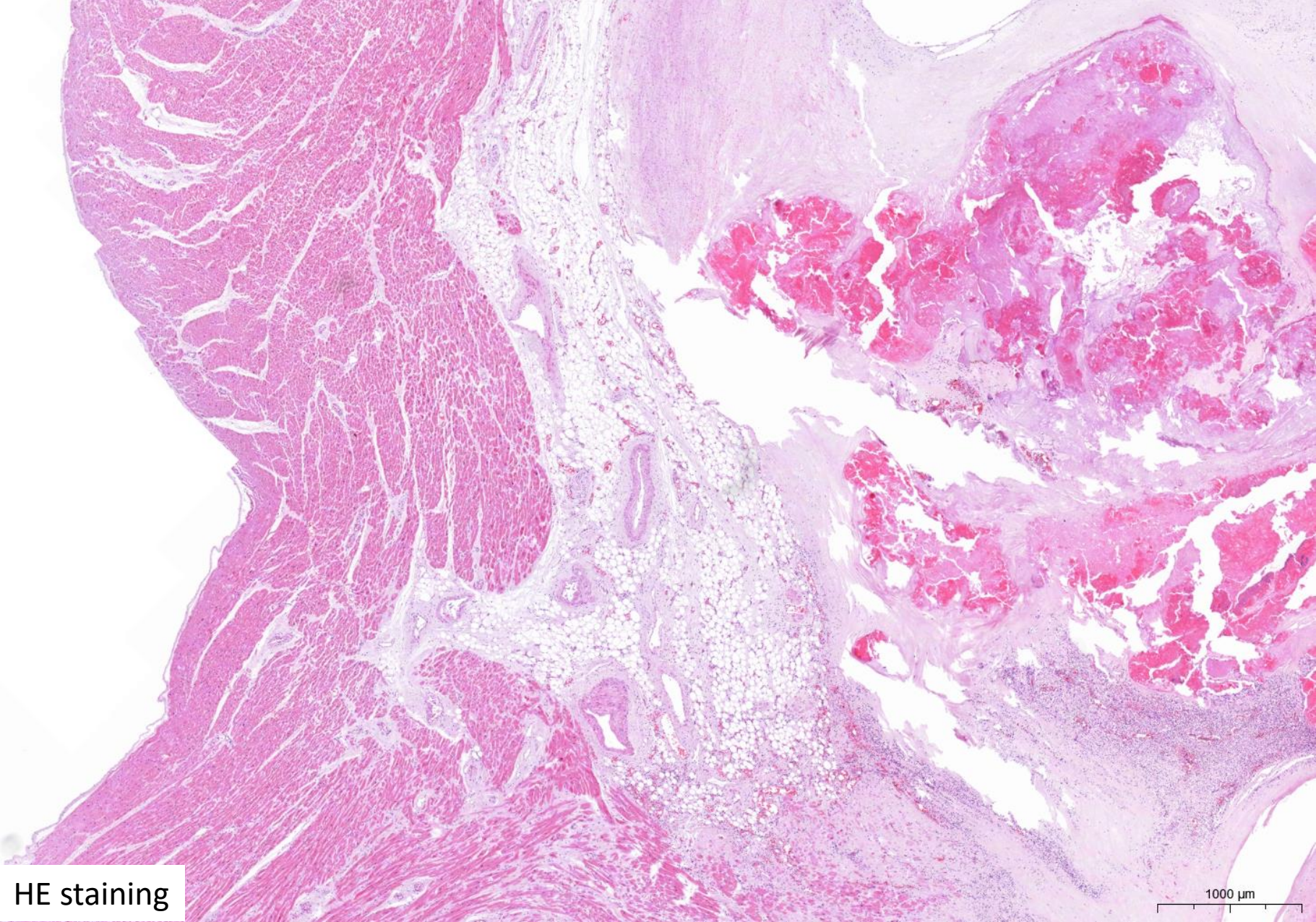
HE staining

20 μ m



Semmelweis University
<http://semmelweis.hu>

Attila Fintha MD PhD



HE staining

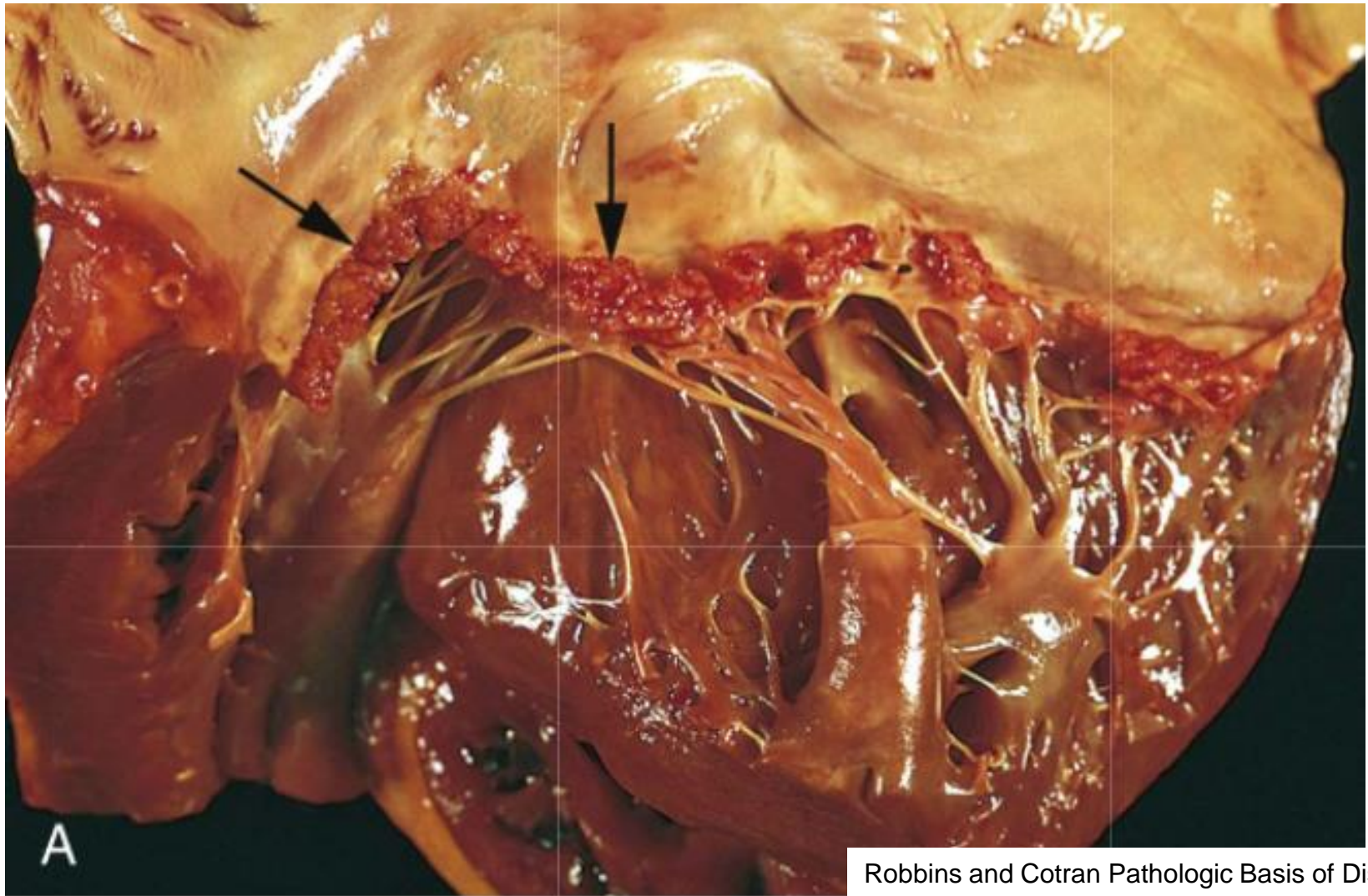
1000 μm



Semmelweis University
<http://semmelweis.hu>

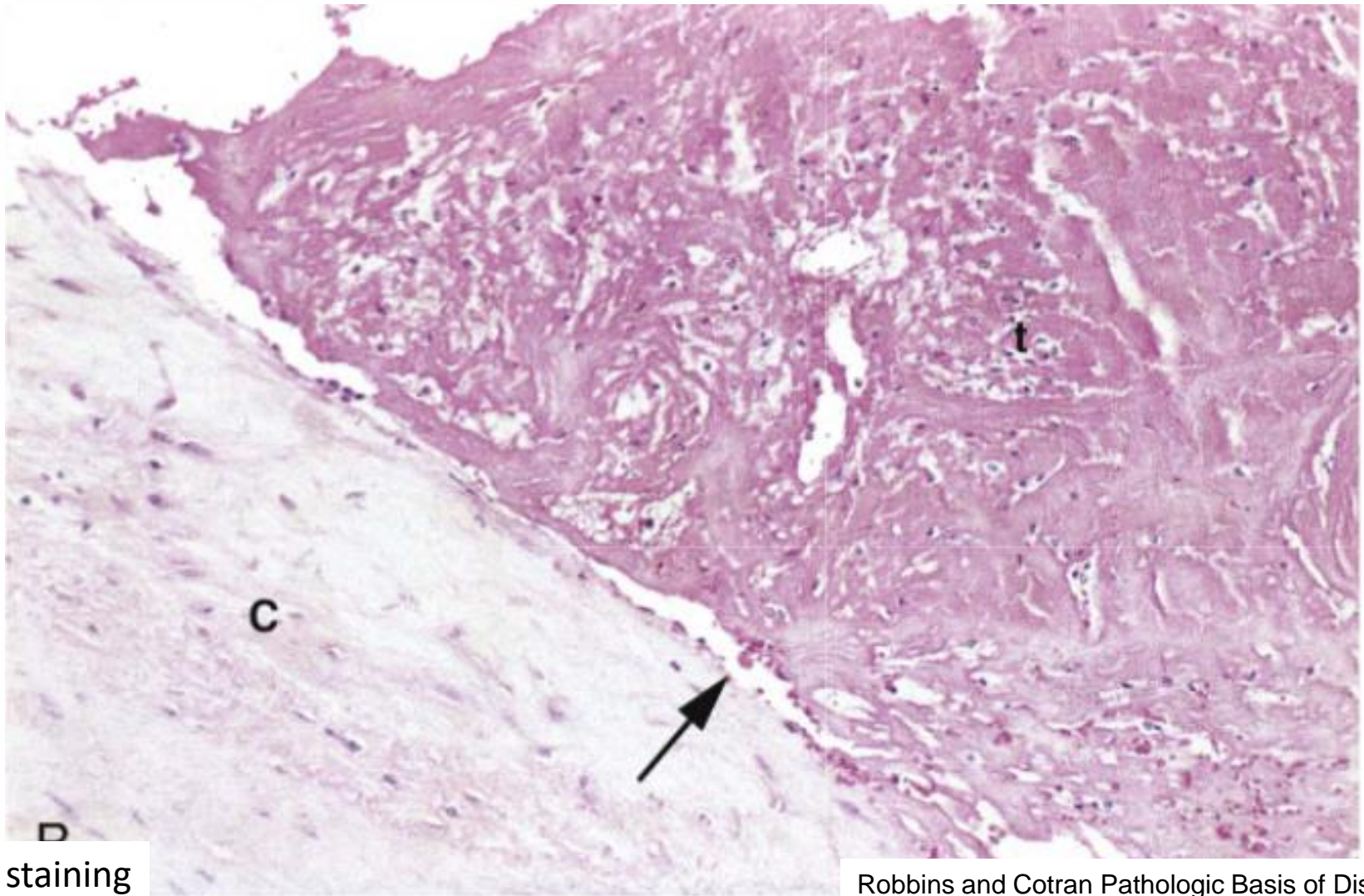
Attila Fintha MD PhD

Non-bacterial thrombotic endocarditis



Robbins and Cotran Pathologic Basis of Disease

Non-bacterial thrombotic endocarditis



HE staining

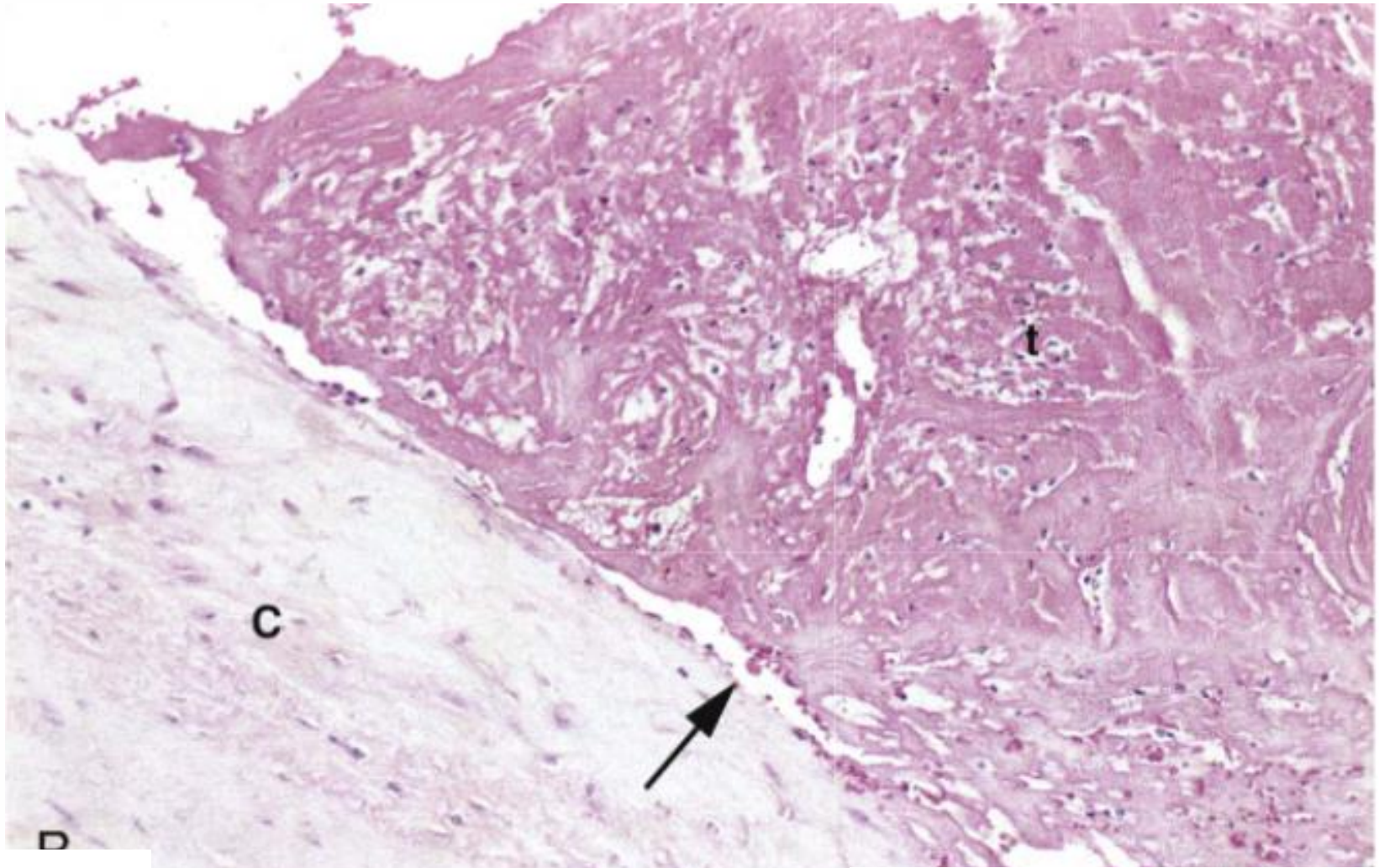
Robbins and Cotran Pathologic Basis of Disease



Semmelweis University
<http://semmelweis.hu>

Attila Fintha MD PhD

Libman-Sacks endocarditis (in SLE)



HE staining

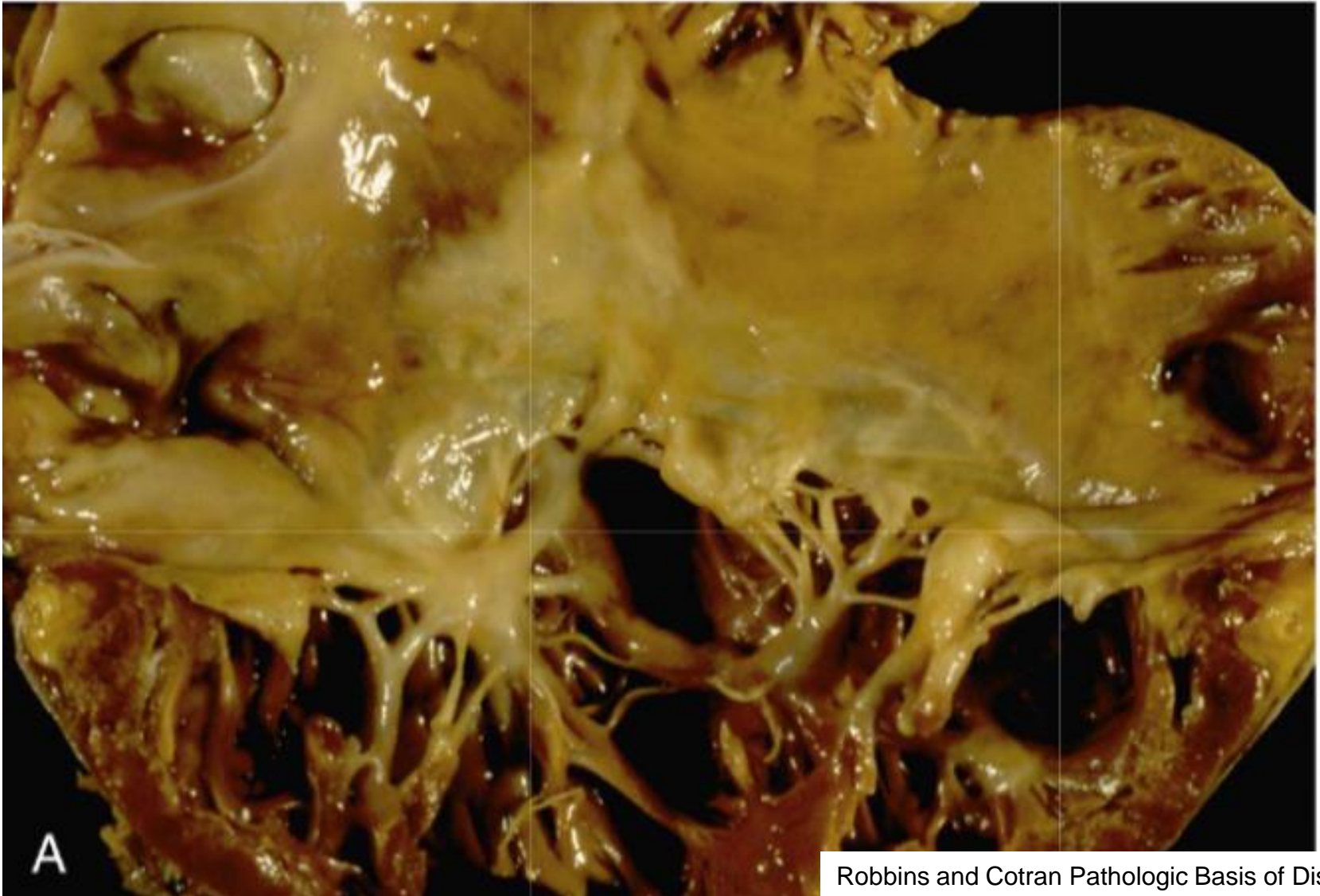
Robbins and Cotran Pathologic Basis of Disease



Semmelweis University
<http://semmelweis.hu>

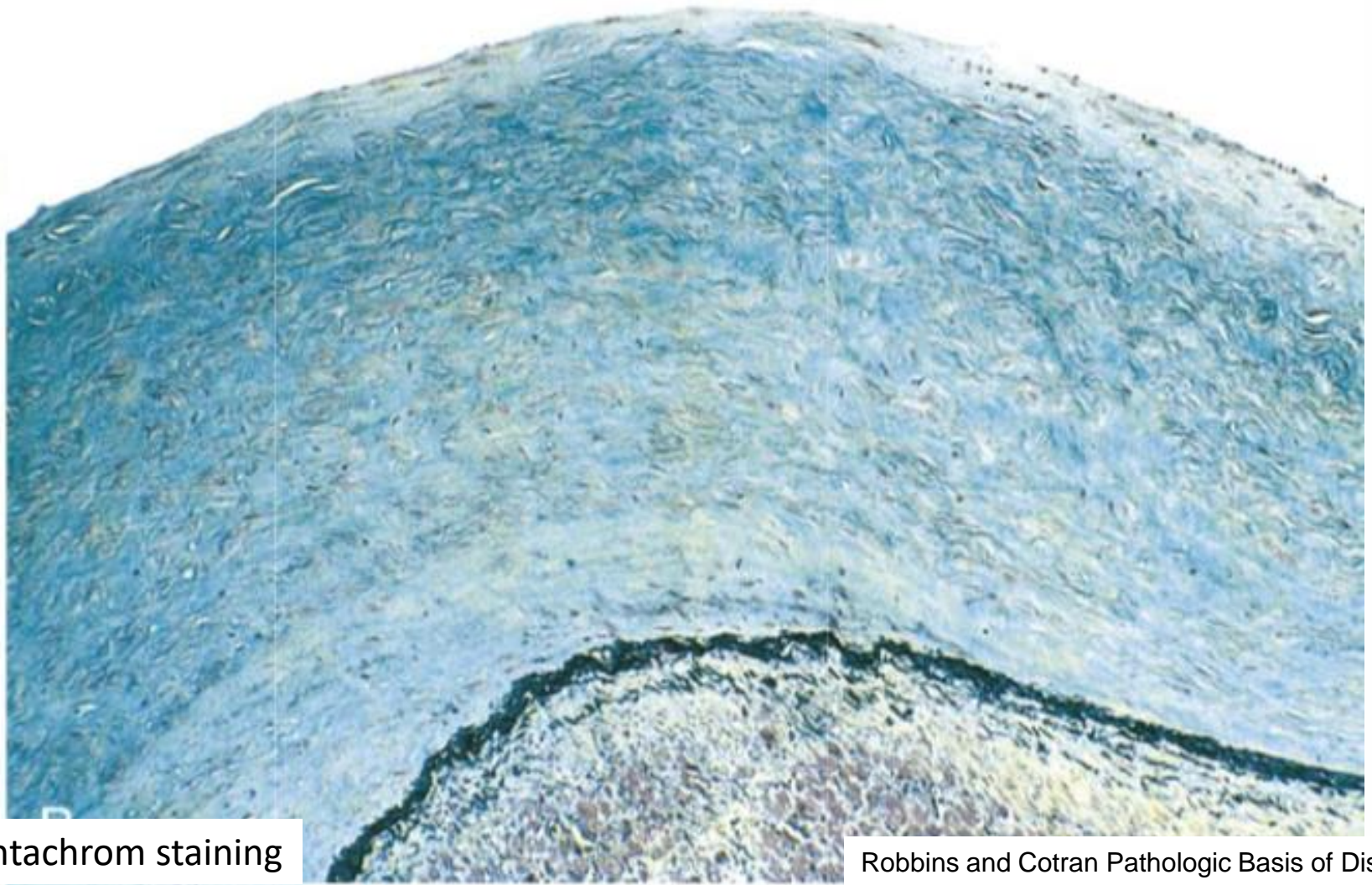
Attila Fintha MD PhD

Carcinoid heart disease



Robbins and Cotran Pathologic Basis of Disease

Carcinoid heart disease



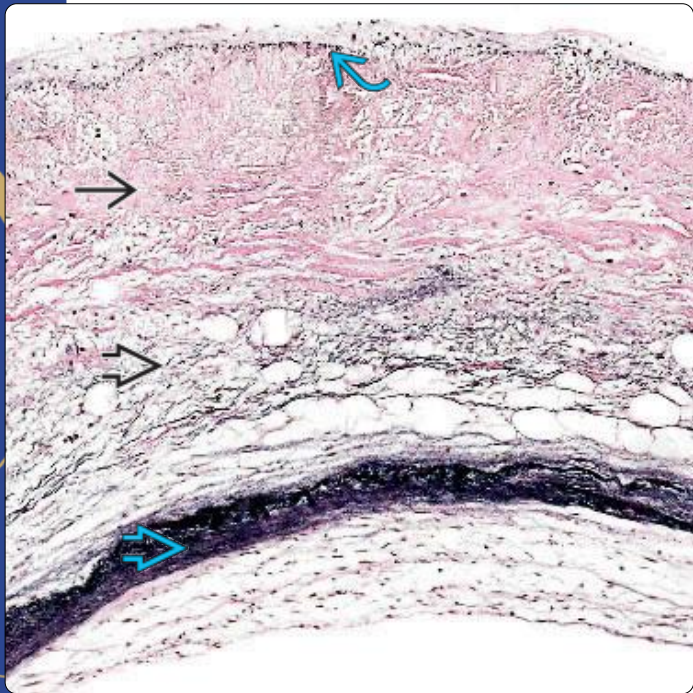
Pentachrom staining

Robbins and Cotran Pathologic Basis of Disease

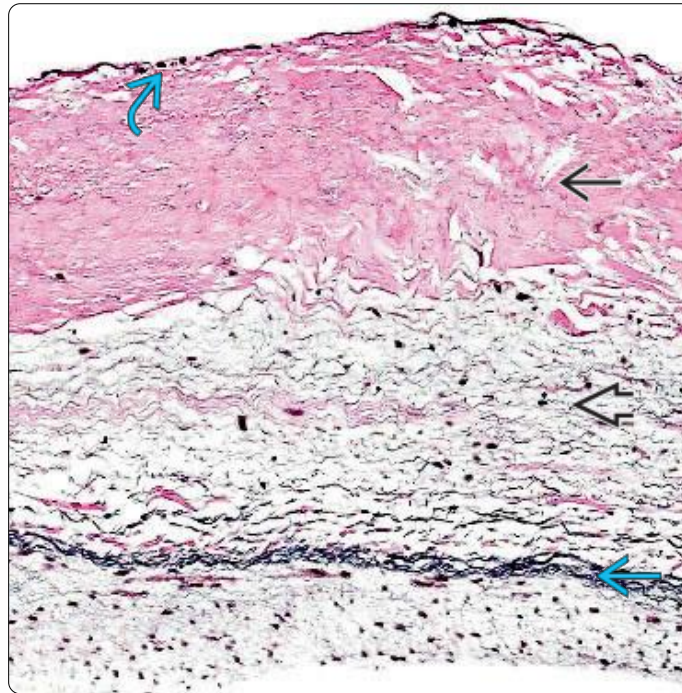


Normal histology of valves

Semilunar Valve



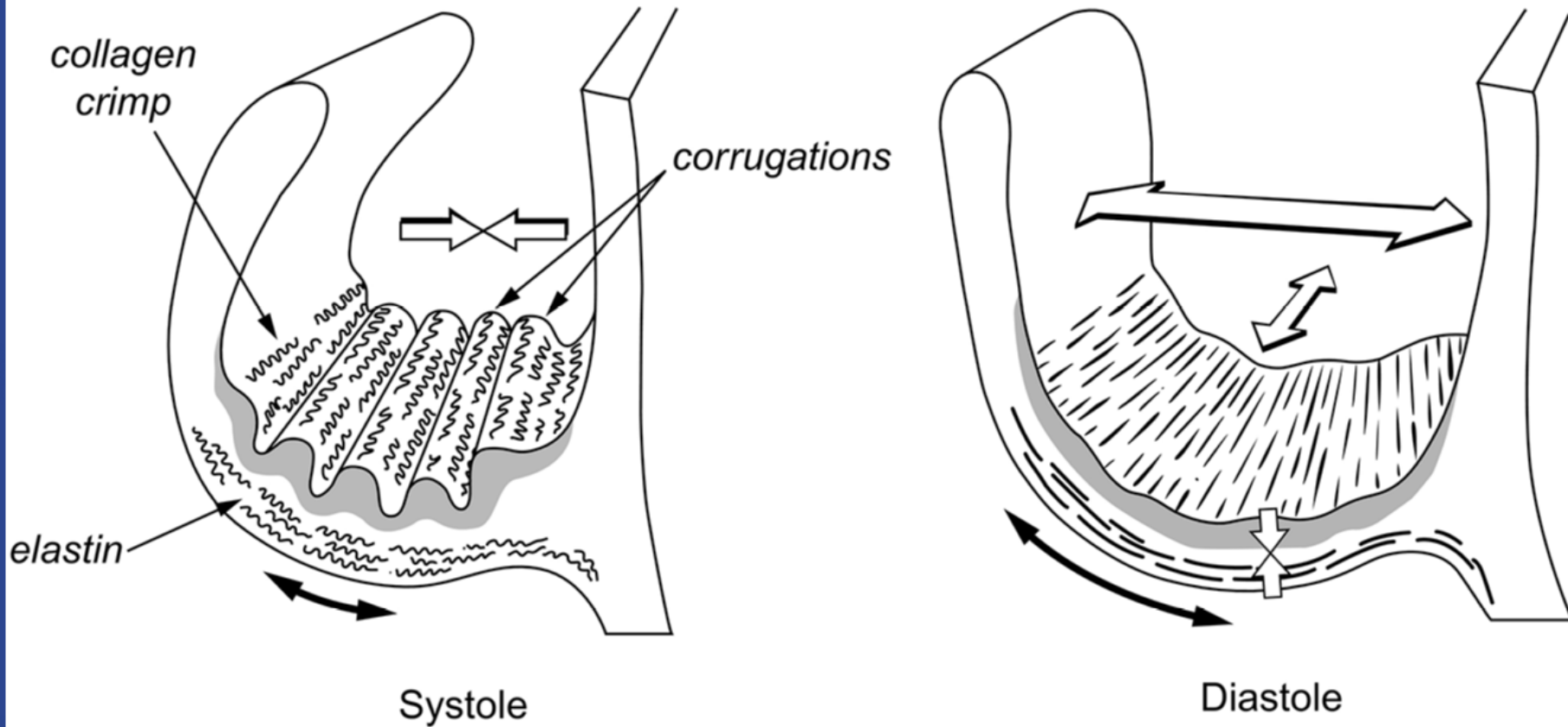
Atrioventricular Valve



(Left) The 3 distinct valvular layers are the fibrosa [box], spongiosa [box], and ventricularis [box]. A fine line of elastic tissue is seen beneath the endocardium overlying the fibrosa layer [box]. The ventricularis layer is the richest in elastic tissue, as shown by the heavy black band on this elastic stain. (Right) This photo shows the 3 distinct valvular layers: Fibrosa [box], spongiosa [box], and ventricularis [box], with the subendocardial elastic layer [box].

Diagnostic Pathology: Normal histology

Normal histology of valves



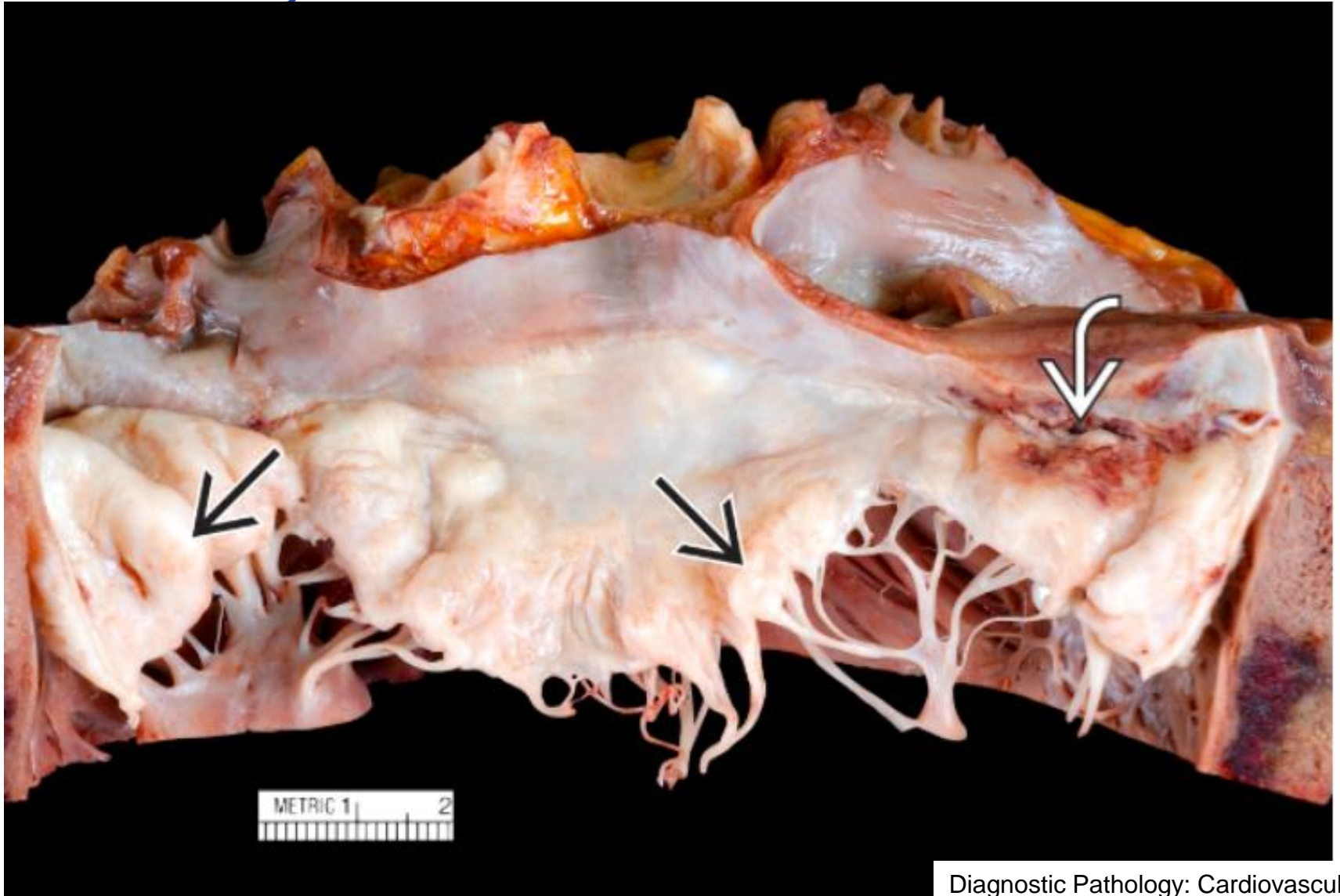
Cardiovascular Pathology, 4 ed



Semmelweis University
<http://semmelweis.hu>

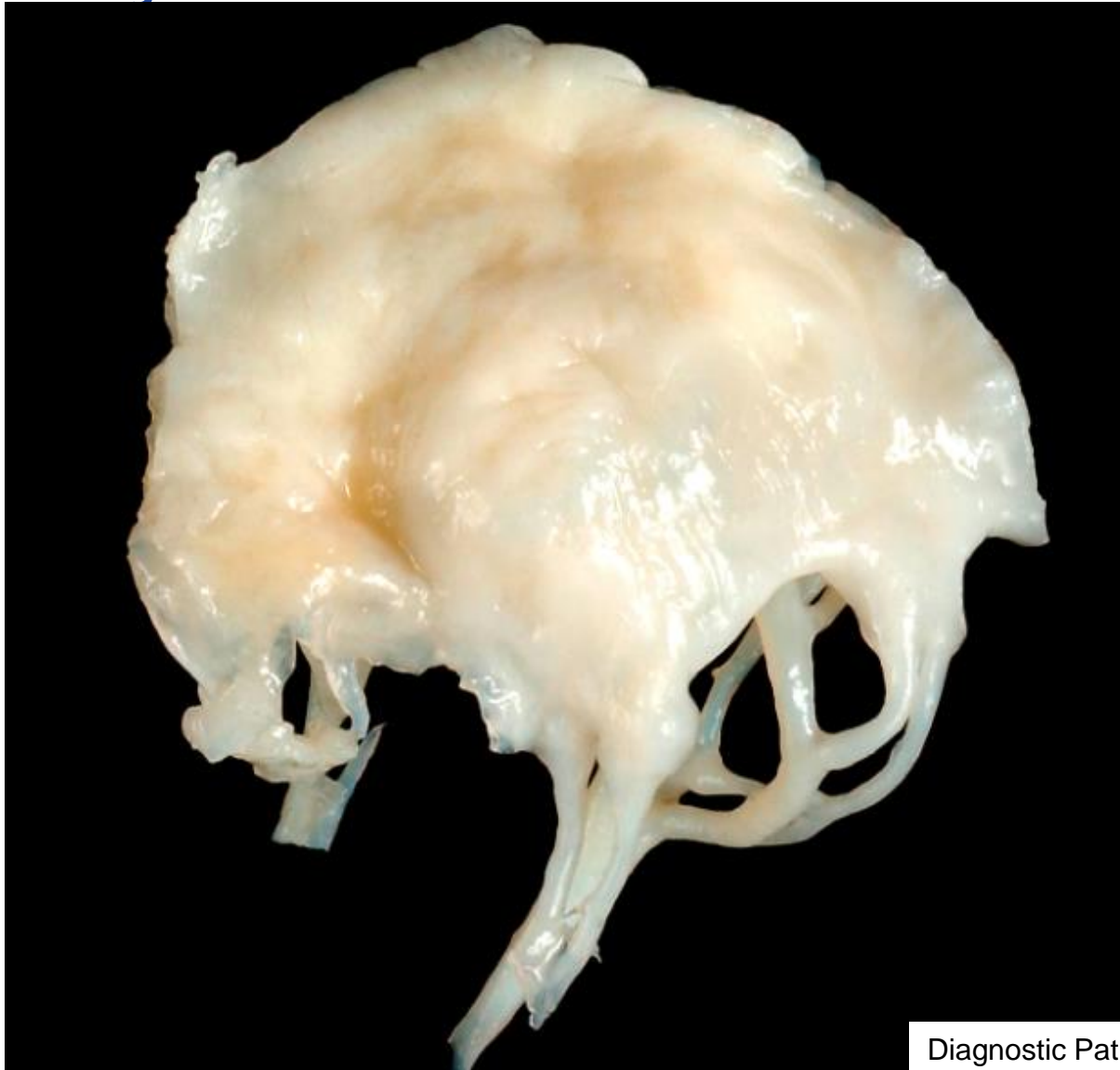Attila Fintha MD PhD

Myxomatous mitral valve



Diagnostic Pathology: Cardiovascular

Myxomatous mitral valve



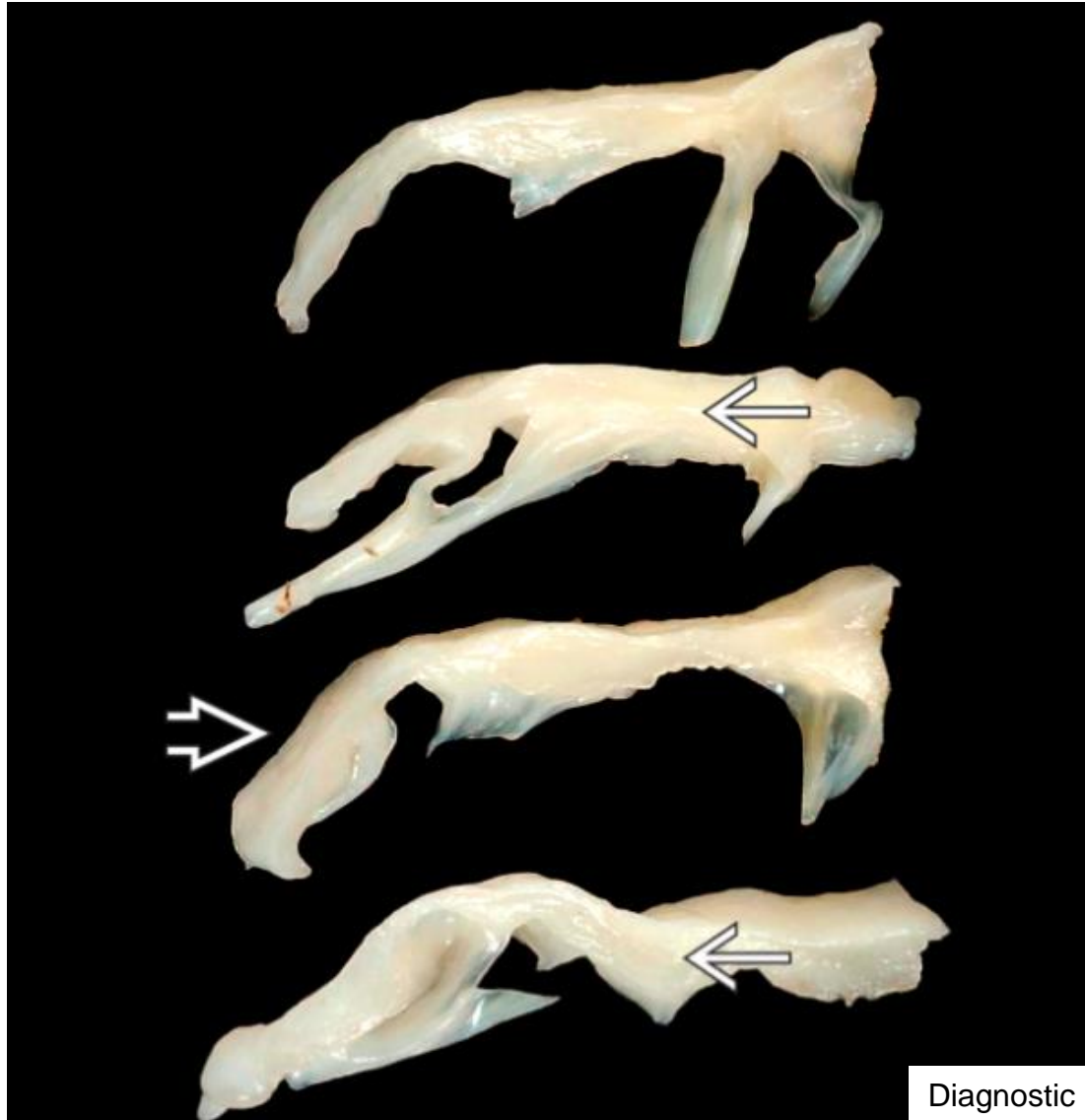Diagnostic Pathology: Cardiovascular



Semmelweis University
<http://semmelweis.hu>

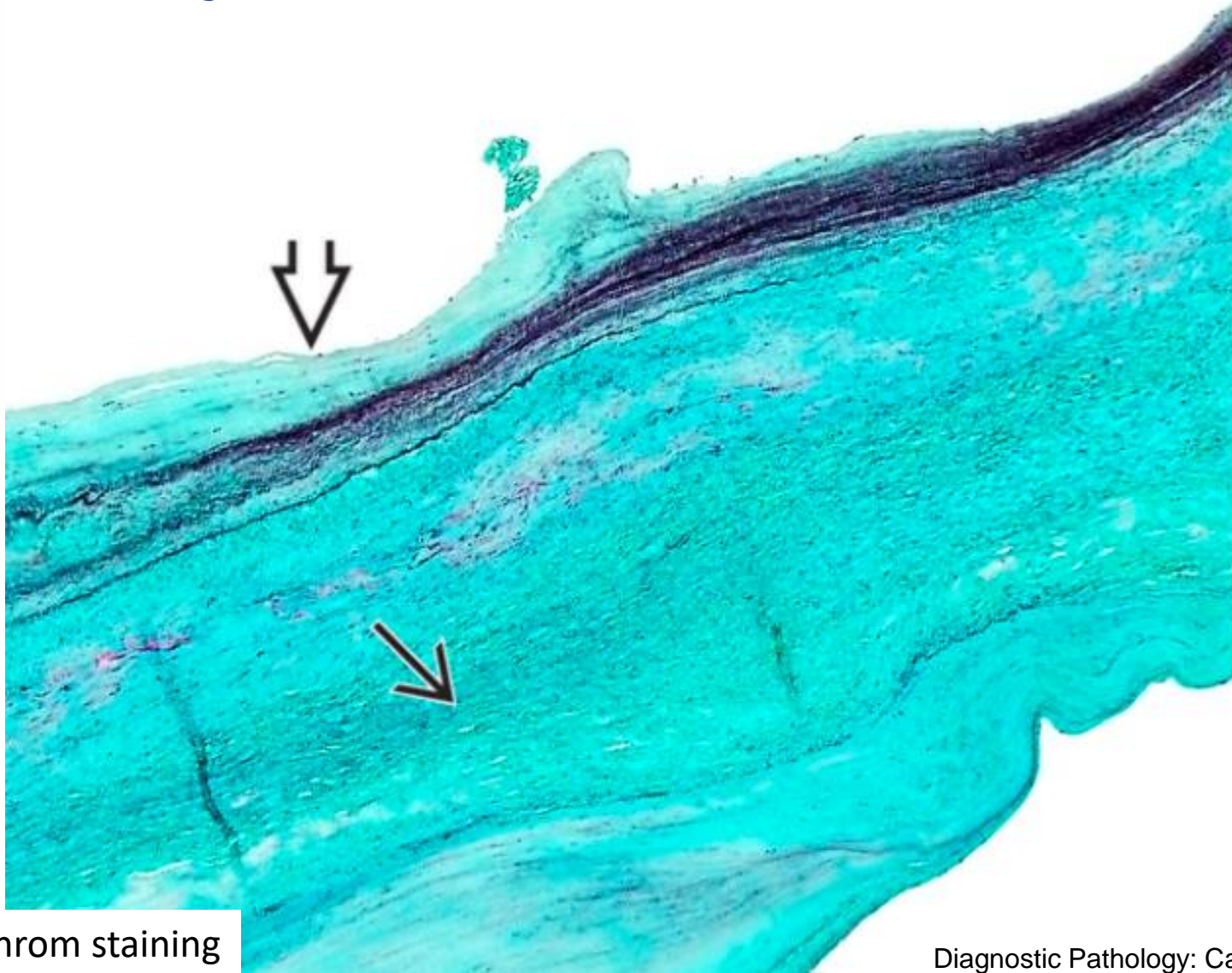
Attila Fintha MD PhD

Myxomatous mitral valve



Diagnostic Pathology: Cardiovascular

Myxomatous mitral valve

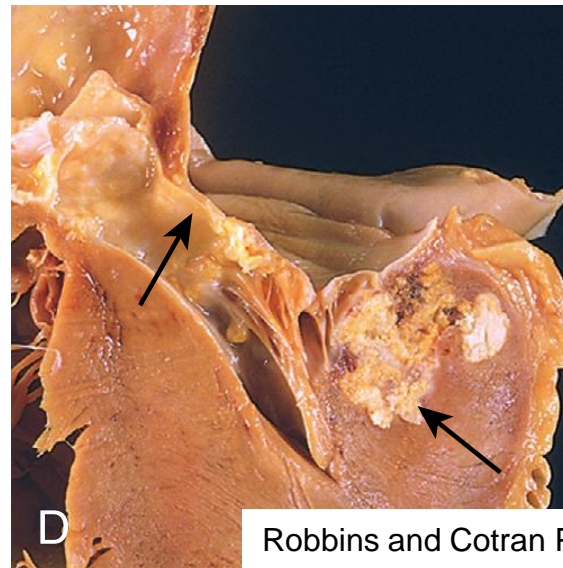
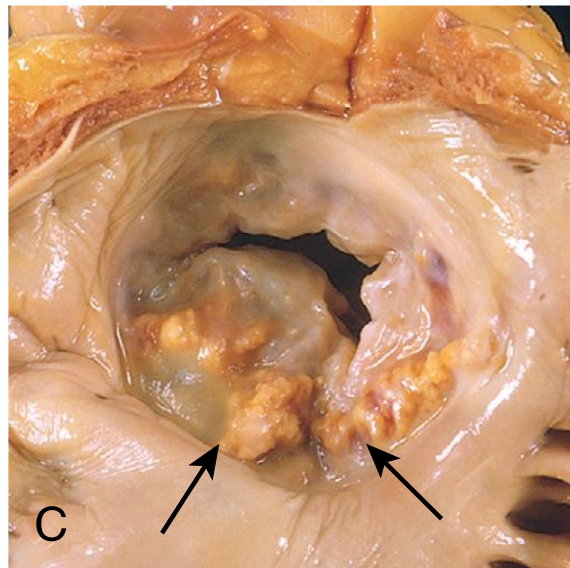
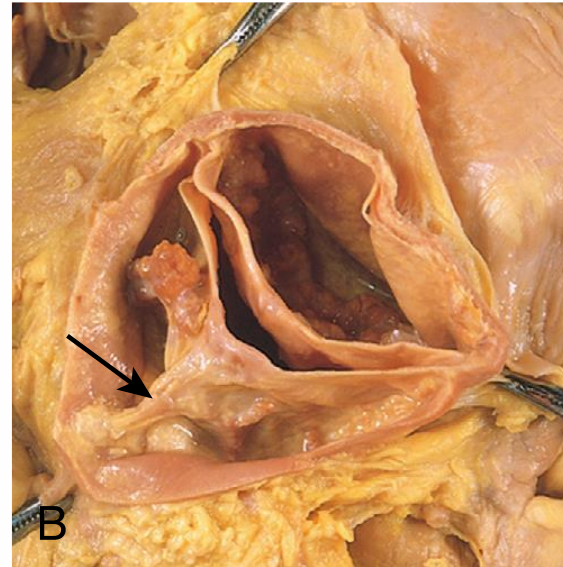
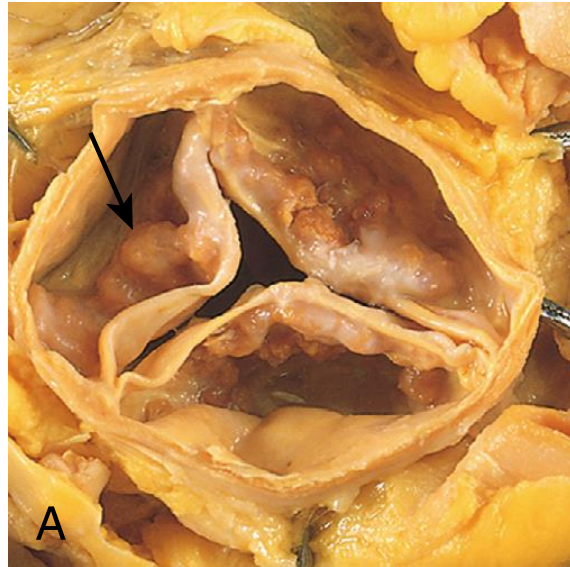


Pentachrom staining

Diagnostic Pathology: Cardiovascular



Calcific aortic stenosis

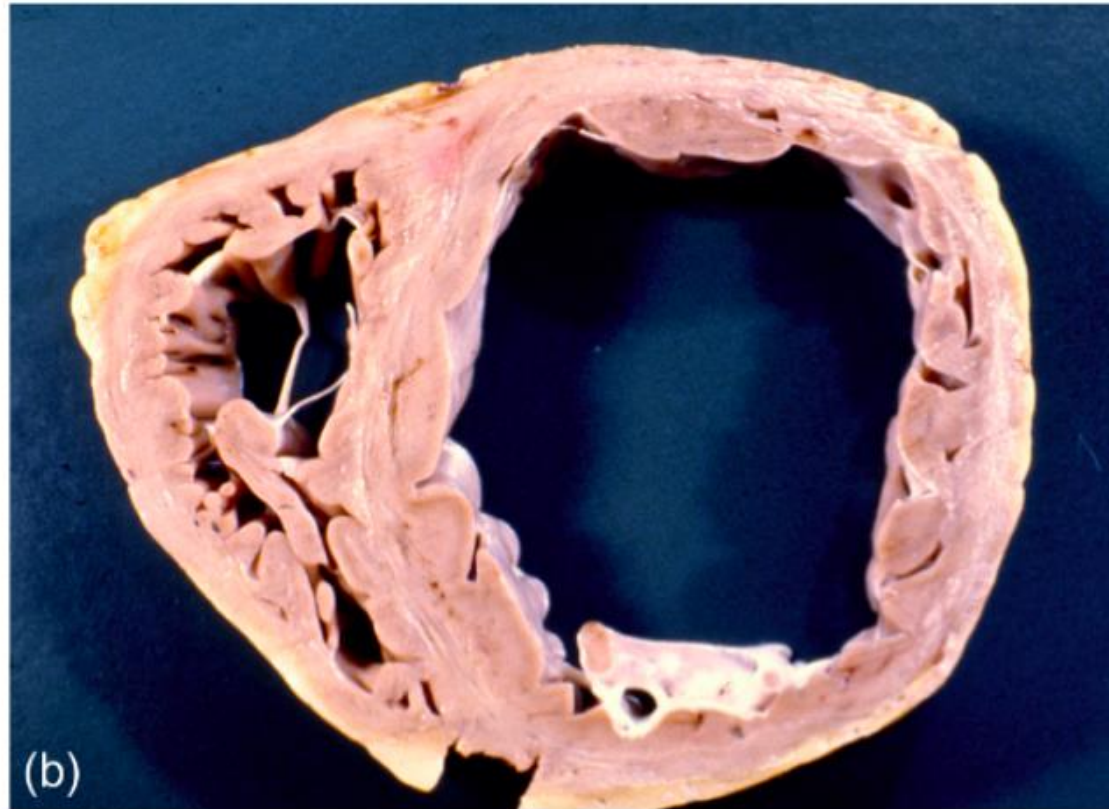
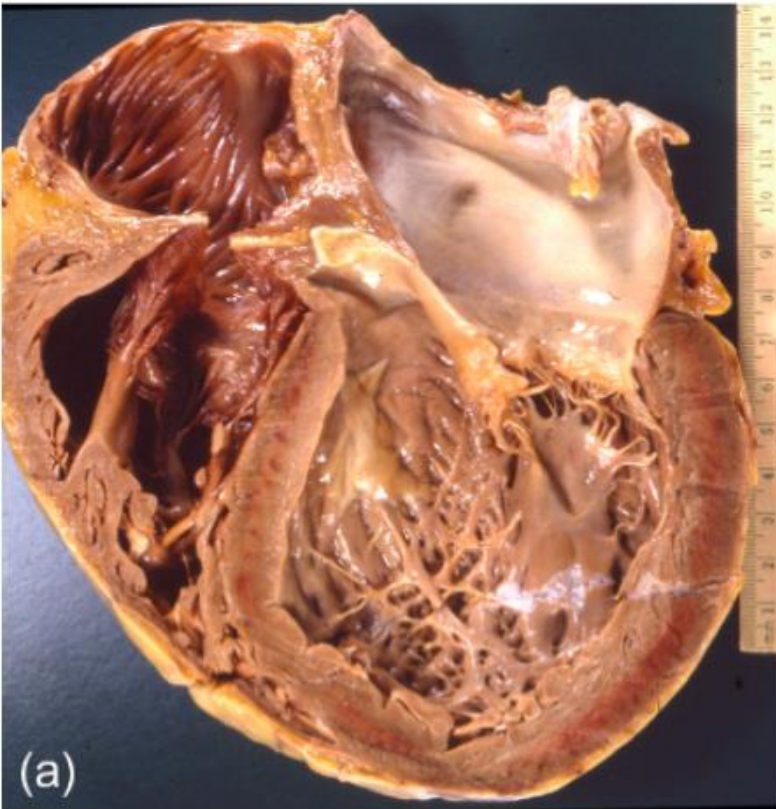


Robbins and Cotran Pathologic Basis of Disease

Cardiomyopathies



Dilated cardiomyopathy



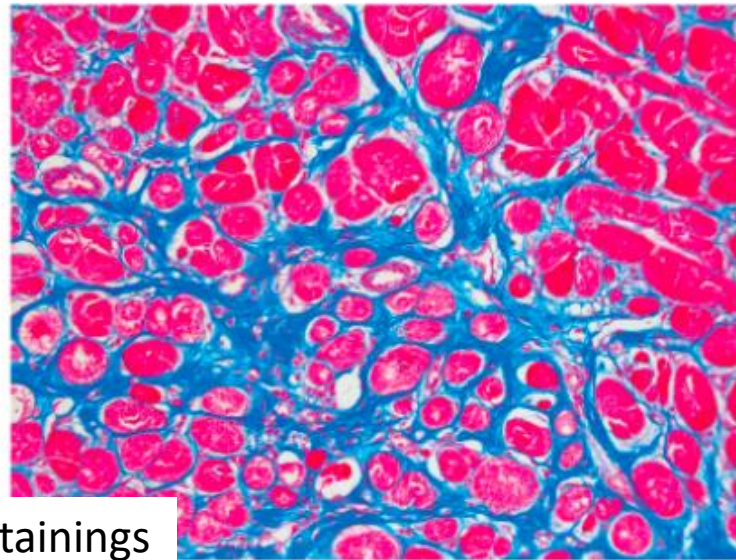
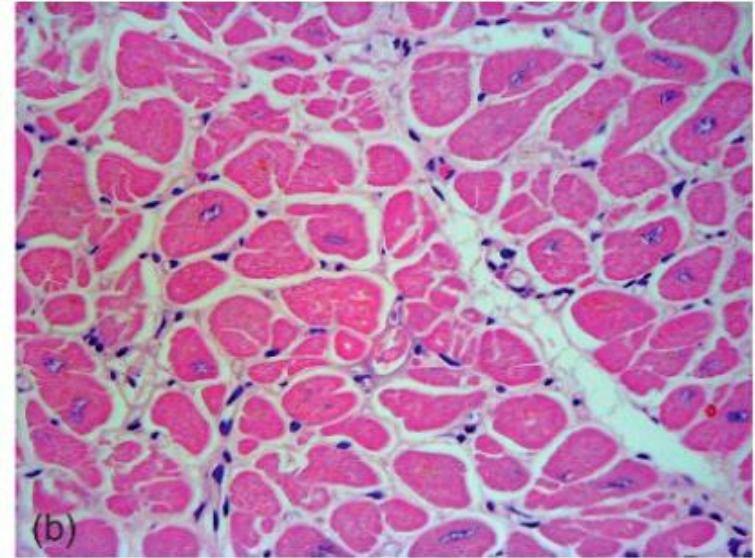
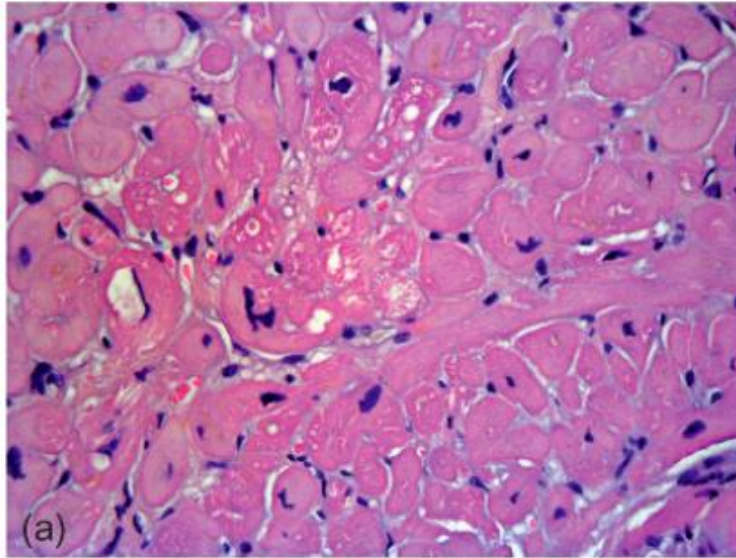
Cardiovascular Pathology, 4 ed



Semmelweis University
<http://semmelweis.hu>

Attila Fintha MD PhD

Dilated cardiomyopathy

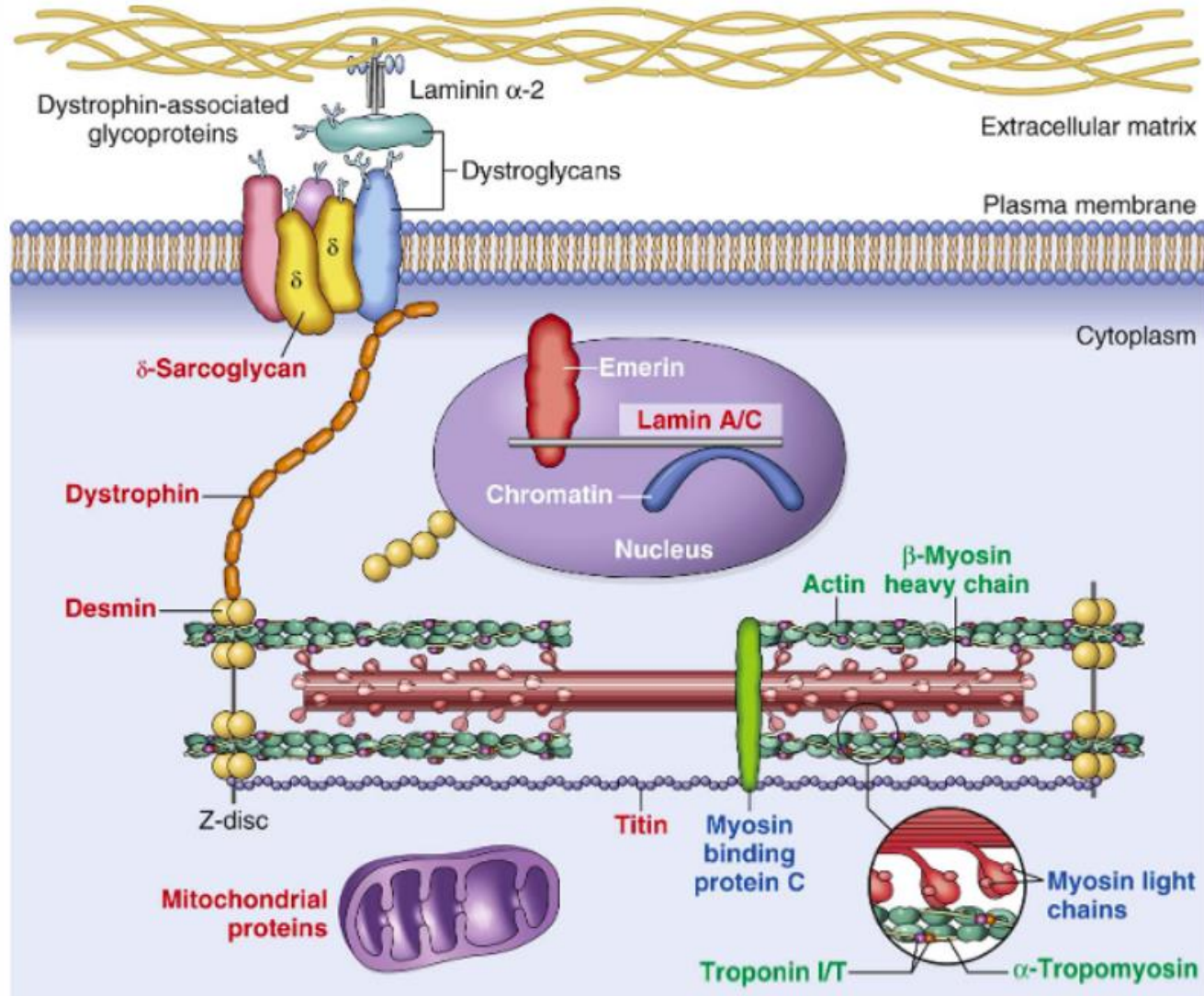


HE and Masson-trichrom stainings

Cardiovascular Pathology, 4 ed

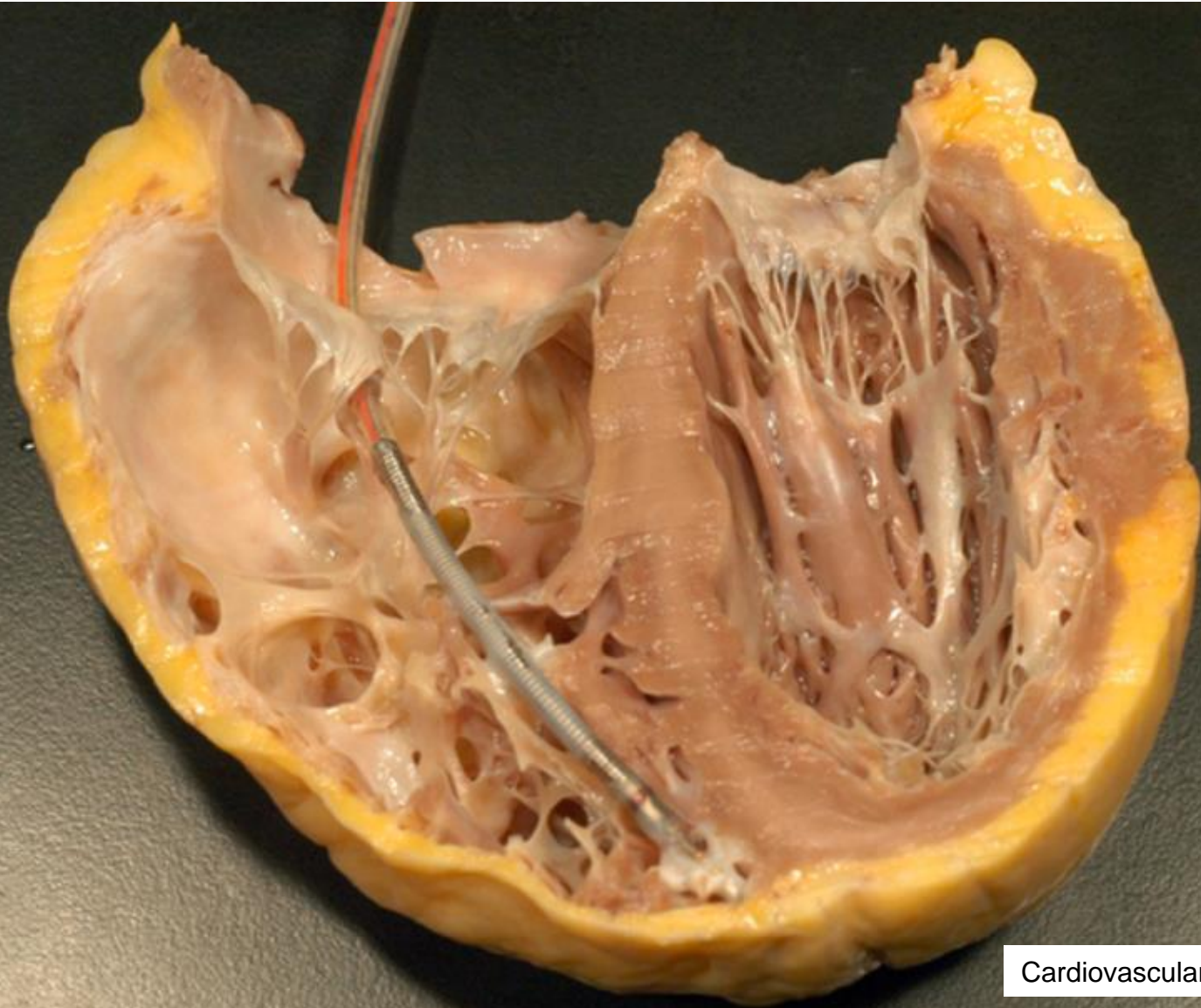


Dilated cardiomyopathy



Robbins and
Cotran
Pathologic Basis
of Disease

Arrhythmogenic cardiomyopathy



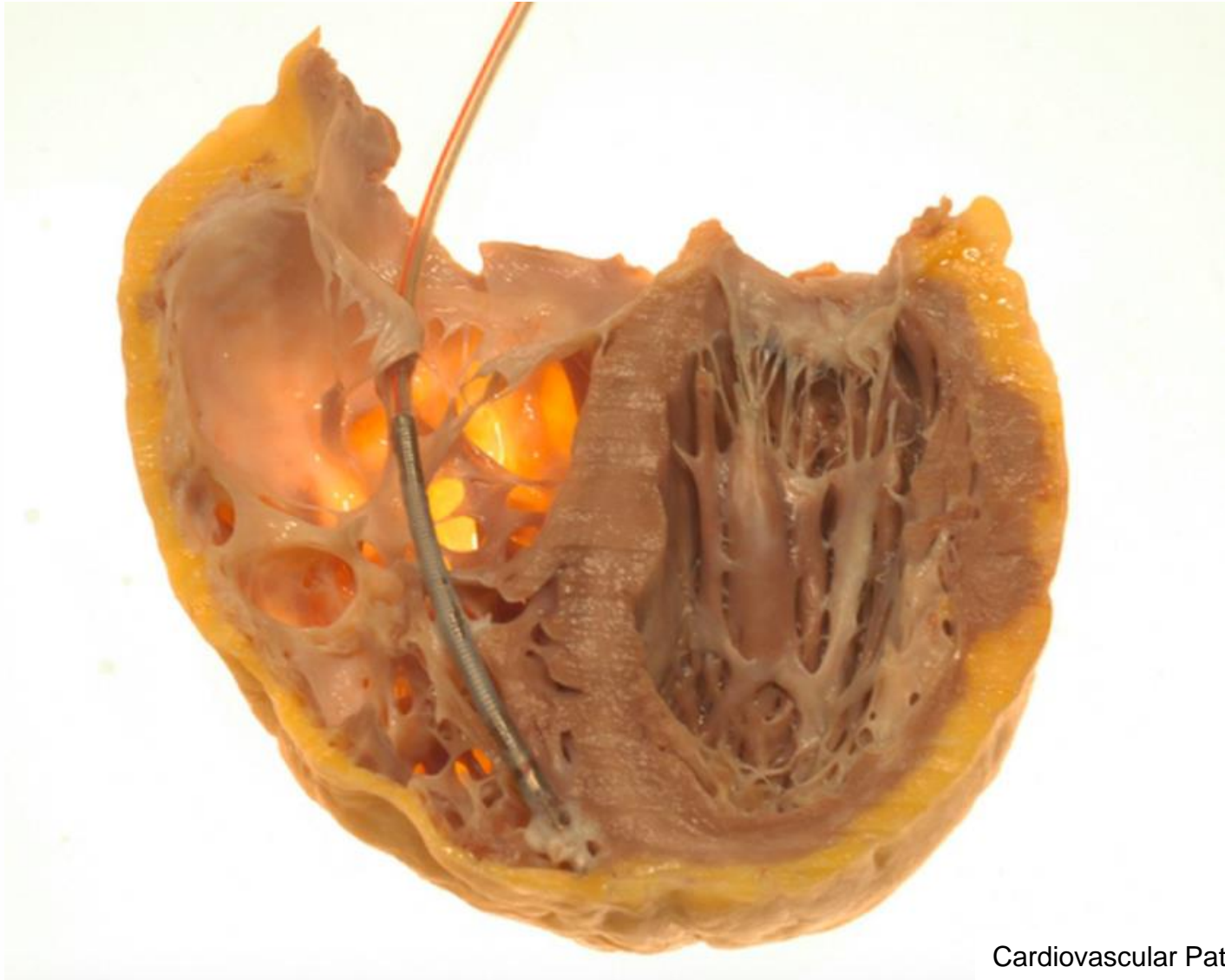
Cardiovascular Pathology, 4 ed



Semmelweis University
<http://semmelweis.hu>

Attila Fintha MD PhD

Arrhythmogenic cardiomyopathy



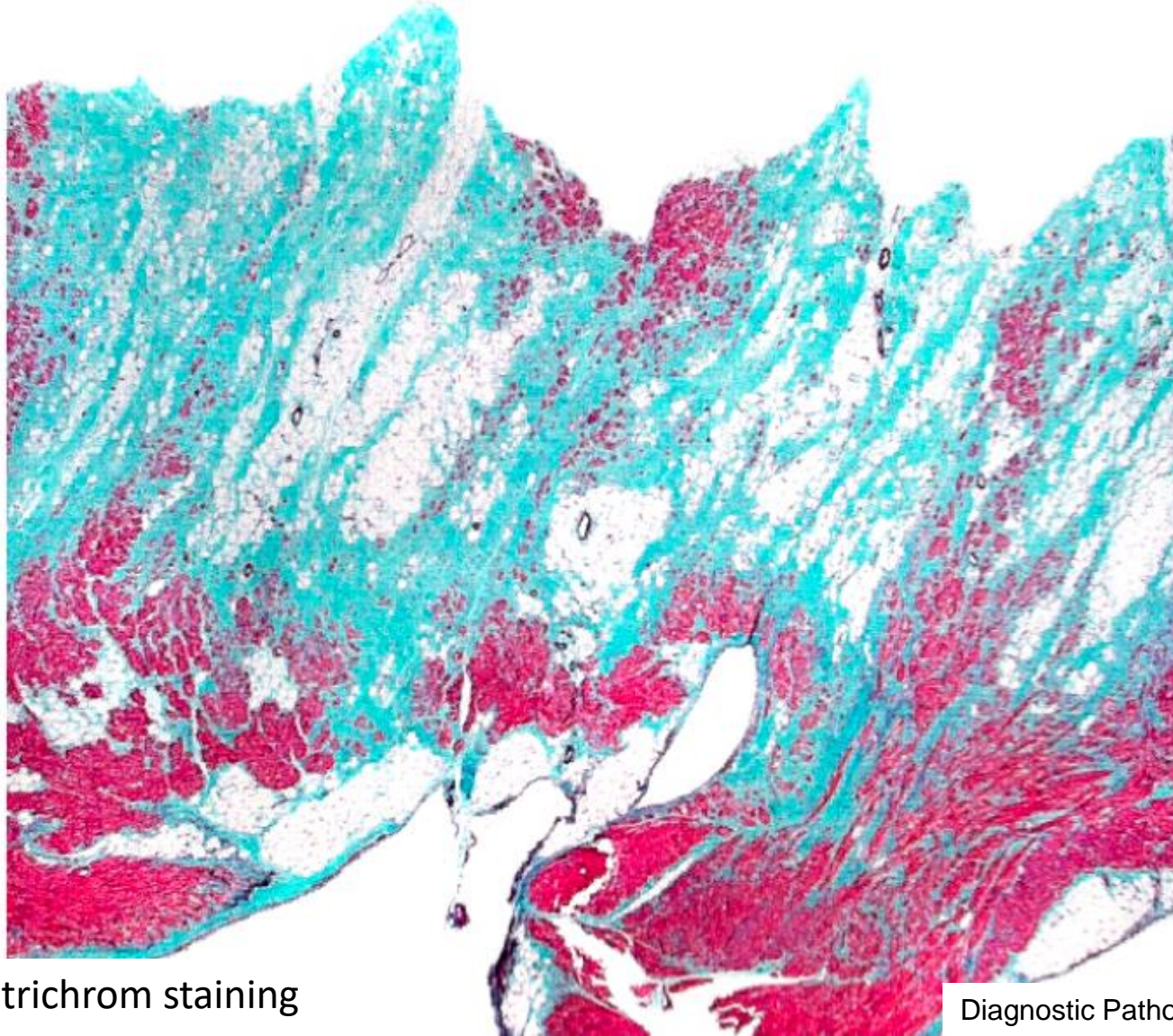
Cardiovascular Pathology, 4 ed



Semmelweis University
<http://semmelweis.hu>

Attila Fintha MD PhD

Arrhythmogenic cardiomyopathy

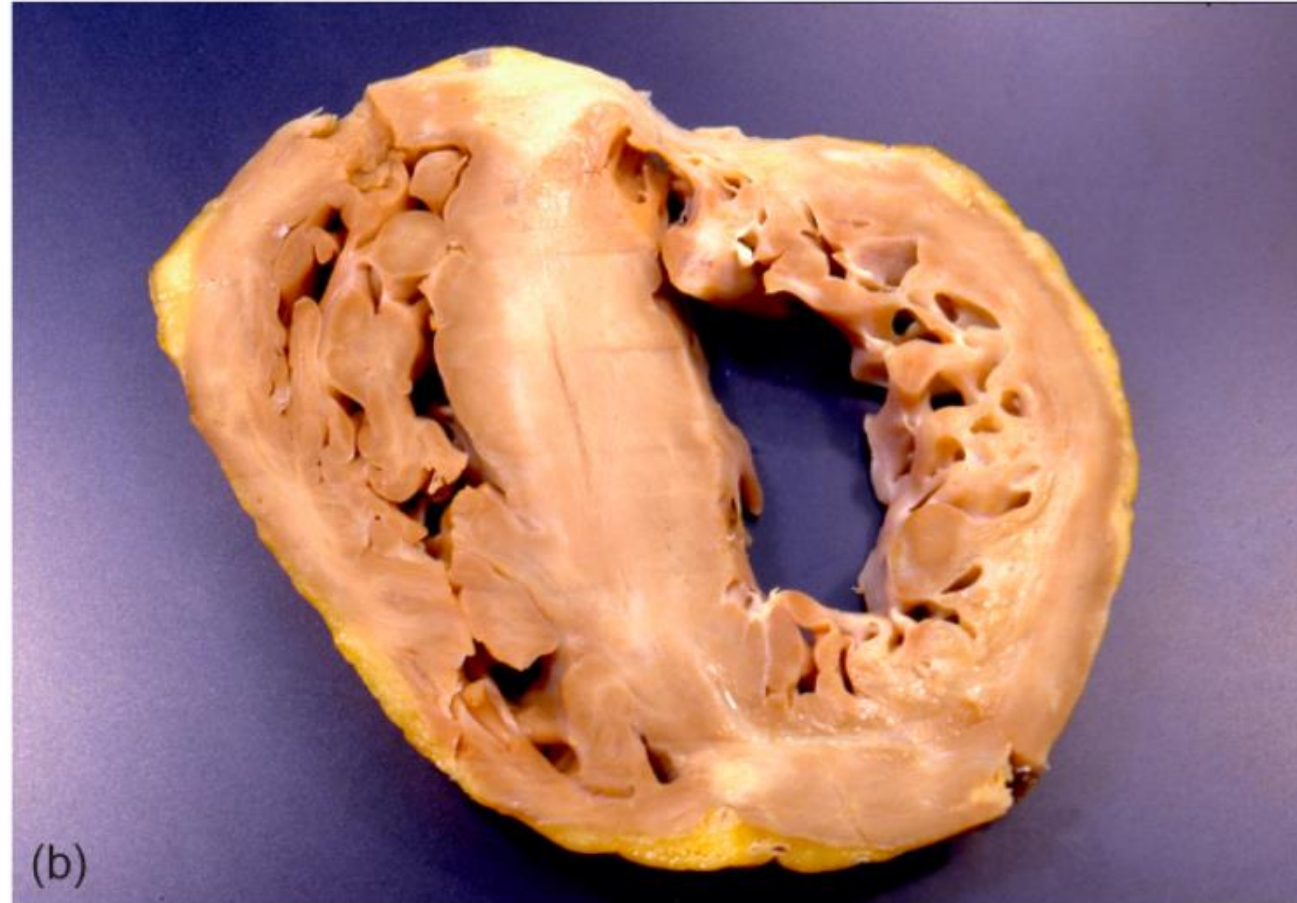
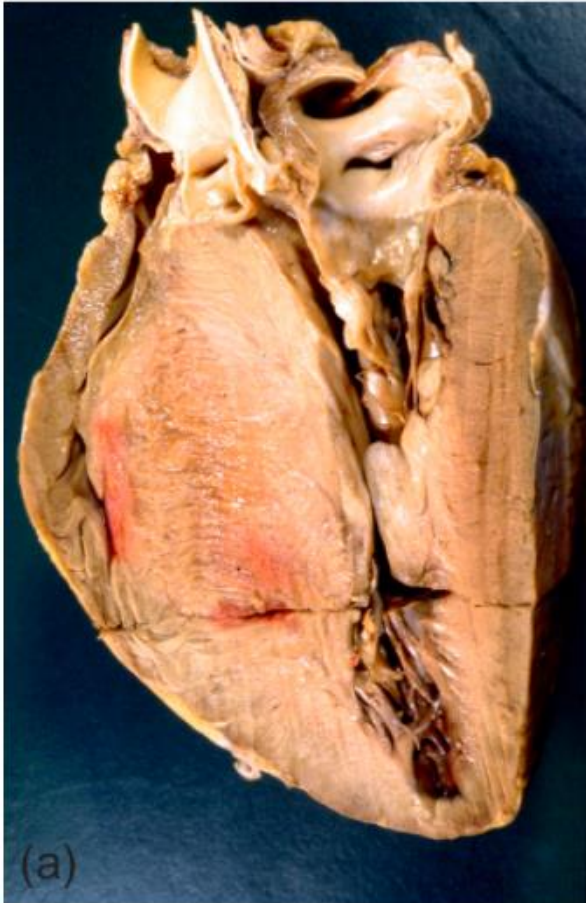

Masson-trichrom staining

Diagnostic Pathology: Cardiovascular



Hypertrophic cardiomyopathy



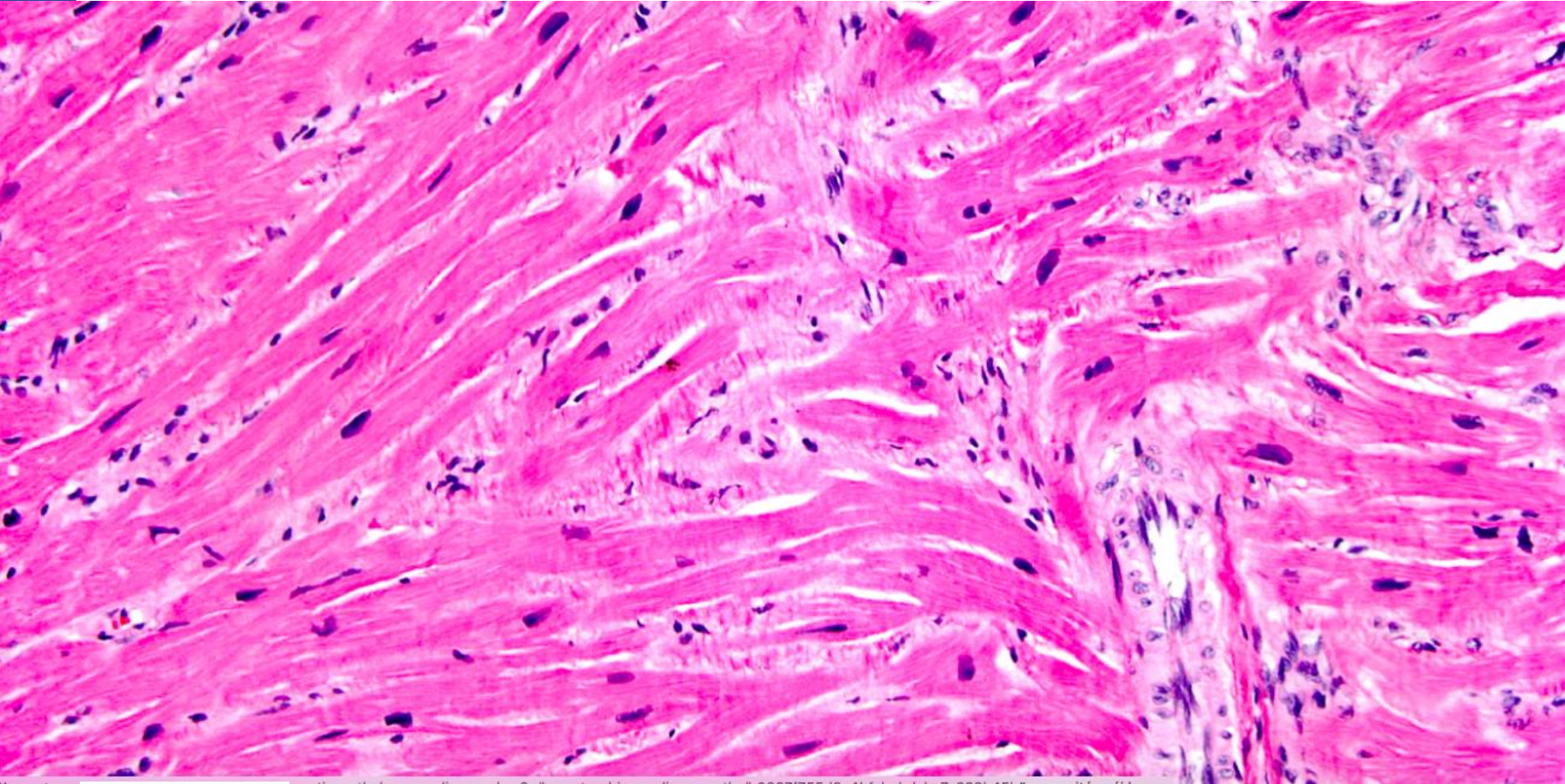
Cardiovascular Pathology, 4 ed



Semmelweis University
<http://semmelweis.hu>

Attila Fintha MD PhD

Hypertrophic cardiomyopathy



HE staining

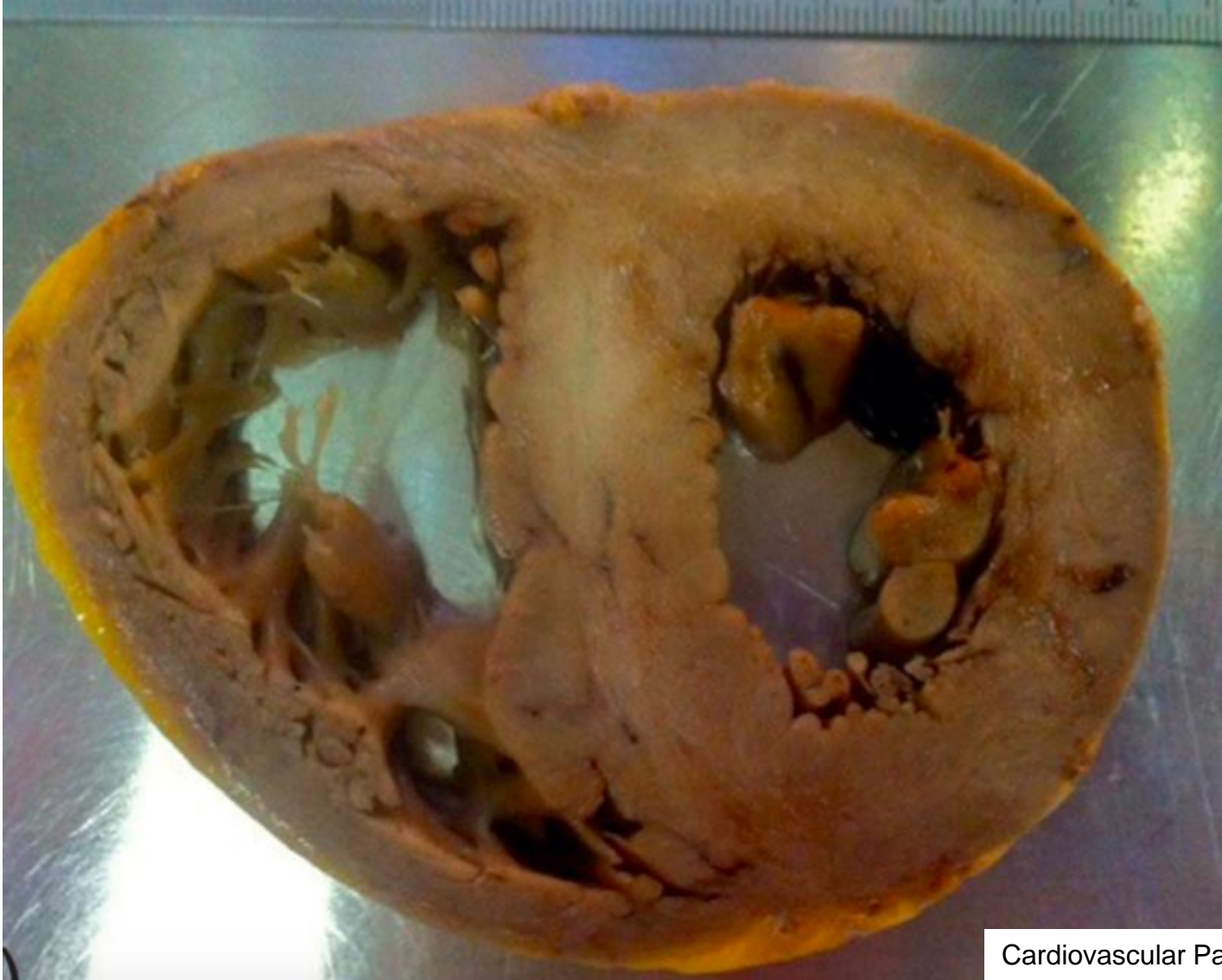Diagnostic Pathology: Cardiovascular



Semmelweis University
<http://semmelweis.hu>

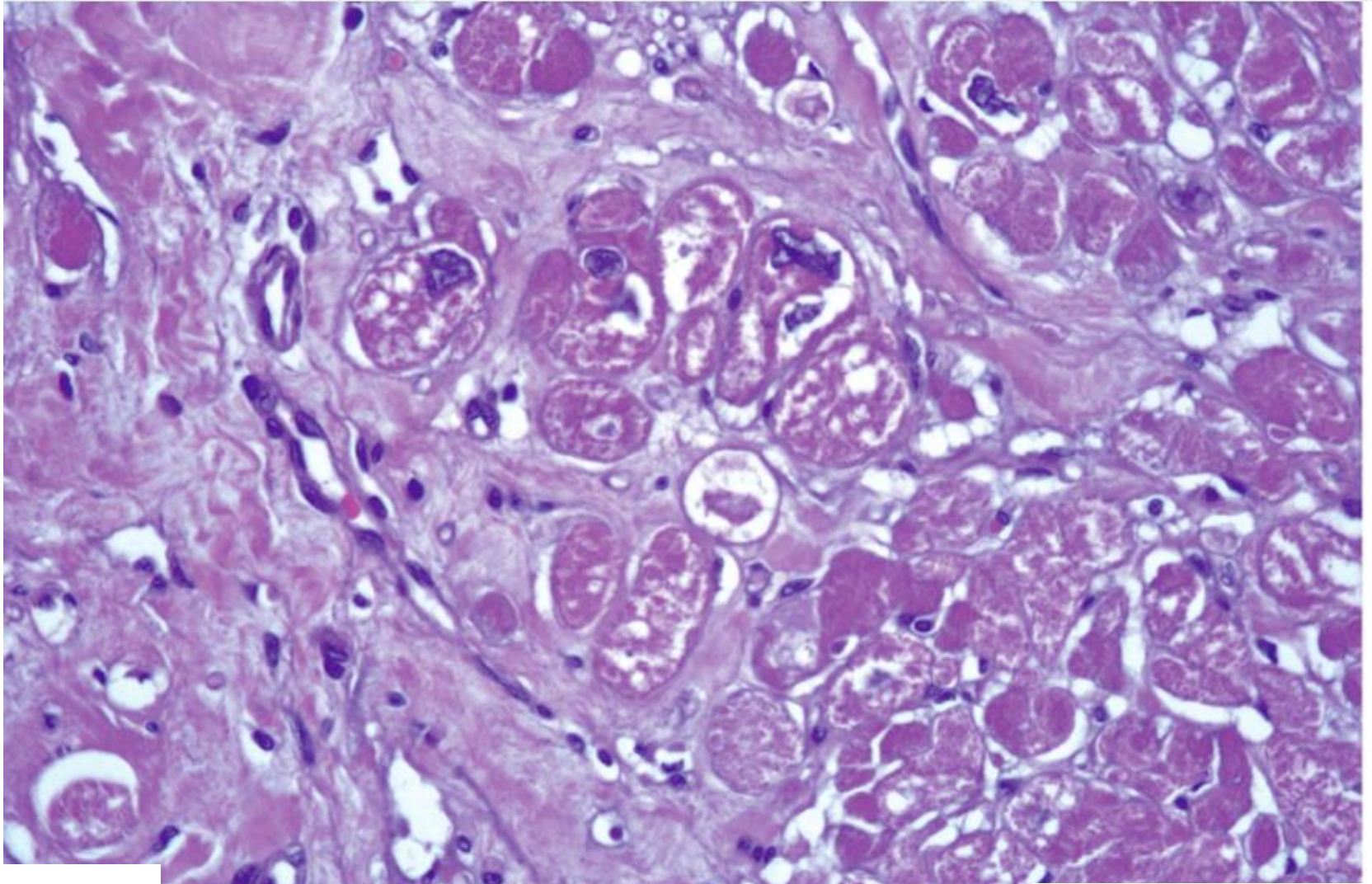
Attila Fintha MD PhD

Restrictive cardiomyopathy



Cardiovascular Pathology, 4 ed

Restrictive cardiomyopathy

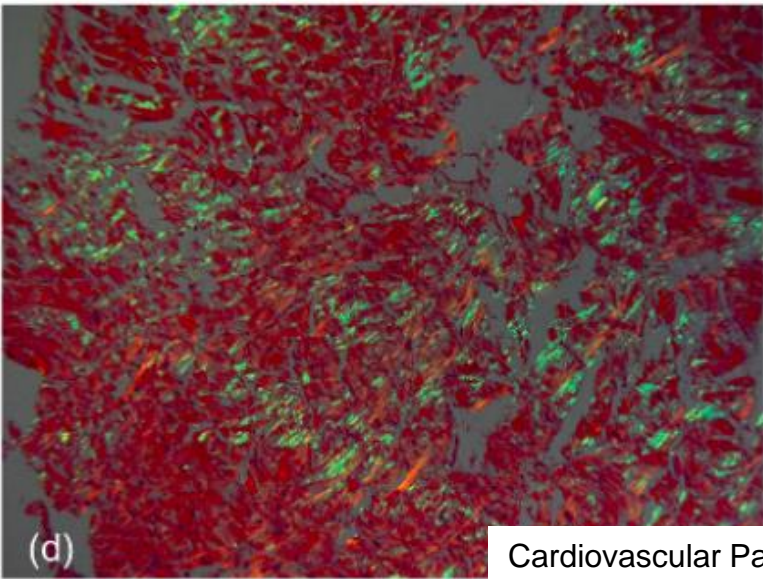
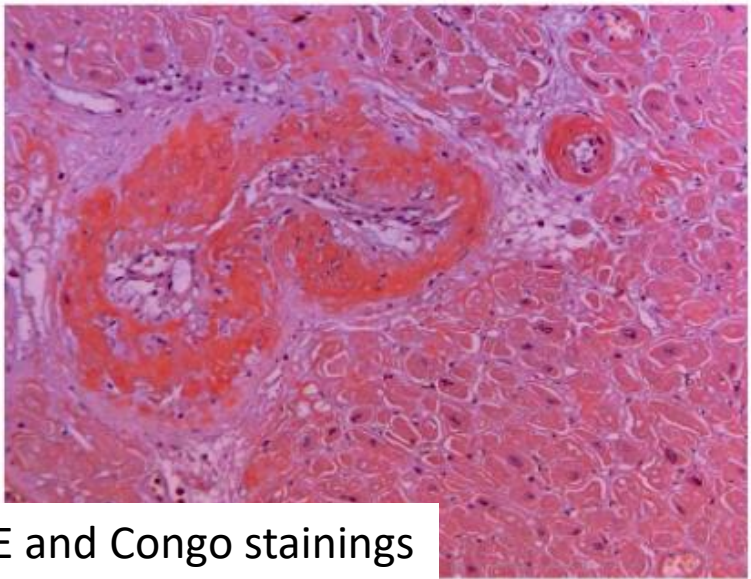
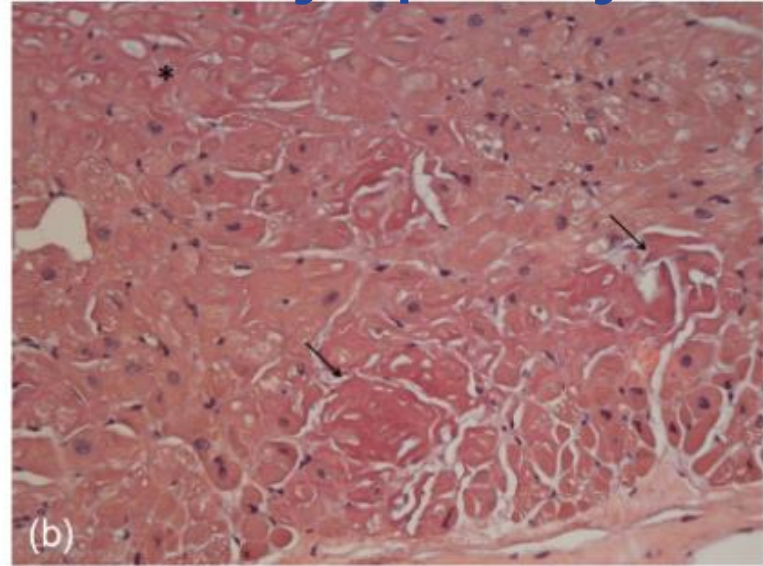
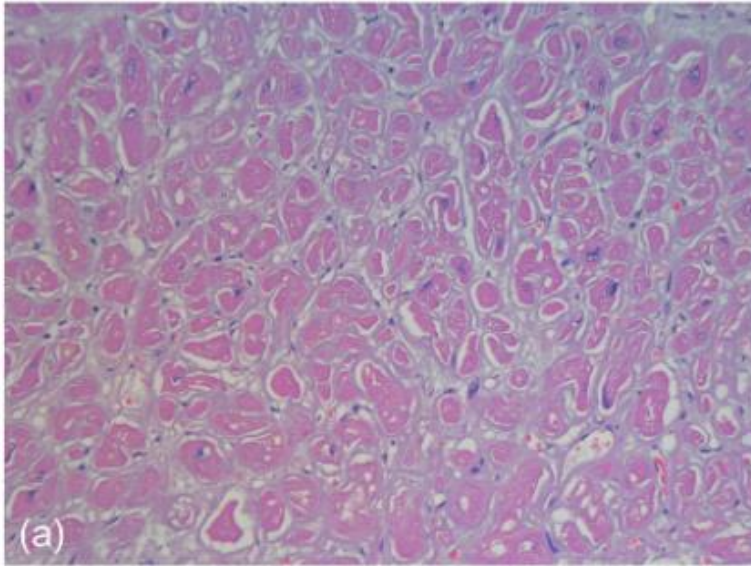


HE staining

Cardiovascular Pathology, 4 ed



Restrictive cardiomyopathy



HE and Congo stainings

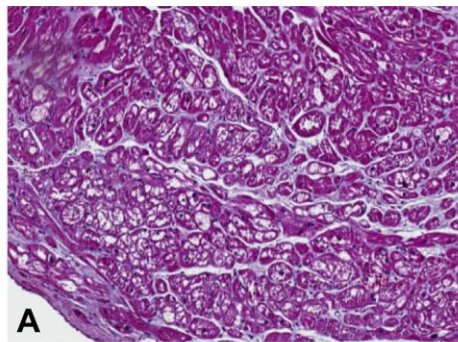
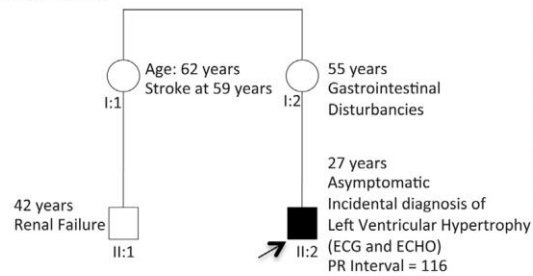
Cardiovascular Pathology, 4 ed



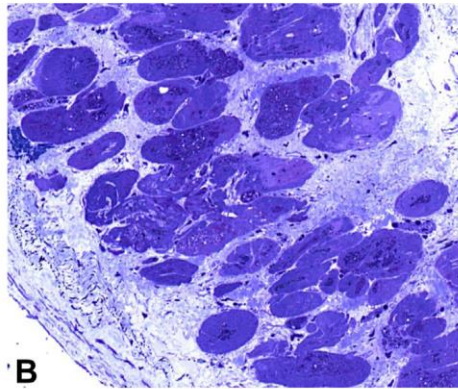
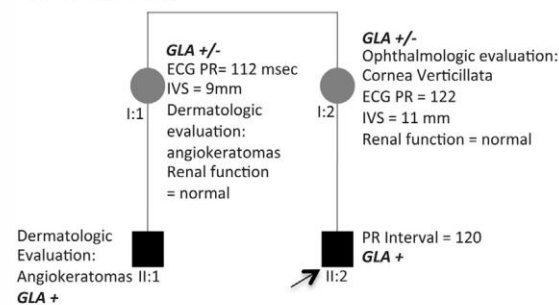
Diagnosis of cardiomyopathies

Morphofunctional Organ Genetic or familial Etiology Heart Failure Stage

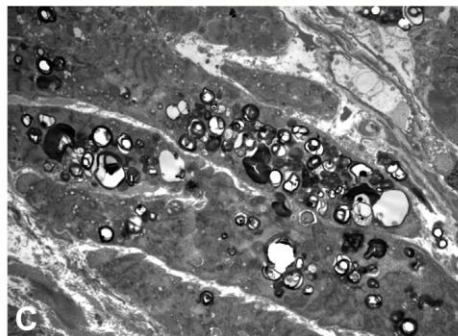
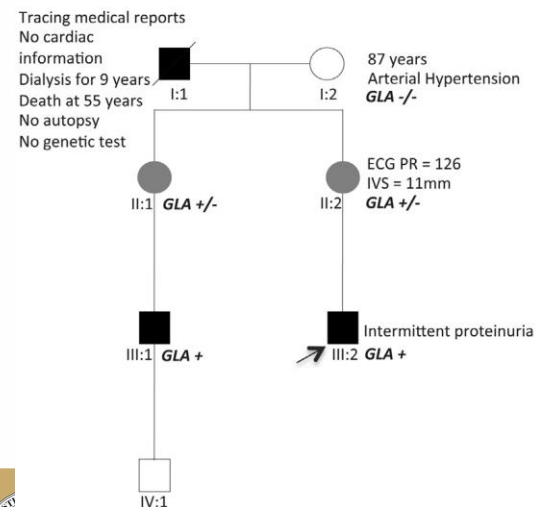
Family History



Family Screening



Extension of information and tests in family



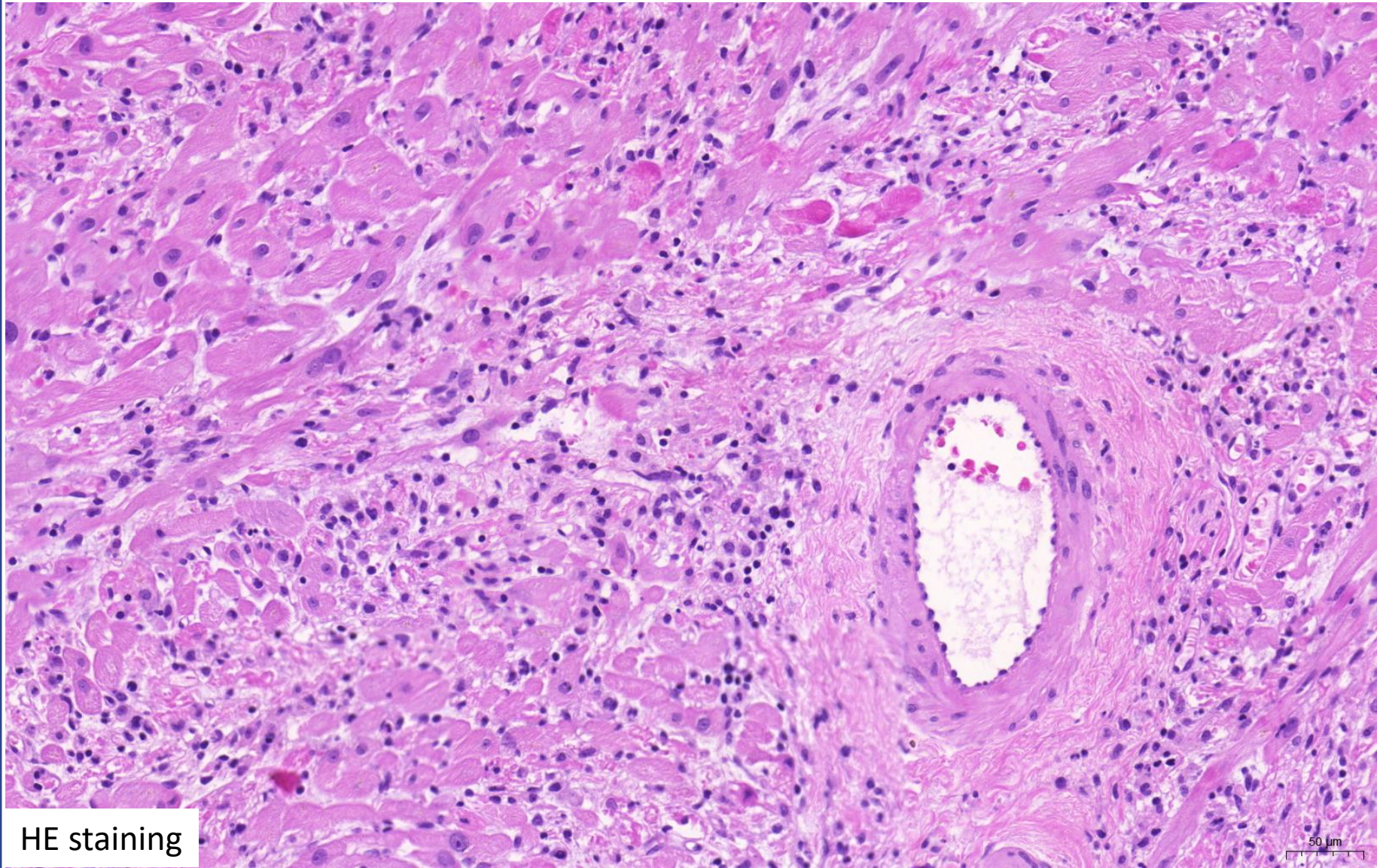
Pedigree	M O G E
I:1	M _{NA[H]} O _K G _{OC} E ₀
I:2	M ₀ O ₀ G ₀ E _{G-GLA-/-}
II:1	M _{H[βPR]} O _{H+N+C} G _{X-L} E _{G-GLA+/-}
II:2	M _H O _{E+G} G _{X-L} E _{G-GLA+/-}
III:1	M _H O _{K+C} G _{X-L} E _{G-GLA+}
III:2	M _H O _K G _{X-L} E _{G-GLA+}
IV:1	M ₀ O ₀ G _{ONC} E ₀

JACC Vol. 62, No. 22, 2013

Attila Fintha MD PhD

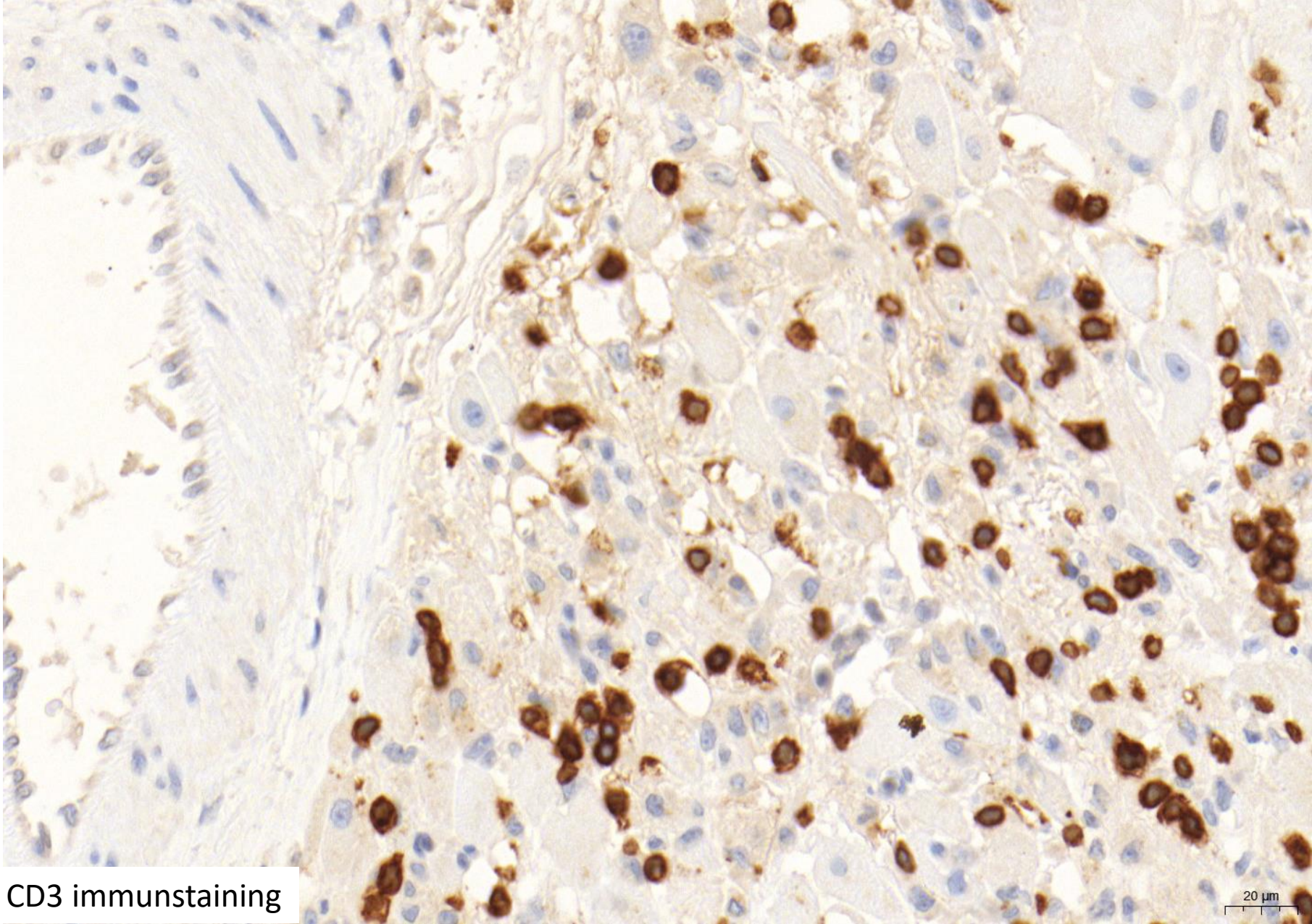


Myocarditis

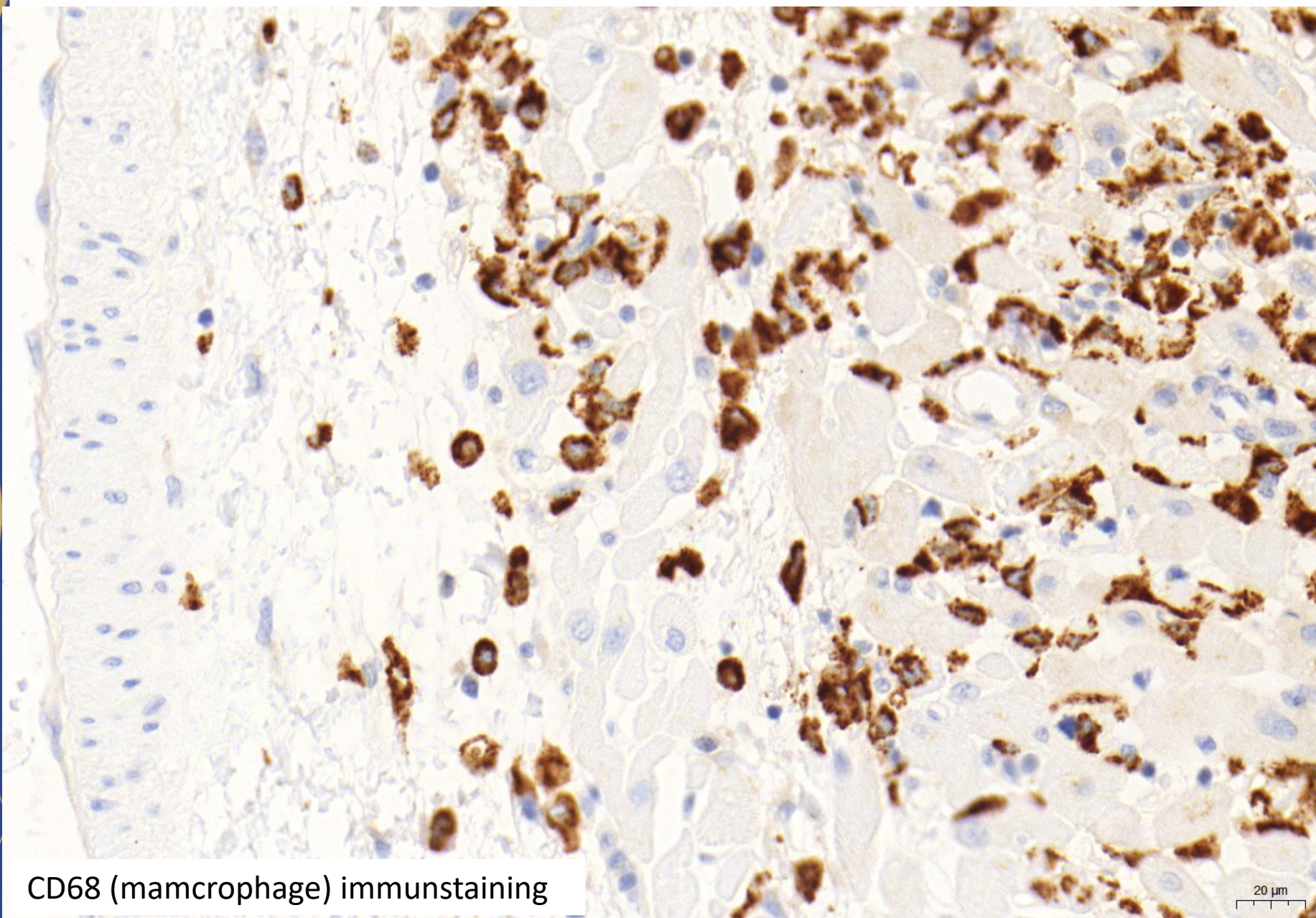


HE staining





CD3 immunostaining

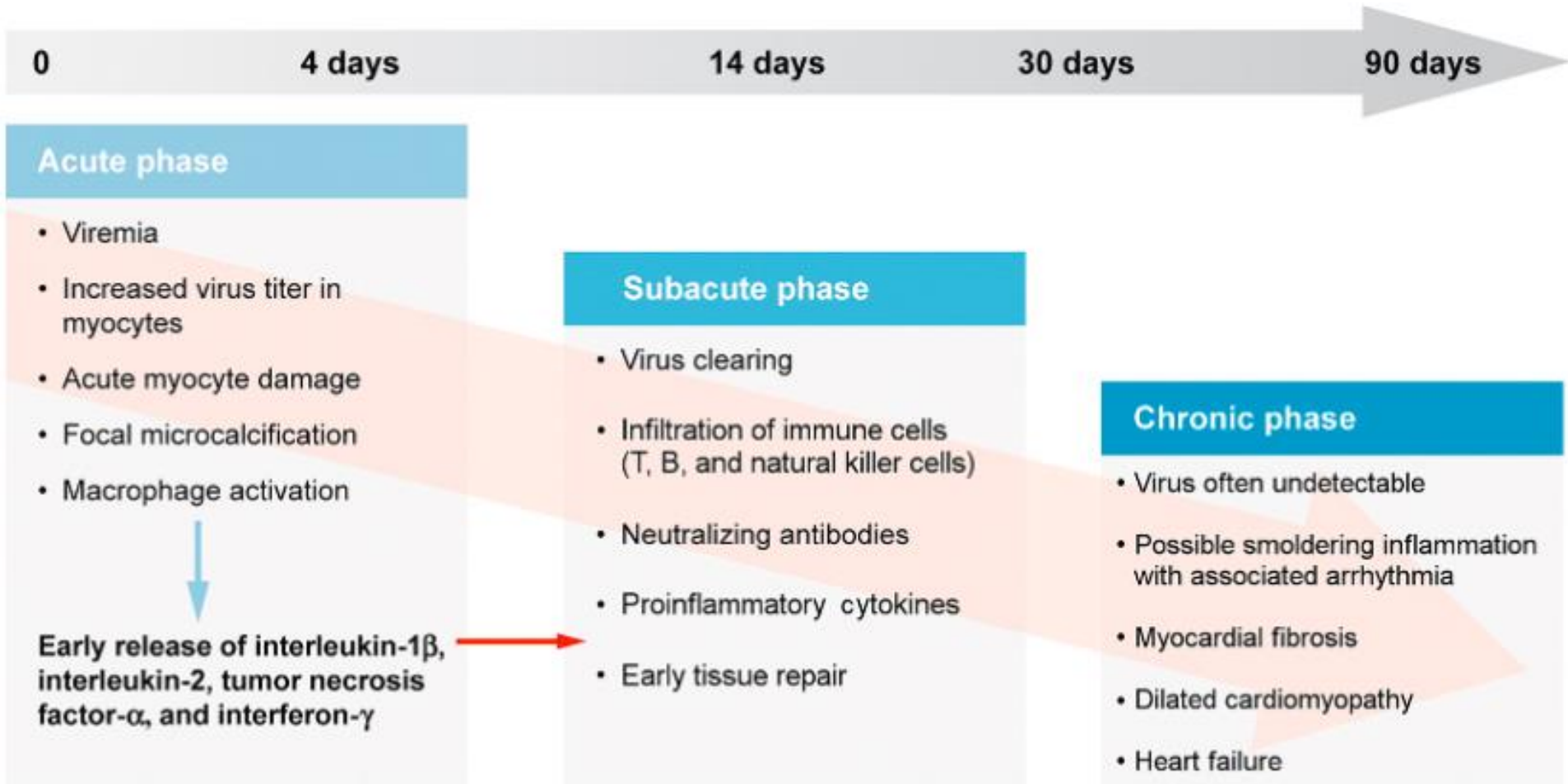


CD68 (macrophage) immunostaining

20 μ m



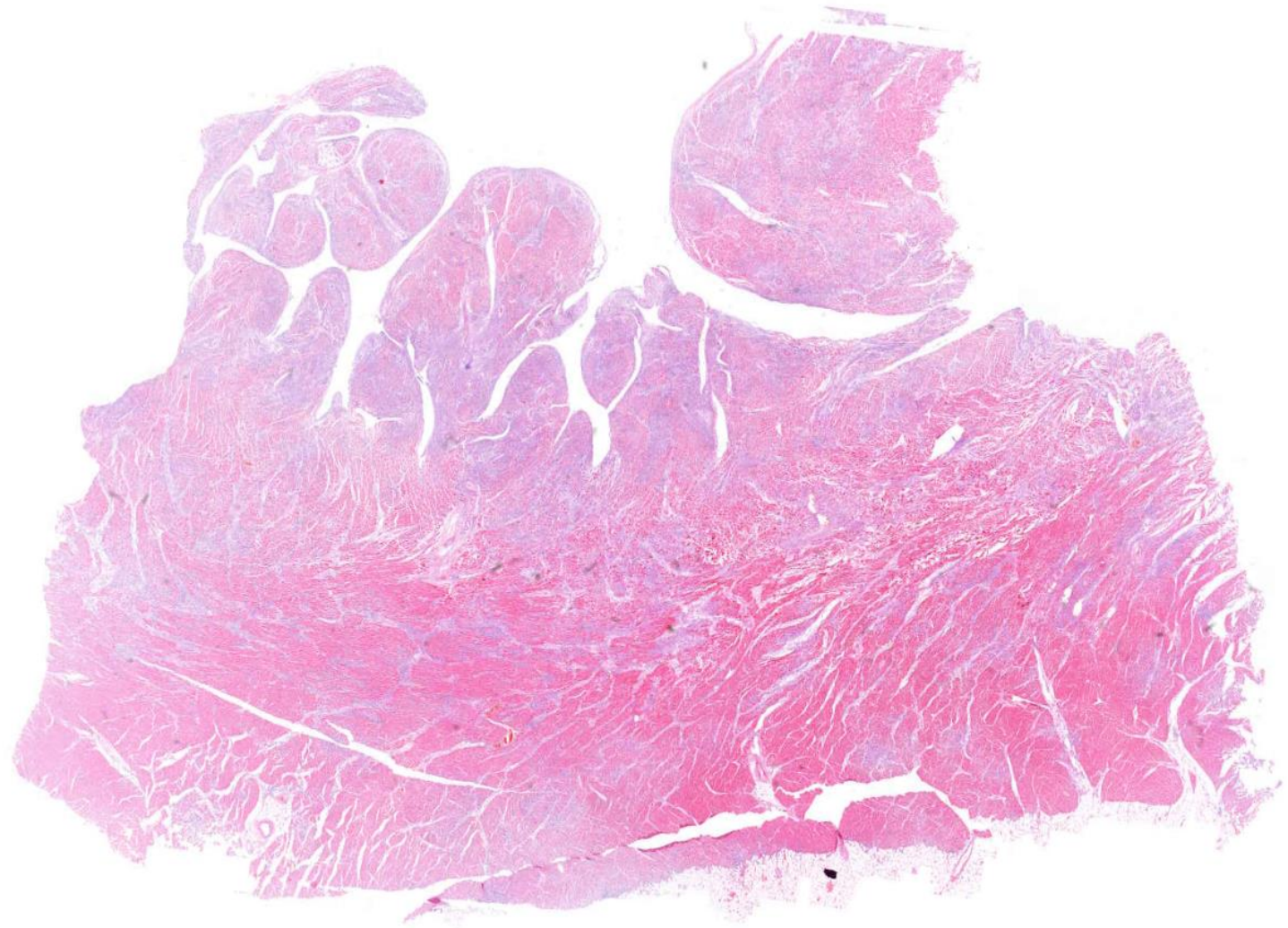
Myocarditis



Cardiovascular Pathology, 4 ed



Myocarditis



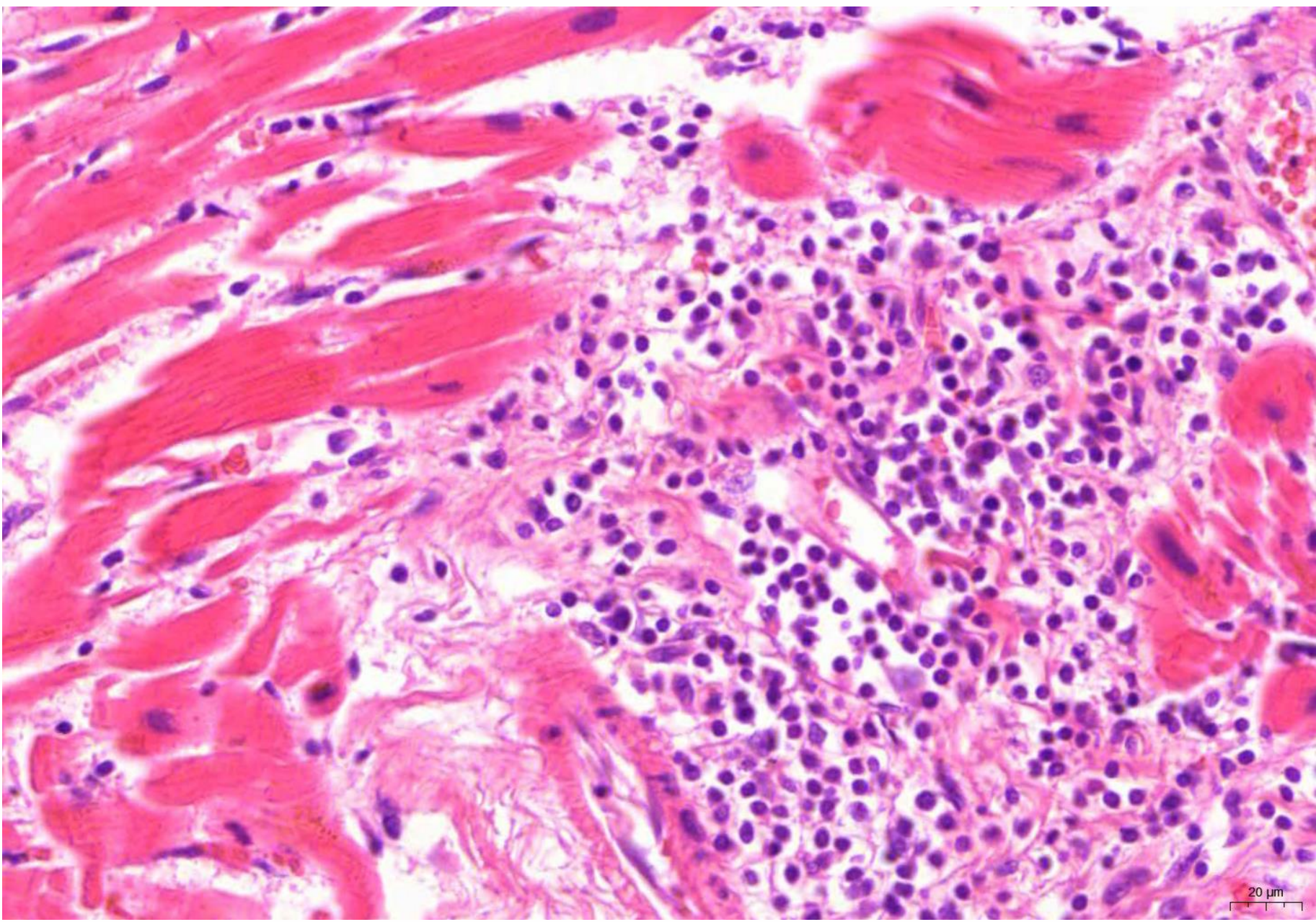
HE staining

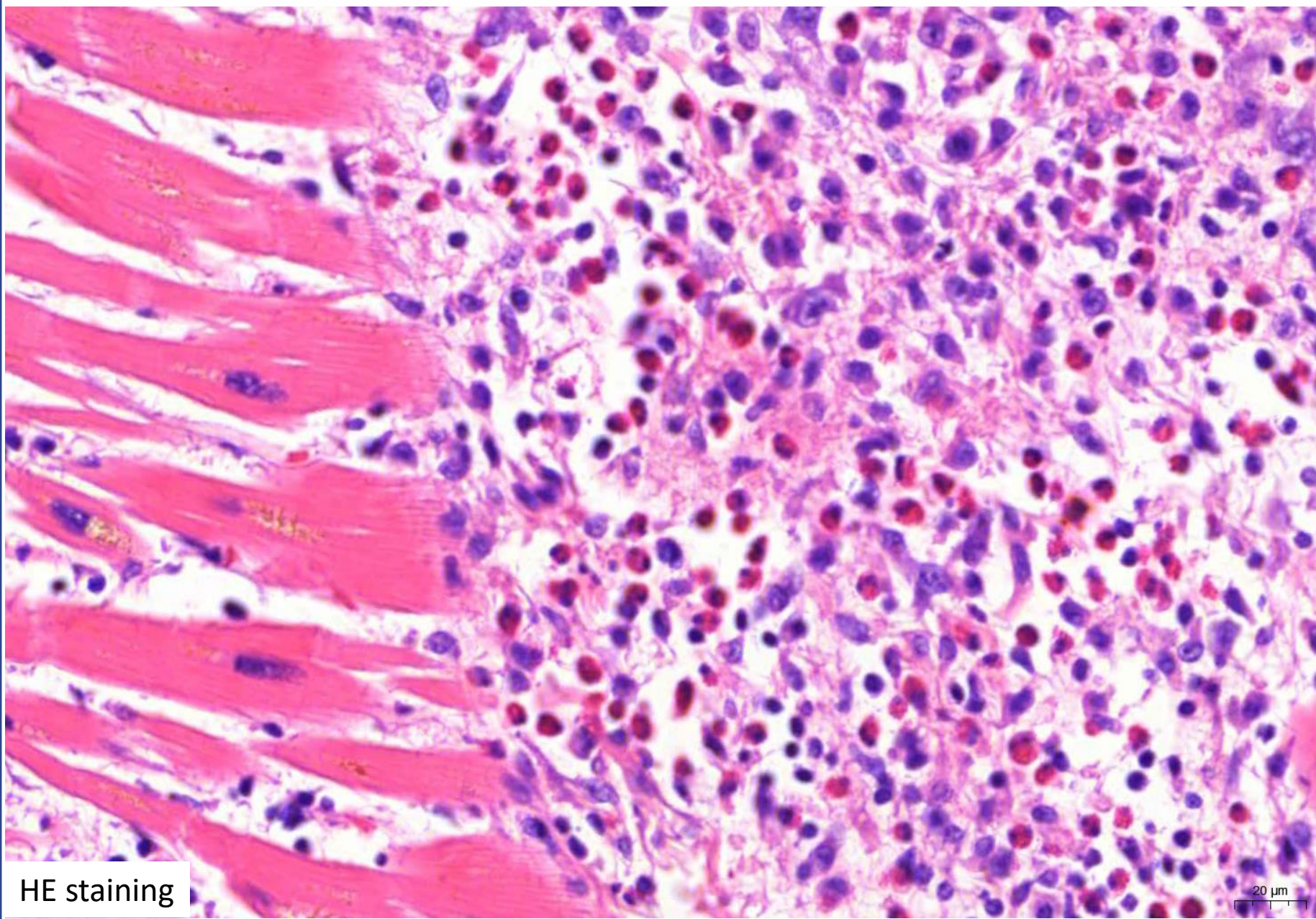
5000 μm



Semmelweis University
<http://semmelweis.hu>

Attila Fintha MD PhD





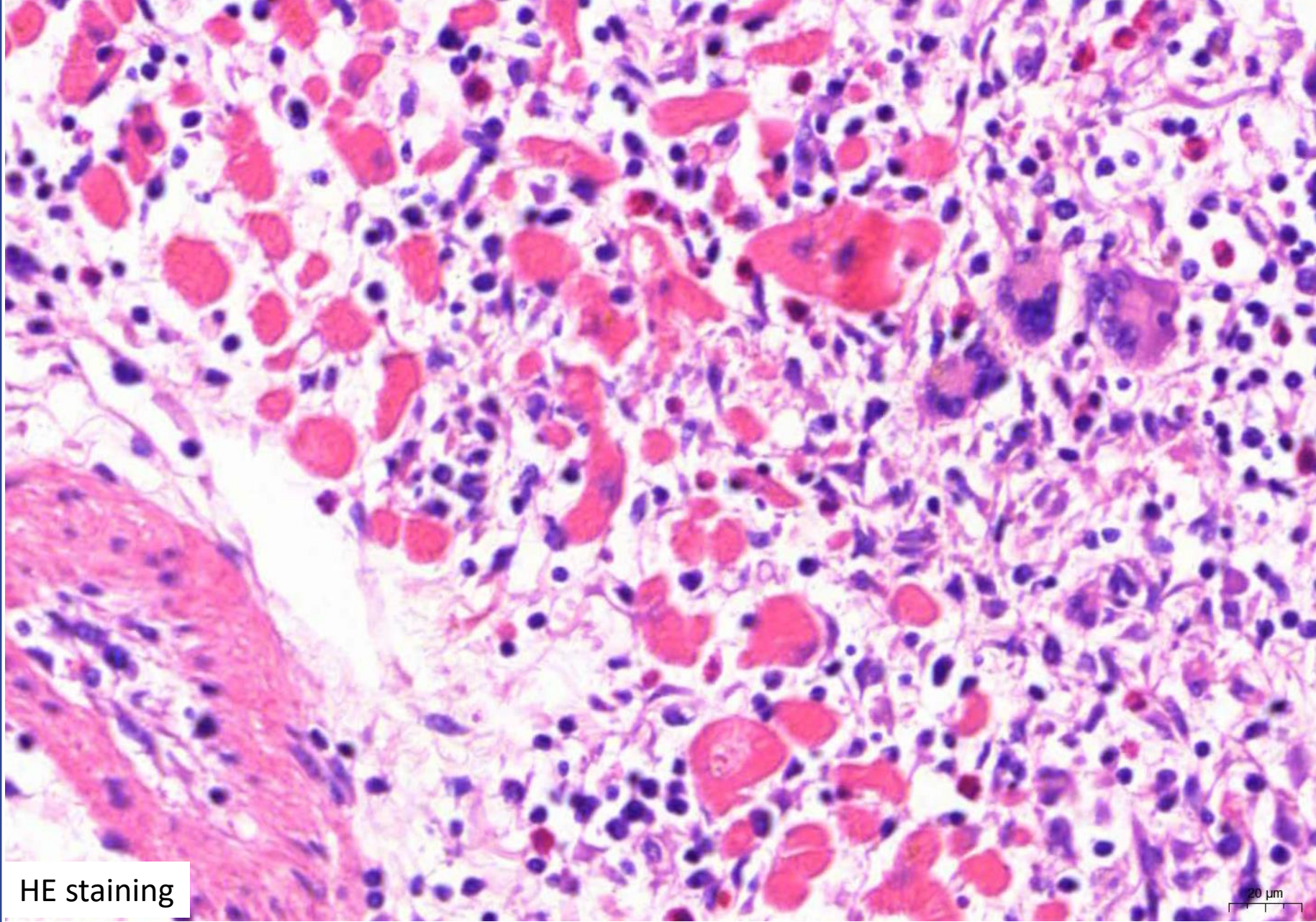
HE staining

20 μ m



Semmelweis University
<http://semmelweis.hu>

Attila Fintha MD PhD



HE staining

20 μ m



Diagnosis of myocarditis

Cardiology

Radiology (US, MR)

Pathology (EMB)

Laboratory medicine

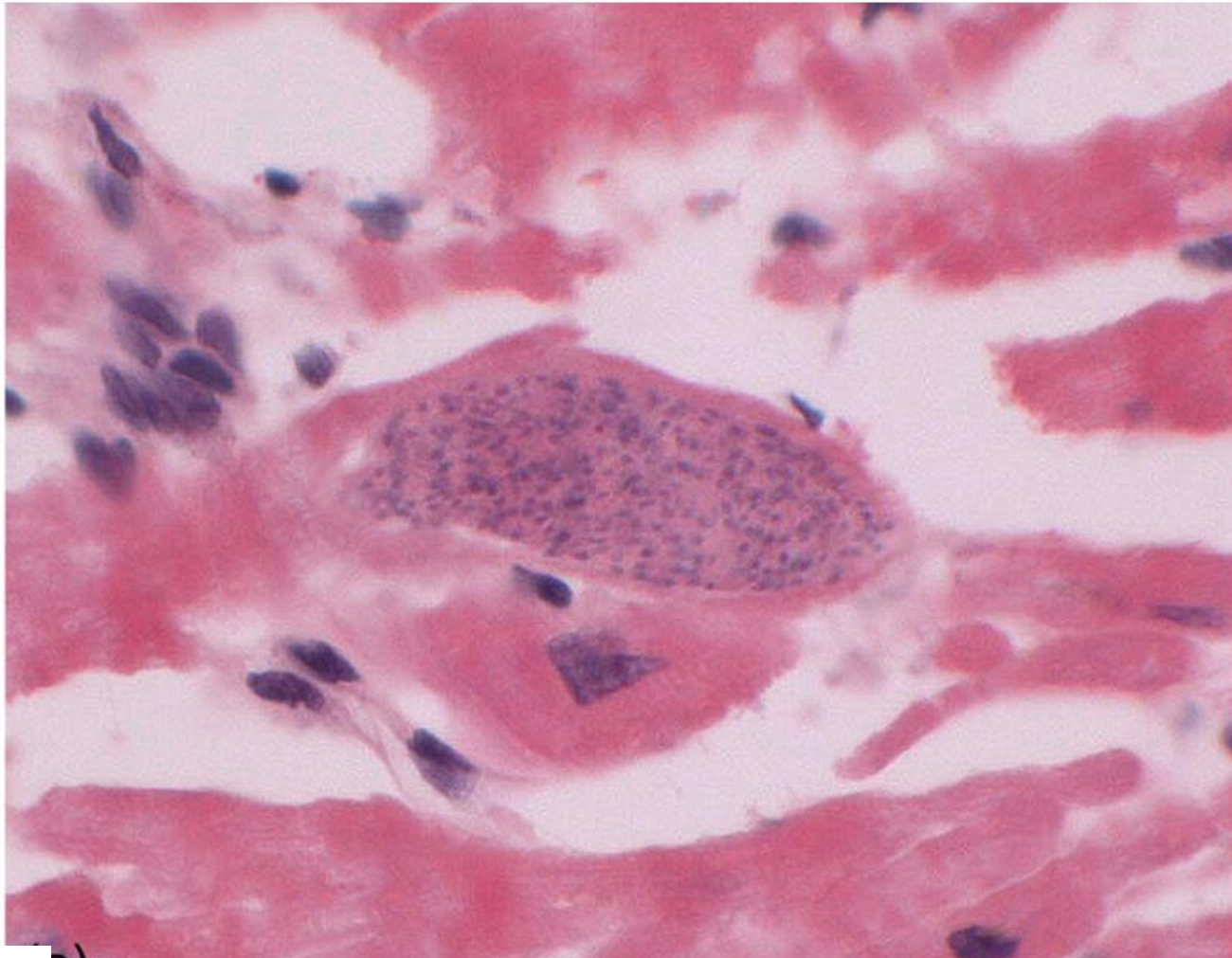
Microbiology

Virology

Genetic consultation



Toxoplasma myocarditis



HE staining

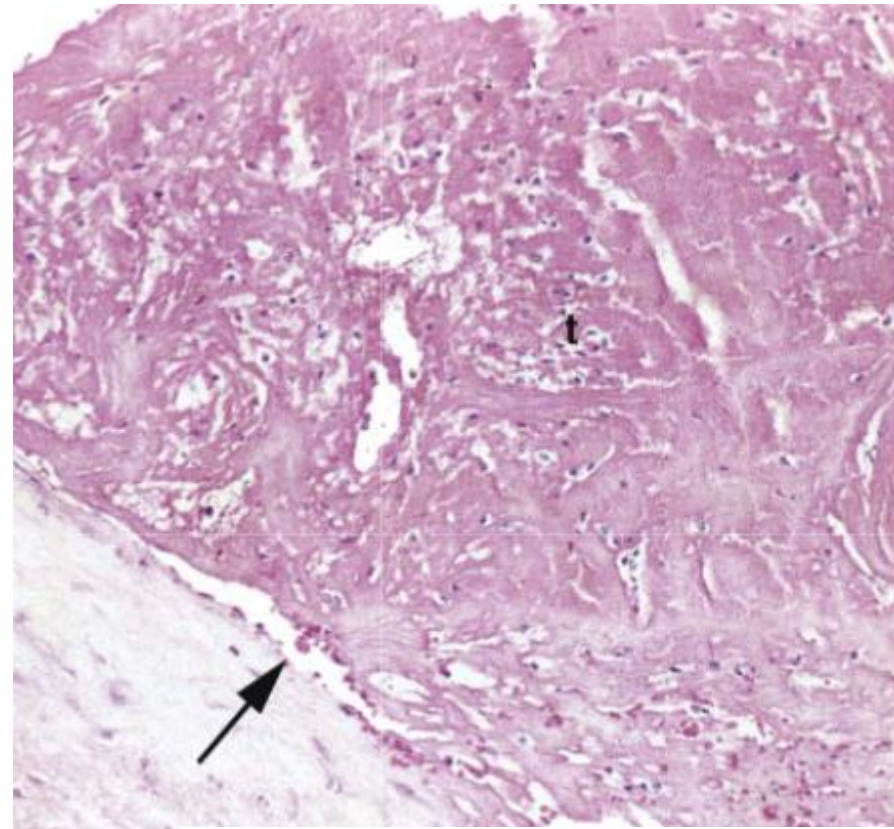
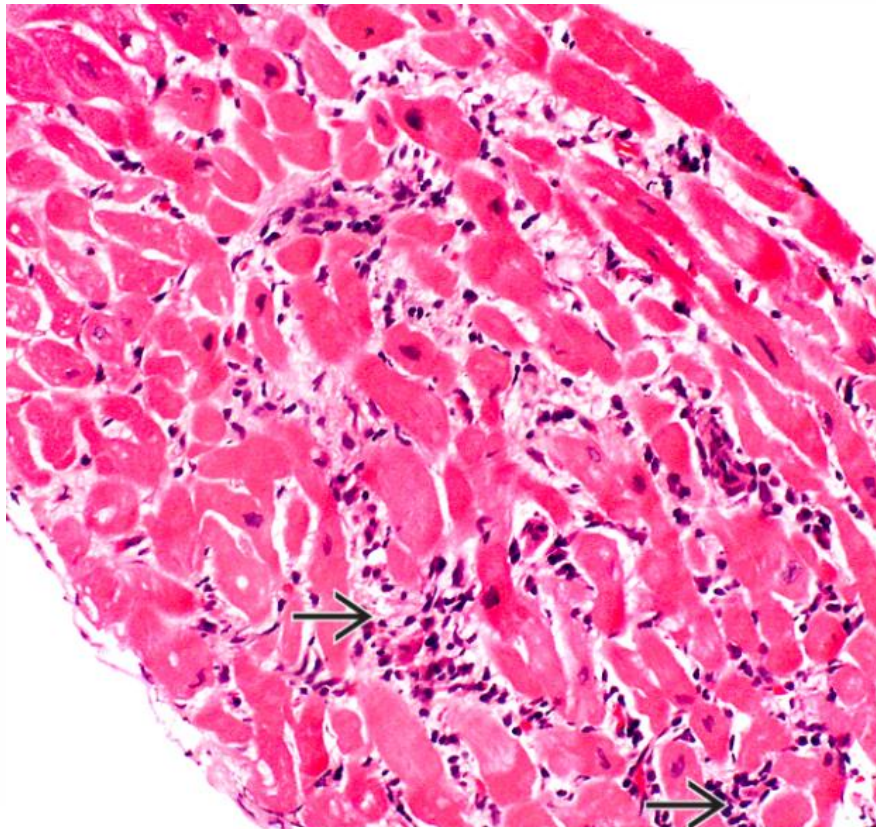
Cardiovascular Pathology, 4 ed



Semmelweis University
<http://semmelweis.hu>

Attila Fintha MD PhD

Autoimmune disease (SLE) (Libman-Sacks endocarditis)



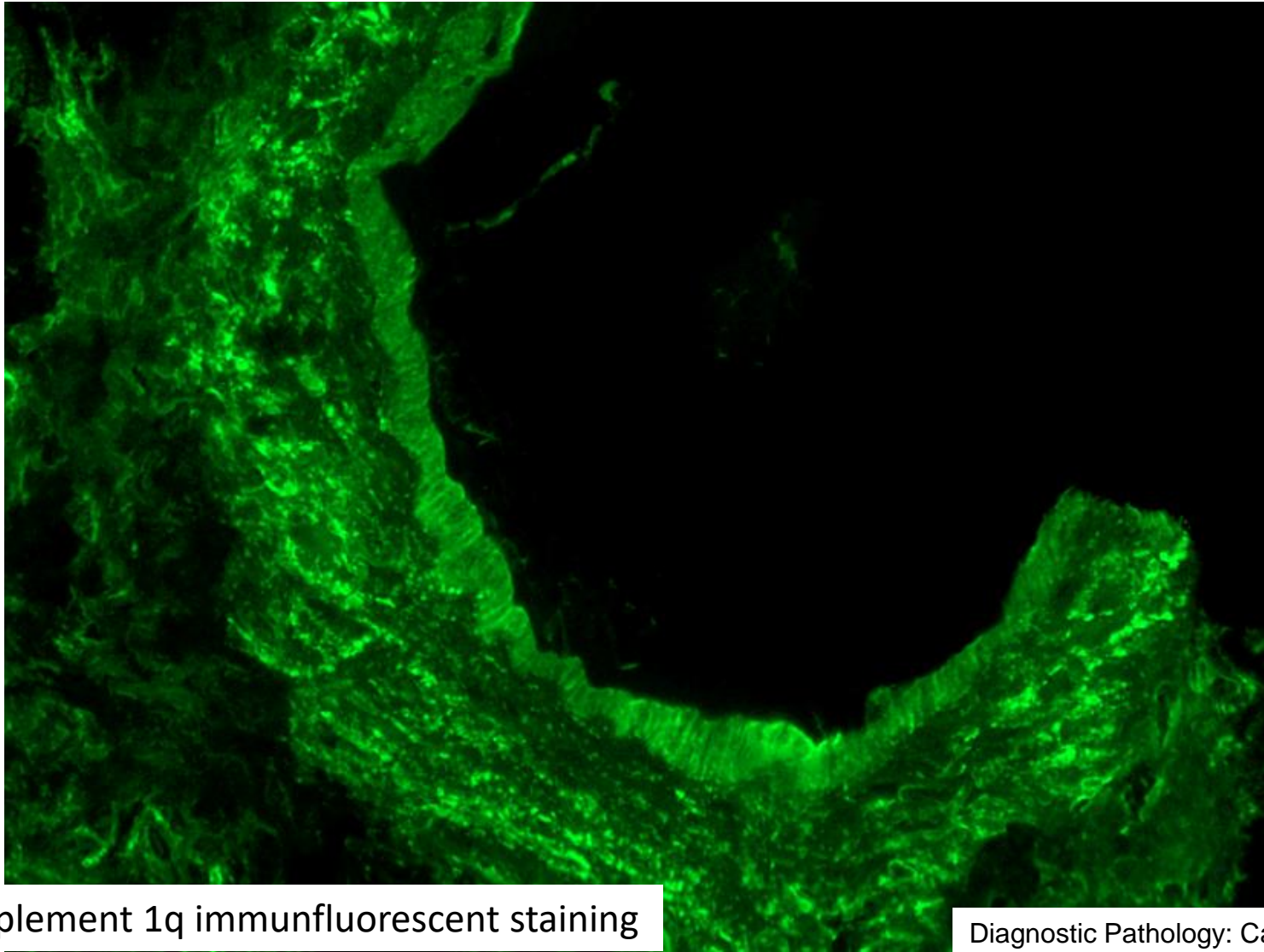HE staining

Diagnostic Pathology: Cardiovascular

Robbins and Cotran Pathologic Basis of Disease



Autoimmune disease (SLE)

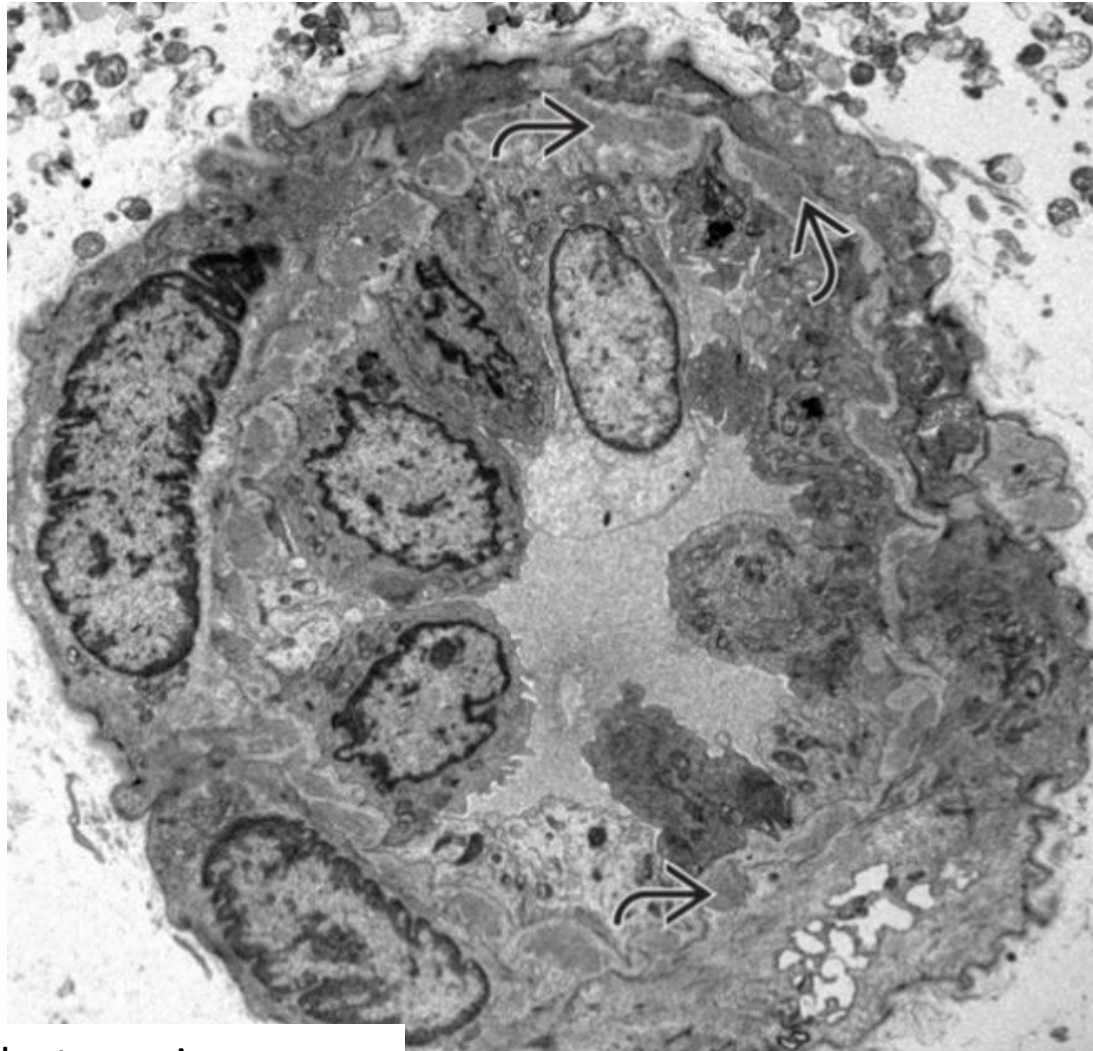


Complement 1q immunofluorescent staining

Diagnostic Pathology: Cardiovascular



Autoimmune disease (SLE)



Transmission electronmicroscopy

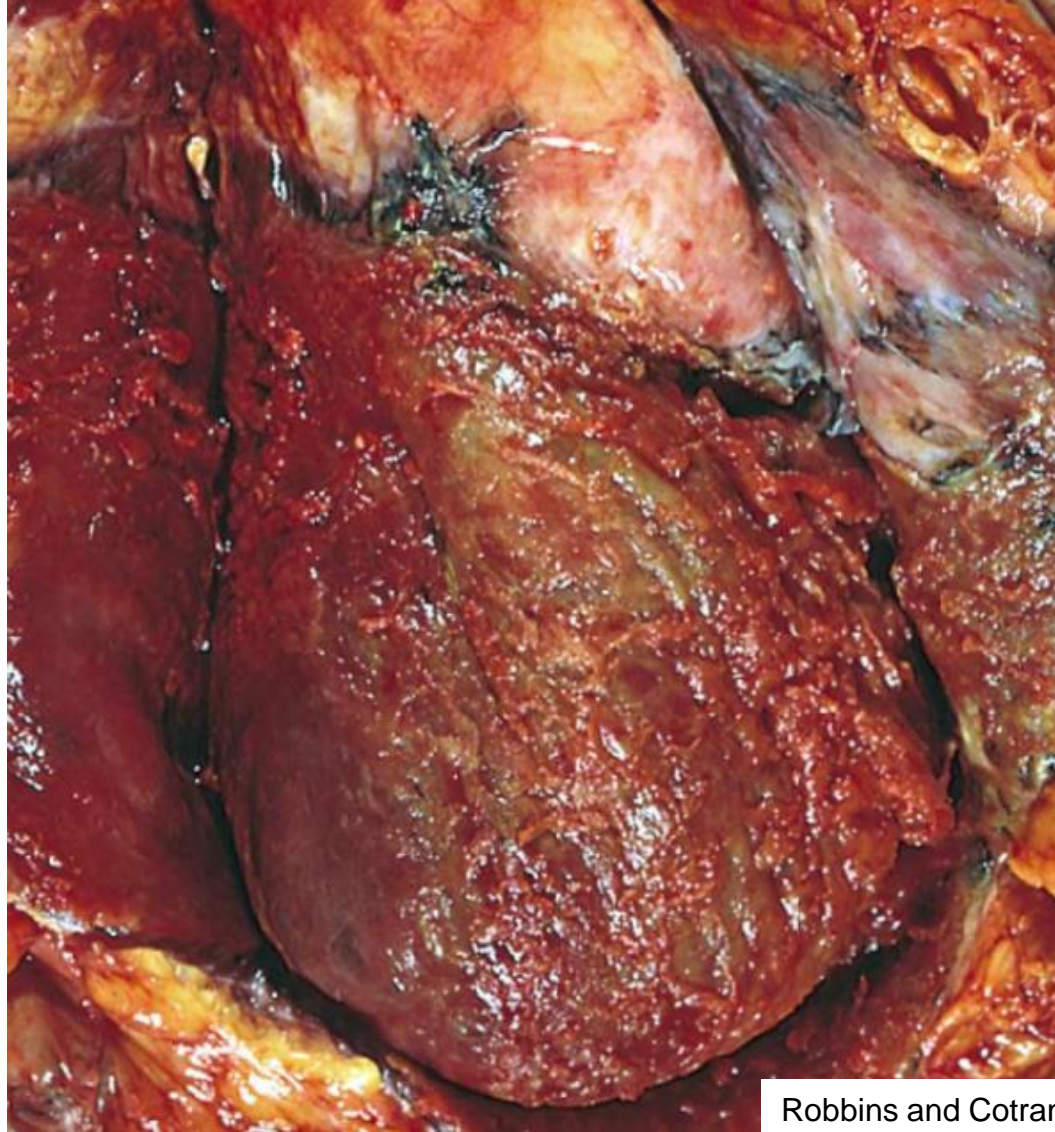
Diagnostic Pathology: Cardiovascular



Semmelweis University
<http://semmelweis.hu>

Attila Fintha MD PhD

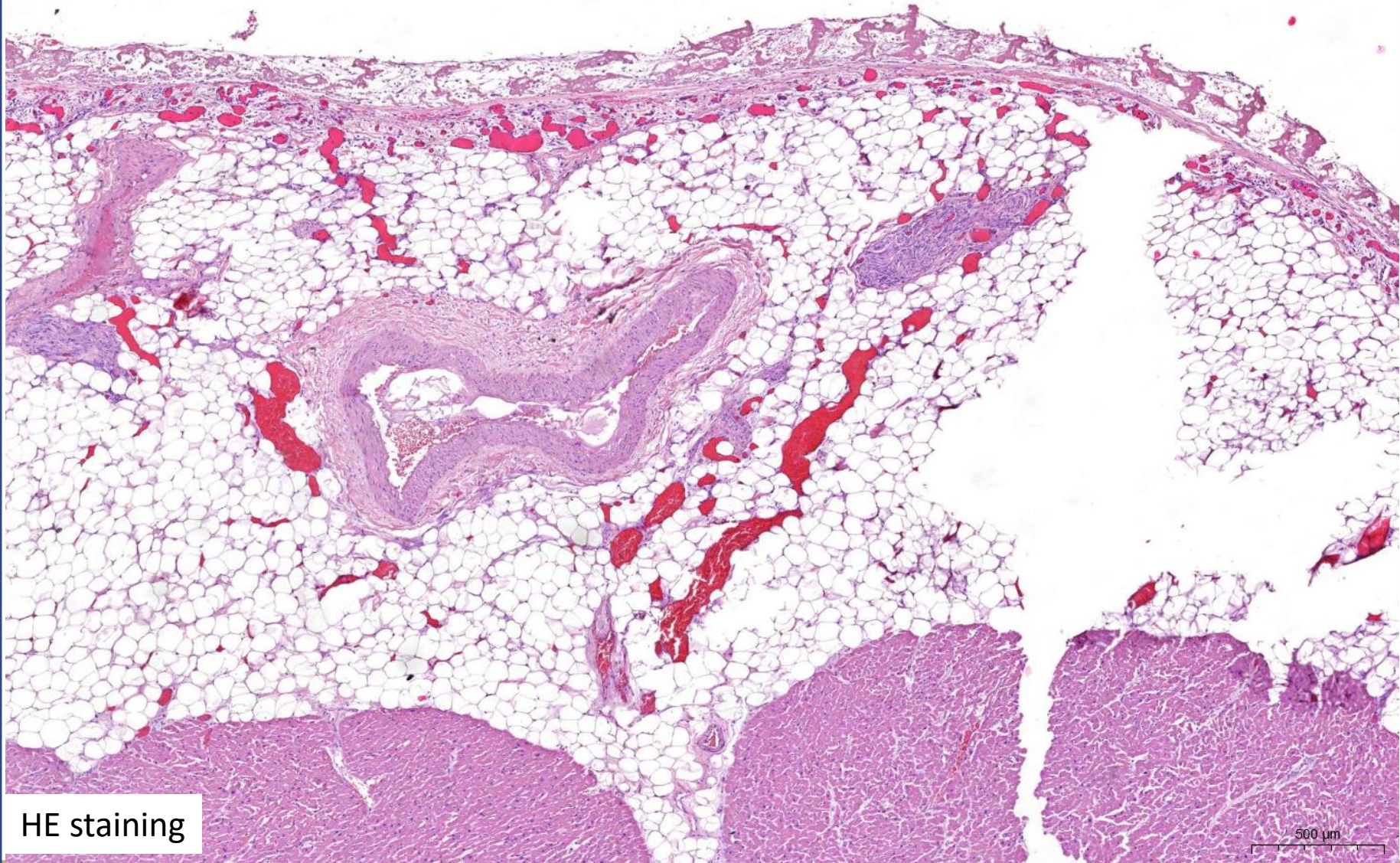
Pericarditis



Robbins and Cotran Pathologic Basis of Disease



Pericarditis



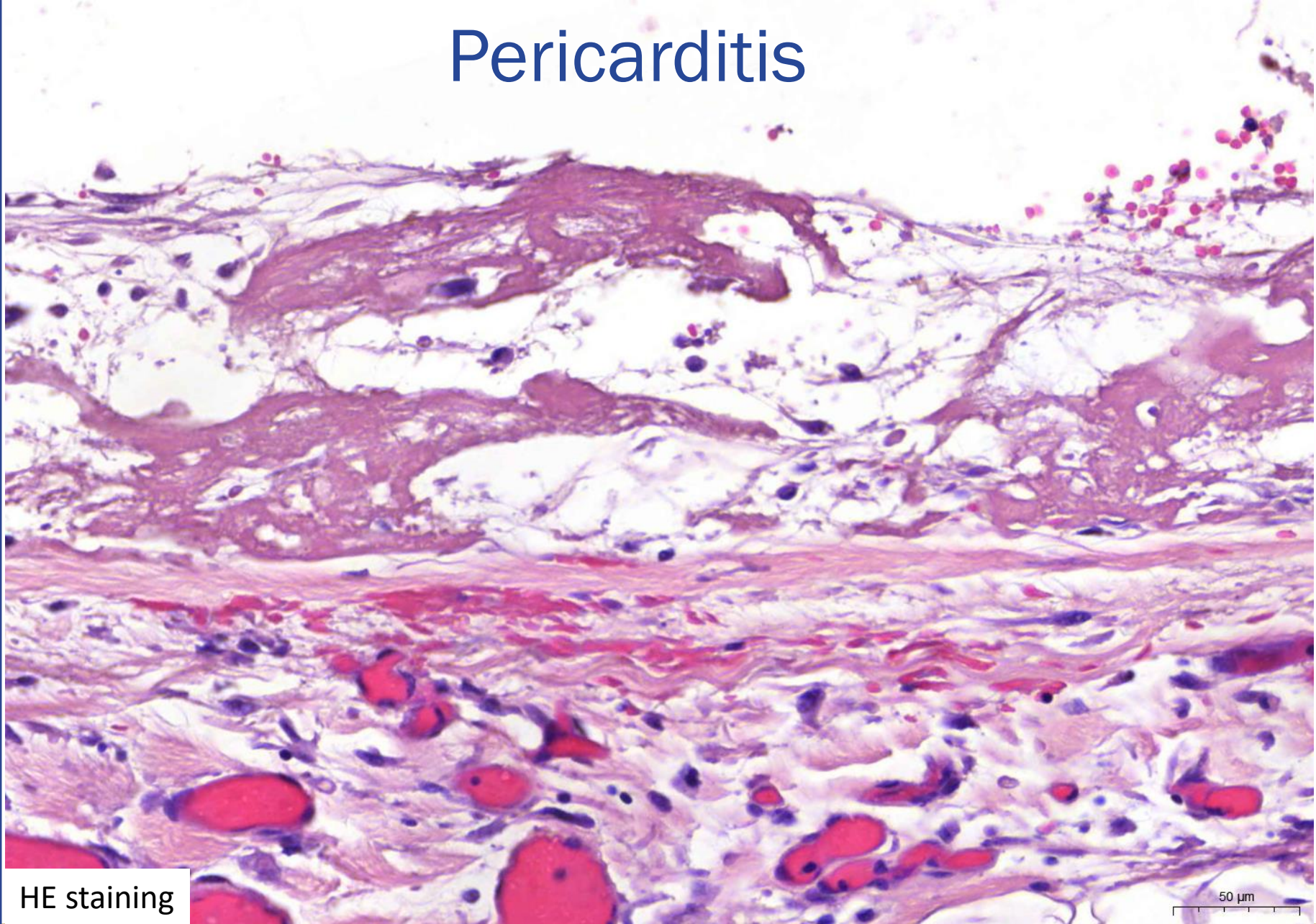
HE staining



Semmelweis University
<http://semmelweis.hu>

Attila Fintha MD PhD

Pericarditis



HE staining

50 μ m



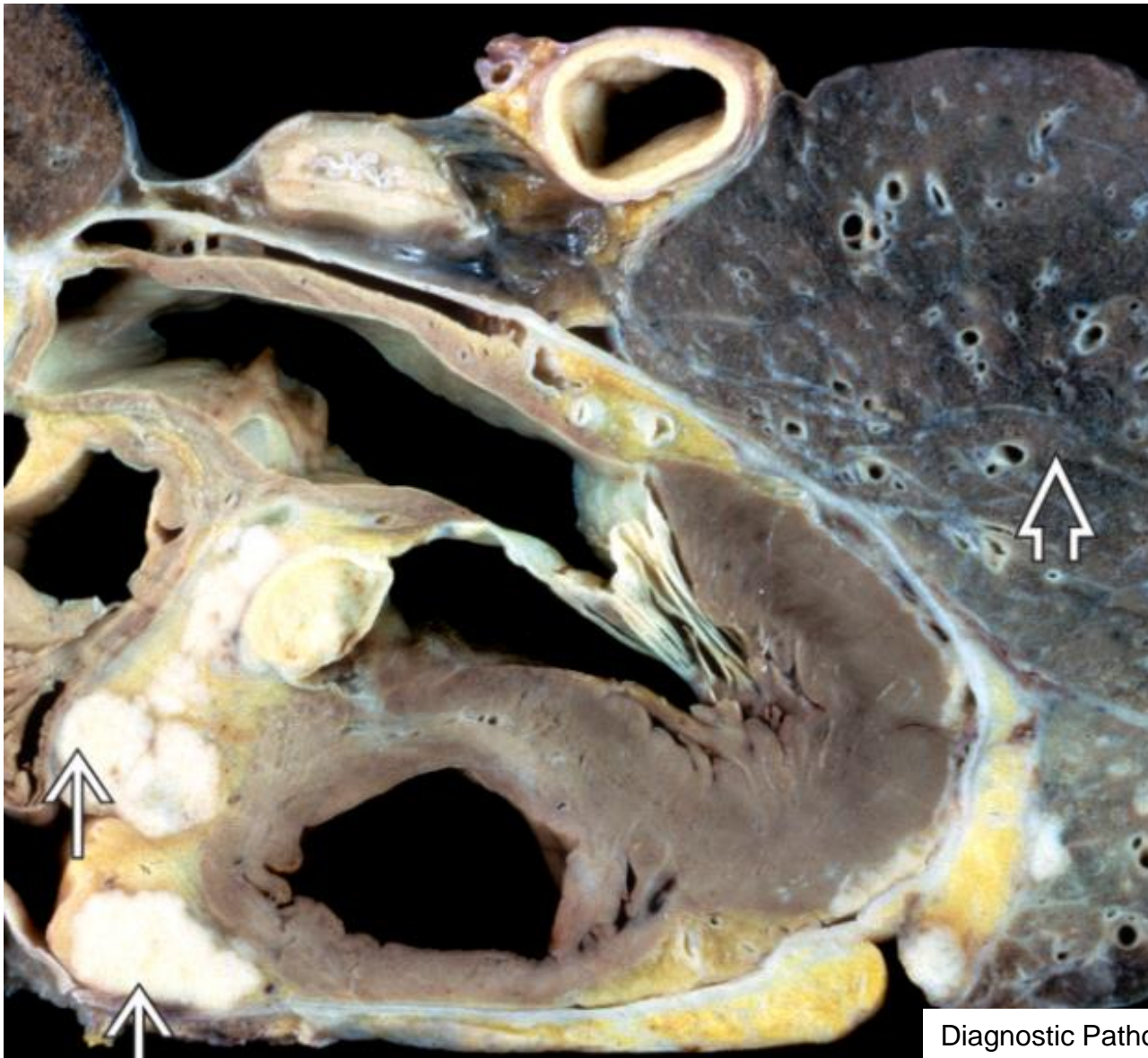
Semmelweis University
<http://semmelweis.hu>

Attila Fintha MD PhD

Cardiac tumors

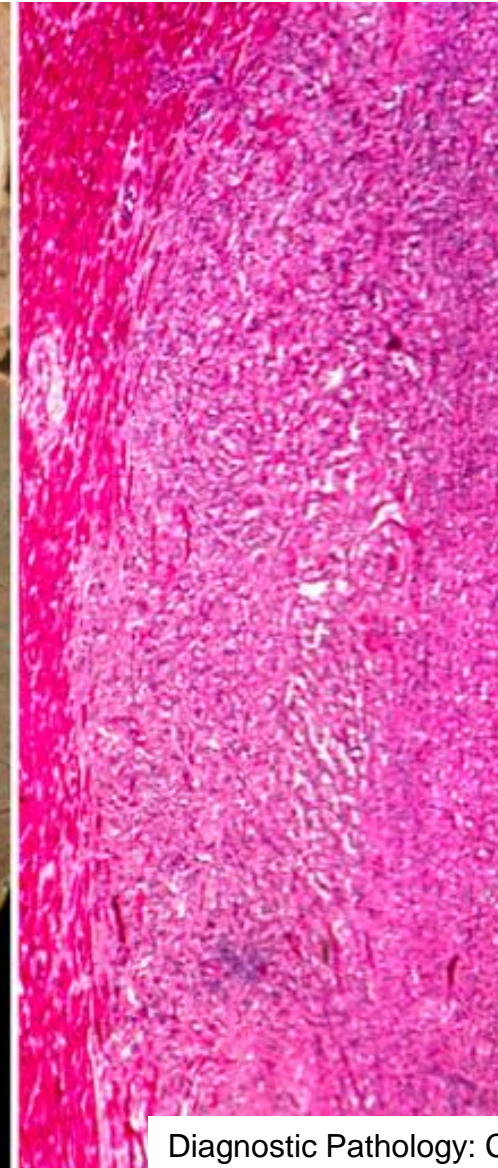
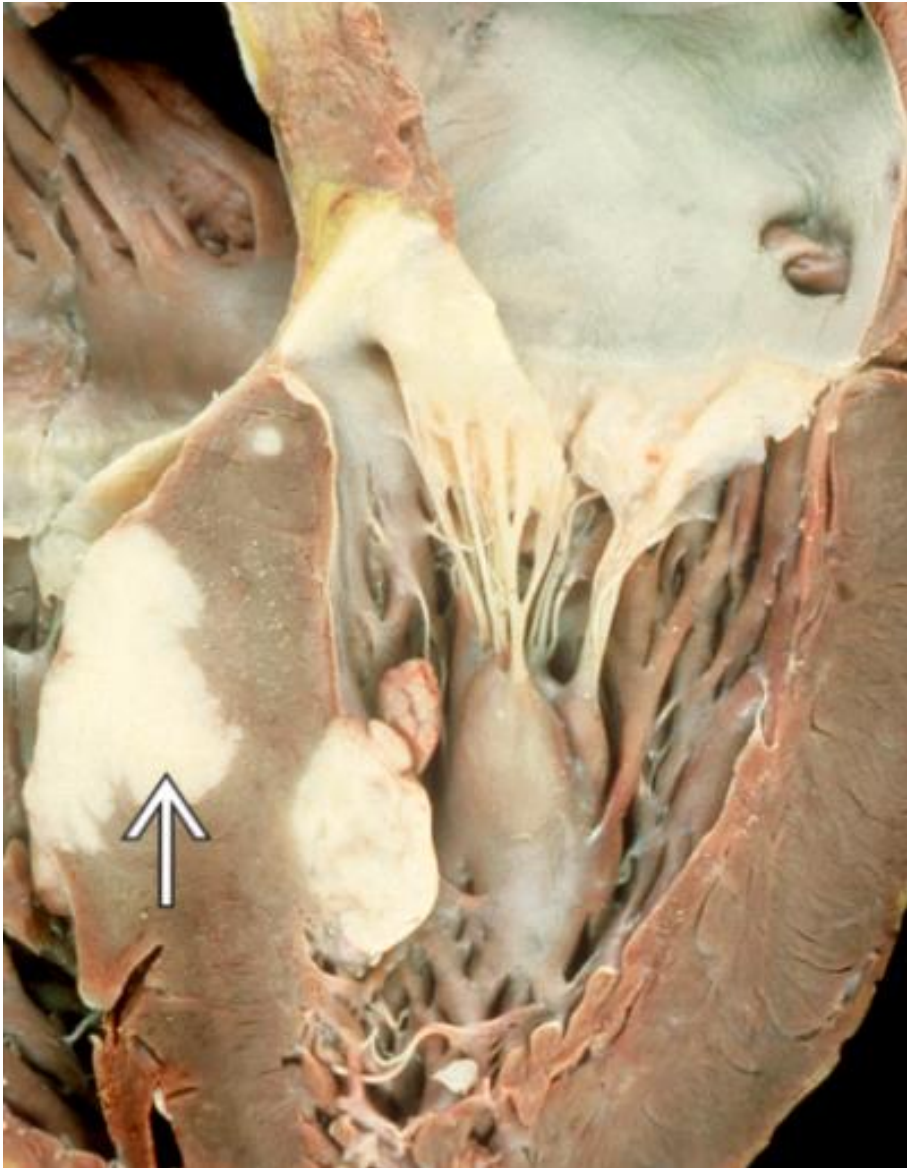


Cardiac metastasis



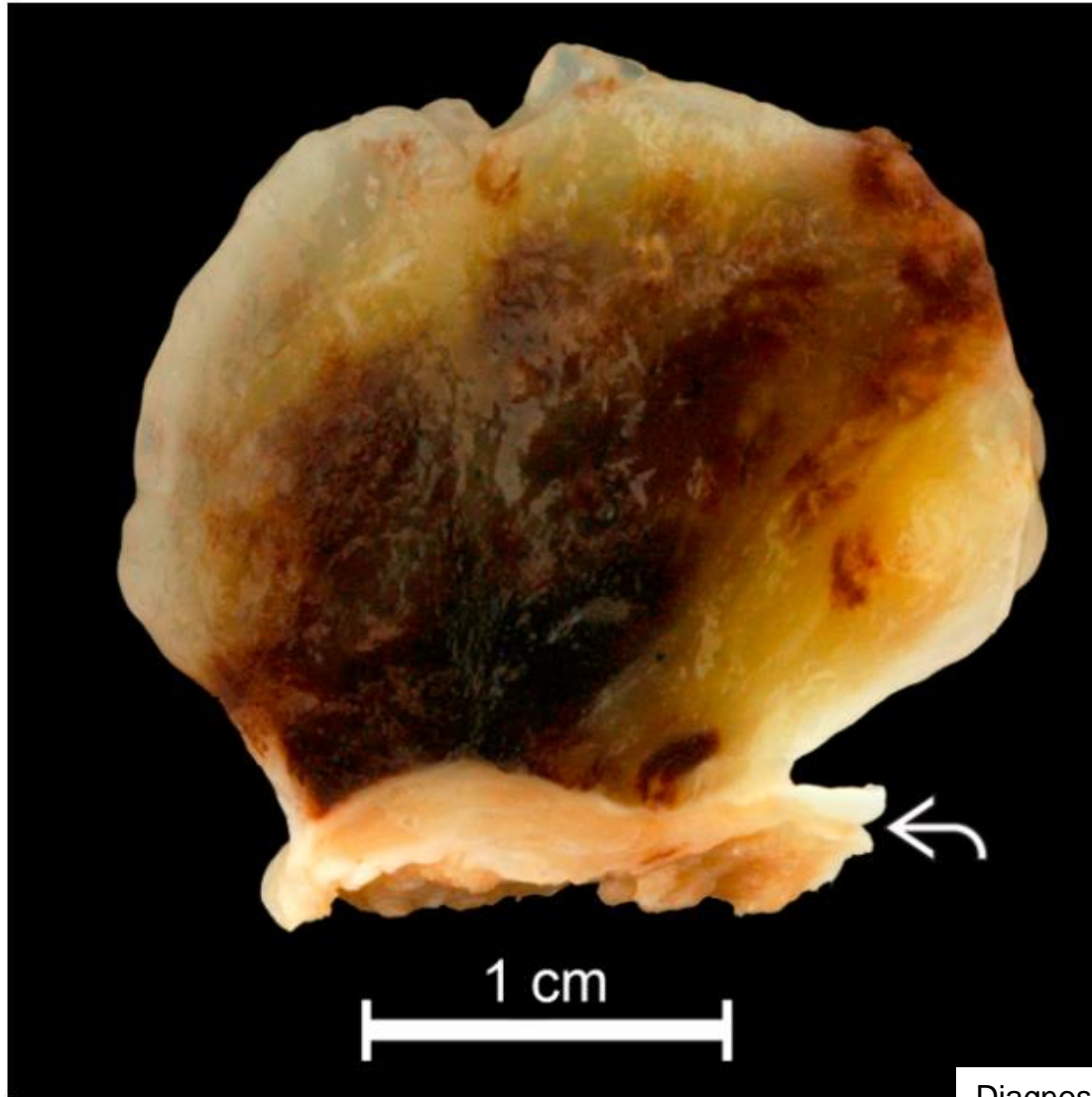
Diagnostic Pathology: Cardiovascular

Cardiac metastasis



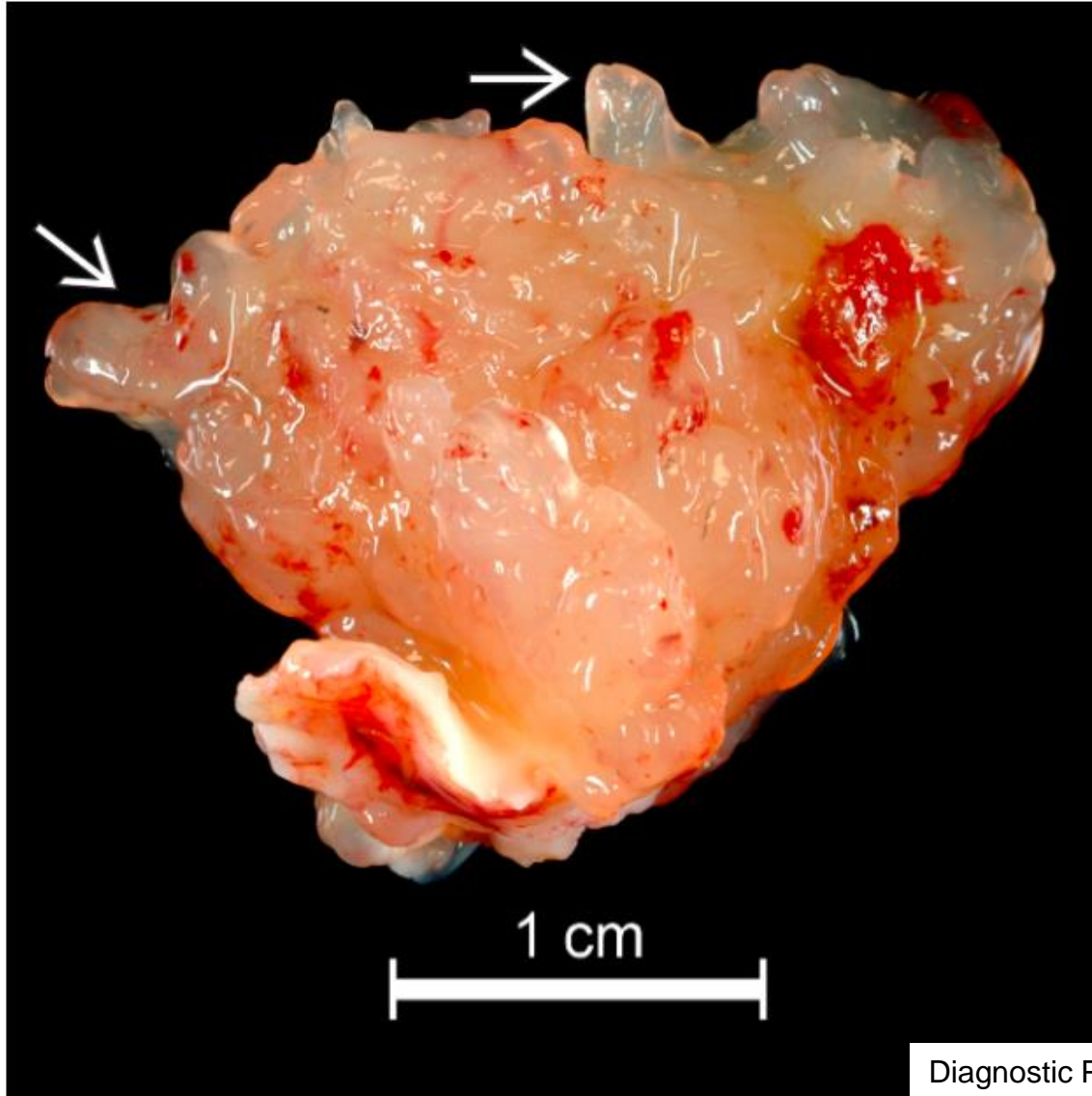
Diagnostic Pathology: Cardiovascular

Myxoma



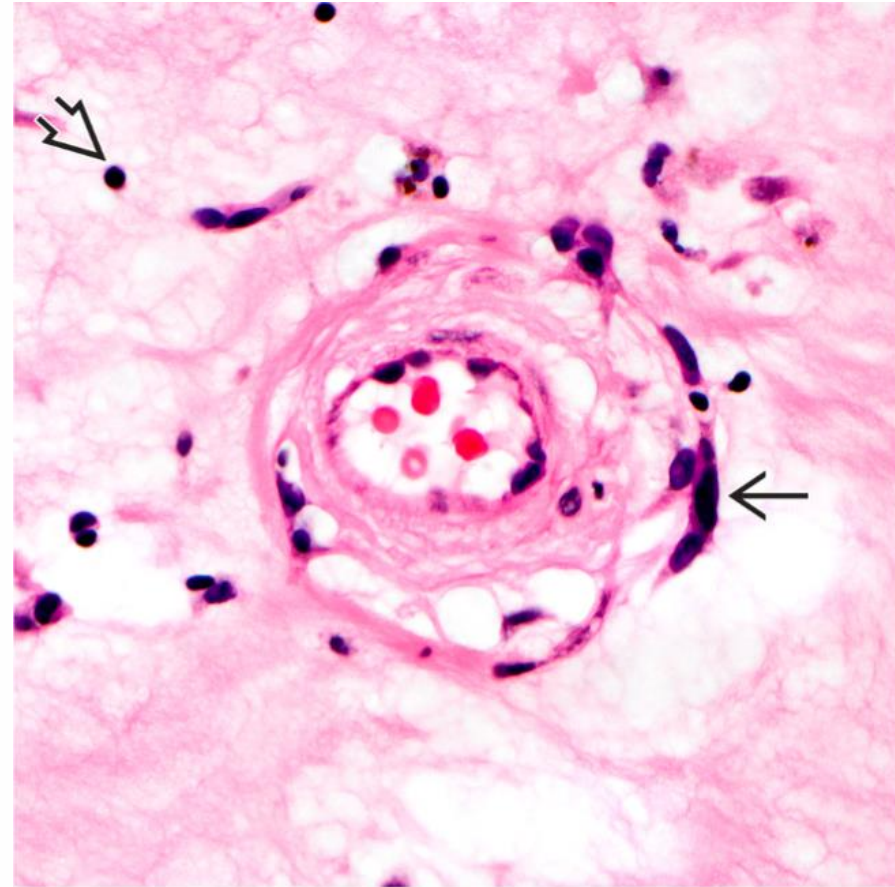
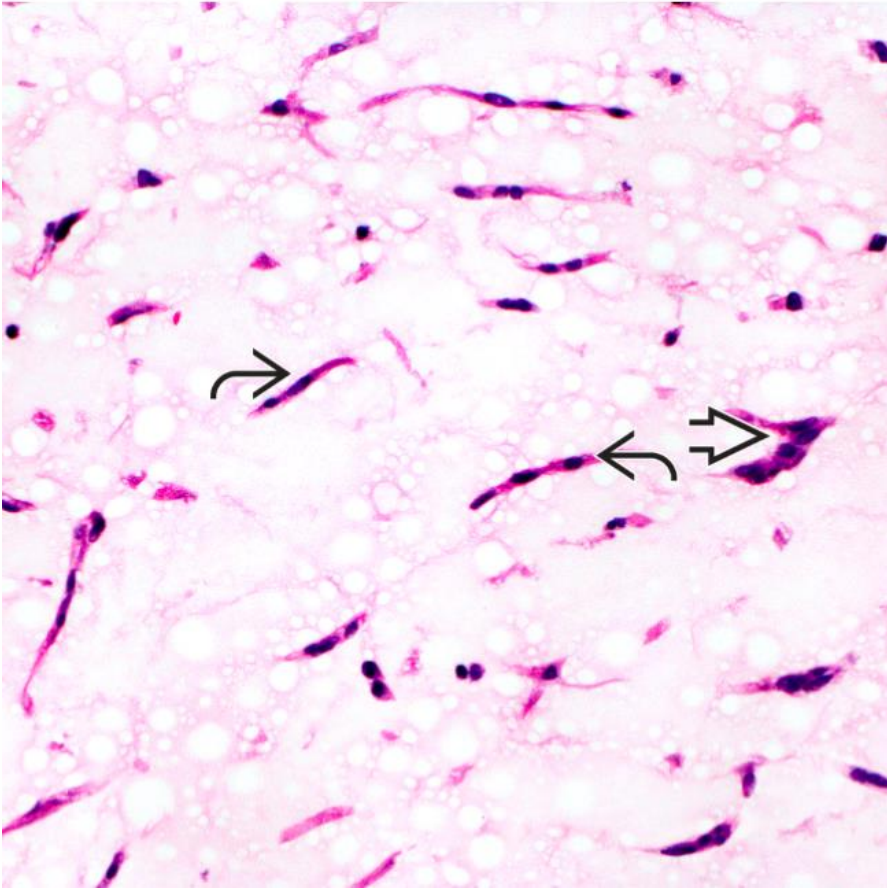
Diagnostic Pathology: Cardiovascular

Myxoma



Diagnostic Pathology: Cardiovascular

Myxoma



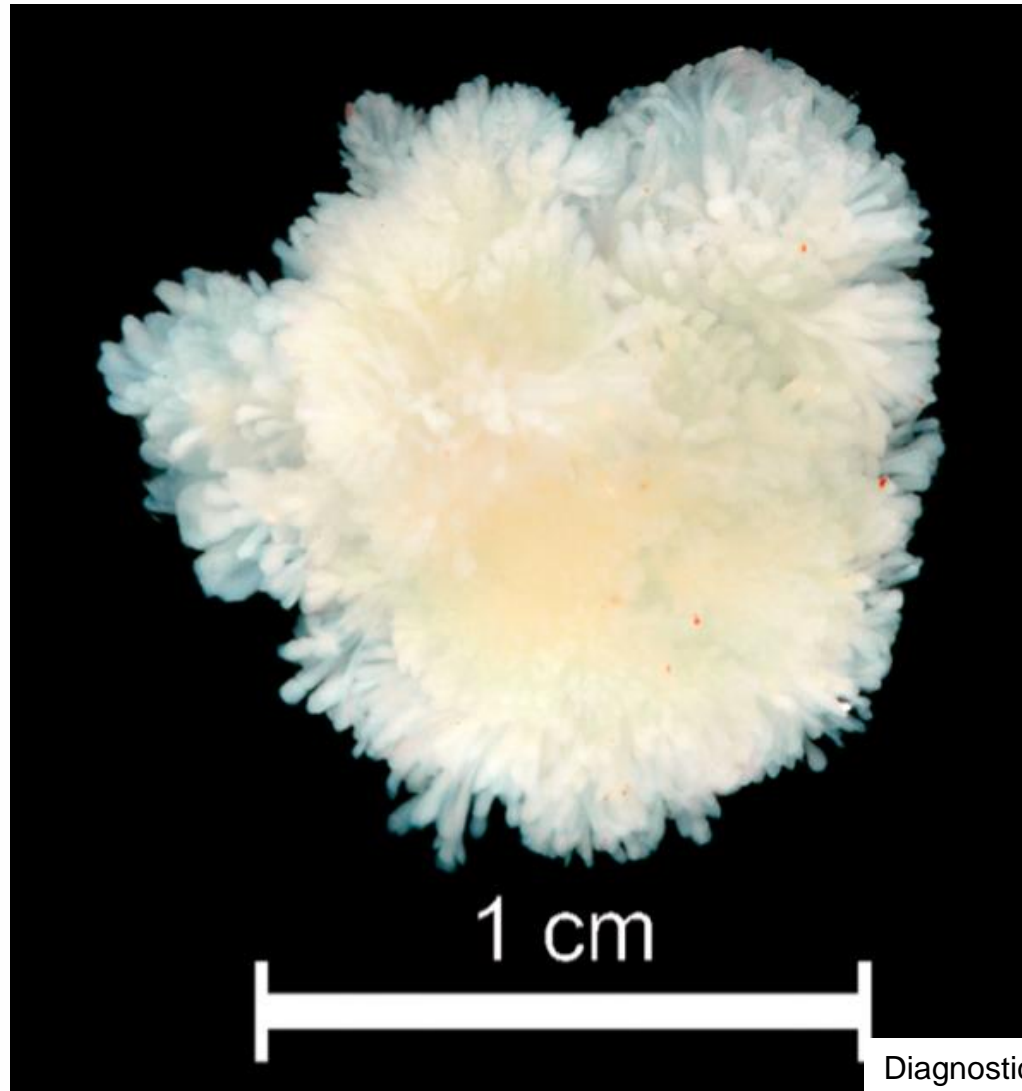
Diagnostic Pathology: Cardiovascular



Semmelweis University
<http://semmelweis.hu>

Attila Fintha MD PhD

Fibroelastoma

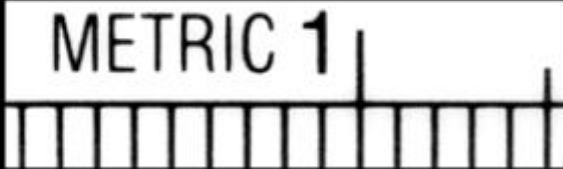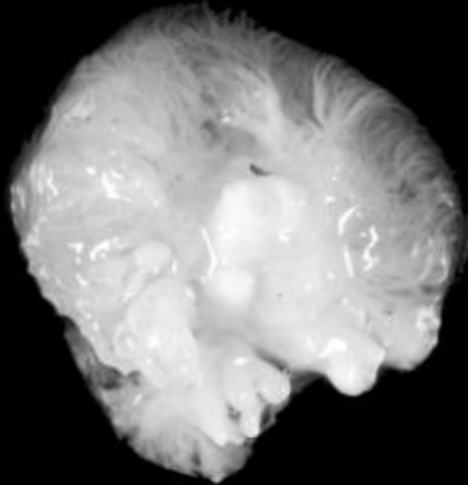


Diagnostic Pathology: Cardiovascular

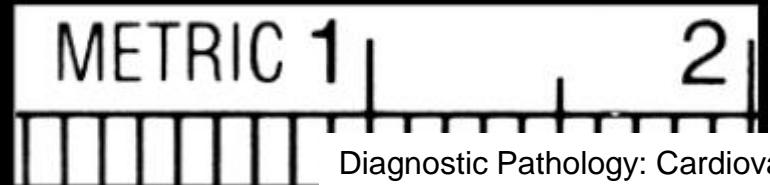


Fibroelastoma

Dry



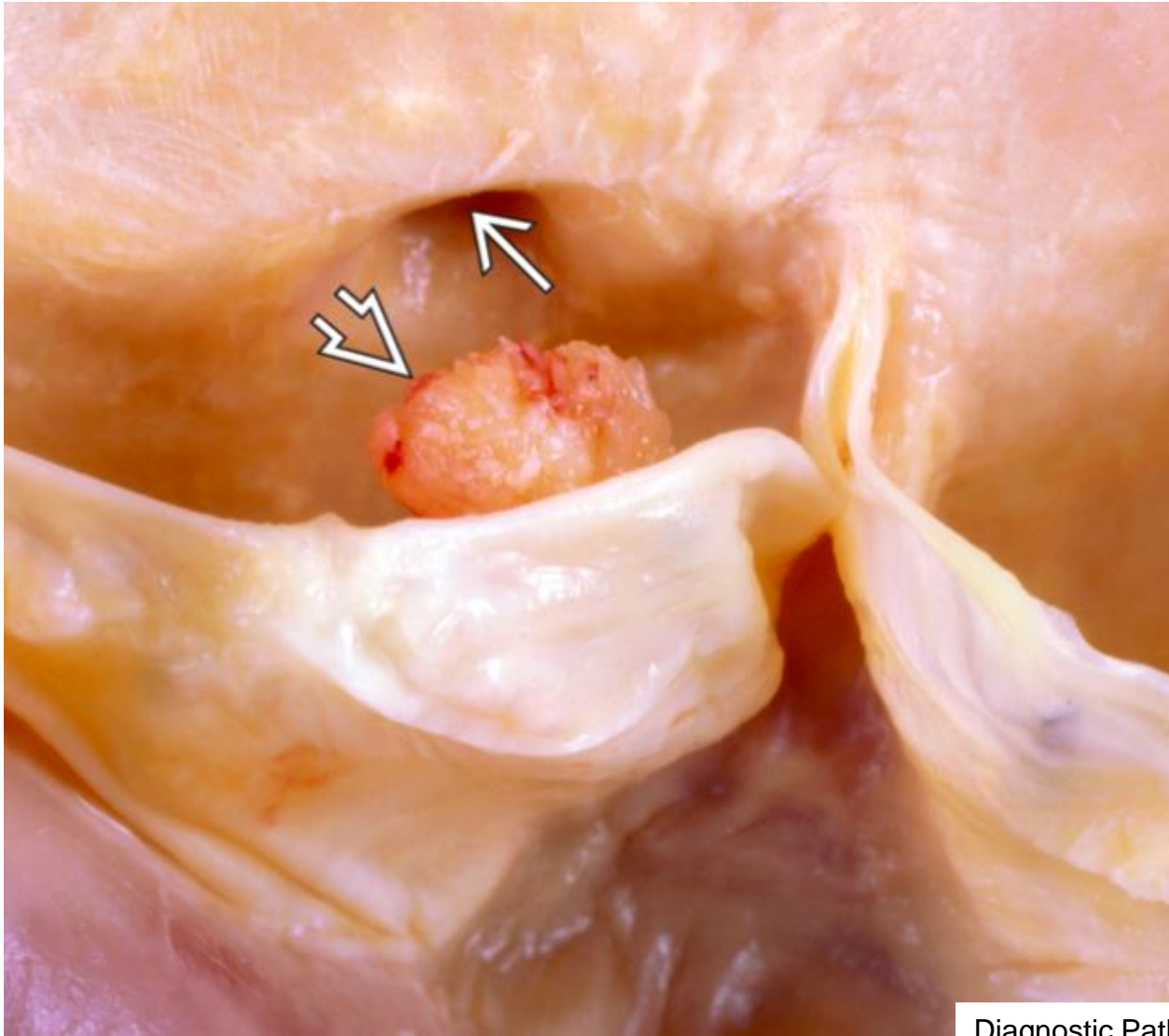
Floating



Diagnostic Pathology: Cardiovascular

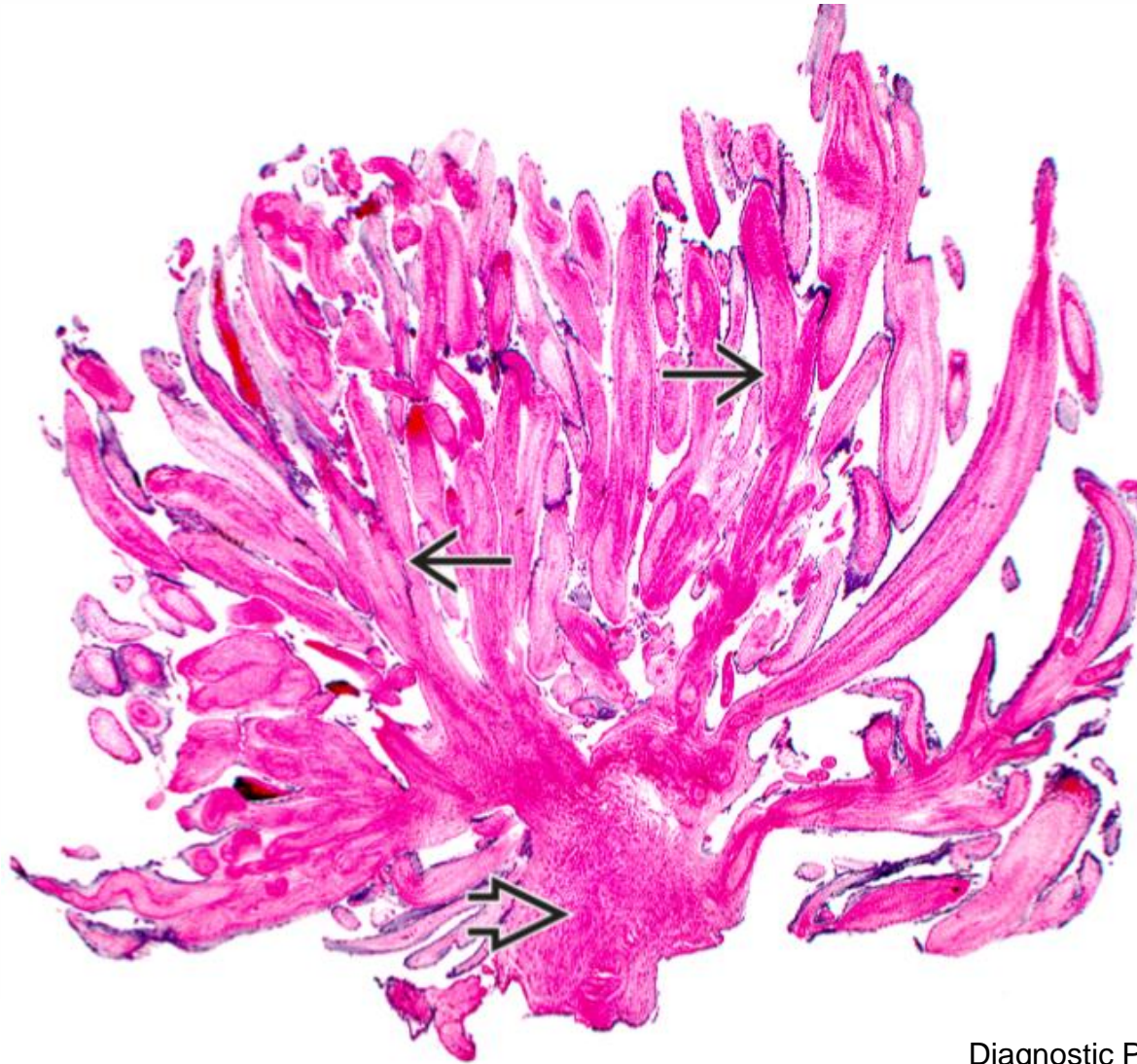


Fibroelastoma



Diagnostic Pathology: Cardiovascular

Fibroelastoma



HE staining

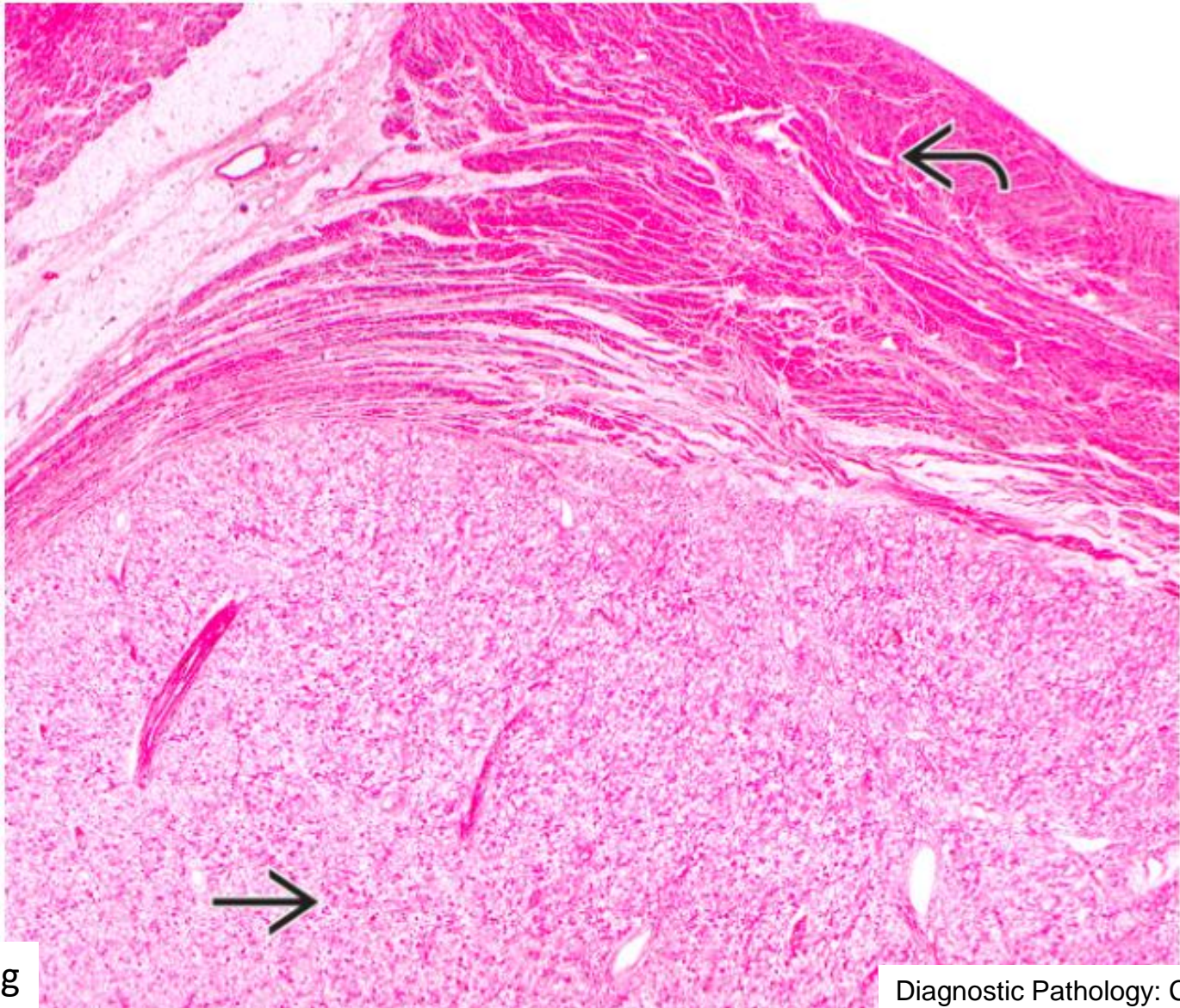
Diagnostic Pathology: Cardiovascular



Semmelweis University
<http://semmelweis.hu>

Attila Fintha MD PhD

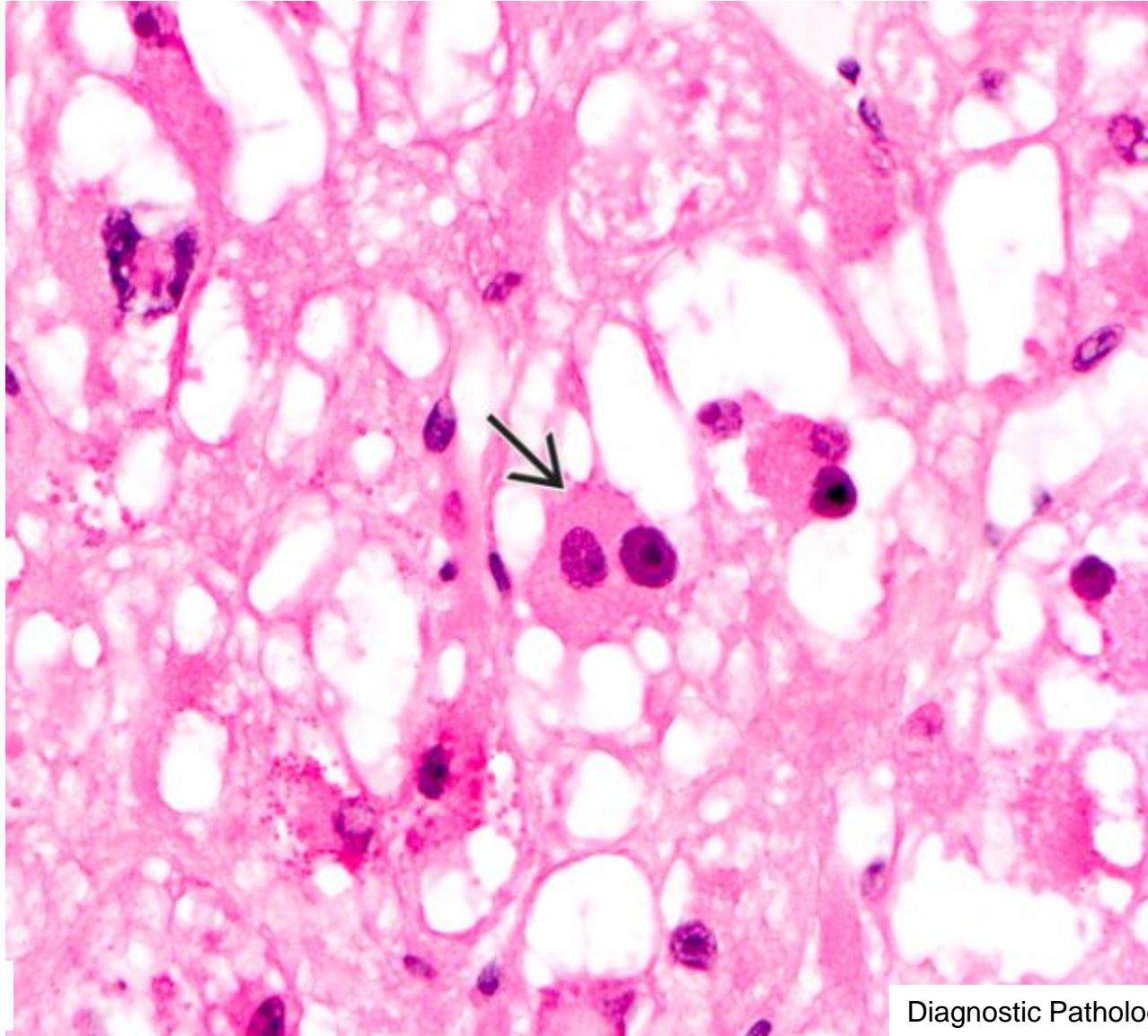
Rhabdomyoma



HE staining

Diagnostic Pathology: Cardiovascular

Rhabdomyoma



HE staining

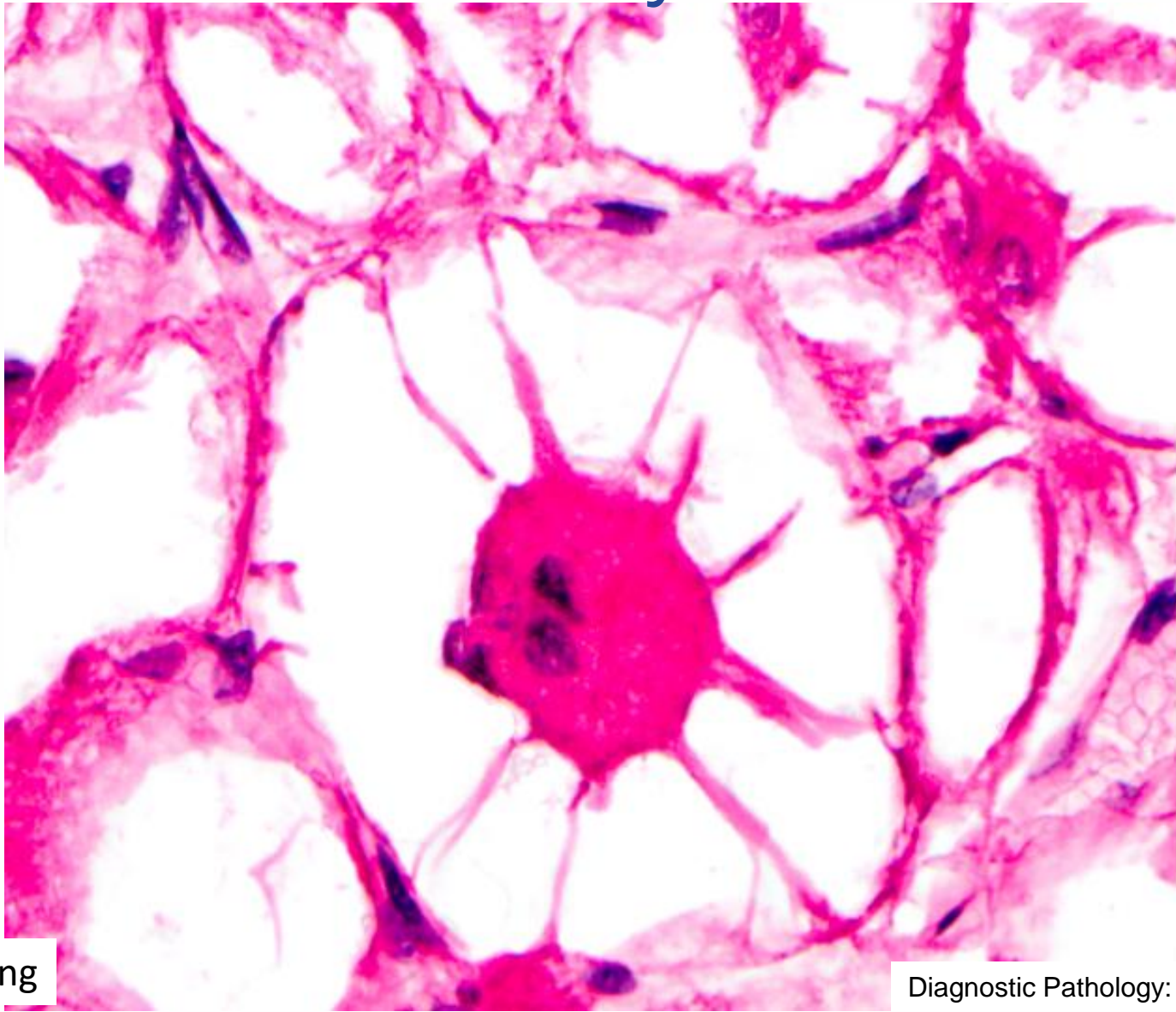
Diagnostic Pathology: Cardiovascular



Semmelweis University
<http://semmelweis.hu>

Attila Fintha MD PhD

Rhabdomyoma



HE staining

Diagnostic Pathology: Cardiovascular



Semmelweis University
<http://semmelweis.hu>

Attila Fintha MD PhD



Complication of infective endocarditis could be...

- A. Thromboemboli
- B. Glomerulonephritis
- C. Valvular regurgitation
- D. Intracardial abscess
- E. All of them.



Which cause can lead to dilated cardiomyopathy?

- A. Hypertension
- B. Ischaemic heart disease
- C. Dystrophin mutation.
- D. Infective endocarditis
- E. None of them

