

Pathology of the skin

Dr Fónyad László, 1sz. Patológiai és Kísérleti Rákkutató Intézet, SE

The skin

Biggest organ

- ~ 1.8 m
- ~ 10 kg

Most frequent site for tumor development (BCC)

Pathology of the skin

Inflammatory diseases - dermatosis

Epidermal changes

Melanocytic changes

Skin appendageal changes

Dermal changes

Lymphoproliferative changes

Pathology of the skin

Clinical

- Macule/patch
- Papule/nodule
- Bullae
- Purpura
- Pustule
- ...

Histology

- Hyperkeratosis
- Parakeratosis
- Acanthosis
- Spongiosis
- Psoriasiform hyperplasia
- Lichenoid inflammation
- ...

Pathology of the skin

Inflammatory diseases - dermatosis

Epidermal changes

Melanocytic changes

Skin appendageal changes

Dermal changes

Lymphoproliferative changes

dermatosis

dermatosis

Spongiotic pattern	Ekzema (atopic, contact, allergic)
Acanthotic pattern	Lichen simplex chronicus, Psoriasis
Lichenoid pattern	Lichen sclerosus, Lichen planus
Vesiculobullous pattern	Bullosus pemphigoid, gestation pemphigoid, pemphigus vulgaris, cicatricial pemphigoid
Acantholytic pattern	Hailey-Hailey, Darier
Granulomatous pattern	Crohn's
Vasculopathic pattern	Zoon vulvitis Aphthous ulcers Behcet's

dermatosis

Spongiotic pattern	Ekzema (atopic, contact, allergic)
Acanthotic pattern	Lichen simplex chronicus, Psoriasis
Lichenoid pattern	Lichen sclerosus, Lichen planus
Vesiculobullous pattern	Bullosus pemphigoid, gestation pemphigoid, pemphigus vulgaris, cicatricial pemphigoid
Acantholytic pattern	Hailey-Hailey, Darier
Granulomatous pattern	Crohn's
Vasculopathic pattern	Zoon vulvitis Aphthous ulcers Behcet's

Spongiotic pattern - “eczema”

- Allergic contact dermatitis
- Irritant contact dermatitis
- Atopic dermatitis
- Drug induced eczema
- Stasis dermatitis

Erythematous plaques
(vesicles, crusts)

Pruritus

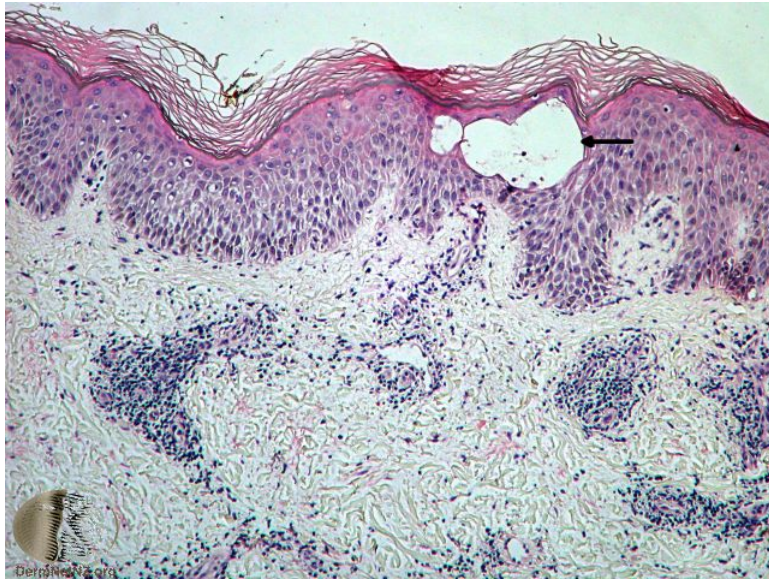
(scratching -> scaling
plaques)

Acut

Subacute

Chronic

Spongiotic pattern - “eczema”

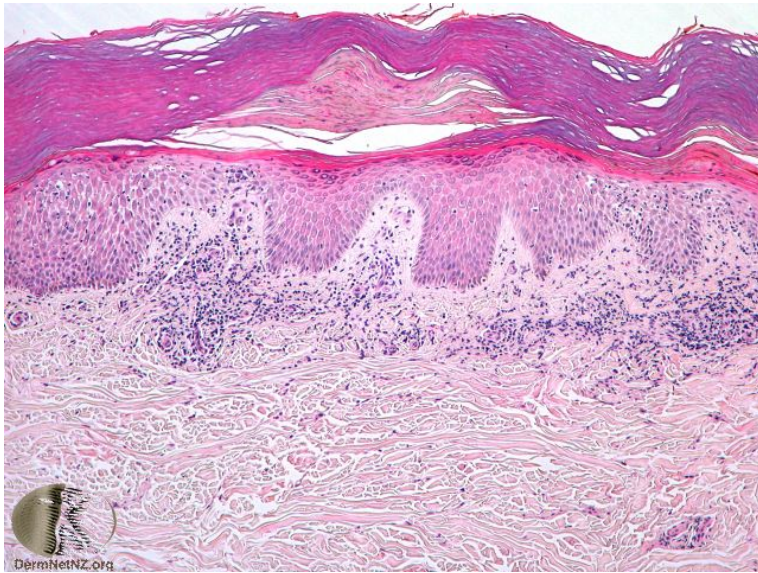


Constantly changing histology - acute

- Preserved stratum corneum
- Intercellular edema
- Spongiotic microvesicles +/-
- Papillary edema +/-
- SPVI lymphocytes, eosinophils

Phelps RG, Miller MK, Singh F. The varieties of "eczema": clinicopathologic correlation. *Clin Dermatol.* 2003 Mar-Apr;21(2):95-100.

Spongiotic pattern - “eczema”

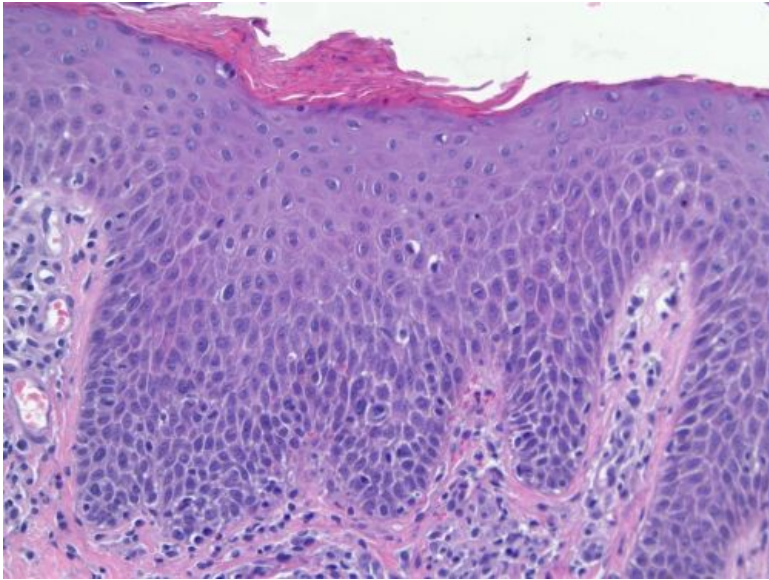


Constantly changing histology - subacute

- Parakeratosis
- Spongiosis
- Acanthosis
- Papillary edema -/mild
- SPVI lymphocytes, eosinophils

Phelps RG, Miller MK, Singh F. The varieties of "eczema": clinicopathologic correlation. Clin Dermatol. 2003 Mar-Apr;21(2):95-100.

Spongiotic pattern - “eczema”



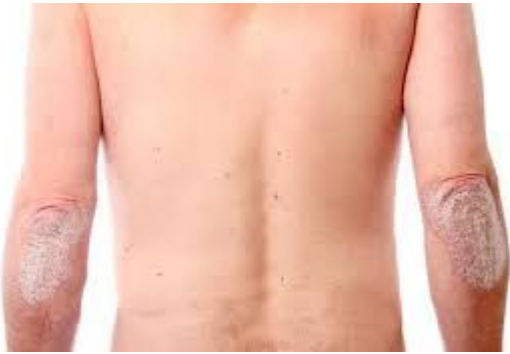Phelps RG, Miller MK, Singh F. The varieties of "eczema": clinicopathologic correlation. *Clin Dermatol.* 2003 Mar-Apr;21(2):95-100.

Constantly changing histology - chronic

- Compact hyperkeratosis
- Parakeratosis -/minimal
- Acanthosis
- Minimal spongiosis
- Superficial dermal fibrosis
- Mild SPVI ly/eos

Acanthotic pattern - psoriasis

Acanthotic pattern - psoriasis



Classic

- Well demarcated erythematous non-puritic plaques covered by fine, loosely adherent, silvery-white scales
- Auspitz-sign, Koebner-phenomenon

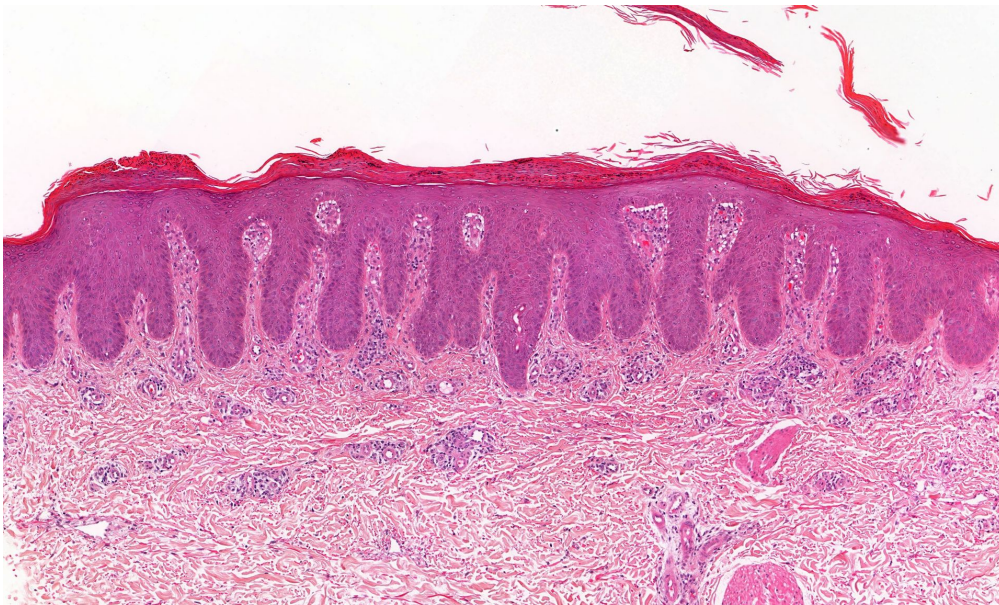
Guttate

- After Streptococcal infection
- Might result in Classic psoriasis

Pustular

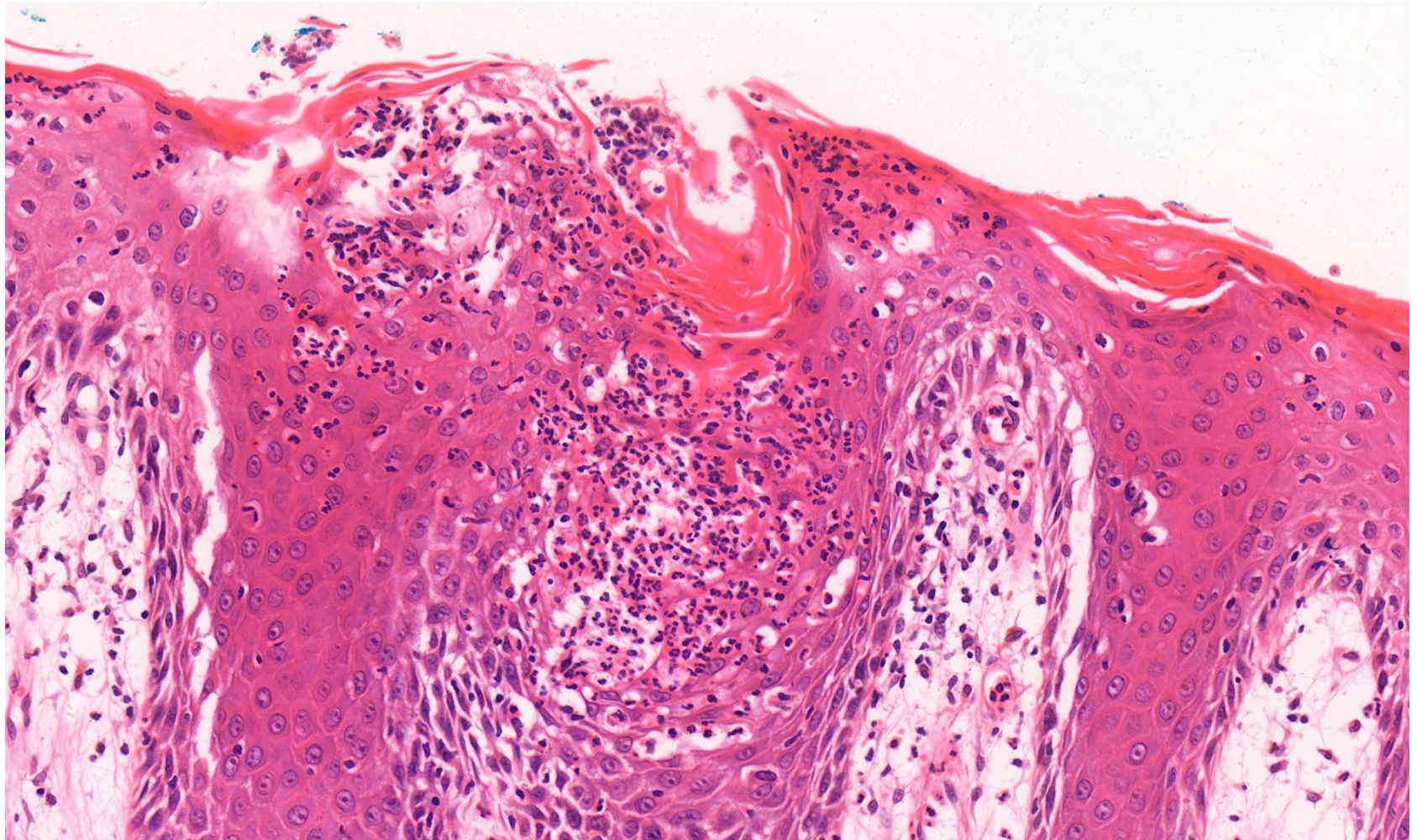
- Systemic signs/symptoms, high fever

Acanthotic pattern - psoriasis



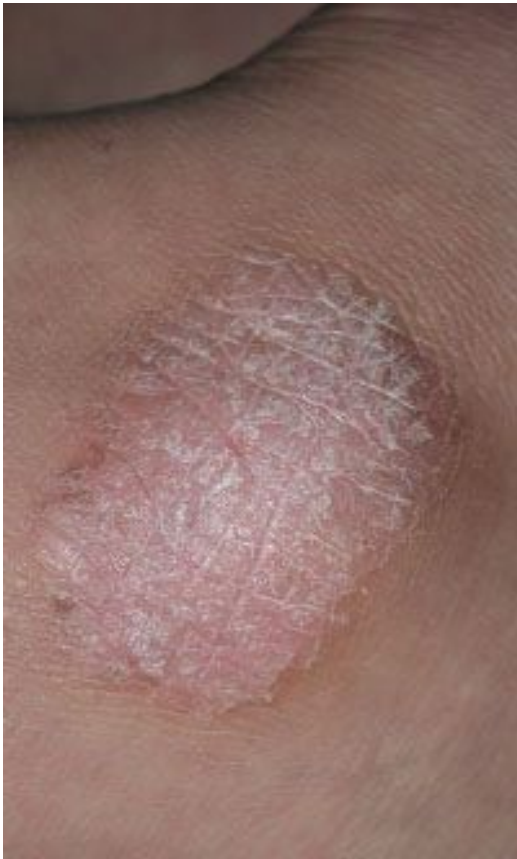- Parakeratosis
- Regular acanthosis
- Neutrophils in stratum corneum/epidermis
- Loss of granular layer
- Suprapapillary plate thinning
- Dilated tortuous vessels in the papillary dermis
- Dermal infl. wo. eosinophils

Acanthotic pattern - psoriasis



Acanthotic pattern - lichen simplex chronicus (LSC)

Acanthotic pattern - lichen simplex chronicus (LSC)



Not a real entity

Reaction to repetitive minor trauma (eg. scratching)

Indurated

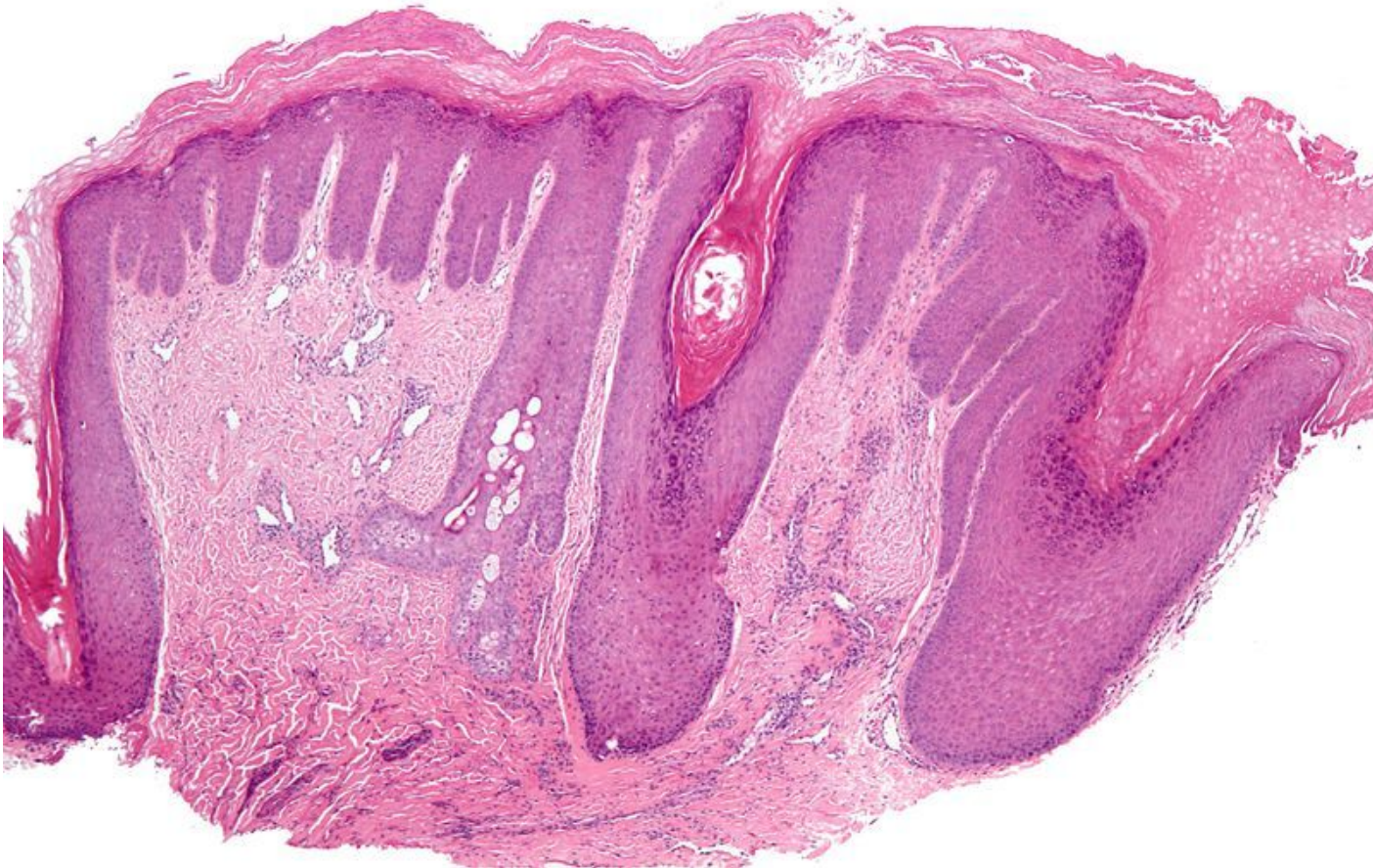Erythematous

Scaly

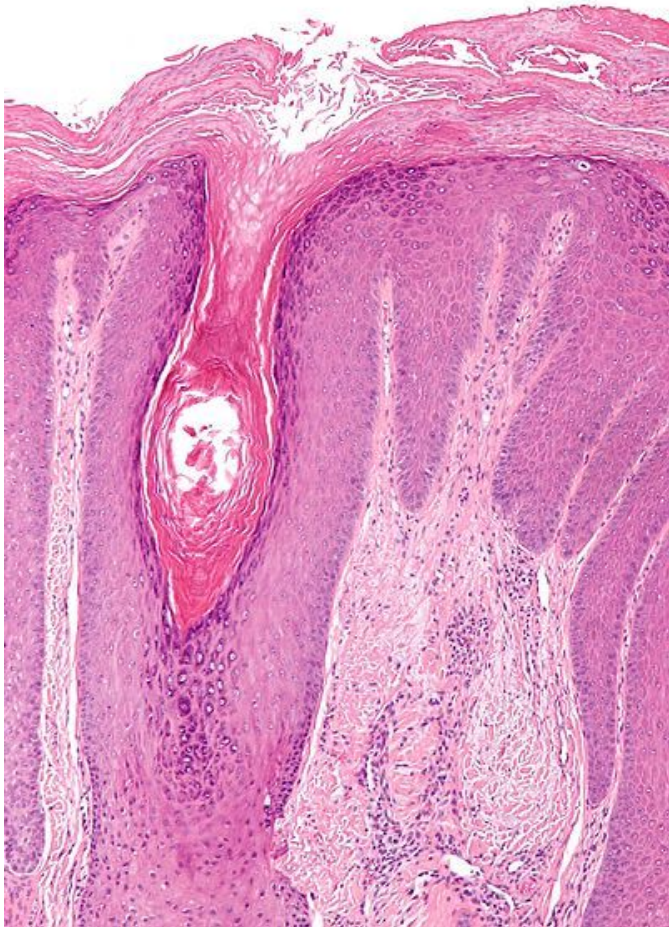
Hyperpigmented (later could be hypopigmented!)

Usu. soliter

Acanthotic pattern - lichen simplex chronicus (LSC)



Acanthotic pattern - lichen simplex chronicus (LSC)



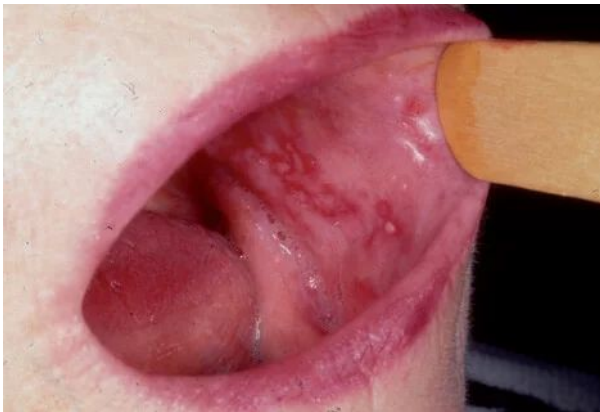- compact hyperkeratosis
- Parakeratosis -/focal
- Irregular acanthosis
- prominent granular layer
- Vertical streaks of dermal collagen
- Mild inflammation (eos)

lichenoid pattern - lichen planus

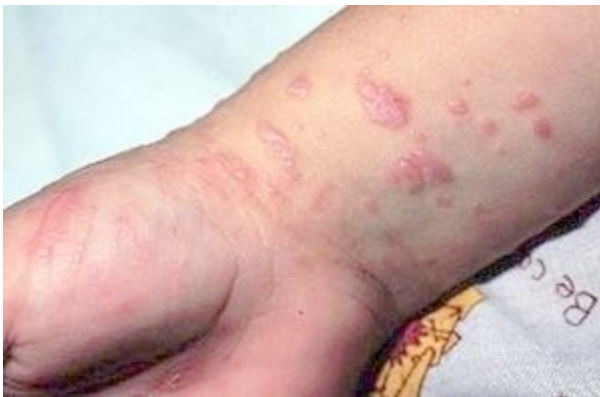lichenoid pattern - lichen planus

- Chronic, T-cell mediated dermatosis
 - Cutan
 - Wrist, elbow
 - Mucosal
 - Oral, genital
 - Destructive

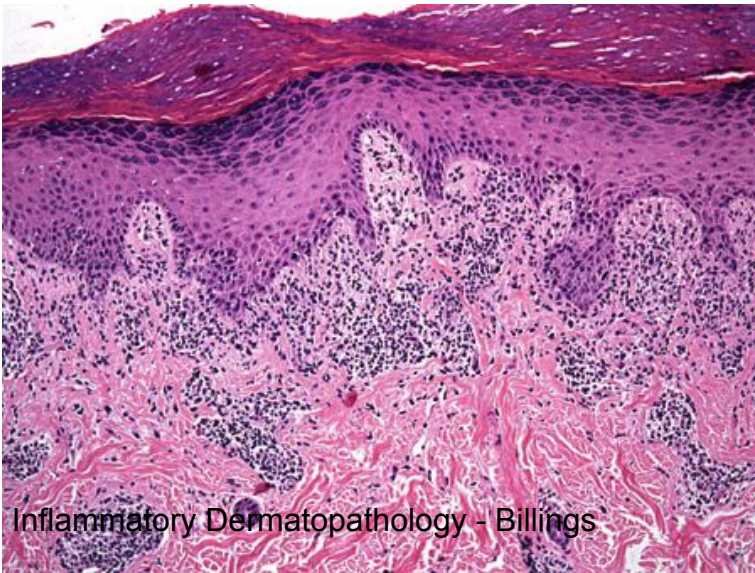
lichenoid pattern - lichen planus



- small papules
- Poorly demarcated
- Extremely itchy



lichenoid pattern - lichen planus



- Compact hyperkeratosis
- No parakeratosis
- Hypergranulosis
- **Band like inflammation**
- Basal vacuolisation
- Dyskeratotic keratinocytes
- Saw-tooth DE-junction
- No Eos.

dermatosis

Spongiotic pattern	Eczema
Acanthotic pattern	Lichen simplex chronicus, Psoriasis
Lichenoid pattern	Lichen planus

Pathology of the skin

Inflammatory diseases - dermatosis

Epidermal changes

Melanocytic changes

Skin appendageal changes

Dermal changes

Lymphoproliferative changes

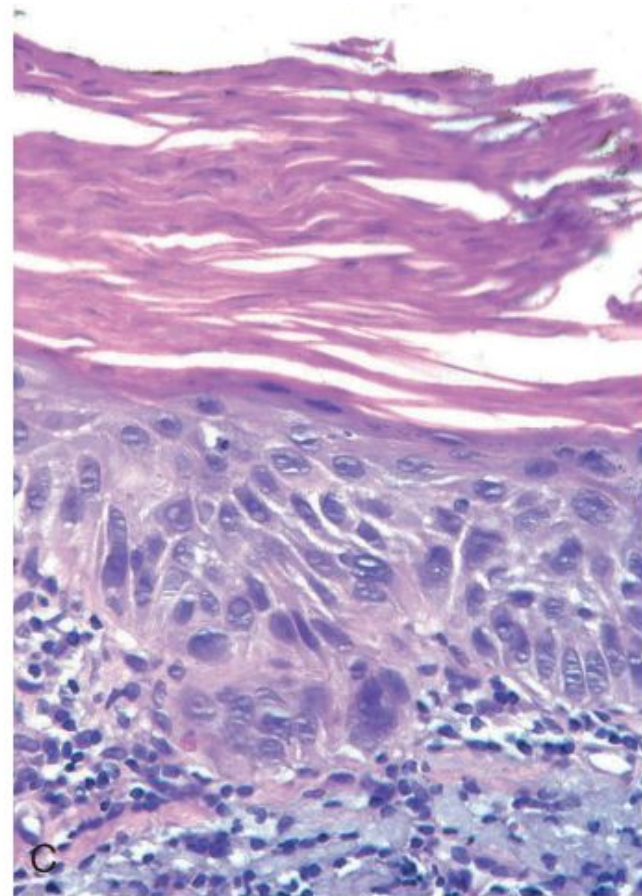
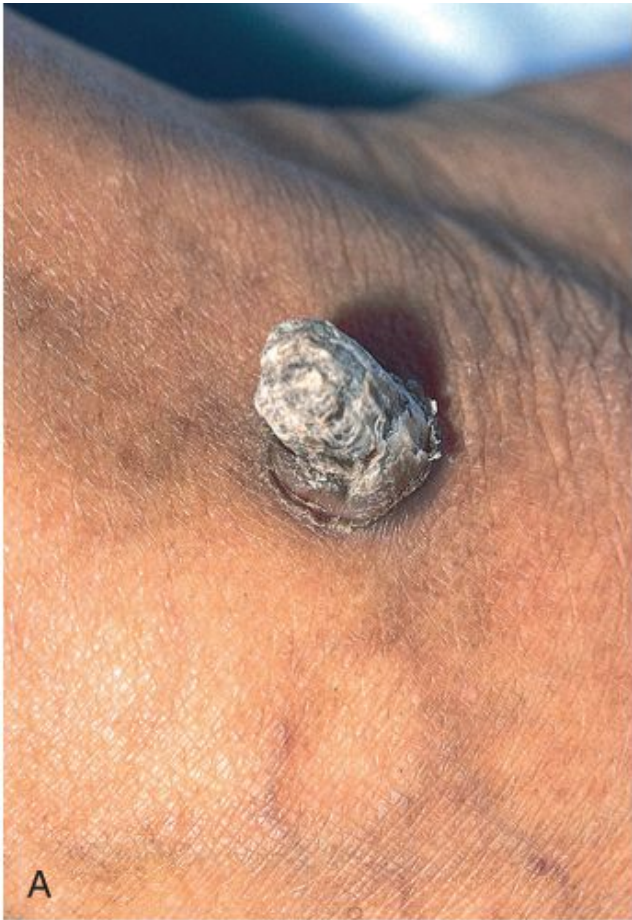Epidermal changes

- Benign
 - Seborrheic keratosis
- Premalignant
 - Actinic keratosis
 - In situ scc.
- Malignant
 - BCC
 - SCC

Epidermal changes

- Benign
 - Seborrheic keratosis
- Premalignant
 - **Actinic keratosis**
 - **In situ scc.**
- Malignant
 - BCC
 - SCC

Epidermal changes - actinic keratosis



Pathology of the skin

Inflammatory diseases - dermatosis

Epidermal changes

Melanocytic changes

Skin appendageal changes

Dermal changes

Lymphoproliferative changes

Melanocytic lesions

Acquired nevi

Dysplastic nevi

Melanoma

Melanocytic lesions - melanoma

etiology

- UV, dysplastic nevus syndrome
- Skin - NRAS, BRAF activating mutations
- Mucosa - cKIT activating mutations
- PTEN ts. loss

- **ABCDE-rule**

Melanocytic lesions - melanoma

types

- SSM
- Nodular
- Lentigo maligna, lentigo maligna melanoma
- ...

Melanocytic lesions - melanoma

Melanoma

- Breslow
- Clark

- Sentinel node
- Atypical metastatic sites

Pathology of the skin

Inflammatory diseases - dermatosis

Epidermal changes

Melanocytic changes

Skin appendageal changes

Dermal changes

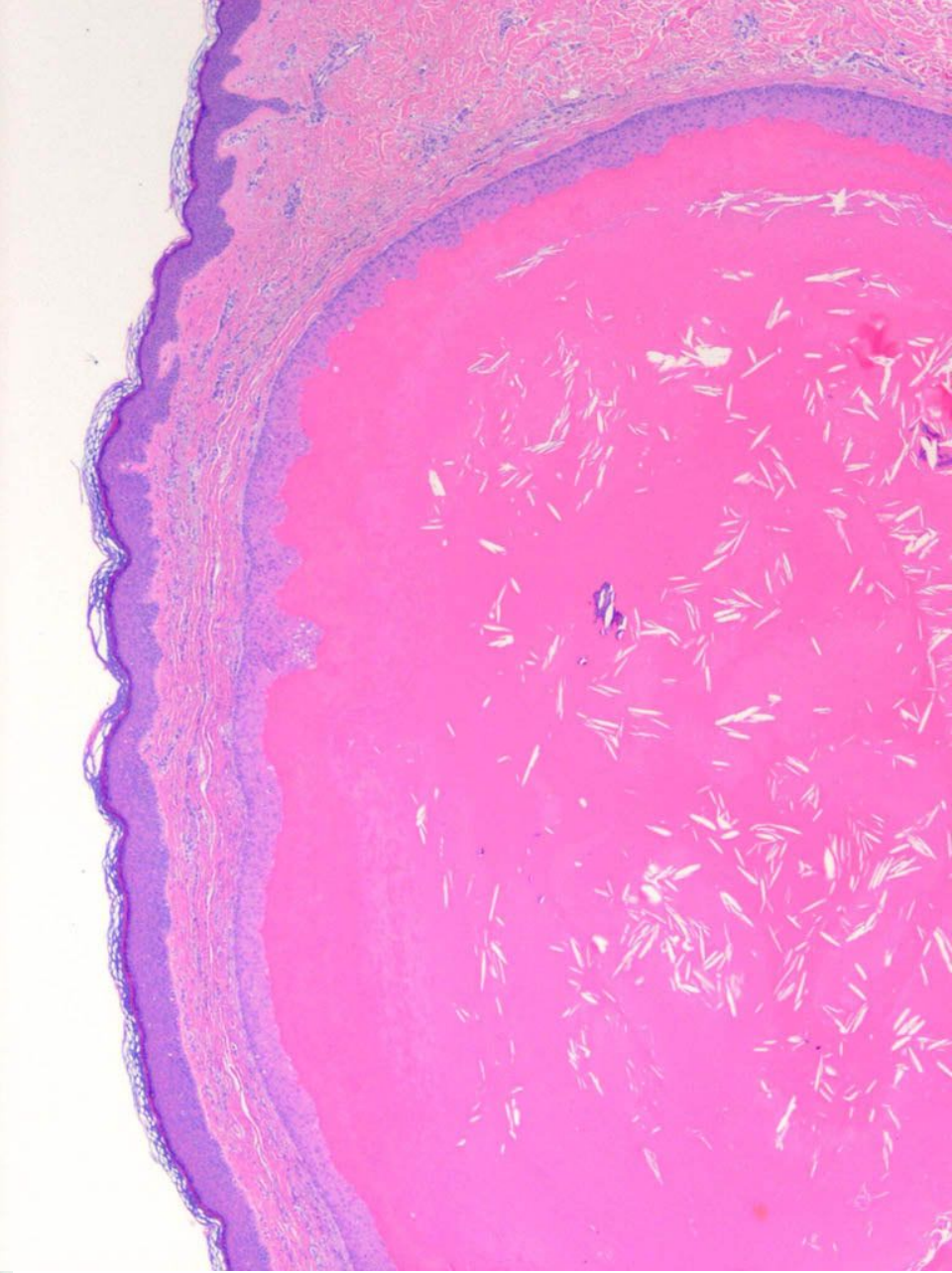
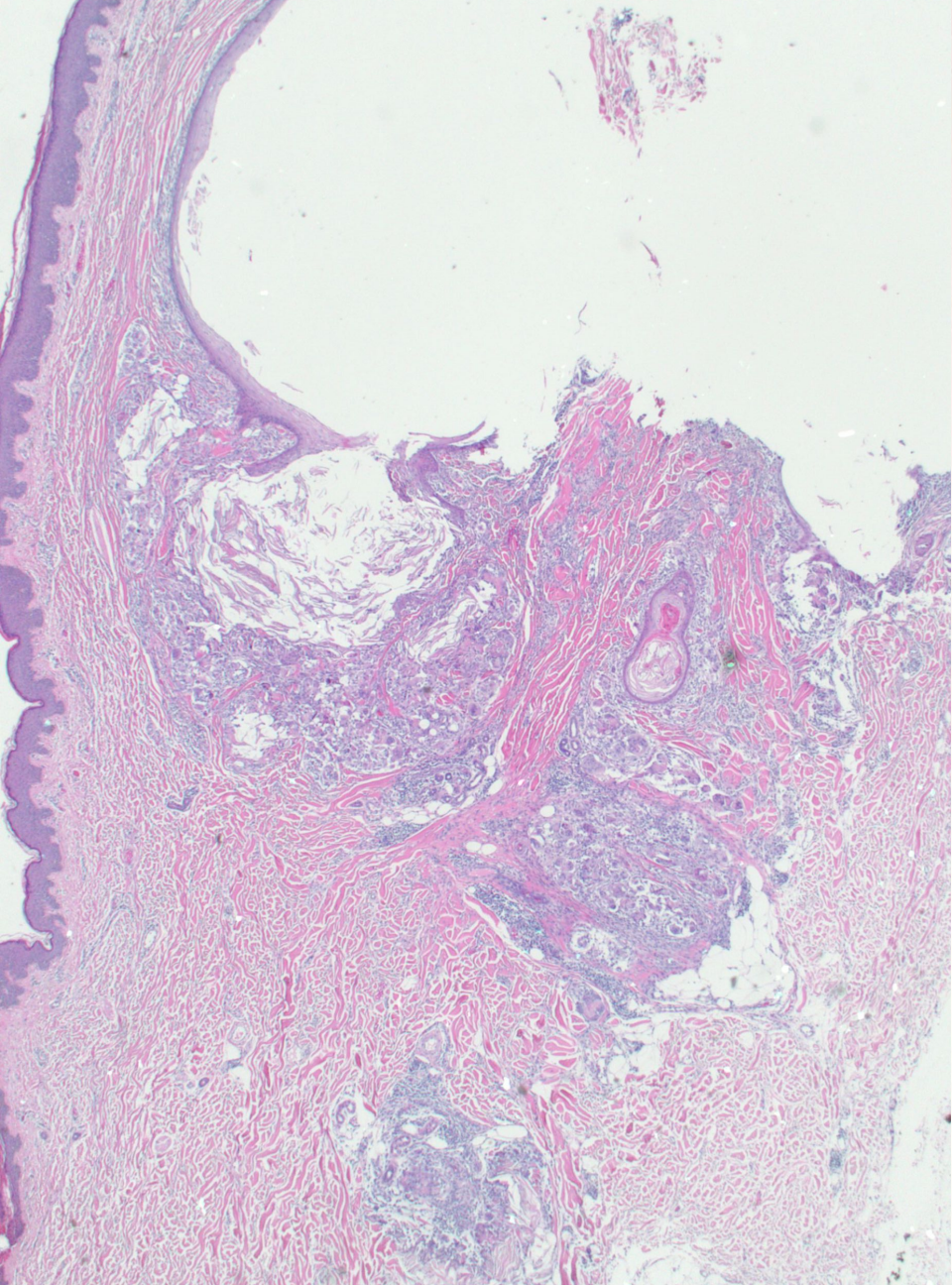
Lymphoproliferative changes

Appendageal lesions, cysts

- **Follicular lesions**
 - **Cysts**
 - Benign tumors
 - Malignant tumors
- **Sebaceous lesions**
 - Benign tumors
 - Malignant tumors
- **Eccrine lesions**
 - Benign tumors
 - Malignant tumors

Appendageal lesions, cysts

- Follicular lesions
 - Cysts
 - Epidermal cyst
 - Trichilemmal cyst



Pathology of the skin

Inflammatory diseases - dermatosis

Epidermal changes

Melanocytic changes

Skin appendageal changes

Dermal changes

Lymphoproliferative changes

Dermal lesions (soft tissue tumors)

Adipous tumors

Fibrous tumors

Neuroectodermal tumors

Smooth muscle tumors

Striated muscle tumors

Vascular tumors

Cartilage/bone forming tumors

Others...

Dermal lesions (soft tissue tumors)

Adipous tumors

Fibrous tumors - **dermatofibroma**

Neuroectodermal tumors

Smooth muscle tumors

Striated muscle tumors

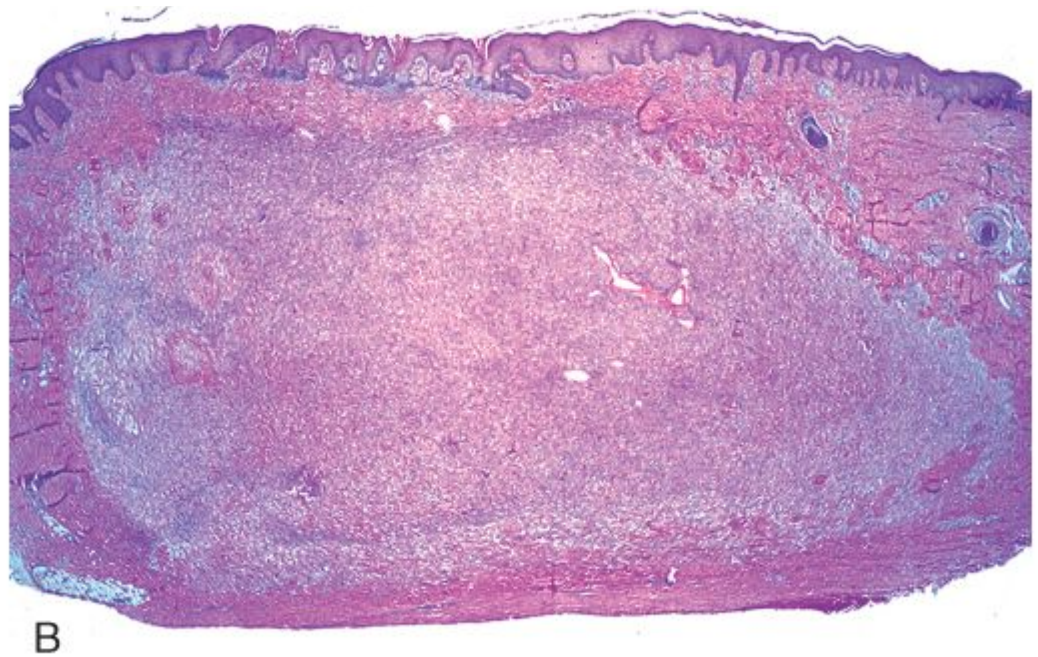
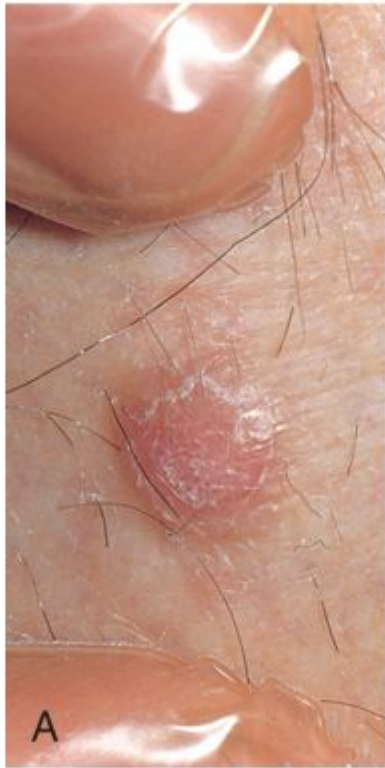Vascular tumors


Cartilage/bone forming tumors

Others...

Dermal lesions - dermatofibroma

dermatofibroma





Dr Fónyad László, 1sz. Patológiai és Kísérleti Rákkutató Intézet, SE