Clinical and radiographical diagnostics

Dr.Csifó-Nagy Boróka
Department of Periodontology
Semmelweis University
2016

Introduction

- correct diagnosis is the condition for successful therapy
- localization, extension, seriousness, prognosis of a disease
- diagnosis based treatment plan

Introduction

- primary goal of the clinical periodontal diagnosis:

- to isolate the abnormal gingival-periodontal condition from the healthy periodontium

- distinguish between reversible and irreversible processes

- active/inactive process

Steps of the full periodontal diagnosis

1. general and dental history - general medical aspects, systemic diseases, pregnancy, medication, AB prophylaxis requiring conditions, infectious diseases, smoking, dental history

2. general medical consultation - if necessary

3. clinical periodontal diagnosis - objective assessment of the oral hygiene, the actual extent of the inflammation and tissue destruction

4. special laboratory diagnosis - if necessary

Goal of periodontal diagnostics

Patient

Information

- Recognise the signs and symptoms of periodontal diseases
- Measure the bone destruction by radiographic examination
- Classification of the disease
- Assessment of indirect informations and periodental treatment plannig

Evidence-based dentistry

Diagnosis based therapy

Examination of the oral hygiene status

- plaque accumulation
- the deposits may be stained with a disclosing solution to facilitate their detection
- accumulation rate of the calculus
- the presence of retentive factors for plaque

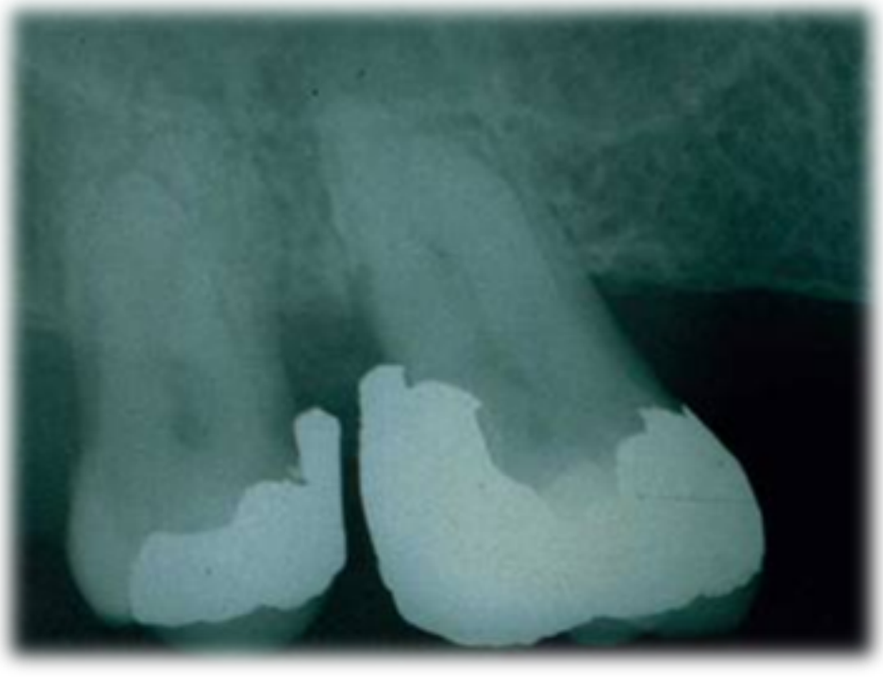

Examination of the oral hygiene habits

Examination of the gingiva

- changes in color
- shape
- texture
- bleeding on probing
- shape of the interdental papillae
- width of the keratinized gingiva
- mucogingival junction
- depth of the vestibule

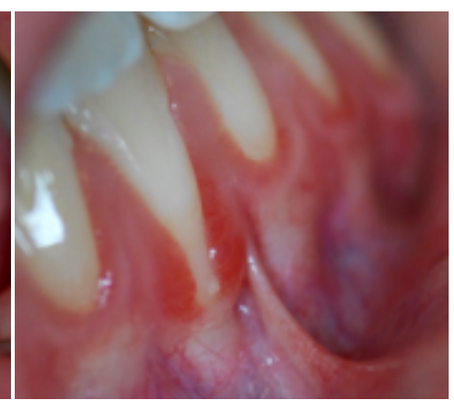

Assessment of probing pocket depth

- calibrated periodontal probes - Williams, WHO, UNC-15
- distance from the gingival margin to the bottom of the gingival sulcus/pocket
- parallel to the longitudinal axis of the tooth
- force of 0.2-0.25 Newton
- clinical probing depth

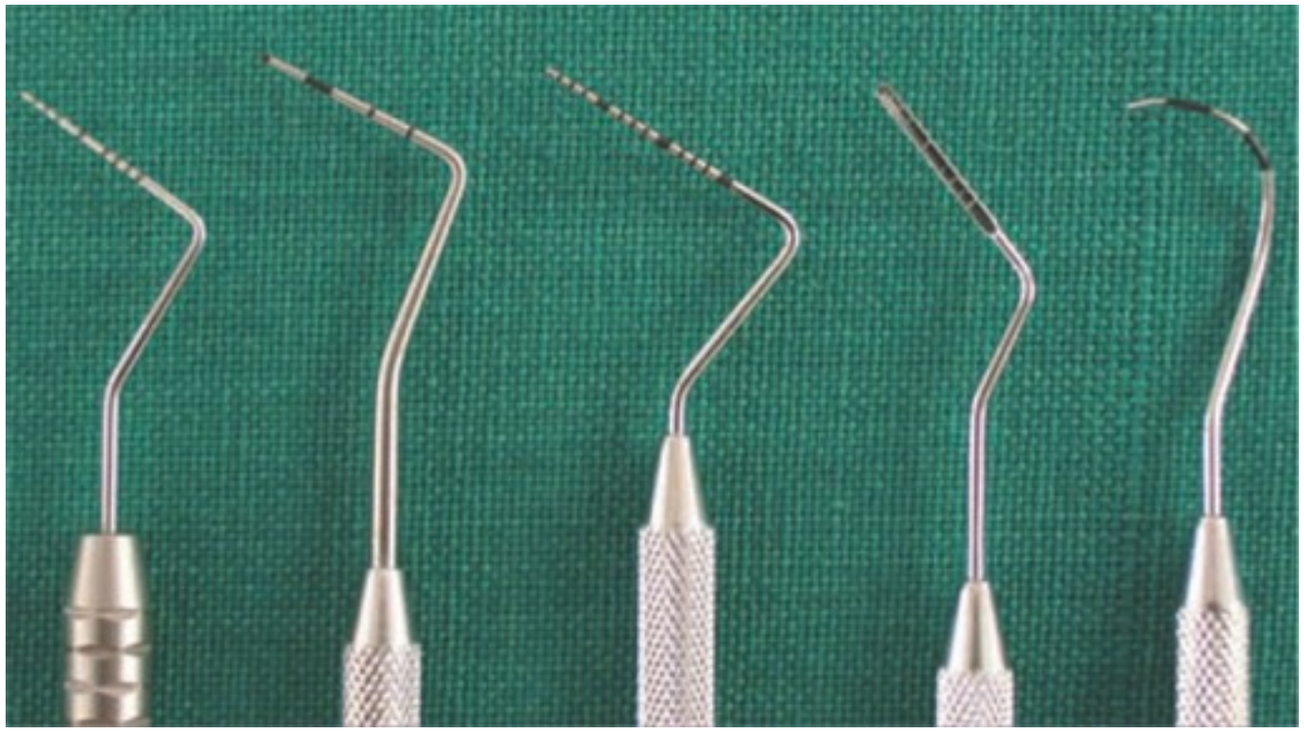



Indirect diagnostic tools - appropriate assessment of pocket depth and clinical attachment level

Intermediate surrogate markers: indirect clinical signs of the extension of inflamation, or periodontal healing

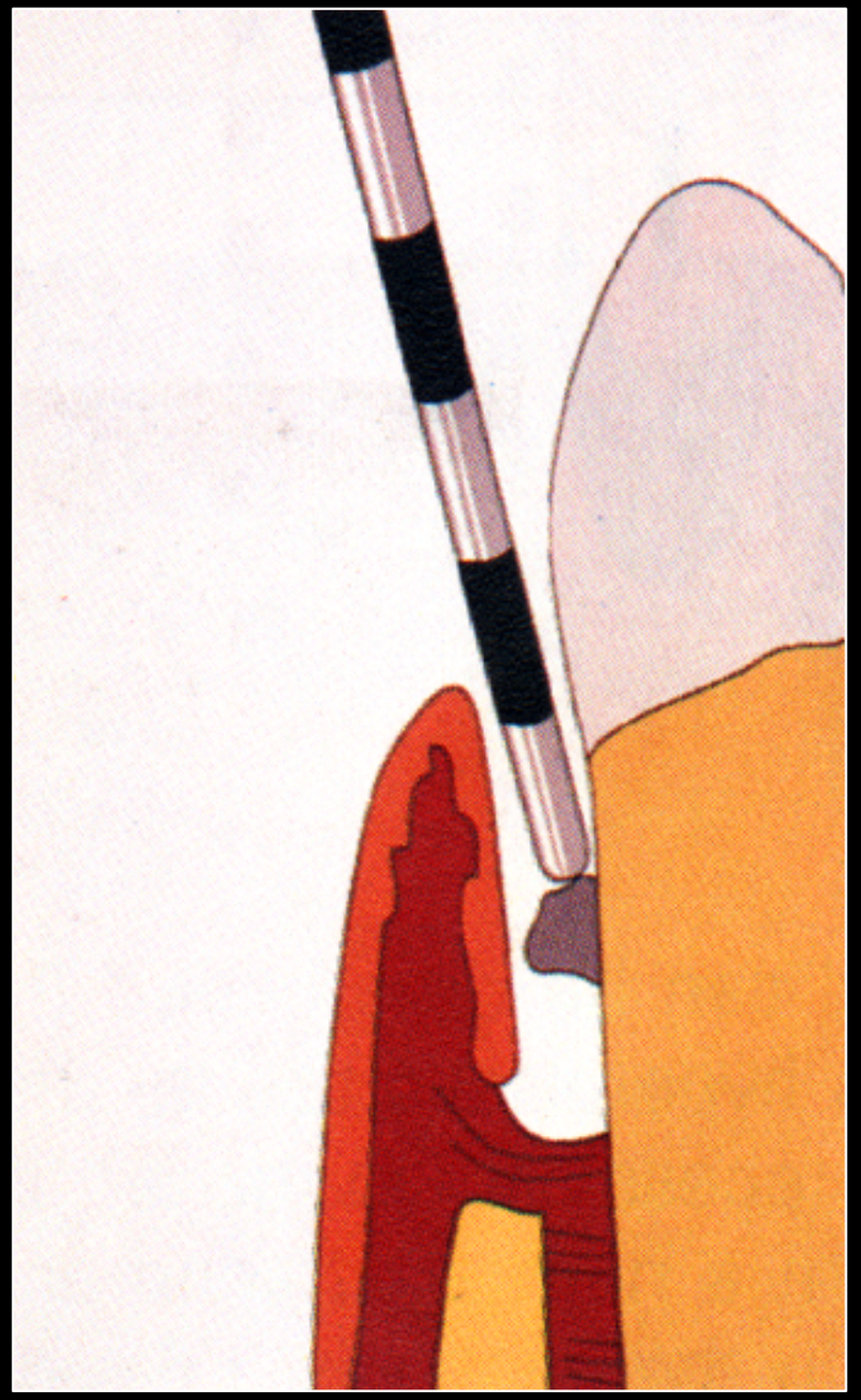

Indirect diagnostic tools - appropriate assessment of pocket depth and clinical attachment level

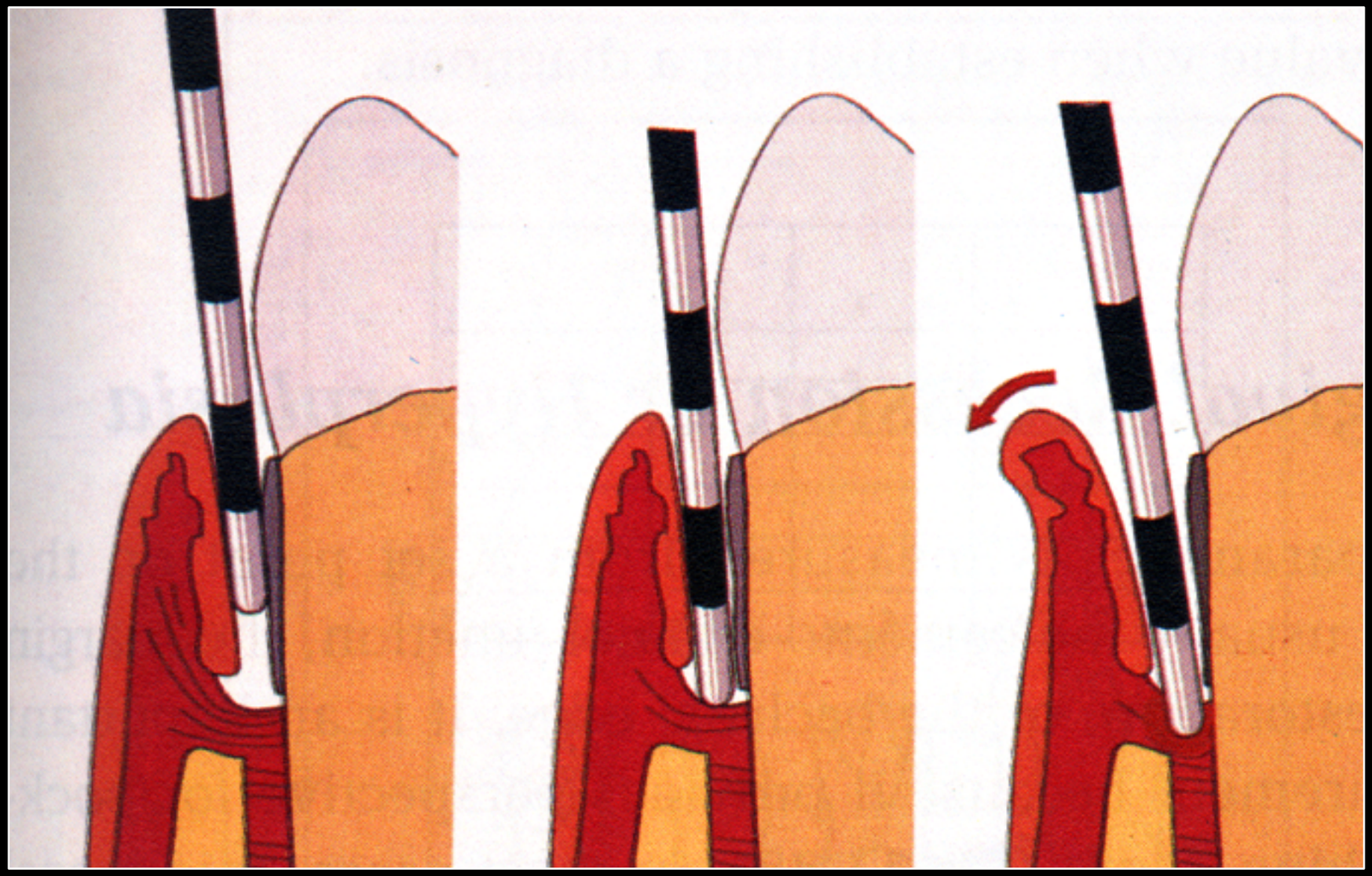

Challenges in diagnosis and classification of periodontal diseases and conditions
Armitage GC. Zhonghua Kou Qiang Yi Xue Za Zhi. 2008 May;43(5):260-3.
Manual periodontal probing in supportive periodontal treatment.
Armitage GC. Periodontol 2000. 1996 Oct;12:33-9.
Microscopic evaluation of clinical measurements of connective tissue attachment levels.
Armitage GC, Svanberg GK, Löe H. J Clin Periodontol. 1977 Aug;4(3):173-90

Assessment of probing attachment level

- the distance in mm from the cemento-enamel junction (CEJ) to the bottom of the probeable gingival/periodontal pocket - clinical attachment level (CAL) - probing attachment level (PAL)

- the difference between the actual probing depth and CAL is the gingival recession (GR)

- influencing factors: thickness of the used probe, force, angulation and positioning of the used probe, the applied pressure, the degree of the inflammation

Indirect diagnostic tools - appropriate assessment of pocket depth and clinical attachment level

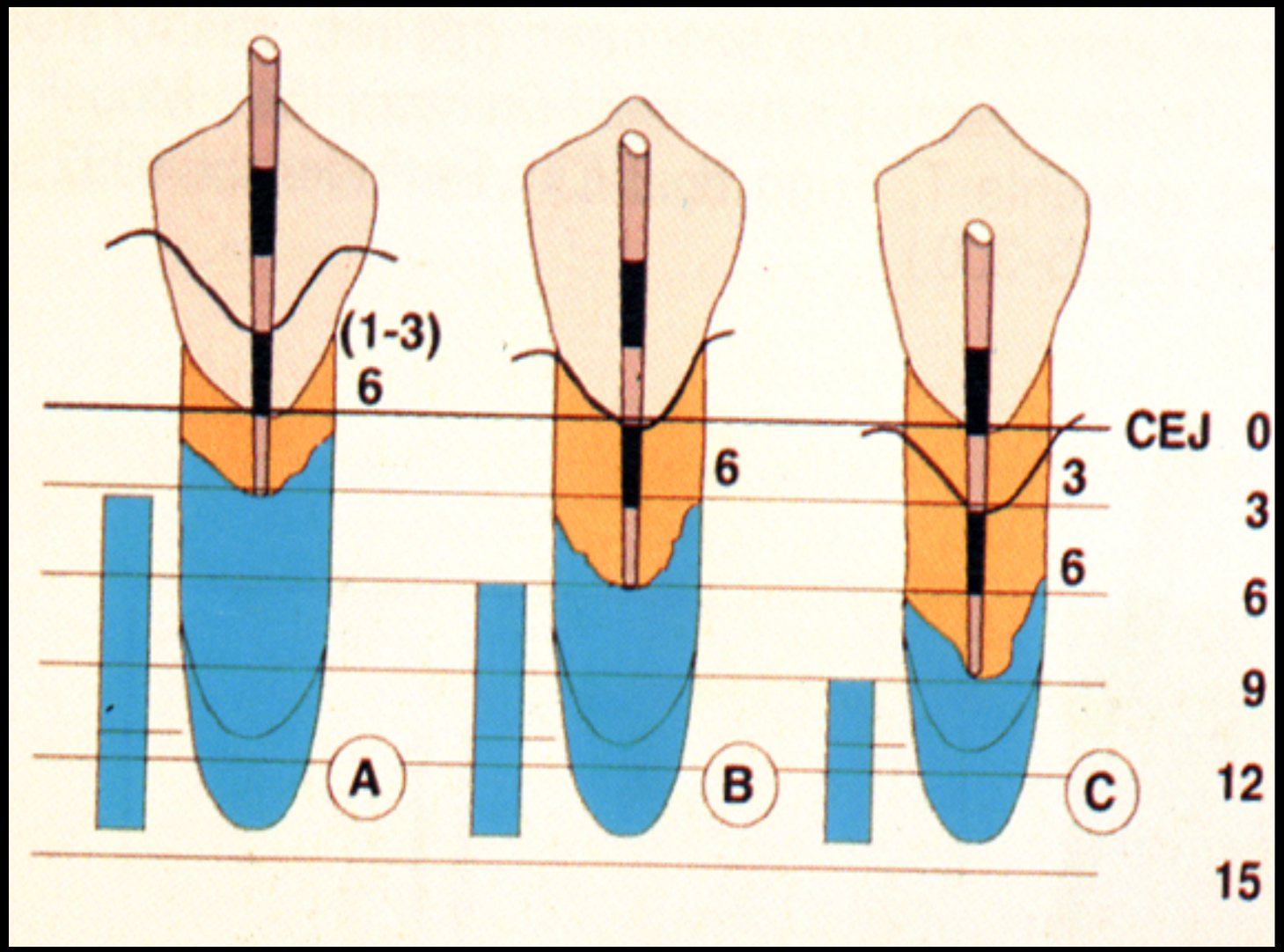

CAL=PPD+GR

Indirect diagnostic tools - appropriate assessment of pocket depth and clinical attachment level

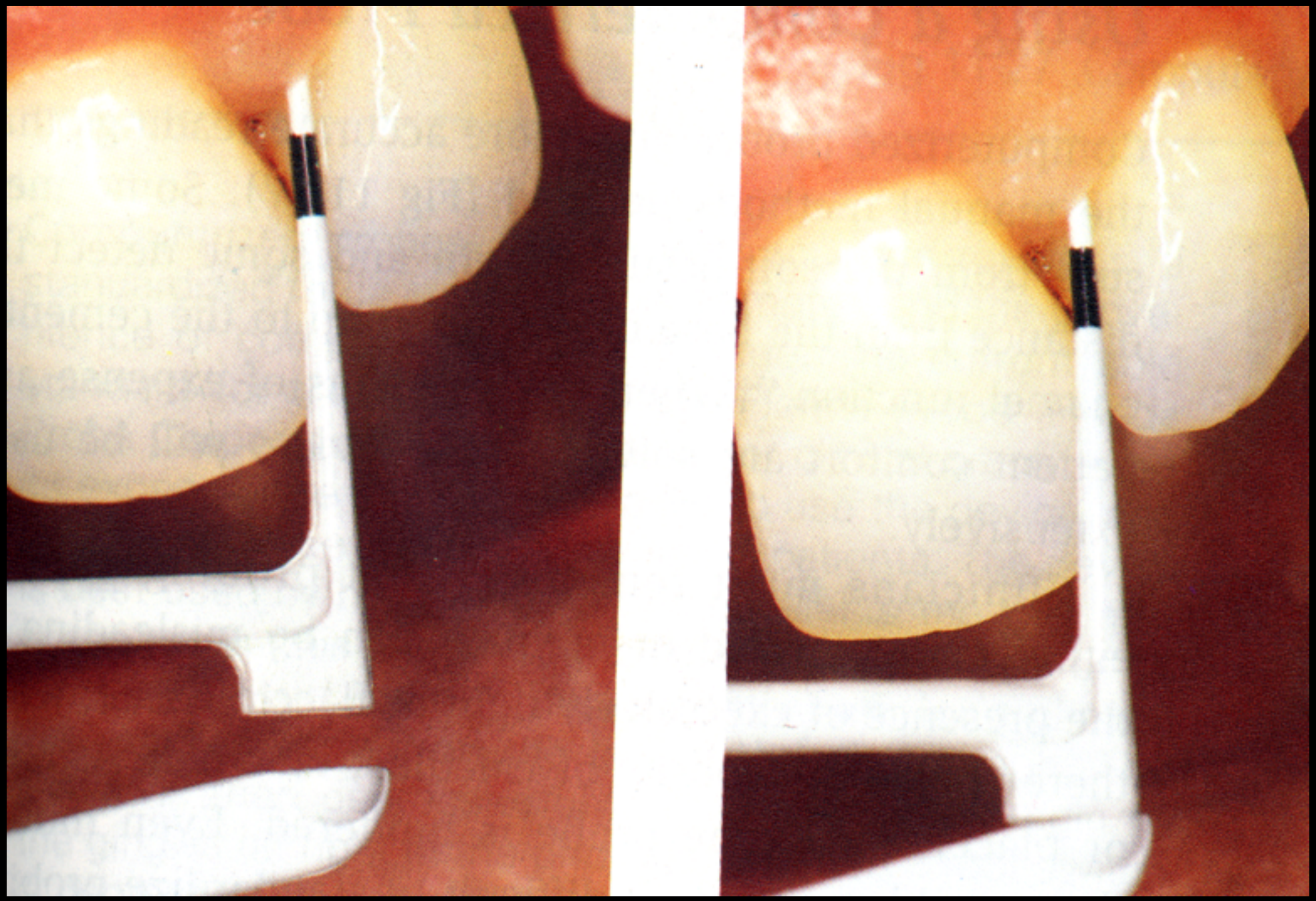

BPE - Basic Periodontal Examination

How to record the BPE?

1. The dentition is divided into 6 sextants:
 - upper right (17 to 14), upper anterior (13 to 23), upper left (24 to 27)
 - lower right (47 to 44), lower anterior (43 to 33), lower left (34 to 37)

2. All teeth in each sextant are examined (with the exception of 3rd molars).

3. For a sextant to qualify for recording, it must contain at least 2 teeth. (If only 1 tooth is
present in a sextant, the score for that tooth is included in the recording for the adjoining
sextant).

4. A WHO BPE probe is used (World Health Organisation probe). This has a “ball end” 0.5 mm in diameter, and a black band from 3.5 to 5.5 mm. Light probing force should be used (20-25 grams).

http://www.bsperio.org.uk/publications/downloads/39_143748_bpe2011.pdf -

BPE - Basic Periodontal Examination

Scoring codes

0 - No pockets >3.5 mm, no calculus/overhangs, no bleeding after probing (black band completely visible)

1 - No pockets >3.5 mm, no calculus/overhangs, but bleeding after probing (black band completely visible)

2 - No pockets >3.5 mm, but supra- or subgingival calculus/overhangs (black band completely visible)

3 - Probing depth 3.5-5.5 mm (black band partially visible, indicating pocket of 4-5 mm)

4 - Probing depth >5.5 mm (black band entirely within the pocket, indicating pocket of 6 mm or more)

* - Furcation involvement

BPE - Basic Periodontal Examination

0	No need for periodontal treatment
1	Oral hygiene instruction (OHI)
2	OHI, removal of plaque retentive factors, including all supra- and subgingival calculus
3	OHI, root surface debridement (RSD)
4	OHI, RSD. Assess the need for more complex treatment; referral to a specialist may be indicated.
*	OHI, RSD. Assess the need for more complex treatment; referral to a specialist may be indicated.

- As a general rule, radiographs to assess alveolar bone levels should be obtained for teeth or sextants where BPE codes 3 or 4 are found.

Information

General case history, dental case history

+

Probing pocket depth (PPD)

Gingival recession (GR)

Full mouth plaque score (FMPS)

Intraoperativ measurements

Bone sounding

Radiographic evaluation

Furcation involvement

Tooth movement

Mucogingival lesions

Full mouth bleeding score (FMBS)

Clinical attachement level (CAL)

Diagnostic tools

Indirect

Probing pocket depth (PPD)

Clinical attachment level (CAL)

Radiographic examination

Furcation involvement

Direct

Gingival recession (GR)

Bone sounding

Intraoperativ measurements

Diagnostic tools

Indirect

Direct

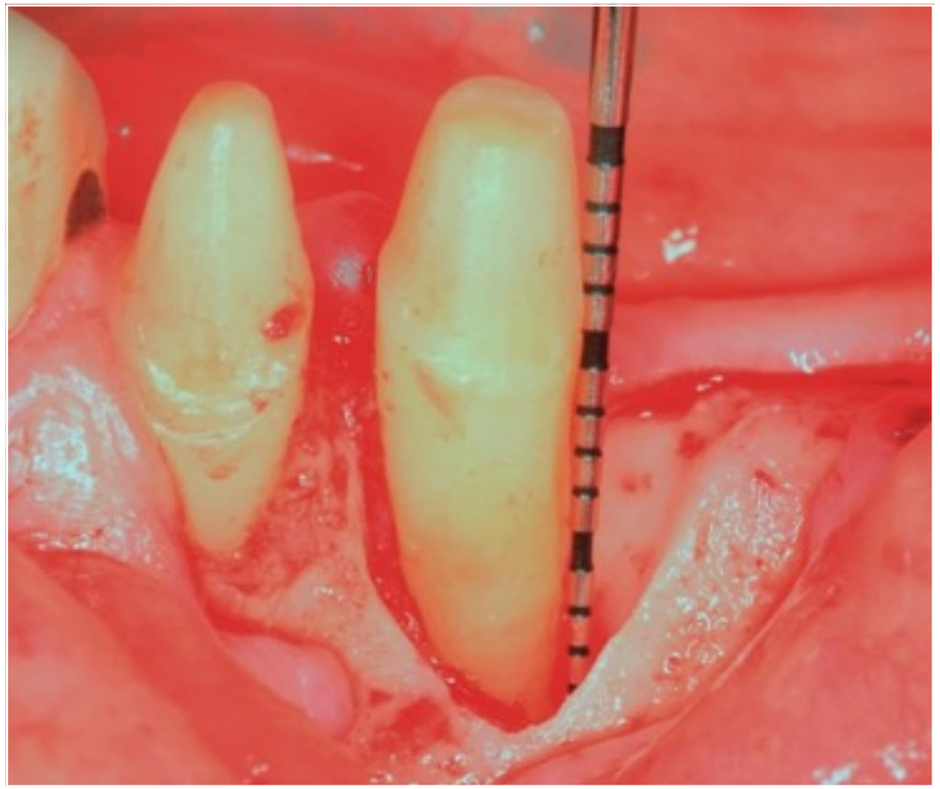

Gingival recession – direct diagnostic parameter - classification after Miller

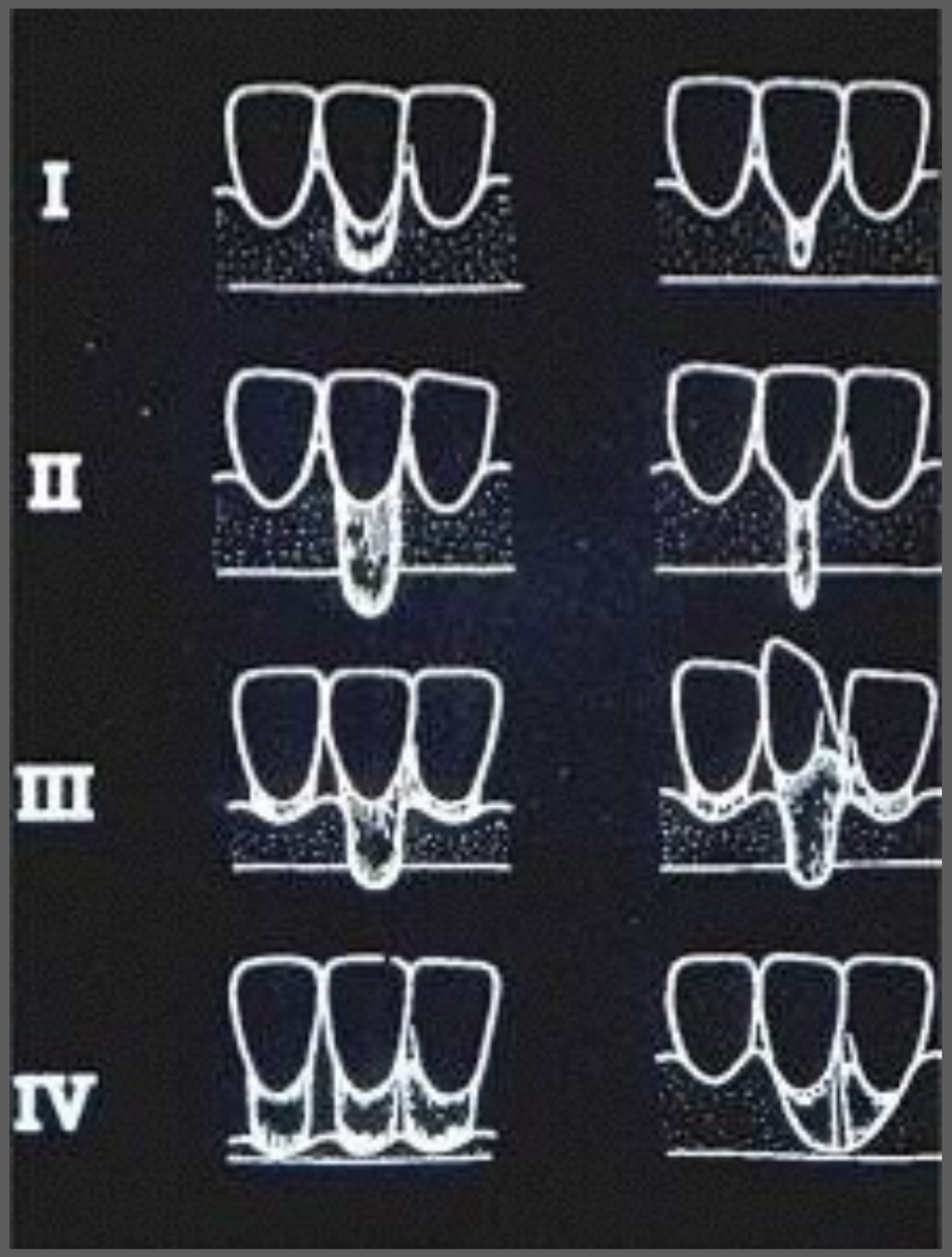

- distance between cemento-enamel junction and gingival margin

Class I:
- marginal tissue recession not extending to the mucogingival junction
- no loss of interdental bone or soft tissue

Class II:
- marginal tissue recession extends to or beyond the mucogingival junction
- no loss of interdental bone or soft tissue

Class III:
- marginal tissue recession extends to or beyond the mucogingival junction
- loss of interdental bone (III.a)
- loss of interdental bone and_soft tissue (III.b)
- or malposition of the tooth

Class IV:
- marginal tissue recession extends beyond the mucogingival junction
- severe bone loss and soft tissue loss interdentally
- and/or severe tooth malposition

To give an objective information about the disease, wich may involve treatment plan too.

Miller PD: „A classification of marginal tissue recession“. 1985, 9-14, Int J Periodontics Restorative Dent.

Gingival recession – direct diagnostic parameter

- GRD: gingival recession depth
- GRW: width of the gingiva recession
- AGW: width of the attached gingiva
- PCD: papilla contact point distance
- PW: papilla width
- PD: pocket depth

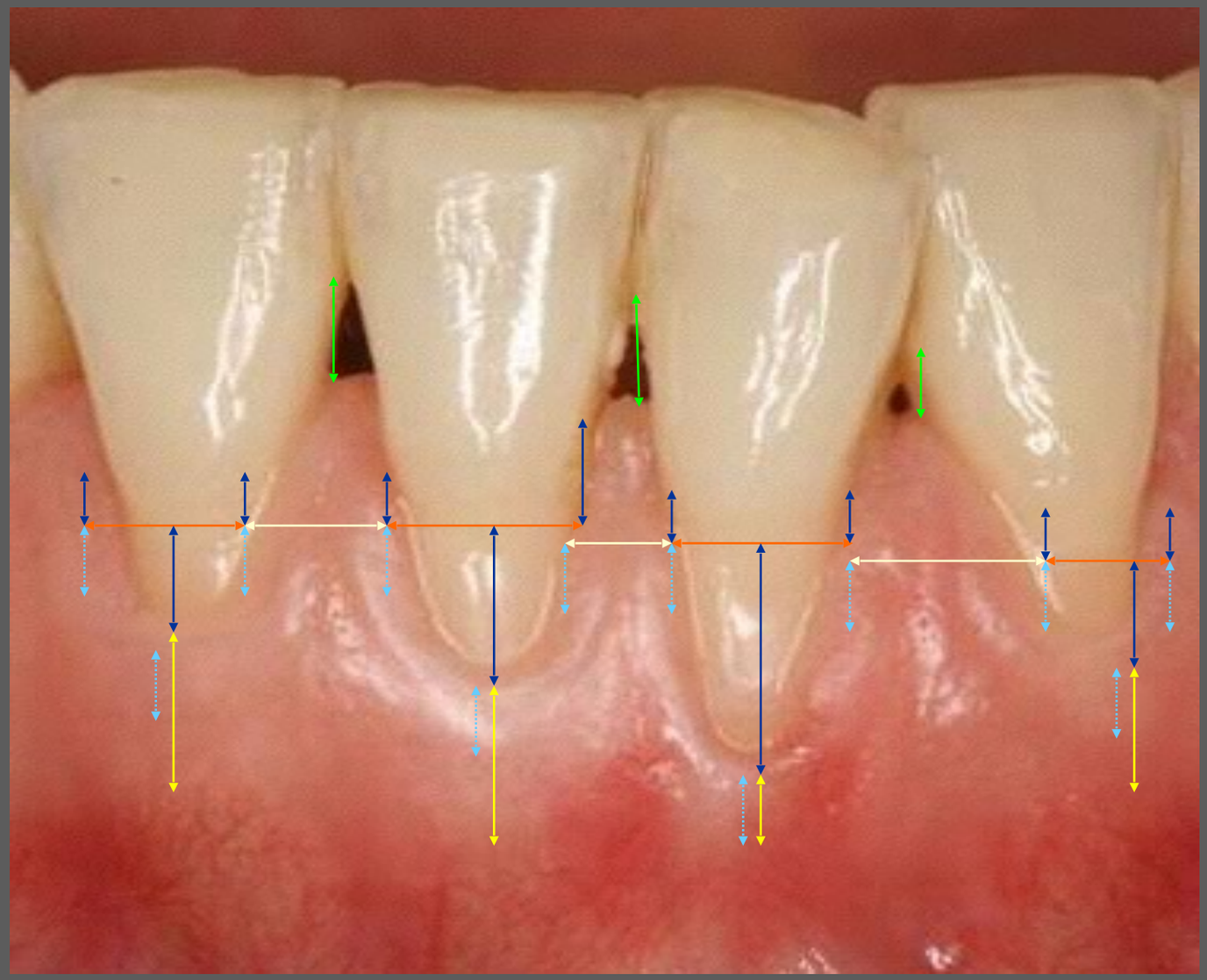

	44			43			42			41			31			32			33			34			
GRM																									**GRM**
GRSZ																									**GRSZ**
KGSZ																									**KGSZ**
PKD																									**PKD**
PSZ																									**PSZ**
PD																									**PD**
BUCCAL																									

Assessment of furcation involvement

- in the progression of periodontitis around multirooted-teeth, the destructive process may involve the supporting structures of the furcation area

- Nabers furcation probe - curved, graduated at 3mm

- depending on the penetration depth:

- I. class - horizontal probing depth less than 3 mm from one or two entrances

- II. class - horizontal probing depth is more than 3 mm from one entrance

- III. class - horizontal probing depth is more than 3 mm from in two or more entrances, “through-and-through” involvement

Assessment of furcation involvement

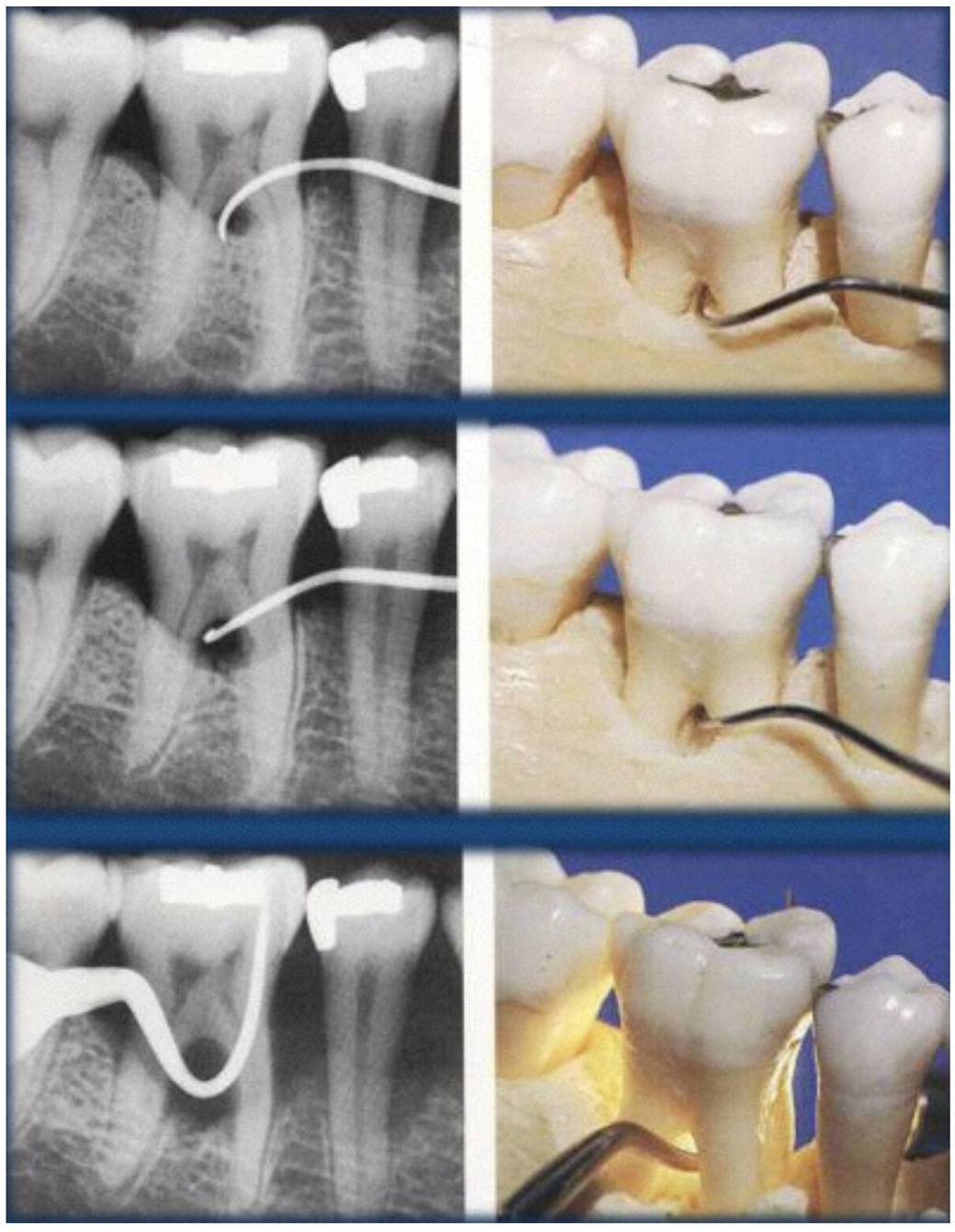

Furcation involvement

Class I.

Class II.

Class III.

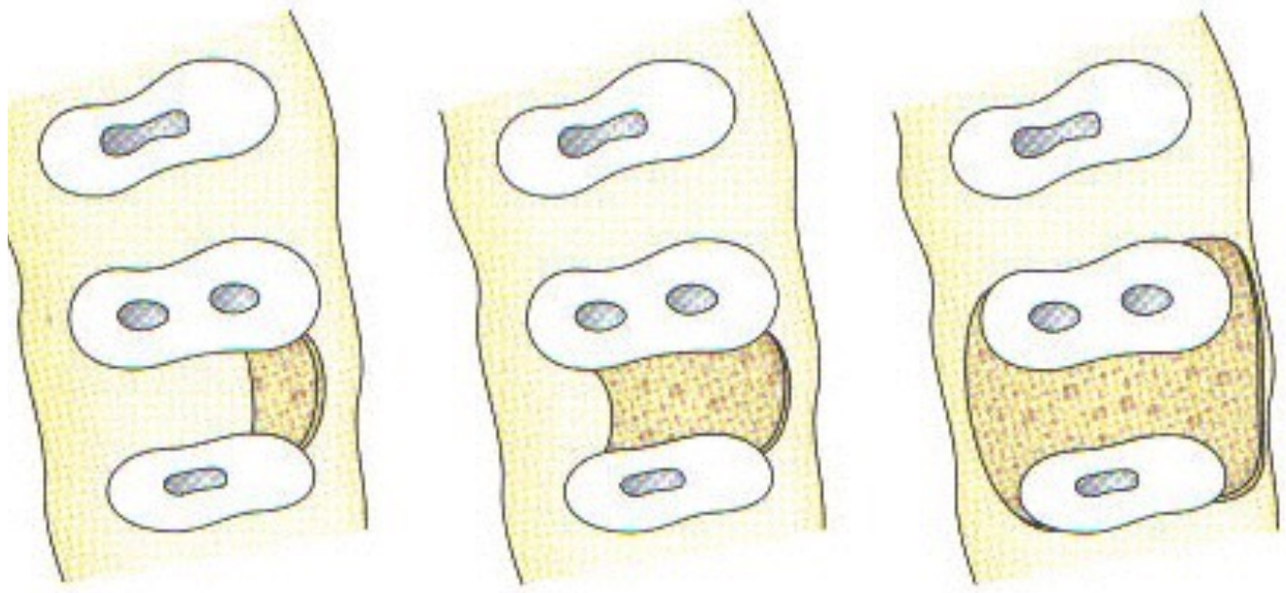

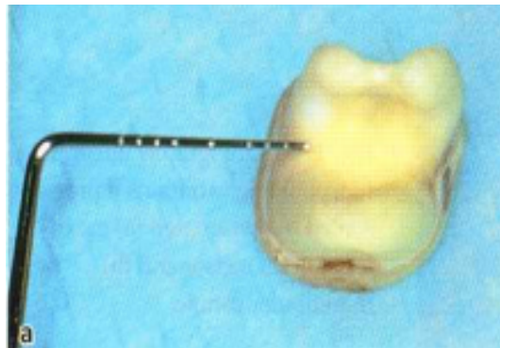

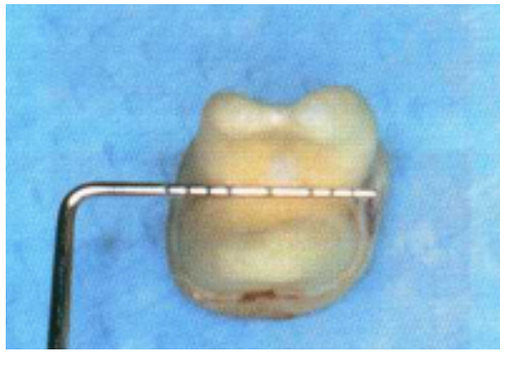

Class I- initial, furcation involvement, vertical bone loss

Class II – incomplete furcation defect, horizontal and vertical bone loss

Class III – complete penetration

Assessment of tooth mobility

- the continuous loss of the supporting tissue during periodontal disease progression may result in increased tooth mobility

- degree 0: “physiological” mobility measured at the crown level, the tooth is mobile in a horizontal direction to 0.1-0.2 mm

- degree 1: increased mobility of the crown of the tooth to at the most 1mm in a horizontal direction

- degree 2: visually increased mobility of the crown of the tooth exceeding 1mm in a horizontal direction

- degree 3: severe mobility, exceeding 1mm in a horizontal direction

- trauma from occlusion!!! - widened periodontal ligament, overloading of the teeth

Radiology - objective diagnostical parameter

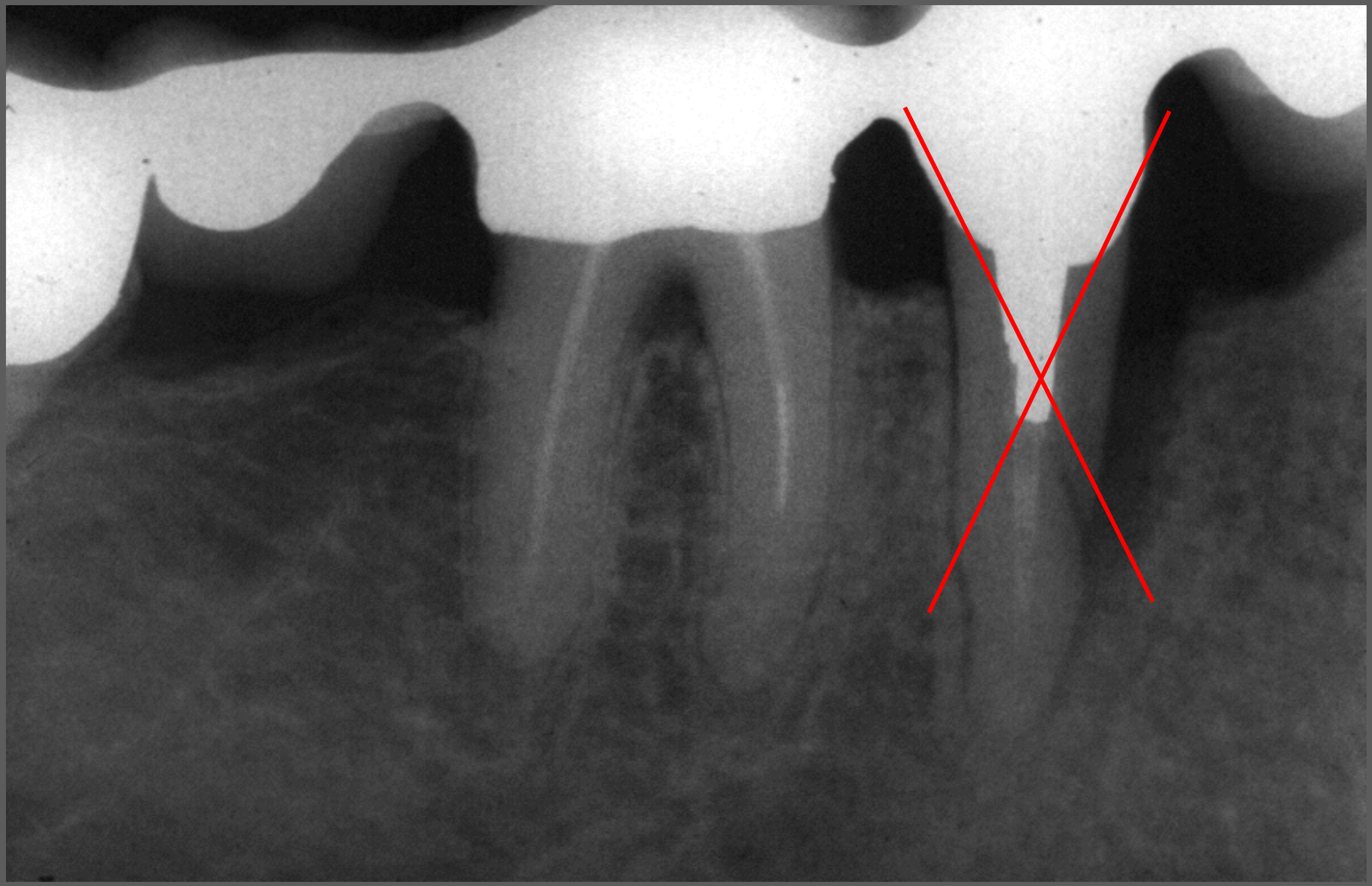

Vertical root fracture

Radiographic examination

- panorama x-ray is just informative
- the height of the alveolar bone and the outline of the bony crest are examined in radiographs
- a long-cone paralleling technique is recommanded
- reproducibility! - silicone templates

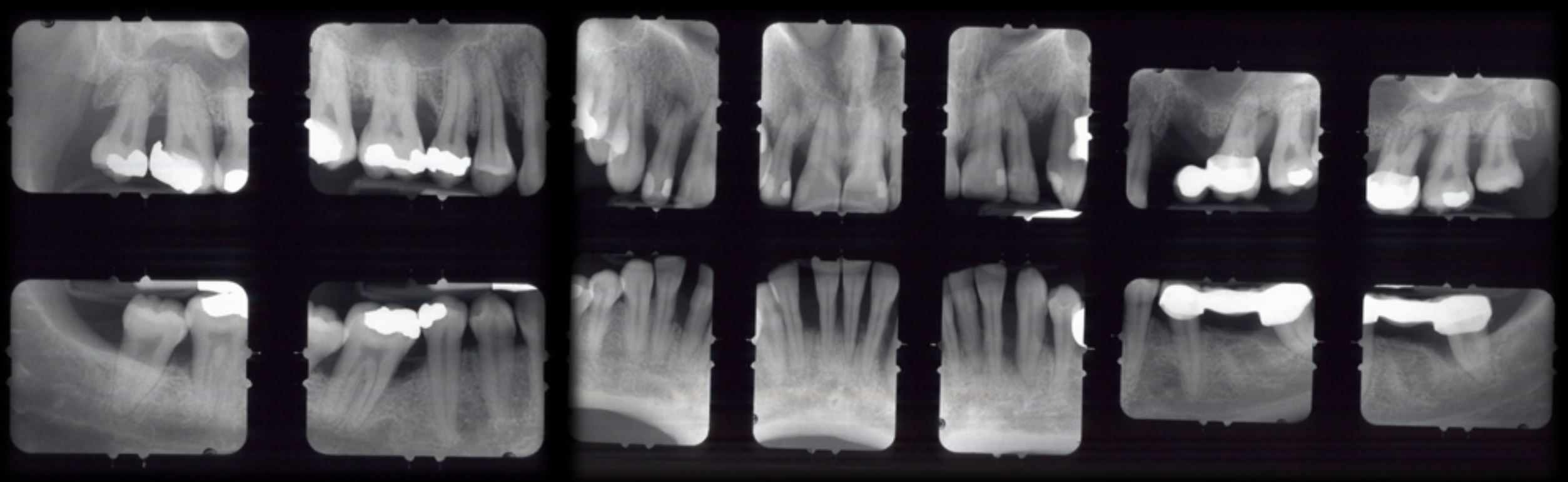

Relevant formulas from the perspectives of the periodontal disease

- tooth crown- CEJ, the presence of plaque retentive factors, the presence of calculus
- limbus alveolaris - the presence of the lamina dura
- interdental/interradicular bone - density, structure
- roots of the tooth - number, shape, divergence, furcation involvement
- periodontal gap - presence, width, form

Interdental bone level, trabecular bone structure

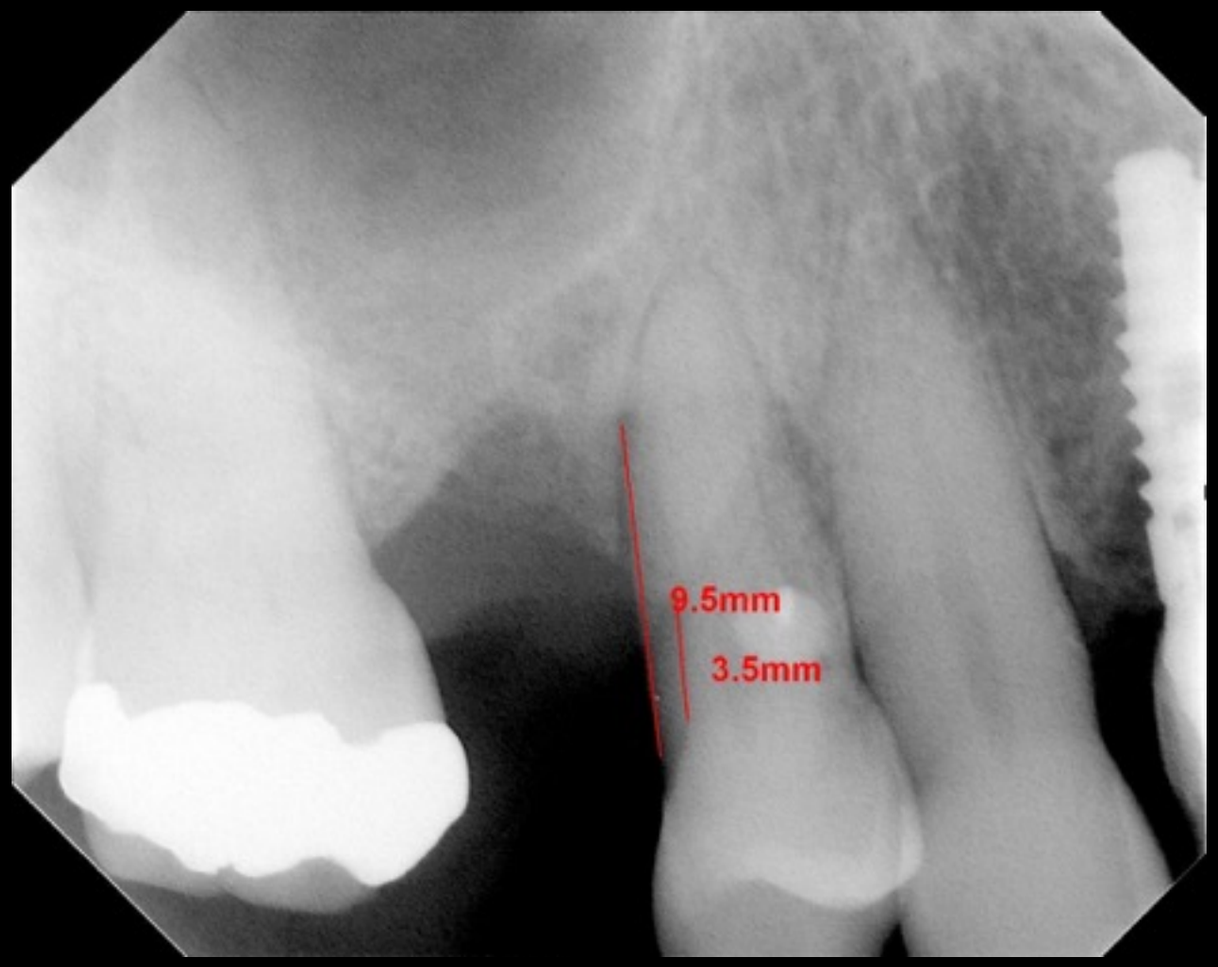

Lamina dura and furcation involvement

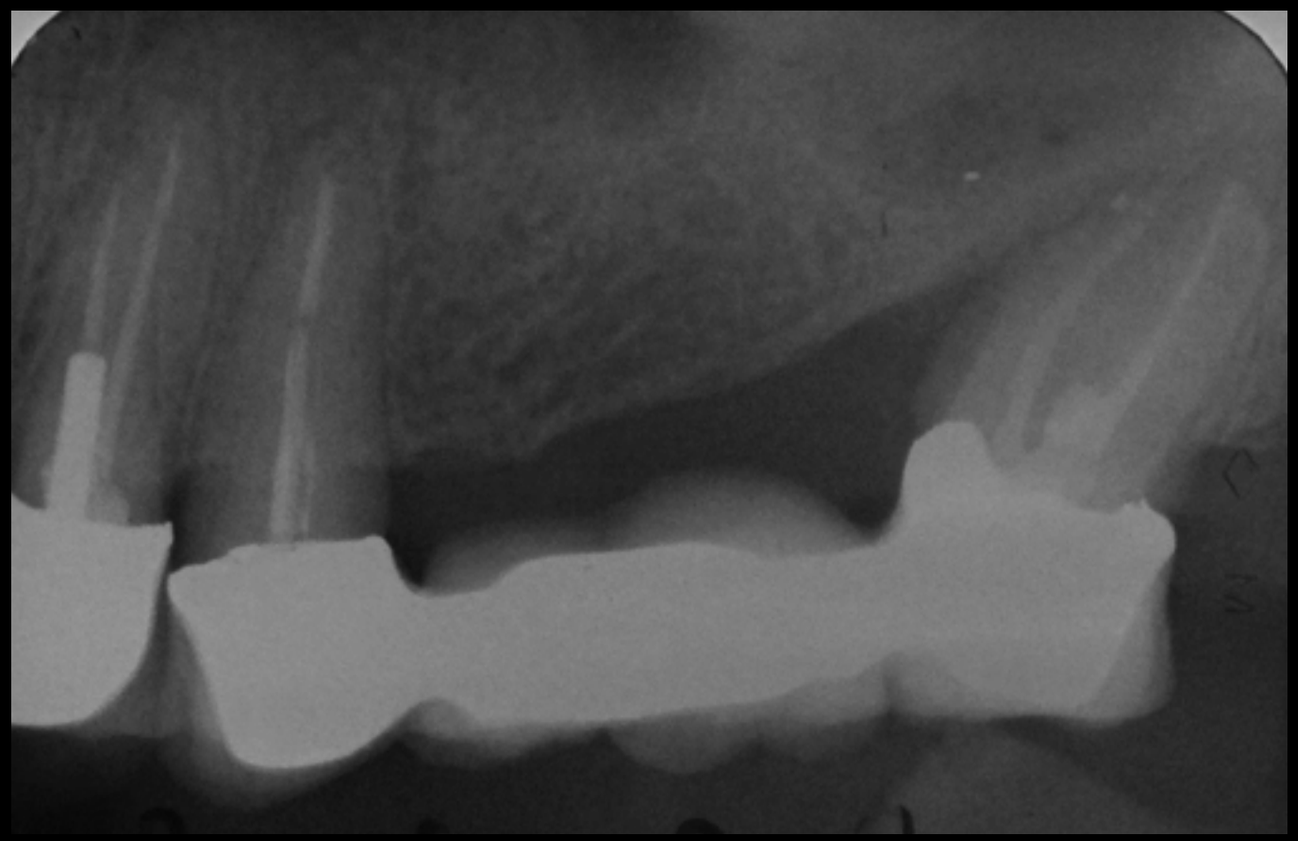

Root length and shape, width of the periodontal gap

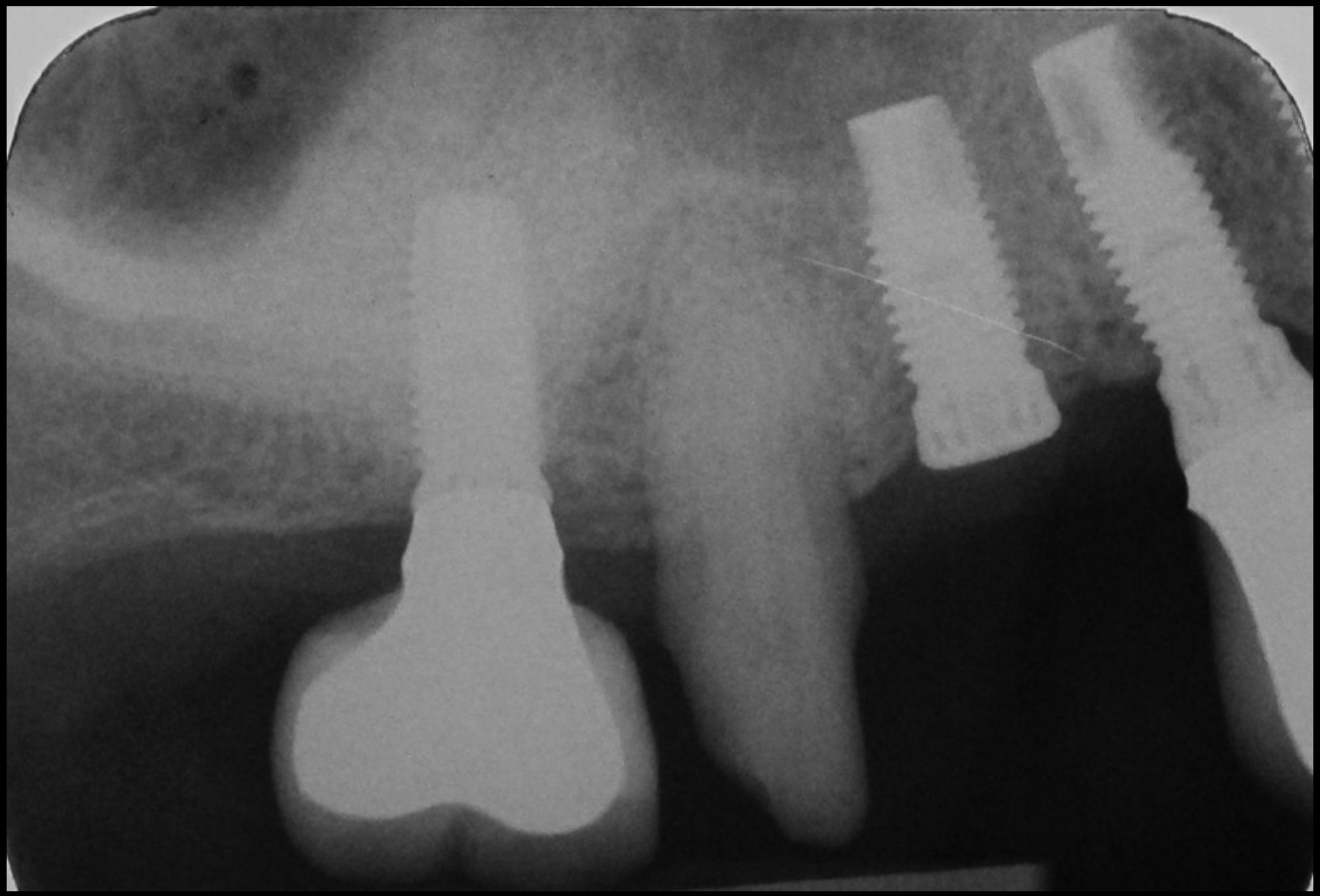

Radiographic characteristics of the healthy periodontium

- limbus alveolaris clearly distancing itself
- lamina dura is located 1-2mm apically from the CEJ
- in slimmer interdental spaces the shape of the limbus alveolaris has a sharpening edge
- in wider interdental spaces it will be rounded

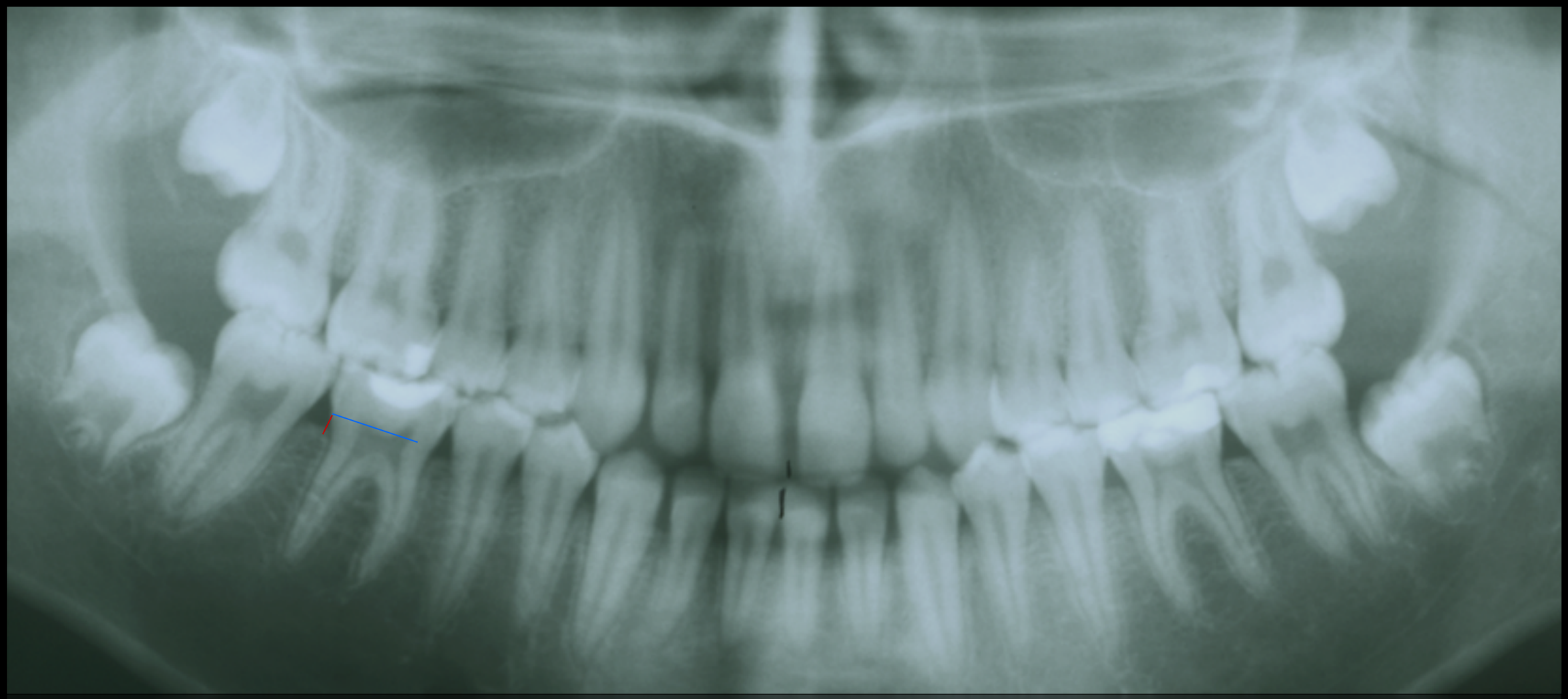

Radiographic characteristics of gingivitis

- is simmilar to healthy periodontium
- interdental septum shows lower density

Radiographic characteristics of the chronic periodontitis

- limbus alveolaris is parallel with the occlusal plane
- more than 2mm from the CEJ apically
- the line of the lamina densa is barely visible or not visible

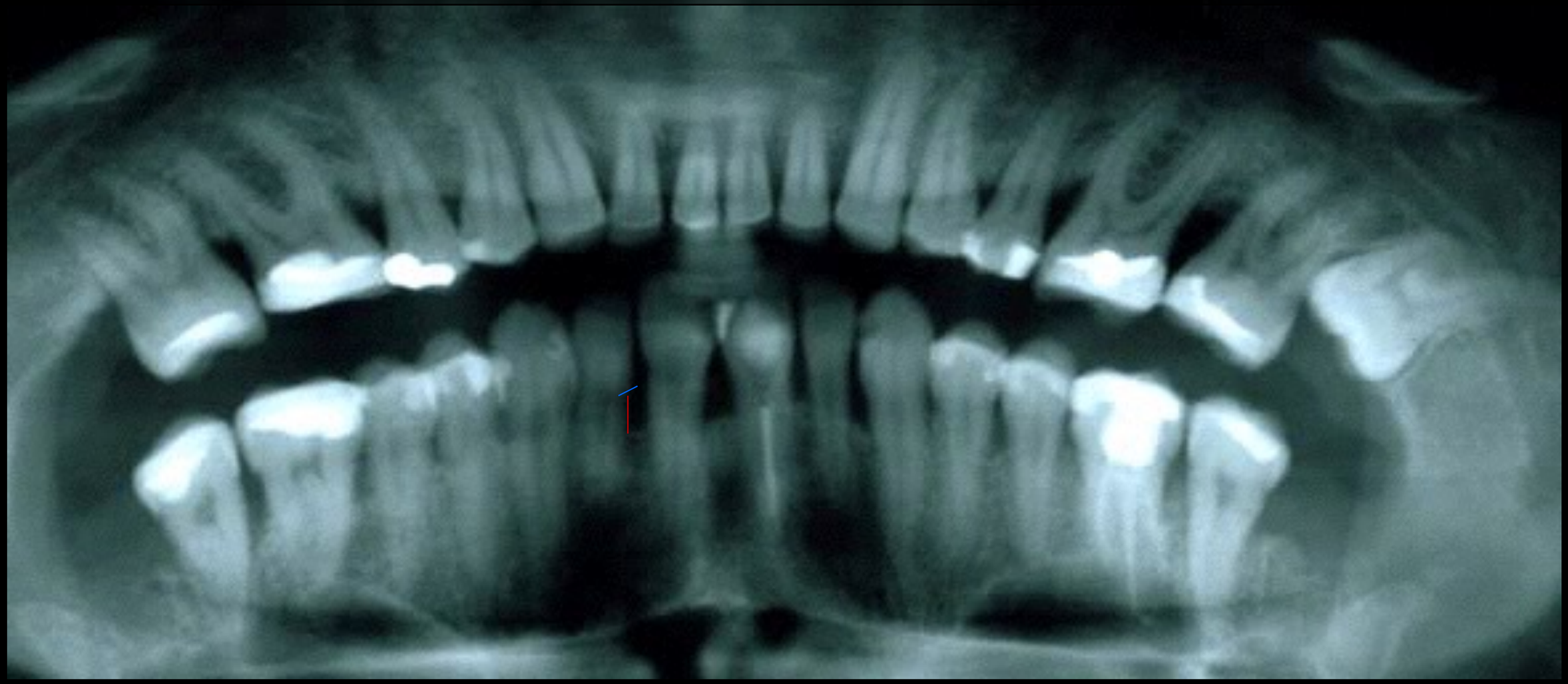

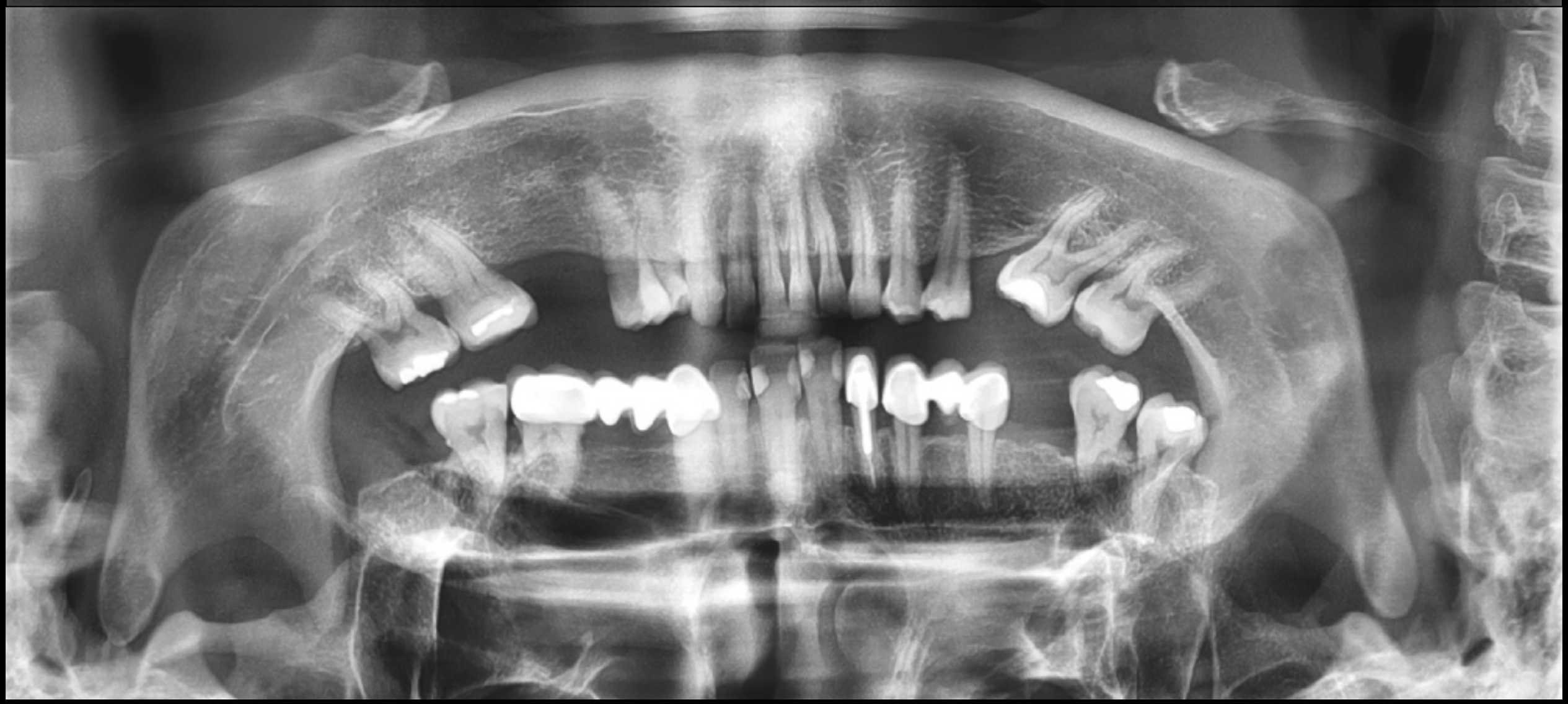

Radiographic characteristics of the repaired chronic periodontitis

- the same as the picture of the chronic periodontitis
- but the line of the lamina densa is clearly visible

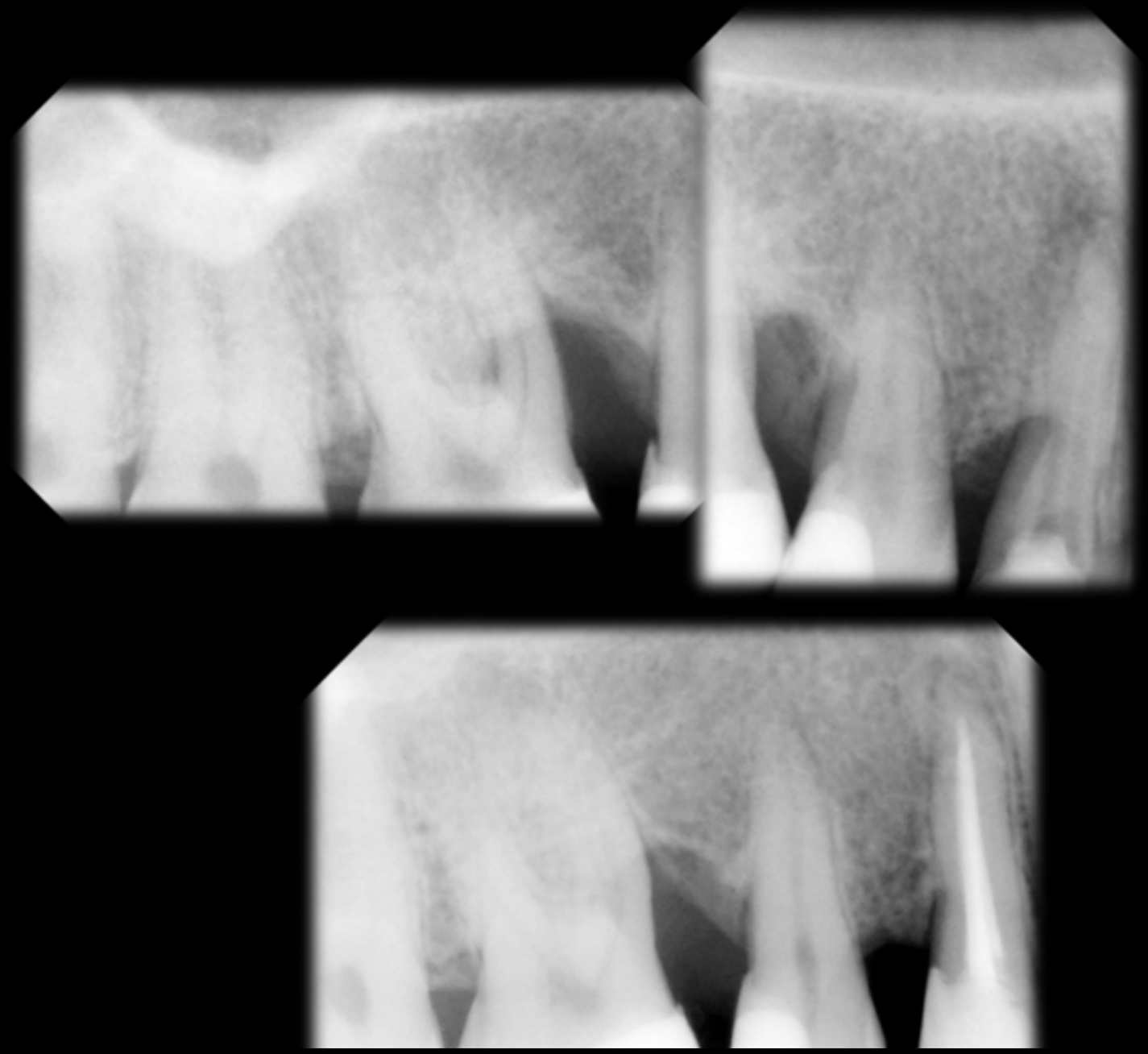

before treatment

after 1 year

after 5 years

Radiographic characteristics of the aggressive periodontitis

- limbus alveolaris is not parallel with the occlusal plane
- more than 2mm from the CEJ apically
- the line of the lamina densa is not visible
- horizonto-vertical bone loss
- building of proximal defects
- circumferential defects around the teeth

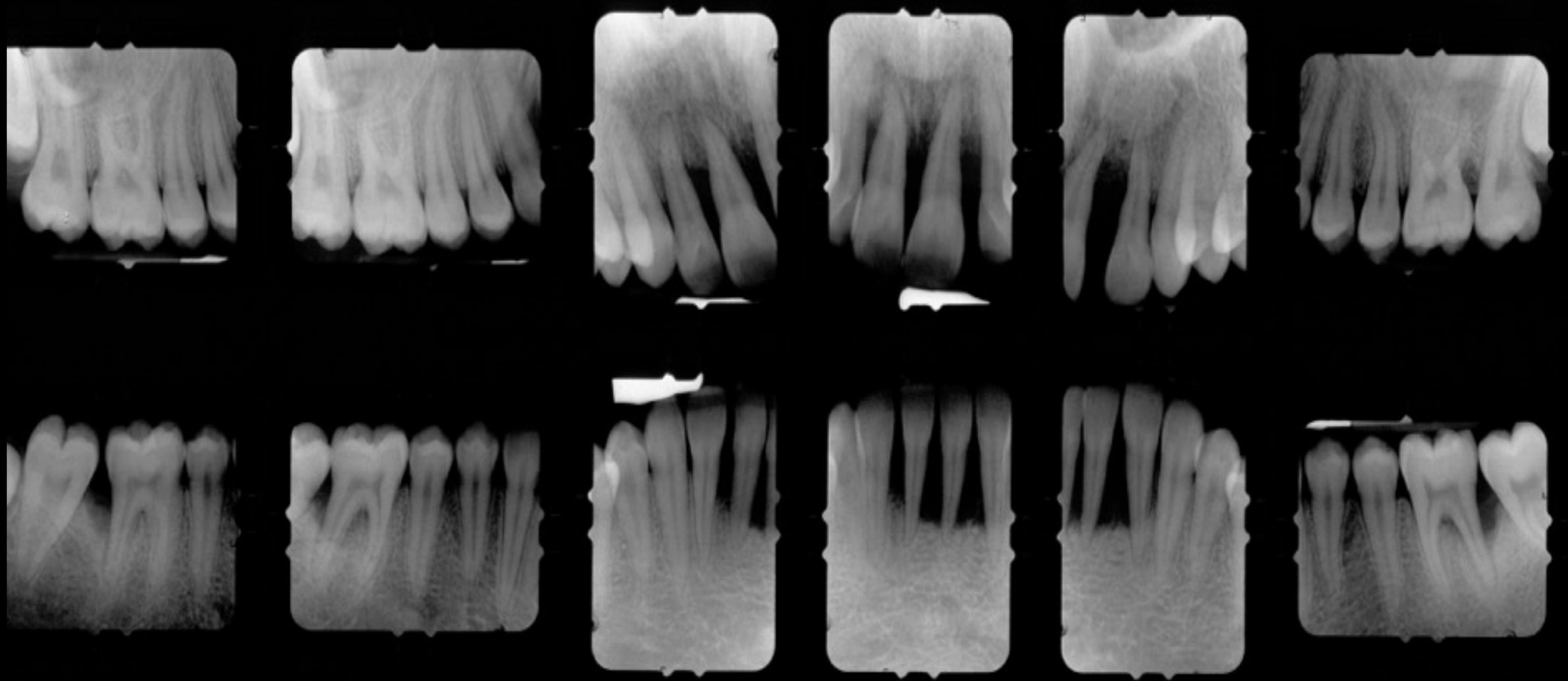

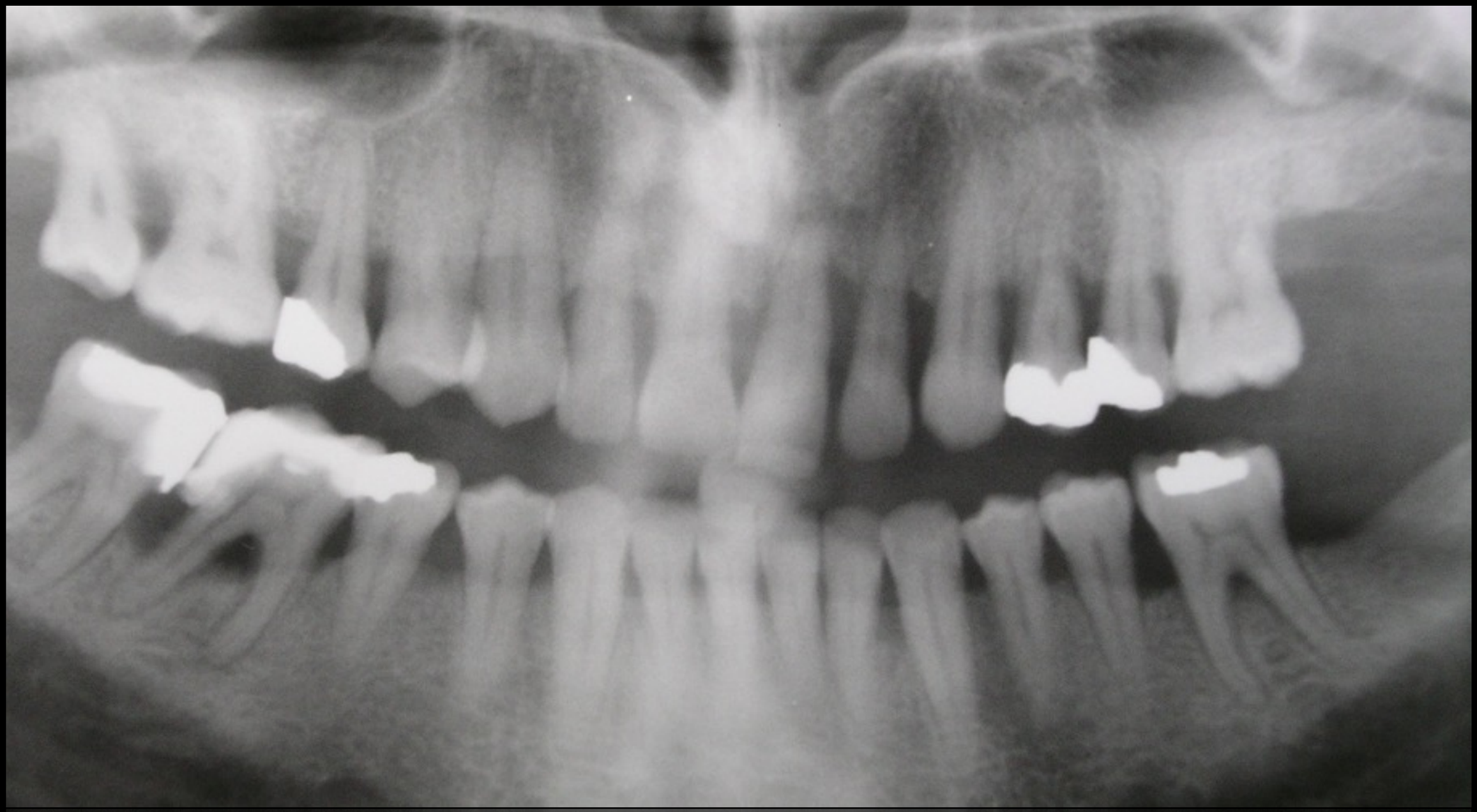

Classification of periodontal defects - Papapanou and Tonetti

Suprabony – intrabony defects

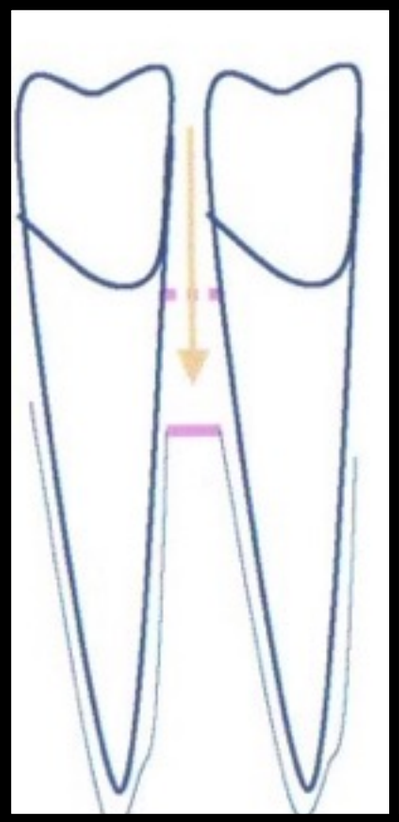

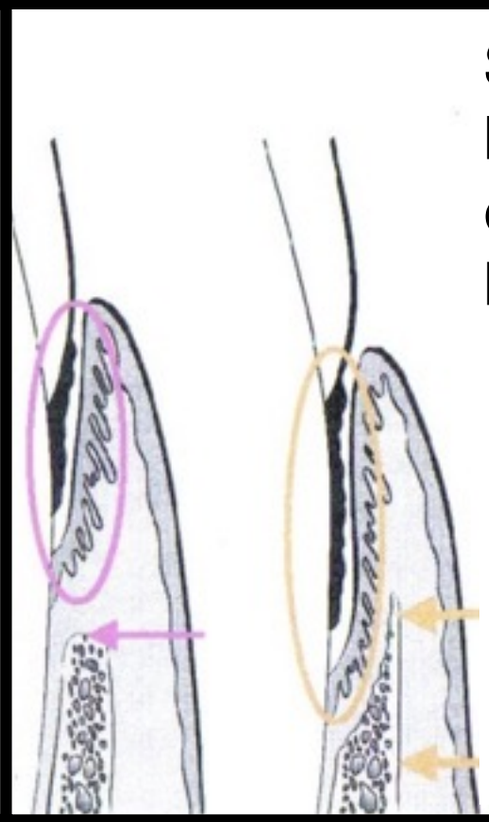

Supraosseal pocket – horizontal bone loss, epithelial migration above bone level

Intraosseal pocket – vertical bone loss, epithelial migration beyond the highest level of the alveolar crest

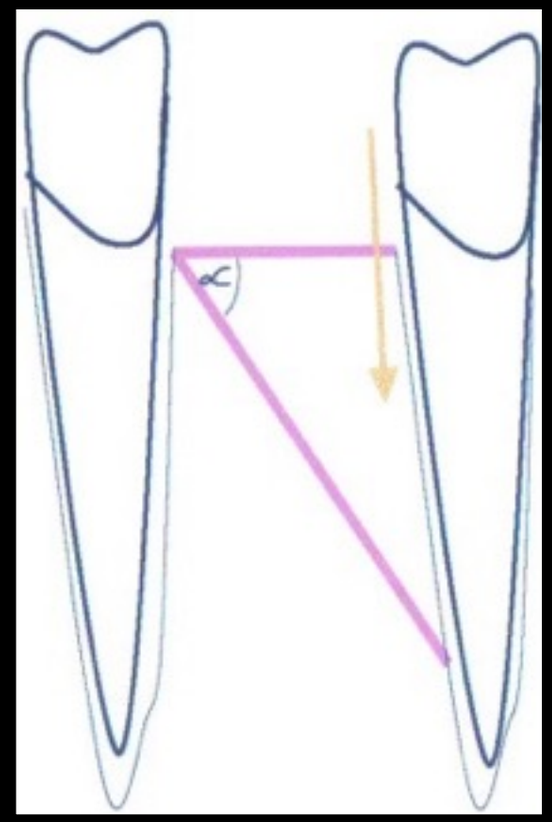

Papapanou PN, Tonetti MS..
Diagnosis and epidemiology of periodontal osseous lesions.
Periodontol 2000. 2000 Feb;22:8-21. Review

Intrabony periodontal defects

Regenerative capacity depends on number and position of the maintained periodontal walls

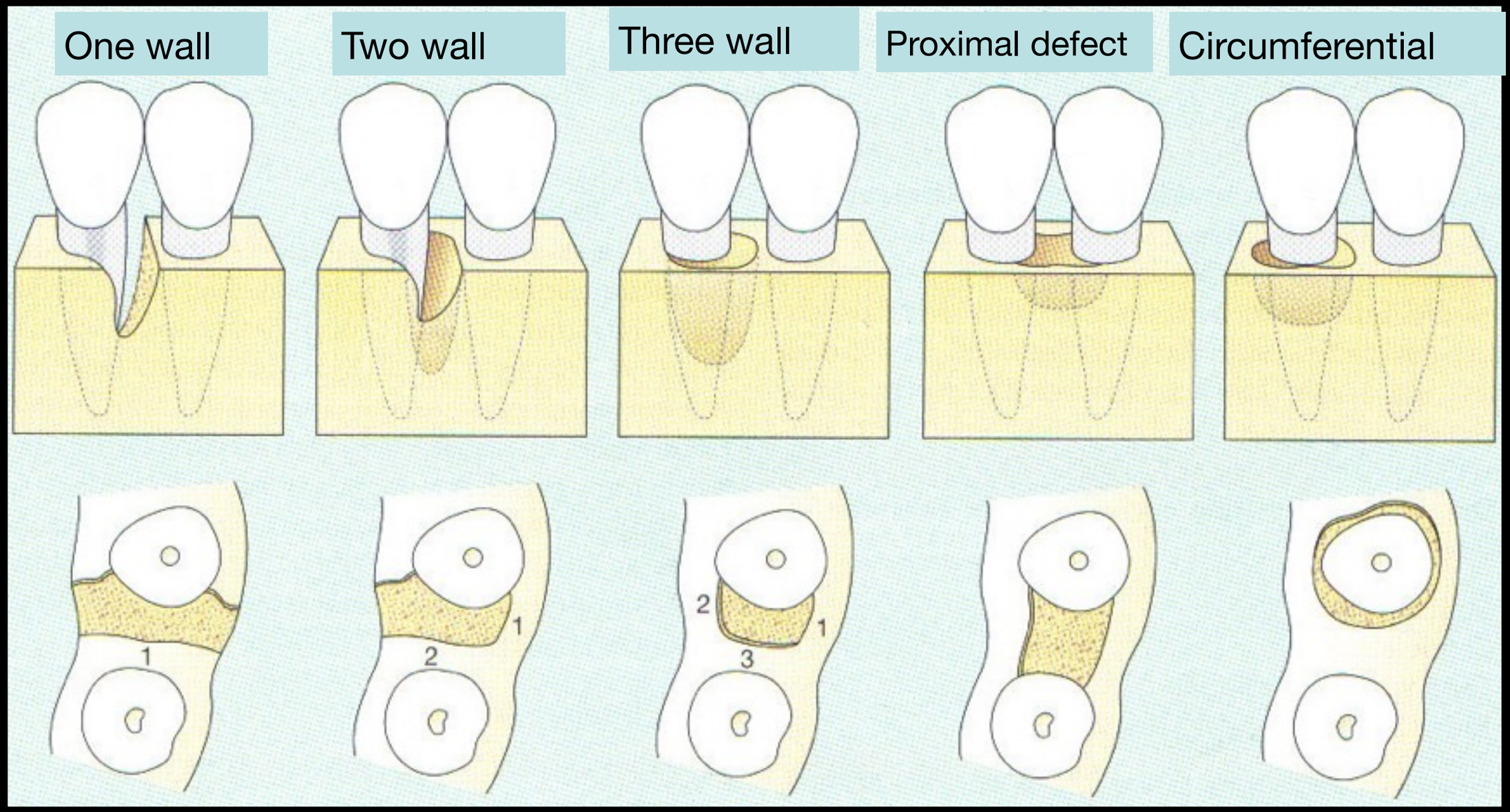

Goldman HM, Cohen DW.
The infrabony pockets. Classification and treatment.
J Periodontol 38, 455 (1958)

Kalpidis DR, Ruben MP.
Treatment of Intrabony Periodontal Defects With Enamel Matrix Derivative: A Literature Review;
Journal of Periodontology November 2002, Vol. 73, No. 11: 1360-1376.

Diagnostic tools

Indirect

- Probing pocket depth (PPD)
- *Clinical attachment level (CAL)*
- *Radiographic examination*
- *Furcation involvement*

Direct

- *Gingival recession (GR)*
- *Bone sounding*
- *Intraoperativ measurements*

Pocket depth, as diagnostical problem- bone sounding

Combined treatment: Emdogain-Bio-Oss, Bio-Gide (collagene) membrane

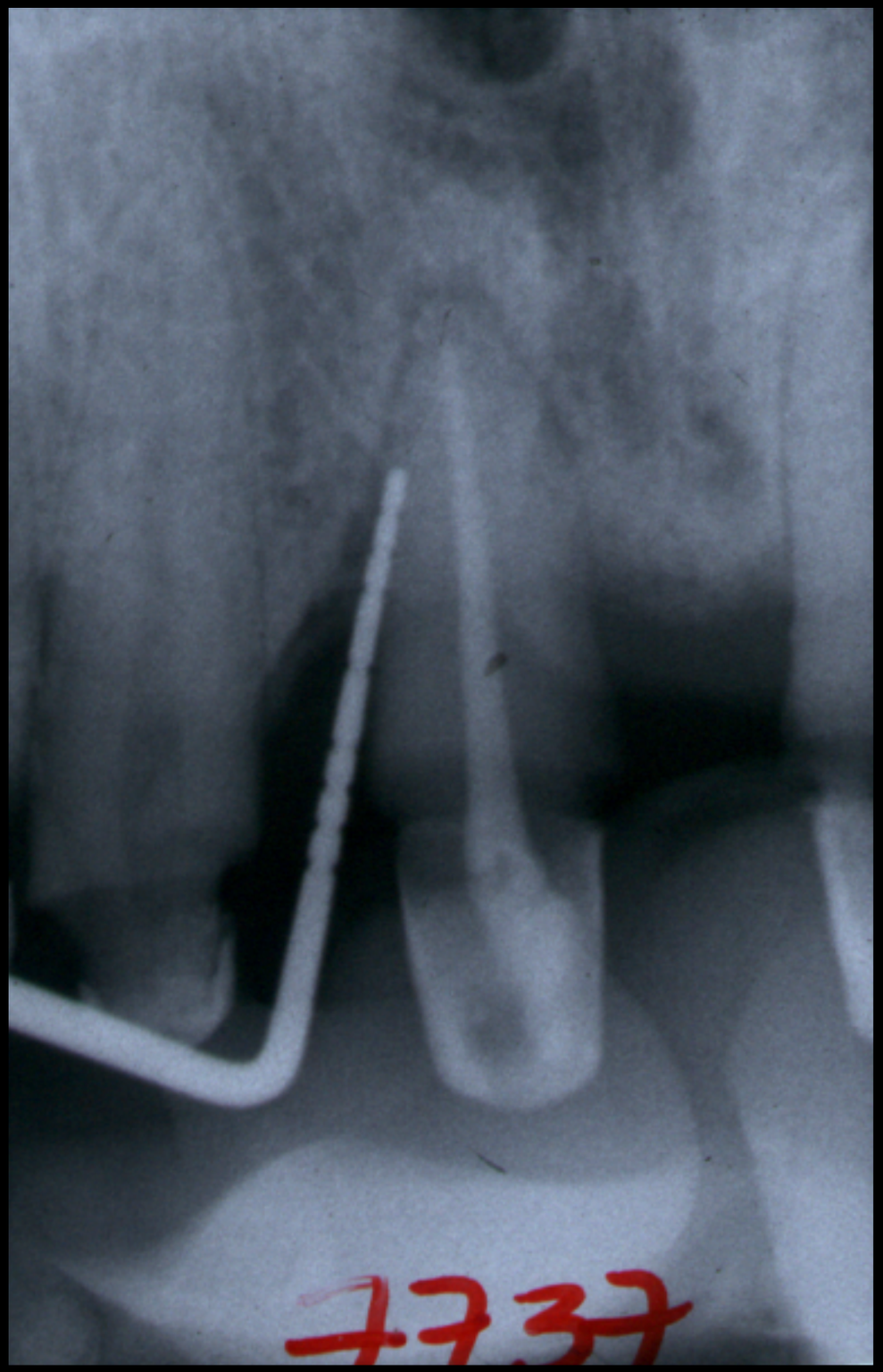

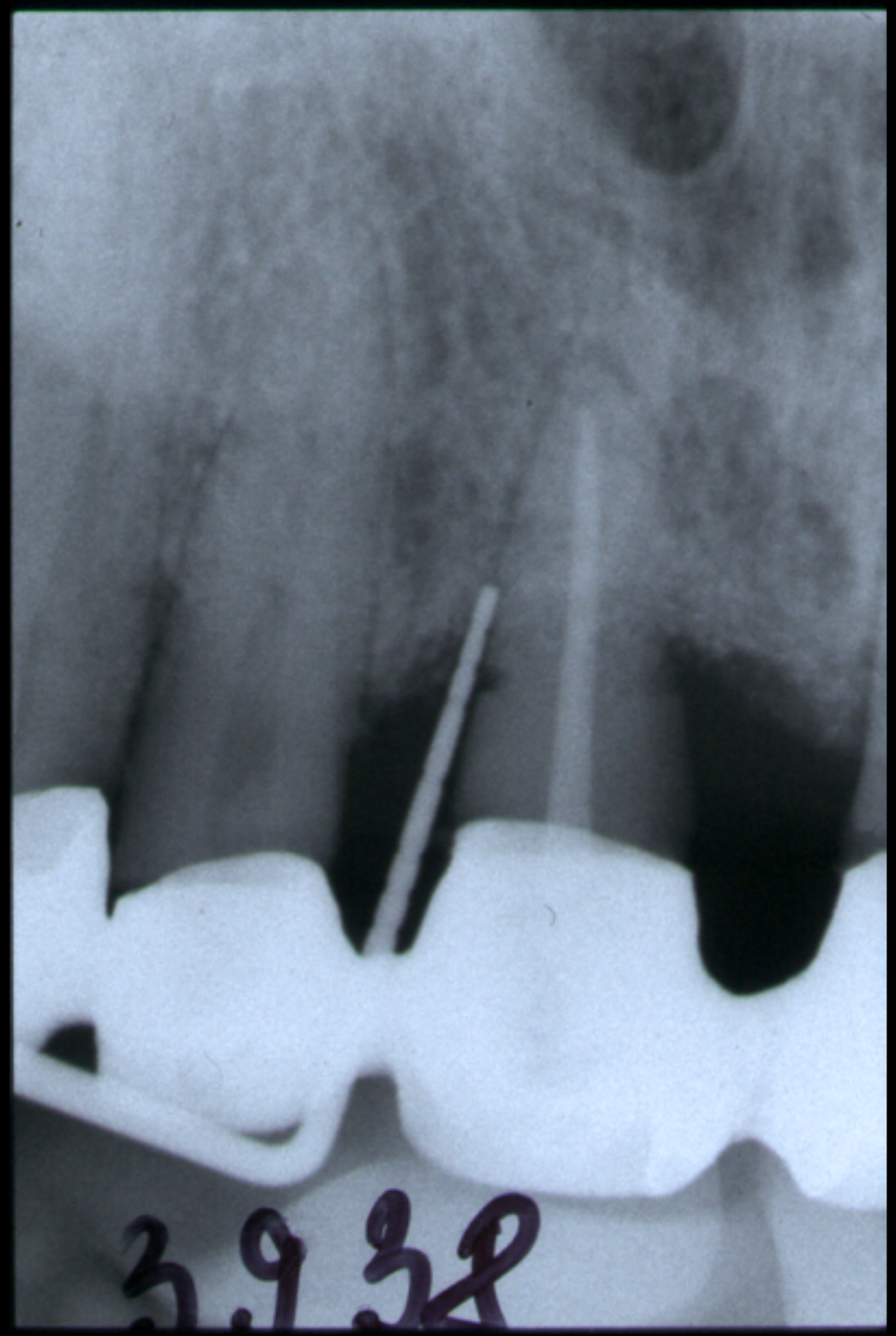

Pocket depth, as diagnostical problem

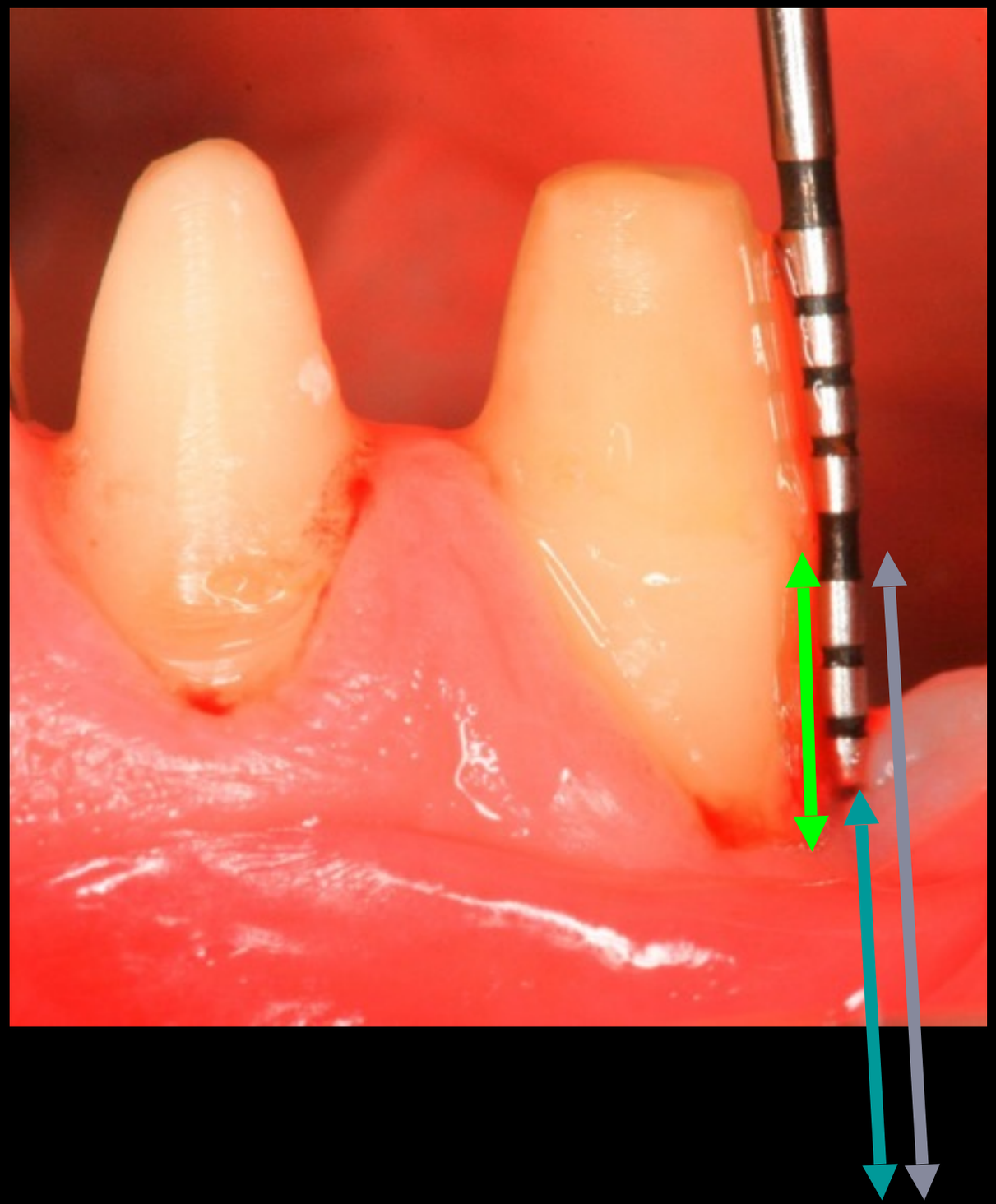

Probing pocket depth (PPD - PD): distance between gingival margin and pocket base

Gingival recession (GR): distance between CEJ and gingival margin

Clinical attachment level (CAL – PAL - RAL): distance between CEJ and gingival margin

Pocket depth, as diagnostical problem

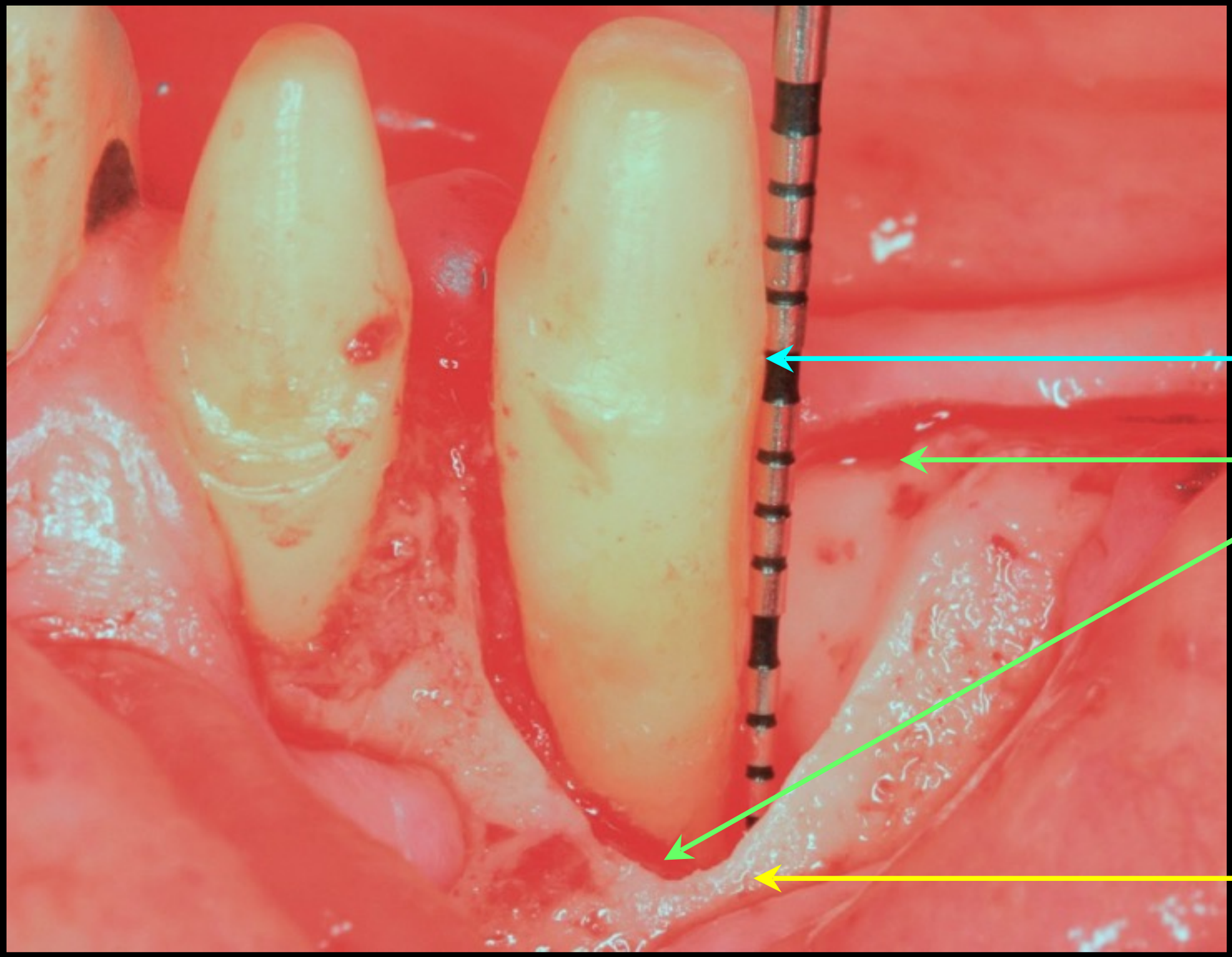

Eickholz P, Hörr T, Klein F, Hassfeld S, Kim TS.
Radiographic parameters for prognosis of periodontal healing of infrabony defects: Two different definitions of defect depth. J Periodontol 2004;75:399-407.
Kim TS, Knittel M, Dörfer C, Steinbrenner H, Holle R, Eickholz P.
Comparison of two types of synthetic biodegradable barriers for GTR in interproximal infrabony defects. Clinical and radiographic 24-month results. Int J Periodontics Restorative Dent 2003;23: 481-489.

Pocket depth, as diagnostical problem

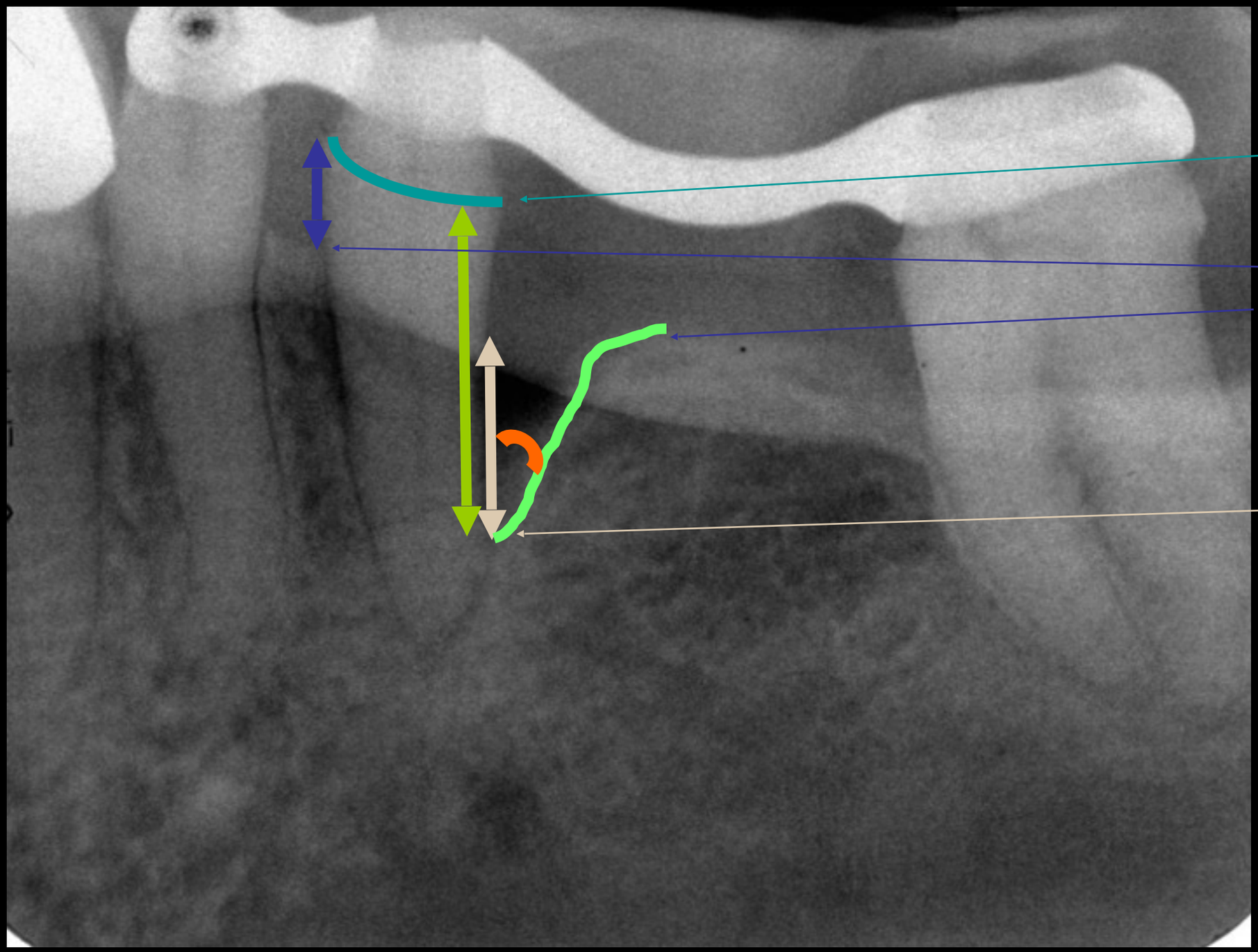

Cemento-enamel junction (CEJ)

Level of the healthy alveolus (AC): a the highest point of the intraabony defect from CEJ

Intrabony component of the defect (**Intra)**

Angle of the intrabony defect

Basis of the pocket (BD) : Radiologically deepest point from the CEJ

Eickholz P, Hörr T, Klein F, Hassfeld S, Kim TS.
Radiographic parameters for prognosis of periodontal healing of infrabony defects: Two different definitions of defect depth. J Periodontol 2004;75:399-407.

Kim TS, Knittel M, Dörfer C, Steinbrenner H, Holle R, Eickholz P.
Comparison of two types of synthetic biodegradable barriers for GTR in interproximal infrabony defects. Clinical and radiographic 24-month results. Int J Periodontics Restorative Dent 2003;23: 481-489.

Comparison of direct intraoperativ measurements with precision, digital radiological measurements

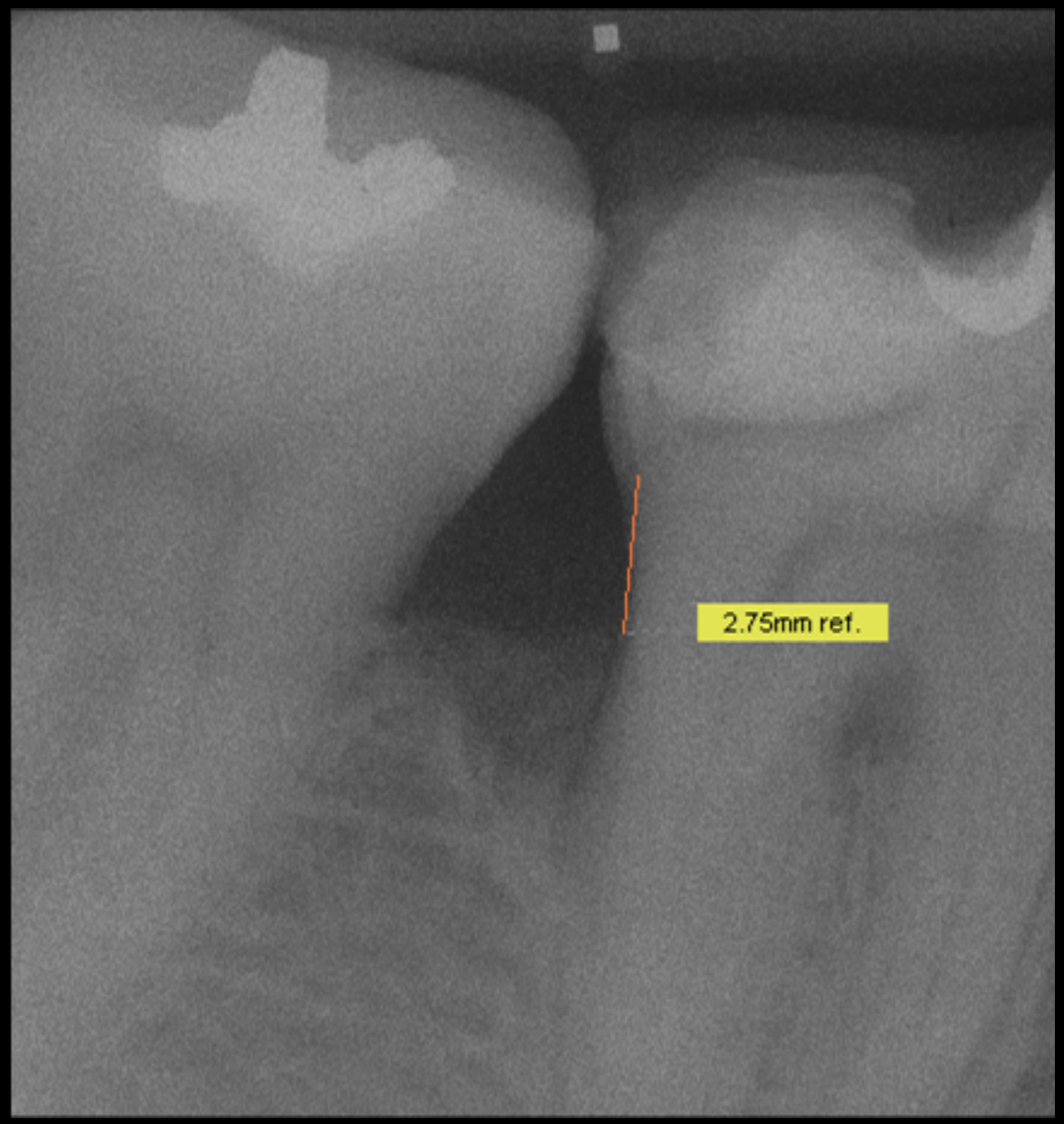

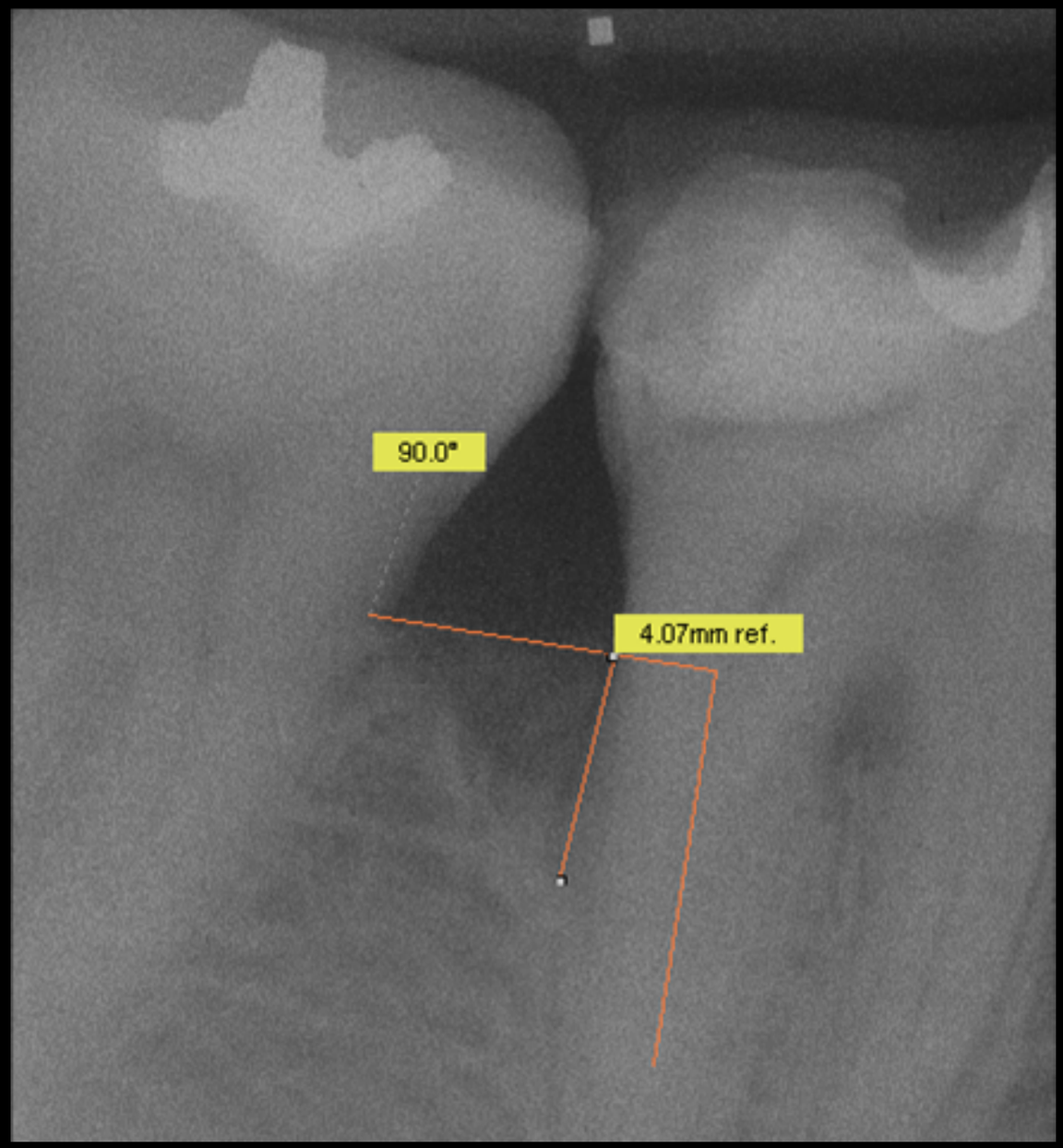

The healing can be measured in mm-s without any reentry.

CBCT vs. Intraoral x-ray

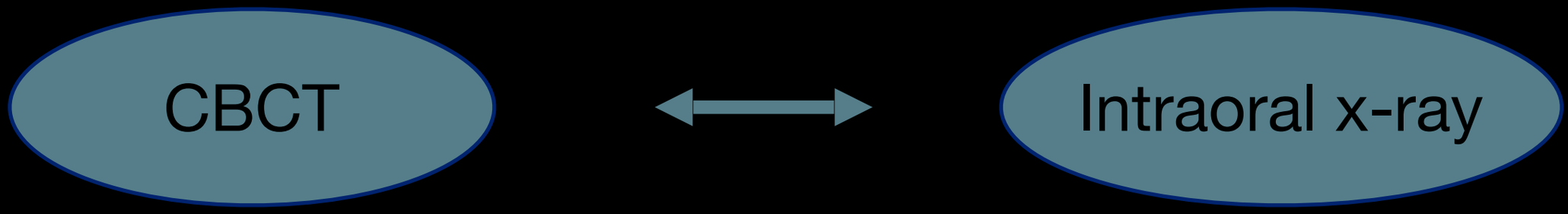

- CBCT images allowed comparable measurements of periodontal bone levels and defects as intraoral radiography.

- CBCT images demonstrated more potential in the morphological description of periodontal bone defects, while the digital radiography provided more bone details.

- These findings may offer perspectives for further studies on periodontal diagnostics, prognostics, and presurgical planning with CBCT.

Mengel R, Candir M, Shiratori K, Flores-de-Jacoby L.
Digital volume tomography in the diagnosis of periodontal defects: an in vitro study on native pig and human mandibles.

J Periodontol. 2005 May;76(5):665-73.

Additional possibilities for examination

- bacteriological tests - bacterial DNA analysis
- immunological tests
- microbial enzymatic reactions
- laboratory evaluation of the predisposing factors
- PMN-leukocyte function analysis
- monocyte reactivity analysis
- genetic tests

Defining prognostic factors

- general factors:
- age
- the severity of the disease
- the clinical form of periodontitis - any form of the aggressive periodontitis is not good
- the individual plaque-controll, cooperation
- smoking
- genetic and systemic factors

Defining prognostic factors

- local factors:
- presence of plaque and calculus
- tooth mobility
- furcation involvement
- **prosthetic viewpoint** - to keep periodontally compromised teeth? extraction and implantation?