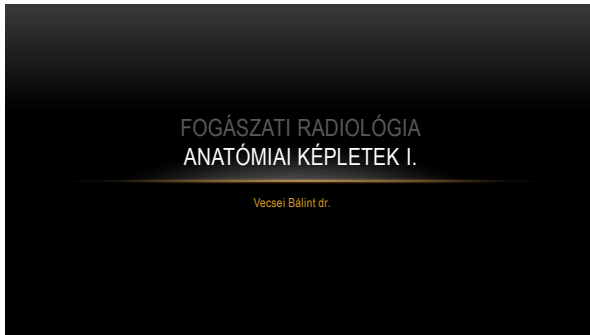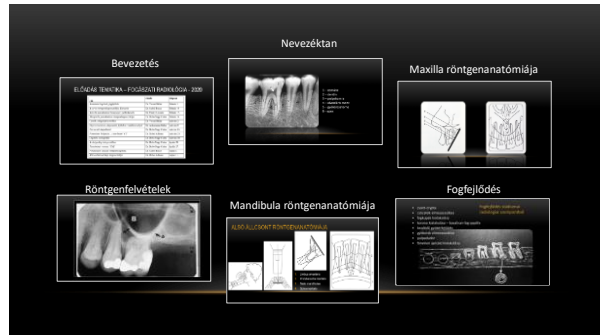

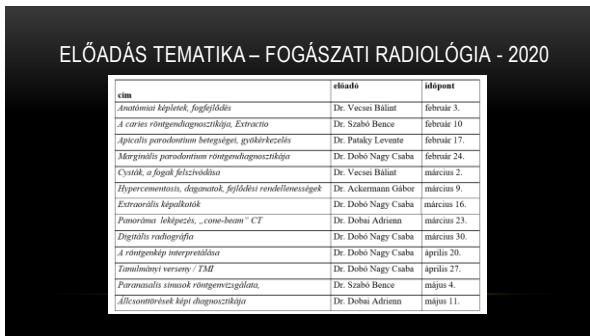


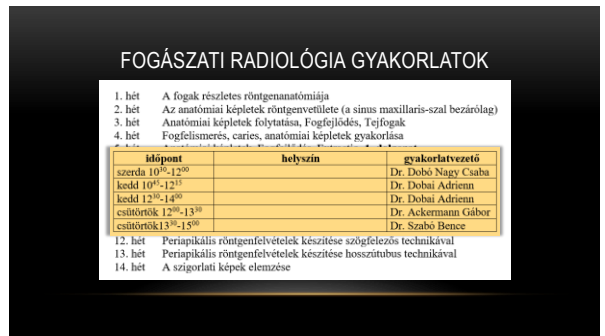
1



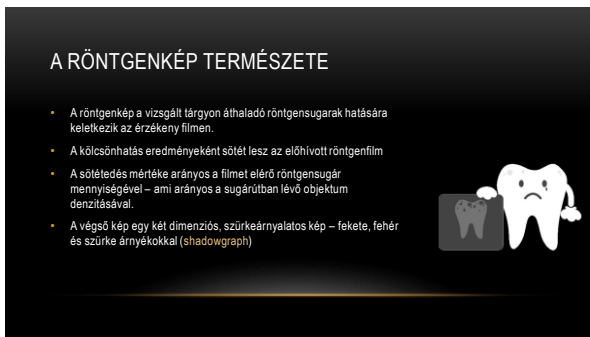2



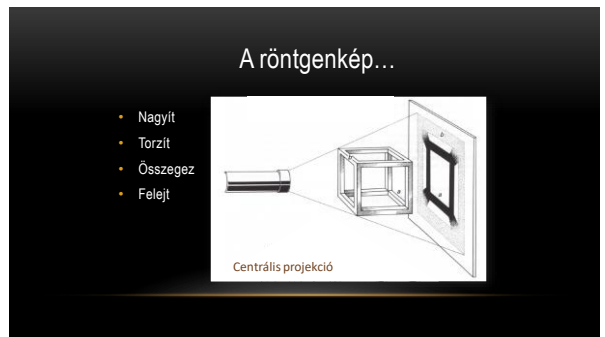3



4



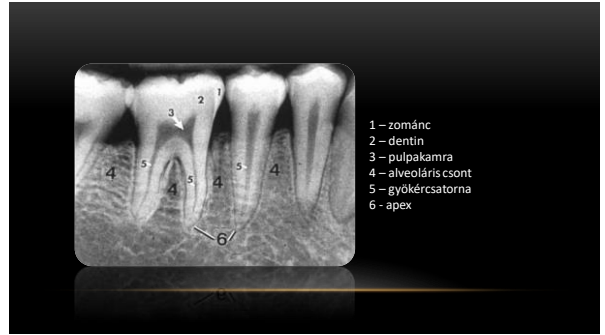
5



6

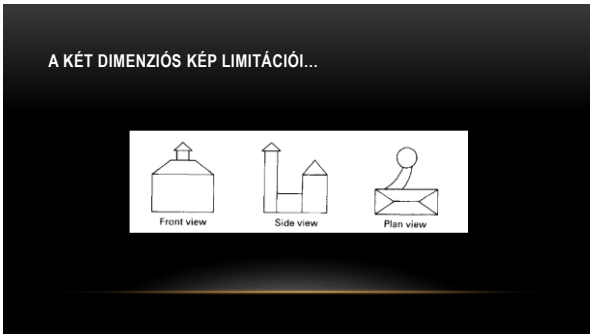

7

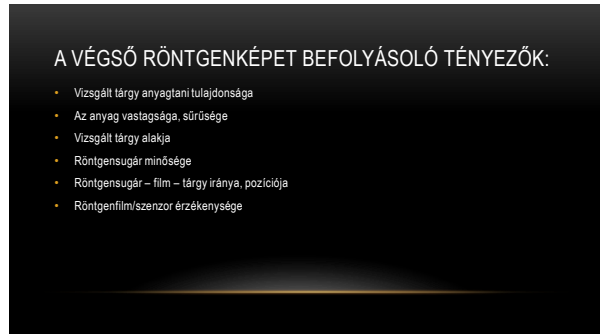

- 1 – zománc
- 2 – dentin
- 3 – pulpakamra
- 4 – alveoláris csont
- 5 – gyökércsatorna
- 6 - apex

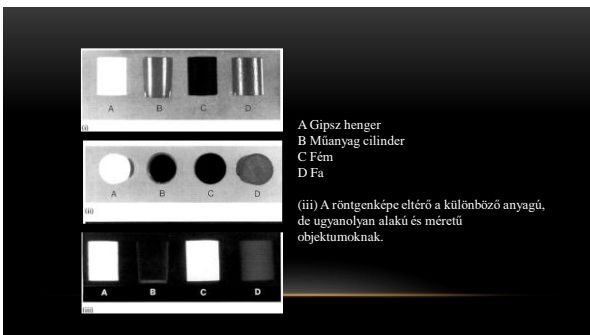
8




9



10



11



12



(iii) Különböző intenzitású röntgensugár hatására létrejövő röntgenkép (gipsz hengerekről)

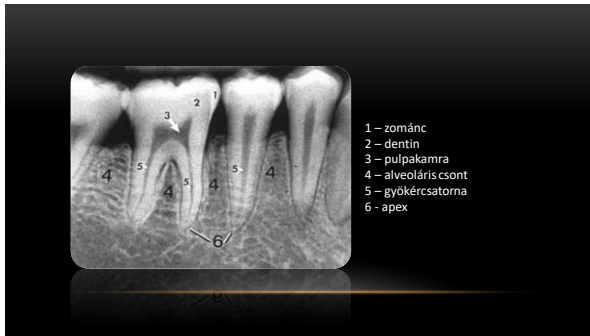
13

RADIOPAK VS. RADIOLUCENS

- Fehér = A röntgensugarat teljesen elnyelő objektumok
- Fekete = A röntgensugár számára teljesen átjárható szövetek
- Szürke = A röntgensugarat részben elnyelő képletek

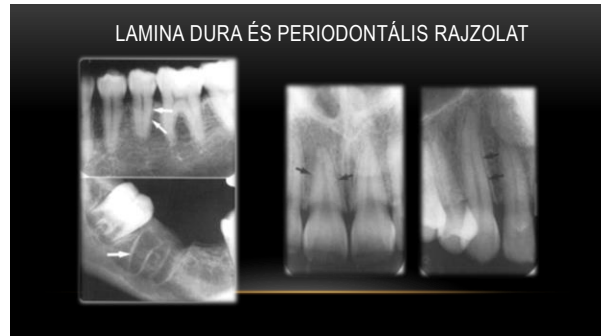Radiopak	Fém
	Zománc
	Cement - Dentin
	Csont
	Izom
	Zsír
Radiolucens	Levegő

14

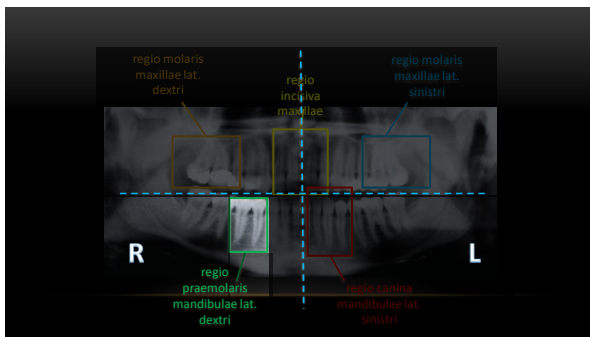


1 - zománc
2 - dentin
3 - pulpakamra
4 - alveoláris csont
5 - gyökércsatorna
6 - apex

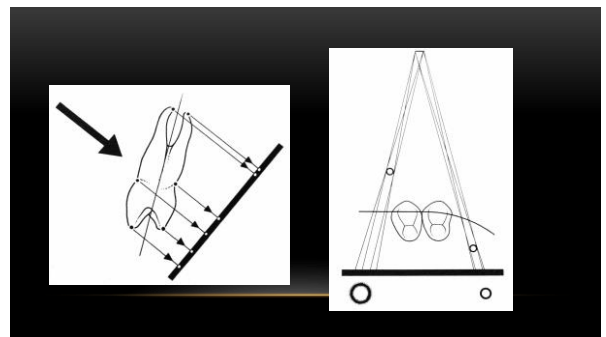
15



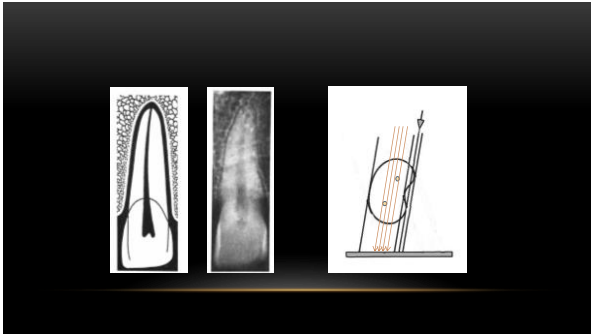
16



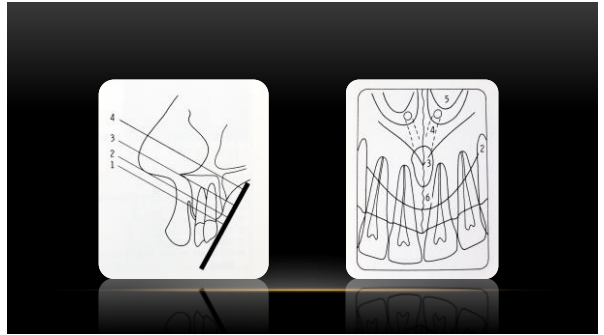
17



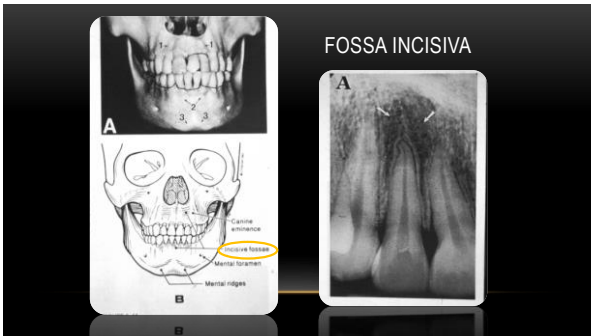
18



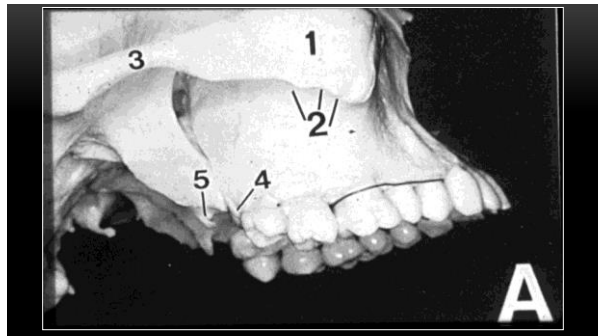
19



20



21



22

MAXILLA

- sutura intermaxillaris
- spina nasalis anterior
- cavum nasi
- foramen incisivum
- fossa incisiva
- sinus maxillaris
- proc. zygomaticus
- os zygomaticum
- tuber maxillae
- proc. pterygoideus

23

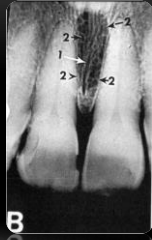SUTURA INTERMAXILLARIS

- középvonal
- egyenes varrat – kötőszöveti rostokkal
- translucens csik két opac cortikális között

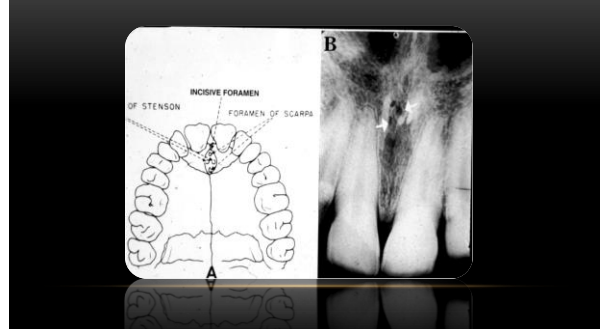
24

FORAMEN INCISIVUM

- canalis incisivus szájpadi nyílása
- alakja „kerek, tojásdad, szív alakú”
- mérete is változatos
- felső széle éles – alsó elmosódott



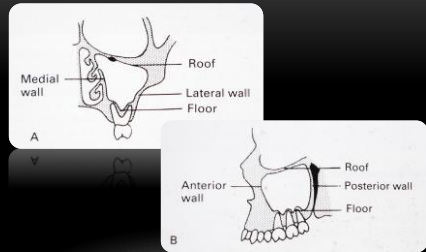
25



26

SINUS MAXILLARIS

- recessusai:
 - r. frontalis
 - r. infraorbitalis
 - r. zygomaticus
 - r. palatinalis
 - r. alveolaris

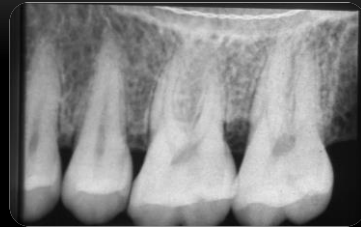

27

28

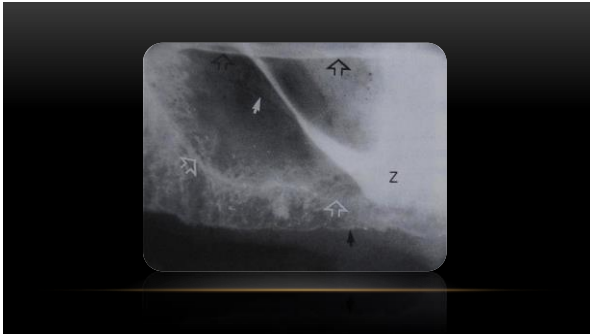RECESSUS ALVEOLARIS

- sinus-vonal – világos compacta vonal
- kisörlökig terjed általában
- legmélyebb első, ill. második molárisnál
- LATEROBASALIS – fal vetülete!
- nasalis vonnallal a sinusvonal X, Y, V-alakú rajzolatot alkot

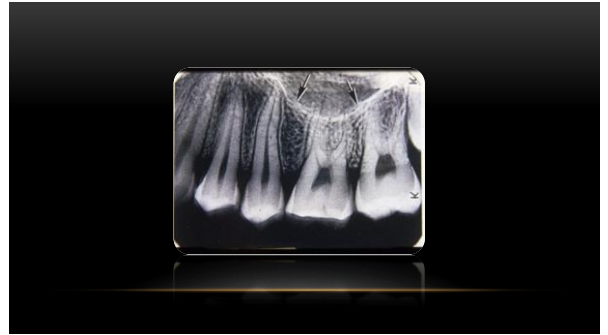

29

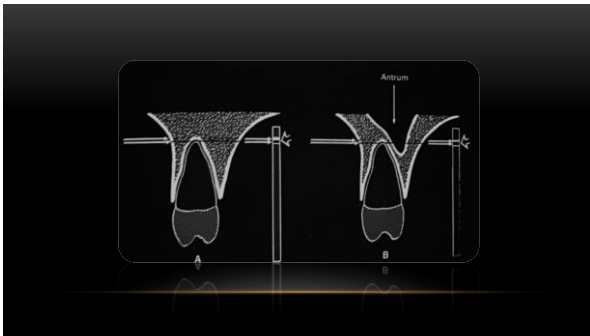
30



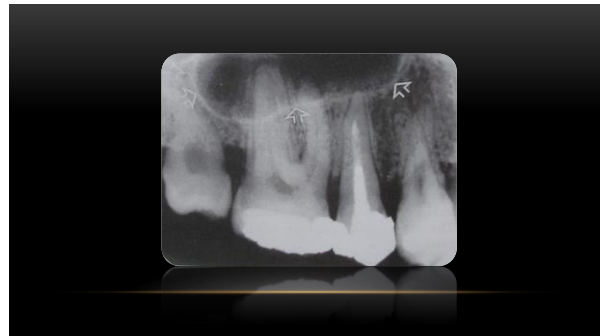31



32



33

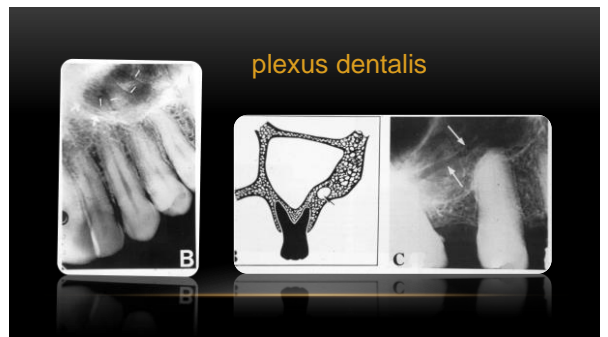


34

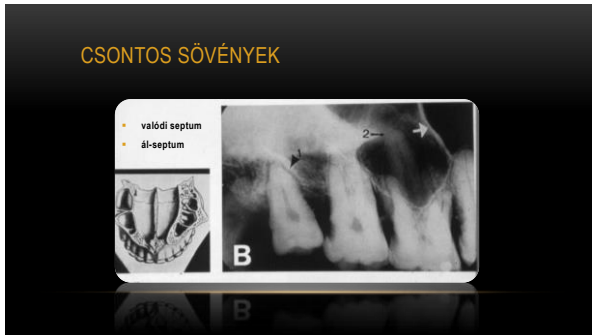RECESSUS ALVEOLARIS KITÜREMKEZÉSEI

- extensio frontalis
- extensio basalis
 - sinus interradicularis
 - sinus interdentalis
 - sinus alveolaris (extractiót követő secunder pneumatizáció következtében)
- extensio tuberalis

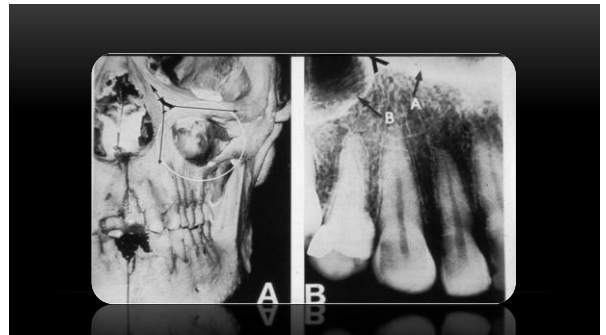
35



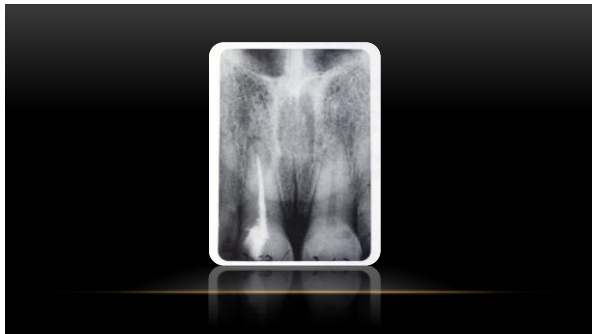
36



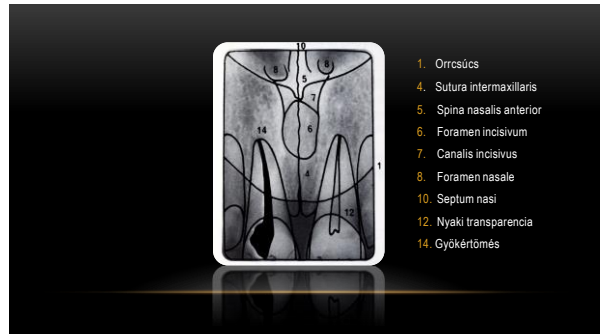37



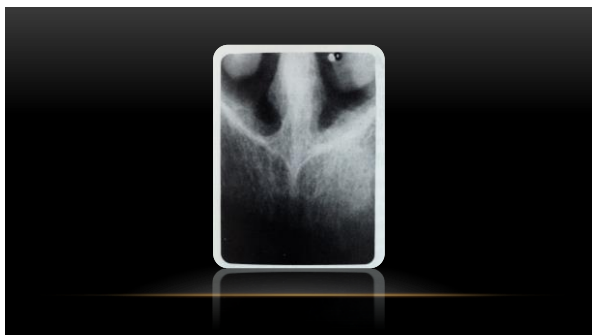
38



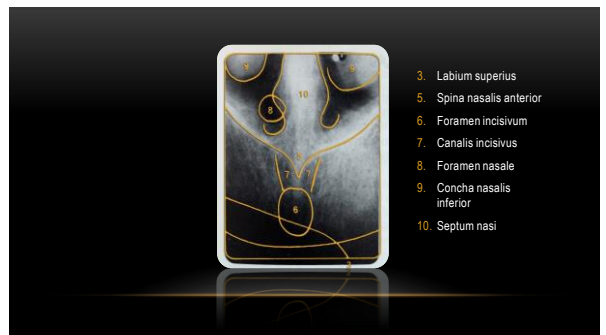39



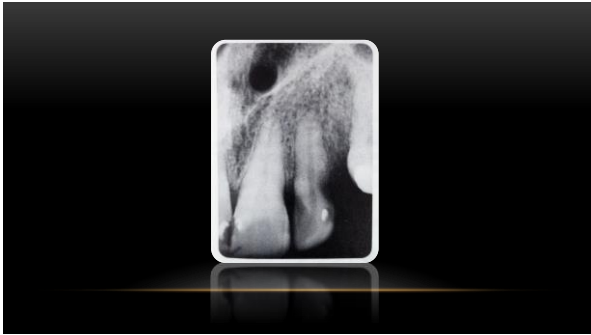
40



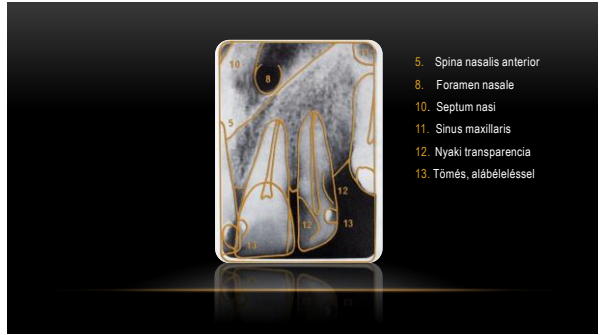41



42

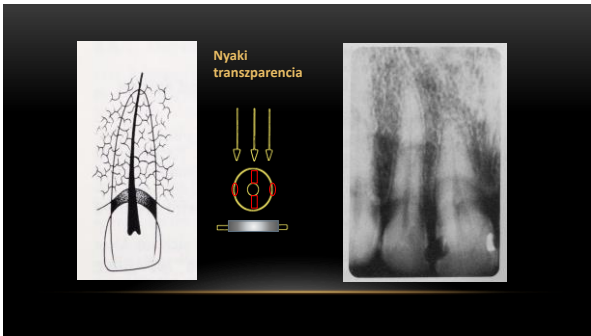


43



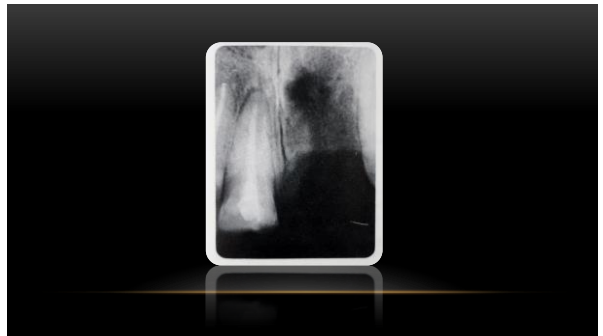
- 5. Spina nasalis anterior
- 8. Foramen nasale
- 10. Septum nasi
- 11. Sinus maxillaris
- 12. Nyaki transzparencia
- 13. Tömés, alábéleléssel

44

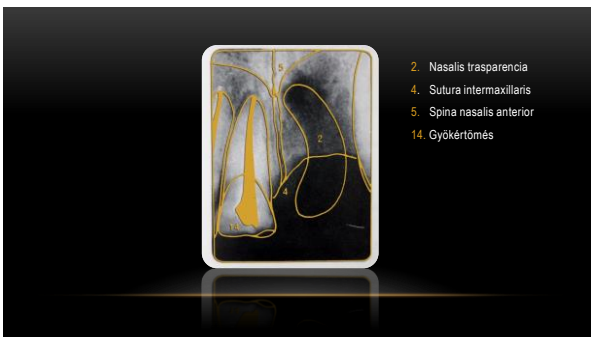


Nyaki transzparencia

45




46

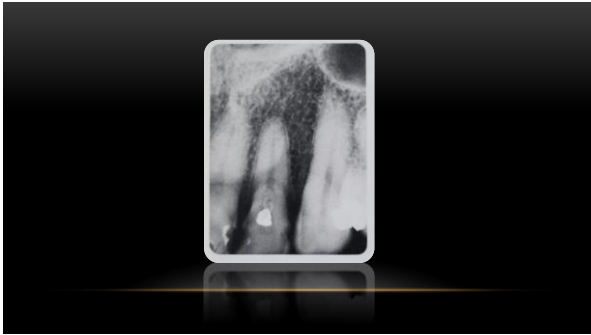


- 2. Nasalis transzparencia
- 4. Sutura intermaxillaris
- 5. Spina nasalis anterior
- 14. Gyökértömés

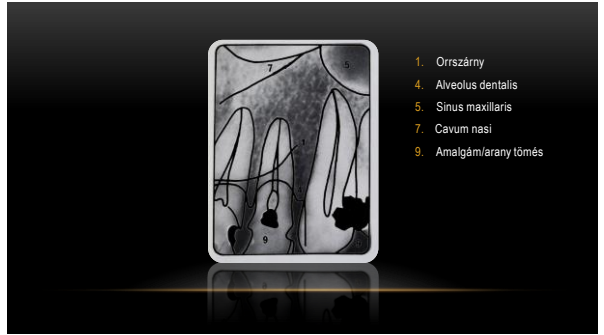47



48

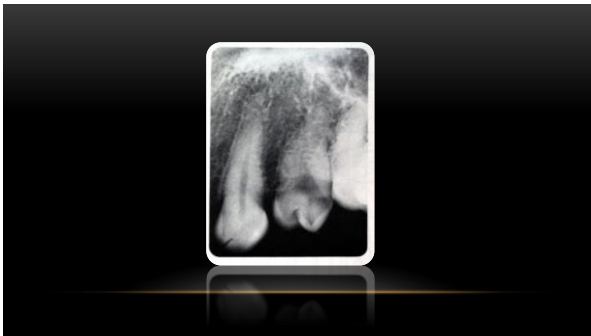


49

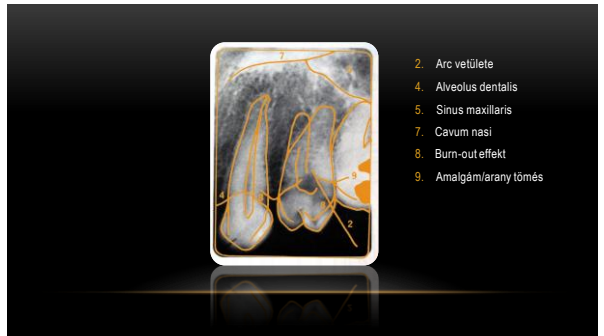

50

- 1. Orrszárny
- 4. Alveolus dentalis
- 5. Sinus maxillaris
- 7. Cavum nasi
- 9. Amalgám/árány tömés

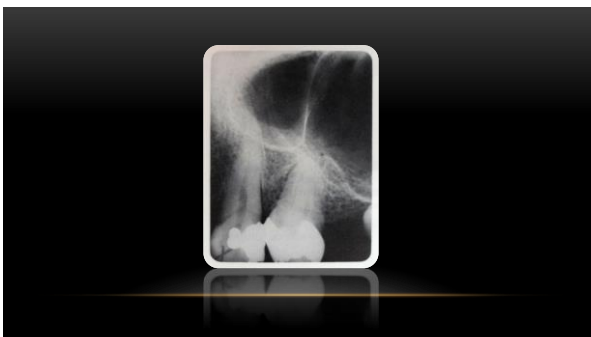


51

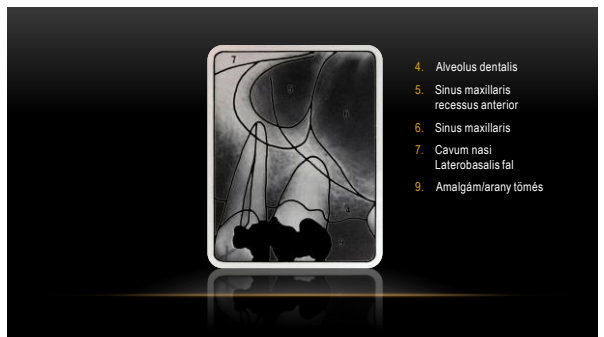

52

- 2. Arc vetülete
- 4. Alveolus dentalis
- 5. Sinus maxillaris
- 7. Cavum nasi
- 8. Burn-out effekt
- 9. Amalgám/árány tömés

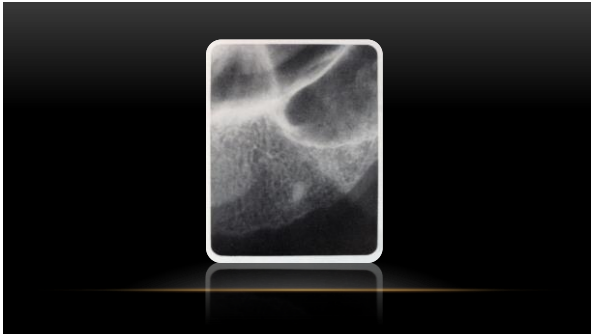

53

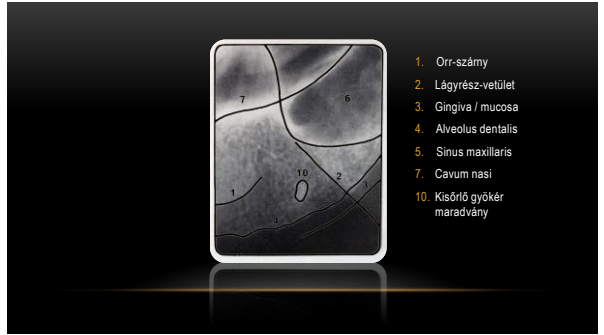

54

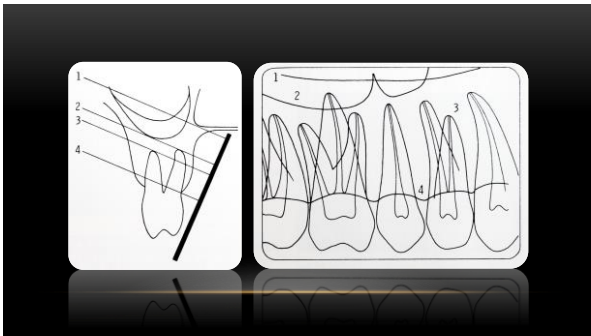
- 4. Alveolus dentalis
- 5. Sinus maxillaris recessus anterior
- 6. Sinus maxillaris
- 7. Cavum nasi Laterobasalis fal
- 9. Amalgám/árány tömés



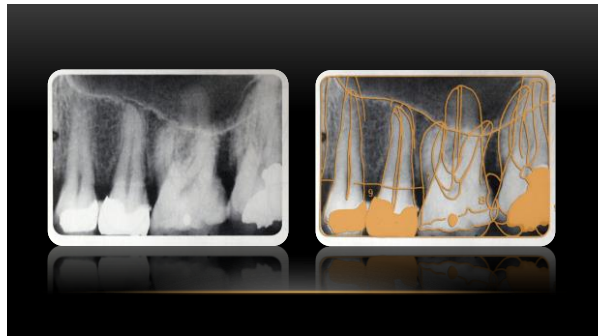
55



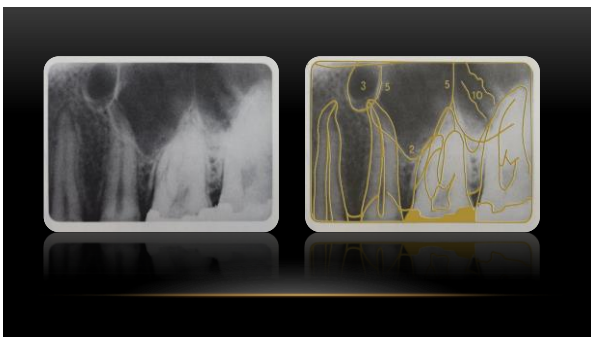
56



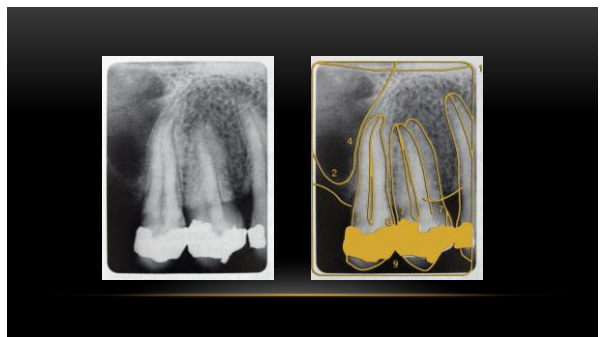57



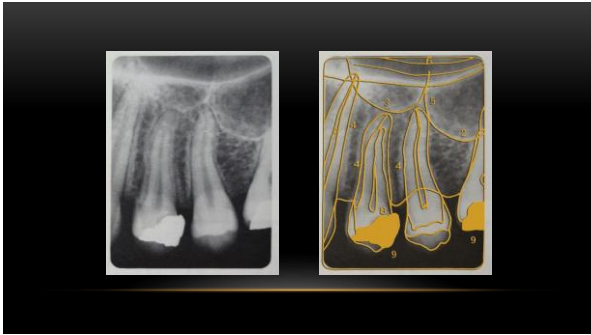58



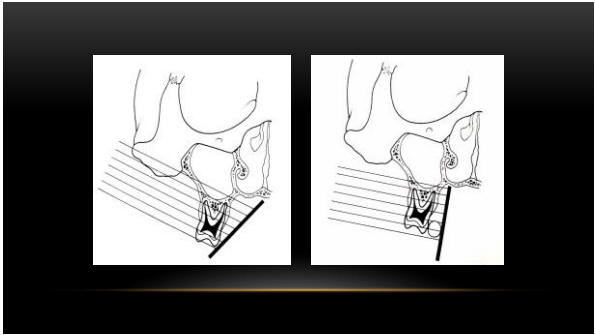
59



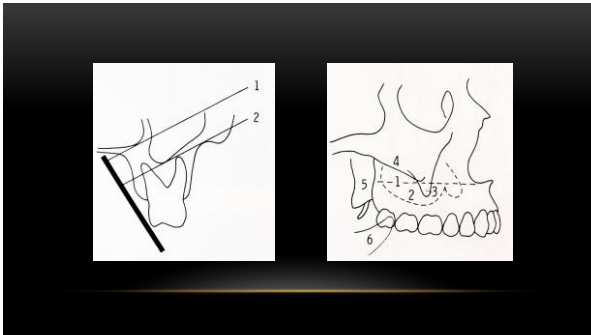
60




61



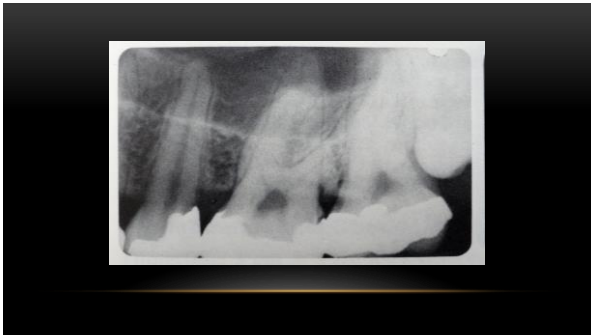62



63



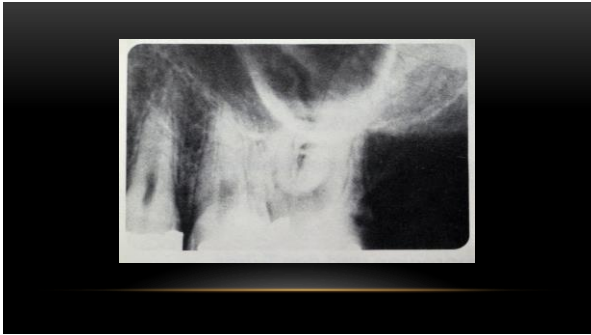64



65



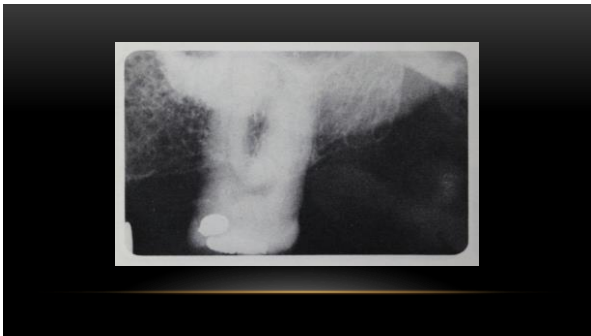
66



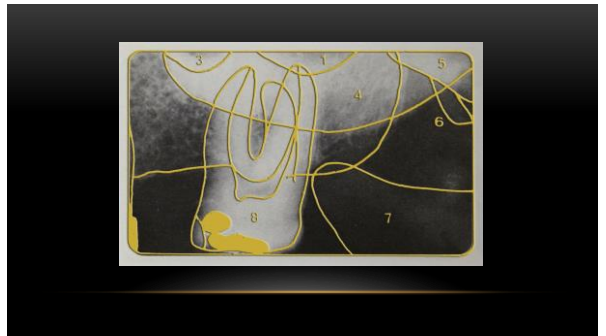67



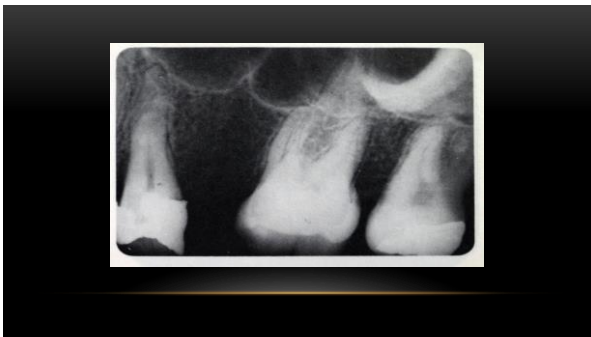68



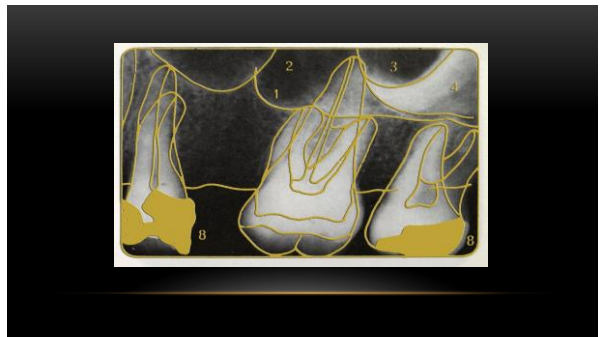
69



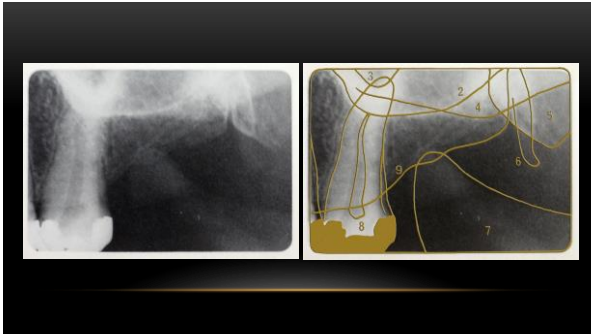
70



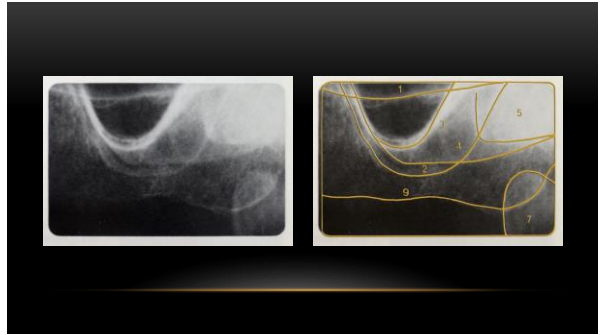
71



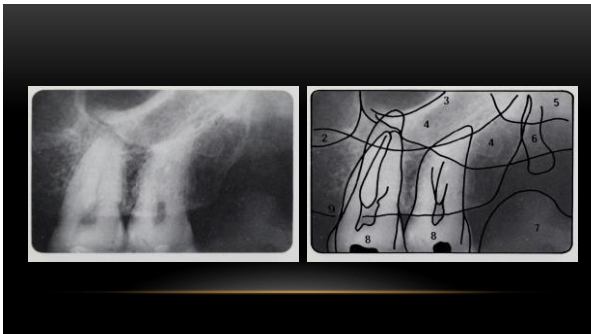
72



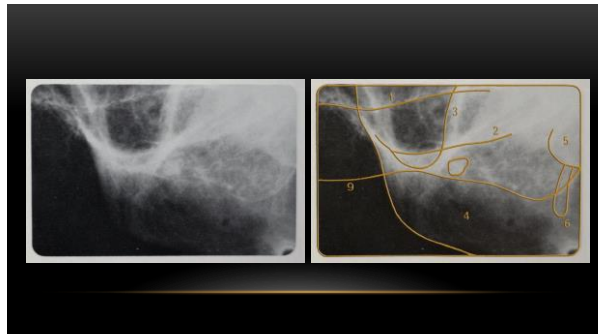
73



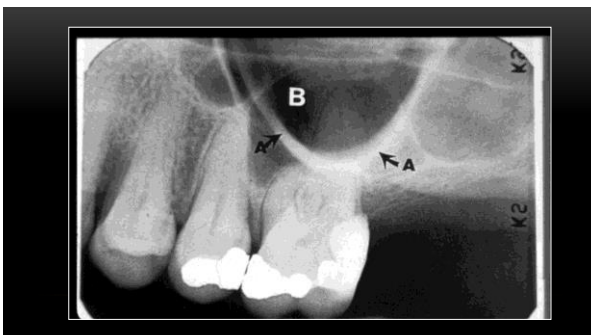
74



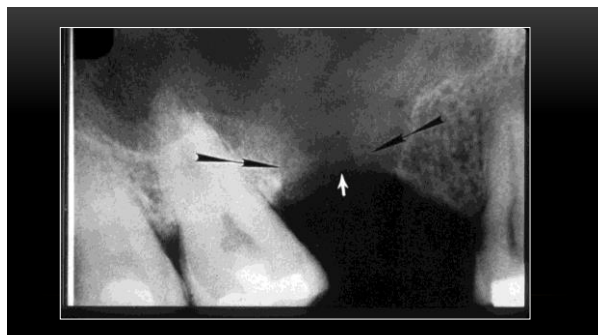
75



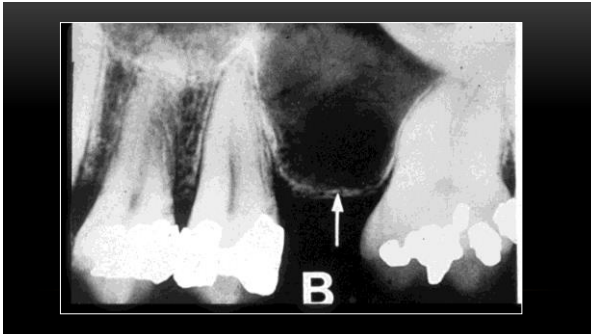
76



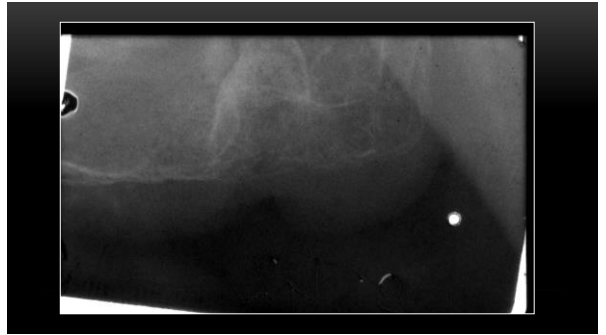
77



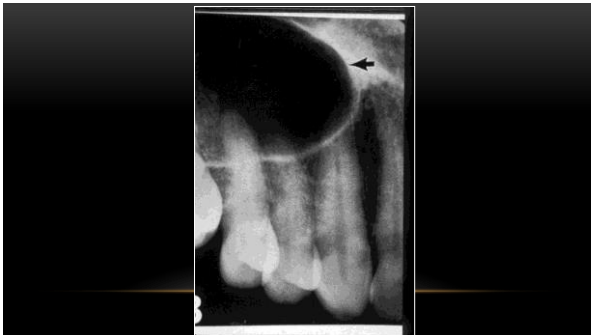78



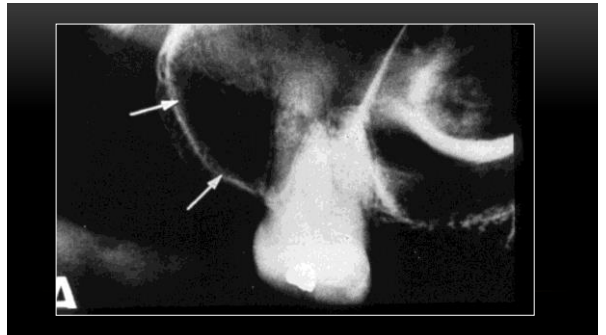
79



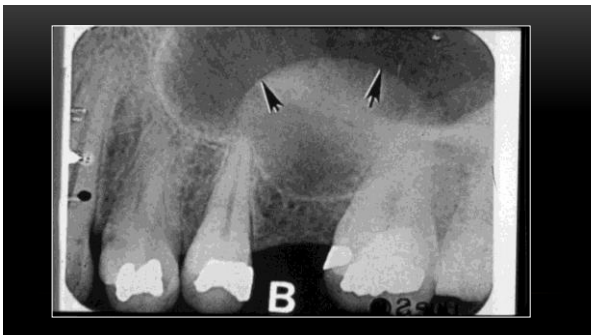
80



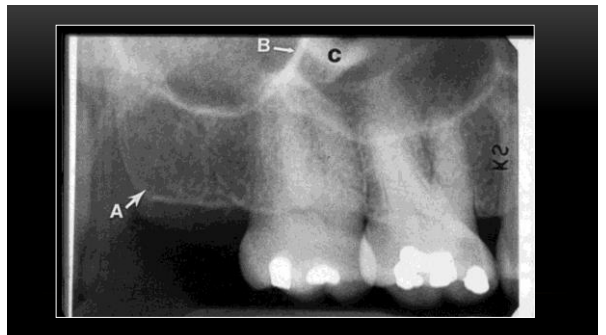81



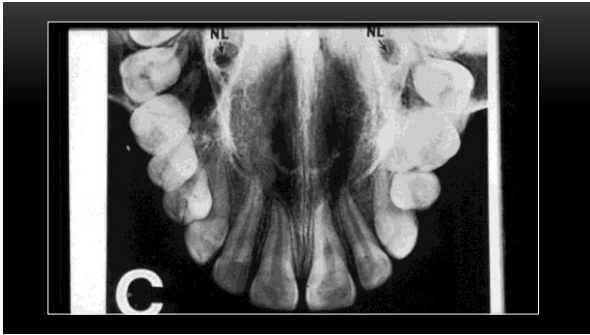
82



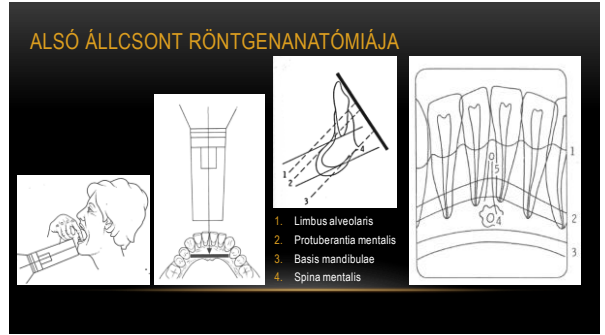
83



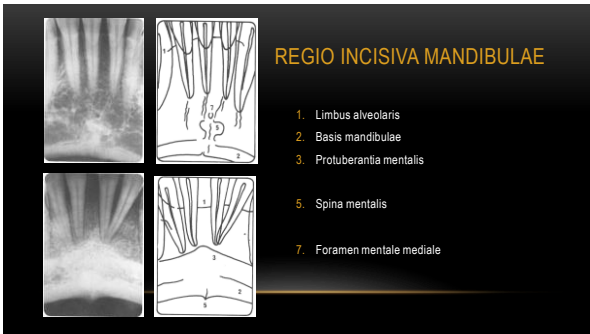84



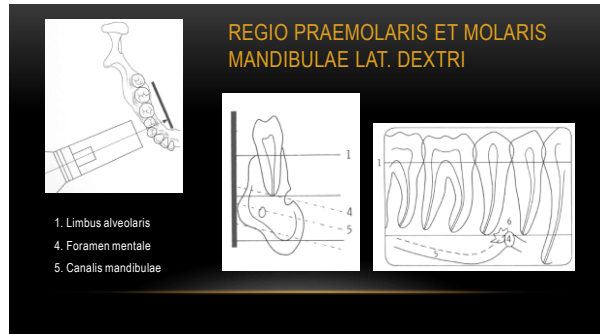
85



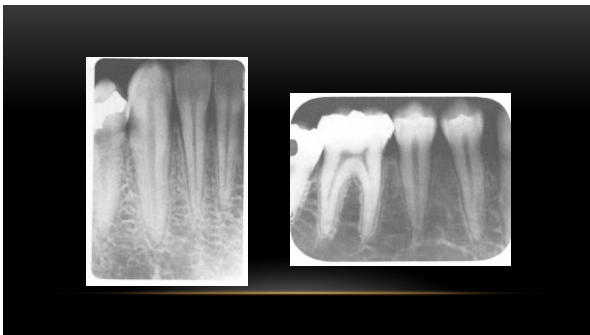86



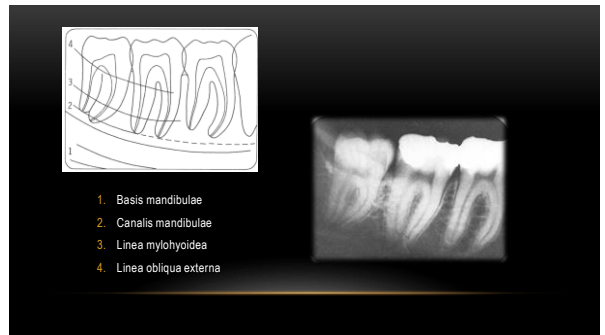87



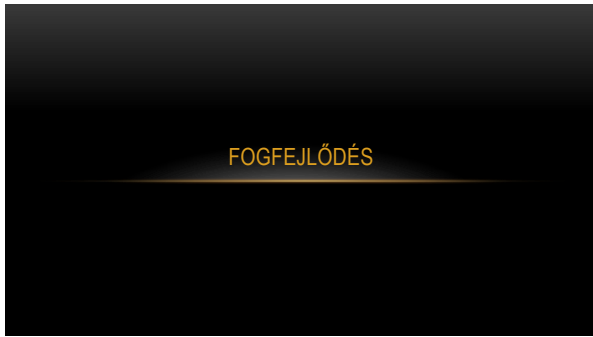
88



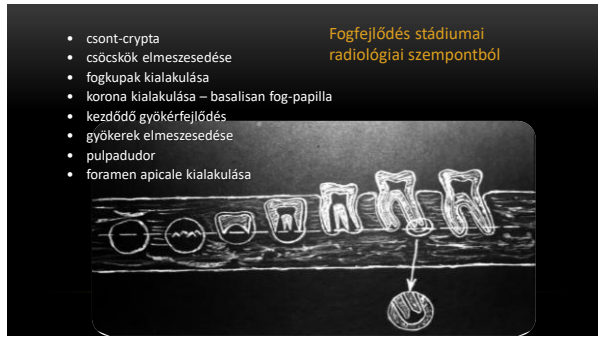89




90




91



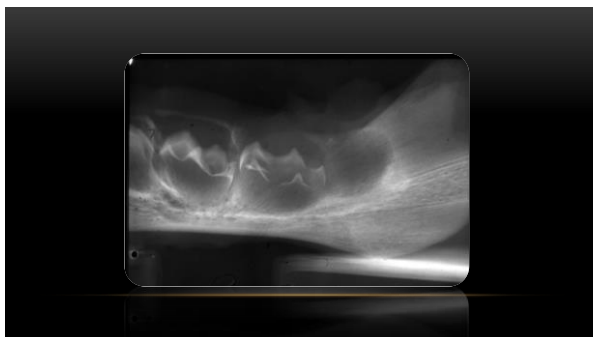92



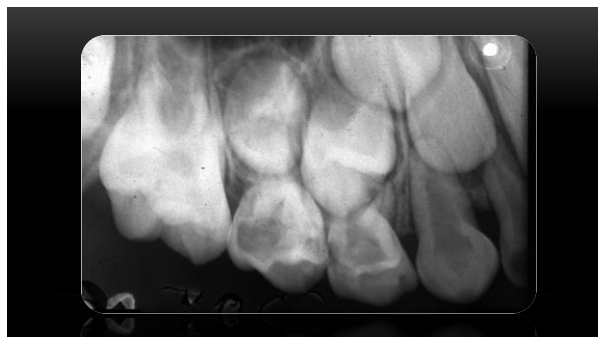93



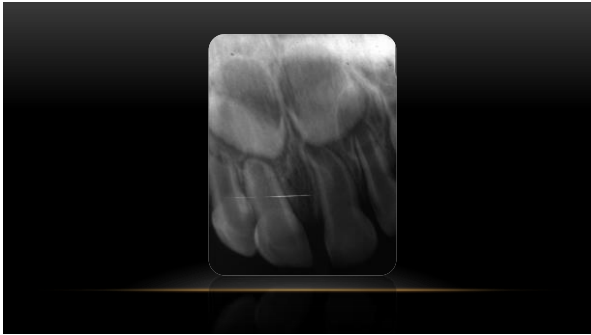
94



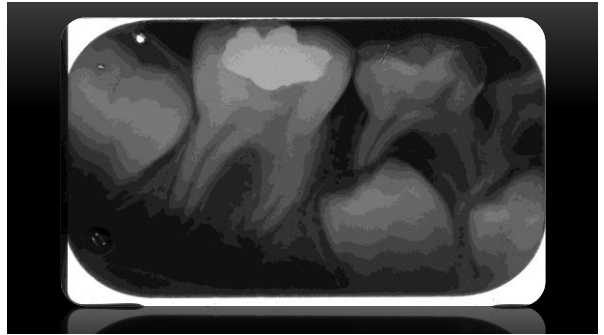
95



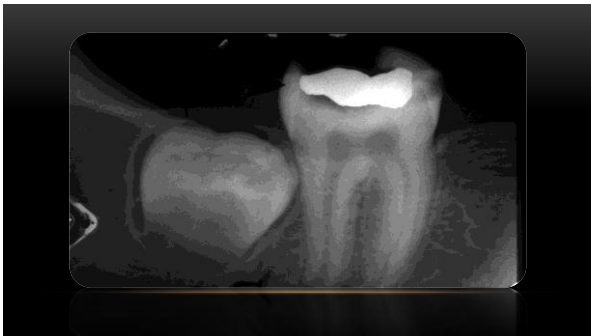
96



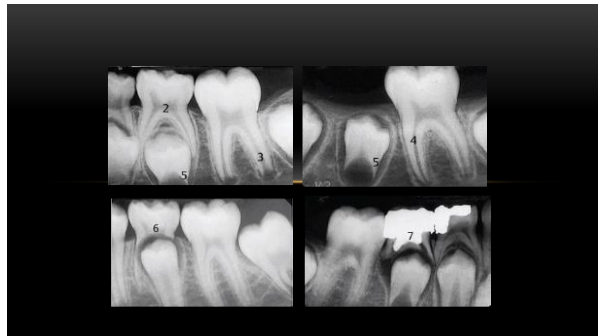97



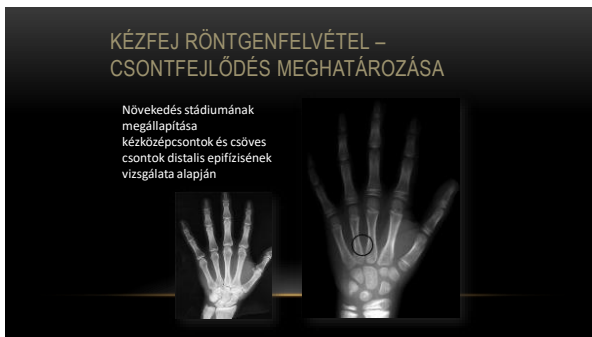98



99



100



101