



Semmelweis University Faculty of Dentistry Department of Community Dentistry

Head of Department: Dr. Peter Kivovics associate professor

<http://semmelweis-egyetem.hu/fszoi/>

<https://www.facebook.com/fszoi>



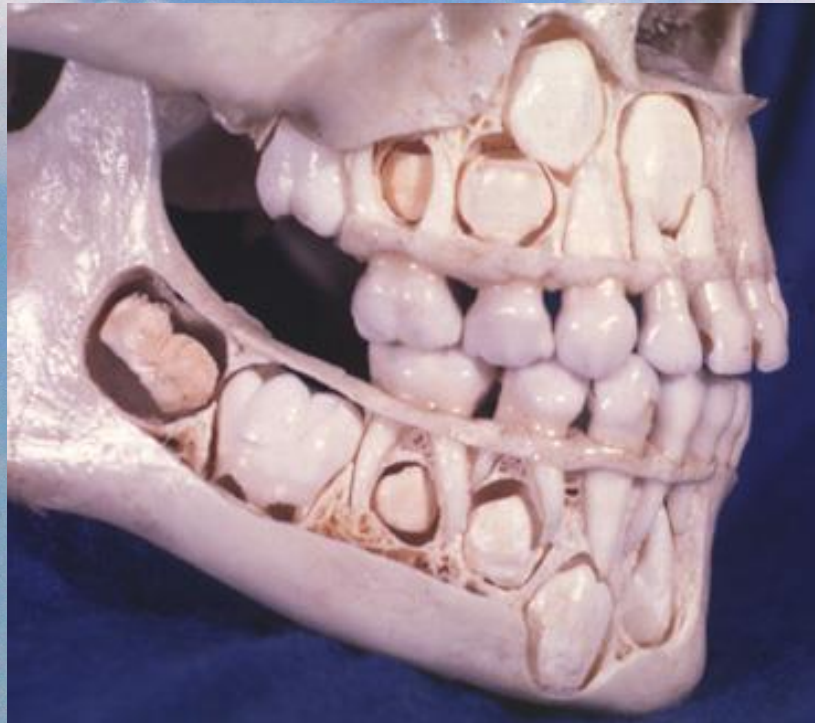Pedodontic aspects of Emergency dentistry



Dr. Orsós Mercédesz
MsC and PhD student

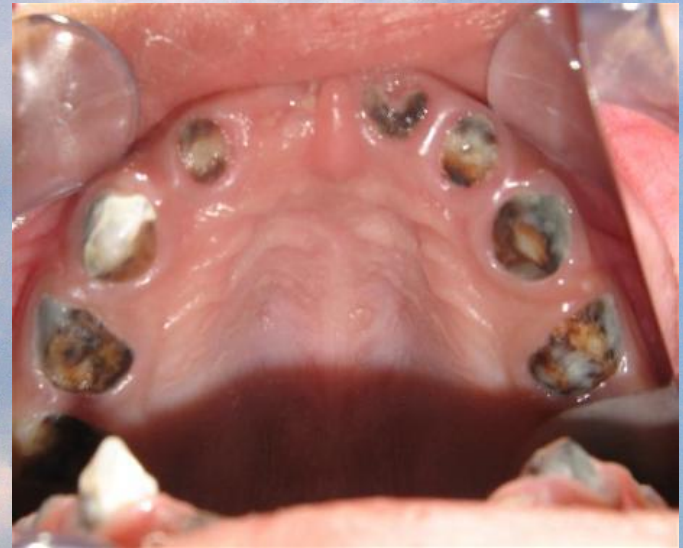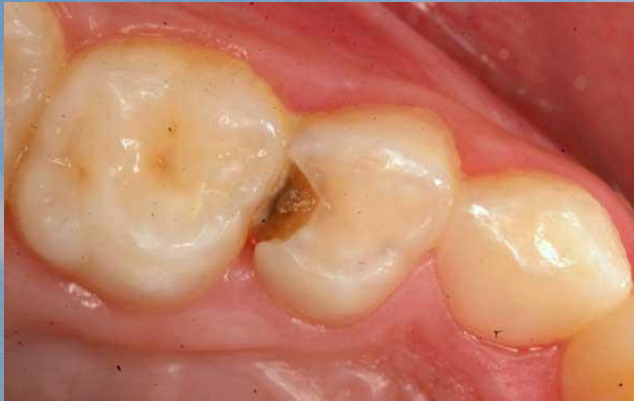Most frequent cases

1. Consecutive illnesses of caries
2. Injuries



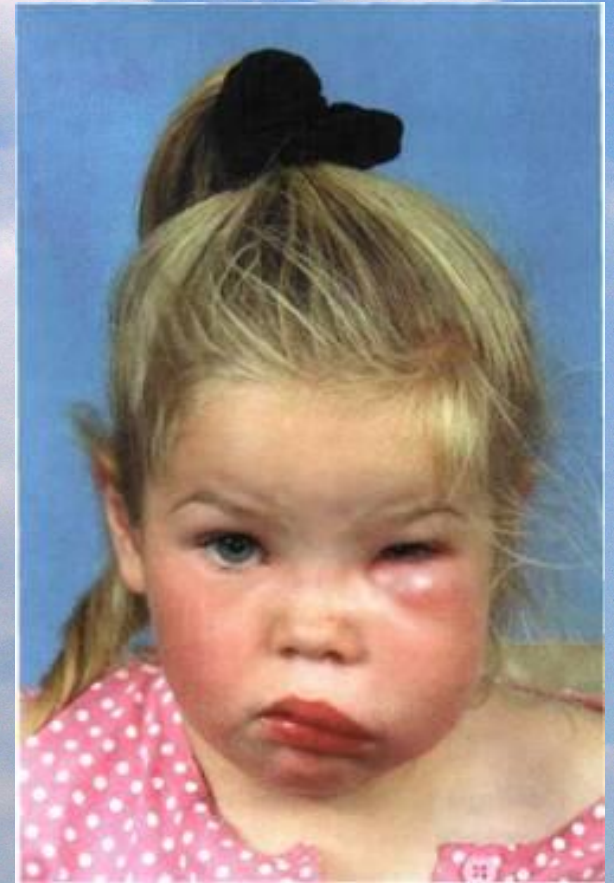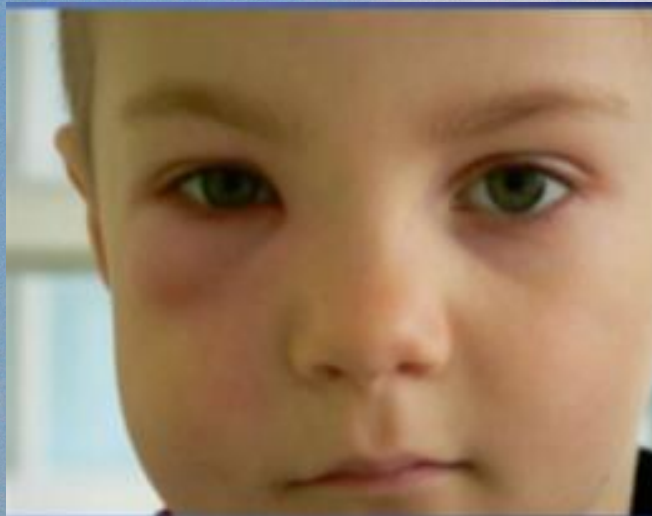Consecutive illnesses of caries in primary teeth

- Symptoms are like with adults but the treatment is different!
- Parental cooperation



Consecutive illnesses of caries in primary teeth

- Endodontic treatment
- Extraction?
- AB



Injuries

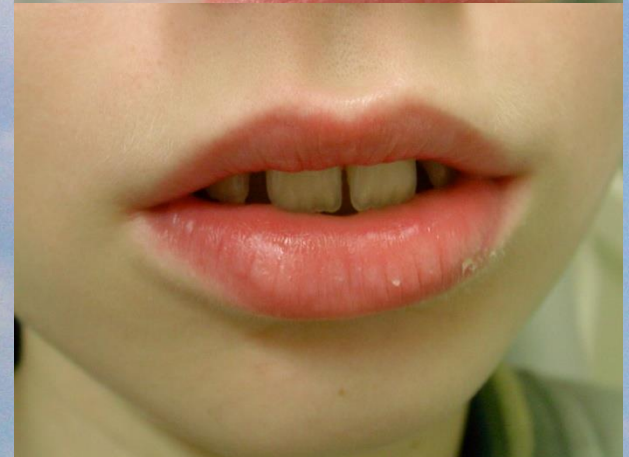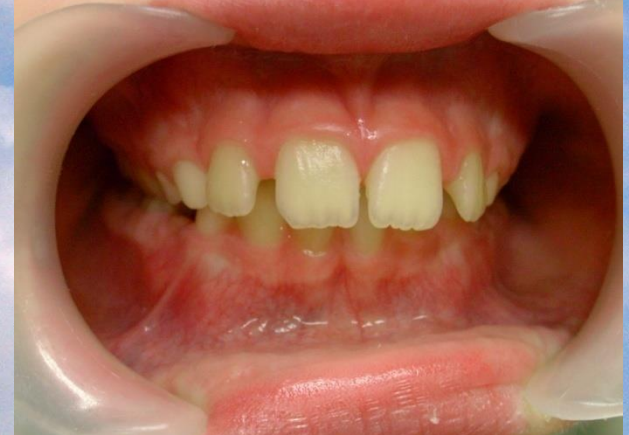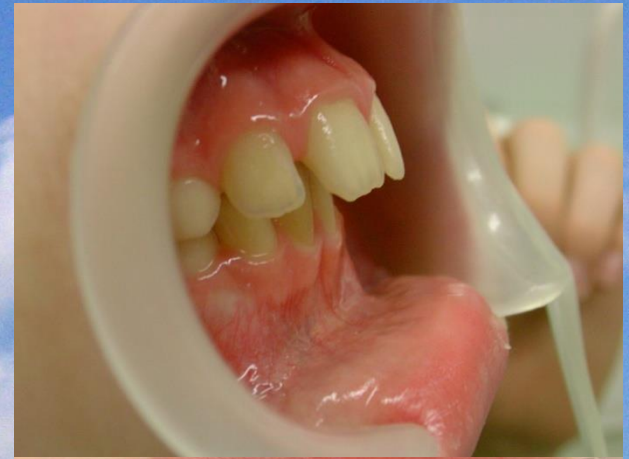Risk - Angle II/1

Predisposing factors:

Overjet

Protrusion of upper incisors

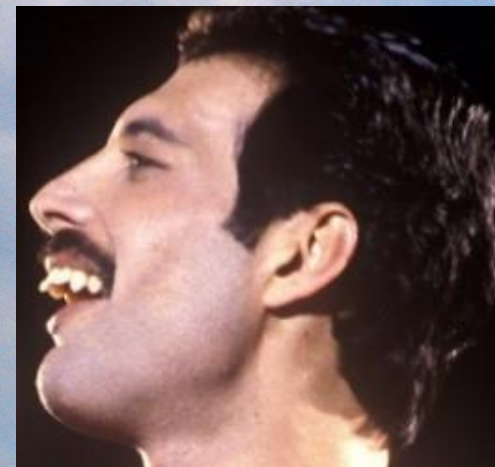
Insufficient lip closer



Angle II.

- Africa: 10%
- America: 16,5%
- Asia: 27%

- Sweden: 52%
- Hungary: 47,2%

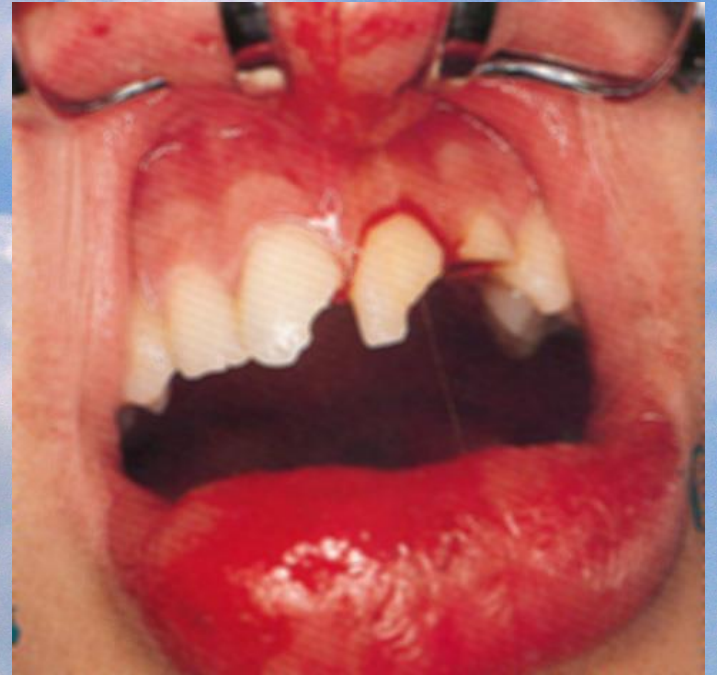
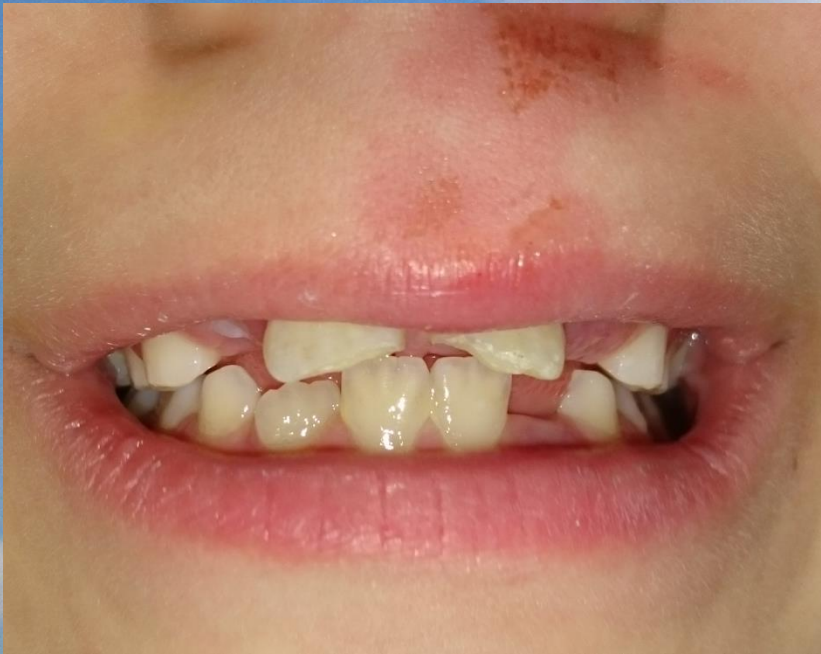
Injuries

- Sport related

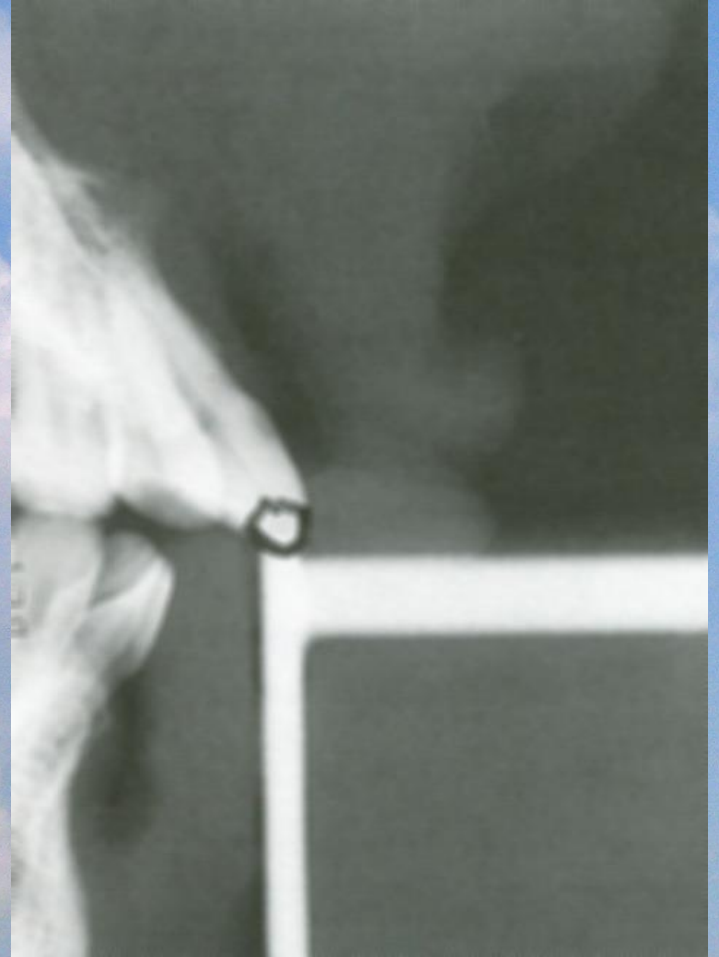


Injuries



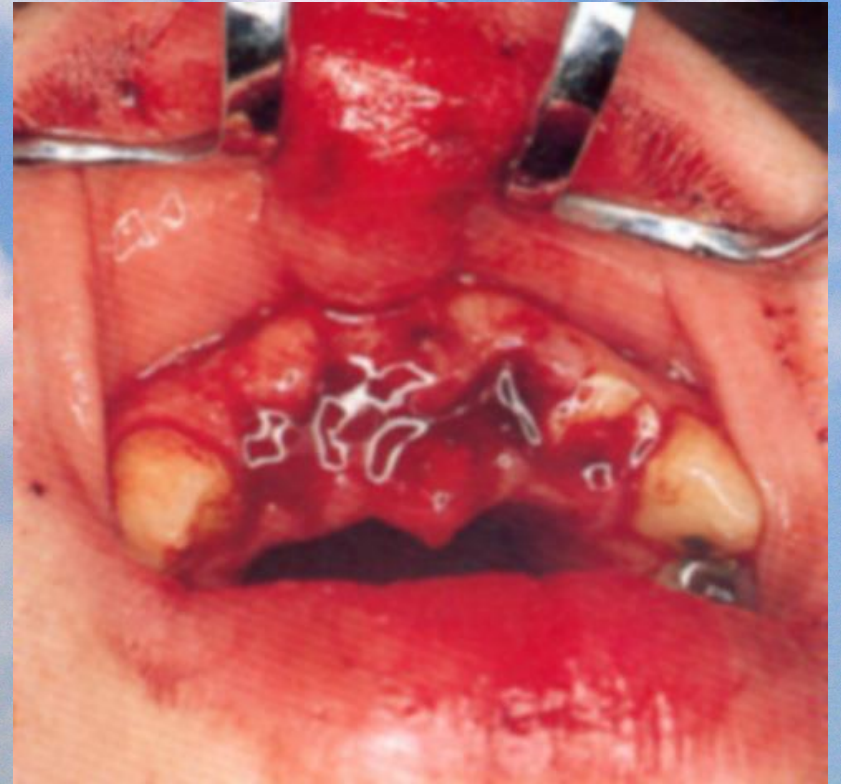Injuries

- Playground



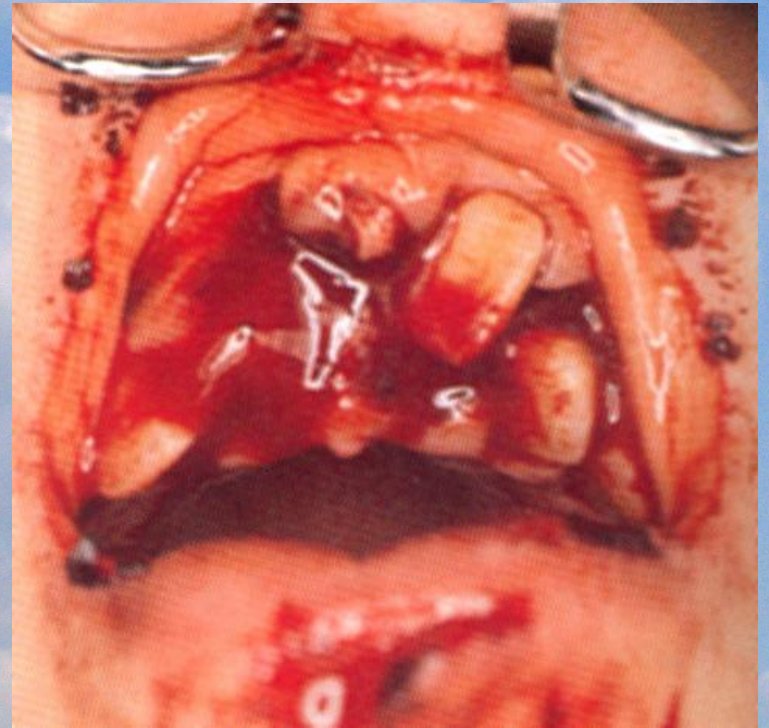Injuries

- Fights

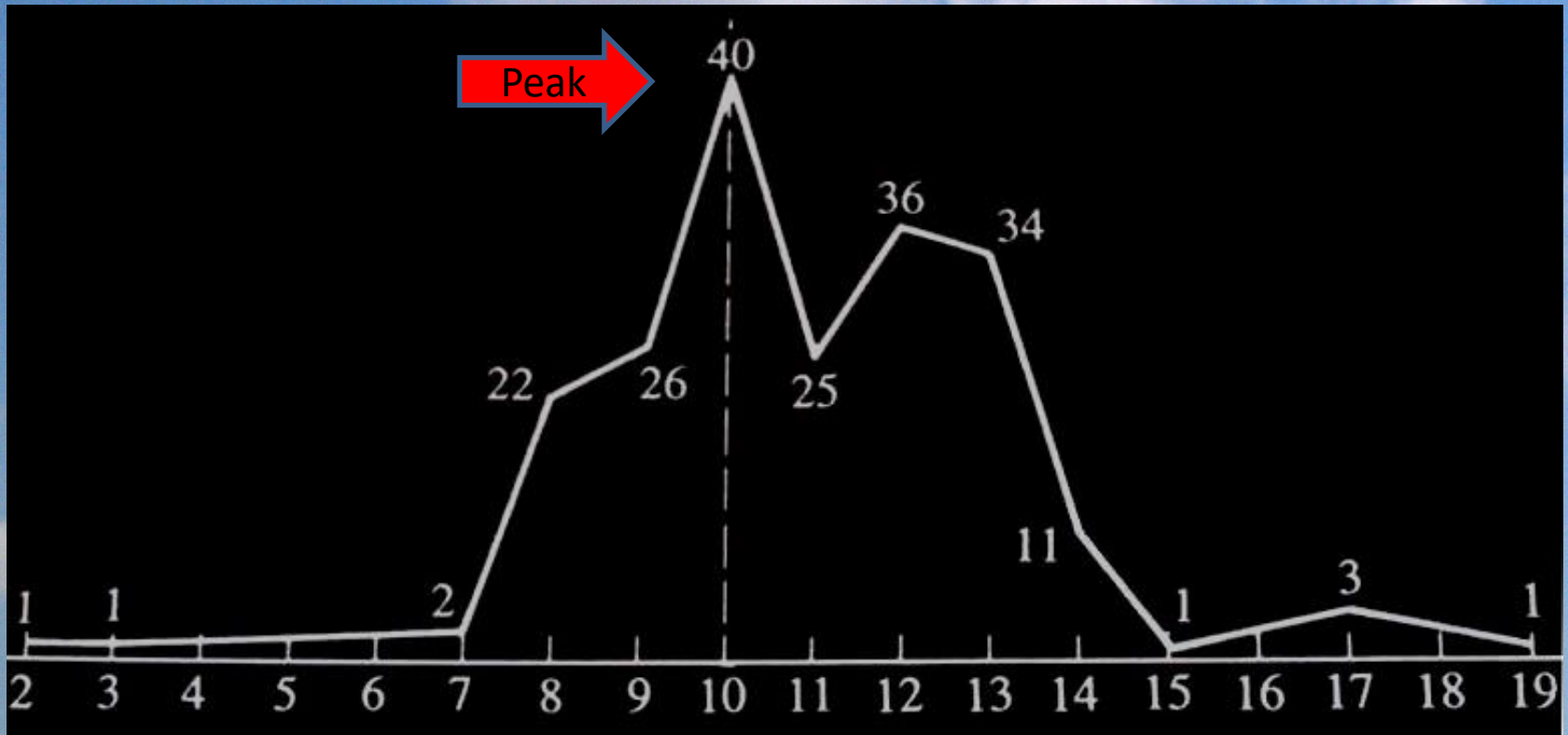


Injuries

- Car accidents



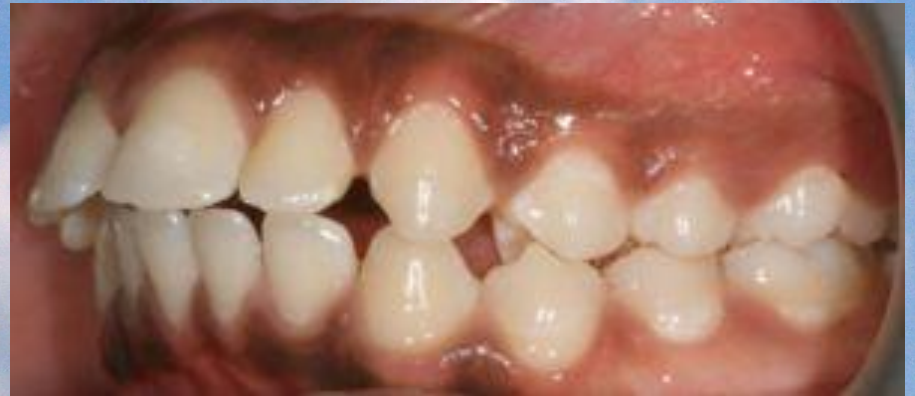Age distribution



Highest incidence

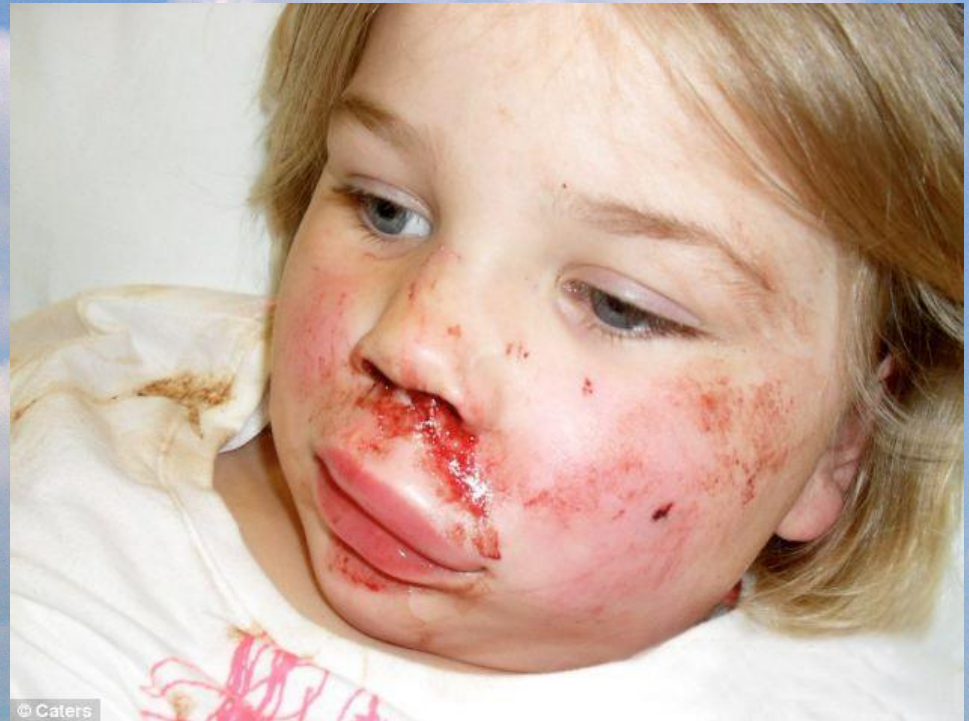Incidence of injured teeth in %

- Upper central incisors 85,39%
- Upper lateral incisors 10,06%
- Lower central incisors 3,57%
- Lower lateral incisors 0,97%



History

1. General history
2. Circumstences of injury
3. Dental history

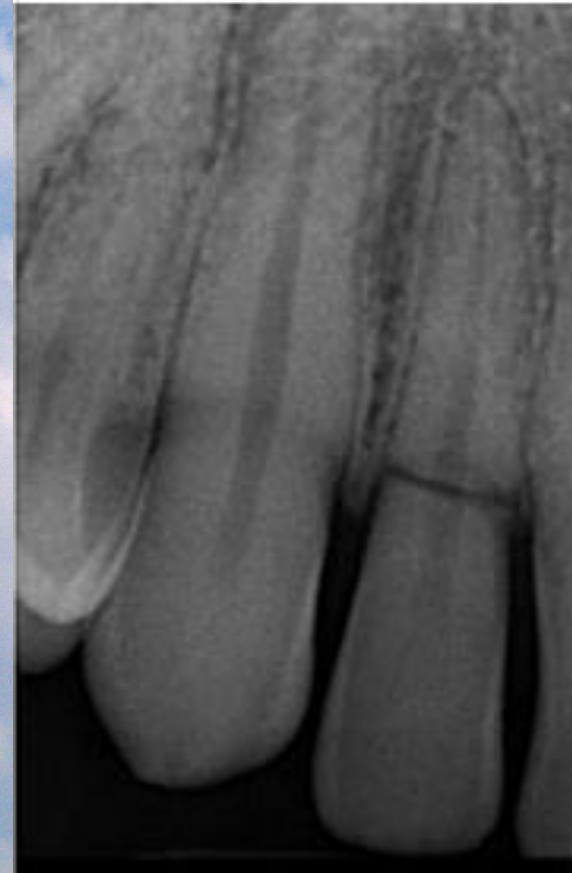


Most important questions

When?Where?How?

Clinical examination

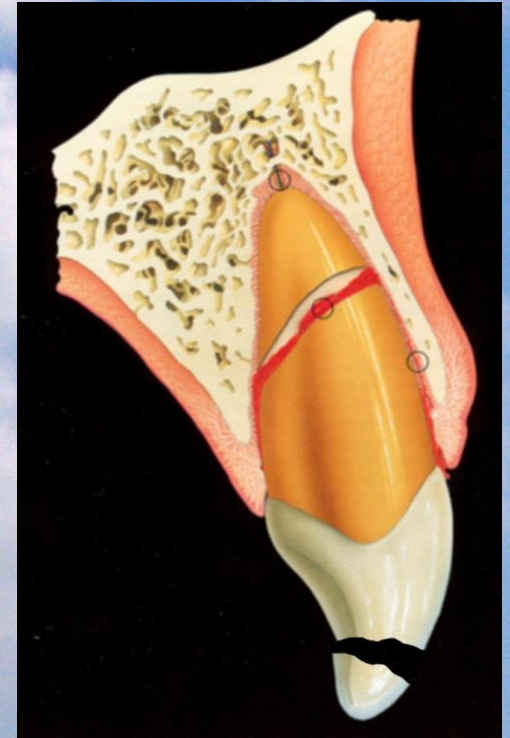
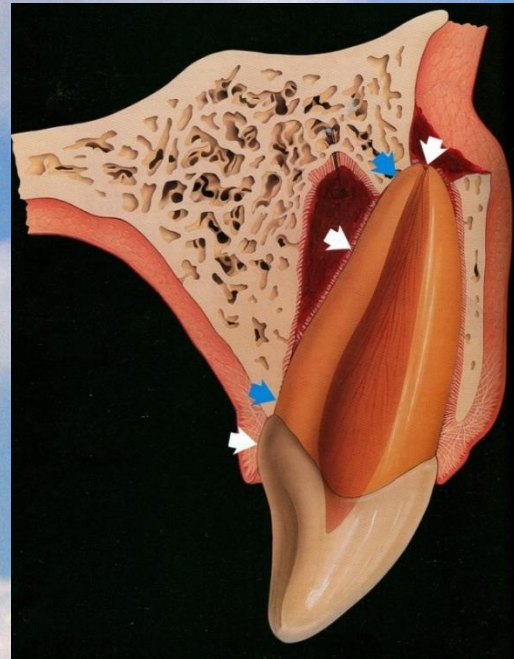
- Extraoral
- Intraoral
- Photo documentation
- X-ray



Type of injuries

- Tooth
- Alveolar bone
- Soft tissue

Combinations



Classification of dental injuries WHO 1995

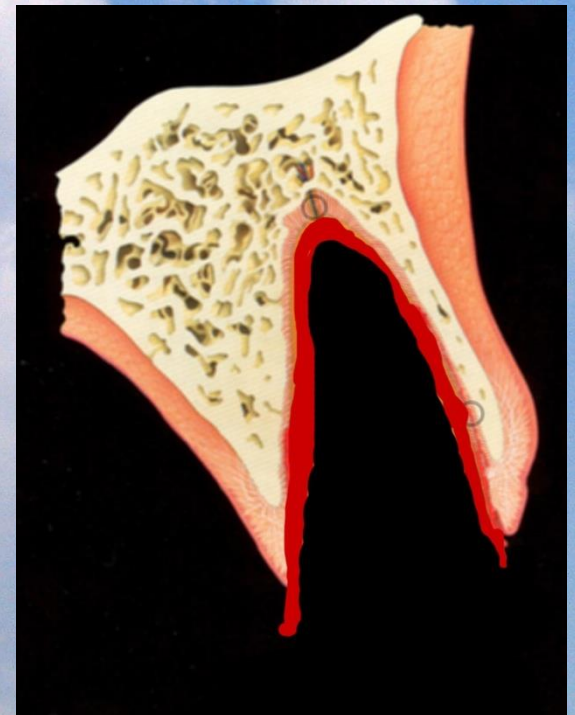
Luxatio totalis dentis permanentis

Complete displacement

Time factor! Intact PDL?

Treatment:

- Preparation of alveolar socket
- Replantation
- Splinting (2 weeks)
- Wound treatment



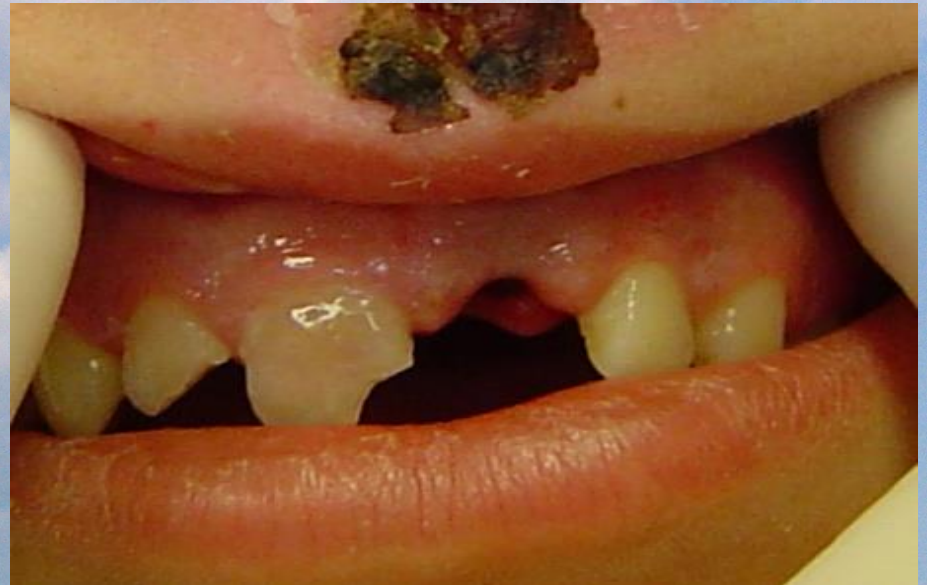Luxatio totalis dentis permanentis

- Pulpy diet
- Cleaning
- Chlorhexidin
- AB
- Tetanus

1week later:

- Root canal treatment
- Control

If replantation is not possible?



Luxatio partialis dentis permanentis

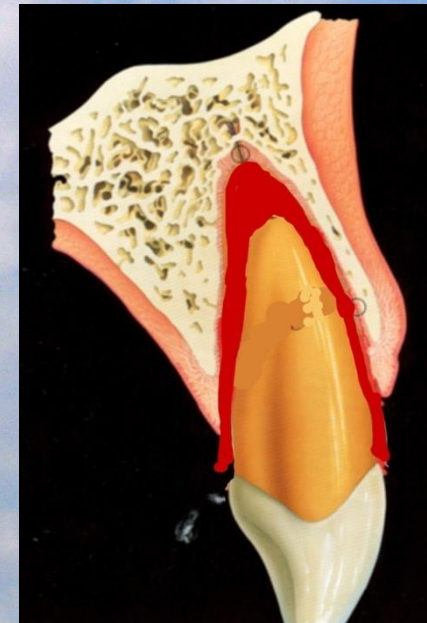
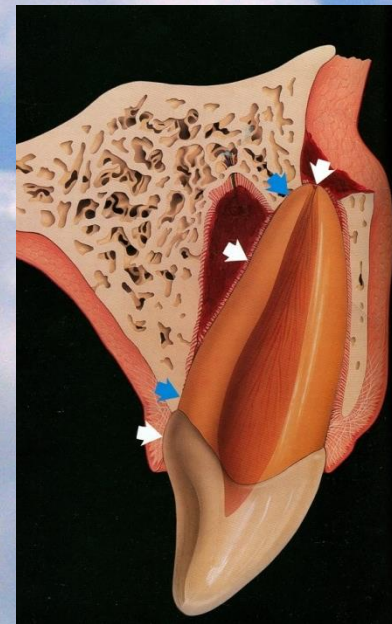
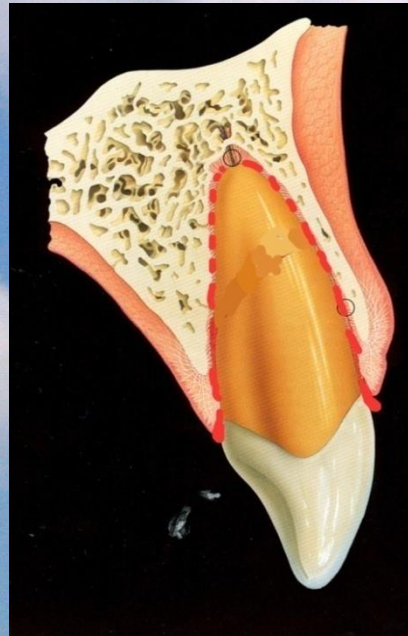
Subluxation

- Observation

Lateral luxation

Extrusion

- Reponation
- Fixation
- Later orthodontic treatment



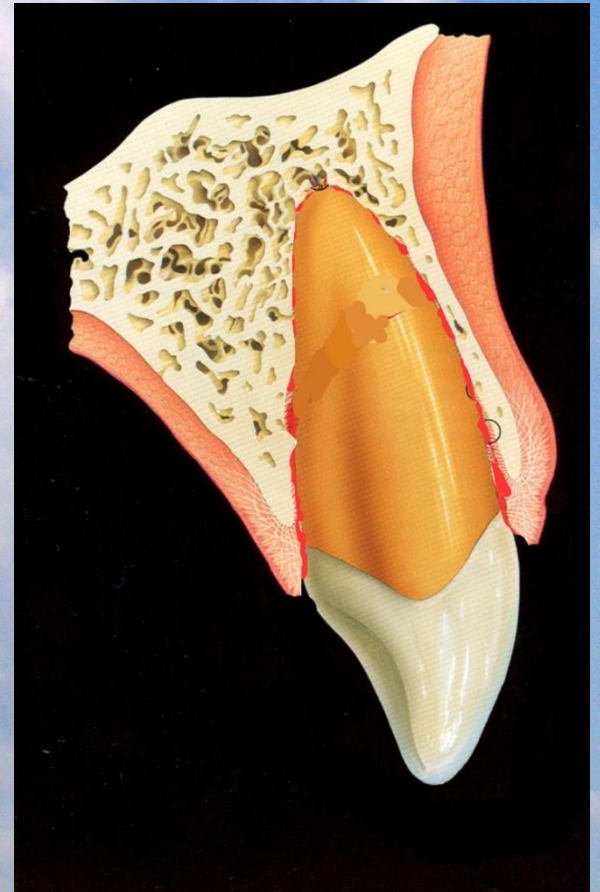
Intrusio

Open apex:

- spontaneous re-eruption

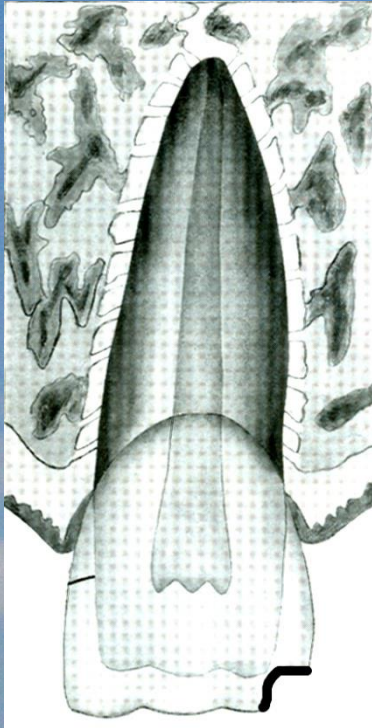
Closed apex:

- surgical or ortho. reposition
- Splinting
- RCT

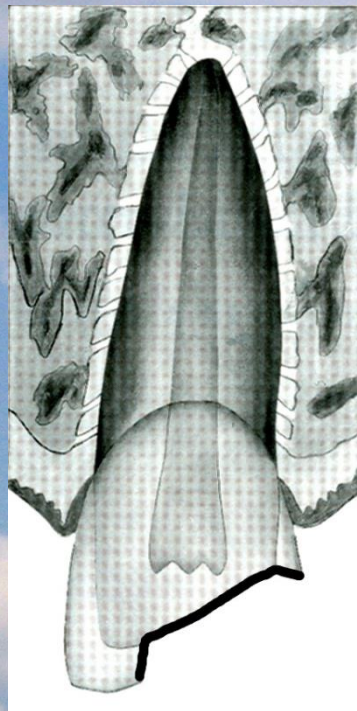


Fractura coronae dentis permanentis

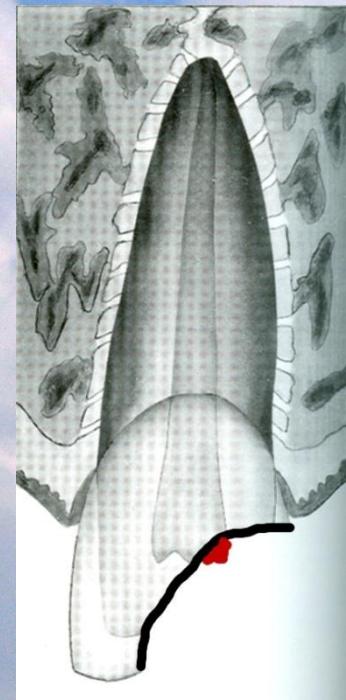
Most frequent injury



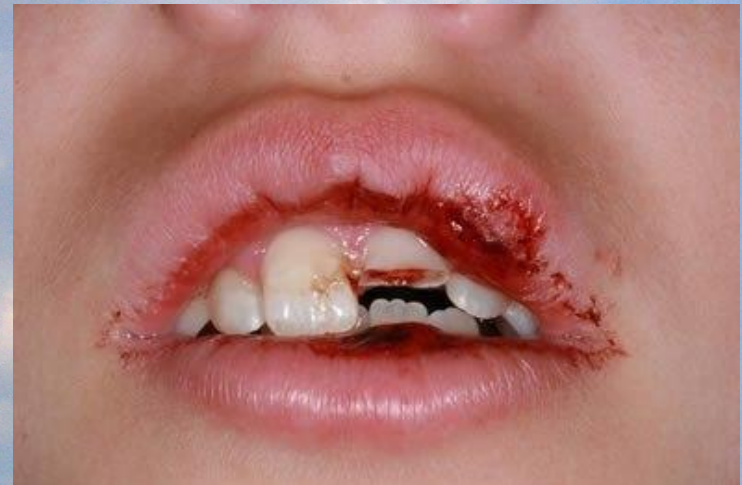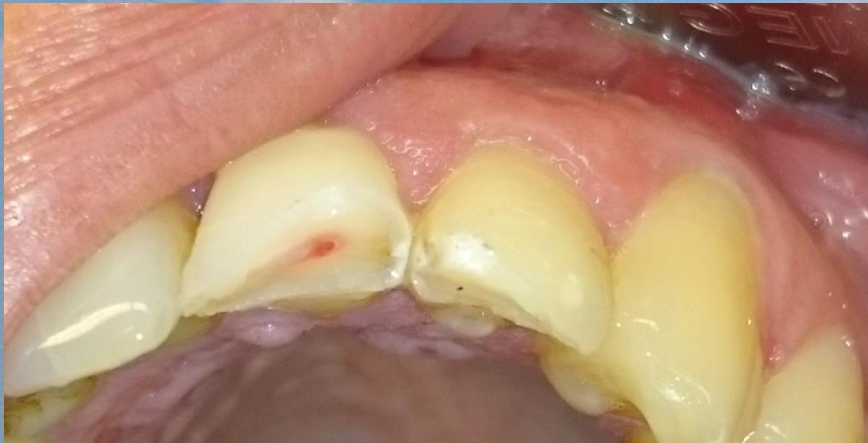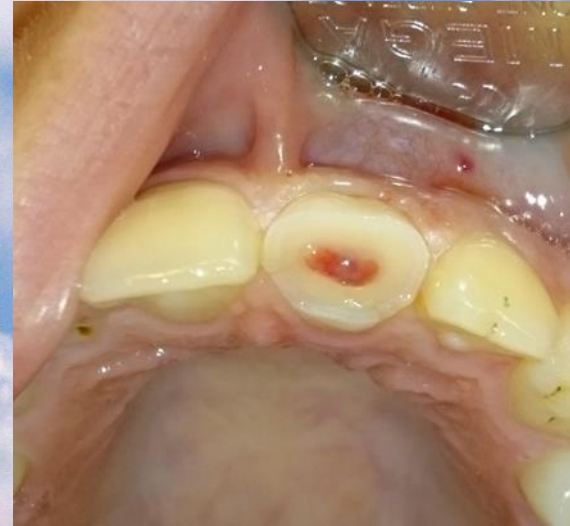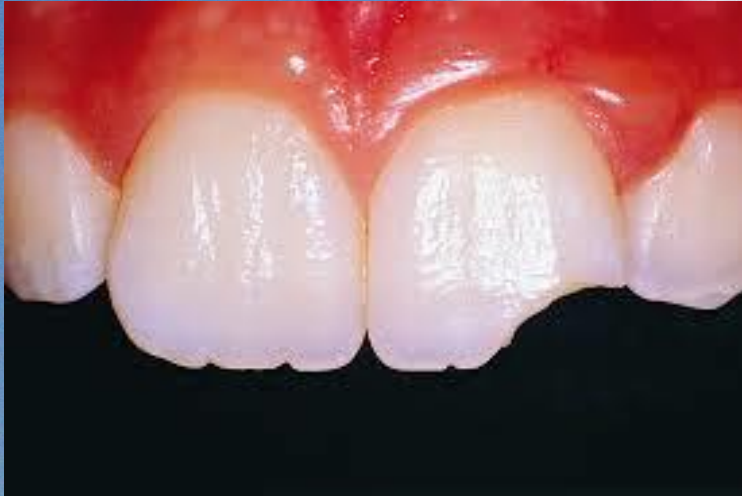Only Enamel



Enamel&Dentin Pulp exposition



Fractura coronae dentis permanentis

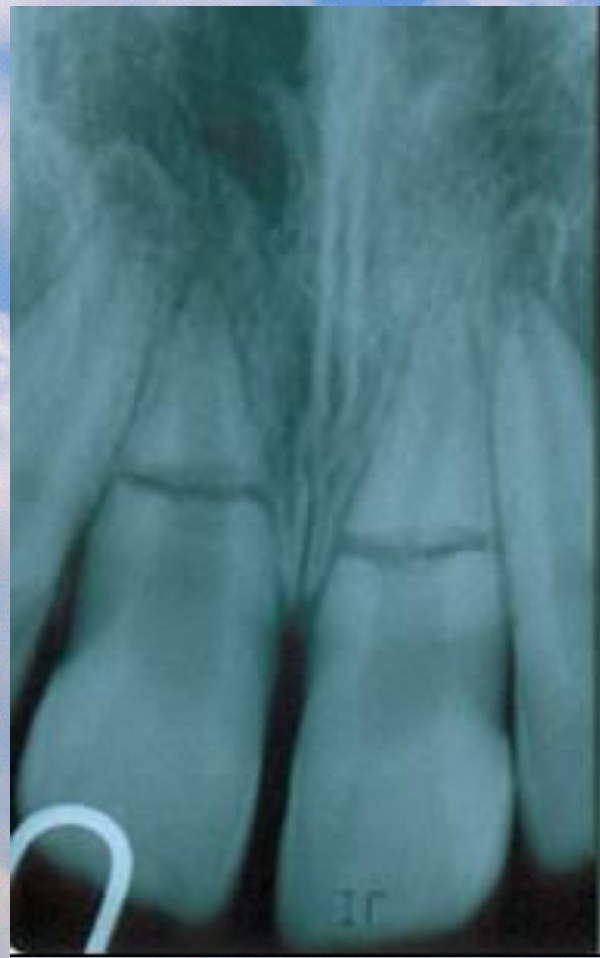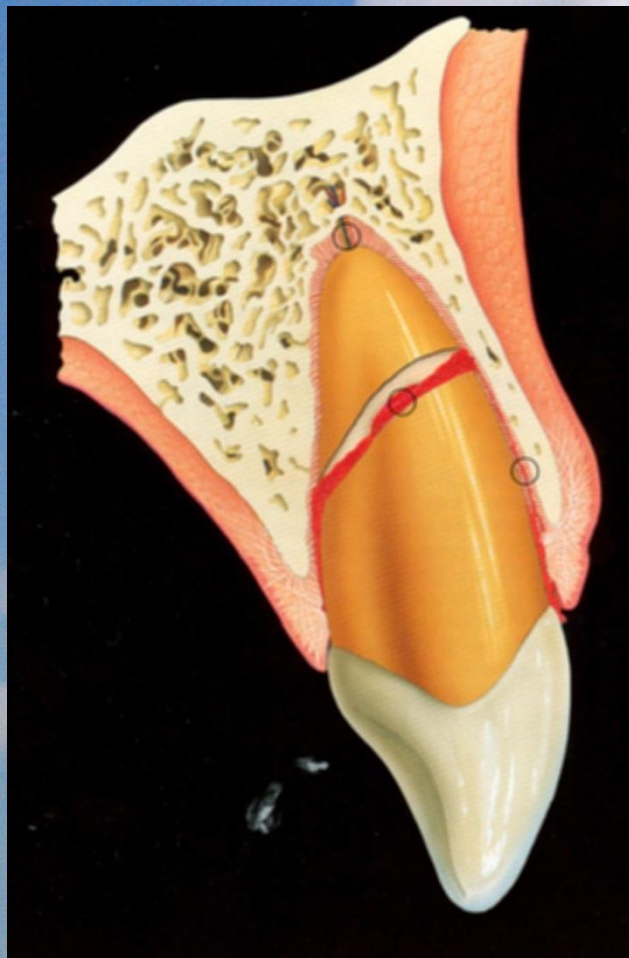


Fractura coronae dentis permanentis

The treatment of crown fracture depends on which third of the crown is injured

- Only polishing
- Fluoride solution
- Composite restoration
- RCT (by pulp exp.)
- Final restorations (closed apex)

Fractura radices dentis permanentis



Fractura radice dentis permanentis

Fracture in cervical third

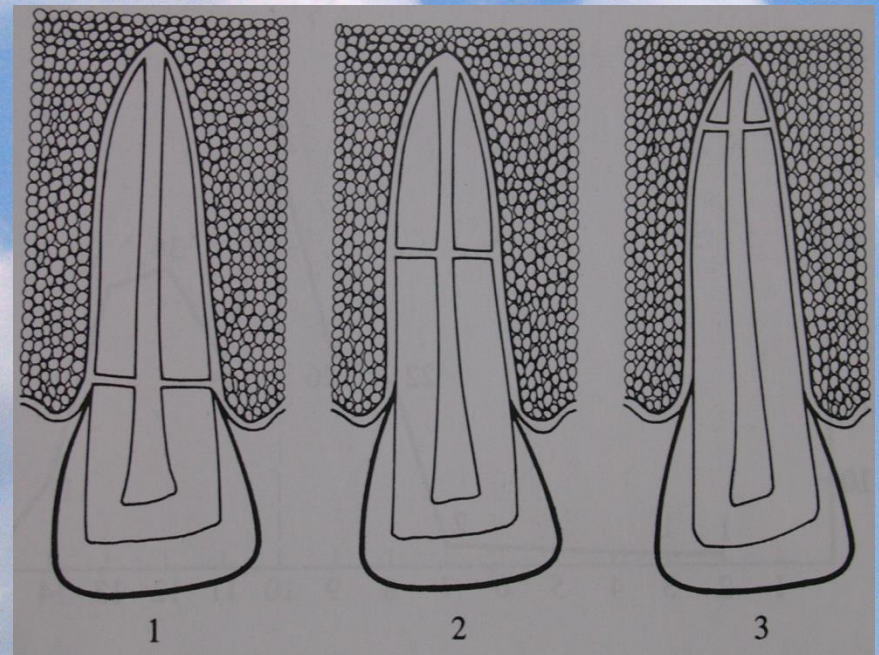
- Orthodontic extrusion
- Extraction & implantation

Fracture in middle third

- Reposition & splinting & RCT

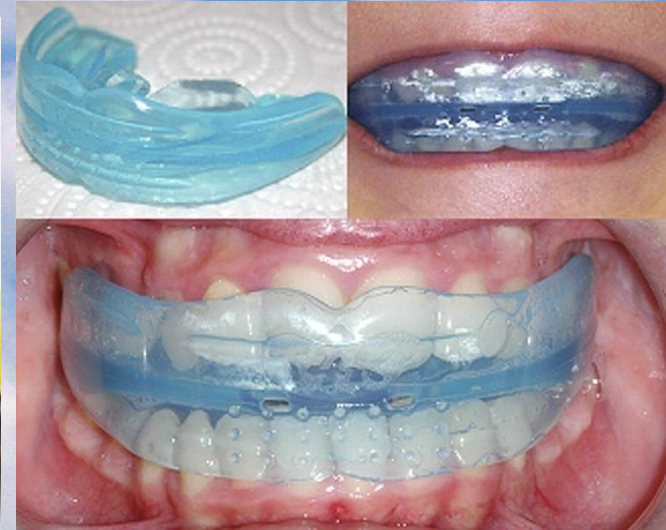Fracture in apical third

- Observation
- RCT

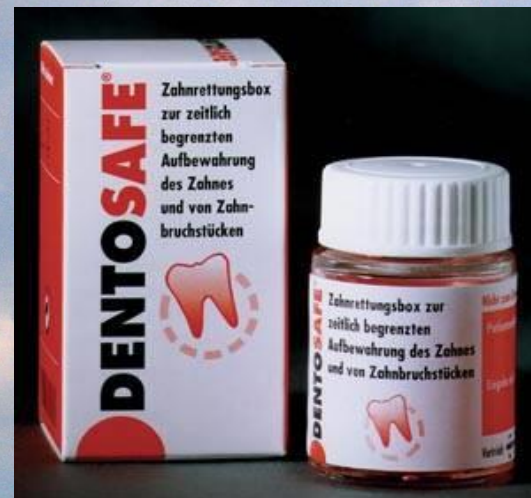

Prevention

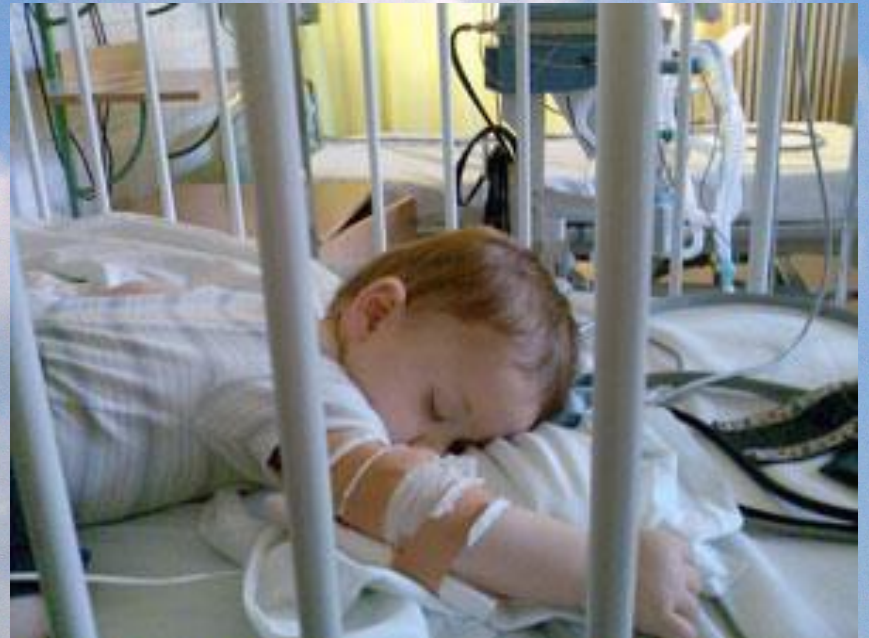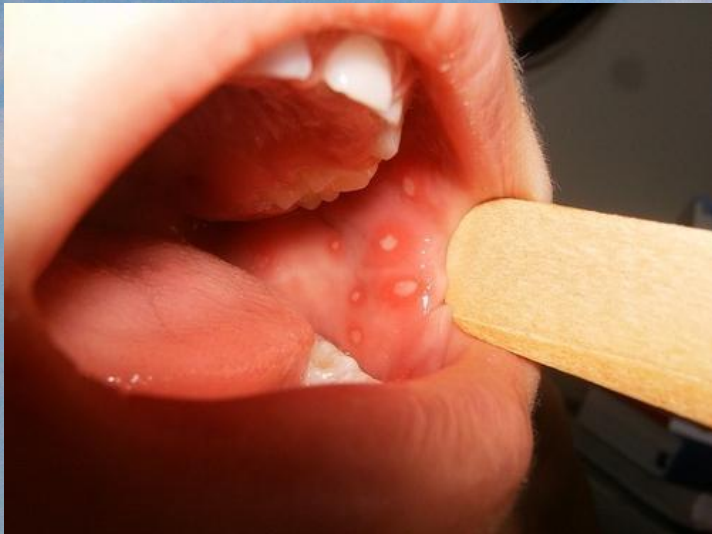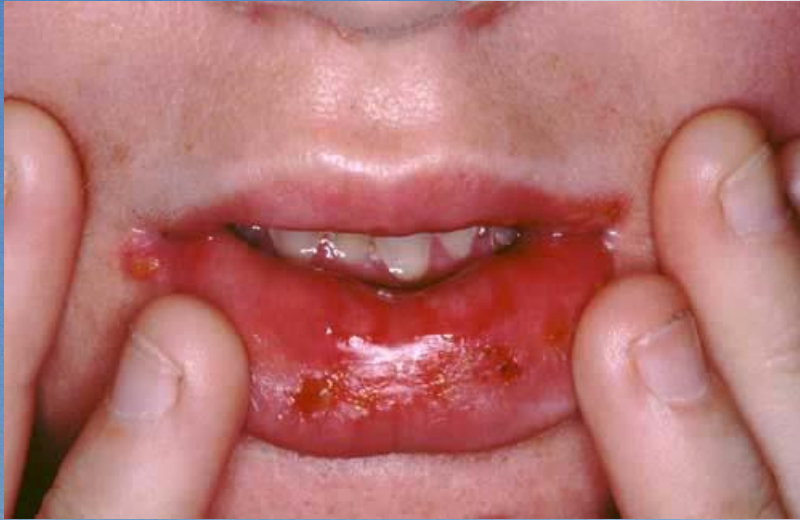- Protection
Mouthguard



- Education
Dentosafe box



Other emergency cases



Thank you for your kind attention!

