

Semmelweis University
Department of Anatomy, Histology and Embryology
2018/2019

Faculty of Dentistry
2nd year, 2nd semester

ANATOMY HANDBOOK



Dr. Andrea D. Székely
Associate Professor
Course Director of the English Language Program

Dr. Gábor Gerber
Associate Professor
Deputy Head of the Department of Anatomy
Dean of the Faculty of Dentistry



Anatomy, Histology and Embryology for ED students

TEACHING DEPARTMENT:

SEMMELWEIS UNIVERSITY

Department of Anatomy, Histology and Embryology

Budapest, Tűzoltó utca 58.

H-1094 Budapest

<http://semmelweis.hu/anatomia/en/>

LEARNING OBJECTIVES

Aims of the lectures in Anatomy - Presentation of important and/or complicated topics such as: 1st semester - the structure of the body wall (e.g. thorax, pelvis), extremities and the cranium, 2nd semester - the morphology of internal organs including the cardiovascular, digestive and urogenital systems; 3rd semester - the composition of the central nervous system, together with the organs of special senses and topography of body regions, and the 4th semester is devoted entirely to maxillofacial topographical anatomy.

Aims of the lectures in Histology - Presentation of the cell, basic principles in cellular morphology, detailed description of the epithelial, connective, muscle and nervous tissues. During the 3 semesters, the lectures contribute to the gross anatomical description of organs with a detailed presentation of their fine structures, including ultrastructural details. Important chapters: basic tissues, viscera, central nervous system.

Aims of the lectures in Embryology - Presentation of the early development from the differentiation of the germ cells to the formation of the human embryo (basic embryology) as well as the development of the locomotor system (1st semester). In the 2nd and 3rd semesters, the embryology topics will complement the gross anatomy and histology lectures of the organs and systems, also mentioning the most frequent malformations.

For the deeper understanding of relatively difficult questions small group discussions may be organized during the practical dissection room classes.

Aims of the practical dissection classes - In the first three semesters, based on their weekly programs, the students will study the morphology of the human body using anatomical specimens (bones, joints, muscles, viscera, brain) as well as learning the basic principles of dissection, including the proper usage of tools (scalpel, forceps, scissors) under the supervision of their lab instructors. The anatomy of the locomotor system and the peripheral nervous system will be principally taught in the dissecting room.

Aims of the histology practical classes - Under supervision by the lab instructor, the students will learn the use of the light microscope and the individual viewing of histology slides will facilitate the understanding of the basic tissues (epithelial, connective, muscle and nervous) and the fine structure of the organs.

The knowledge of students will be tested by regular **mid-term examinations** and a Semester-end Dissection Test.

Lectures:

First semester: 3x 45 min; second semester: 3x 45 min;

third semester: 3x 45 min; fourth semester: 3x 45 min.

Topics:

First semester: Gross anatomy of the bones, joints and muscles, basic histology, general embryology, development of the skull, spine and limbs.

Second semester: Morphology, histology and embryology of the heart and vessels, lymphatic organs, viscera, body cavities and serous membranes. Sectional anatomy of the thorax, abdomen and pelvis. Description of the diaphragmas.

Third semester: Morphology, histology and embryology of the central and peripheral nervous systems, the organs of special senses, as well as of the endocrine organs; topographical anatomy of the extremities.

Fourth semester: Maxillofacial anatomy - organs, cavities, nervous and vascular supply of the head and neck regions, including topographical and cross sectional anatomy. Revision of the topics of the first three semesters.

Practical course:

First semester 5x 45 min; second semester: 4x 45 min;

third semester: 4x 45 min; fourth semester: 2x 45 min;

First semester: Gross anatomy of the bones, joints and muscles, basic histology, general embryology, development of the skull, spine and limbs.

Second semester: Morphology, histology and embryology of the heart and vessels, lymphatic organs, viscera, body cavities and serous membranes. Sectional anatomy of the thorax, abdomen and pelvis. Description of the diaphragmas

Third semester: Morphology, histology and embryology of the central and peripheral nervous systems, the organs of special senses, as well as of the endocrine organs; topographical anatomy of the extremities.

Fourth semester: Topographical anatomy of the head and neck. Individual revision of the subjects taught and studied during the four semesters.

Type of exams: first, second and third semesters: semifinal examination, fourth semester: final exam from the subjects of the four semesters.

ECTS credits: four semesters together: 27 (first semester: 8; second semester: 7; third semester: 7; fourth semester: 5)

MAXILLOFACIAL ANATOMY ANNOUNCEMENTS

Acceptance of the semester: active participation in lectures, and dissection room sessions is obligatory for every student. Students should attend at least 75% of the scheduled hours to gain a signature proving the validity of the semester. Absences are therefore limited in **25%**. Presence will be recorded in the lectures and in the dissection room classes.

Midterm examinations: During the 4th semester, both practical and theoretical knowledge will be regularly evaluated. The midterms will be either oral and written exams. The **maxillofacial midterm** includes the identification of a number of anatomical and histological features in projected images as well as theoretical questions related to the subject. The **anatomy midterm** includes both the identification of several structures on the specimen and oral theoretical questions related to the subject. A

The date of the tests is always set previously. The results of all tests will appear on the personal achievement cards.

Evaluation is made using a five-grade scale (1-5)

Those who fail, or absent from, both of the midterms will have to sit for an oral practical retake (exact date TBA) during the last two weeks of the semester.

A practical mark is calculated from the result of the midterms together with a „diligence mark” given by the instructor.

The obligatory dissection task has to be presented before the end of the 4th semester.

Final examination

The final examination consists of a written pretest (100 questions) and two practical/oral parts:

Histology: 2 slides and a oral question in Maxillofacial Anatomy

Anatomy: Identification of structures on prosected cadaver specimen and/or skull.

*N.B. – In case neither the first nor the repeated takes of a final exam have been successful, the students may sit for a CV final examination in the **subsequent winter examination period**, in case they have „chances” left, or, may repeat the semester in the following year.*

RULES AND REGULATIONS IN THE DISSECTING ROOM

IT IS STRICTLY FORBIDDEN to eat, drink, smoke, to chew gums, or to use music devices or phones.

Bags and coats should be left in the lockers before entering the dissecting room.

The lockers will have to be locked using your padlocks.

Please, remember to keep your valuables always on you, or lock them in the lockers since the department takes no responsibility for lost items.

Everybody is supposed to behave in the dissecting room conforming to the spirit of the site. Loud speech, out-of-place jokes and any kind of behaviour, disregarding the dignity of human corpses, should strictly be avoided.

Students are expected to be prepared for the practical work.

Students should take care of the furniture and equipment of the dissecting room. Do not sit on the dissection tables or stand on the tripod stools to avoid accidents. **Fire and work safety regulations** should be maintained. The dissection room is a hazard area. **Cleanliness and order** should be kept.

Working in the dissection room involves the use of **sharp and pointed tools**, injuries should be reported to the lab instructor. The technical personnel will provide first aid when necessary.

The white lab coats should be worn while in the dissection room, but should be removed before leaving the dissection room area. The purpose of wearing the lab coats is to protect one's clothing from contacting the cadaver specimen. Furthermore we advise you to wear closed toed shoes and clothing covering the legs. In the end of the class, lab coats should be emptied and left in order on the coat hangers. The department is not responsible for valuables left in the dissecting room.

Only the members of the study group can participate in the sessions, visitors may be present only with prior permission by the lab instructor. Students can leave the sessions only with the approval of the lab instructor.

Photos, or videos of blackboard/smart board drawings or anatomical or histological schematics can only be made with the agreement and in the presence of the lab instructor.

Specimen preparations should be wrapped and labeled. Dissection materials of other groups or individuals should not be handled. Dissected cadaver pieces should be discarded in a designated container and discarded blades have to be collected separately.

Dissecting rooms are closed between 6:00 PM to 8:00 AM and over the weekends Students may not stay in the dissecting room without the supervision of one of the assistants of the department. In the absence of an instructor, the technical personnel should ask the students to leave the dissecting room.

**SMOKING IS STRICTLY FORBIDDEN
ON THE DEPARTMENTAL PREMISES,
INCLUDING THE GARDEN AND THE YARD!**

ED II MAXILLOFACIAL ANATOMY

Subject matter of the 4th semester

The topics of the semester include the chapters of Maxillofacial Anatomy as well as the entire material of the previous semesters, including Anatomy, Embryology and Histology.

MIDTERM TESTS

Test I.

Place: Histology Laboratory (e-learning type written test)

Topic: 1-19. lectures

Date: 7th study week, March 21.

Test II.

Place: Dissection room (practical test)

Topic: Topographical and sectional anatomy of the head and neck + their internal organs

Date: 13th study week, May 6.

FINAL EXAMINATION

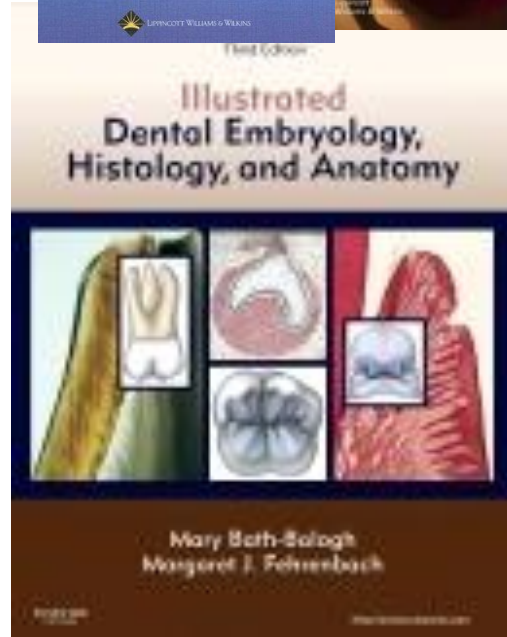
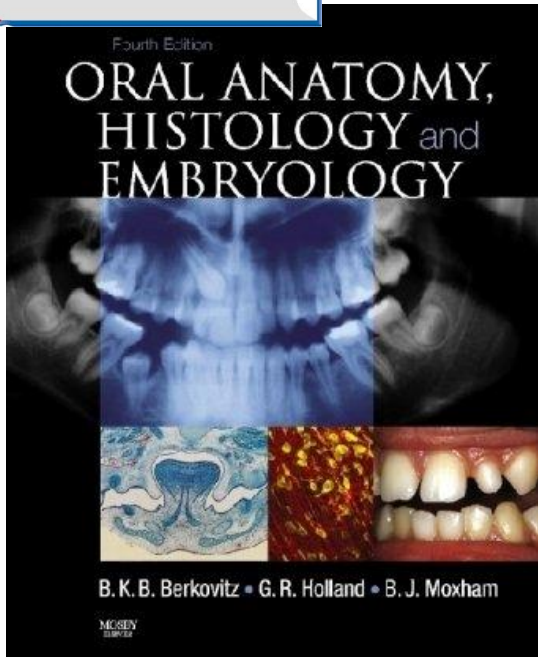


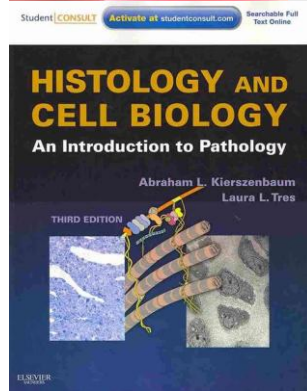
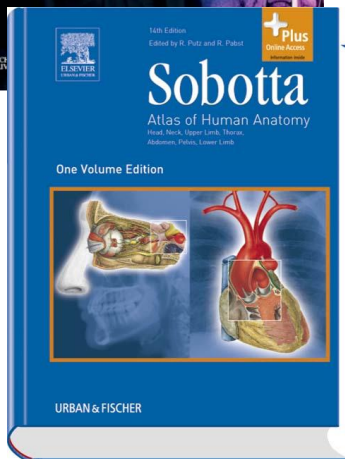
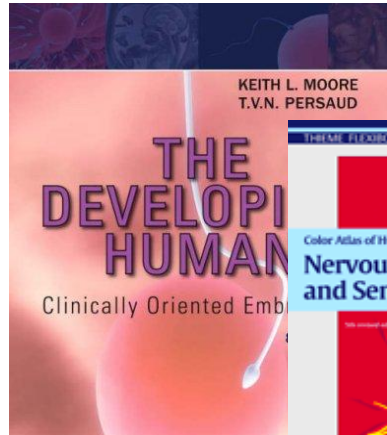
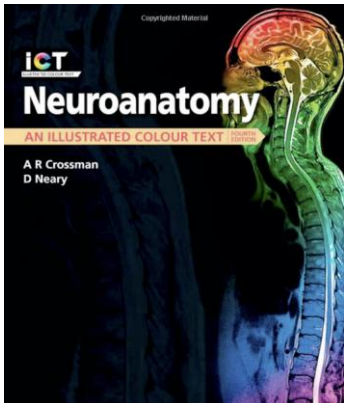
Topics: Subject matter of the 4 semesters in Anatomy, Histology and Embryology

The final examination consists of three parts:

1. Written pretest
2. Histology (2 slides) including relevant theoretical questions
3. Oral theoretical question in Maxillofacial Anatomy
4. Anatomy (identification of structures on true anatomical specimens) including relevant theoretical questions
(the Topic List is included in the last section of the Handbook)

Week	Lectures <i>Monday 10.00 – 11.40 and Thursday 14.00 – 14.45</i>	Dissection room <i>Monday 8.00 - 9.30</i>
Week 1 Febr. 4-8.	1. Introduction, composition and development of the skull 2. Maxilla, mandible. The temporomandibular joint, masticatory muscles, mechanism of mastication 3. Walls and parts of the oral cavity, the oral mucosa	Bones and spaces of the skull, content of the orbit
Week 2. Febr. 11-15	4. Anatomy, histology and innervation of the tongue 5. Topography, histology, innervation of the salivary glands 6. The palate and the faucial isthmus	TDK Conference - OPTIONAL DISSECTION CLASS Prosected specimen: demonstration of the head@neck: oral cavity, tongue and the salivary glands
Week 3. Febr. 18-22.	7. Nasal cavity and paranasal sinuses 8. The pharynx and the parapharyngeal spaces 9. The cavity, muscles and the mucosa of the larynx	Prosected specimen: demonstration of the head@neck: oral cavity, tongue, salivary glands pahrynx, larynx. Mediansagittal section of head
Week 4. Febr. 25- March 1.	10. Development of the face, malformations 11. Pharyngeal pouches, development of the tongue 12. Anatomy of the teeth I	Prosected specimen: demonstration of the head@neck: oral cavity, tongue, salivary glands pahrynx, larynx. Mediansagittal head section Teeth
Week 5. March 4-8.	13. Anatomy of the teeth II. 14. Histology of the teeth I. 15. Histology of the teeth II.	Prosected specimen: demonstration of the head@neck: oral cavity, tongue, salivary glands pahrynx, larynx. Mediansagittal head section Teeth, morphology and histology (photos)
Week 6. March 11-15. March 15 is National Holiday	16. Parodontium 17. Bone formation, bone remodelling and supplementation 18. Tooth development, malformations	Prosected specimen: demonstration of the head@neck: oral cavity, tongue, salivary glands pahrynx, larynx. Mediansagittal head section Teeth, morphology and histology (photos)
Week 7. March 18-22.	19. <i>Anatomical relevances in gnathology</i> 20. Blood vessels of the head&neck region 21. Midterm test 1 (written): Lectures 1-19.	Prosected specimen: demonstration of the head@neck: oral cavity, tongue, salivary glands pahrynx, larynx. Mediansagittal head section Teeth, morphology and histology (photos)
Week 8. March 25-29.	22. The lymphatic system of the head&neck region 23. Nerves of the head&neck region I.: CN 5 24. Innervation of the teeth and the gingiva, the anatomy of dental local anaesthesia	Maxilla, mandible. Prosected specimen: demonstration of the temporomandibular joint, muscles of mastication and facial expression.
Week 9. April 1-5.	25. Reflex arc of mastication, the clinical anatomy of trigeminal neuralgia 26. Nerves of the head&neck region II. CN 7 and 9 27. Nerves of the head&neck region III CN 10, 11 and 12	Prosected specimen (torso and head): demonstration of the vessels and nerves of the head&neck regions. Regional anatomy of the head
Week 10. April 8-12.	28. Topography of the viscerocranium. The orbit 29. Superficial regions and muscles of the head 30. Deep regions and sectional anatomy of the head	Prosected specimen (torso and head): demonstration of the vessels and nerves of the head&neck regions. Regional anatomy of the head
Easter break (2019 April 15-19.)		
Week 11. April 23-26.	31. - Easter Monday 32. - Easter Monday 33. Superficial regions, muscles and fasciae of the neck	Easter Monday <i>During the week</i> CONSULTATION - Prosected specimen (torso and head): demonstration of the vessels and nerves of the head&neck regions.
Week 12. April 29- May 3. April 30 is Faculty day	34. Deep regions and sectional anatomy of the neck 35. The concept of the spinal nerve, dorsal branches, branches of the cervical plexus 36. The cutaneous innervation of the head&neck region	Prosected specimen (torso and head): demonstration of the vessels and nerves of the head&neck regions. Regional anatomy of the head Demonstration of the final's specimens: parapharyngeal space, cross section of the thorax, pelvis, head and neck
Week 13. May 6-10.	37. Topography of the neurocranium 38. The cranial parasymphathetic and sympathetic system 39. Surgical relevances of the head and neck region	Midterm test 2 Topographical and sectional anatomy of the head and neck regions including their internal organs
Week 14. May 13-17.	40. Imaging anatomy of the jaws, teeth and the maxillary sinus (Radiology lecture) 41. Histology revision 1. 42. Histology revision 2.	Revision

RECOMMENDED BOOKS



TOPICS OF THE FINAL EXAMINATION IN ANATOMY, HISTOLOGY AND EMBRYOLOGY

EMBRYOLOGY

Spermatogenesis

Oogenesis, Female reproductive cycles

Fertilization, cleavage of the zygote

Blastocyst formation. The bilaminar embryonic disc

Implantation

Gastrulation, The notochord

Neurulation

Development and differentiation of the neural tube

Derivatives of the ectoderm

Derivatives of the endoderm

Differentiation of the mesoderm. Formation and derivatives of the somites

Derivatives of the mesoderm

Lateral mesoderm and its derivatives

Folding of the embryo

Development of the primitive cardiovascular system and the placental circulation

The structure of the placenta

Fetal membranes. Umbilical cord

The embryonic and fetal periods. Parturition, multiple birth

Stages of human prenatal development

Development of the limbs

Development of the skull

Development of the muscular system

Early development of the heart. Folding of the heart tube.

Development and partitioning of the primitive atrium

Development and partitioning of the primitive ventricle.

The aorticopulmonary septum.

Development of the great arteries. Derivatives of the aortic arches.

Development of the inferior vena cava and the portal vein.

Development of the superior vena cava, the azygos and hemiazygos veins.

The fetal and neonatal circulation

Development of the face and palate

Development of nasal cavity and paranasal sinuses

Development of the teeth and the tongue

Development of the branchial arches and their derivatives

Development of laryngo-tracheal tube, bronchi and the lung

Development of branchial grooves, the pharyngeal pouches and their derivatives

The formation and differentiation of the foregut

Formation and development of the midgut

Development of liver and pancreas

The formation and differentiation of hindgut

Development of the kidneys

Development of the urinary passages
Development of the gonads
Development of the male genital ducts and auxiliary glands
Development of the female genital ducts and auxiliary glands
Development of the male and female external genitalia
Formation and division of the body cavities
Development of the peritoneum
Development and differentiation of the spinal cord
Development of the forebrain
Development of the peripheral nervous system
Development of the eye and optic nerve
Development of the organs of hearing and equilibration.

HISTOLOGY

Concept of basic tissues .
Definition and classification of epithelial tissue
Simple epithelia
Stratified epithelia
Membrane specialisations of epithelia
Glandular epithelia
Pigment epithelium and sensory epithelium
Cells of connective tissue
Ground substance and fibres of connective tissue
Types of connective tissue
Blood and the formed elements of blood
Bone marrow maturation of erythrocytes and platelets
Maturation of granulocytes, lymphocytes and monocytes.
Histology of cartilage
Histology of the bone
Intramembranous ossification
Endochondral ossification
Growth and remodeling of bone
Smooth muscle and myoepithelial cells
Histology skeletal muscle
Cardiac muscle
Sarcoplasmic reticulum and transverse tubule system
Histology of the neuron
Microscopic structure of neurons in the CNS
Neuroglia
Nervous and supporting cells in the CNS
Neurons and supporting cells of the neural crest
Nerve fibres, Myelin sheath
Receptors. Effectors. Motor end-plate
Interneuronal synapses
Gross anatomy of pituitary gland. Histology and development of neurohypophysis
Blood supply of pituitary. Histology of adenohypophysis
Gross anatomy and histology of pineal body

Gross anatomy, histology and development of the thyroid gland
Gross anatomy, histology and development of the parathyroid glands
Microscopic anatomy and development of adrenal cortex
Gross anatomy of adrenal glands, Histology and development of adrenal medulla
Histology of pancreas and the islets of Langerhans
Microscopic anatomy of lymph nodes
Gross and microscopic anatomy of the spleen
Microscopic anatomy of thymus
Microscopic anatomy of tonsils
Microscopic anatomy of arteries and arterioles
Microscopic anatomy of capillaries and veins
Microscopic anatomy of skin
Microscopic anatomy of epidermal appendages of skin and mammary glands
Microscopic structure of the wall in the gastrointestinal tract
Microscopic structure of exocrine glands
Microscopic structure of intestinal villi

LOCOMOTOR SYSTEM

Architecture and classification of bones
Fibrous and cartilaginous joints
Components of synovial joints
Classification of synovial joints. Movements and mechanisms
Structure and actions of somatic muscles
Structure of the vertebral column and the muscles responsible for its movements
Movements of the head and the muscles participating in them
Osteofibrous structure of the thoracic cage
Joints of the shoulder girdle and the muscles acting on them
The shoulder joint and the muscles acting on it
The axilla, the quadrangular and triangular spaces
The elbow joint, movements and muscles acting on it
The cubital fossa
Muscles and cross section of the arm
Muscles and cross section of forearm
Structure and movements at the wrist joint and the muscles acting on it
Osteofibrous spaces and muscle compartments of the hand
Joints of fingers and muscles concerned in their movements
Joints of the thumb and the muscles concerned in their movements
Structure of the osteofibrous pelvis
Muscles of the buttock, the posterior abdominal wall and the pelvis (external and internal muscles of the hip).
The hip joint and muscles concerned in its movements
Osteofibrous compartments, muscles and cross section of the thigh
The knee joint and muscles concerned in its movements
Popliteal fossa
Femoral sheath, vascular and muscular compartments. Adductor canal
Osteofibrous compartments, muscles and the cross section of the leg
Ankle joint and muscles concerned in its movements

Subtalar and talocalcaneonavicular joints and muscles acting on them
Structure of the foot. Arches of the foot
Osteofibrous compartments of the foot
Mechanism of walking
Anterior cranial fossa (composition, boundaries, connections)
Middle cranial fossa (composition, boundaries, connections)
Posterior cranial fossa (composition, boundaries, connections)
Walls and connections of the orbit
Walls and connection of the nasal cavity
Inferior surface and connections of the base of the skull
Bony walls of the oral cavity, the temporal and infratemporal fossa
Walls and connections of the pterygopalatine fossa
Temporomandibular joint and the muscles concerned in its movements
Diaphragm
Lateral superficial abdominal muscles and fasciae
Rectus abdominis muscle and its sheath
Inguinal canal
Femoral canal
Muscles of the pelvic floor
Superficial muscles of the neck and the muscle triangles
Deep muscles of the neck and the laminae of the cervical fascia
Muscles of facial expression

CIRCULATION

Shape and surfaces of the heart
Skeleton of the heart
Structure of the myocardium
Chambers of the heart
Endocardium and the valves of the heart
Conducting system of the heart
Blood supply of the heart
Pericardium
Surface anatomy of the heart. Heart sounds
Position and radiology of the heart.
The pulmonary circulation
Subdivisions and topography of the aorta
Arch of the aorta and its branches
Subclavian artery and its branches
Axillary artery and its branches
Arteries and veins of the arm and forearm
Vessels of the hand
External carotid artery and its branches
Maxillary artery and its branches
Course and distribution of the internal carotid artery
Venous drainage of the head
Course and branches of the thoracic aorta
Course and branches of the abdominal aorta

Coeliac trunk and its branches
Superior mesenteric artery and its branches
Inferior mesenteric artery and its branches
Branches of the internal and external iliac arteries
Vessels of the thigh and leg
Vessels of the foot
Course and tributaries of superior vena cava
Course and tributaries of inferior vena cava
Portal system of veins. Communication between portal and systemic veins
Venous and lymphatic drainage of the body wall including the breast
Lymph nodes and lymphatic drainage of head and neck
Lymphatic drainage of upper limb
Lymphatic drainage of lower limb
Thoracic and the right lymphatic ducts.

ORGANS OF SPECIAL SENSES

Fibrous coat of the eyeball
Vascular coat of the eyeball
Retina
Visual pathways
Optic lens and the convergence-accomodation reaction
Chambers of eye and vitreous body
Extrinsic muscles of the eyeball
Eyelids, conjunctiva, fascial sheath of eyeball. Lacrimal apparatus
External ear and tympanic membrane
Walls of the tympanic cavity. Auditory tube
Shape, joints and muscles of auditory ossicles.
Bony and membranous labyrinth
Bony cochlea and cochlear duct
Auditory pathways
Organs of taste and olfaction

INTERNAL ORGANS

Oral cavity
Gross anatomy and histology of tongue
Morphology of the permanent teeth, blood and nerve supply
Fine structure of dentin and enamel
Histology of cementum and periodontium
Development of teeth. Dentition
Gross anatomy, histology and topography of salivary glands
Isthmus of fauces
Gross anatomy and muscles of pharynx
Microscopic anatomy, blood and nerve supply of pharynx
Topography of pharynx. Para and retropharyngeal spaces
Gross anatomy, histology and topography of oesophagus
Gross anatomy and peritoneal relations of stomach
Microscopic anatomy of stomach

Gross anatomy of duodenum
Gross anatomy of jejunum and ileum
Microscopic anatomy of small intestines
Microscopic structure of intestinal villi
Gross anatomy of large intestines and vermiform appendix
Microscopic anatomy of large intestines
Gross anatomy and histology of rectum and anal canal
Gross anatomy and peritoneal relations of liver
Microscopic structure of liver
Gross and microscopic anatomy of gall bladder and bile ducts
Gross anatomy and topography of pancreas
Structure of nasal cavity and paranasal sinuses
Skeleton of larynx. Joints and fibroelastic membranes
Cavity of larynx. Mucous membrane and muscles
Gross anatomy and histology of trachea
Bronchial tree. Histology of the lung
Gross anatomy of the lung
Pleura
Subdivision and contents of mediastinum
Gross anatomy of the kidney
Microscopic anatomy of the kidney
Gross anatomy and histology of renal pelvis and ureter
Gross and microscopic anatomy of urinary bladder
Gross anatomy and histology of male and female urethra
Gross anatomy of the testis
Histology of the testis
Gross and microscopic anatomy of epididymis and ductus deferens
Spermatic cord, scrotum and coverings of testis
Gross anatomy and histology of seminal vesicle and prostate
Gross anatomy and histology of penis. Mechanism of erection
Gross anatomy of the ovary
Histology of the ovary
Gross and microscopic anatomy of the uterine tube
Gross anatomy and fixation of the uterus
Histology of the uterus. Menstrual cycle
Gross anatomy and histology of vagina and female external genitalia
Topography of female genital organs in the pelvis. Connective tissue spaces, peritoneal relations
Topography of male genital organs in the pelvis. Connective tissue spaces, peritoneal relations
Anatomy of peritoneum . Lesser and greater omentum. Omental bursa, mesentery.

NERVOUS SYSTEM

Gross anatomy of spinal cord. Spinal segment. Spinal nerve. Blood supply and meninges of the spinal cord
Microscopic structure of spinal cord
Spinal proprioceptive reflex arc

Spinal flexor (withdrawal) reflex arc
Spinal autonomic reflexes
Fourth ventricle
Gross and microscopic anatomy of medulla oblongata
Gross and microscopic anatomy of pons
Gross and microscopic anatomy of midbrain
Cranial nerve nuclei
Tracts of the brainstem
Reticular formation and monoaminergic brainstem systems
Gross and microscopic anatomy of cerebellum
Afferent and efferent connections of cerebellum
Anatomy, blood supply and development of the diencephalon
Third ventricle
Gross and microscopic anatomy of thalamus
Hypothalamo-hypophyseal systems
Gross anatomy of hemispheres
Gross and microscopic anatomy of basal nuclei
Lateral ventricles
Arterial circle of Willis and veins of the brain
Microscopic structure of cerebral cortex. Cortical areas
Spinothalamic tract
Dorsal funiculus-medial lemniscus system
Pyramidal tract
Extrapyramidal system
Limbic system
Cranial dura mater and its sinuses
Arachnoid and pia mater. Subarachnoid cisterns Cerebrospinal fluid
Central nuclei and peripheral distribution of cranial nerves III., IV., VI.
Nuclei of trigeminal nerve and distribution of ophthalmic nerve
Peripheral distribution of maxillary nerve
Peripheral distribution of mandibular nerve
Central nuclei and peripheral distribution of facial nerve
Central nuclei and peripheral distribution of glossopharyngeal nerve
Central nuclei and peripheral distribution of vagus nerve
Nuclei and branches of accessory and hypoglossal nerves
Cervical plexus
Brachial plexus
Dorsal rami of spinal nerves. Intercostal nerves
Lumbar plexus
Sacral plexus
General structure of autonomic nervous system
Cervical and thoracic part of sympathetic trunk
Abdominal and pelvic part of sympathetic trunk
Cranial parasympathetic
Sacral parasympathetic

MAXILLOFACIAL ANATOMY

(theoretical oral question following the Histology parts)

1. Composition of enamel
2. Amelogenesis
3. Composition of dentin
4. Dentinogenesis
5. Fine structure of the dental pulp
6. Composition and formation of the cementum
7. Parodontium
8. Parts and histology of the gingiva
9. Development of teeth, malformations
10. Eruption of teeth
11. Development of the maxilla and the mandible
12. Development of the face, malformations
13. Frontal section of the oral cavity
14. Gross morphology, histology and development of the primary and secondary palate
15. Gross morphology, histology and development of the tongue
16. Topographical anatomy of the oral diaphragm
17. Morphology of the incisors and the canine teeth
18. Morphology of the premolar teeth
19. Morphology of the molar teeth
20. Dentition and exfoliation
21. Blood supply and innervation of the upper teeth
22. Blood supply and innervation of the lower teeth
23. Temporomandibular joint
24. Muscles concerned with the opening and closure of the mouth
25. Muscles of facial expression and mastication
26. Mechanism of mastication
27. Reflex arc of mastication
28. Morphological background of taste perception (gustatory organ, pathways)
29. Gross morphology and histology of the parotid gland, nidus parotideus
30. Gross morphology and histology of the submandibular gland, submandibular region
31. Gross morphology and histology of the sublingual gland, sublingual region
32. Neuroanatomy of trigeminal pain
33. Autonomic innervation of the salivary glands