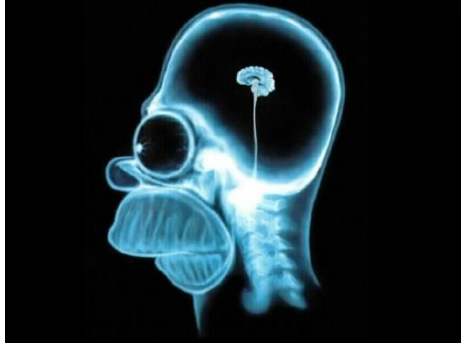

Blood supply to the brain, CSF circulation

ED II. 2017

"The problem is, God gave man a brain and another important organ, and only enough blood to run one at a time…" R. W.

PhD Dr. David Lendvai

Vascular supply and drainage of the brain

- The brain is a highly vascular organ
- It has a high metabolic rate that reflects the energy requirements of constant neural activity
- It receives about 15% of the cardiac output and utilizes 25% of the total oxygen consumption of the body.

Topics

1. Arterial supply of the brain

2. Venous drainage of the brain

3. Chorid plexus and the circulation of CSF

Arterial supply of the brain

Arterial supply of the brain

- The brain is supplied by two **internal carotid arteries** and two **vertebral arteries** that form a complex anastomosis (circulus arteriosus, circle of Willis) on the base of the brain.

Overview of the arterial supply of the brain

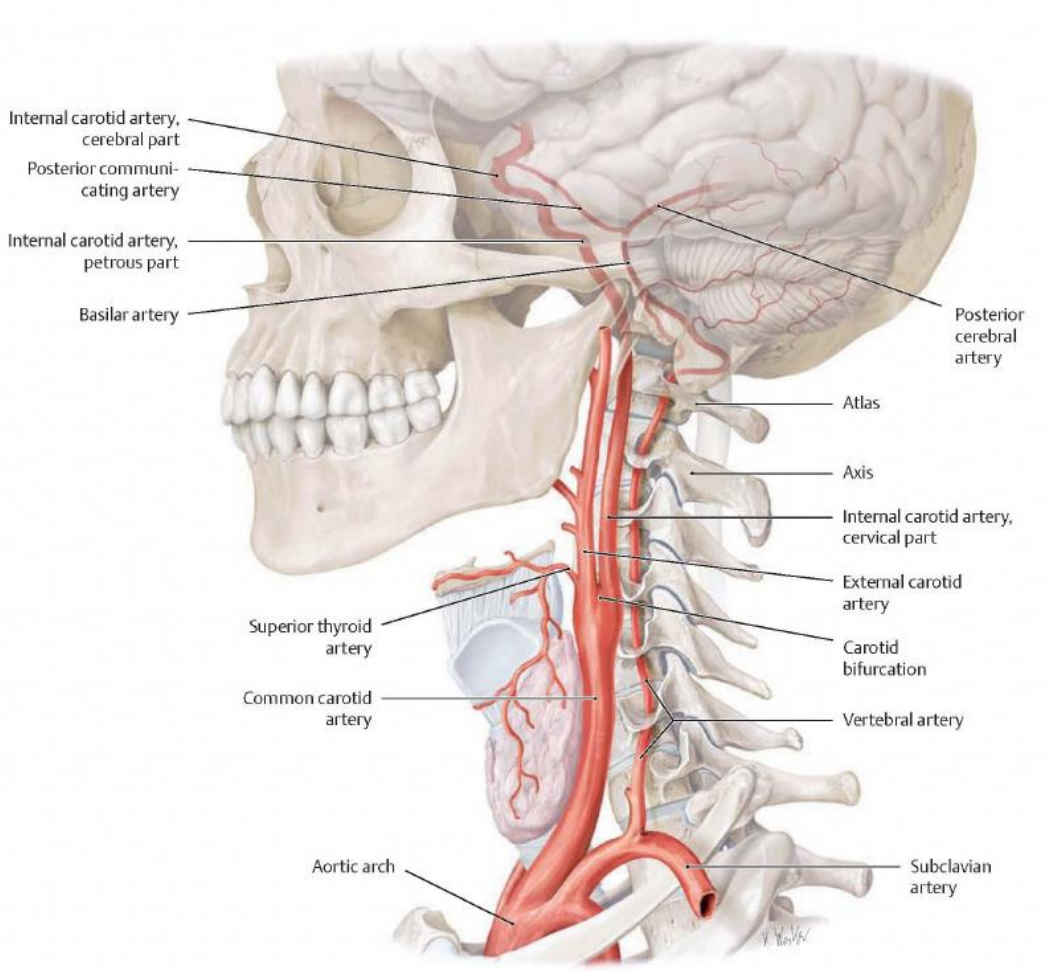

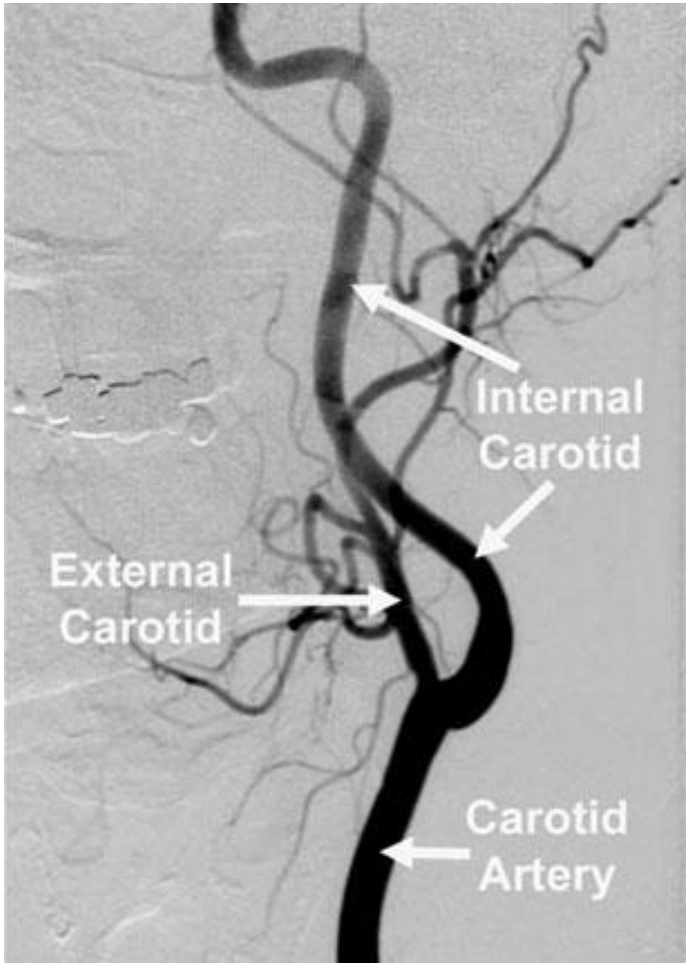

Overview of the arterial supply of the brain

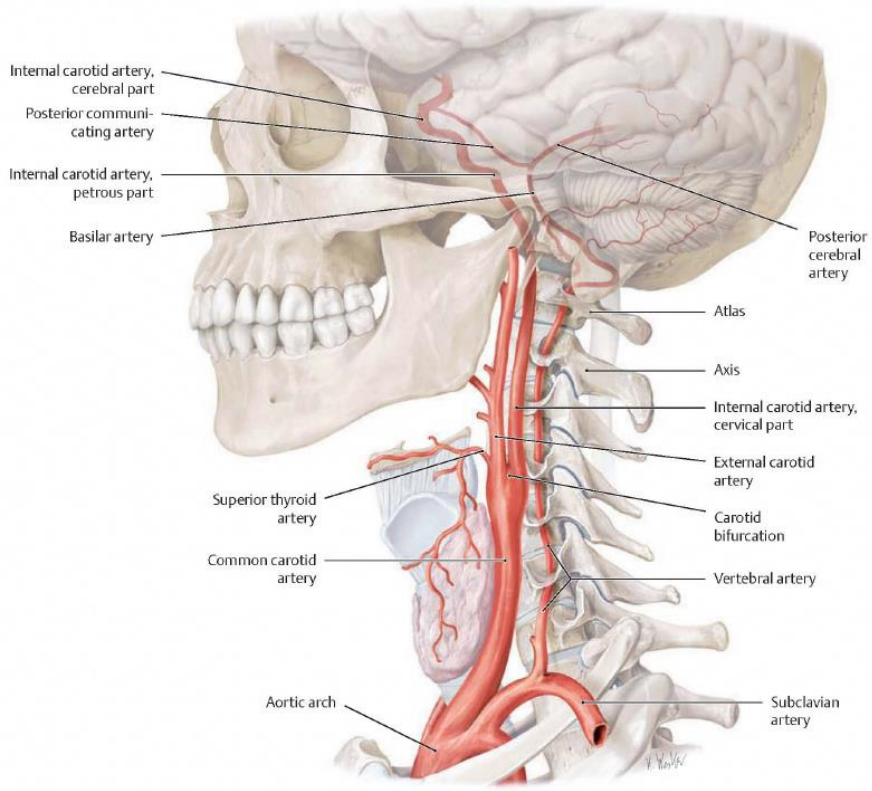

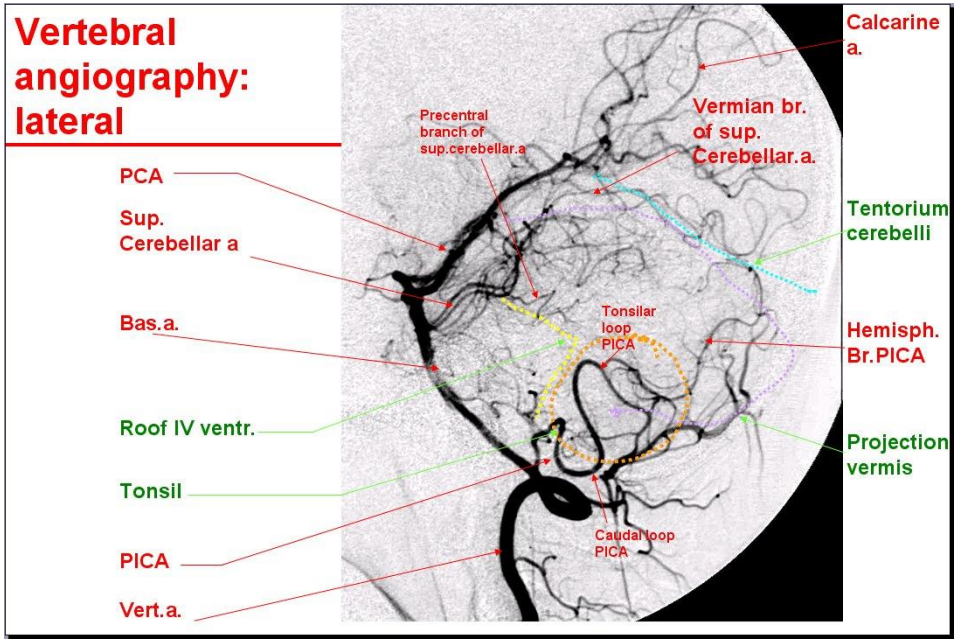

Internal carotid artery

Parts of the ICA:

Cervical

Petrous

Cavernous

Carotid siphon

Cerebral

Circle of Willis

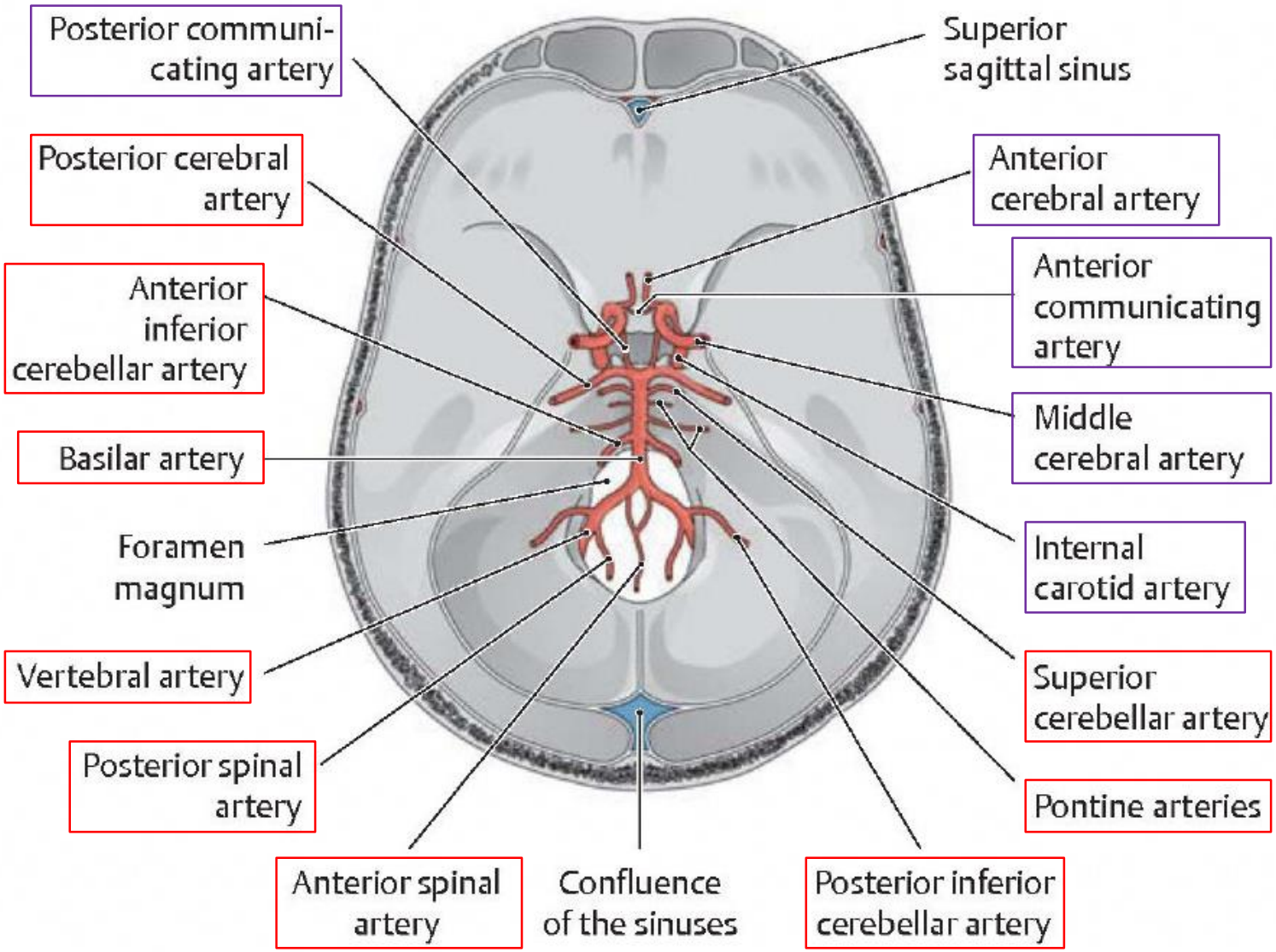

Variants of the circle of Willis (after Lippert and Pabst)

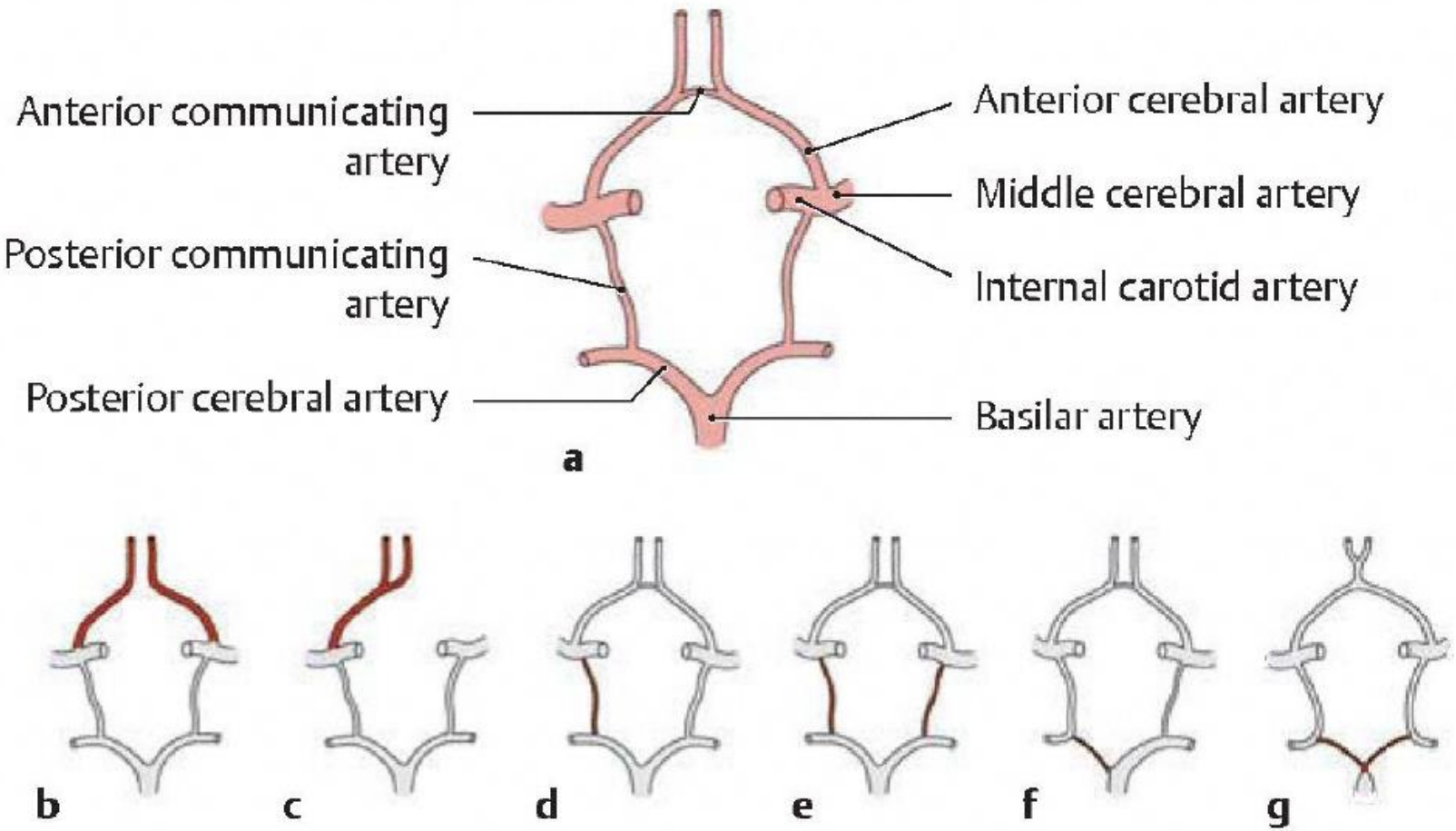

Stenoses and occlusions of arteries supplying the brain

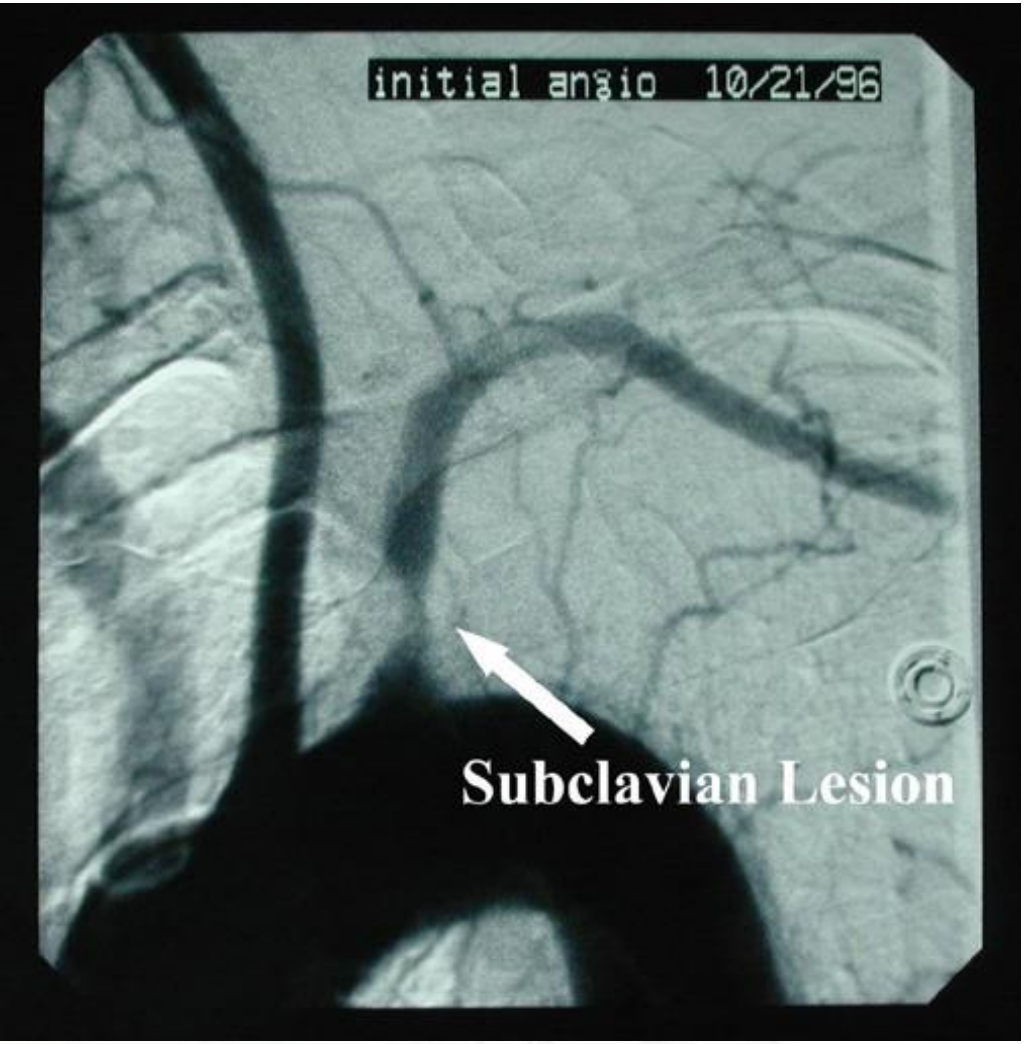

Subclavian steal syndrome (SSS)

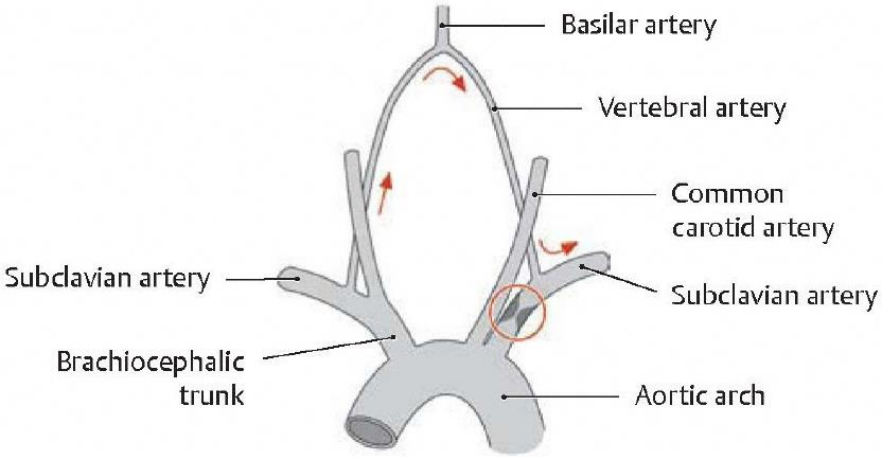

Classically, SSS is a consequence of a redundancy in the circulation of the brain and the flow of blood.

The blood flow from the brain to the upper limb in SSS is considered to be stolen as it is blood flow the brain must do without. This is because of collateral vessels.

Arteries of the cerebrum

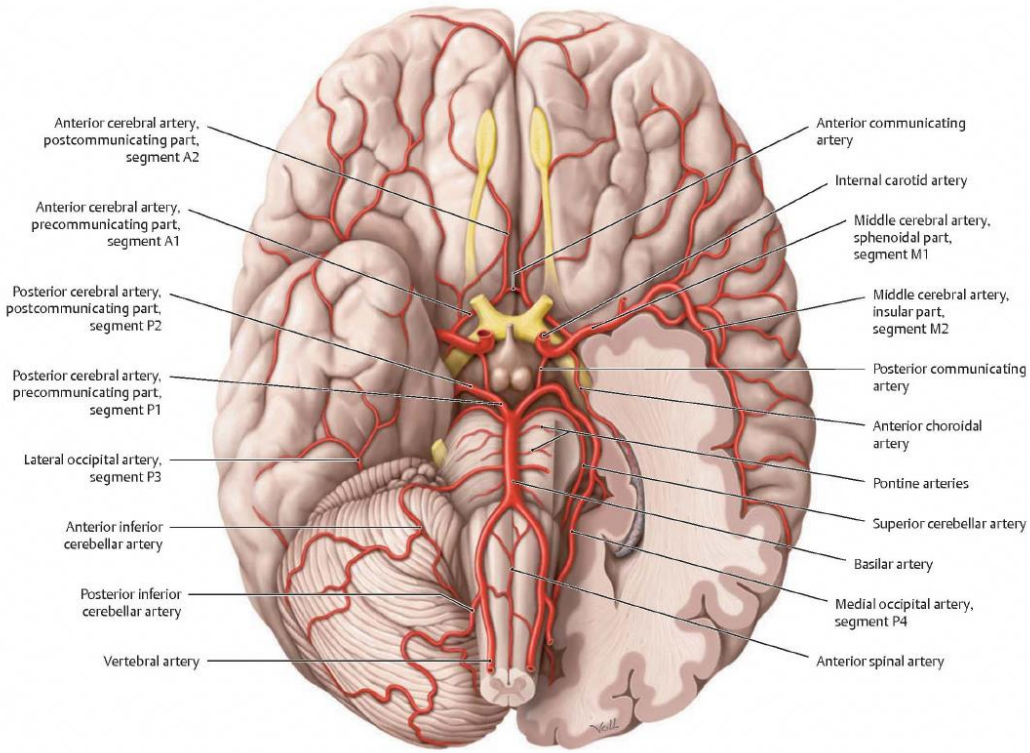

Artery	Parts	Segments
Anterior cerebral artery	• Precommunicating part • Postcommunicating part	• A1 = segment proximal to the anterior communicating artery • A2 = segment distal to the anterior communicating artery
Middle cerebral artery (MCA)	• Sphenoidal part • Insular part	• M1 = first horizontal segment of the artery (horizontal part) • M2 = segment on the insula
Posterior cerebral artery	• Precommunicating part • Postcommunicating part	• P1 = segment between the basilar artery bifurcation and posterior communicating artery • P2 = segment between the posterior communicating artery and anterior temporal branches • P3 = lateral occipital artery • P4 = medial occipital artery

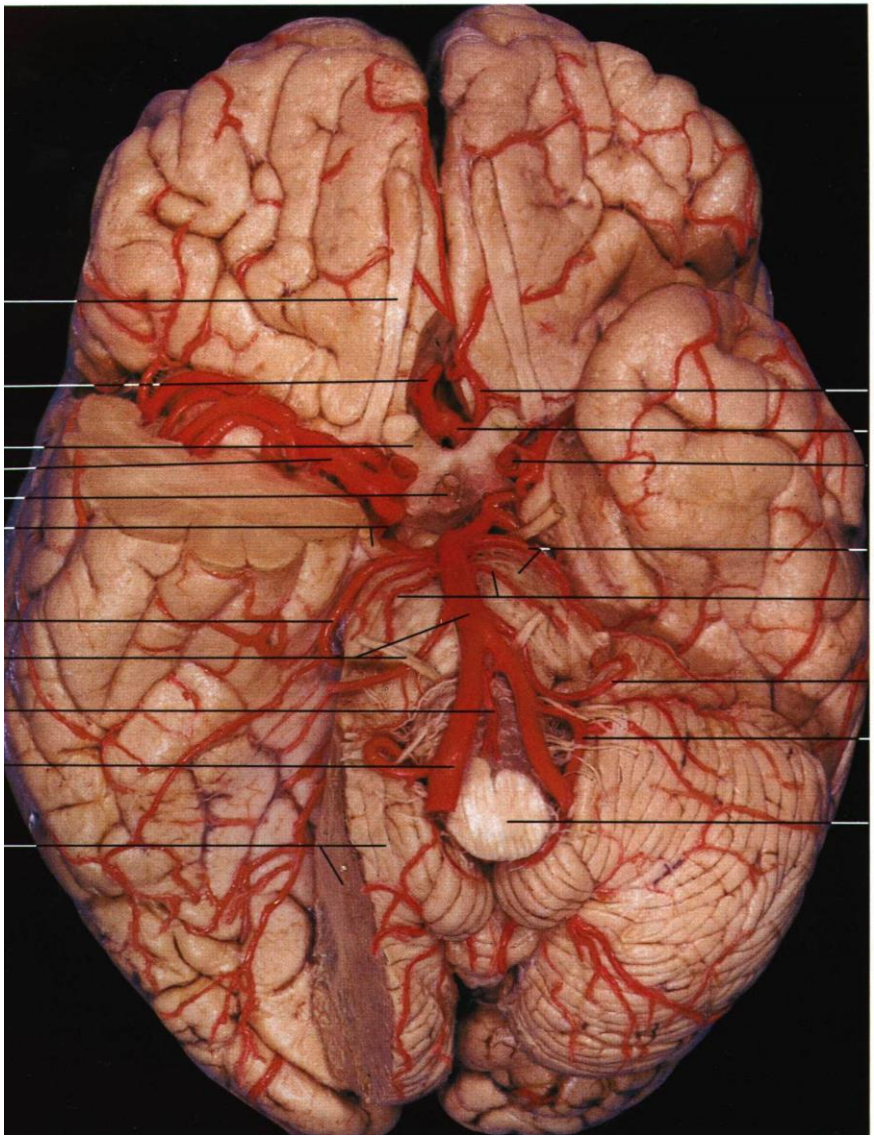

Middle cerebral artery

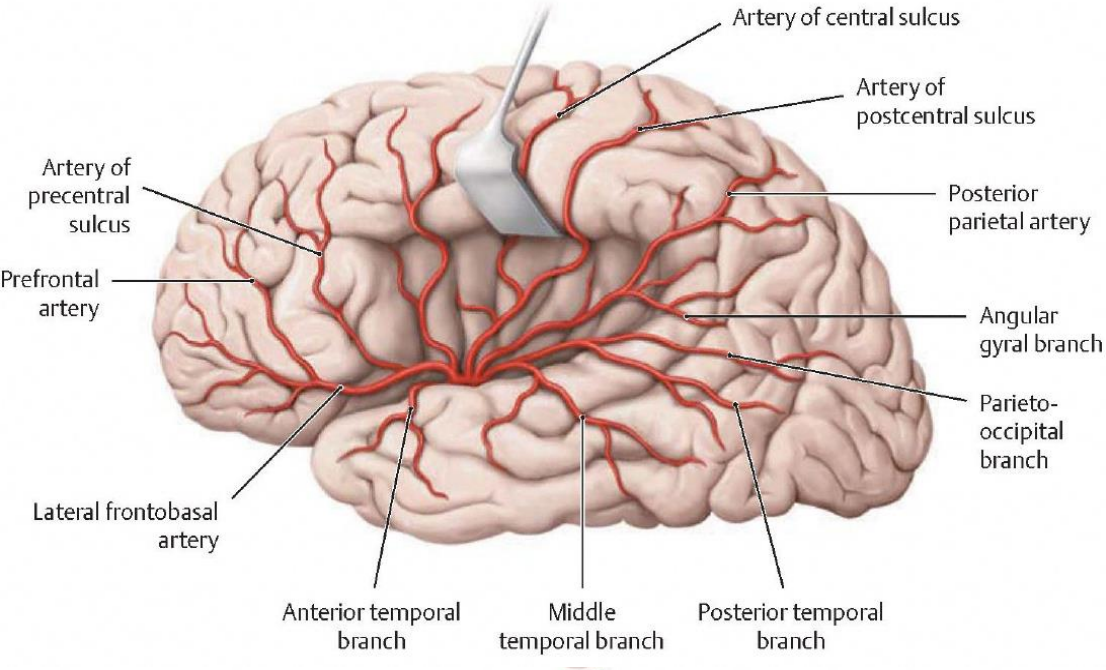

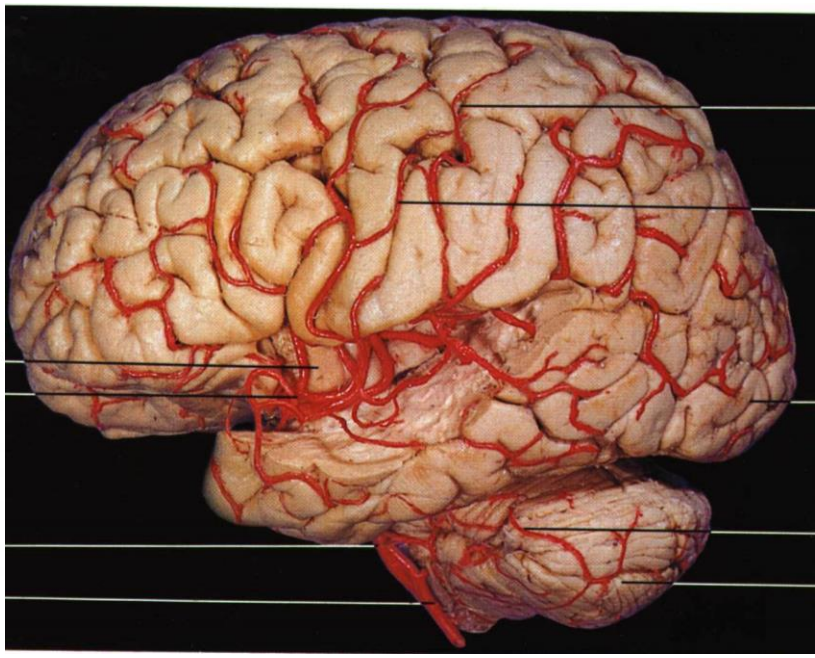

Anterior and posterior cerebral artery

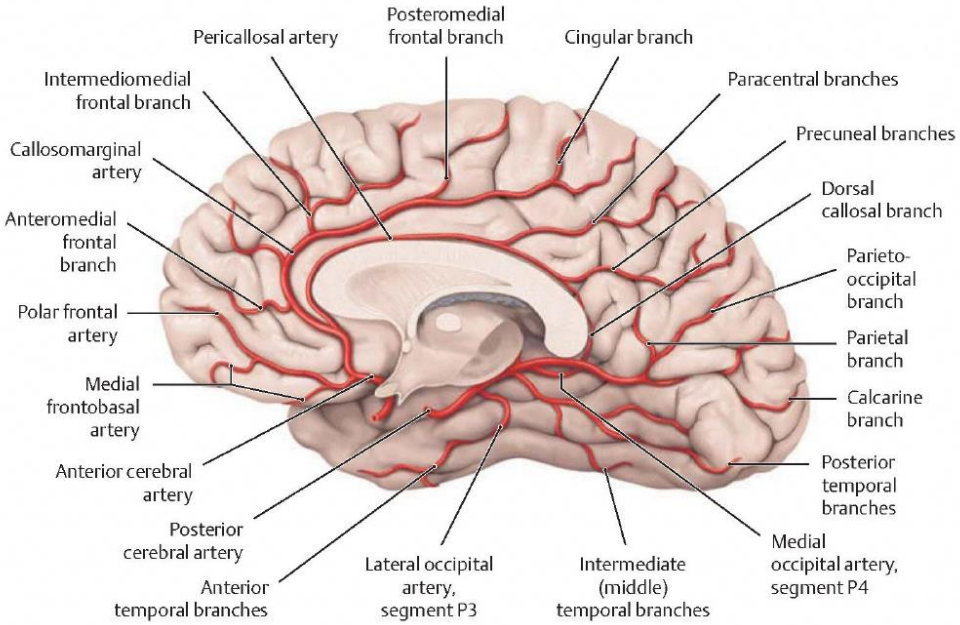

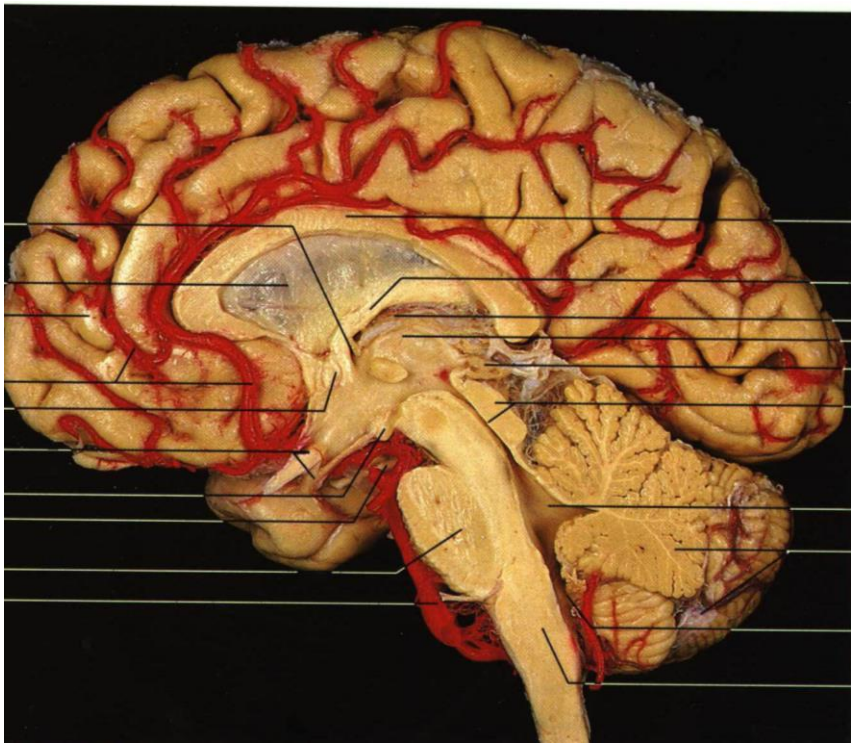

Distribution areas of the main cerebral arteries

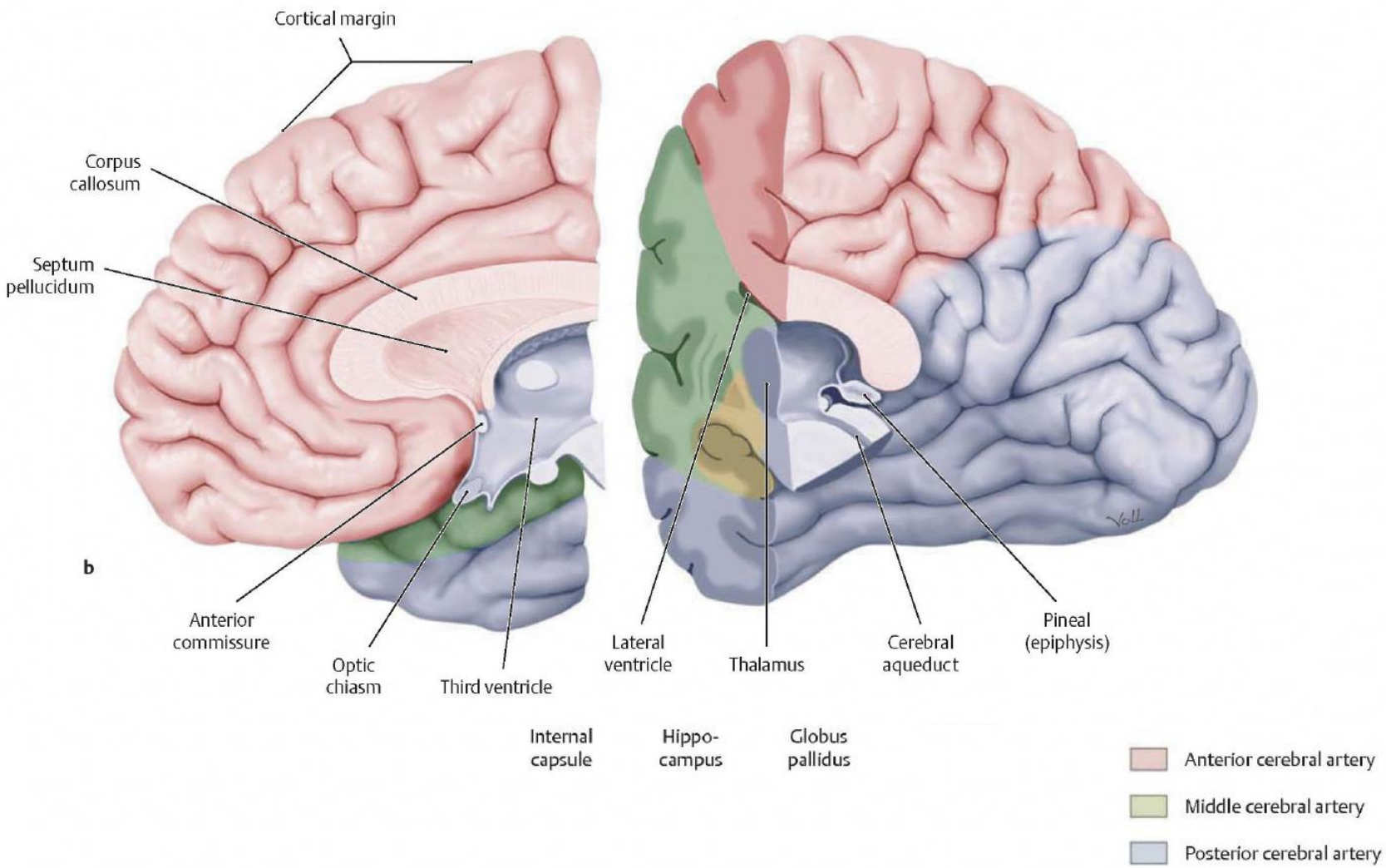

Distribution of the main cerebral arteries

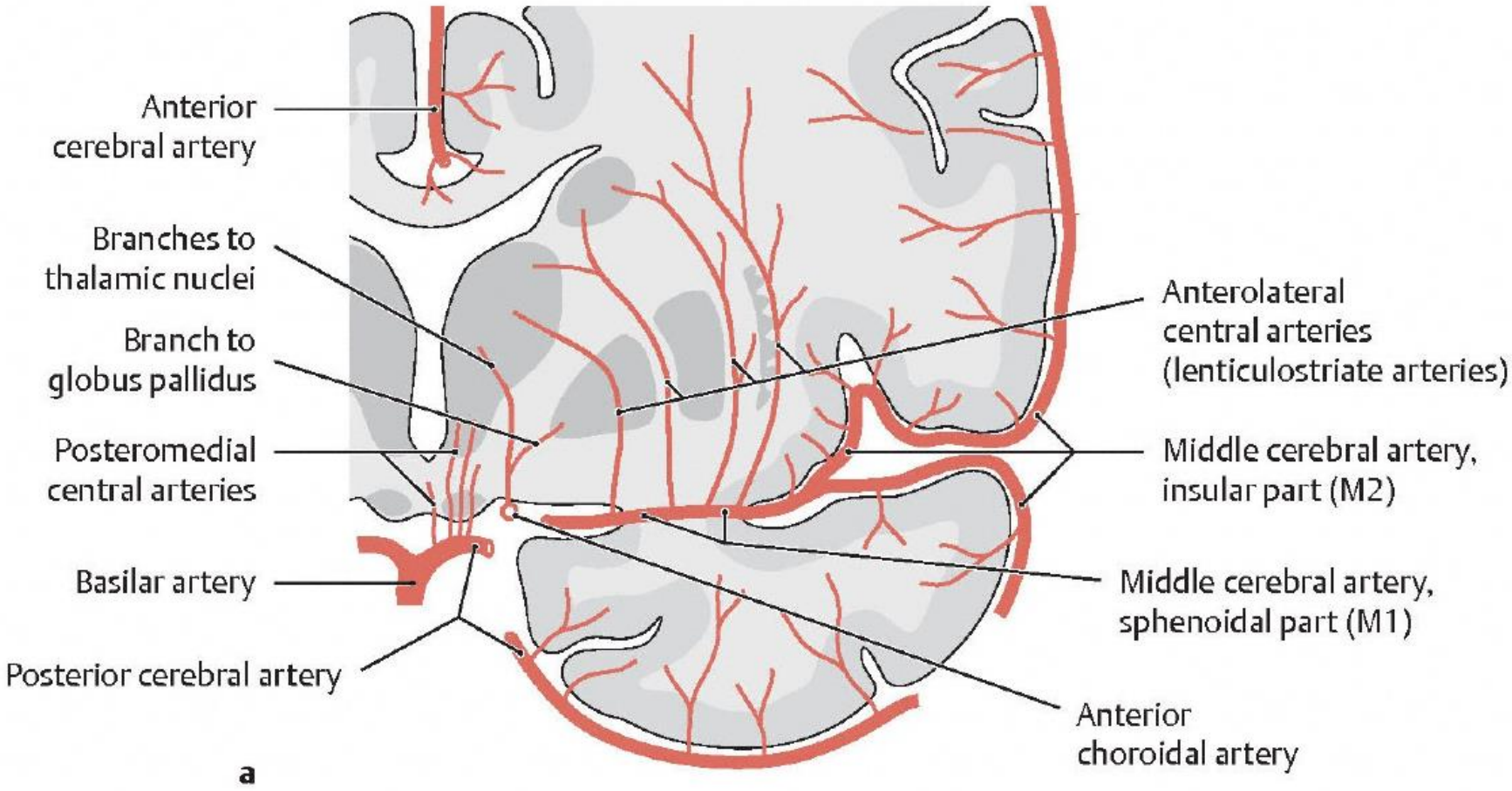

Distribution of the main cerebral arteries, functional centers

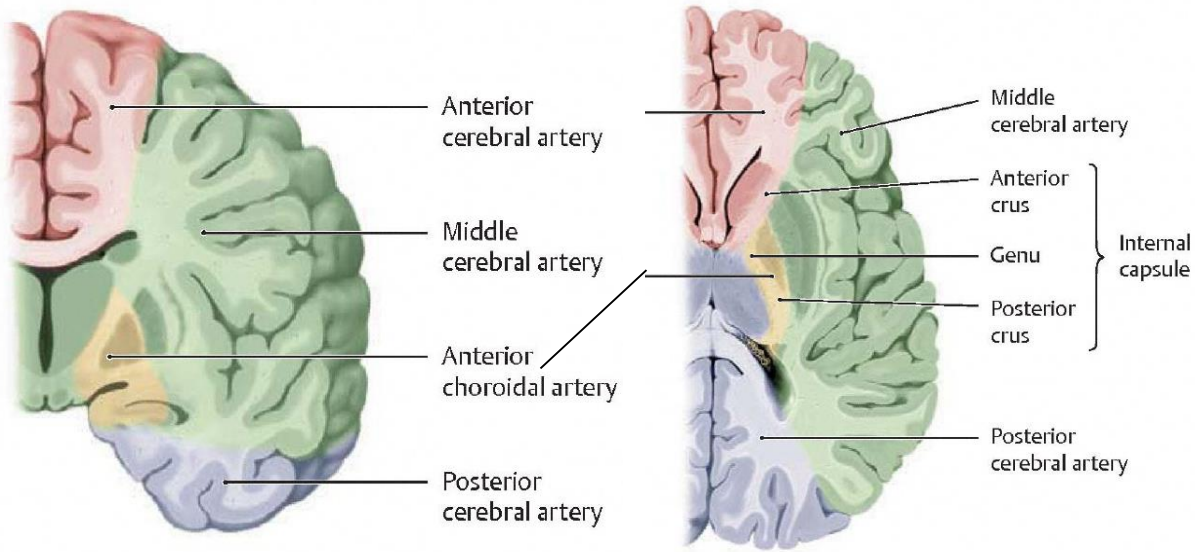

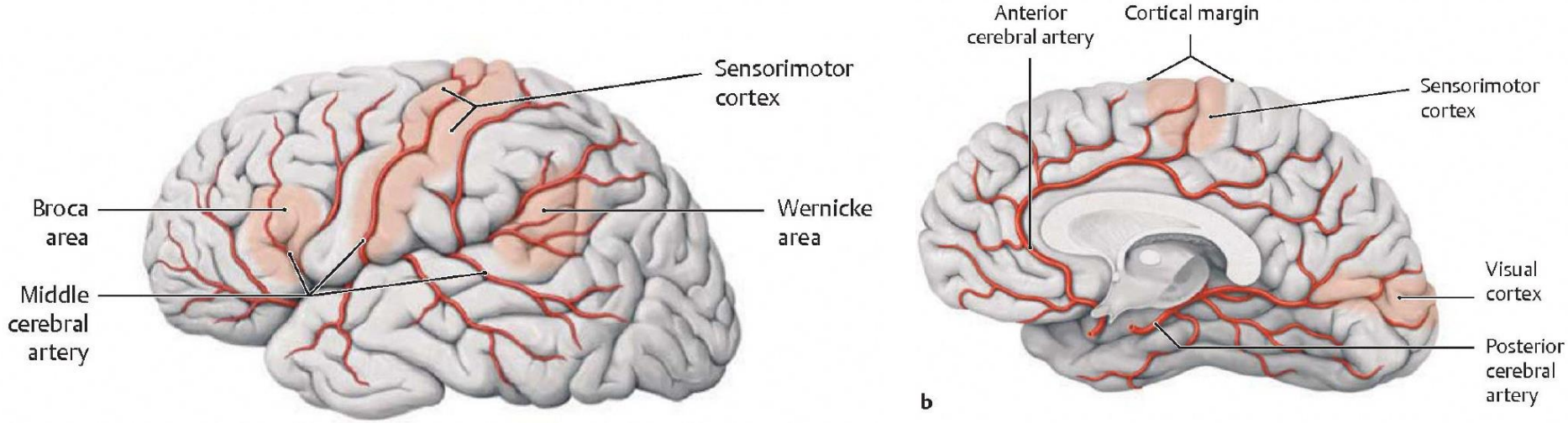

Arteries of the brainstem and cerebellum

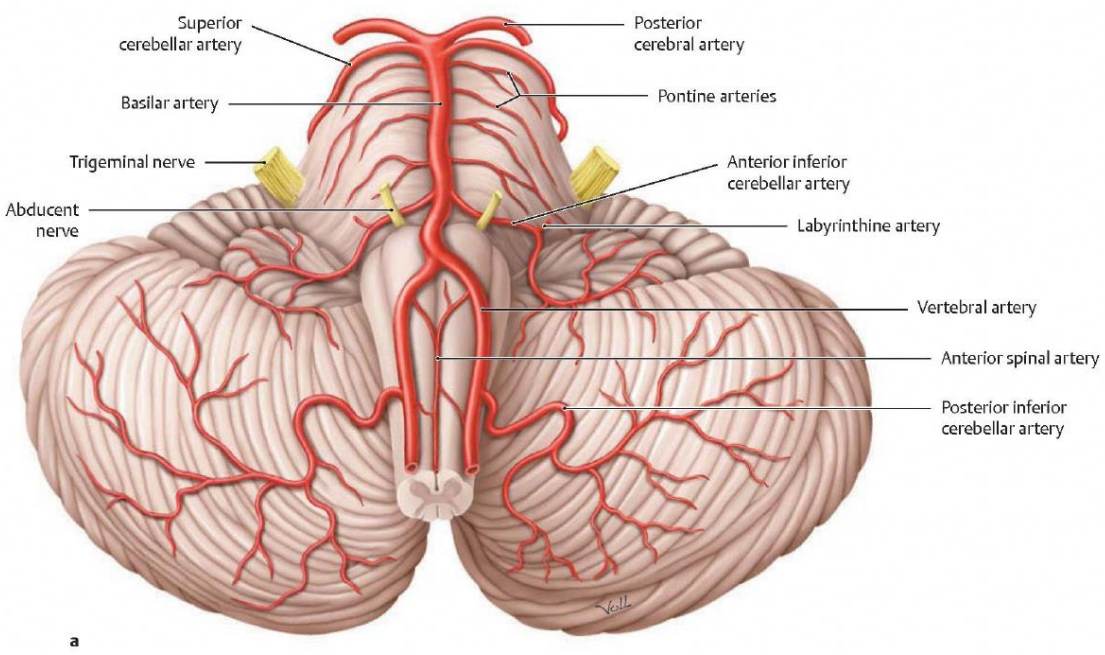

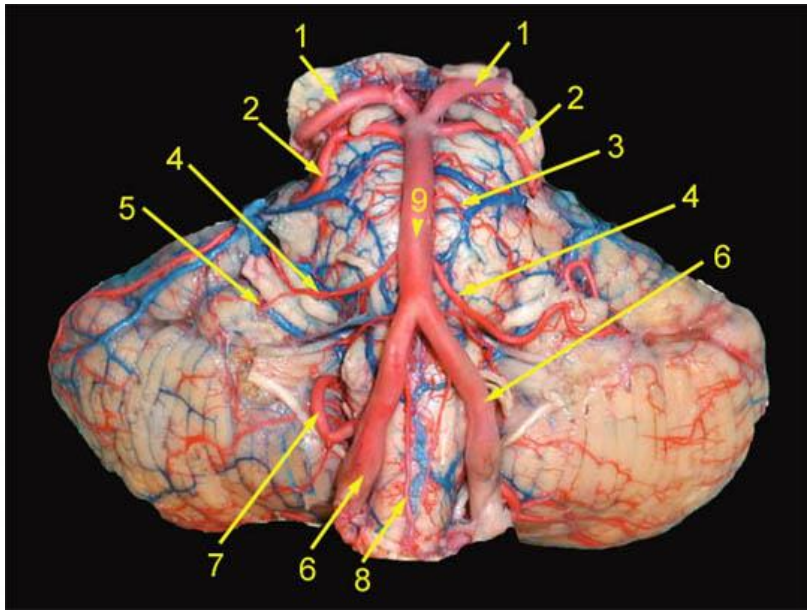

Arteries of the brainstem and cerebellum, distributions

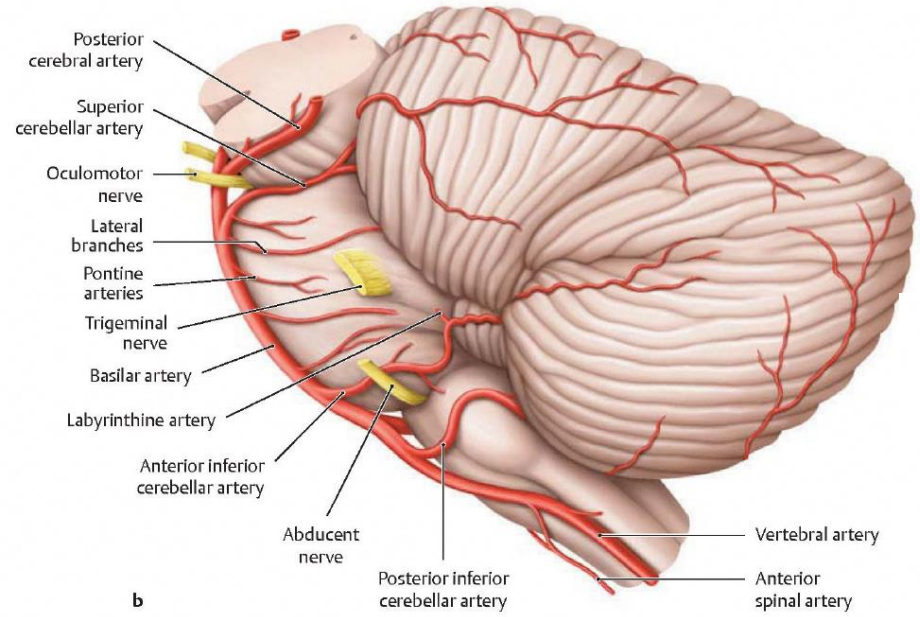

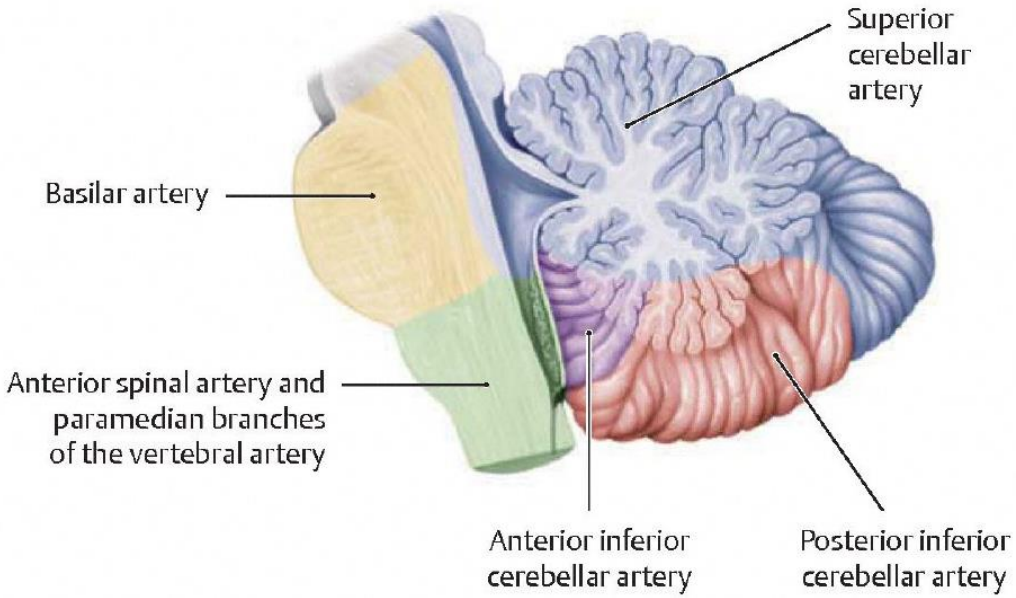

Arteries of the brainstem and cerebellum, distributions

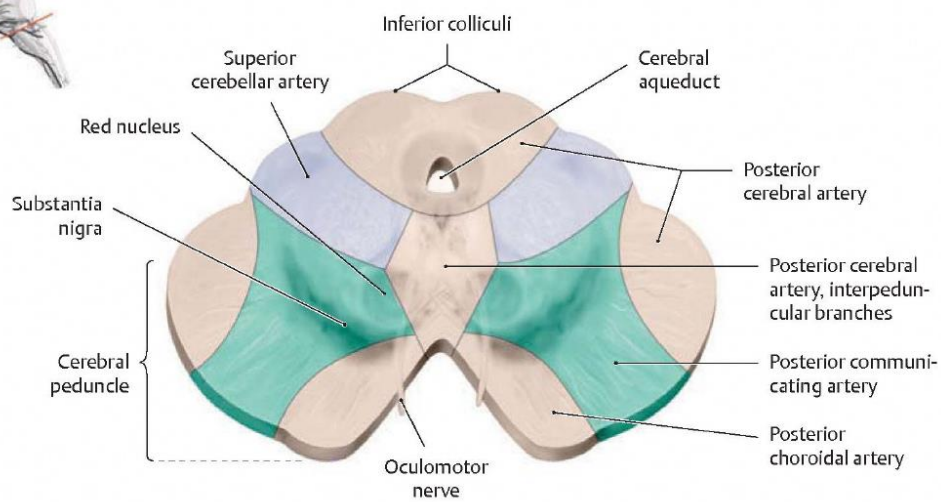

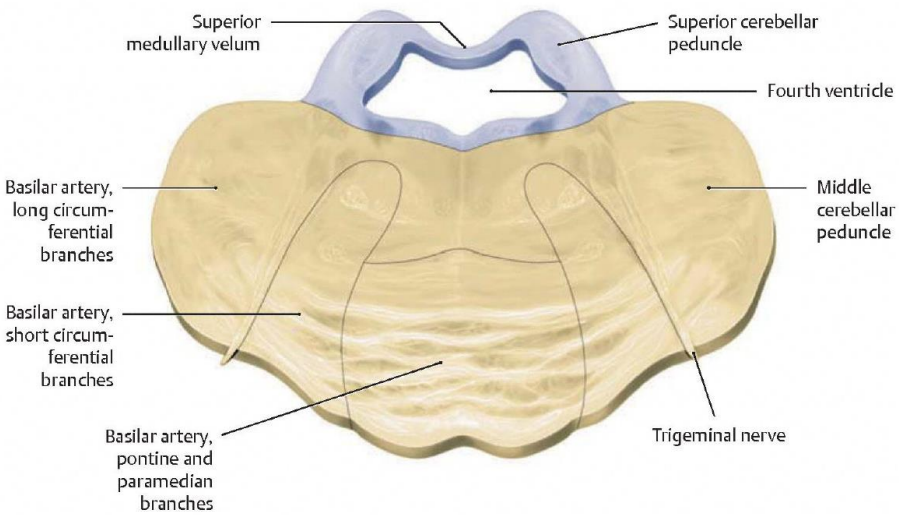

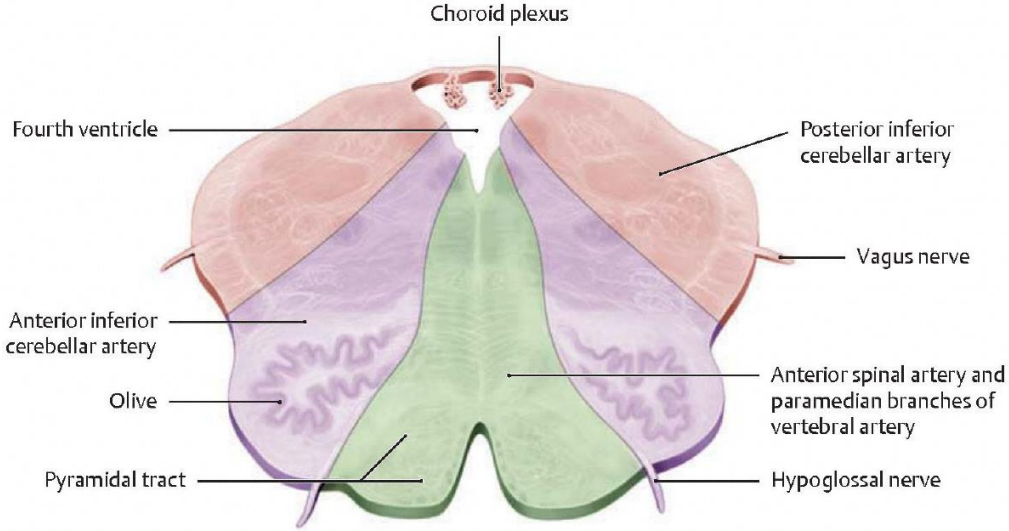

Venous drainage of the brain

Relationship of the pricipal dural sinuses to the skull

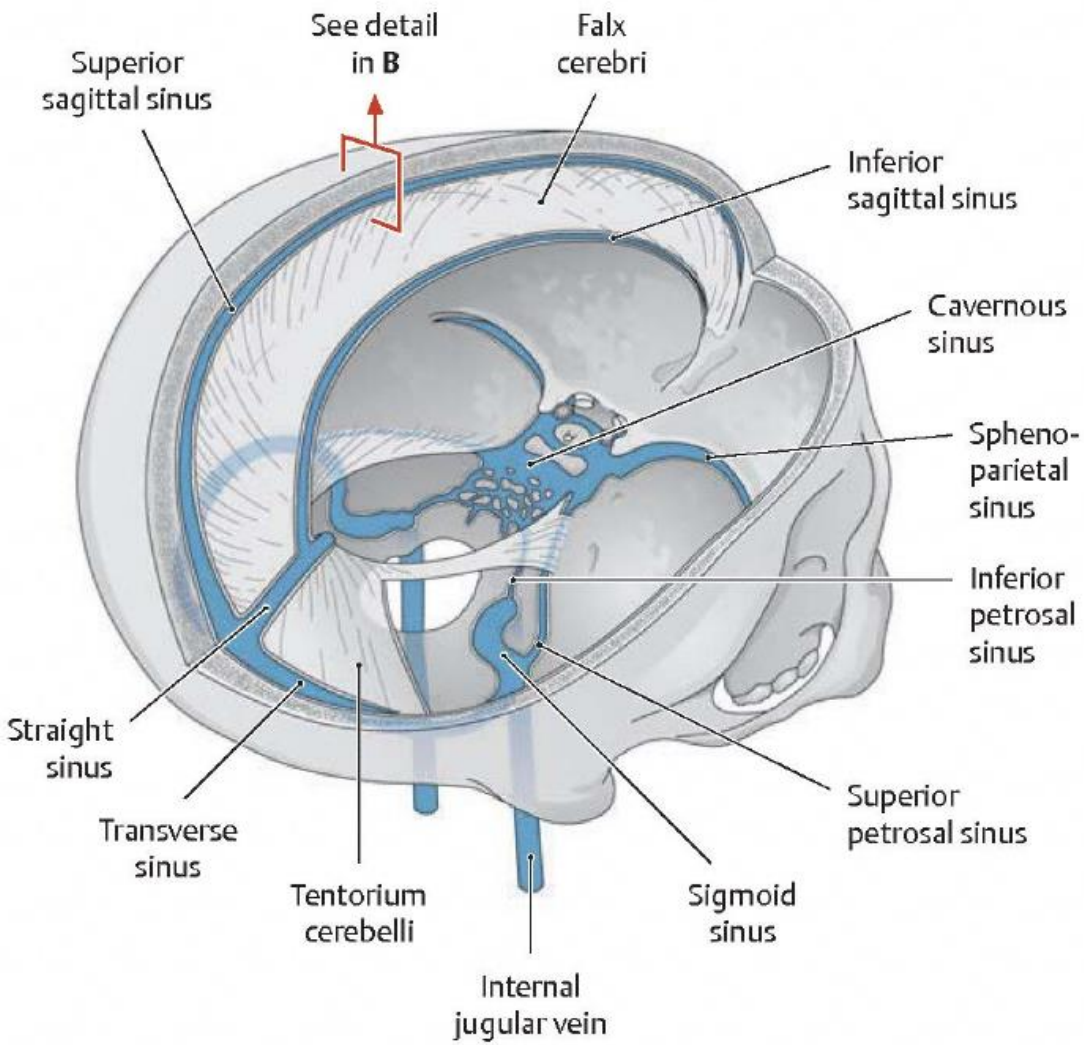

Stucture of the dural sinus

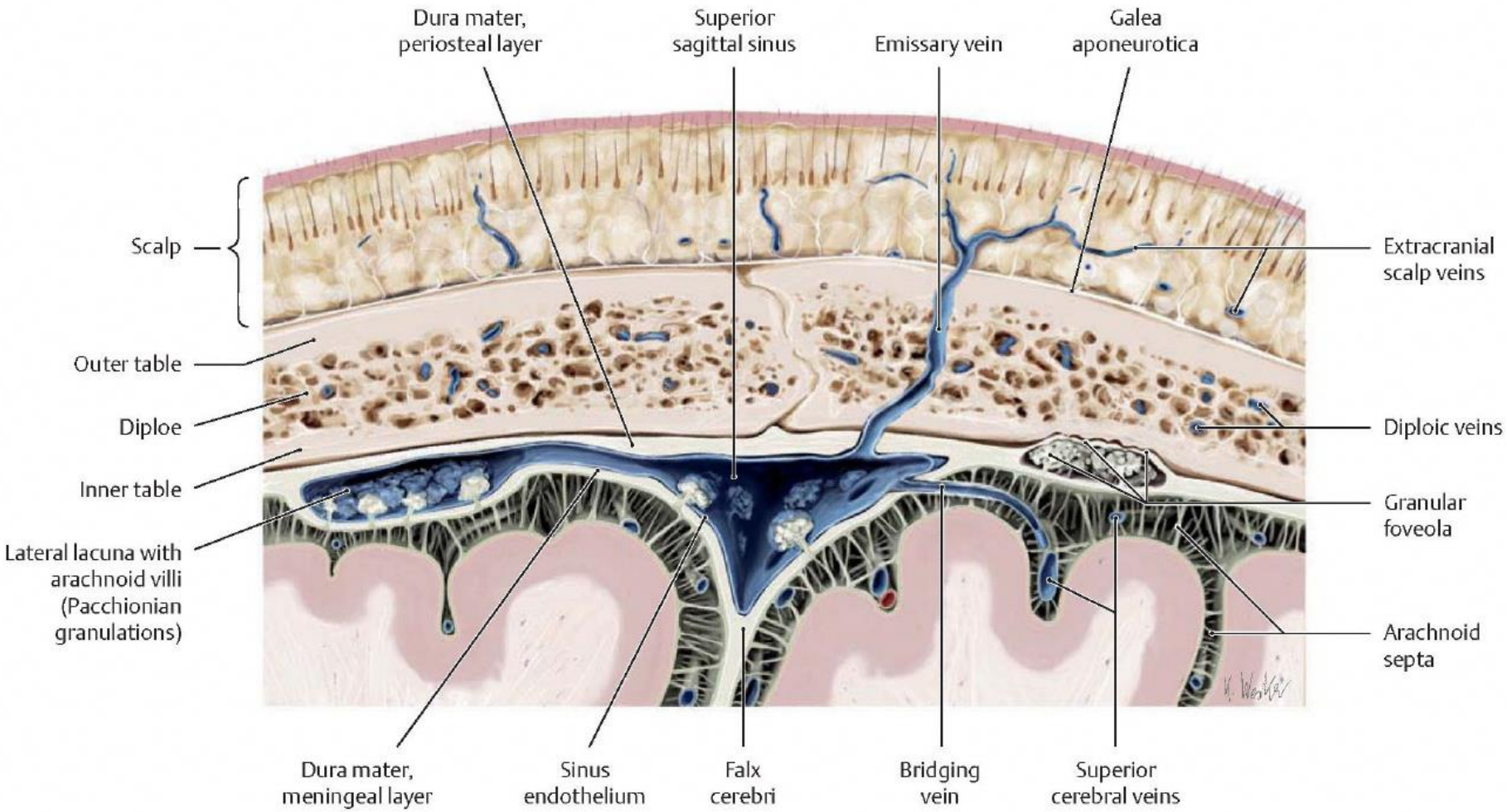

Dural sinuses at the skull base

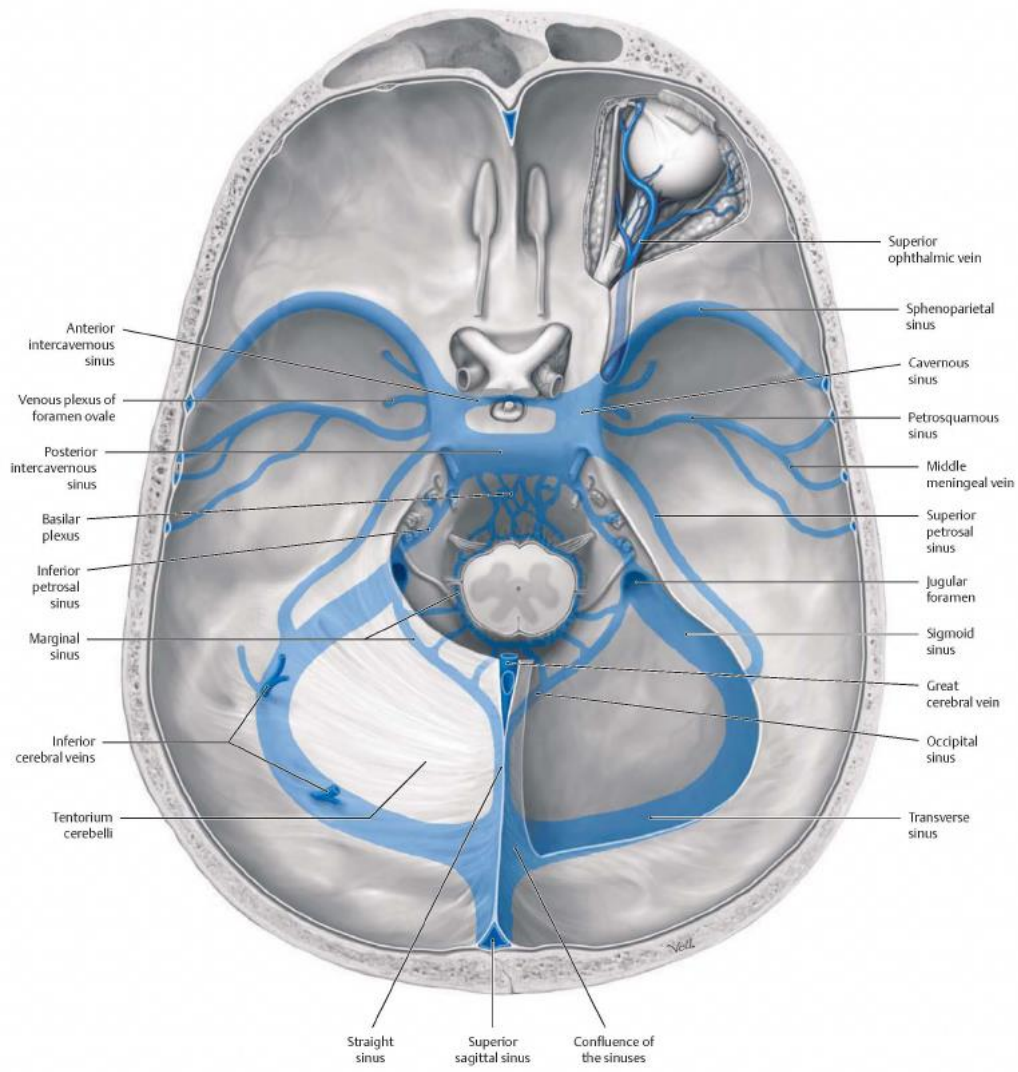

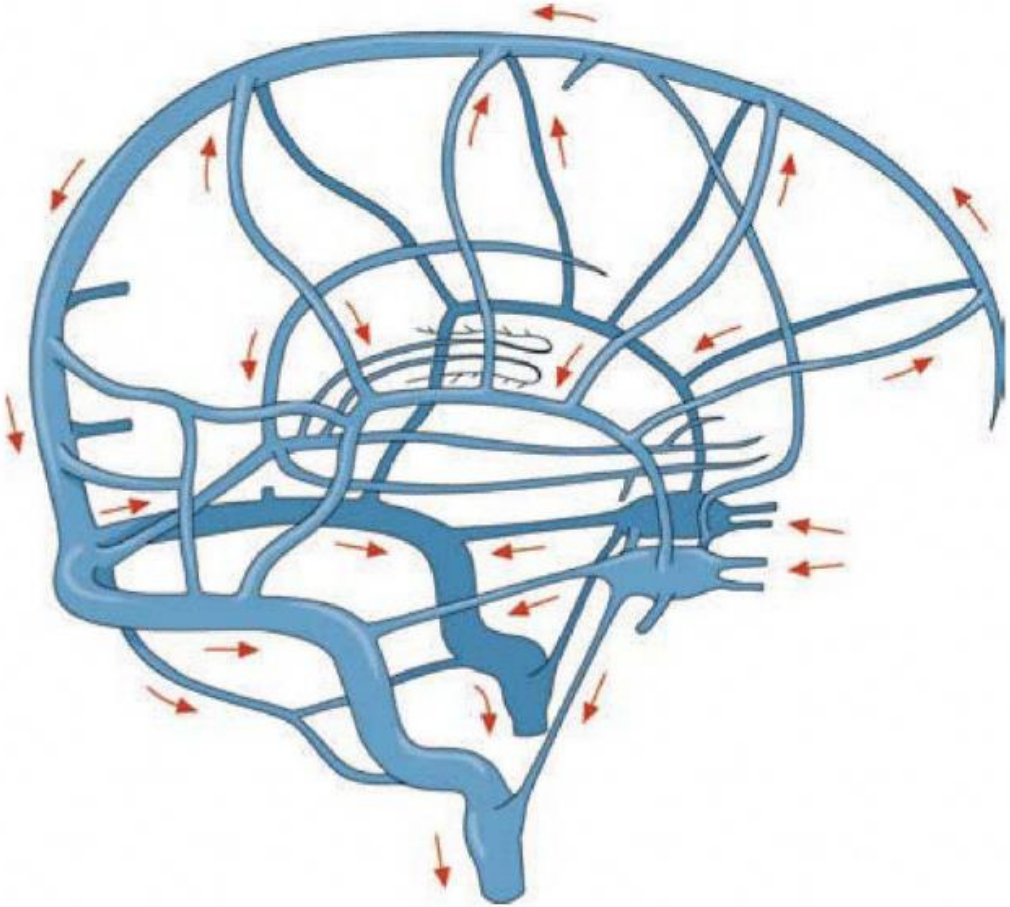

Accessory drainage pathways of the sinuses

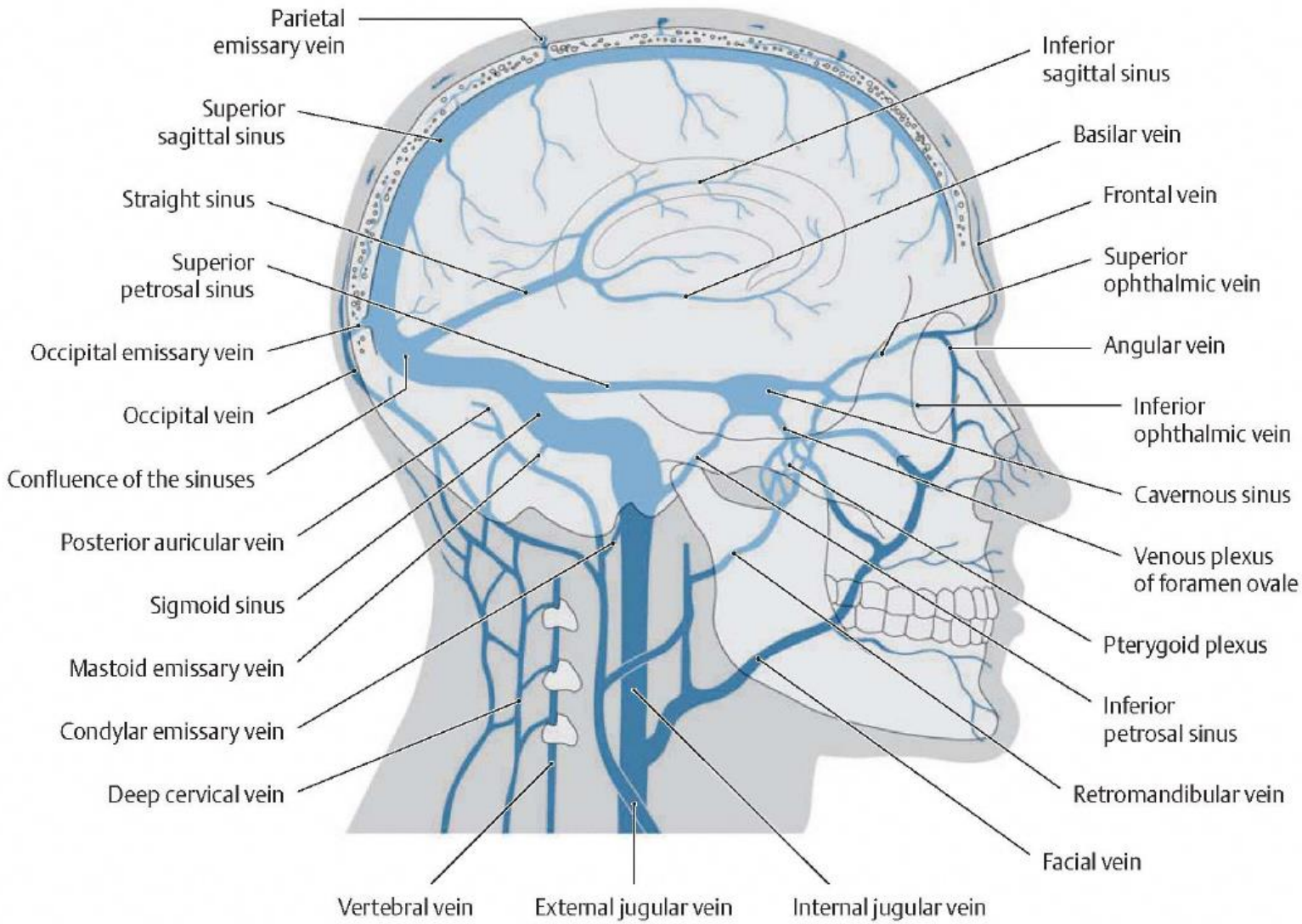

Occipital emissary sinus

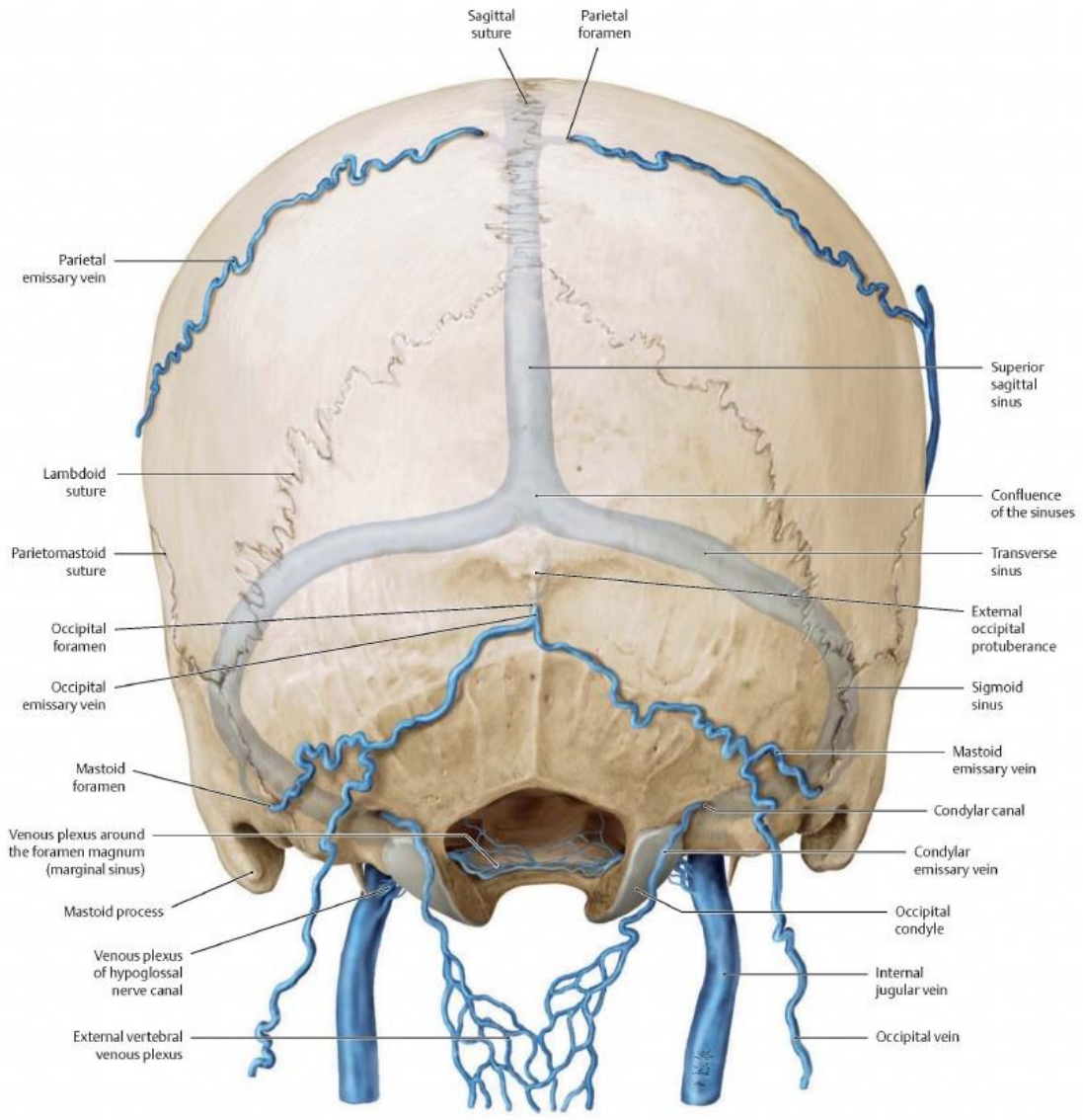

Superficial and basal veins of the brain

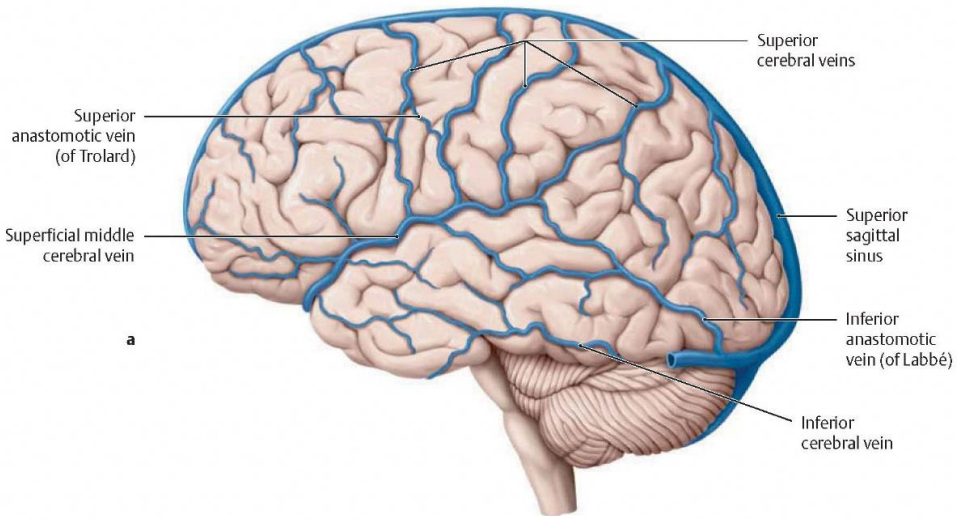

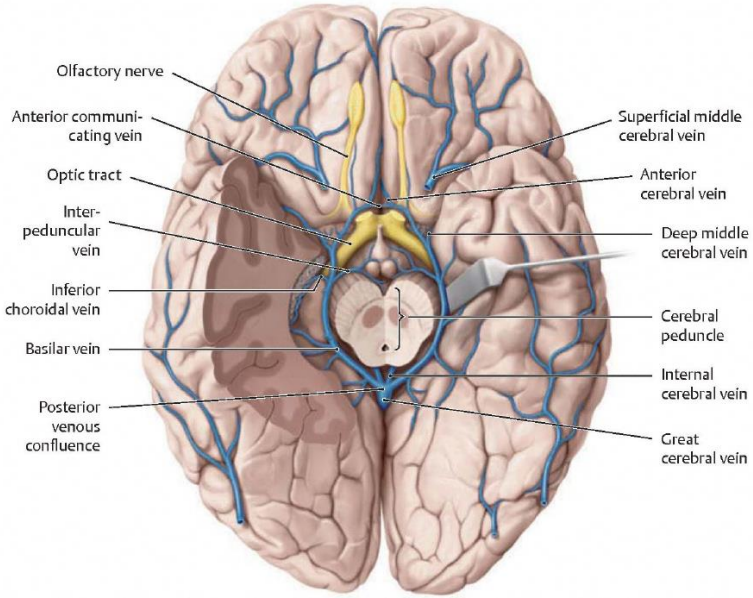

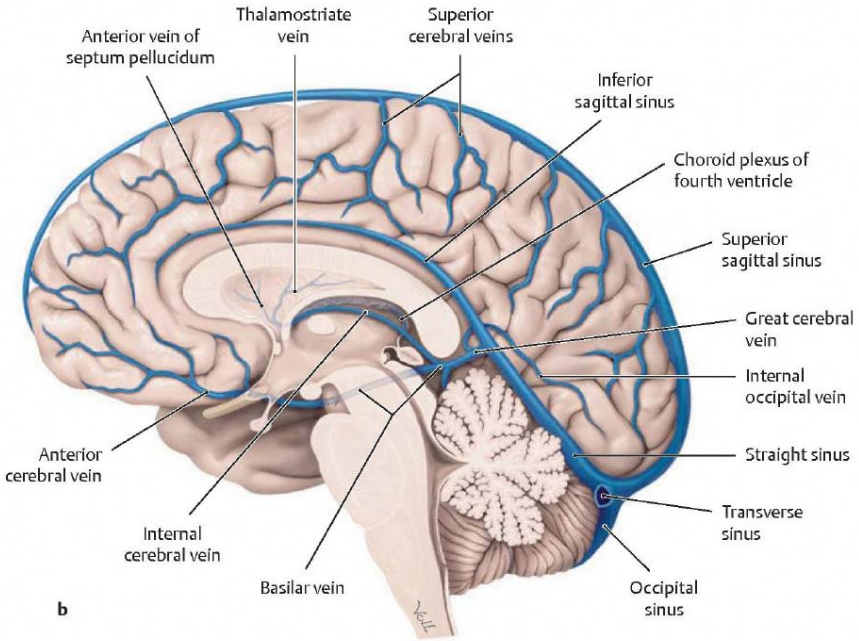

Regoins drained by the sup. cer. veins

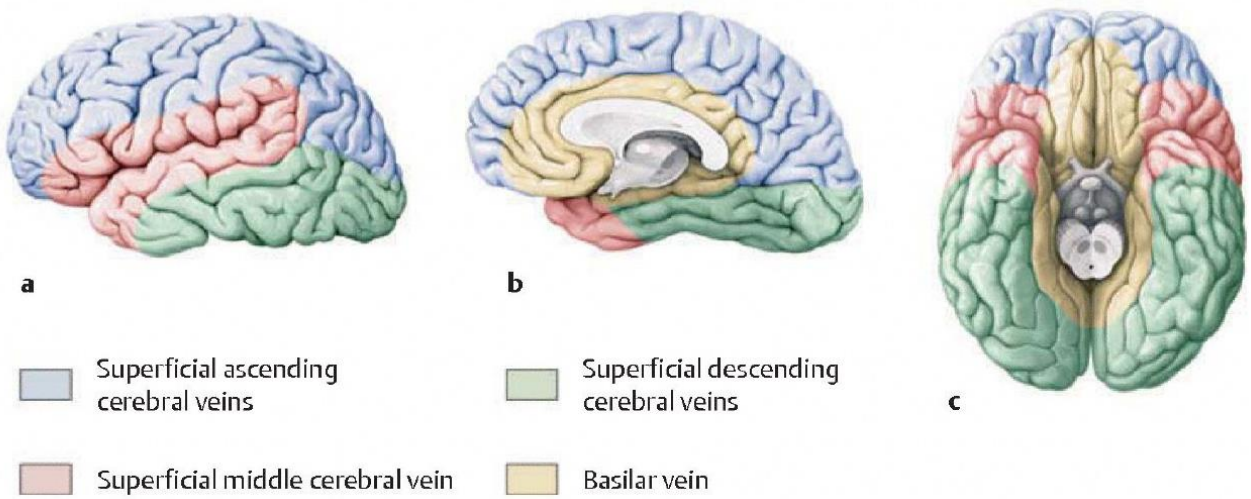

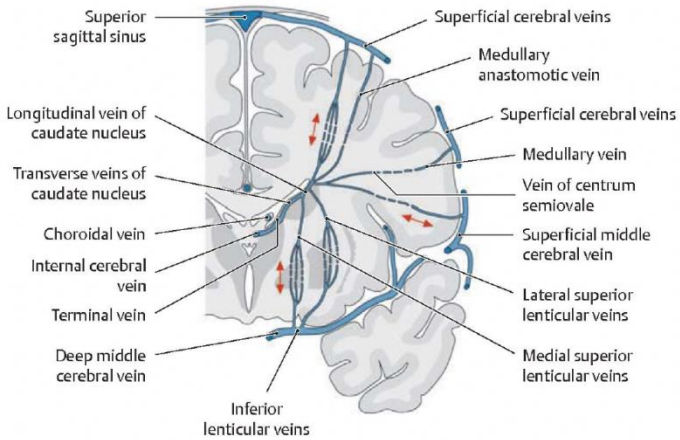

D Anastomoses between the superficial and deep cerebral veins

Deep cerebral veins

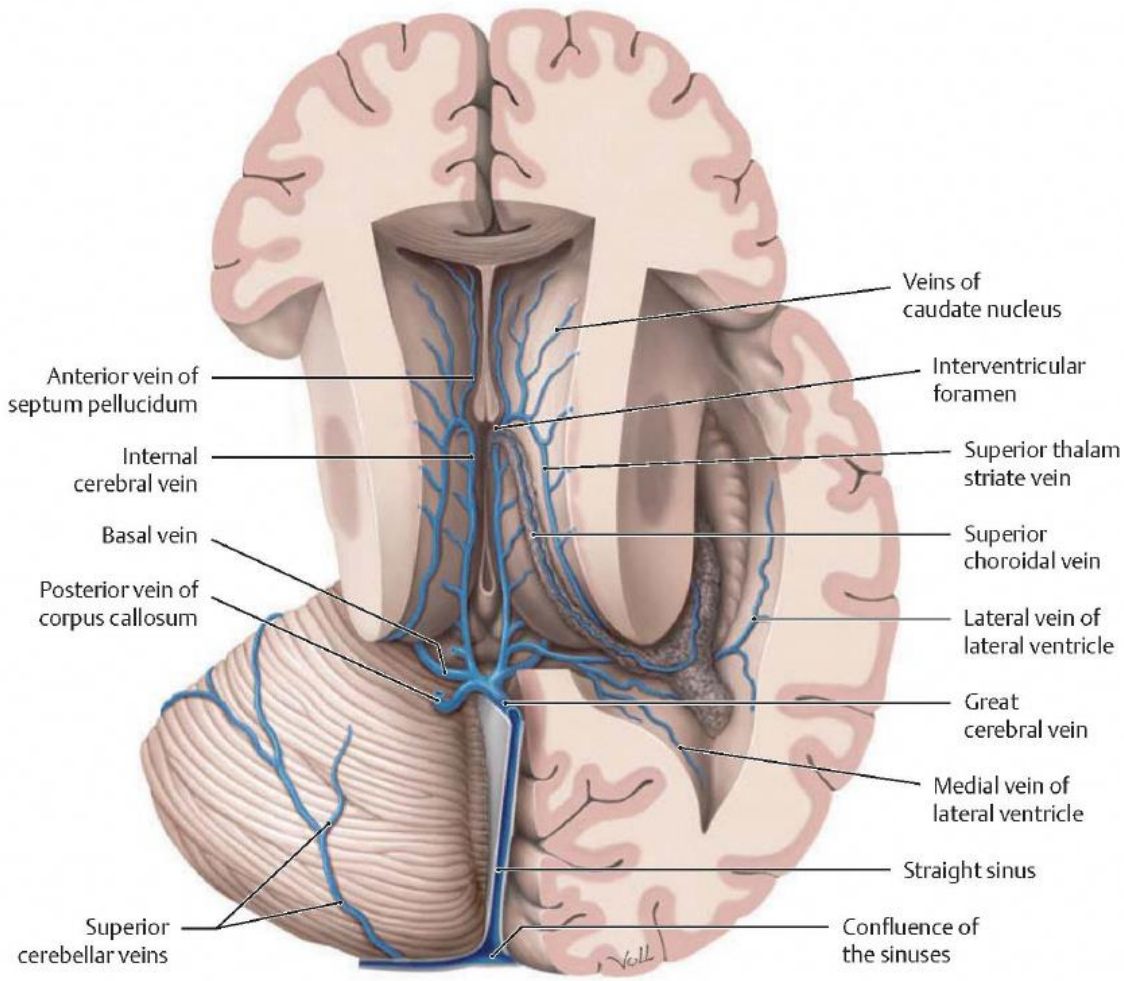

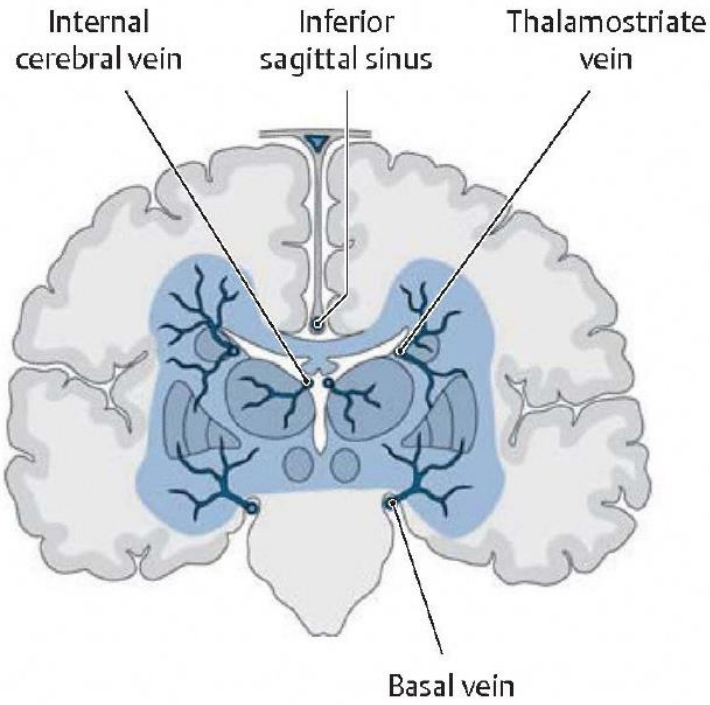

Cerebellar veins

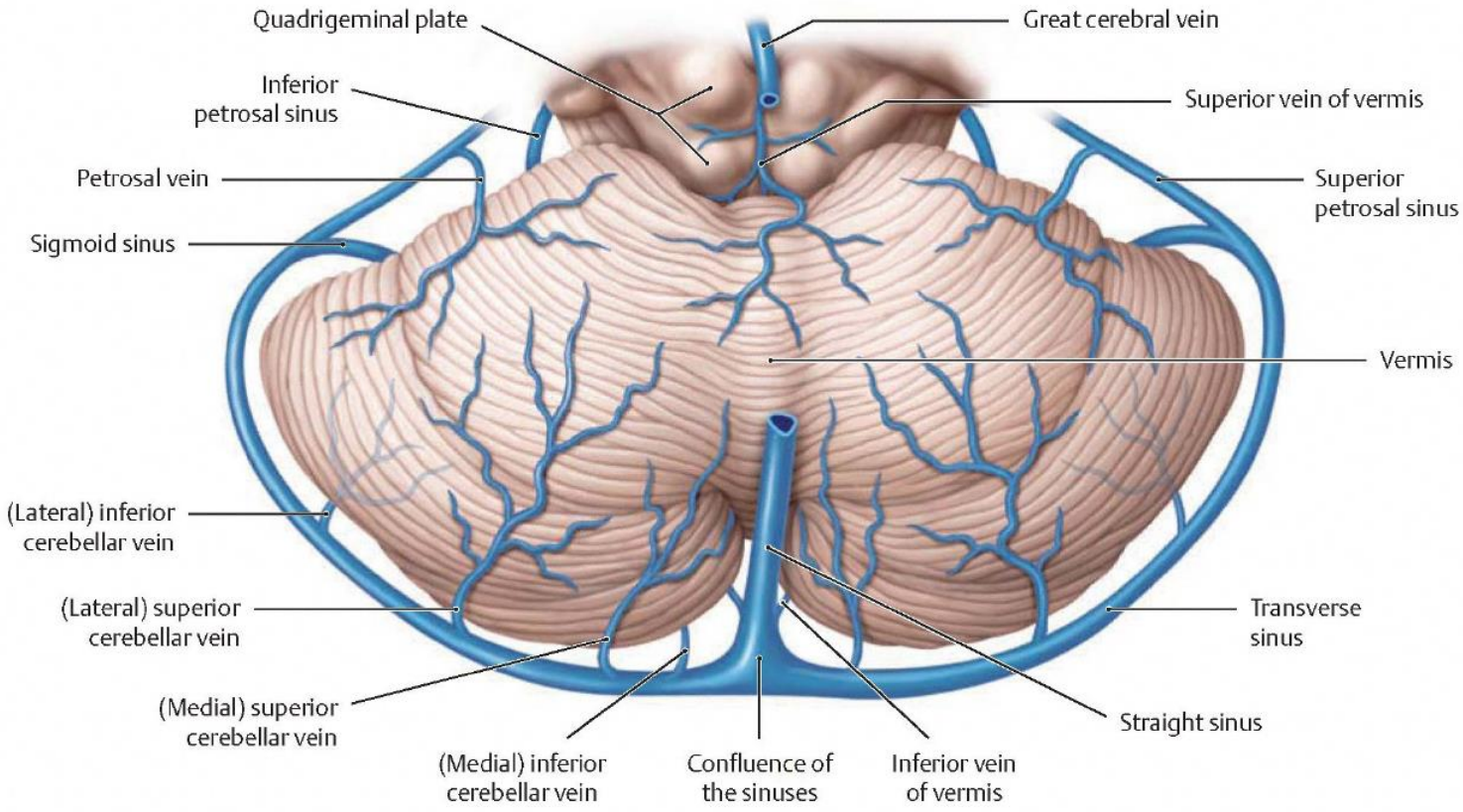

Veins of the brainstem

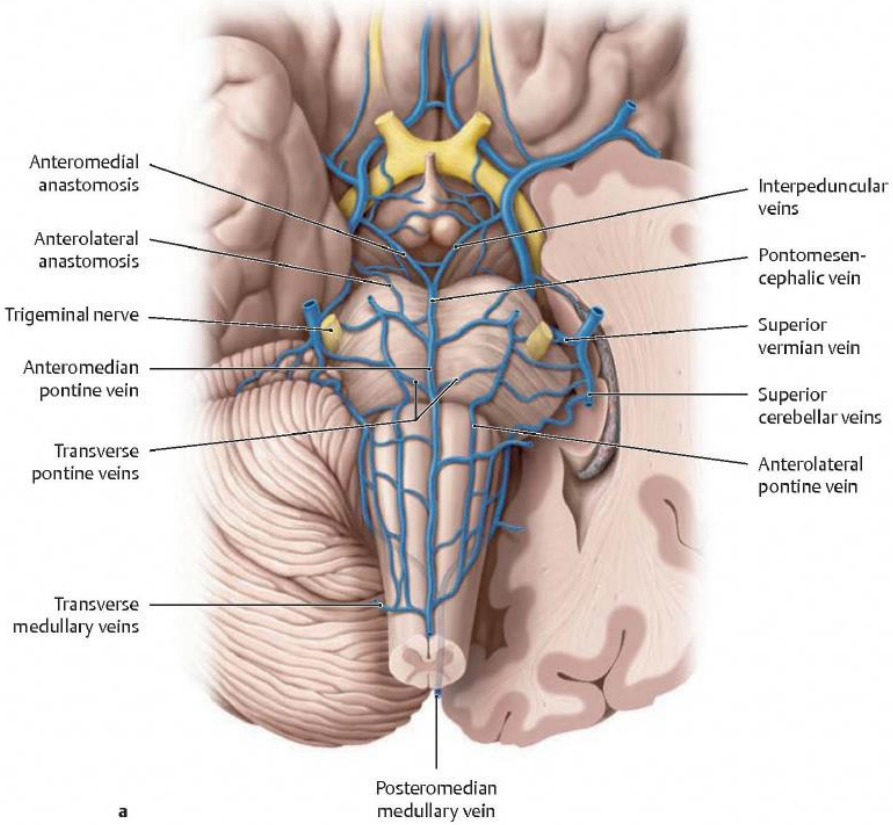

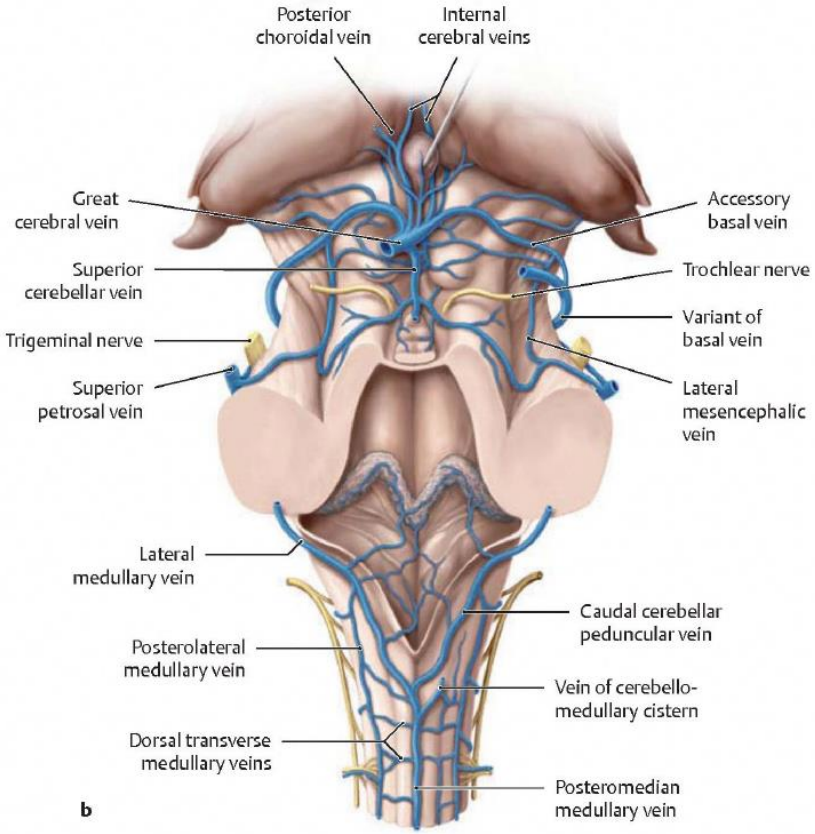

Extracerebral hemorrhages

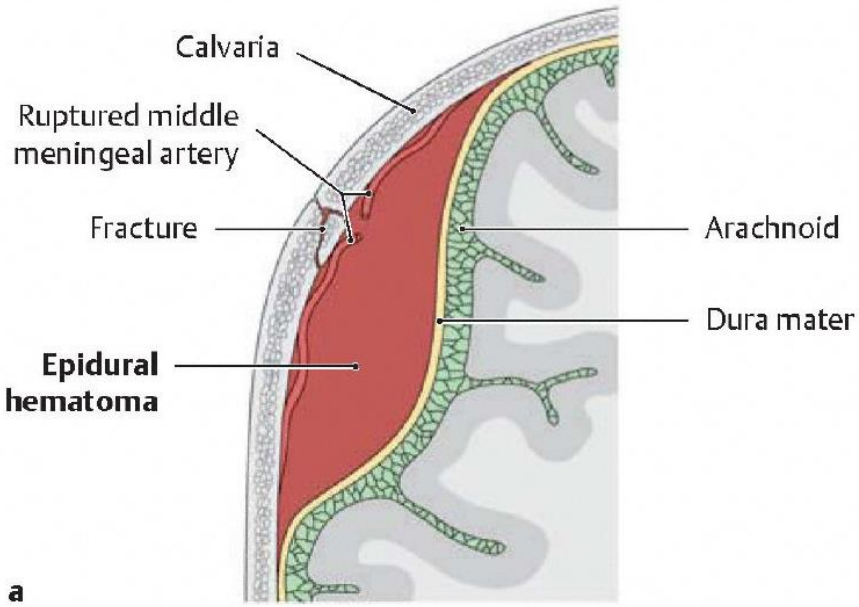

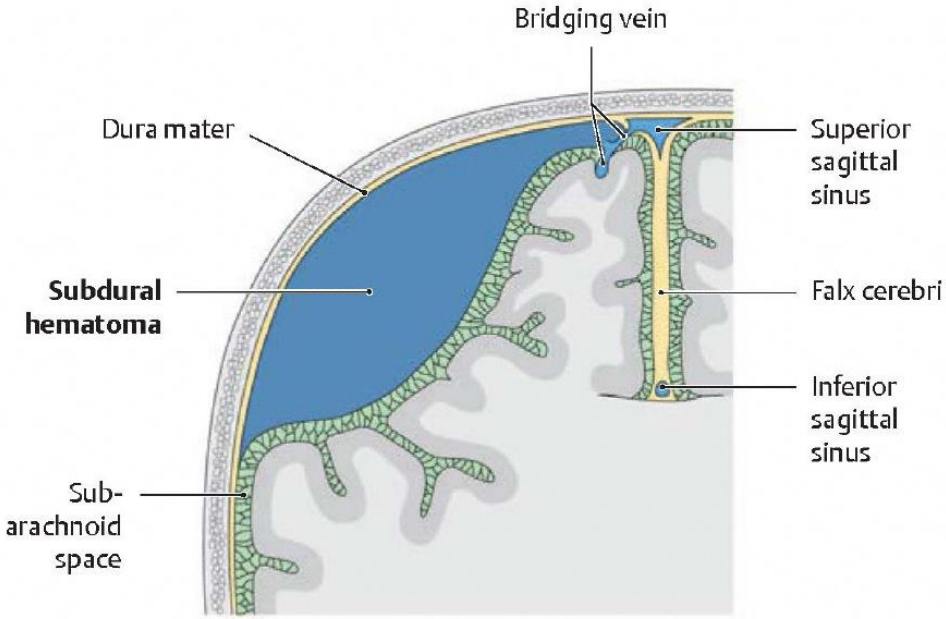

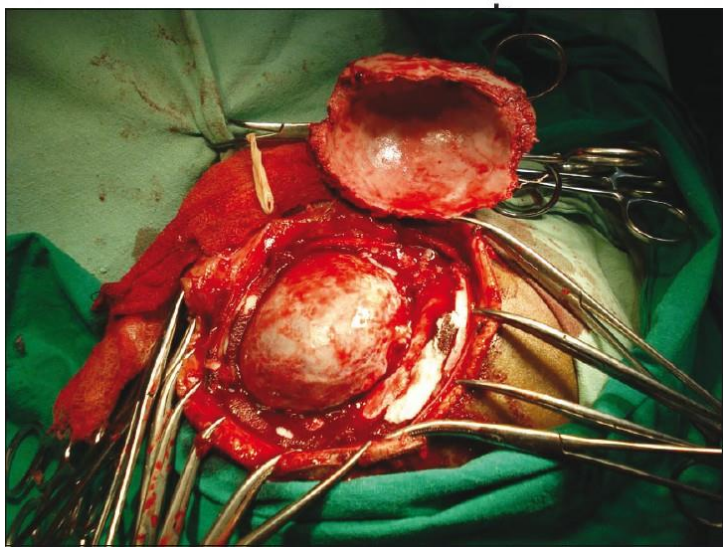

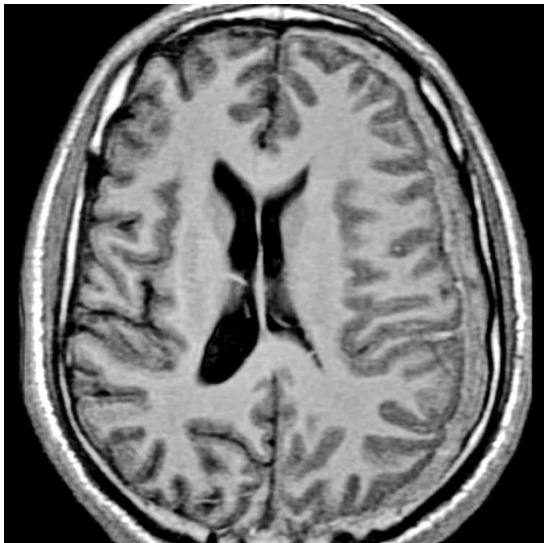

Extracerebral hemorrhages

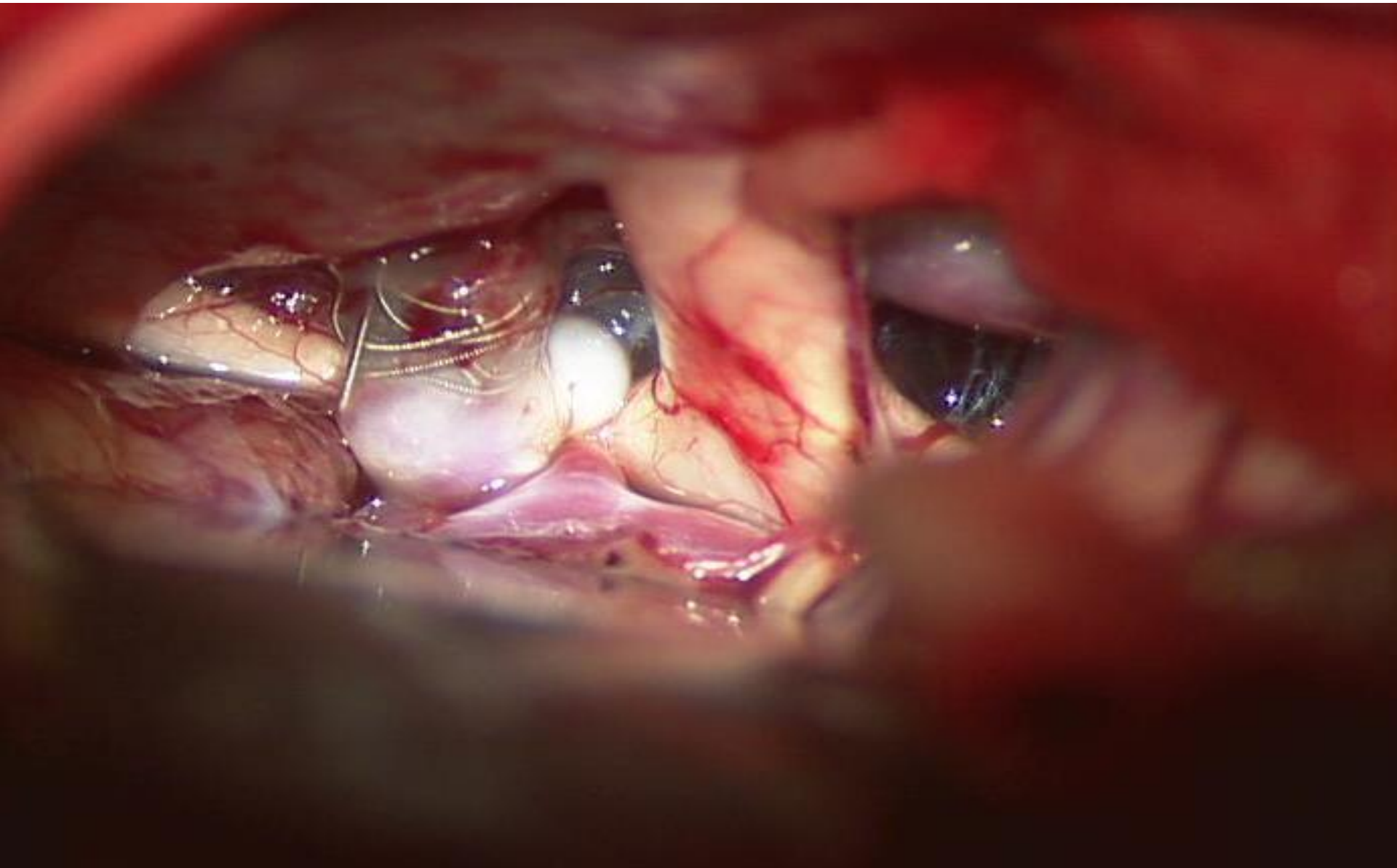

Cerebrovascular diseases

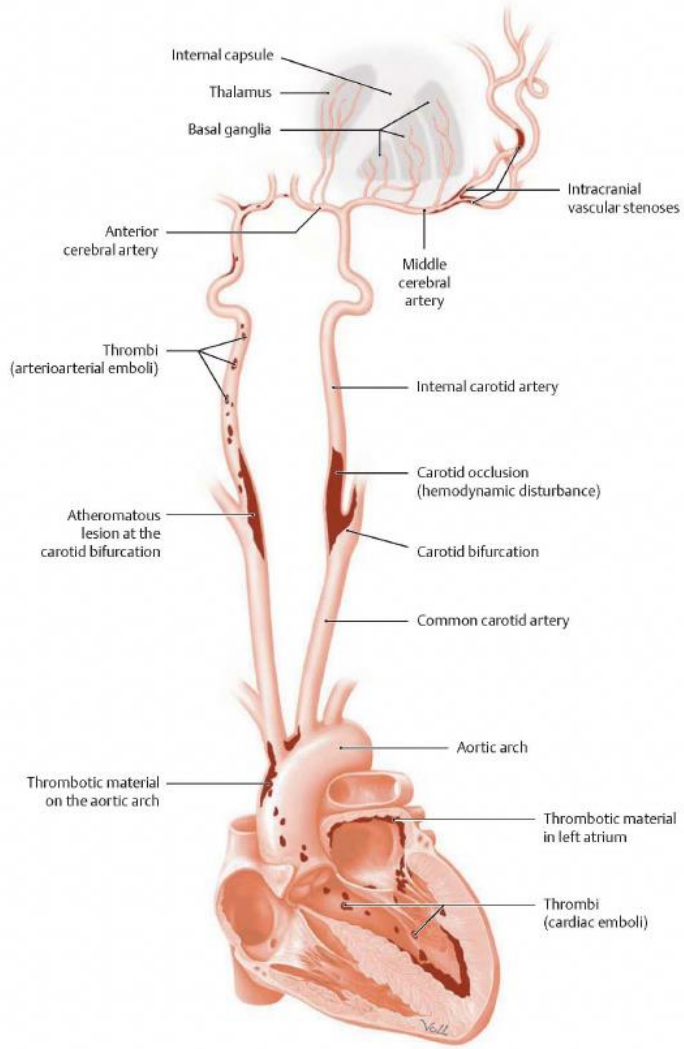

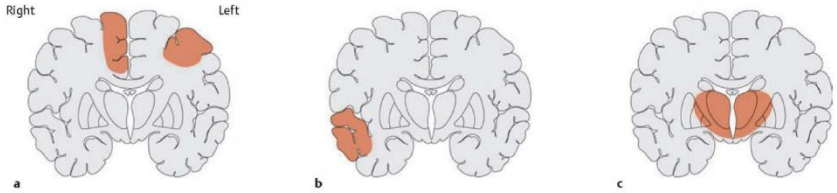

B Cerebral venous thrombosis
Coronal section, anterior view.

a Medial (right) and posterior (left) superior cerebral wein thrombosis.
b Right inferior cerebral vein thrombosis.
c Bilateral thrombosis of internal cerebral veins.

Illustrator: Markus Voll pp. 264-265

Thieme

Vascular territory	Neurological symptoms	
Anterior cerebral artery	Hemiparesis (with or without hemisensory deficit)	Bladder dysfunction
Middle cerebral artery	Hemiparesis (with or without hemisensory deficit) mainly affecting the arm and face (Wernicke-Mann type)	Aphasia
Posterior cerebral artery	Hemisensory losses	Hemianopia

Cortical blindness syndrome

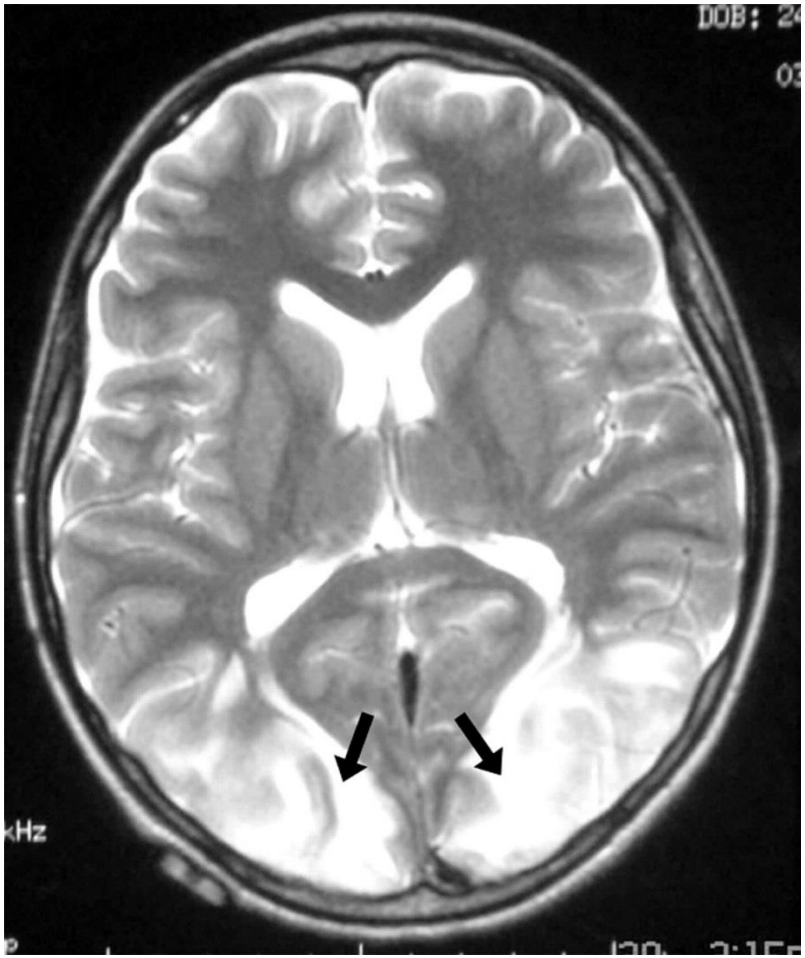

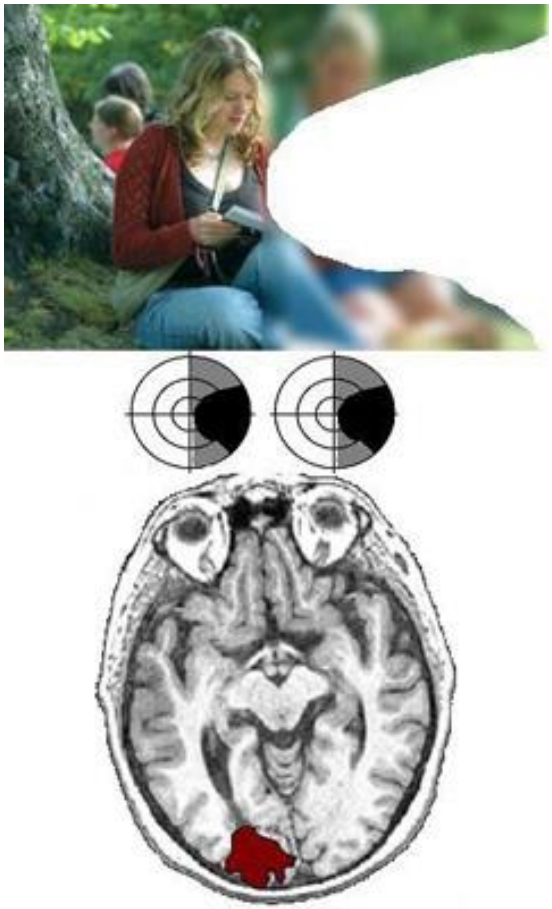

CSF circulation

Chorid plexus and the circulation of CSF

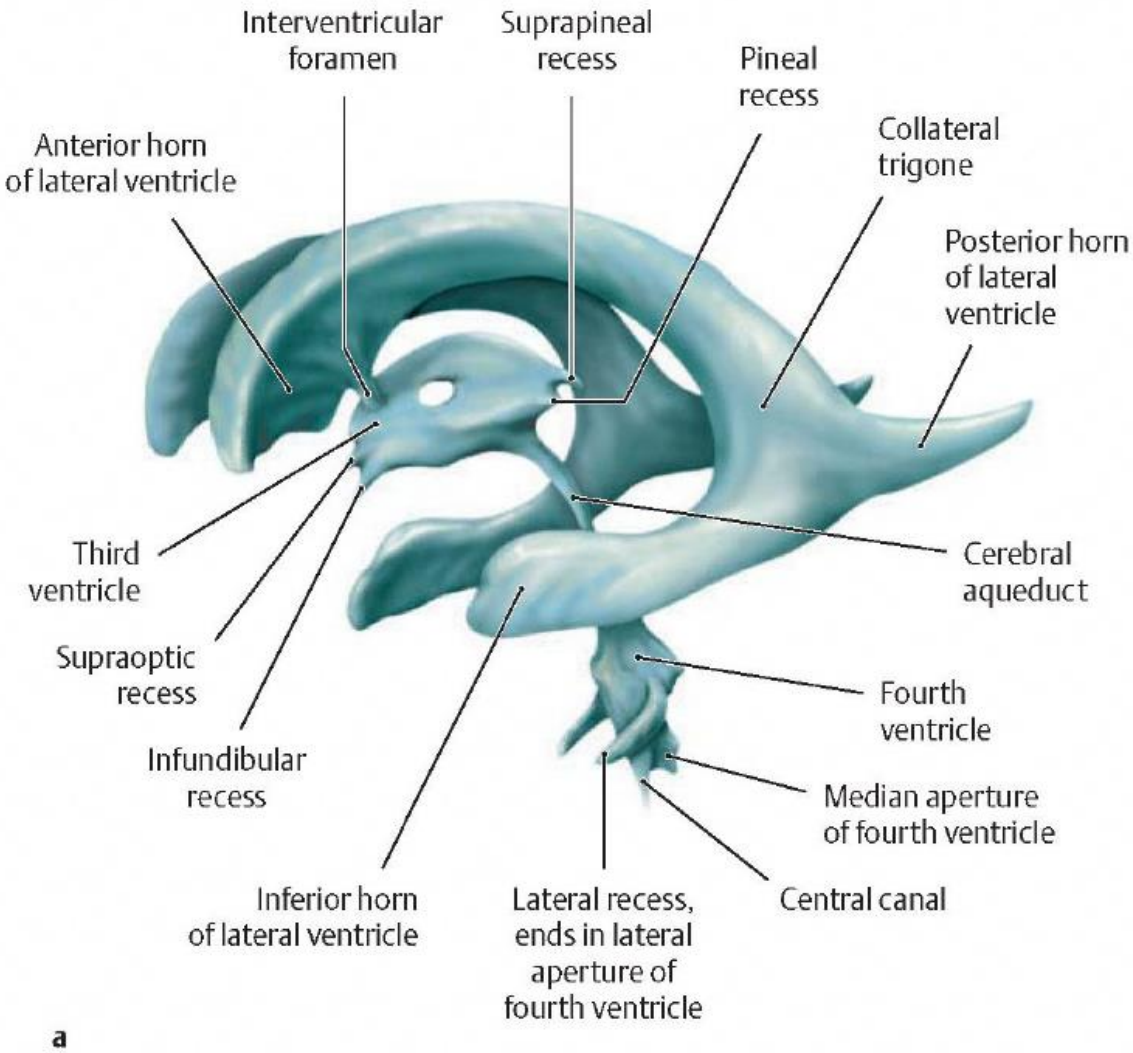

Chorid plexus

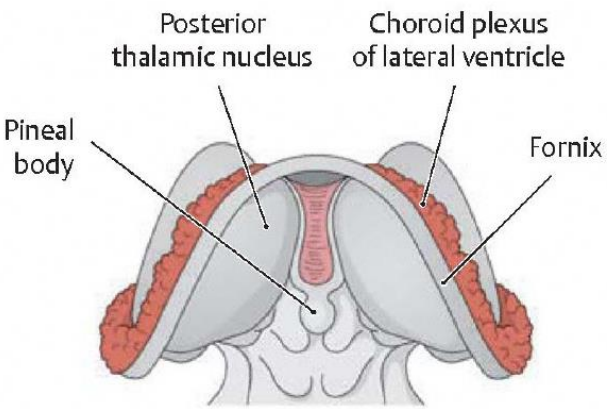

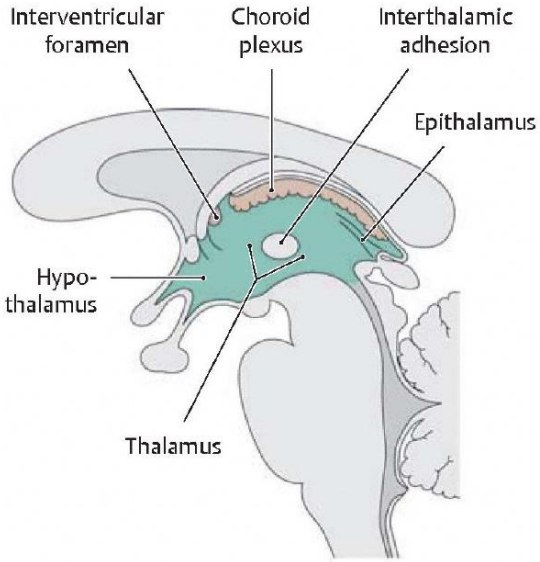

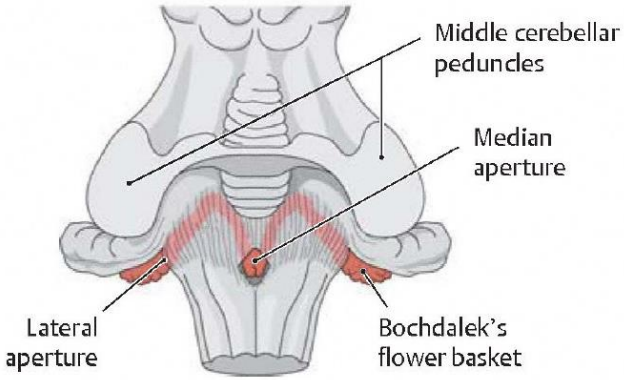

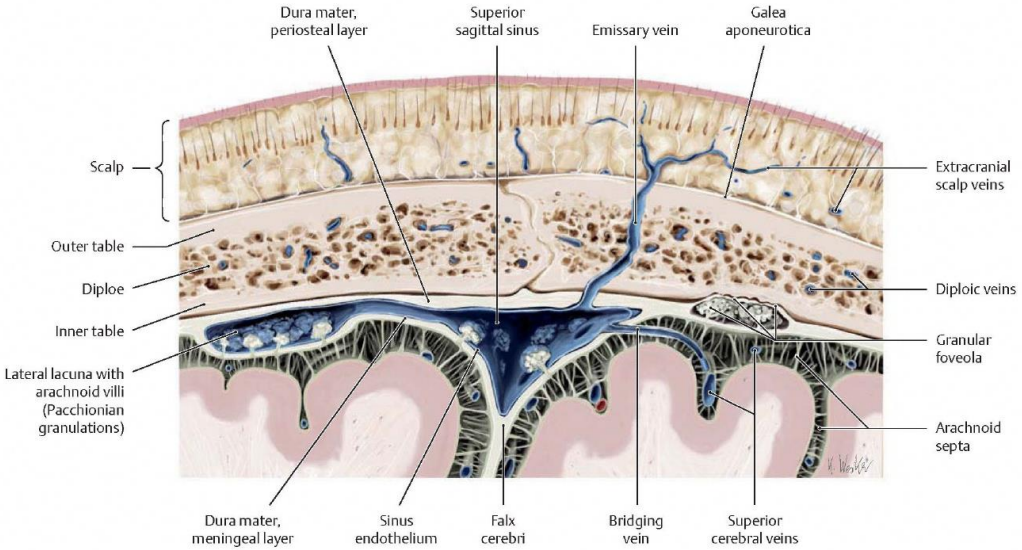

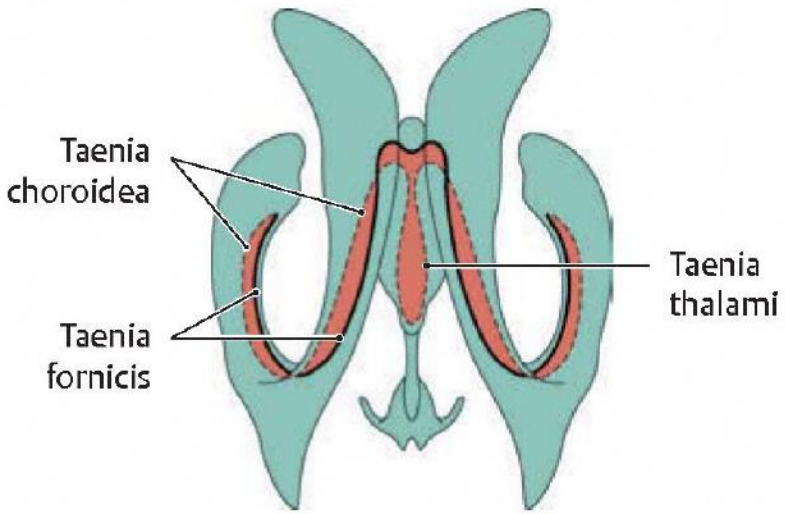
Taenia
choroidea
Taenia
fornicis
Taenia
thalami

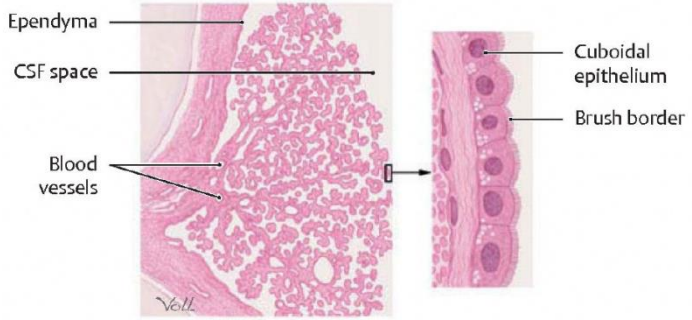
Ependyma
CSF space
Blood
vessels
Cuboidal
epithelium
Brush border

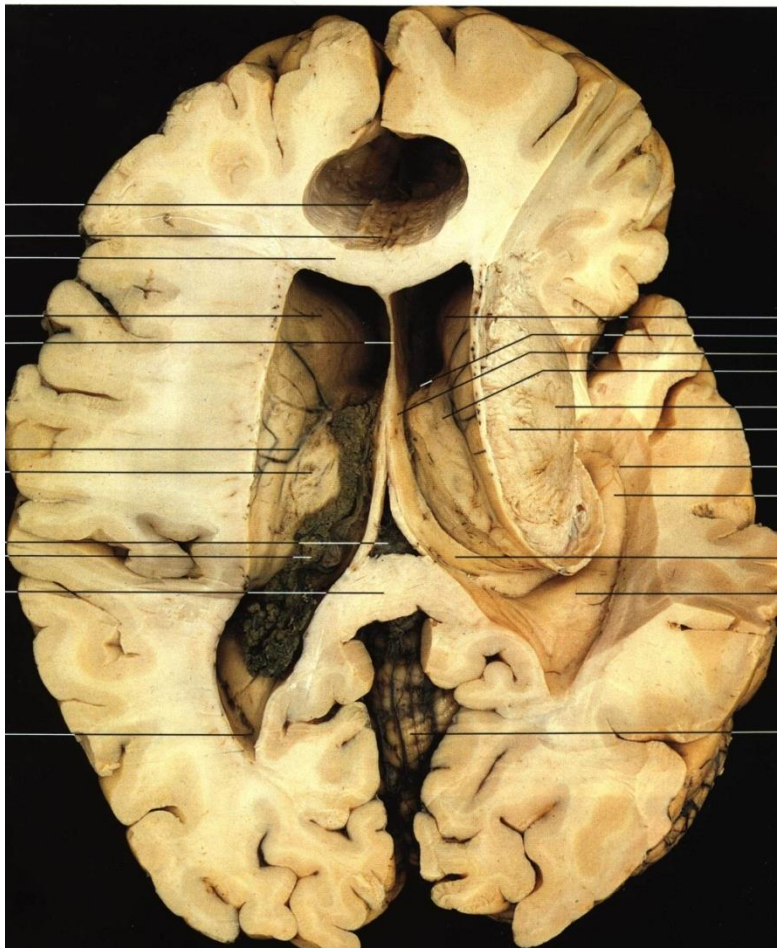

Chorid plexus

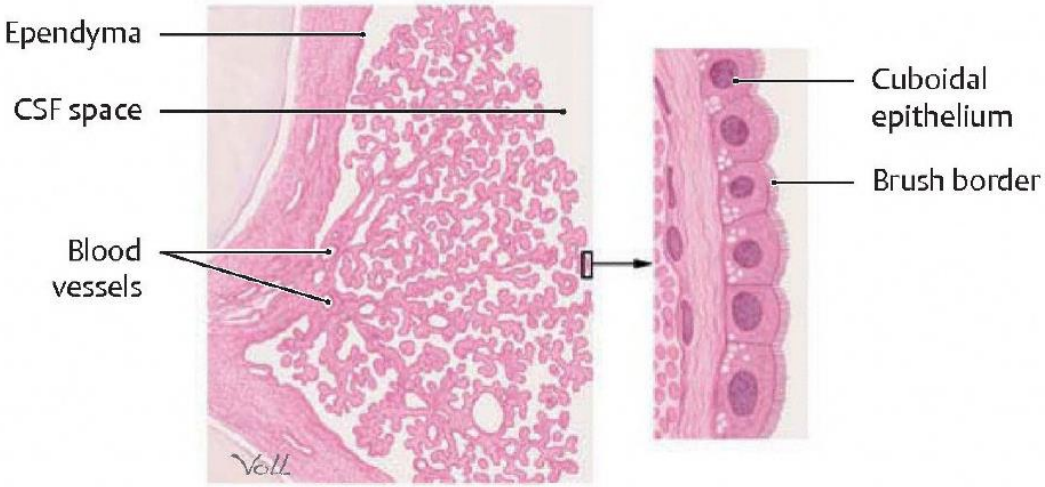

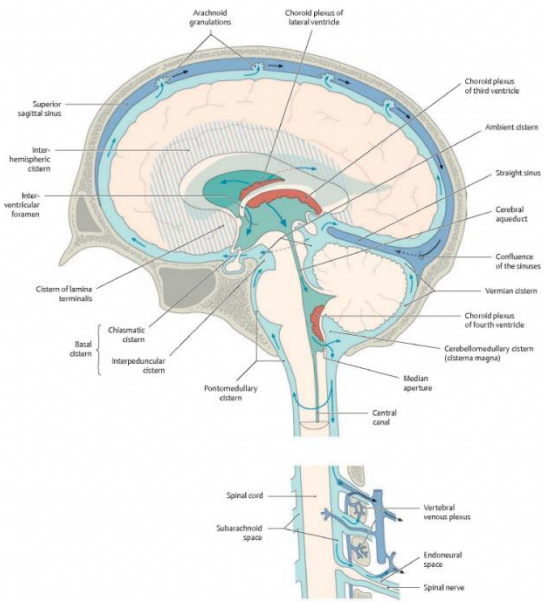

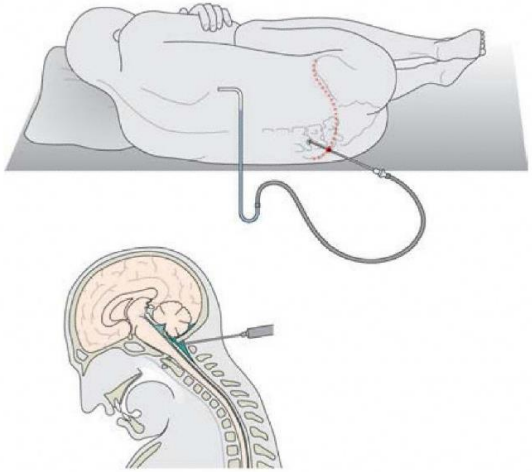

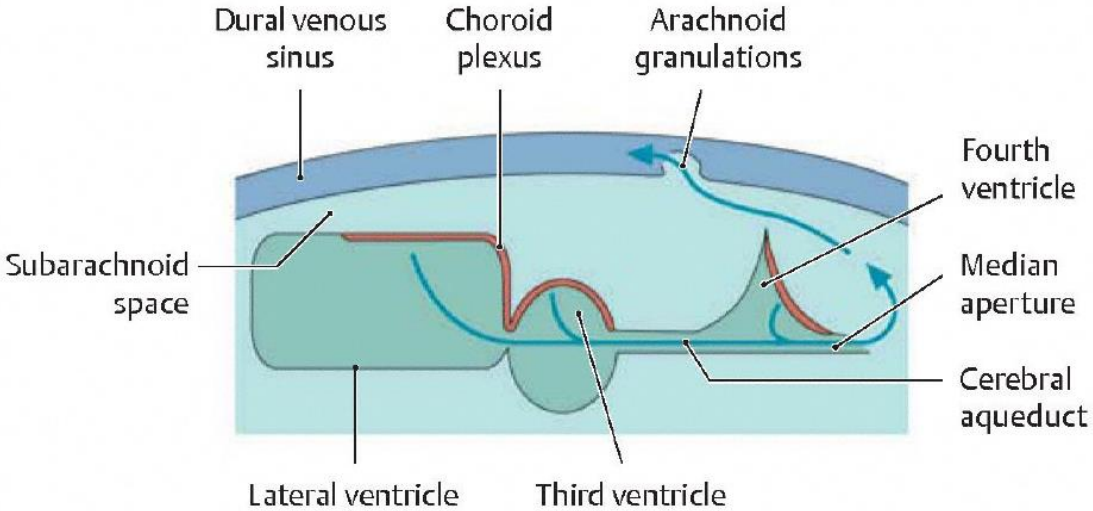

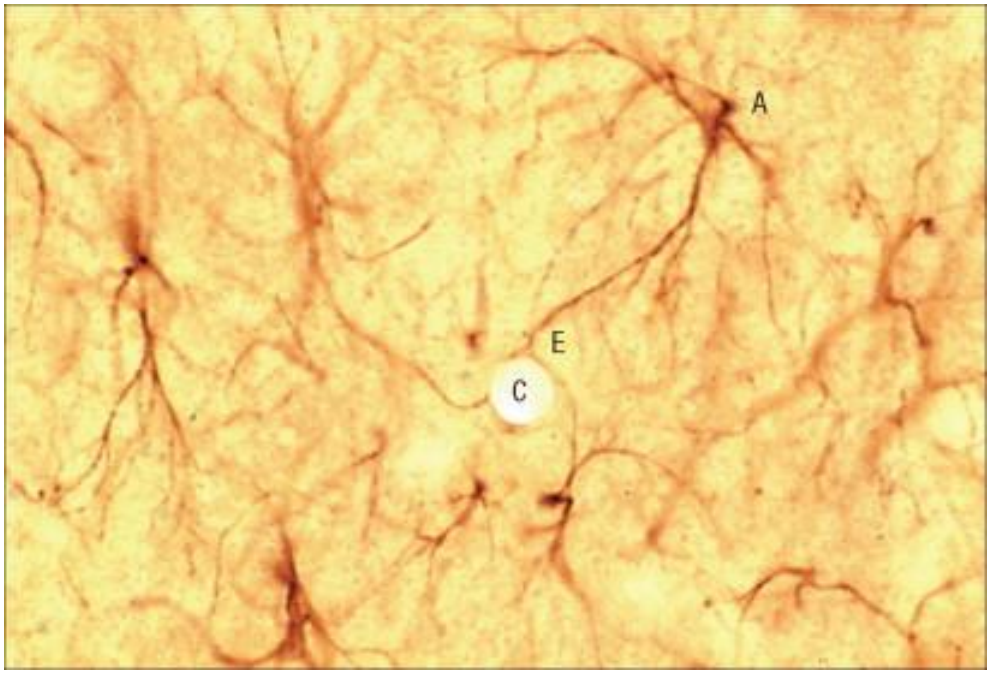

Astrocytes (A) in rat brain, immunolabelled to show glial fibrillary acidic protein (brown). Fine processes form end-feet (E) on brain capillaries (C). Note that astrocytes have extremely dense, numerous processes: immunostaining only reveals a proportion of the processes.

(Prepared by Mr Marios Hadjipavlou, King's College, London.)

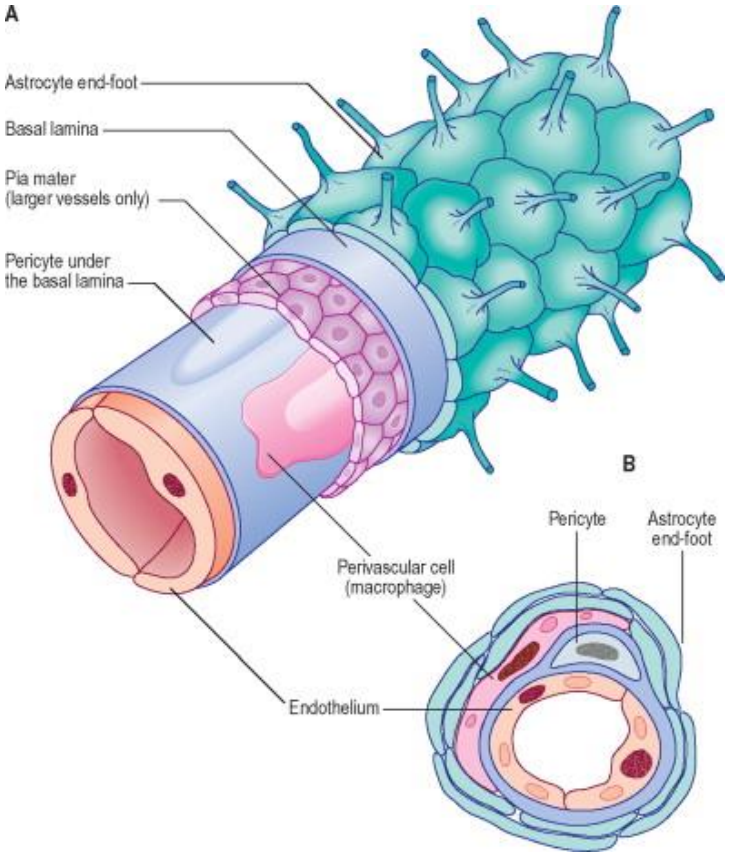

The relationship between the glia limitans, perivascular cells and blood vessels within the brain, in longitudinal and transverse section. A sheath of astrocytic end-feet wraps around the vessel and, in vessels larger than capillaries, its investment of pial meninges. Vascular endothelial cells are joined by tight junctions and supported by pericytes; perivascular macrophages lie outside the endothelial basal lamina.

Blood-brain barrier and blood-CSF barrier

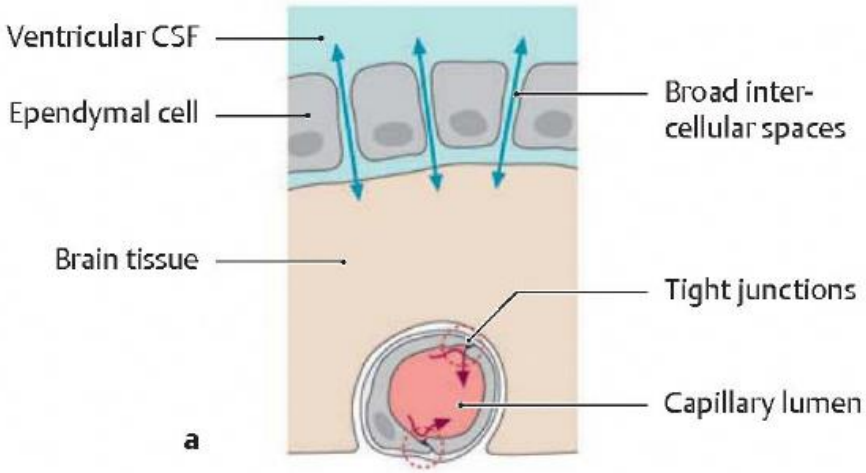

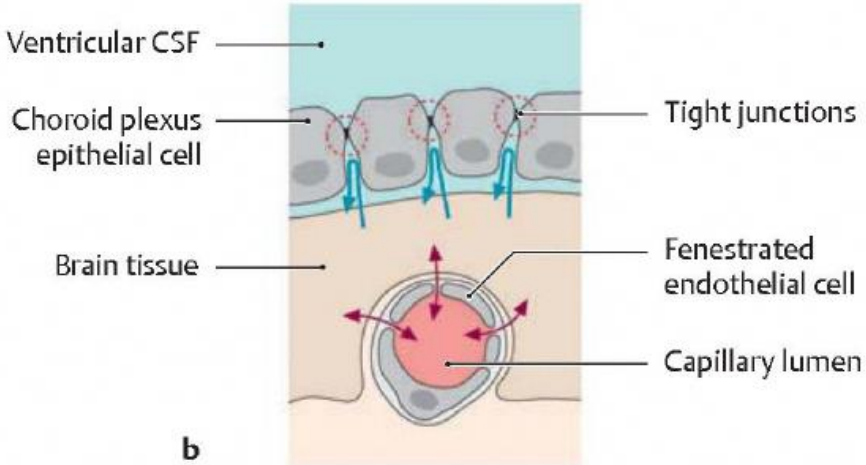

- The blood-brain barrier develops during embryonic life but may not be fully completed by birth.
- There are certain areas of the adult brain where the endothelial cells are not linked by tight junctions, which means that a free exchange of molecules occurs between blood and adjacent brain.
- Most of these areas are situated close to the ventricles and are known as circumventricular organs.
- Elsewhere, unrestricted diffusion through the blood-brain barrier is only possible for substances that can cross biological membranes because of their lipophilic character. Lipophilic molecules may be actively re-exported by the brain endothelium.

Circumventricular organs

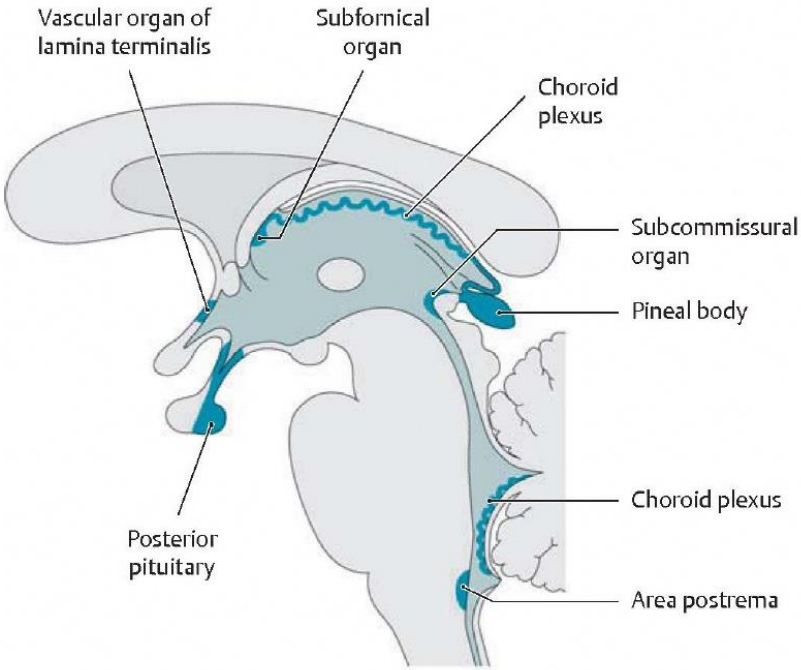

B Summary of the smaller circumventricular organs

Organ	Location	Function
Vascular organ of the lamina terminalis (VOLT)	Vascular loops in the rostral wall of the third ventricle (lamina terminalis); rudimentary in humans	Secretes the regulatory hormones somatostatin, luliberin, and motilin; contains cells sensitive to angiotensin II; is a neuroendocrine mediator
Subfornical organ (SFO)	Fenestrated capillaries between the interventricular foramina and below the fornices	Secretes somatostatin and luliberin from nerve endings; contains cells sensitive to angiotensin II; plays a central role in the regulation of fluid balance ("organ of thirst")
Subcommissural organ (SCO)	Borders on the pineal body; overlies the epithalamic commissure at the junction of the third ventricle and cerebral aqueduct	Secretes glycoproteins into the aqueduct that condense to form the Reissner fiber, which may extend into the central canal of the spinal cord; blood-brain barrier is intact; function is not completely understood
Area postrema (AP)	Paired organs in the floor of the caudal end of the rhomboid fossa, richly vascularized	Trigger zone for the emetic reflex (absence of the blood-brain barrier); atrophies in humans after middle age


THANK
YOU
FOR
YOUR
ATTENTION


If you have one
try to use it
851FACEBOOK.COM
please!